



International Journal of Case Reports (ISSN:2572-8776)



Autologous Tenocyte Implantation for the Treatment of Chronic Degenerative Rotator Cuff Tendinopathy

Bonnie McRae, Jane Fitzpatrick, Hussain Khan

McRae - Australasian College of Sport & Exercise Medicine, Griffith University. Fitzpatrick - University of Melbourne, Australasian College of Sport & Exercise Medicine, Joint Health Institute. Khan - Australasian College of Sport & Exercise Medicine, Olympic Park Sports Medicine Centre

ABSTRACT

The use of injectable cell therapies to treat tendon pathology has become significantly more popular in recent years. They are appealing treatment modalities as they are minimally invasive, autologous, non-surgical management options which theoretically allow tendon regeneration and return to function. This case report will focus on the use of autologous tenocyte implantation (ATI) injection therapy to treat chronic degenerative rotator cuff tendinopathy.

Keywords: autologous tenocyte implantation, chronic rotator cuff tendinopathy, cell therapy

*Correspondence to Author:

Dr Bonnie McRae
Australasian College of Sports &
Exercise Medicine, Griffith University,
BSEMS
drbonniemcrae@gmail.com

How to cite this article:

Bonnie McRae, Jane Fitzpatrick,
Hussain Khan. Autologous Tenocyte
Implantation for the Treatment of
Chronic Degenerative Rotator Cuff
Tendinopathy. International Journal
of Case Reports, 2020 4:124

 eSciPub
eSciPub LLC, Houston, TX USA.
Website: <https://escipub.com/>

INTRODUCTION

Tendon overuse pathology is associated with tenocyte depletion, microscopic collagen breakdown, and failed healing.^{1 2} These changes result in pain and altered function and contribute to tearing at lower strain thresholds. This process is defined as tendinopathy, a term that is inclusive of both tendinosis and tendinitis.³ This correlates to a change in tendon pathology, from angiofibroblastic hyperplasia with disorganisation of collagen fibres to a degenerative state characterised by cellular depletion, collagen discontinuity and small partial tears, eventually resulting in macroscopic tears with bonetendon separation.⁴ Morbidity and disability associated with chronic degenerative tendinopathy may last for months or years, despite appropriate medical care. Chronic de-generative tendinopathy has a poor prognosis, and if left untreated there is high probability of progression to complete mechanical failure and tendon rupture.⁵⁻⁷ A recent meta-analysis demonstrated that in the majority of studies following conservatively treated painful rotator cuff tears or asymptomatic tears that are monitored at regular intervals, slow progression of tear enlargement and muscle degeneration over time.⁷

In sports medicine, rotator cuff tendinopathy and small partial-thickness tears are difficult to treat with considerable controversy among orthopaedic surgeons regarding the optimal management of rotator cuff disease and there is significant variation in the management of cuff tears. Consistent across studies is the finding that increasing age is associated with increased prevalence of rotator cuff pathology as the most common cause of shoulder disability. In patients with chronic degenerative tendinopathy, the current standard of care is surgery, corticosteroid or platelet-rich plasma (PRP) injections. Corticosteroid and PRP injections provide short term pain relief, are minimally invasive, do not require long work absence or rehabilitation to maximise efficacy, and are relatively low in cost, which makes them

attractive to patients. However, there is no evidence base for long-term efficacy of these treatments, and corticosteroid injections carry a known risk of tendon rupture that increases with subsequent treatments.

Surgery is a clinically established treatment modality with an evidence base for efficacy, especially in younger active patients with acute tears, although there is significant variability in failure rates and full restoration of function. Treatment of rotator cuff tears that occur in older patients is more controversial. Many factors including patient age, tear size, tendon retraction, muscle degeneration, and overall healing capacity must be taken into account. A recent meta-analysis, examining the natural history of rotator cuff disease and management implications, recommended maximum conservative treatment for patients older than 65 years as surgery is unlikely to achieve satisfactory tendon healing and improvement in function.⁷ Surgery is also less attractive to patients as it is invasive, expensive, has a higher risk of complications, results in extended absence from work and requires compliance with a prescribed rehabilitation program.

Autologous tenocyte implantation (ATI) is a minimally-invasive, bioengineered treatment that is designed to address the underlying pathology of chronic degenerative tendinopathy by replenishing the local tenocyte population with cultured autologous tenocytes. The Australian Therapeutic Goods Administration approved the manufacture and supply of ATI in 2010, and promising results have been obtained in human studies of lateral epicondylitis, gluteal tendinopathy⁸⁻¹² and rotator cuff tendinopathy in elite athletes.^{8,9}

CASE PRESENTATION

A 77-year-old male presented to the clinic in October 2015 with acute on chronic left shoulder pain. He described a long history of chronic shoulder pain treated by his General Practitioner with physiotherapy, conservative care including injection therapy (prolotherapy) but his pain had not settled and frequently kept him awake at

night. He had suffered an acute exacerbation five months previously, whilst playing golf; he was swinging a soft sand iron and felt severe pain in his left shoulder. Since that time, he had ongoing pain which affected his sleep, pain with any attempts at arm elevation, difficulty with forceful overhead activities with that arm, and was subsequently unable to play golf. On examination he was found to have an normal range of motion, however had positive impingement tests with severe pain on resisted shoulder elevation and abduction, and pain on long head biceps tendon (LHBT) stress testing.

MRI is a commonly used tool in the diagnosis and evaluation of rotator cuff tears and tendinopathies and is considered a reliable tool for diagnosis of shoulder tendinopathy when assessed by a well-trained radiologist.^{13 14} Previous MRI of the shoulder performed July 2015 noted significant pathology, including severe supraspinatus tendinosis with mild muscle belly atrophy and fatty infiltration, moderate subscapularis tendinosis, anteromedial subluxation of the intra-articular LHBT in keeping with a partial tear at the subscapularis insertion, and a multiloculated ganglion cyst with synovitis anteriorly involving the LHBT, subdeltoid and subcoracoid bursae,

coracobrachialis and short head of biceps muscle bellies (Figure 1). The infraspinatus appeared relatively normal. Glenohumeral cartilage was generally preserved throughout the joint. Moderate-severe acromioclavicular degeneration with under-surface spurring and associated subacromial/subdeltoid bursitis was also noted.

The patient underwent review by a sport and exercise physician and had screening blood tests to exclude significant disease which may have compromised or contraindicated ATI. Sterile biopsy of his left patella tendon was performed and sent for culture. In February 2016 the patient underwent ATI reimplantation under aseptic conditions. Half of the cultured cells were injected into the biceps tendon and the remainder injected into the supraspinatus under ultrasound guidance. The patient experienced very little discomfort from the procedure.

At the six-week post-implantation review, the patient was pleased with his progress. He had increased his levels of activity without significant shoulder pain and was able to work in his 11-acre garden with marginal discomfort. He was referred to physiotherapy for a strength-based exercise program focusing on shoulder girdle and rotator cuff strength.

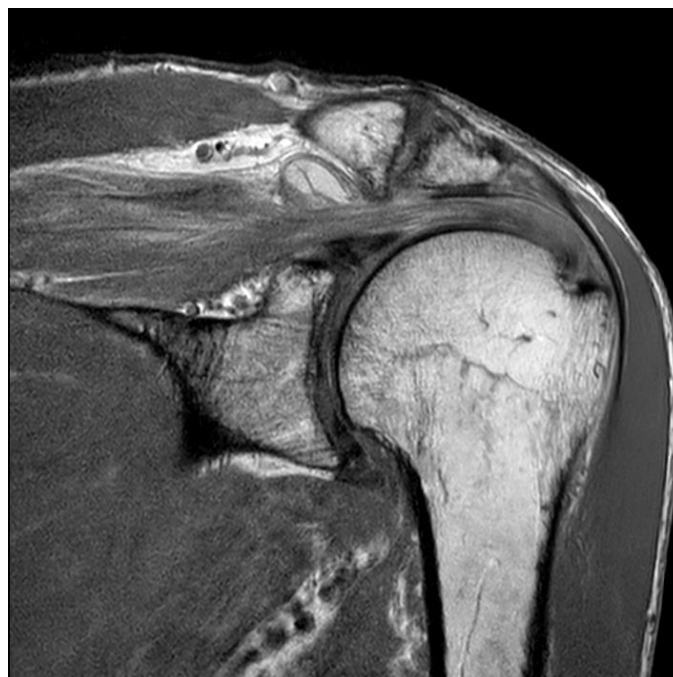

Figure 1. Pre-treatment shoulder MRI

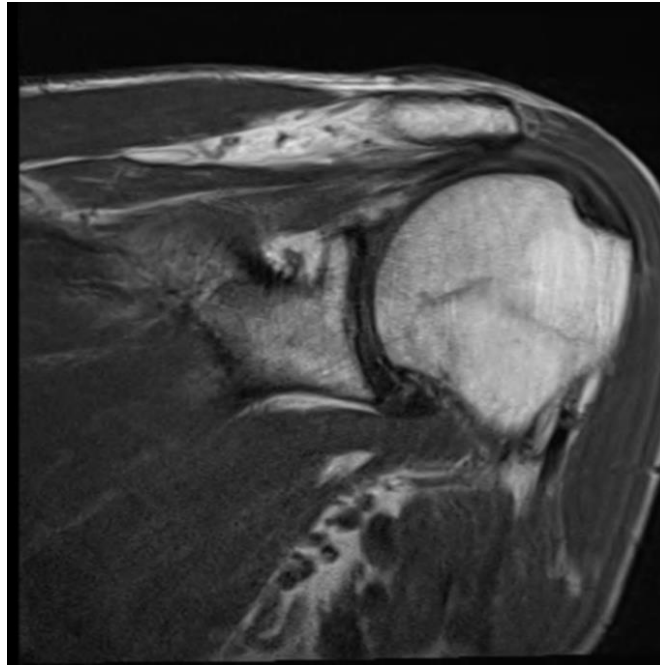


Figure 2. Post-treatment shoulder MRI

Eight months post-implantation (October 2016) the patient was still progressing well. He had returned to sleeping normally without pain, was able to do everything in his garden again and had returned to playing 3-4 holes of golf and hitting well. The patient continued to have symptomatic impingement pain from his ACJ spurring however this was not concerning him and he did not wish to proceed with operative intervention to resolve this.

Repeat MRI in May 2017 demonstrated a reduction in the extensive subdeltoid bursitis previously seen, and resolution of the intramuscular oedema within the supraspinatus muscle (Figure 2). Diffuse marked hyperintensity throughout the supraspinatus and infraspinatus consistent with moderate tendinosis was noted, with minor muscle belly atrophy of the supraspinatus. Minor increased signal intensity of the intra-articular LHBT consistent with minor tendinosis was reported, along with minor insertional tendinosis without tear demonstrated in subscapularis with minor fatty infiltration seen in the inferior muscle belly. ACJ degeneration and subacromial spur were again noted.

Final review more than 12 months following ATI (April 2017) found the patient to be completely symptom-free. He had a complete range of

movement, had returned to playing golf without limitation, and was even able to do 30 push-ups every day without concern.

DISCUSSION

Tendons are hypocellular, collagenous connective tissues which connect muscle to bone, and are integral to the function of the musculoskeletal system through the transmission of force to generate joint movement.³ They are complex structures composed of tenocytes embedded within a dense extracellular matrix (ECM).¹⁵ Healthy tendon has a high proportion of type I collagen (synthesised by tenocytes) arranged in a hierarchical structure which bestows great tensile strength to the tissue and reduced stress exertion during muscle contraction.¹⁵ Tendons are poorly vascularised and principally utilise anaerobic energy systems which results in poor regeneration and healing potential after injury.¹⁵⁻¹⁷

Tendon overuse pathology is associated with tenocyte depletion, microscopic collagen breakdown, and failed healing.^{1 2} These changes result in pain and altered function and contribute to tearing at lower strain thresholds. This process is defined as tendinopathy, a term that is inclusive of both tendinosis and

tendinitis.³ Rotator cuff disease is multifactorial, and includes biologic and mechanical influences. Recent studies have also suggested a strong genetic influence on disease development.^{7 18-20} Degenerative rotator cuff disease is commonly associated with ageing and is often asymptomatic. Pathological studies have demonstrated rotator cuff tenocyte depletion and dysfunction.⁴

Initial management of tendinopathy is conservative and usually prolonged, with a high relapse rate.^{3 15} Rest, physiotherapy, non-steroidal anti-inflammatory drugs (NSAIDs), and injection therapy have formed the mainstay of treatment for rotator cuff tendinopathy. There is moderate evidence to support the role of exercise rehabilitation in tendinopathy, but limited evidence of efficacy for any of the other non-operative treatments.²¹⁻²³ Conflicting and inconsistent evidence exists regarding the clinical efficacy of injection therapies (i.e. corticosteroids and Platelet-Rich Plasma (PRP)) in tendinopathy.⁸ Whilst corticosteroid injection therapy studies have demonstrated short-term benefits of pain relief and improved function, long-term study results tend to report a return of pain, worsening of symptoms, and tendon atrophy and even rupture.^{22 24} Regenerative approaches for tendinopathy include treatment with autologous blood, plasma, or cells (such as autologous mesenchymal stem cells, skin fibroblasts, or tenocytes).⁹ Meta-analysis of the use of PRP for shoulder tendinopathy suggested that PRP fails to enhance clinical outcomes or re-tear rates in the tendon.²⁵ Meta-analysis demonstrated that in the majority of conservatively treated painful rotator cuff tears or asymptomatic tears that are monitored at regular intervals, slow progression of tear with enlargement and muscle degeneration occurs over time.⁷

Surgical repair or reconstruction is typically reserved for large partial and full thickness tears,⁹ or in situations where the normal healing processes cannot occur such as unstable apposition of the free ends.³ Trials of surgical

rotator cuff repairs augmented with PRP^{26 27} and stem cells²⁸ during open or arthroscopic surgery have previously been published, however the outcome benefits have not been scientifically proven. Treatment of atraumatic degenerative rotator cuff tears that occur with advancing age is controversial, and many factors including patient age, tendon retraction, muscle degeneration, and overall healing capacity must be taken into account.⁷ Meta-analysis has demonstrated that surgery is not an effective option and that conservative treatment needs to be maximised in patients where successful tendon healing is unlikely. This groups includes older patients (>65-70 years), patients with chronic full-thickness tears (retracted tears of any size with advanced muscle degeneration), and tears associated with fixed proximal humeral head migration (signs of chronic mechanical contact of the greater tuberosity and acromium).⁷

Ortho-ATI is a Class 3 Biological ATI product manufactured in Australia by OrthoCell since 2008. It is intended for homologous and autologous use only. ATI was approved by the Australian Therapeutic Goods Administration in 2010 for treatment of tendon pathology⁸ as it was deemed safe for human interventions as tenocytes are homologous mature cells that have been previously shown to maintain their cellular phenotype in in vitro culture.^{10 12}

ATI procedure involves a biopsy of a small piece of tissue from a healthy tendon, typically the patellar tendon. The biopsied tendon is screened under ultrasound for abnormality prior to harvesting, and screening tests for consistency of cell morphology are undertaken. Mandatory venous blood sampling is also performed to screen for infection, syphilis, hepatitis, and human immunodeficiency virus prior to the patient being accepted for treatment.⁸ Tendon cells are cultured over 4-5 weeks in a scaffold medium and stored until implantation is carried out via ultrasound guided injection into the affected tendon area.⁸

ATI is seen as a less invasive technique to use before resorting to operative intervention.⁸ It attempts to restore cellular density and counteract the slow rate of healing in tendon injuries by injecting the patient's own cultured tenocyte cells back into the damaged tendon.⁹ It is designed to improve tendon regeneration rather than repair in tendinopathy and tears.³⁻⁸ ATI attempts to disrupt the process of tendon injury (disorganisation of collagen fibres, variation in collagen type, fibroblast proliferation and neovascularisation) and stimulate production of interleukins, growth factors, and ordered collagen fibres to create a better healing response.²⁹ Animal studies have shown increased type 1 collagen synthesis following ATI injection, and tendon healing with regeneration of a normal tendon structure in acute and chronic rotator cuff lesions.²⁹⁻³⁰

Previous studies using ATI have shown promising results for the treatment of lateral elbow, gluteal, and shoulder tendinopathy, with improvement noted in pain, strength, and function in both human and animal studies.⁸⁻¹¹ Whilst not all studies demonstrated MRI changes following ATI injection,¹⁰⁻¹¹ one recent study demonstrated both improved clinical and radiological outcomes in patients with rotator cuff injuries following ATI.⁹

Whilst the patient in our study made excellent clinical improvements following ATI, there are several limitations to this case report. One major limitation is the inability to exclude other intervention variables and categorically determine their contribution to the outcome. The improvement in tendinopathy by the commencement of a physiotherapy program, or simply the natural history of tendon injury healing could have contributed but this patient had had more than three years of symptoms prior as well as previous physiotherapy in that time, so he could be regarded as having natural history resistant disease, which makes it less likely it was the post ATI rehabilitation.

Following the success of cases like this, further high-level research is planned regarding the role

and effect of ATI. An RCT of Ortho-ATI versus corticosteroid injection for treatment of rotator cuff tendinopathy and tear is registered with ANZCTR (ACTRN12617000684325) and currently recruiting patients in Australia. Another trial (ACTRN12616000458437) is currently recruiting patients with severe chronic resistant lateral epicondylitis for a randomised study comparing Ortho-ATI with surgery. With the completion of multiple high yield randomised studies in the next few years, further reliable data regarding the efficacy of ATI will be available for future clinical management of patients.

CONCLUSIONS

- ATI is an easy, relatively non-invasive, low-risk intervention that has the potential to change the way chronic tendinopathies are managed.
- ATI appears to be a good option for conservative management of tendinopathy, especially in the populations who do not want/are at high risk from complications of surgery.
- ATI may produce better results when combined with physiotherapy, compared to just ATI or physiotherapy alone. This requires further research.
- Whilst ATI shows promising results in case reports and animal studies, further research with RCTs is required to explore the role ATI has in the treatment of tendinopathy in humans.

PATIENT'S PERSPECTIVE

"My shoulder is now functional for all tasks that I require eg: gardening, golf, push-ups etc. Before the treatment I was restricted to approximately 20%. I could not play golf or do push-ups at all"

REFERENCES

1. Khan KM, Cook JL, Bonar F, et al. Histopathology of common tendinopathies. Update and implications for clinical management. *Sports Med* 1999;27(6):393-408. doi: 10.2165/00007256-199927060-00004

2. Cook JL, Purdam CR. Is tendon pathology a continuum? A pathology model to explain the clinical presentation of load-induced tendinopathy. *Br J Sports Med* 2009;43(6):409-16. doi: 10.1136/bjism.2008.051193
3. Young M. Stem cell applications in tendon disorders: a clinical perspective. *Stem Cells Int* 2012;2012:637836. doi: 10.1155/2012/637836
4. Wu B, Chen J, Dela Rosa T, et al. Cellular response and extracellular matrix breakdown in rotator cuff tendon rupture. *Arch Orthop Trauma Surg* 2011;131(3):405-11. doi: 10.1007/s00402-010-1157-5
5. Bhabra G, Wang A, Ebert JR, et al. Lateral Elbow Tendinopathy: Development of a Pathophysiology-Based Treatment Algorithm. *Orthop J Sports Med* 2016;4(11):2325967116670635. doi: 10.1177/2325967116670635 published Online First: 2016/11/12
6. Chen J, Wang A, Xu J, et al. In chronic lateral epicondylitis, apoptosis and autophagic cell death occur in the extensor carpi radialis brevis tendon. *J Shoulder Elbow Surg* 2010;19(3):355-62. doi: 10.1016/j.jse.2009.07.064 published Online First: 2009/10/20
7. Hsu J, Keener JD. Natural History of Rotator Cuff Disease and Implications on Management. *Oper Tech Orthop* 2015;25(1):2-9. doi: 10.1053/j.oto.2014.11.006
8. Schwab LM, Blanch P, Young M. Autologous tenocyte implantation into shoulder tendon pathology in an elite swimmer. *Physical therapy in sport : official journal of the Association of Chartered Physiotherapists in Sports Medicine* 2018;29:19-25. doi: 10.1016/j.ptsp.2017.10.004 published Online First: 2017/11/21
9. Wang AW, Bauer S, Goonatillake M, et al. Autologous tenocyte implantation, a novel treatment for partial-thickness rotator cuff tear and tendinopathy in an elite athlete. *BMJ case reports* 2013;2013 doi: 10.1136/bcr-2012-007899 published Online First: 2013/01/15
10. Bucher TA, Ebert JR, Smith A, et al. Autologous Tenocyte Injection for the Treatment of Chronic Recalcitrant Gluteal Tendinopathy: A Prospective Pilot Study. *Orthop J Sports Med* 2017;5(2):2325967116688866. doi: 10.1177/2325967116688866
11. Wang A, Mackie K, Bredahl W, et al. Evidence for the Durability of Autologous Tenocyte Injection for Treatment of Chronic Resistant Lateral Epicondylitis: Mean 4.5-Year Clinical Follow-up. *Am J Sports Med* 2015;43(7):1775-83. doi: 10.1177/0363546515579185
12. Wang A, Bredahl W, Mackie KE, et al. Autologous tenocyte injection for the treatment of severe, chronic resistant lateral epicondylitis: a pilot study. *Am J Sports Med* 2013;41(12):2925-32. doi: 10.1177/0363546513504285
13. Morag Y, Jamadar DA, Miller B, et al. The subscapularis: anatomy, injury, and imaging. *Skeletal Radiol* 2011;40(3):255-69. doi: 10.1007/s00256-009-0845-0
14. Sein ML, Walton J, Linklater J, et al. Reliability of MRI assessment of supraspinatus tendinopathy. *Br J Sports Med* 2007;41(8):e9. doi: 10.1136/bjism.2006.034421
15. Ho JO, Sawadkar P, Mudera V. A review on the use of cell therapy in the treatment of tendon disease and injuries. *J Tissue Eng* 2014;5:2041731414549678. doi: 10.1177/2041731414549678
16. Vailas AC, Tipton CM, Laughlin HL, et al. Physical activity and hypophysectomy on the aerobic capacity of ligaments and tendons. *J Appl Physiol Respir Environ Exerc Physiol* 1978;44(4):542-6. doi: 10.1152/jappl.1978.44.4.542
17. Kannus P, Jozsa L. Histopathological changes preceding spontaneous rupture of a tendon. A controlled study of 891 patients. *J Bone Joint Surg Am* 1991;73(10):1507-25.
18. Harvie P, Ostlere SJ, Teh J, et al. Genetic influences in the aetiology of tears of the rotator cuff. Sibling risk of a full-thickness tear. *J Bone Joint Surg Br* 2004;86(5):696-700.
19. Tashjian RZ, Farnham JM, Albright FS, et al. Evidence for an inherited predisposition contributing to the risk for rotator cuff disease. *J Bone Joint Surg Am* 2009;91(5):1136-42. doi: 10.2106/JBJS.H.00831
20. Gwilym SE, Watkins B, Cooper CD, et al. Genetic influences in the progression of tears of the rotator cuff. *J Bone Joint Surg Br* 2009;91(7):915-7. doi: 10.1302/0301-620X.91B7.22353
21. Andres BM, Murrell GA. Treatment of tendinopathy: what works, what does not, and what is on the horizon. *Clin Orthop Relat Res* 2008;466(7):1539-54. doi: 10.1007/s11999-008-0260-1
22. Coombes BK, Bisset L, Vicenzino B. Efficacy and safety of corticosteroid injections and other injections for management of tendinopathy: a systematic review of randomised controlled trials. *Lancet* 2010;376(9754):1751-67. doi: 10.1016/S0140-6736(10)61160-9
23. de Vos RJ, Weir A, van Schie HT, et al. Platelet-rich plasma injection for chronic Achilles tendinopathy: a randomized controlled trial. *JAMA* 2010;303(2):144-9. doi: 10.1001/jama.2009.1986

24. Buchbinder R, Green S, Youd JM. Corticosteroid injections for shoulder pain. *Cochrane Database Syst Rev* 2003(1):CD004016. doi: 10.1002/14651858.CD004016
25. Saltzman BM, Jain A, Campbell KA, et al. Does the Use of Platelet-Rich Plasma at the Time of Surgery Improve Clinical Outcomes in Arthroscopic Rotator Cuff Repair When Compared With Control Cohorts? A Systematic Review of Meta-analyses. *Arthroscopy* 2016;32(5):906-18. doi: 10.1016/j.arthro.2015.10.007
26. Castricini R, Longo UG, De Benedetto M, et al. Platelet-rich plasma augmentation for arthroscopic rotator cuff repair: a randomized controlled trial. *Am J Sports Med* 2011;39(2):258-65. doi: 10.1177/0363546510390780
27. Randelli P, Arrigoni P, Ragone V, et al. Platelet rich plasma in arthroscopic rotator cuff repair: a prospective RCT study, 2-year follow-up. *J Shoulder Elbow Surg* 2011;20(4):518-28. doi: 10.1016/j.jse.2011.02.008
28. Ellera Gomes JL, da Silva RC, Silla LM, et al. Conventional rotator cuff repair complemented by the aid of mononuclear autologous stem cells. *Knee Surg Sports Traumatol Arthrosc* 2012;20(2):373-7. doi: 10.1007/s00167-011-1607-9
29. Chen J, Yu Q, Wu B, et al. Autologous tenocyte therapy for experimental Achilles tendinopathy in a rabbit model. *Tissue Eng Part A* 2011;17(15-16):2037-48. doi: 10.1089/ten.TEA.2010.0492
30. Chen JM, Willers C, Xu J, et al. Autologous tenocyte therapy using porcine-derived bioscaffolds for massive rotator cuff defect in rabbits. *Tissue Eng* 2007;13(7):1479-91. doi: 10.1089/ten.2006.0266





Minerva Access is the Institutional Repository of The University of Melbourne

Author/s:

McRae, B; Fitzpatrick, M; Khan, H

Title:

Autologous Tenocyte Implantation for the Treatment of Chronic Degenerative Rotator Cuff Tendinopathy

Date:

2020

Citation:

McRae, B., Fitzpatrick, M. & Khan, H. (2020). Autologous Tenocyte Implantation for the Treatment of Chronic Degenerative Rotator Cuff Tendinopathy. *International Journal of Case Reports*, 4 (124), <https://doi.org/10.28933/ijcr-2020-02-0805>.

Persistent Link:

<http://hdl.handle.net/11343/235909>

File Description:

Published version