

# Subcutaneous ICD lead position affects defibrillation threshold



Hariharan Sugumar, MBBS, BMedSci,<sup>\*†‡§||</sup> Matthew K. Tung, MBBS,<sup>\*</sup> Arthur J. Lee, MD,<sup>¶</sup> Jamil Bashir, MD,<sup>¶</sup> Christopher Lane, MD<sup>\*</sup>

From the <sup>\*</sup>Royal Jubilee Hospital, Victoria, Canada, <sup>†</sup>The Baker Heart & Diabetes Institute, Melbourne, Australia, <sup>‡</sup>The Alfred Hospital, Melbourne, Australia, <sup>§</sup>Royal Melbourne Hospital, Melbourne, Australia, <sup>||</sup>University of Melbourne, Melbourne, Australia, and <sup>¶</sup>University of British Columbia Division of Cardiovascular Surgery, St. Paul's Hospital, Providence Health, Vancouver, Canada.

## Introduction

Subcutaneous implantable cardioverter-defibrillators (S-ICD) provide an alternative to traditional transvenous implantable cardioverter-defibrillators (TV-ICD) and avoid complications associated with intravascular access and leads. They are highly effective in detecting and treating ventricular arrhythmias, with comparable inappropriate shock rates.<sup>1</sup> Use of S-ICD is anticipated to increase significantly.<sup>2</sup>

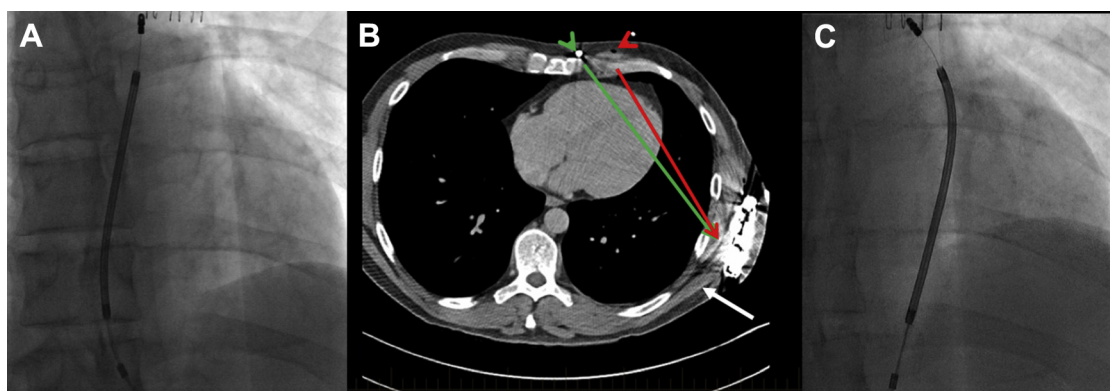
Defibrillation testing (DT) is no longer routinely recommended for TV-ICDs.<sup>3</sup> Although S-ICD systems have high rates of successful defibrillation threshold, DT is routinely recommended as part of the procedure. Implant factors that affect defibrillation threshold have not been fully evaluated. Initial experience has suggested that factors such as amount of adipose tissue below the coil and generator, along with

the transverse position of the generator, affect defibrillation threshold.<sup>4</sup> There is increasing opinion that DT may not be needed for S-ICD systems owing to their efficacy in the future.

We describe a case with suboptimal DT outcomes owing to lead position.

## Case report

A 40-year-old man with a structurally normal heart had an S-ICD for secondary prevention. The initial part of the procedure was uneventful, with a S-ICD generator (Cameron Health/Boston Scientific Inc., Minneapolis–St. Paul, MN–A 209 Emblem) placed over the left lateral chest wall muscle (Figure 1B, white arrow) and a Boston Scientific 3401 Emblem S-ICD 45 cm lead tunneled immediately over the



**Figure 1** A: Radiograph in straight posterior-anterior (PA) view showing position of subcutaneous implantable cardioverter-defibrillator lead after repositioning with successful defibrillator testing at 65 J. B: Computed tomography image demonstrating improved shock vector. Initial lead position (red arrow) and final lead position (green arrow). C: Initial lead position, which failed to defibrillate at 80 J, in straight PA view.

**KEYWORDS** Failure to defibrillate; High threshold; Reposition lead; Subcutaneous ICD; Shock vector; Screening at implant (Heart Rhythm Case Reports 2018;4:29–30)

**Address reprint requests and correspondence:** Hariharan Sugumar, Royal Jubilee Hospital, VIHA, 1952 Bay St, Victoria, BC V8R 1J8, Canada. E-mail address: [hsugumar@yahoo.com](mailto:hsugumar@yahoo.com).

fascial layer in the left parasternal position using the 3-incision technique. The sensing and impedance (69  $\Omega$ ) values were within normal limits. DT failed at 65 J and twice at 80 J despite adequate and appropriate sensing. Fluoroscopy revealed that the lead position was lateral to the midline (Figure 1C; position C). The lead was then re-tunneled and

## KEY TEACHING POINTS

- Defibrillation testing (DT) is successful in the majority of subcutaneous implantable cardioverter-defibrillator (S-ICD) cases.
- In cases where DT is unsuccessful, in addition to structural causes, lead position and shock vector need to be considered.
- The S-ICD lead can be safely repositioned at the time of implant and may improve DT in selected cases.
- Intraoperative fluoroscopy may assist with confirming adequate lead position at the time of implant.

placed 2 cm more medially and directly adjacent to the sternum (Figure 1A; position A). The impedance was now 62  $\Omega$ , with DT now successful at 65 J with appropriate sensing. The patient's implant and recovery were otherwise unremarkable. His follow-up computed tomography (CT) demonstrates that the shock vector improved following the lead repositioning from position C (Figure 1B, red arrow) to position A (Figure 1B, green arrow). The additional myocardium subtended by the revised shock vector was thought to account for the DT results. Video images of the fluoroscopic acquisition in positions C and A at the time of implant are attached as supplementary material.

## Discussion

A limitation of our case report is that defibrillation is a probabilistic phenomenon, which may have caused our first defibrillation attempts to be ineffective and which may have been successful with further shocks. Nonetheless, shock vector is an important consideration in TV-ICD implantation, and it certainly should be no different in S-ICD implantation. As illustrated in this case, a small change in lead position has significant impact on defibrillation threshold in S-ICD implants. There is a reluctance to reposition the S-ICD lead once implanted. However, as shown in our case, repositioning is feasible and safe and will provide long-term benefit. The most recent and largest analysis of the S-ICD implant

and follow-up showed that S-ICD repositioning was required in up to 3.5% of cases and that DT failed in 1.3% of patients.<sup>5</sup>

One perceived advantage of an S-ICD system is that the procedure can be performed without the need for ionizing radiation. Many centers do not use fluoroscopy for S-ICD implant. However, as this case demonstrates, it may be of benefit to visualize the final lead position at the end of implant to exclude bowing of the defibrillation coil away from the midline. This could simply avoid futile defibrillation attempts and allow the operator the option of repositioning the lead.

Preimplant screening with surface electrocardiogram/sensing does not include assessment of ideal shock vector based on anatomy. Preimplant planning may be improved with CT, allowing better definition of cardiac anatomy and optimization of shock vector in addition to the manufacturer's standard patient screening tool.

Intraoperative fluoroscopy may assist in confirming lead position prior to DT. Alternatively, if DT fails, consideration for examining the position of the lead with respect to the myocardium should be undertaken. When required, intraoperative S-ICD lead repositioning is safe and can improve defibrillation threshold in selected patients.

## Appendix Supplementary data

Supplementary data associated with this article can be found in the online version at <https://doi.org/10.1016/j.hrcr.2017.10.017>.

## References

1. Burke MC, Gold MR, Knight BP, et al. Safety and efficacy of the totally subcutaneous implantable defibrillator: 2-year results from a pooled analysis of the IDE Study and EFFORTLESS Registry. *J Am Coll Cardiol* 2015;65:1605–1615.
2. Friedman DJ, Parzynski CS, Varosy PD, Prutkin JM, Patton KK, Mithani A, Russo AM, Curtis JP, Al-Khatib SM. Trends and in-hospital outcomes associated with adoption of the subcutaneous implantable cardioverter defibrillator in the United States. *JAMA Cardiol* 2016;1(8):900–911.
3. Healey JS, Hohnloser SH, Glikson M, et al. Cardioverter defibrillator implantation without induction of ventricular fibrillation: a single-blind, non-inferiority, randomised controlled trial (SIMPLE). *Lancet* 2015;385:785–791.
4. Heist K, Stahl W, Belalcazar A. AB01-01 to AB41-06: AB05-03-Impact of generator location and sub-coil fat on subcutaneous-ICD defibrillation thresholds. *Heart Rhythm* 2016;13:S11–S12.
5. Gold MR, Aasbo JD, El-Chami MF, et al. Subcutaneous implantable cardioverter-defibrillator Post-Approval Study: clinical characteristics and perioperative results. *Heart Rhythm* 2017;14(10):1456–1463.



Minerva Access is the Institutional Repository of The University of Melbourne

**Author/s:**

Sugumar, H; Tung, MK; Lee, AJ; Bashir, J; Lane, C

**Title:**

Subcutaneous ICD lead position affects defibrillation threshold.

**Date:**

2018-01

**Citation:**

Sugumar, H., Tung, M. K., Lee, A. J., Bashir, J. & Lane, C. (2018). Subcutaneous ICD lead position affects defibrillation threshold.. HeartRhythm Case Rep, 4 (1), pp.29-30.  
<https://doi.org/10.1016/j.hrcr.2017.10.017>.

**Persistent Link:**

<http://hdl.handle.net/11343/255956>

**File Description:**

Published version

**License:**

CC BY-NC-ND