



## Trans-cervical resection of a separate substernal goitre



Henry To<sup>a,\*</sup>, Antara Karmakar<sup>a</sup>, Stephen Farrell<sup>b</sup>, Steve Manolas<sup>a</sup>

<sup>a</sup> Department of Surgery, The Northern Hospital, 185 Cooper St, Epping, Victoria, 3076, Australia

<sup>b</sup> Department of Surgery, St Vincent's Hospital, Victoria St, Fitzroy, 3065, Australia

### ARTICLE INFO

#### Article history:

Received 18 September 2017

Accepted 6 November 2017

Available online 10 November 2017

#### Keywords:

Goitre

Sub-sternal

Ectopic thyroid

Sternotomy

### ABSTRACT

**INTRODUCTION:** A separate substernal goitre which is not continuous with the main cervical thyroid proves a unique challenge for resection. A trans-cervical approach is preferred but may be hazardous due to the possibility of ectopic thyroid tissue with alternate blood supply.

**PRESENTATION OF CASE:** A 72 year old female who had a previous left hemithyroidectomy presents with a symptomatic central substernal thyroid mass. Following radiological work-up, the separate goitre was carefully removed via a trans-cervical approach and avoidance of sternotomy. She had a rapid recovery without complication.

**DISCUSSION:** The anatomy and embryology of substernal masses need to be carefully considered particularly if the mass is ectopic thyroid tissue. Careful pre-operative assessment may determine its nature and anatomical features. Intra-operative dissection requires consideration of blood supply and surrounding structures, but often may be and is best completed via a cervical approach to minimise morbidity. Review of the literature affirms the preference for a trans-cervical approach and offers criteria for successful resection via this method.

**CONCLUSION:** Confirming the nature and anatomy of a separate substernal goitre enables successful removal of the mass via a trans-cervical approach with minimal morbidity.

© 2017 The Author(s). Published by Elsevier Ltd on behalf of IJS Publishing Group Ltd. This is an open access article under the CC BY-NC-ND license (<http://creativecommons.org/licenses/by-nc-nd/4.0/>).

### 1. Introduction

Removal of a substernal goitre is generally indicated for symptomatic lesions, and asymptomatic lesions where there is a concern for compression or malignancy. It may be completed via a trans-cervical or trans-thoracic approach [1]. Careful workup, predominantly via imaging [2], aids in the approach. In the case of a separate substernal thyroid goitre, there is potential for alternative blood supply due to the nature of its origin, whether residual thyroid tissue that has descended from the cervical region, ectopic thyroid tissue or a separate mediastinal mass [3]. A trans-thoracic approach has advantages of improving access for safe dissection away from vital structures, predominantly vascular structures. However, this approach has increased morbidity [4]. This case report highlights the pre- and intra-operative considerations for the appropriate approach to a separate substernal goitre. This work has been reported in line with the SCARE criteria [5].

### 2. Presentation of case

A 72-year-old female presented with respiratory and minor voice changes. She had a left hemithyroidectomy for multinodular

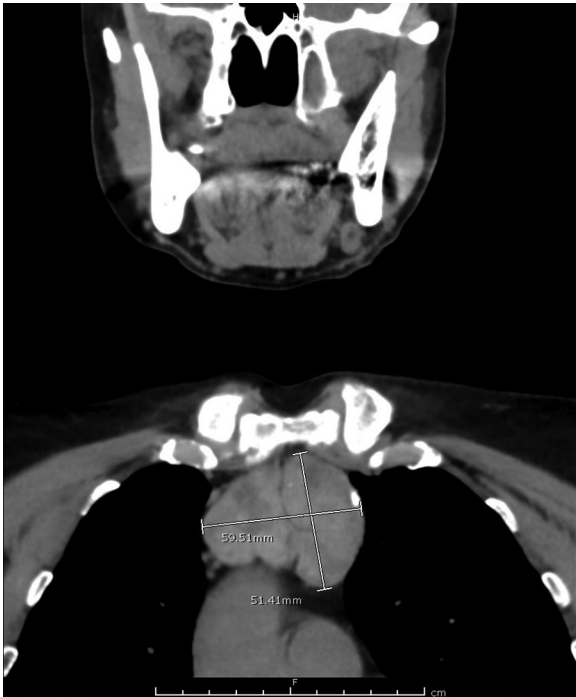goitre thirteen years prior via a cervical approach. There were no significant medical co-morbidities. Physical examination showed a previous thyroidectomy scar and mildly enlarged but uniform right thyroid. There were no abnormal respiratory findings. Pemberton's sign was negative. A pre-operative vocal cord check was normal and she was biochemically euthyroid.

Contrast enhanced computer tomography (CT) scan of the neck showed a left anterior mediastinal mass and mildly enlarged right thyroid gland. The lesion was a uniformly heterogenous and bilobed 5 × 6 cm mass, separate to the thyroid gland, and located in front of the trachea (without compression), above the level of the aortic arch (Fig. 1). Importantly, there was an apparent plane around the lesion. There were no visible feeding blood vessels and no identifiable tract to the cervical region. A radioactive iodine uptake scan showed increased uptake in the right thyroid lobe and in the mediastinal mass, confirming a goitre (Fig. 2).

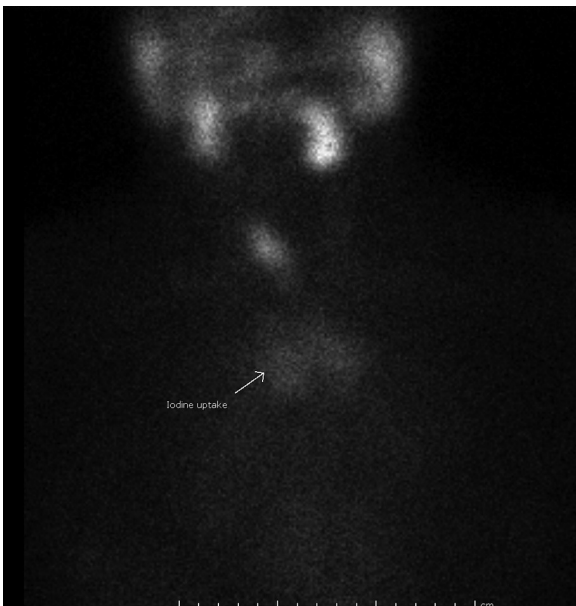
At operation, a thoracic surgeon was present and the patient was prepared for a sternotomy if required. A transverse incision through her previous scar was performed and sub-platysmal flaps were created. Careful sub-sternal dissection with identification of the innominate and brachiocephalic vessels were completed. The mass was identified and, using blunt, capsular dissection with careful traction via peanut sponges mounted on long fine artery forceps and upward traction using these peanut sponges, the mass was compressed and delivered through the thoracic inlet (Fig. 3). Importantly, the soft nature of the mass without attachment or infiltration

\* Corresponding author.

E-mail addresses: [Henry.to@nh.org.au](mailto:Henry.to@nh.org.au), [to.henry7@gmail.com](mailto:to.henry7@gmail.com) (H. To).



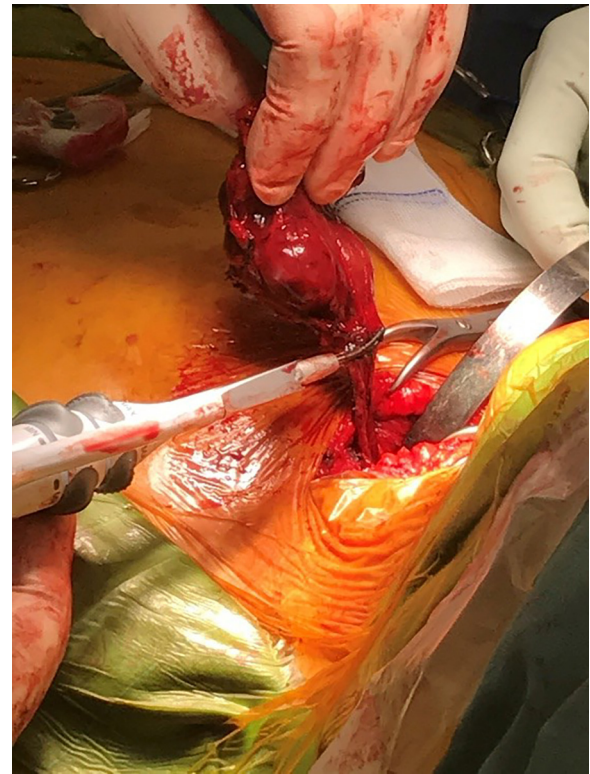
**Fig. 1.** Non-contrast computer tomography (CT) scan with coronal views of the 5 × 6 cm anterior mediastinal mass, above the aortic arch.



**Fig. 2.** Iodine radionuclear scan with anterior views, showing iodine avidity of the normal right thyroid and the mediastinal mass (marked with arrow).

to surround structures enabled its delivery. Presumed inferior thyroid vessels from above and the presumed thyrothymic ligament were divided using a Harmonic scalpel energy device. The recurrent laryngeal nerve was not visualised. The right thyroid lobe was not removed. A drain tube was placed in the cavity and layers closed.

The patient was well post-operatively without voice change. The drain tube was removed on Day 1 and she was discharged later the same day. Histopathology reported a benign 60 g multinodular thyroid mass without parathyroid glands. She was well on review in clinic at one and six weeks with normal thyroid function tests.



**Fig. 3.** Intra-operative photo of the mass post cervical delivery at division of the thyrothymic ligament.

### 3. Discussion

This case report highlights the work up and surgical approach of a separate substernal (and possible ectopic) goitre. A goitre is defined as a thyroid gland that has enlarge to twice its normal size, or weights more than 40 g; a substernal goitre is one which has descended below the plane of the thoracic inlet. Definitions vary for substernal goitre, but between 2–19% of patients who have thyroidectomies have a substernal component [6]. Indications for resection include compressive symptoms to the airway, oesophagus or great vessels. Pemberton's sign (facial flushing on lifting of the arms) is a good test for vascular thoracic outlet obstruction by a goitre which may have a substernal component [7]. The risk of carcinoma is the same as in cervical goitre, and is not of itself an indication for operation [8]. Separate substernal goitres are uncommon entities which may be residual thyroid tissue post thyroidectomy (up to 5% of cases [8]), or ectopic thyroid tissue [3].

Substernal goitres may also be classified as primary or secondary. Fewer than 1% of substernal goitres are primary in nature, arising from ectopic thyroid tissue in the mediastinum. They do not have any connection with the cervical thyroid gland and may receive blood supply from the intrathoracic arteries [3]. Given this, a sternotomy may be required for primary substernal goitres to control of blood supply [9]. Alternatively, secondary substernal goitres are the most common, and develop due to the downward growth of cervical thyroid tissue. They grow into the anterior mediastinum, anterior to the recurrent laryngeal nerve (RLN) and anterolateral to the trachea. Their blood supply is from the superior and inferior thyroid arteries [10].

An alternative classification system for substernal goitres is based on anatomical location which correlates to the suggested surgical approach. This includes (a) above the aortic arch which may be removed via a cervical approach, (b) to the pericardium requiring

a manubriotomy, and (c) below the right atrium a full sternotomy [1].

There is slightly higher rate of complications when a substernal goitre exists [1,11]. These include uncontrolled and obscured bleeding from the substernal component, RLN injury, permanent hypoparathyroidism and tracheomalacia [12]. Bleeding rates for substernal goitre resections are underreported, but can range from 0.1 to 0.5% [13]. Tracheomalacia, due to softening and subsequent collapse of the trachea post-resection, were only marginally increased with substernal goitres, but were increased in those present more than 5 years [8] and rarely required a tracheostomy or tracheal stent. RLN injury were marginally increased [11]. Importantly, mortality from a trans-cervical approach is extremely rare [13].

Pre-operative workup remains key for substernal or ectopic goitres. When a separate mediastinal mass is present, a CT scan best characterises the lesion and its anatomical relations. A clear plane around the substernal component increases the likelihood of completing the procedure via a cervical approach [2]. The presence of a connection with the cervical thyroid gland suggests that the mass is cervical thyroid in origin and may be used to aid in its delivery [9]. A CT can also measure the thyroid volume, the thoracic inlet diameter, and distance to the inlet to determine of the lesion can be delivered by a cervical approach [14]. A thyroid nuclear medicine can help to determine if the mass is thyroid in nature if there is uncertainty. Rarely, a separate iodine avid mass may represent a thyroid carcinoma metastasis and may be considered depending on risk factors [3]. Definition of vascular supply via CT angiography or magnetic resonance imaging is generally unhelpful as blood vessel supply is typically close to the capsule of the lesion. Pre-operatively, radioactive iodine may reduce thyroid tissue volume but must be used with caution.

Operative details are not well described in the literature, particularly for a separate substernal thyroid lesion. Given the possibility of difficult access to the lesion and need for control of feeding blood vessels in ectopic thyroid tissue [9], a thoracic surgeon was present for this case. We advocate a cervical approach where possible, as careful blunt capsular manipulation is often able to define and deliver the sub-sternal thyroid tissue if the anterior-posterior diameter is close or slightly larger than the thoracic inlet. Removal of any suprasternal component is best completed prior to the substernal dissection. Anatomical definition of major blood vessels is achievable via the cervical approach with good views. The use of long artery forceps with peanut sponges is able to increase length for dissection and ensures capsular dissection to identify feeding vessels. Careful traction can elevate the substernal mass without shearing feeding vessels. The trans-thoracic approach may improve access and aid visualisation of surrounding structures, but needs to be balanced by its morbidity. A large American study reviewed 2716 patients who had a substernal goitre, and those with a trans-thoracic approach had increased rates of unplanned intubations, transfusion and longer length of stay but no deaths. With these significant morbidity considerations in mind, they concluded that where anatomically possible, a trans-cervical approach should be used regardless of pathology [4]. Alternatively, there are reported video-assisted thoracoscopic approaches which may be of benefit in select patients where the anterior mediastinal space may be accessed [15].

#### 4. Conclusion

A trans-cervical approach is a safe and preferred option for a separate substernal (and potentially ectopic) goitre. Careful workup via nuclear medicine and CT imaging aid in determining the surgical approach and dissection. Careful manipulation of the substernal

gland with a thoracic surgeon available ensures safety in completing the dissection.

#### Conflicts of interest

None.

#### Funding

This research did not receive any specific grant from funding agencies in the public, commercial or not-for-profit sectors.

#### Ethical approval

Not required for case reports, but patient consent was completed (available upon request).

#### Consent

Consent completed (available upon request).

#### Author contribution

Henry To – study concept and design, writing the paper.  
Antara Karmakar – data collection, writing the paper.  
Stephen Farrell – study concept, data analysis and interpretation, writing the paper.  
Steve Manolas – data analysis and interpretation.

#### Guarantor

Henry To.

#### Acknowledgement

We thank Professor Bruno Carnaille (University of Lille) for his advice and suggestions for this manuscript.

#### References

- [1] C.T. Huins, C. Georgalas, H. Mehrzad, N.S. Tolley, A new classification system for retrosternal goitre based on a systematic review of its complications and management, *Int. J. Surg.* 6 (1) (2008) 71–76.
- [2] J.P. Cohen, Substernal goiters and sternotomy, *Laryngoscope* 119 (4) (2009) 683–688.
- [3] G. Noussios, P. Anagnostis, D.G. Goulis, D. Lappas, K. Natsis, Ectopic thyroid tissue: anatomical, clinical, and surgical implications of a rare entity, *Eur. J. Endocrinol.* 165 (3) (2011) 375–382.
- [4] M.N. Khan, E. Goljo, R. Owen, R.C.W. Park, M. Yao, B.A. Miles, Retrosternal goiter: 30-day morbidity and mortality in the transcervical and transthoracic approaches, *Otolaryngol. Head Neck Surg.* 155 (4) (2016) 568–574.
- [5] R.A. Agha, A.J. Fowler, A. Saeta, I. Barai, S. Rajmohan, D.P. Orgill, et al., The SCARE statement: consensus-based surgical case report guidelines, *Int. J. Surg.* 34 (2016) 180–186.
- [6] A.S. Moten, D.P. Thibault, A.W. Willis, A.I. Willis, Demographics, disparities, and outcomes in substernal goiters in the United States, *Am. J. Surg.* 211 (4) (2016) 703–709.
- [7] S. Basaria, R. Salvatori, Pemberton's sign, *New Engl. J. Med.* 350 (13) (2004) 1338.
- [8] M.L. White, G.M. Doherty, P.G. Gauger, Evidence-based surgical management of substernal goiter, *World J. Surg.* 32 (7) (2008) 1285–1300.
- [9] T.S. Hall, P. Caslowitz, C. Popper, G.W. Smith, Substernal goiter versus intrathoracic aberrant thyroid: a critical difference, *Ann. Thorac. Surg.* 46 (6) (1988) 684–685.
- [10] E. Mack, Management of patients with substernal goiters, *Surg. Clin. North Am.* 75 (3) (1995) 377–394.
- [11] M. Testini, A. Gurrado, R. Bellantone, P. Brazzarola, R. Cortese, G. De Toma, et al., Recurrent laryngeal nerve palsy and substernal goiter: an Italian multicenter study, *J. Visc. Surg.* 151 (3) (2014) 183–189.
- [12] F.M. Pieracci, T.J. Fahey III, Substernal thyroidectomy is associated with increased morbidity and mortality as compared with conventional cervical thyroidectomy, *J. Am. Coll. Surg.* 205 (1) (1998) 1–7.

- [13] B. Abboud, G. Sleilaty, N. Mallak, H. Abou Zeid, B. Tabchy, Morbidity and mortality of thyroidectomy for substernal goiter, *Head Neck* 32 (6) (2010) 744–749.
- [14] F. Riffat, M.M. Del Pero, B. Fish, P. Jani, Radiologically predicting when a sternotomy may be required in the management of retrosternal goiters *Annals of Otology, Rhinol. Laryngol.* 122 (1) (2013) 15–19.
- [15] P. Gupta, K. Lau, I. Rizvi, S. Rathinam, D. Waller, Video assisted thoroscopic thyroidectomy for retrosternal goitre, *Ann. R. Coll. Surg. Engl.* 96 (8) (2014) 606–608.

#### Open Access

This article is published Open Access at [sciedirect.com](http://sciedirect.com). It is distributed under the [IJSCR Supplemental terms and conditions](#), which permits unrestricted non commercial use, distribution, and reproduction in any medium, provided the original authors and source are credited.



Minerva Access is the Institutional Repository of The University of Melbourne

**Author/s:**

To, H; Karmakar, A; Farrell, S; Manolas, S

**Title:**

Trans-cervical resection of a separate substernal goitre.

**Date:**

2017

**Citation:**

To, H., Karmakar, A., Farrell, S. & Manolas, S. (2017). Trans-cervical resection of a separate substernal goitre.. *Int J Surg Case Rep*, 41, pp.373-376.

<https://doi.org/10.1016/j.ijscr.2017.11.005>.

**Persistent Link:**

<http://hdl.handle.net/11343/270727>

**File Description:**

Published version

**License:**

CC BY-NC-ND