

THE STRUCTURAL SUPPORT OF THE NOSE

GRAEME M. CLARK

Melbourne

Interest in the structural support of the nose is not new, for example 5,000 years ago the Egyptians were aware that the nose had to be supported while nasal fractures healed. This is evident in the Edwin Smith Surgical Papyrus, which dates from 3,000 B.C. It says:

"Instructions concerning a break in the column of his nose . . . Treatment—thou shouldst cleanse it for him with two plugs of linen saturated with grease in the inside of his two nostrils. Thou shouldst put him at his mooring stakes until the swelling is reduced. Thou shouldst apply for him stiff rolls of linen by which his nose is held fast. Thou shouldst treat him afterwards with grease, honey and lint every day until he recovers."

There was no further advance in our knowledge of the structural support of the nose until a couple of hundred years ago when our ancestors began to cut off people's noses as a form of punishment. This custom became quite marked in India, and a certain King Gloorka ordered all the inhabitants of Kirtipoor to have their noses cut off as a penalty for having been conquered. Consequently, the surgeons of the day were kept busy replacing people's noses, and their main concern was how to support the graft, and for this purpose they used ivory, bone, cartilage, metals and other substances.

Our present day interest in nasal support commenced during the latter part of the 19th century when it was realized that a combined submucous resection of the septum and rhinoplasty could lead to a loss of nasal support. It was not until Metzenbaum (1929) developed the septoplasty operation however, that the two operations were combined with satisfactory results.

We are still faced with the problem of knowing precisely to what extent different structures are responsible for supporting the nose. Only when we have this understanding will we be able to perform definitive surgery

for cosmetic and breathing problems with complete confidence. At the moment there is still disagreement even about fundamental issues, for example, whether the septum is responsible for taking any load on the nose, and whether its removal can lead to "saddling" of the dorsum. Fomon and his co-workers (1946) have been foremost in saying that the septum does not take any load under normal circumstances, as it acts like a king rod in a mechanical model. They considered that post-operative "saddling" was due to fibrous contracture and not loss of septal support.

To help answer these questions I have made calculations of load distributions in a mathematical model, performed a series of

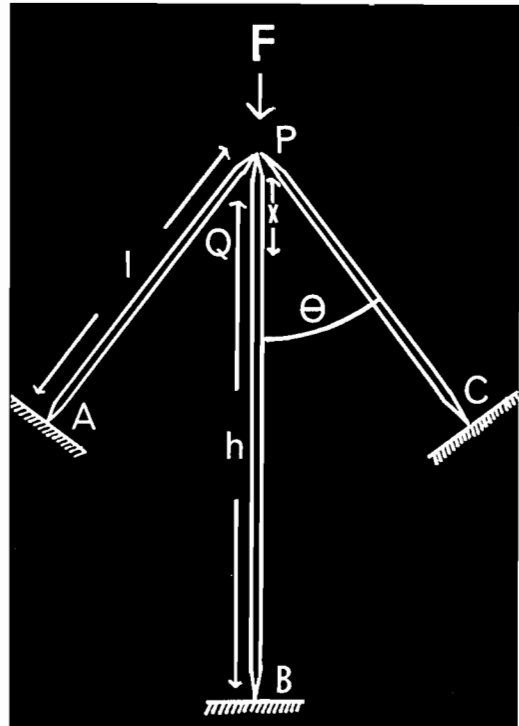


FIGURE 1

(Clark and Wallace, 1970)

Diagrammatic representation of the nasal bones and septum. AP, PC, l, the nasal bones; PB, h, the septum; PQ, X, distance P moves with a force F; θ , angle between the nasal bone and septum.

This paper was presented to the 20th Annual Meeting of the Otolaryngological Society of Australia in Melbourne on 5th March, 1970.

experiments on the nasal skeleton and mechanical models, and applied the results to the surgery of patients with nasal deformities and injuries.

The mathematical model can be seen in Figure 1 (Clark and Wallace, 1970). If the dorsum is loaded by a force F , the apex at P must be depressed, and however slightly, this will lead to a longitudinal strain in the septum. The mathematics show that if the nose is broad and the septum short and thick, the septum will take a greater portion of the load than it would if the nose were steeple-shaped and the septum long and thin.

In order to give some idea of the theoretical distribution of the load between the nasal bones and the septum, it is assumed that in the nose the angle is 20° , and that the nasal bones are half the length of the septum but of equal thickness. In this example the calculations show that the nasal septum would take half the load taken by each nasal bone.

All mathematical models simplify the problem, and do not always represent the true state of affairs. For this reason it is important to test the conclusions on the nose or similar model. Consequently my first series of experiments were performed on cadaver specimens. They were designed to weaken the nose at different situations and in different orders, so that the effect of these manipulations on nasal support could be determined. The experimental set-up can be seen diagrammatically in Figure 2A. In this Figure it can be seen that a force has been applied to the

nose by means of a spring balance, and the deflection produced has been measured on a linear scale. In these experiments, the force required to move the pointer half a centimetre, was taken as a measure of the extent to which the nasal support had been weakened.

In these experiments it was discovered that an area of the nasal septum beneath the nasal dorsum was important in the support of the nose. This area acts like a cantilever, and has therefore been designated "the cantilever of the nose". Figure 2B (Clark, 1967) shows a mounted cadaver specimen with all nasal structures removed except for the cantilever. As shown, a large force was applied by the spring balance, and the structural support was maintained. Figure 3 shows a similar specimen where medial and lateral osteotomies were performed on the nasal bones, and a crack had developed through "the cantilever of the nose". As can be seen, the structural support of the nose was minimal, and a force of 1 lb. resulted in a half centimetre deflection of the pointer.

In summary, the results of the study described above show that there is a particular area of the nasal septum that is important in nasal support. Figure 4 shows this area diagrammatically. It consists of portion of the perpendicular plate of the ethmoid, the nasal spine of the frontal bone, the nasal crests of the nasal bones, and the superior part of the septal cartilage. This cantilever should be left when performing an operation on the

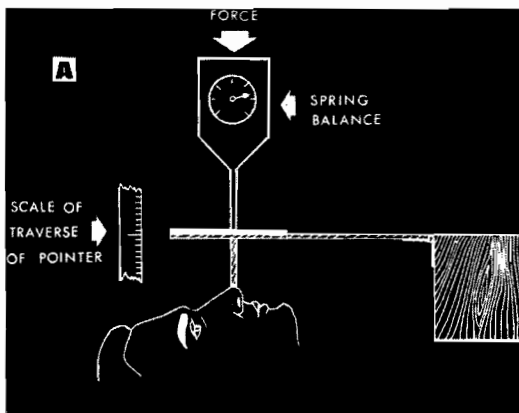


FIGURE 2A
(Clark, 1967)

The method of applying and measuring a force to the nose.




FIGURE 2B

Force applied to an anatomical preparation where the "cantilever" is the only remaining structure.

nasal septum, but it does not seem to be so necessary now to leave a ventral strut when performing a submucous resection of the septum.

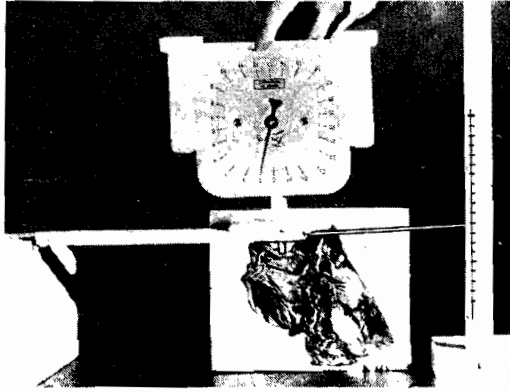


FIGURE 3
(Clark, 1967)

An anatomical specimen where medial and lateral osteotomies were performed on the nasal bones, and a crack had developed through "the cantilever of the nose".

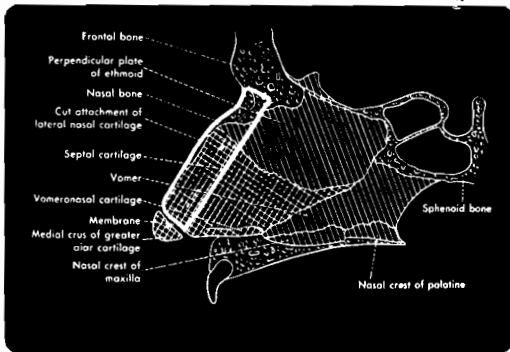


FIGURE 4
(Clark, 1967)

Structure of the nasal septum.

My next series of experiments were undertaken to see what proportion of a load is taken by the septum and by the nasal bones. I felt that it was important to do these experiments so that we will know whether it is safe to remove the nasal septum, particularly the cantilever, and still leave the nasal bone intact.

These experiments were performed by gluing very small strain gauges to the nasal bones and osseous septum, and measuring strain before and after excision of the septum. From the results obtained it was possible to calculate the percentage of the load borne by the septum and the nasal bones. Figure 5

shows the strain measurements recorded from strain gauges attached to different parts of the nasal skeleton. The points from which the strain measurements were made are indicated by the numbers on the insert. The strain from area 1 or the inner aspect of the left nasal bone, is shown in the top graph marked F1. The weight in lbs. applied to the dorsum is along the ordinate, and strain is measured along the abscissa. When the nasal septum was divided, a greater strain occurred in the nasal bones, indicating that the nasal septum was supporting a proportion of the load. Calculations showed that in one skull the septum took 8% of the load and in the second skull it took 63% of the load.

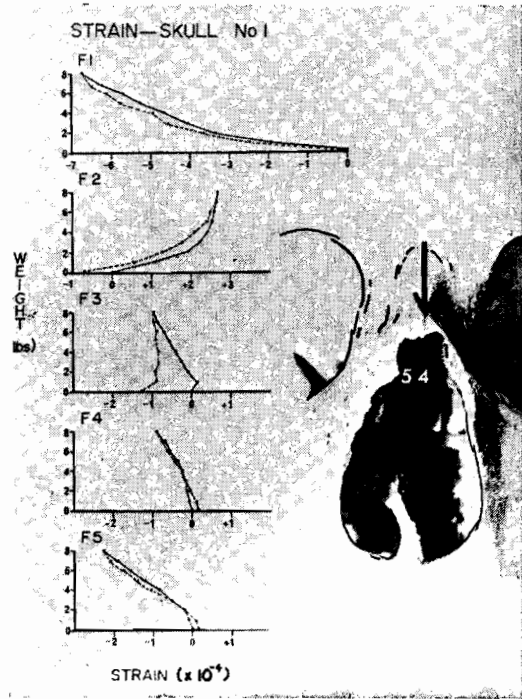


FIGURE 5
(Clark and Wallace, 1970)

Strain measurements recorded from strain gauges attached to different parts of the nasal skeleton.

Although there was considerable variation in the proportion of the load taken by the septum, the results show that the septum plays an active role in supporting the nose, and this must always be considered when performing rhinoplasty operations. The differences between the two skulls could be due to anatomical variations such as nasal breadth, thickness and length of the septum, as indicated from the mathematical model.

As the original paper of Fomon's was quite emphatic that the nasal septum was a redundant member and did not support any weight unless the nasal bones were broken, I have performed a further series of experiments using a plastic model of the nose (Clark, in press). This model was a triradiate truss and was made from a material which had photo-elastic properties. As a result, when polarized light was shone through the model, areas of strain concentration could be seen when the model was loaded. When white light was used instead of monochromatic light, the areas of strain concentration showed up as different colours.

The results of this study showed that when a force was applied to the apex of the model, a portion of the load was taken by the central member.

The results of these studies have been applied in the cases of 50 combined rhinoplasty and septoplasty operations for a variety of

cosmetic and septal deformities. In each case the cantilever of the nose was preserved, and there were no cases where a collapse of the nasal dorsum developed.

The pre- and post-operative photographs of a typical patient can be seen in Figure 6 (Clark, 1967). In the pre-operative photographs on the top, it can be seen that the patient had a small osseous lump and supra tip saddle. In addition there was a deviation of the nasal pyramid and nasal septum proper, and an anterior dislocation of the septum to the left. At operation it was necessary to remove a complete inferior strip of the septum because of spur formations, but as the cantilever was preserved no post-operative saddling developed.

I also had the opportunity of applying some of these principles to a patient with a nasal fracture which had led to loss of support. His pre-operative photograph can be seen in Figure 7A (Clark, 1968), and as can

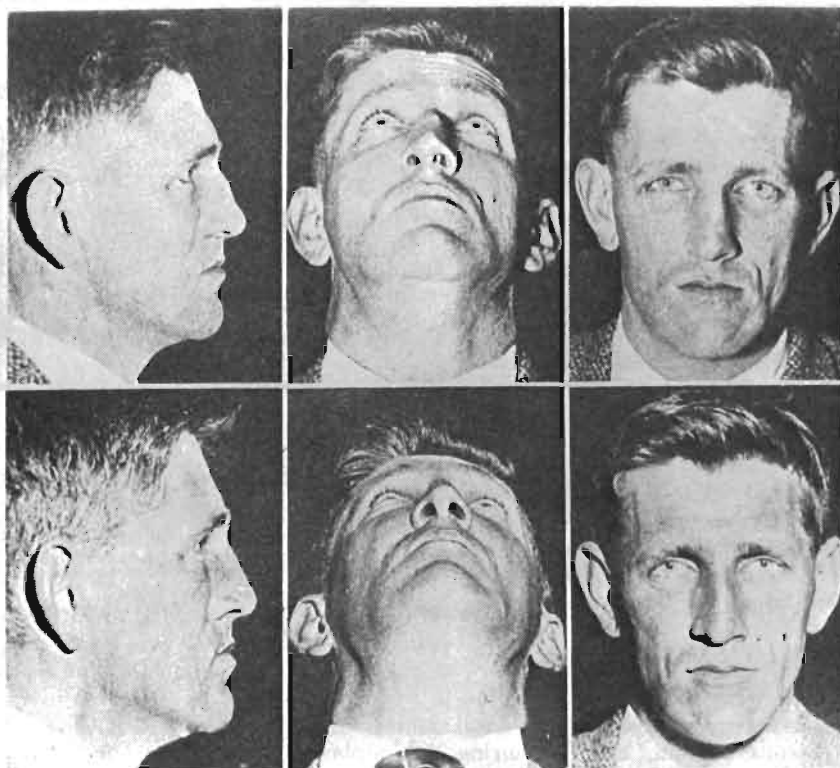


FIGURE 6
(Clark, 1967)

Top, patient before operation. *Bottom*, patient after operation.

be seen there is a saddling of the nose. At operation it was necessary to explore the septum, and I found that a fracture had occurred across the cantilever area. To support this area, I inserted a septal strut of "Boplast"

which helped correct the saddling. His post-operative photograph is seen in Figure 7B (Clark, 1968).

In summary, it appears that the nose has a complex structural design. Nevertheless the

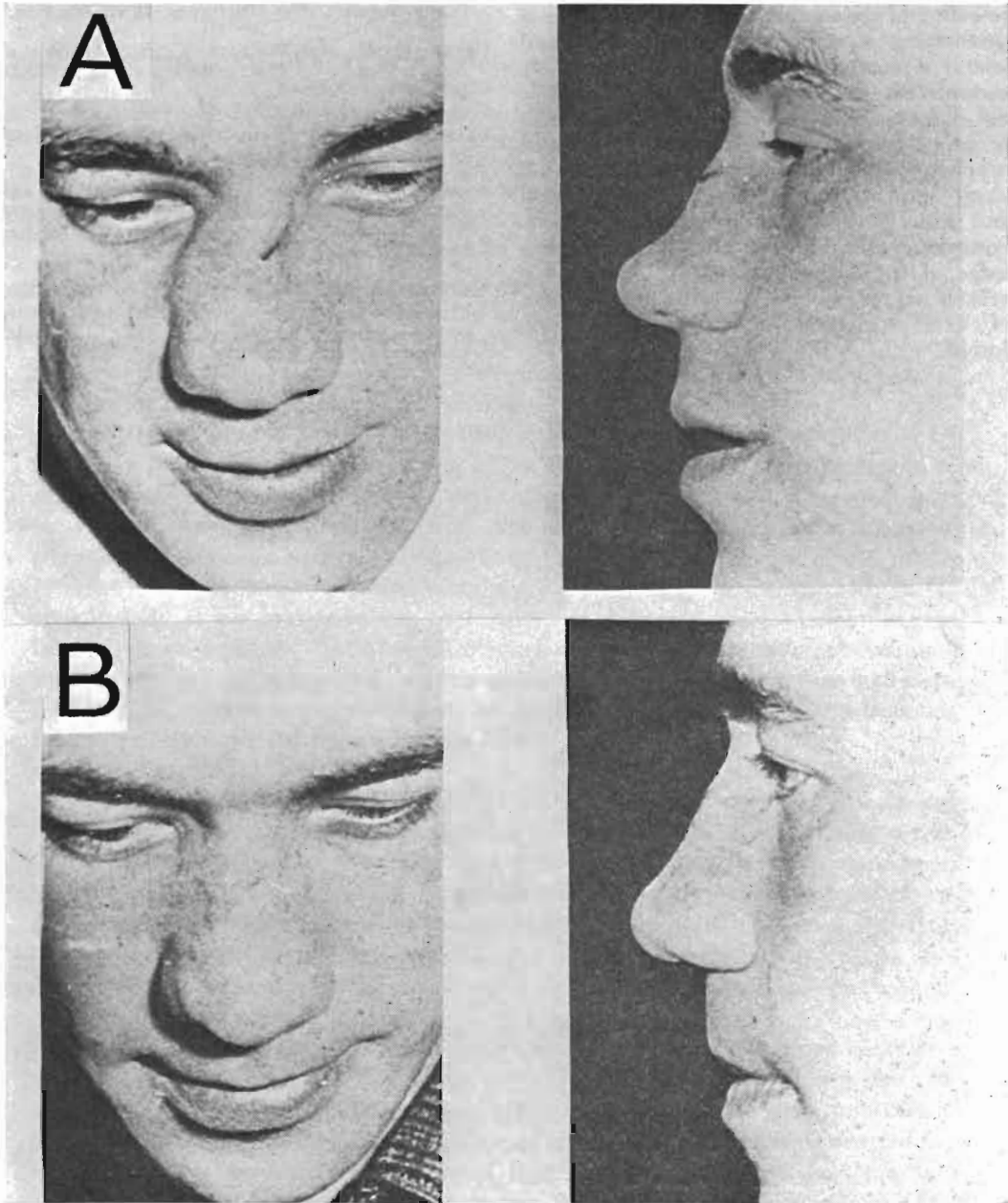


FIGURE 7A
(Clark, 1968)

Pre-operative photographs of patient with a saddle nose due to injury. Left, frontal view. Right, lateral view.

FIGURE 7B

Post-operative photographs of patient. Left, frontal view; Right, lateral view.

evidence suggests that it is supported by a cantilever in the septum, and a triradiate truss composed of the nasal bones and septum. As a result of this study it appears that it is not always necessary to leave a caudal part of the septum when performing a routine submucous resection of the septum. In addition, if one is performing a rhinoplasty with medial and lateral osteotomies, one has to be extremely careful that the cantilever of the septum is not damaged, otherwise a nasal collapse will occur. Although this analysis of the structural support of the nose could help in performing nasal surgery, nevertheless, judgment, skill and experience are still required. I hope, however, in the future a more precise knowledge of supporting mechanisms will give a greater degree of certainty to the management of nasal structural defects and deforming forces.

REFERENCES

- CLARK, G. M., "The Role of the Nasal Septum in One-Stage Rhinoplasty", *Arch. Otolaryng.* 85 : 418-423, 1967.
- CLARK, G. M., "Septal Transplant for a Saddle Nose Due to Injury", *Arch. Otolaryng.* 88 : 87-90, 1968.
- CLARK, G. M. and WALLACE, C. S., "Analysis of Nasal Support", *Arch. Otolaryng.* 92 : 118-123, 1970.
- CLARK, G. M., "A Photoelastic Analysis of Nasal Support", *Arch. Otolaryng.* In Press.
- FOMON, S., SYRACUSE, V. R., BOLOTOW, N. and PULLEN, M., "Plastic Repair of the Deflected Nasal Septum", *Arch. Otolaryng.* 44 : 141-156, 1946.
- METZENBAUM, M., "Replacement of the Lower End of the Dislocated Septal Cartilage Versus Submucous Resection of the Dislocated End of the Septal Cartilage", *Arch. Otolaryng.* 9 : 282, 1929.



Minerva Access is the Institutional Repository of The University of Melbourne

Author/s:

Clark, Graeme M.

Title:

The structural support of the nose

Date:

1971

Citation:

Clark, G. M. (1971). The structural support of the nose. *Journal of the Otolaryngological Society of Australia*, 3(2), 235-240.

Persistent Link:

<http://hdl.handle.net/11343/27126>

File Description:

The structural support of the nose