

Endotracheal Tube Placement During Computed Tomography of Brachycephalic Dogs Alters Upper Airway Dimensional Measurements

Nai-Chieh Liu¹, Eileen L. Troconis², Matthew McMillan^{1,3}, Marie-Aude Genain^{1,3}, Lajos Kalmar¹, David J. Price¹, David R. Sargan¹, Jane F. Ladlow^{1,3,*}

¹ Department of Veterinary Medicine, University of Cambridge

² College of Veterinary Medicine, Cornell University

³ Queen's Veterinary School Hospital, University of Cambridge

* Corresponding author: Jane F. Ladlow

Address: Department of Veterinary Medicine, University of Cambridge, Madingley road, Cambridge CB30ES, United Kingdom

E-mail: jfl1001@cam.ac.uk

Key Words: endotracheal tube, computed tomography, brachycephalic dogs, soft palate, nasopharynx, trachea

Abstract

This is the author manuscript accepted for publication and has undergone full peer review but has not been through the copyediting, typesetting, pagination and proofreading process, which may lead to differences between this version and the [Version of Record](#). Please cite this article as [doi: 10.1111/vru.12590](https://doi.org/10.1111/vru.12590).

This article is protected by copyright. All rights reserved.

Computed tomography (CT) is used to document upper airway lesions in dogs with brachycephalic obstructive airway syndrome. The presence of an endotracheal tube during CT scanning is often required for general anaesthesia. We hypothesized that the endotracheal tube placement would change the soft tissue dimensions of the upper airway. The aims of this prospective, method comparison study were to evaluate the reliability of the previously reported upper airway CT measurements with endotracheal tube placement, and to propose measurements that are minimally affected by endotracheal tube. Twenty brachycephalic dogs were included in this study. Each dog underwent head/neck CT with an endotracheal tube, followed by a second scan without the endotracheal tube. Ten measurements of the soft palate, nasopharynx, and trachea were performed. Tracheal dimension was significantly larger with the endotracheal tube compared to without, whereas the soft palate cross-sectional area was significantly smaller with the endotracheal tube than without the endotracheal tube. The influence of the endotracheal tube on the caudal nasopharynx cross-sectional area varied with a mean proportional absolute difference of 35%. Rostral soft palate thickness, tracheal perimeter, and cross-sectional area of the rostral nasopharynx were the measurements least affected by the endotracheal tube (intraclass correlation coefficient=0.964, 0.967, and 0.951, respectively). Therefore, we proposed that these three measurements may be most useful for future brachycephalic obstructive airway syndrome studies that require CT scanning of intubated animals. However, with endotracheal tube placement, measurements of soft palate length, caudal nasopharyngeal cross-sectional area, and trachea height and width may not be reliable.

Introduction

Brachycephalic obstructive airway syndrome is most commonly seen in extreme brachycephalic canine breeds such as pugs, French bulldogs and bulldogs (English bulldogs) where approximately 20-50% of the dogs are affected with the condition ^{1,2}. In practice, diagnosis is usually subjective and

made from a combination of clinical history and clinical signs. More recently, an objective and non-invasive respiratory function test for brachycephalic obstructive airway syndrome has been developed using whole body barometric plethysmography, which has allowed quantification of disease severity^{2,3}. Brachycephalic obstructive airway syndrome is a conformation-related disease in that the upper airway obstruction is caused by disproportionate reduction of the facial bones with respect to the soft tissue within the skull^{4,5}. Therefore, studies have focussed on the anatomical measurements associated with brachycephalic obstructive airway syndrome severity⁶⁻¹⁰. While the external conformation such as head shape has become more uniform within breeds, the wide variation in clinical severity in dogs^{2,11} of similar conformation has fuelled interest in finding the internal conformational predictors (e.g. upper airway dimensions) for brachycephalic obstructive airway syndrome.

Imaging is used to support the diagnosis of brachycephalic obstructive airway syndrome by documenting obstructive tissue or areas of airway narrowing^{6-9,12-14}, and increasingly, advanced imaging such as CT is often used as part of the diagnostic protocol. Computed tomography of the head and neck is used to document lesions such as a long and thickened soft palate⁶, abnormally positioned turbinates (rostral or caudal aberrant turbinates)^{12,14,15}, nasopharyngeal narrowing⁷, laryngeal dimensions^{9,16}, and tracheal hypoplasia⁸. The use of CT allows the thoracic cavity to be assessed and may reveal aspiration pneumonia secondary to regurgitation, bronchial collapse, oesophageal thickening or hiatal hernia. One major limitation of using CT is that only static lesions can be assessed in anaesthetized animals. Brachycephalic obstructive airway syndrome is a dynamic disease and the extent of obstruction is dependent on a number of factors, such as the stage of the respiratory cycle¹⁷ and the state of wakefulness. For this reason, other ways of imaging brachycephalic obstructive airway syndrome lesions have been explored such as fluoroscopy^{5,18}, endoscopy^{9,12} and ultrasound examination¹⁹. Nonetheless, these imaging techniques also have

limitations when applied to brachycephalic obstructive airway syndrome. For example, fluoroscopic images are often complicated by movement blur, which makes accurate quantitative measurements difficult. In the case of endoscopy, no bony marker is available to normalise the subject size and to define the relative position and dimensions of the soft tissues. Therefore, for direct measurement of static upper airway structures, and particularly for comparison of lesions between dogs of varying severity of brachycephalic obstructive airway syndrome, CT may be the most reliable and practical imaging modality.

Computed tomographic scans of the head and the neck have been widely used to quantify upper airway dimensions for sleep apnoea studies in humans²⁰⁻²³. The patients are usually scanned without sedation or general anaesthesia. Unfortunately, CT scanning in dogs usually requires physical restraint by sedation or general anaesthesia with placement of an endotracheal tube⁶⁻⁸. However, we are not aware of any studies that document the effect of the endotracheal tube on the upper airway dimensions.

In this study, we hypothesized that endotracheal tube placement would increase the cross-sectional area of the tracheal lumen while decreasing the cross-sectional area of the nasopharyngeal air cavity, and decreasing the area of the soft palate on the mid-sagittal plane. The aims of this study were to evaluate the reliability of the previously reported measurements for brachycephalic obstructive airway syndrome study and to propose measurements that are minimally affected by endotracheal tube placement.

Materials and Methods

Subjects

This study is a prospective, method comparison study, which included brachycephalic dogs (pugs, French bulldogs, bulldogs and Shih-Tzu dogs) that underwent CT scanning of the head and neck prior to upper airway corrective surgery or dental treatment between August 2014 and March 2017 at the Queen's Veterinary School Hospital (QVSH). All candidates for this study were assessed by a board-certified veterinary anaesthetist or by residents under their supervision prior to premedication and anaesthesia. This involved a clinical examination, performed with a particular focus on airway dysfunction and cardiovascular status, and examination of the animals' clinical notes plus any supporting information such as clinical pathology or previous diagnostic imaging. This allowed an individual anaesthetic risk assessment to be made. Dogs that had history of frequent regurgitation and/or had a high risk of airway obstruction while under general anaesthesia without placement of an endotracheal tube for the time period of a single head/neck CT scan were excluded. All dogs had brachycephalic obstructive airway syndrome (BOAS) assessment (i.e. "brachycephalic obstructive airway syndrome Functional Grading"²), and then underwent CT scans of the head and chest prior to the surgery under the same general anaesthetic. All procedures were approved by the Department of Veterinary Medicine at the University of Cambridge, under informed ethical consents CR62 and CR63. All dog owners provided informed consent for the inclusion of their animals in this study.

Computed tomography

All dogs had premedication with 1.5 µg/kg of dexmedetomidine or 0.01 mg/kg of acepromazine given randomly to each patient as per protocol of another study the dogs were enrolled with. The dog was induced with either alfaxalone or propofol to effect depending on anaesthetists choice. Isoflurane was used for maintenance of anaesthesia during the procedure. Computed tomography was performed with a 16 slice multislice CT scanner (Aquilion 16, Toshiba America Medical Systems, California, United

States). The images were acquired in helical mode, with a slice thickness of 0.5 mm, with an image reconstruction index of 0.3, a pitch factor of 0.938, and a standard 512 x 512 matrix. Tube rotation time was 0.5 seconds and KVp=100, mAs=150. The images were acquired in bone and soft tissue windows (Bone: window width (WW) 3500 Hounsfield unit (HU), window level (WL) 1500 HU, soft tissue WW 350 HU, WL 50 HU). The procedure was performed by the imaging team at the authors' institution and the dog's condition was monitored at all times by an anaesthetist. All dogs were anaesthetized for the CT scanning. An endotracheal tube was placed with an inflated cuff. The size and the type of the tube were selected by the anaesthetist and the information was recorded. A spacer of 2.5 cm in length made from a 3 mL syringe was placed in between the ipsilateral maxillary and mandibular canine teeth to facilitate visualization of the individual airway structures on the CT images. The dogs were in sternal recumbency, and hyperventilated to apnoea with oxygen prior to the thoracic scans, followed by the first head/neck intubated scan. The dogs were hyperventilated again prior to the extubated scan. The endotracheal tube was then carefully de-cuffed and removed for the second head/neck scan without altering the dog's position. The dogs were re-intubated immediately after the end of extubated scan. All dogs were continuously monitored with pulse oximetry throughout the procedure.

Upper airway quantitative measurements on CT images

Image analysis was performed using the commercially available software (Mimics Research, version 19.0, Materialise, Leuven, Belgium). Anatomical bone landmarks were defined under the predetermined contrast bone scale from Mimics (WW 2674 HU, WL 313 HU, range -1024 to 1650 HU). Measurements of the soft palate and nasopharynx were performed using a soft tissue window (WW 500 HU, WL 100HU, range -150 to 350 HU); measurements of the trachea were performed using the bone window. Before initiating the measurement protocol, the interactive multiplanar

reconstruction option was used to align the three planar axes and reconstruct the project using a slice thickness of 0.5 mm. The detailed criteria used in re-slicing are described in Figure 1.

All measurements were performed by one of the authors (NCL). The evaluator was blinded to the patient's clinical signs and patient's data. The intubated CT measurements were performed on all dogs first. The extubated CT measurements were performed two days after. The two sets of data were recorded separately and then merged for data analyses. Ten measurements were performed and their descriptions are demonstrated in Table 1. These ten measurements include soft palate length (SP_L), rostral soft palate thickness (SP_RT), middle soft palate thickness (CP_MT), soft palate cross-sectional area (SP_CSA), rostral cross-sectional area of the nasopharynx (NP_R), caudal cross-sectional area of the nasopharynx (NP_C), tracheal height (T_H), tracheal width (T_W), trachea cross-sectional area (T_CSA), and trachea lumen perimeter (T_P).

Statistical analyses

Statistical analyses were selected and performed by two of the authors (NCL and DJP, the latter is a statistician). All analyses were conducted using the open source programming language and software environment (R version 3.3.0 for Mac, <http://www.r-project.org>). Significance level was set at 0.05 in all tests.

Three different types of tests were used to compare the intubated and extubated measurements of each anatomical quantity of interest:

- (1) Bland and Altman plots²⁴ were produced to show the 95% confidence interval (CI) of agreement limits, and the association between the differences (intubated value minus extubated value) and

their means (i.e., to detect any relative differences). The normality of the differences was first tested using Shapiro-Wilk tests²⁵. If the assumptions of normality were violated, a non-parametric Wilcoxon signed-ranks test was used to test the systematic difference between the two groups; otherwise a paired t-test was used.

- (2) A simple linear regression was used to describe the associations between the intubated and extubated measurements, and thus test the predictive ability of intubated measurements to extubated measurements.
- (3) The reliability between the intubated and extubated measurements was assessed using intraclass correlation coefficient (ICC) (two-way model with single rater and test for agreement)²⁶. The ICC was then used to suggest the most reliable measurement among other measurements in the same area.

A multiple linear regression was used to assess the effect of brachycephalic obstructive airway syndrome severity and the relative size of the endotracheal tube on the CT measurement differences between intubation and extubation. The “relative size of the endotracheal tube” was defined as the ratio of the external endotracheal tube diameter (mm) to the average of T_H (mm) and T_W (mm) (e.g. a ratio of 1 means the endotracheal tube diameter was the same as the average of T_H and T_W). The brachycephalic obstructive airway syndrome severity was based on a previously established brachycephalic obstructive airway syndrome functional grading system³. Here, Grade 0 and Grade I were combined into a single category as clinically unaffected, Grade II was moderately affected, and Grade III was severely affected.

Finally, Pearson’s correlation was used to assess the associations between the newly proposed measurements in this study (SP_RT, NP_R, and T_P) and other measurements (at the same

anatomical area) that were previously reported for brachycephalic obstructive airway syndrome study⁶⁻⁸.

Results

Subjects

Twenty brachycephalic dogs met the study criteria during the study period were included. Among the 20 dogs, 9 were females and 11 were males. Breeds included the pug (n=6), the French bulldog (n=10), the bulldog (n=3), and the Shih-Tzu dog (n=1). The median age was 19.5 months old (range: 10 to 61 months) and the median body weight was 11.43 kg (range: 5.65 to 32.25 kg). 3/20 dogs were brachycephalic obstructive airway syndrome Functional Grade 0/I (absent/mild brachycephalic obstructive airway syndrome), 11/20 dogs were brachycephalic obstructive airway syndrome Functional Grade II (moderate brachycephalic obstructive airway syndrome), and 6/20 were brachycephalic obstructive airway syndrome Functional Grade III (severe brachycephalic obstructive airway syndrome). The mean of relative size of the tube was 0.78 (standard deviation (SD) = 0.13).

(1) Soft palate

On average, SP_CSA was significantly smaller with the endotracheal tube placement than without the endotracheal tube placement (mean difference = 55.77 mm², t=-2.804, p=0.012). Figure 3A demonstrates the alteration in measurements by the endotracheal tube placement. SP_L (t=0.307, p=0.726), SP_RT (t=0.162, p=0.873), and SP_MT (t=-1.52, p=0.146) were not significantly different

between intubated and extubated CT images (Table 2). However, 5/20 dogs had a difference in SP_L of over 15% of the average of the two measurements, and the difference was up to 12 mm. The R^2 value of 0.637 reveals that the intubated SP_L only accounts for 63.7% of the variance in the extubated SP_L, which is the lowest value compared to other measurements of the soft palate (Table 2). The intubation effect on the SP_MT measurement was related to the measurement value. Figure 3B shows that dogs with thicker SP_MT had a larger measurement difference between intubated and extubated images. The SP_RT, on the other hand, had a consistent difference regardless of the value of SP_RT. The differences between the intubated and extubated measurements of all four soft palate quantities of interest were not significantly affected by brachycephalic obstructive airway syndrome severity, or the relative size of the tube (statistical outputs can be found in Appendix 1).

Overall, according to the ICC value and its lower bound of the 95% confidence interval (CI) (Table 2), SP_RT was the most reliable measurements and least affected by the endotracheal tube among soft palate measurements (ICC = 0.964, 95%CI = 0.910 to 0.986). The extubated SP_RT is highly correlated with the extubated SP_MT ($r=0.863$, $p<0.0001$) and extubated SP_CSA ($r=0.912$, $p<0.0001$), but has a weaker correlation to SP_L ($r=0.649$, $p=0.003$).

(2) Nasopharynx

On average, the difference between the intubated and extubated NP_C was not significant ($W=53$, $p = 0.276$). However, Figure 4C shows how NP_C varies with the presence of the endotracheal tube. With extubated NP_C values that were close to zero, the measurements did not alter much with endotracheal tube placement; whereas Figure 4B shows a bulldog that had an intubated NP_C of 87.5 mm² but an extubated NP_C of 165.44 mm².

There was no systematic difference in NP_R between intubation and extubation ($t=0.361$, $p=0.722$). Within the range of measurements from 20 to 120 mm² the difference was consistent (Figure 4C). By comparing the proportional absolute difference, and the R² from the linear regression models, the endotracheal tube placement had less effect on NP_R (14% and 0.929, respectively) than on NP_C (35% and 0.806, respectively) (Table 2). Moreover, both measurements had ICC values >0.9, but NP-R has narrower 95%CI, with a lower bound of 0.92, compared to that of NP_C at 0.78 (Table 2).

The extubated NP_R was highly correlated to the extubated NP_C ($r=0.961$, $p<0.0001$). The differences between the intubated and extubated measurements of NP_R and NP_C were not significantly affected by brachycephalic obstructive airway syndrome severity or the relative size of the tube (statistical outputs can be found in Appendix 1).

(3) Trachea

On average, T_H ($t=2.378$, $p=0.028$), T_W ($t=2.066$, $p=0.053$), T_P ($t=2.466$, $p=0.023$), and T_CSA ($t=3.899$, $p=0.001$) were higher with the endotracheal tube than without the endotracheal tube. T_CSA, in particular, had a proportional absolute difference of 21% (Table 2). Figure 5A shows the effect of the endotracheal tube on the tracheal dimensions, particularly the displacement of the dorsal tracheal membrane. Among other measurements, T_P had the highest R² (0.921) when using the intubated measurement to predict the extubated measurements (Table 2), and the lowest proportional absolute difference (4%). Moreover, it has the highest ICC (ICC = 0.951, 95%CI = 0.855 to 0.982)

among other tracheal measurements with a lower bound of 95%CI at 0.86, while with T_CSA, although the ICC value was 0.86, its lower bound of 95%CI was only 0.34.

The extubated T_P was highly correlated with the extubated T_H ($r=0.901$, $p<0.0001$), extubated T_W ($r=0.871$, $p<0.0001$), and T_CSA ($r=0.924$, $p<0.0001$). The differences between the intubated and extubated measurements of all four tracheal quantities of interest were not significantly affected by brachycephalic obstructive airway syndrome severity or the relative size of the tube (statistical outputs can be found in Appendix 1).

Discussion

The findings of this study support our hypotheses that the endotracheal tube placement decreases the cross-sectional area of the soft palate on the mid-sagittal plane and the cross-sectional area of the nasopharyngeal air cavity, while increasing the cross-sectional area of the tracheal lumen. Three measurements that were only minimally affected by endotracheal tube placement, namely SP_RT, NP_R, and T_P, were proposed as reliable measurements that may be used for future studies of brachycephalic obstructive airway syndrome.

The upper airway constitutes a collapsible tube and the effect of the endotracheal tube on its dimensions could be significant. Yet this effect has never been taken into account when CT measurements of the upper airway were conducted in previous studies⁶⁻⁸. In this study, we specifically selected the three areas that are most likely to be affected by the endotracheal tube and that have been measured in previous brachycephalic obstructive airway syndrome studies. Laryngeal dimensions were not included in this study because consistent and reliable measurements were not

achieved during the preliminary stage of the study. In our study, the endotracheal tube altered the dimensions of the soft palate, nasopharynx, and the trachea to various degrees, and the relative size of the endotracheal tube and the severity of brachycephalic obstructive airway syndrome were not significantly associated with those alterations. One study used the CT to evaluate laryngeal and tracheal airway obstruction in awake or sedated dogs with a positioning device¹⁶. Without the placement of an endotracheal tube, the method provides the advantage of assessing the larynx and trachea in their natural dimensions. However, the major limitations are that the CT images may be obtained during a given phase of respiration, and for dogs with severe brachycephalic obstructive airway syndrome, restraint with the positioning device when awake or sedated could increase the risk of respiratory distress or upper airway obstruction. Therefore, performing CT scans under general anaesthesia with an endotracheal tube is more common in brachycephalic dogs.

An oversized soft palate is the most common upper airway abnormality of brachycephalic obstructive airway syndrome²⁷⁻²⁹. Grand and Bureau (2011) measured the length and the thickness of the soft palate on CT images⁶. They reported that dogs with severe brachycephalic obstructive airway syndrome had a significantly thicker soft palate at all levels than dogs with absent/minimal brachycephalic obstructive airway syndrome, when normalized to the cranial height. However, the length of the soft palate was not significantly different from non-brachycephalic control dogs, when normalized to the skull length. In a different study, Heidenreich *et al.* (2016) showed that pugs had significantly shorter and thinner soft palates than French bulldogs, when the measurements were normalized to skull index⁷. It was noticed that the normalisation measurements for body shape and size were not standardized between studies. Moreover, the larger soft palate length may not necessarily contribute to airway obstruction. It is more dependent on its relative position to the epiglottis; therefore, interpretation and comparison of the findings must be performed with caution. The effect of the endotracheal tube on these soft palate measurements is also questionable. In the

present study, it was found that there was a large difference between intubated and extubated measurements of dogs with thicker SP_MT. Interestingly, the direction of the differences varied: some dogs had a higher intubated SP_MT than extubated SP_MT, and vice versa. The direction of the differences is likely dependent on the endotracheal tube position within the oral cavity. For instance, Figure 3A (right) shows that the endotracheal tube was placed at the midline and as a result the soft palate appears thinner than when there is no endotracheal tube present. In contrast, Figure 6 shows that the endotracheal tube is deflected to the left in the rostral and middle region of the oral cavity, and then turns medially in the caudal oral cavity. It is obvious that the position of the tube affects the soft palate images on the mid-sagittal plane. If the position of the tube is not specified, it is likely to result in incomparable measurements. In this study, the SP_RT was the least affected by the endotracheal tube among soft palate measurements. The authors are not aware of any study that has used the measurement of SP_RT. The SP_RT is highly correlated with the SP_MT (which is thicker in dogs with more severe brachycephalic obstructive airway syndrome ⁶), and may be considered a reliable measurement in future studies that require intubation.

The collapsibility of the nasopharynx in brachycephalic obstructive airway syndrome affected dogs can be explained by the meat-in-box mechanical model and the imbalance of airway anatomy theory ³⁰⁻³². In affected dogs, the anatomical imbalance between the soft tissue volume and bony frame size results in pharyngeal and nasopharyngeal airway obstruction. The soft tissues involved include the tongue, soft palate, tonsils, pharyngeal and nasopharyngeal walls. The narrowing of the nasopharyngeal air passageway, together with other upper airway abnormalities (e.g. hypoplastic trachea, obstructive nasal turbinates, stenotic nares), and the resulting increased negative pressure within the airway tract could lead to collapse of the nasopharynx. Heidenreich *et al.* (2016) measured the cross-sectional area of the nasopharynx at different levels from the caudal end of the choanae to the caudal end of the soft palate ⁷. They found that the smallest nasopharyngeal cross-sectional area

was at the caudal end of the soft palate. While all subjects in that study were intubated, it is likely that the marker used (caudal end of the soft palate) was affected by the position of the endotracheal tube (Figure 3 and Figure 6). In the present study, two levels of nasopharynx were selected and both were defined using bony landmarks on the maxillary bone (pterygoid bone and tympanic bulla), which are easy to locate and are not affected by the endotracheal tube position. NP_C is a similar measurement to 'N at Bulla' in Heidenreich *et al.* (2016) study⁷. This measurement is located at the caudal portion of the soft palate viewed on the sagittal plane. In the present study, the median difference in proportion was high at 35% between intubated and extubated NP_C. The difference was particularly high in dogs with larger NP_C where there was room for the endotracheal tube to alter the position of the soft tissues. On the contrary, in dogs with a small NP_C (close to 0 mm²), there was almost no nasopharyngeal cavity and thus the effect of the endotracheal on the soft tissues is much less and the difference between the intubated and extubated measurements was small. In other words, when intubated, this measurement was highly dependent on the size of the extubated NP_C (Figure 4C).

NP_R is a new proposed measurement in the present study. It presents the cross-sectional area of the nasopharynx at the junction where the soft tissue first loses the lateral support from the pterygoid bone and the hard palate. This measurement was only affected minimally by the endotracheal tube and the effect of the endotracheal tube was independent to the intact size of the NP_R. In addition, extubated NP_R was highly associated with extubated NP_C and could potentially be used in future studies that look at the relationship between brachycephalic obstructive airway syndrome severity and CT nasopharyngeal dimensions, regardless of the need to intubate the study subjects.

Hypoplastic trachea is often seen in brachycephalic obstructive airway syndrome affected dogs^{8,33-35}. This condition usually presents as a reduction in the tracheal lumen size, significant overlap of the

tracheal cartilage and inward folding of the dorsal tracheal membrane^{8,33}. A radiographic ratio of tracheal diameter (tracheal height on the lateral view of the radiographs) to the thoracic inlet (TD:TI) was reported to define hypoplastic trachea³⁴. Brachycephalic dogs had significantly smaller TD:TI ratio than non-brachycephalic dogs, and bulldogs, in particular, had significantly smaller TD:TI ratio than other brachycephalic dogs in that study. Following studies used the same methods to measure the relative size of the trachea^{8,35}. Compared to radiographs, tracheal measurements on CT images have the advantages of better-defined outline of the trachea, and could measure other aspects of the trachea. The main drawback of using CT images of trachea is that general anaesthesia and an endotracheal tube placement are often required. In the present study, it was found that, on average, the tracheal height and width were 10% larger with the endotracheal tube than without the endotracheal tube. Moreover, there was an average increase of 21% in T_CSA, when intubated. Whether this effect of the endotracheal tube would bias the findings of the relationships between the tracheal size and brachycephalic obstructive airway syndrome severity requires further investigation. T_P has been used in several studies in human medicine such as tracheomegaly in children³⁶, age-related changes in the trachea³⁷, and perinatal endotracheal tube size determination³⁸. The dynamics of the trachea are comparable to those of a collapsible tube. If one assumes that the dorsal membrane of the trachea is inextensible, one would predict that the perimeter (unlike other measurements such as height, width, or cross-sectional area) stays the same even when there is a shape change, such as when the dorsal membrane is collapsed or folded inwards. In this study, T_P is only minimally affected by the endotracheal tube placement (4% increase in T_P when intubated), and it is highly correlated to other tracheal measurements. However, T_P was significantly larger (mean difference = 0.86 mm) when the patient was intubated compared to when it was extubated. This finding might be explained by an extensible dorsal membrane (Figure 5A). One physiological study on tracheal mechanics proposes that the changes in the compliance of the dorsal membrane due to pressure could change its length and curvature³⁹. However, this theory has only been tested in rabbits that have a different anatomical tracheal structure compared to dogs. Although T_P was significantly different between intubated and

extubated measurements, the equation reported in this study (extubated T_P = -1.17 + 1.01 * intubated T_P) can be used to predict the extubated measurements from intubated measurements with decent level of accuracy (R²=0.921). Finally, it is worth noting that there could be a 24% difference in the tracheal cross-sectional area when going from inspiration to expiration¹⁷. Thus, we routinely hyperventilate the dogs during the scans, and recommend this procedure when attempting to measure tracheal size consistently.

This study did not evaluate whether there was an association between brachycephalic obstructive airway syndrome severity and the recommended measurements (SP_{RT}, T_P, and NP_R) that were minimally affected by the presence of the endotracheal tube. The decision was made due to the small number of subject with three different breeds involved. Nonetheless, SP_{MT} was found to be significantly thicker in dogs with severe brachycephalic obstructive airway syndrome than absent/minimal brachycephalic obstructive airway syndrome and healthy mesaticephalic dogs⁶. While SP_{MT} and SP_{RT} are highly correlated, it is likely that SP_{RT} is related to the severity of brachycephalic obstructive airway syndrome. Further studies are required to confirm this hypothesis. The cross-sectional area of the nasopharyngeal meatus has not been associated with the severity of brachycephalic obstructive airway syndrome in previous literature. While the collapsibility and narrowing of the nasopharynx were reported in dogs with brachycephalic obstructive airway syndrome³², NP_R may be a useful measurement for the evaluation. Likewise, tracheal dimension has not been proved to be related to the severity of brachycephalic obstructive airway syndrome. According to the Poiseuille's law⁴⁰, the radius of a tube segment is reduced by one-half, the resistance within the tube increases by 16-fold. It is expected the change in T_P would have the similar impact on the airway resistance. Overall, we hypothesize that SP_{RT}, NP_R, T_P are associated with the severity of brachycephalic obstructive airway syndrome. Further studies are warranted.

There are several limitations in this study: only a small number of dogs were included, which may increase the Type II error rate; some brachycephalic obstructive airway syndrome affected dogs could not be included in the study due to their high risk of undergoing airway obstruction during general anaesthesia without placement of an endotracheal tube. Therefore the effect of the endotracheal tube on the most severely affected dogs could not be determined, and thus, we are unable to identify the effect of the highest severity brachycephalic obstructive airway syndrome on the measurement differences. Furthermore, this study did not compare the measurements with different size of endotracheal tube in the same dog. Some may argue that the effect of the endotracheal tube should be minimal if study participants are consistently intubated for CT scans. However, the position of the tube is still likely to alter the measurements, as previously mentioned in the discussion of soft palate measurements. Further studies are needed to confirm this potential issue. In this study, the intubated scan was always performed prior to the extubated scan. The soft tissue could have been displaced by the endotracheal tube and remained at a position that was different from its original. However, it is not feasible to perform the extubated scans prior to the intubated scans without changing the animal's position, thus, this limitation is unavoidable. All CT scans were performed with the dog's mouth open. One could argue the effect of the tube may be different with a different degree of mouth opening. Although we standardized the size of the mouth gag in the study, the effect of the endotracheal tube may be different in other studies with various degrees of mouth opening.

The effect of the endotracheal tube varied on different measurements of the soft palate, nasopharynx and trachea on CT images. Cautious interpretation of other measurements when an endotracheal tube is present is recommended because in some individuals, the difference between intubated and extubated measurements can be significant. Compared to other measurements, SP_RT, NP_R, and T_P were only minimally affected by the endotracheal tube placement at the area of the soft palate,

nasopharynx, and trachea, respectively. Future studies are needed to investigate the associations between these three measurements and the severity of brachycephalic obstructive airway syndrome.

List of Author Contributions

Category 1

- (a) Conception and Design: Nai-Chieh Liu, Eileen L. Troconis, Marie-Aude Genain, Lajos Kalmar, David R. Sargan, Jane F. Ladlow
- (b) Acquisition of Data: Nai-Chieh Liu, Eileen L. Troconis, Matthew McMillan, Marie-Aude Genain, Jane F. Ladlow
- (c) Analysis and Interpretation of Data: Nai-Chieh Liu, Eileen L. Troconis, David J. Price

Category 2

- (a) Drafting the Article: Nai-Chieh Liu, Eileen L. Troconis, Jane F. Ladlow
- (b) Revision Article for Intellectual Content: Nai-Chieh Liu, Eileen L. Troconis, Matthew McMillan, Marie-Aude Genain, Lajos Kalmar, David J. Price, David R. Sargan, Jane F. Ladlow

Category 3

- (a) Final Approval of the Completed Article: Nai-Chieh Liu, Eileen L. Troconis, Matthew McMillan, Marie-Aude Genain, Lajos Kalmar, David J. Price, David R. Sargan, Jane F. Ladlow

Acknowledgements

The authors would like to thank the diagnostic imaging and anaesthesia teams at the Queen's Veterinary School Hospital, University of Cambridge and the Kennel Club Charitable Trust for their financial support of the brachycephalic obstructive airway syndrome research.

References

1. O'Neill D, Jackson C, Guy JH, et al. Epidemiological associations between brachycephaly and upper respiratory tract disorders in dogs attending veterinary practices in England. *Canine Genet Epidemiol.* 2015;2:10.
2. Liu N-C, Adams V, Kalmar L, Ladlow J, Sargan D. Whole-body barometric plethysmography characterizes upper airway obstruction in 3 brachycephalic breeds of dogs. *J Vet Intern Med.* 2016;30:853-865.
3. Liu N-C, Sargan D, Adams V, Ladlow J. Characterisation of brachycephalic obstructive airway syndrome in French bulldogs using whole-body barometric plethysmography. *PLoS One.* 2015;10(6):e0130741.
4. Knecht C. Upper airway obstruction in brachycephalic dogs. *Comp Cont Educ Pract.* 1979;1:25-30.
5. Hendricks JC. Brachycephalic airway syndrome. *Vet Clin North Am Small Anim Pract.* 1992;22(5):1145-1153.
6. Grand J-GR, Bureau S. Structural characteristics of the soft palate and meatus nasopharyngeus in brachycephalic and non-brachycephalic dogs analysed by CT. *J Small Anim Pract.* 2011;52(5):232-239.
7. Heidenreich D, Gradner G, Kneissl S, Dupre G. Nasopharyngeal dimensions from computed tomography of pugs and French bulldogs with brachycephalic airway syndrome. *Vet Surg.* 2016;45(1):83-90.

8. Kaye BM, Boroffka SA, Haagsman AN, Haar GT. Computed tomographic, radiographic, and endoscopic tracheal dimensions in English bulldogs with Grade 1 clinical signs of brachycephalic airway syndrome. *Vet Radiol Ultrasound*. 2015;56(6):609-616.
9. Caccamo R, Buracco P, La Rosa G, Cantatore M, Romussi S. Glottic and skull indices in canine brachycephalic airway obstructive syndrome. *BMC Vet Res*. 2014;10:12.
10. Marchant T, Johnson E, McTeir L, et al. Canine brachycephaly is associated with a retrotransposon-mediated missplicing of SMOC2. *Curr Biol*. 2017;27:1573-1584.
11. Liu NC, Troconis EL, Kalmar L, et al. Conformational risk factors of brachycephalic obstructive airway syndrome (BOAS) in pugs, French bulldogs, and bulldog. *PLoS One*. 2017;12(8):e0181928.
12. Oechtering GU, Pohl S, Schlueter C, et al. A Novel approach to brachycephalic syndrome. 1. Evaluation of anatomical intranasal airway obstruction. *Vet Surg*. 2016;45(2):165-172.
13. Ginn J, Kumar M, McKiernan B, Powers B. Nasopharyngeal turbinates in brachycephalic dogs and cats. *J Am Anim Hosp Assoc*. 2008;44:243-249.
14. Grosso F, Haar G, Boroffka S. Gender, weight, and age effects on prevalence of caudal aberrant nasal turbinates in clinically healthy English bulldogs: a computed tomographic study and classification. *Vet Radiol Ultrasound*. 2015;00:1-8.
15. Auger M, Alexander K, Beauchamp G, Dunn M. Use of CT to evaluate and compare intranasal features in brachycephalic and normocephalic dogs. *J Small Anim Pract*. 2016;57:529-536.
16. Stadler K, Hartman S, Matheson J, O'Brien R. Computed tomographic imaging of dogs with primary laryngeal or tracheal airway obstruction. *Vet Radiol Ultrasound*. 2011;52(4):377-384.

17. Leonard CD, Johnson LR, Bonadio CM, Pollard RE. Changes in tracheal dimensions during inspiration and expiration in healthy dogs as detected via computed tomography. *Am J Vet Res.* 2009;70(8):986-991.
18. Rubin JA, Holt DE, Reetz JA, Clarke DL. Signalment, clinical presentation, concurrent diseases, and diagnostic findings in 28 dogs with dynamic pharyngeal collapse (2008-2013). *J Vet Intern Med.* 2015;29(3):815-821.
19. Cronin A, Ladlow J, Rudolf H. Echolaryngography as a tool to assess laryngeal collapse in brachycephalic dogs. European association of veterinary diagnostic imaging (EAVDI) pre-BSAVA meeting 2016; Birmingham, UK.
20. Abramson Z, Susaria S, August M, Troulis M, Kaban L. Three-dimensional computed tomographic analysis of airway anatomy in patients with obstructive sleep apnea. *J Oral Maxillofac Surg.* 2010;68(2):354-362.
21. Galvin J, Rooholamini S, Stanford W. Obstructive sleep apnea: diagnosis with ultrafast CT. *Radiol.* 1989;171:775-778.
22. Peh W, Lp M, Chu F, Cung K-F. Computed tomographic cephalometric analysis of Chinese patients with obstructive sleep apnoea. *J Med Imaging Radiat Oncol.* 2000;44(4):417-423.
23. Shigeta Y, Ogawa T, Tomoko I, Clark G, Enciso R. Soft palate length and upper airway relationship in OSA and non-OSA subjects. *Sleep Breath.* 2010;14(4):353-358.
24. Bland J, Altman D. Statistical methods for assessing agreement between two pairs of clinical measurement. *Lancet.* 1986;I:307-310.
25. Shapiro S, Wilk M. An analysis of variance test for normality (complete samples). *Biometrika.* 1965;52:591-611.

26. Gamer M, Lemon J, Fellows I, Singh P. irr: Various Coefficients of Interrater Reliability and Agreement. 2012. R package version 0.84.
27. Riecks T, Birchard S, Stephens J. Surgical correction of brachycephalic syndrome in dogs: 62 cases (1991–2004). *J Am Vet Med Assoc.* 2007;230:1324-1328.
28. Torrez C, Hunt G. Results of surgical correction of abnormalities associated with brachycephalic airway obstruction syndrome in dogs in Australia. *J Small Anim Pract.* 2006;47:150-154.
29. Poncet C, Dupré G, Freiche V, Estrada M, Poubannet Y, Bouvy B. Prevalence of gastrointestinal tract lesions in 73 brachycephalic dogs with upper respiratory syndrome. *J Small Anim Pract.* 2005;46:273-279.
30. Tsuiki S, Isono S, Ishikawa T, Yamashiro Y, Tatasumi K, Nishino T. Anatomical balance of upper airway and obstructive sleep apnea. *Anesthesiol.* 2008;108:1009-1015.
31. Isono S. Contribution of obesity and craniofacial abnormalities to pharyngeal collapsibility in patients with obstructive sleep apnea. *Sleep Biol Rhythms.* 2004;2:17-21.
32. Oechtering G. Brachycephalic syndrome – new information on an old congenital disease. *Vet Rec.* 2010;20(2):2-9.
33. Clarke DL, Holt DE, King LG. Partial resolution of hypoplastic trachea in six english bulldog puppies with bronchopneumonia. *J Am Anim Hosp Assoc.* 2011;47(5):329-335.
34. Harvey CE, Fink EA. Tracheal diameter: analysis of radiographic measurements in brachycephalic and nonbrachycephalic dogs. *J Am Anim Hosp Assoc.* 1982;18:570-576.
35. Coyne BE, Finland RB. Hypoplasia of the trachea in dogs: 103 cases (1974-1990). *J Am Vet Med Assoc.* 1992;201(5):768-772.

36. Breyssem L, Debeer A, Claus F, et al. Cross-sectional study of tracheomegaly in children after fetal tracheal occlusion for severe congenital diaphragmatic hernia. *Radiol.* 2010;257:226-232.
37. Sakai H, Nakano Y, Muro S, et al. Age-related changes in the trachea in healthy adults. *Adv Exp Med Biol.* 2010;662:115-120.
38. Fayoux P, Devisme L, Merrot O, Marciniak B. Determination of endotracheal tube size in a perinatal population: an anatomical and experimental study. *Anesthesiol.* 2006;104(5):954-960.
39. Holzhauser U, Lambert R. Analysis of tracheal mechanics and applications. *J Appl Physiol.* 2001;91:290-297.
40. Suter S, Skalak R. The history of Poiseuille's Law. *Annu Rev Fluid Mech.* 1993;25:1-20.

Tables

TABLE 1. Descriptions of the Computed Tomographic Measurements Performed in the Study

Measurements	Abbr.	Descriptions
Soft palate		
Soft palate length	SP_L	From caudal edge of the hard palate to the caudal edge of the soft palate
Rostral soft palate thickness	SP_RT	SP_RT was defined as the distance between the dorsal and ventral limits of the soft palate perpendicular to the SP_L at the caudal end of the hard palate
Middle soft palate thickness	SP_MT	SP_MT was defined as the distance between the dorsal and ventral limits of the soft palate perpendicular to SP_L at the central point of SP_L
Soft palate cross-sectional area	SP_CSA	The cross-sectional area of the soft palate from caudal edge of the hard palate to the caudal edge of the soft palate. The margin of the SP_CSA at the hard palate end was adjacent to the perpendicular line of the SP_L at the end point of the hard palate

Nasopharynx^β

Rostral cross-sectional area of the nasopharynx **NP_R** The cross-sectional area of the nasopharynx at the caudal edge of the hamulus process of the pterygoid bone

Caudal cross-sectional area of the nasopharynx **NP_C** The cross-sectional area of the nasopharynx at the caudal inner edge of the tympanic bulla

Trachea^γ

Tracheal height **T_H** Internal height of the trachea lumen

Tracheal width **T_W** Internal width of the tracheal lumen

Tracheal cross-sectional area **T_CSA** Internal cross-sectional area of the tracheal lumen

Tracheal lumen perimeter **T_P** Internal perimeter of the tracheal lumen

Abbr. = abbreviation

^α All soft palate measurements were performed in the mid-sagittal plane (Figure 2A).

^β All measurements were performed on the transverse planes (Figure 2C).

^γ All measurements were performed on the transverse planes of the trachea (Figure 2B). The region of trachea that was measured was at the level of the 4th cervical vertebra (C4).

TABLE 2. The Comparisons Between the Quantitative Computed Tomographic Measurements with and without Endotracheal Tube Placement

Measurements	Differences ^a	Linear regression				
		R ²	Intercept	β	ICC (95%CI) ^e	
Soft palate	SP_L (mm)	0.35 ± 5.16, 8.6%	0.637	13.98	0.70	0.809 (0.578-0.920)
	SP_RT (mm)	0.03 ± 0.84, 8.9%	0.923	0.47	0.93	0.964 (0.910-0.986)
	SP_MT (mm)	-0.71 ± 2.03, 12.2%	0.761	1.25	0.95	0.870 (0.696-0.948)
	SP_CSA (mm ²)	-55.77 ± 86.69*, 17.3%	0.837	16.21	1.09	0.877 (0.624-0.956)
Nasopharynx	NP_R (mm ²)	0.73 ± 8.86, 14.3%	0.929	0.56	0.98	0.967 (0.917-0.987)
	NP_C (mm ²)	0 (22.44) ^b , 34.8%	0.806 ^d	1.03 ^d	0.94 ^d	0.908 (0.775-0.964)
Trachea	T_H (mm)	0.61 ± 1.15 *, 10.1%	0.756	-0.57	1.0	0.844 (0.607-0.939)
	T_W (mm)	0.52 ± 1.12, 9.4%	0.679	0.78	0.88	0.811 (0.565-0.922)
	T_CSA (mm ²)	13.82 ± 15.85 **, 20.8%	0.775	-1.17	0.86	0.821 (0.338-0.940)
	T_P (mm)	0.86 ± 1.55 *, 4.3%	0.921	-1.17	1.01	0.951 (0.855-0.982)

SP_L=soft palate length; SP_RT=rostral soft palate thickness; SP_MT=middle soft palate thickness; SP_CSA=soft palate cross-sectional area; NP_R=rostral cross-sectional area of the nasopharynx; NP_C=caudal cross-sectional area of the nasopharynx; T_H=tracheal height; T_W=tracheal width; T_CSA=tracheal cross-sectional area; T_P=tracheal lumen perimeter

^a Difference was calculated by intubated measurements minus extubated measurements. Differences are presented as “mean ± standard deviation, proportional absolute difference”, for normal distributed data; and as median (interquartile range), proportional absolute difference, for non-normal distributed data, where labeled with ^b. Proportional absolute difference is defined as the absolute difference divided by the mean of the intubated and extubated measurements (in percentage).

* The difference was significant between the intubated and extubated measurements at the level of $p < 0.05$, ** $p < 0.01$.

^c All the linear regression models were significant at the level of $p < 0.001$.

^d Data were transformed with squared root for the linear regression model.

^e ICC=intraclass correlation coefficient; CI=confidence interval, data presented as lower bound and upper bound of CI. The most reliable measurement (according to the ICC value and the lower bound of its 95%CI) among others from the same anatomical area is highlighted in bold.

Figure Legends

FIGURE 1. Standardization of axes alignment. Two different re-slicing criteria were used: (A)-(C) are for the soft palate and nasopharyngeal measurements. On the sagittal view, the red axis is parallel to the ventral margin of the basisphenoid bone. On the dorsal view, the green axis is located rostrally at the caudal end of the vomer and caudally at the middle distance between the two processes of the pterygoid bones. On transverse view, the green axis is located dorsally at the bregma and ventrally at the middle distance between the two processes of the pterygoid bones; (D)-(F) are for the tracheal measurements. On the sagittal view, at the middle region of the projection of the 4th cervical vertebrae on the trachea, the red axis is adjusted to be parallel to the tracheal internal walls. On the dorsal plane, the green axis is set to be parallel to the tracheal internal walls. On the transverse view, the cross of the two axes (red and green) is at the center of the tracheal lumen.

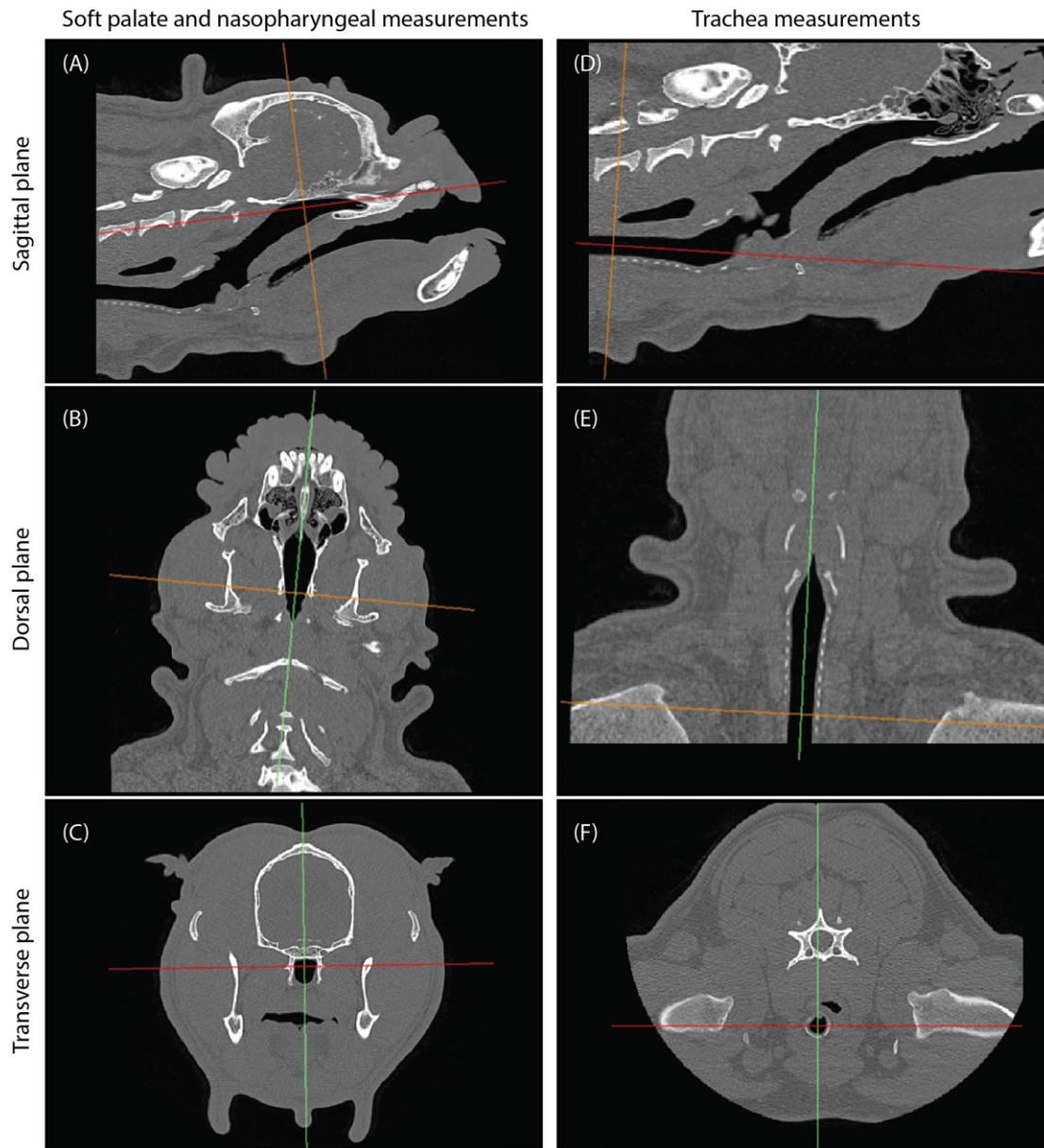
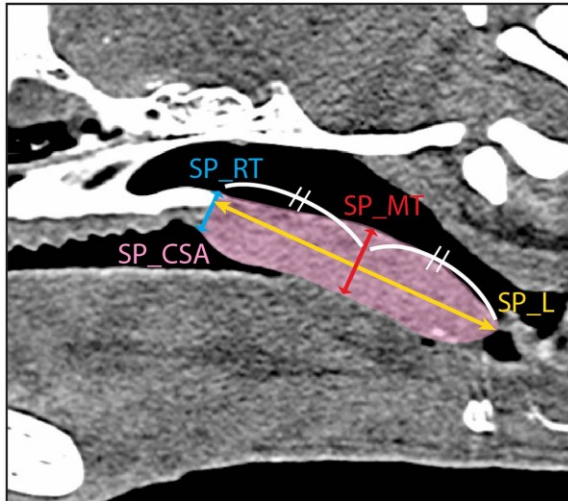


FIGURE 2. Demonstrations of the measurements on computed tomographic images. (A) Soft palate measurements on the mid-sagittal view. SP_L = soft palate length (yellow line), SP_RT = rostral soft palate thickness (blue line), SP_MT = middle soft palate thickness (red line), SP_CSA = soft palate cross-sectional area (pink area); (B) Tracheal measurements on the transverse view. T_H = tracheal height (purple line), T_W = tracheal width (blue line), T_P = tracheal perimeter (red outline), T_CSA = tracheal cross-sectional area (yellow area); (C) Nasopharyngeal measurements. NP_R = rostral nasopharyngeal cross-sectional area (yellow star, NP_C = caudal nasopharyngeal cross-

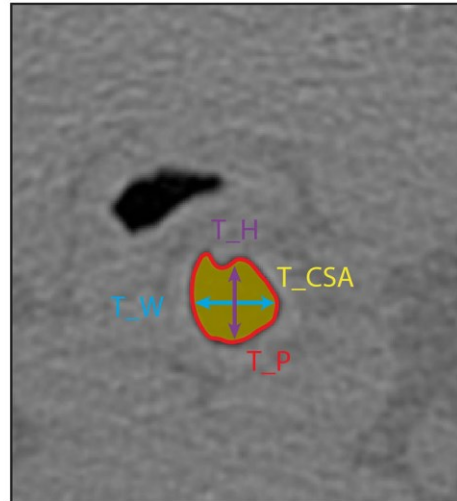
sectional area (red star). The bottom two lateral views demonstrate the corresponding level of the NP_R (yellow line) and NP_C (red line) measurements.



(A) Soft palate



(B) Trachea



(C) Nasopharynx

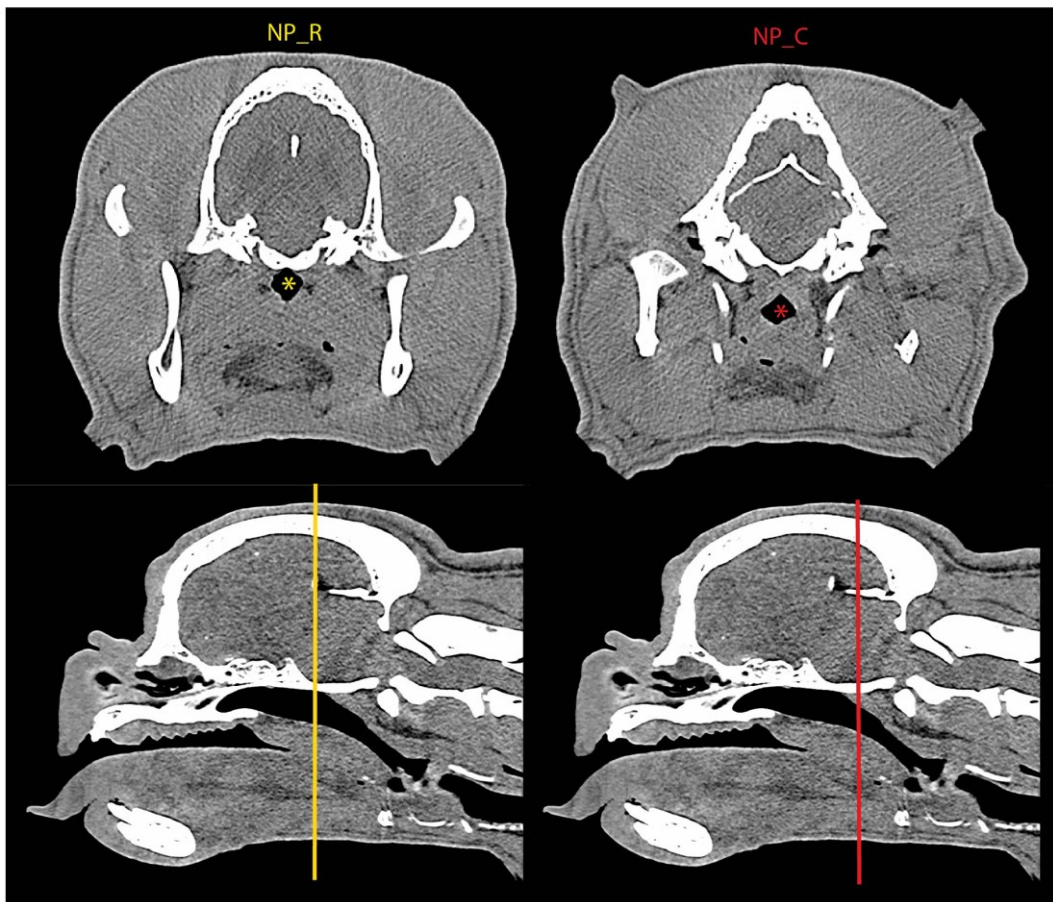


FIGURE 3. Effect of endotracheal (ET) tube placement on soft palate measurements. (A) An example of a bulldog's CT mid-sagittal view demonstrating the changes in soft palate shape caused by the ET tube; (B) Bland and Altman plots show the associations between the mean (average of the intubated and extubated measurements) and the difference (intubated measurements minus extubated measurements). SP_L = soft palate length, SP_RT = rostral soft palate thickness, SP_MT = middle soft palate thickness, SP_CSA = soft palate cross-sectional area. SD = standard deviations. Bias indicates the mean differences. The red shading shows the 95% confidence intervals of the bias, calculated from paired t-test. The region between the ± 1.96 SD indicates the limit of agreement between the intubated and extubated measurements.

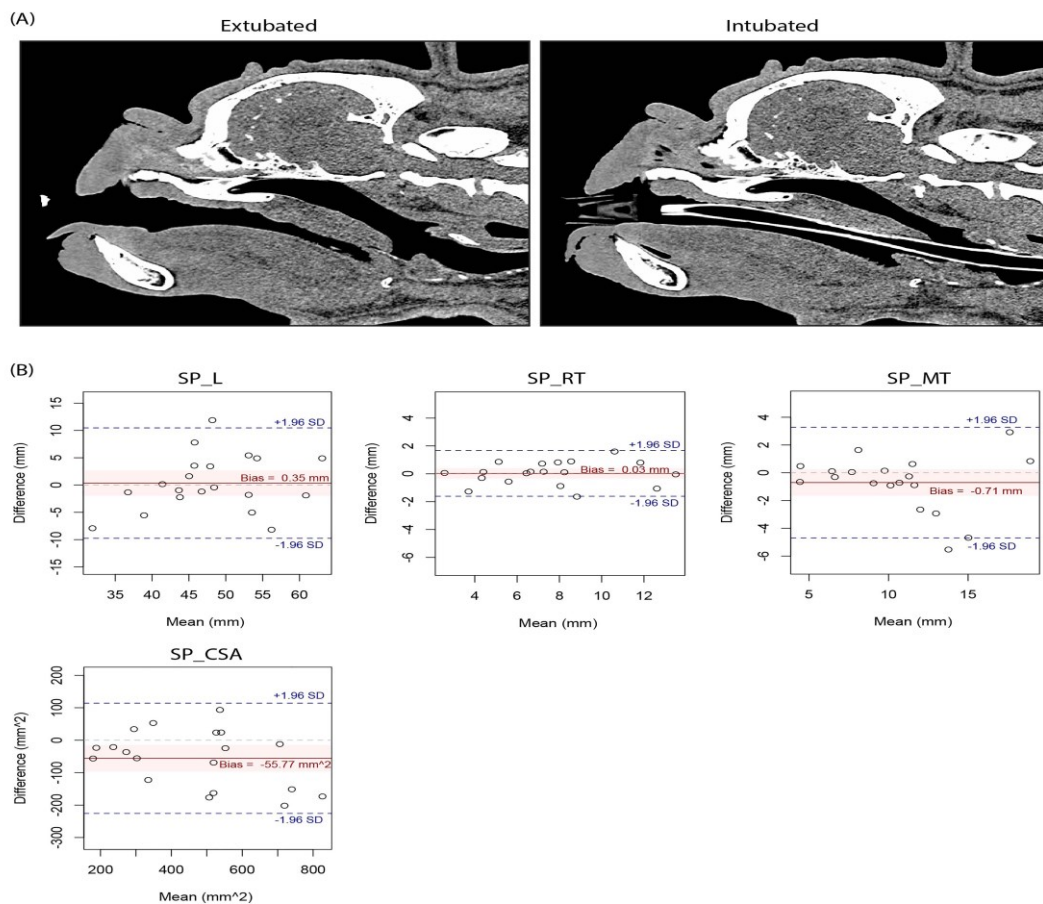
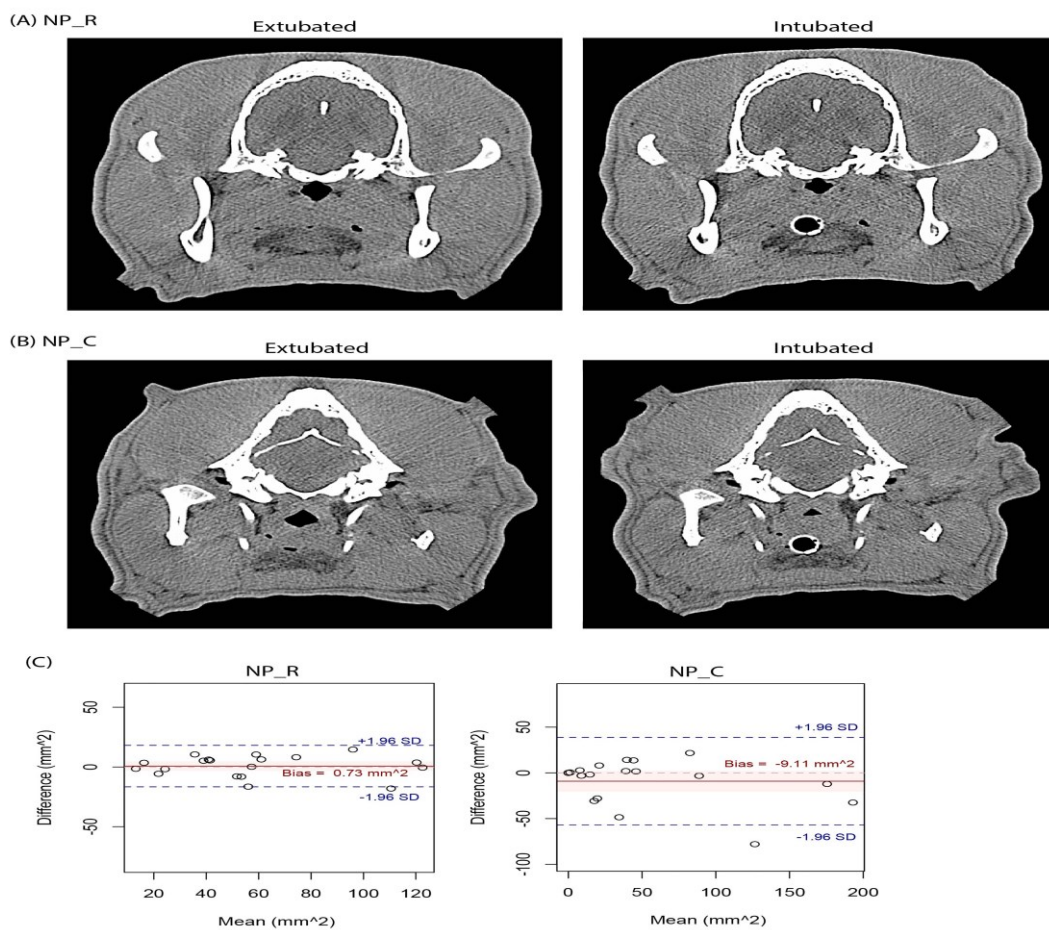


FIGURE 4. Effect of the endotracheal (ET) tube placement on nasopharyngeal measurements.

(A) An example of a bulldog's CT transverse view demonstrating the changes in NP_R caused by the ET tube; (B) An example of a bulldog demonstrating the changes in NP_C by the ET tube on the CT transverse view; (C) Bland and Altman plots show the associations between the mean (average of the intubated and extubated measurements) and the difference (intubated measurements minus extubated measurements). NP_R = rostral nasopharyngeal cross-sectional area, NP_C = caudal nasopharyngeal cross-sectional area. Bias indicates the mean differences. The red shading shows the 95% confidence intervals of the bias, calculated from paired t-tests. The region between the ± 1.96 SD indicates the limit of agreement between the intubated and extubated measurements.



A

FIGURE 5. Effect of the endotracheal (ET) tube placement on tracheal measurements. (A) An example of a bulldog's CT transverse view demonstrating the changes in tracheal cross-sectional dimensions caused by the ET tube; (B) Bland and Altman plots show the associations between the mean (average of the intubated and extubated measurements) and the difference (intubated measurements minus extubated measurements). T_H = tracheal height, T_W = trachea width, T_P = tracheal perimeter, T_CSA = tracheal cross-sectional area. Bias indicates the mean differences. The red shading shows the 95% confidence intervals of the bias, calculated from paired t-tests. The region between the ± 1.96 SD indicates the limit of agreement between the intubated and extubated measurements.

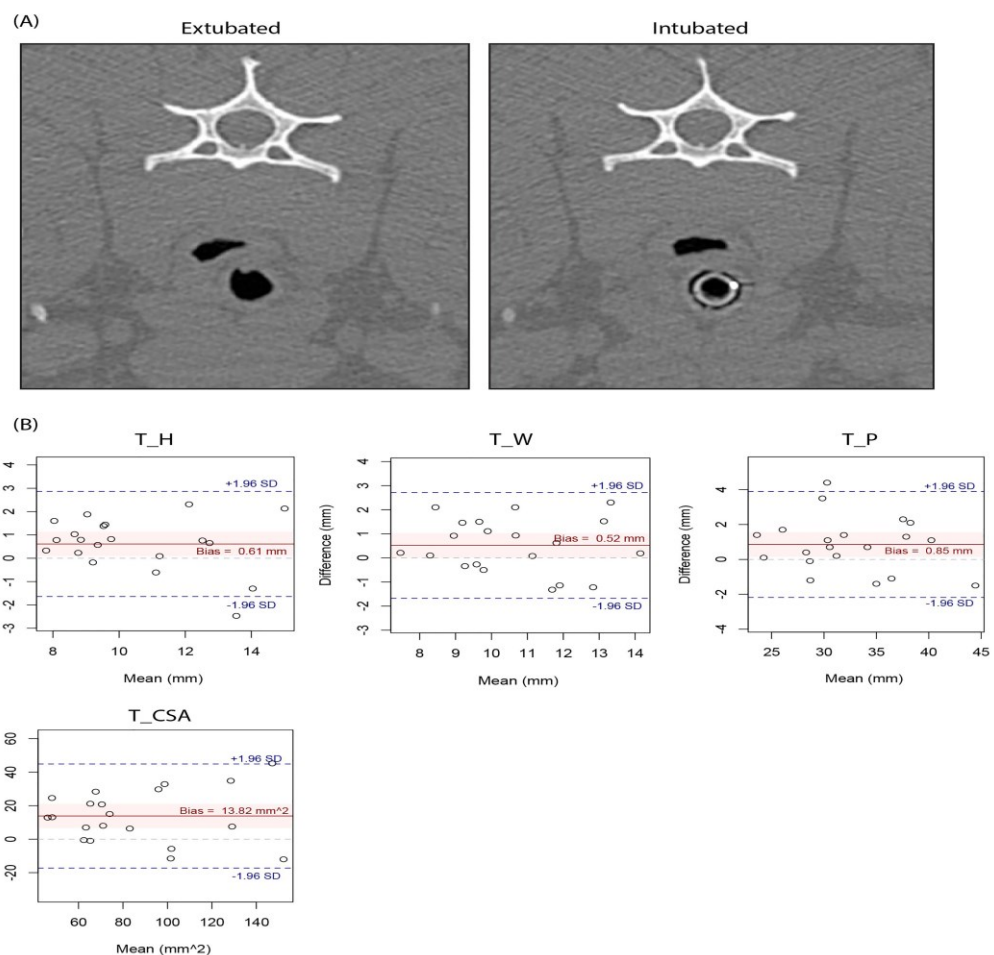
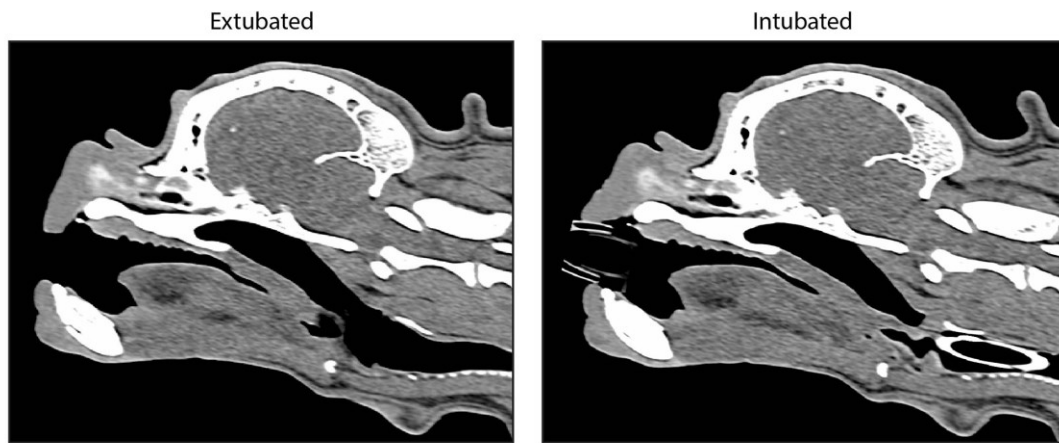


FIGURE 6. Effect of the endotracheal tube (ET) on soft palate on mid-sagittal view of the computed tomographic images. Noted that the ET tube was deflected to the left, compared to Figure 3 where the ET tube was placed along the mid-line. The soft palate shape is altered.



Appendix

Appendix 1. Results of the multiple linear regressions assessing the effect of the relative size of the endotracheal (ET) tube and brachycephalic obstructive airway syndrome (BOAS) severity on the measurement differences between intubation and extubation.

Soft palate

Parameter: SP_L (mm)		Coefficient	SE	p-value
Adjusted R ² =0.121, p=0.176				
(Intercept)		-0.429	4.506	0.925
Relative size of ET tube		7.343	5.399	0.193
BOAS Severity	BOAS Grade 0/I (reference)	-	-	-
	BOAS Grade II	-2.418	1.915	0.225

	BOAS Grade III	0.098	2.082	0.963
--	-----------------------	-------	-------	-------

Parameter: SP_RH (mm) Adjusted R ² =0.047, p=0.862		Coefficient	SE	p-value
(Intercept)		0.303	0.859	0.729
Relative size of ET tube		0.324	1.029	0.758
BOAS Severity	BOAS Grade 0/I (reference)	-	-	-
	BOAS Grade II	0.168	0.364	0.651
	BOAS Grade III	-0.062	0.409	0.881

Parameter: SP_MH (mm) Adjusted R ² =0.208, p=0.093		Coefficient	SE	p-value
(Intercept)		-2.671	2.167	0.237
Relative size of ET tube		4.111	2.597	0.134
BOAS Severity	BOAS Grade 0/I (reference)	-	-	-
	BOAS Grade II	1.533	0.920	0.116
	BOAS Grade III	0.021	1.032	0.984

Parameter: SP_CSA (mm²) Adjusted R ² =0.206, p=0.094		Coefficient	SE	p-value
(Intercept)		-107.75	87.38	0.237
Relative size of ET tube		177.70	104.73	0.110
BOAS Severity	BOAS Grade 0/I (reference)	-	-	-
	BOAS Grade II	72.44	37.09	0.070
	BOAS Grade III	26.72	41.62	0.531

Nasopharynx

Parameter: NP_R (mm ²)		Coefficient	SE	p-value
Adjusted R ² =0.098, p=0.661				
(Intercept)		-1.402	8.187	0.866
Relative size of ET tube		7.148	9.813	0.478
BOAS Severity	BOAS Grade 0/I (reference)	-	-	-
	BOAS Grade II	3.563	3.476	0.322
	BOAS Grade III	3.177	3.900	0.428

Parameter: NP_C (mm ²)		Coefficient	SE	p-value
Adjusted R ² =0.134, p=0.528				
(Intercept)		-19.577	31.937	0.549
Relative size of ET tube		53.915	38.280	0.179
BOAS Severity	BOAS Grade 0/I (reference)	-	-	-
	BOAS Grade II	-7.094	13.557	0.608
	BOAS Grade III	-9.210	15.211	0.554

Trachea

Parameter: T_H (mm)		Coefficient	SE	p-value
Adjusted R ² =0.115, p=0.570				
(Intercept)		-0.10	1.129	0.931
Relative size of ET tube		1.793	1.353	0.204
BOAS	BOAS Grade 0/I (reference)	-	-	-

Severity	BOAS Grade II	-0.275	0.480	0.574
	BOAS Grade III	-0.278	0.522	0.602

Parameter: T_W (mm)		Coefficient	SE	p-value
Adjusted R ² =0.020, p=0.955				
(Intercept)		0.366	1.159	0.757
Relative size of ET tube		0.704	1.389	0.619
BOAS Severity	BOAS Grade 0/I (reference)	-	-	-
	BOAS Grade II	0.081	0.493	0.872
	BOAS Grade III	0.120	0.536	0.825

Parameter: T_CSA (mm ²)		Coefficient	SE	p-value
Adjusted R ² =0.071, p=0.257				
(Intercept)		-16.971	18.170	0.364
Relative size of ET tube		32.863	21.774	0.151
BOAS Severity	BOAS Grade 0/I (reference)	-	-	-
	BOAS Grade II	8.526	7.724	0.286
	BOAS Grade III	11.644	8.397	0.185

Parameter: T_P (mm)		Coefficient	SE	p-value
Adjusted R ² =0.077, p=0.724				
(Intercept)		-0.464	1.723	0.791
Relative size of ET tube		2.326	2.065	0.277
BOAS Severity	BOAS Grade 0/I (reference)	-	-	-
	BOAS Grade II	0.002	0.733	0.998

	BOAS Grade III	0.101	0.796	0.901
--	-----------------------	-------	-------	-------

SP_L=soft palate length; SP_RT=rostral soft palate thickness; SP_MT=middle soft palate thickness;
SP_CSA=soft palate cross-sectional area; NP_R=rostral cross-sectional area of the nasopharynx;
NP_C=caudal cross-sectional area of the nasopharynx; T_H=tracheal height; T_W=tracheal width;
T_CSA=tracheal cross-sectional area; T_P=tracheal lumen perimeter; SE=standard errors.

The dependent variable was the extubated measurement minus the intubated measurement; the independent variables were the relative size of the ET tube (numeric) and BOAS severity (categorical). The relative size of the ET tube was defined as the ratio of the external radius of the ET tube to the internal diameter of the trachea (the mean of T_H and T_W).

Author Manuscript