

Accepted Date : 21-Dec-2016

Article type : Special Report

Instruction manual for the ILAE 2017 Operational Classification of Seizure Types

Robert S. Fisher¹, J. Helen Cross², Carol D'Souza³, Jacqueline A. French⁴, Sheryl Haut⁵, Norimichi Higurashi⁶, Edouard Hirsch⁷, Floor E. Jansen⁸, Lieven Lagae⁹, Solomon L. Moshé¹⁰, Jukka Peltola¹¹, Eliane Roulet Perez¹², Ingrid E. Scheffer¹³, Andreas Schulze-Bonhage¹⁴, Ernest Somerville¹⁵, Michael Sperling¹⁶, Elza Marcia Yacubian¹⁷, Sameer M. Zuberi¹⁸.

robert.fisher@stanford.edu; h.cross@ucl.ac.uk; Jacqueline.french@nyumc.org;
higijh.n@gmail.com; edouard.hirsch@chru-strasbourg.fr; F.E.Jansen@umcutrecht.nl;
lieven.lagae@uzleuven.be; solomon.moshe@einstein.yu.edu ; jukka.peltola@pshp.fi;
eliane.roulet-perez@chuv.hospvd.ch; scheffer@unimelb.edu.au; sameer.zuberi@nhs.net;
andreas.schulze-bonhage@uniklinik-freiburg.de; e.somerville@unsw.edu.au;
Ernest.Somerville@sesiahs.health.nsw.gov.au; Michael.Sperling@jefferson.edu;
sheryl.haut@einstein.yu.edu; yacubian@terra.com.br; carold_souza@hotmail.com

¹ Stanford Department of Neurology & Neurological Sciences, Stanford, CA, USA

² UCL-Institute of Child Health, & Great Ormond Street Hospital for Children, London, UK

This is the author manuscript accepted for publication and has undergone full peer review but has not been through the copyediting, typesetting, pagination and proofreading process, which may lead to differences between this version and the [Version of Record](#). Please cite this article as [doi: 10.1111/epi.13671](https://doi.org/10.1111/epi.13671)

³ Bombay Epilepsy Society, Mumbai, India.

⁴ Department of Neurology, NYU Langone School of Medicine, NY USA

⁵ Montefiore Medical Center, Albert Einstein College of Medicine, Bronx, New York City, NY, USA

⁶ Department of Pediatrics, Jikei University School of Medicine, Tokyo, Japan

⁷ Unite Francis Rohmer, Strasbourg France

⁸ Department of Pediatric Neurology, Brain Center Rudolf Magnus, University Medical Center, Utrecht, The Netherlands

⁹ Pediatric Neurology, University Hospitals KU Leuven, Leuven, Belgium

¹⁰ Saul R. Korey Department of Neurology, Department of Pediatrics and Dominick P. Purpura Department Neuroscience, Montefiore Medical Center, Bronx, NY USA

¹¹ Department of Neurology, Tampere University Hospital, Tampere, Finland

¹² Unité de Neurologie et Neuroréhabilitation Pédiatrique CHUV-1011 Lausanne Switzerland

¹³ Florey Institute and University of Melbourne, Austin Health and Royal Children's Hospital, Melbourne, Australia

¹⁴ Epilepsy Center, University Medical Center Freiburg, Freiburg, Germany.

¹⁵ Prince of Wales Clinical School, Faculty of Medicine, University of New South Wales, NSW 2052, Sydney, Australia

¹⁶ Jefferson Comprehensive Epilepsy Center, Department of Neurology, Thomas Jefferson University, Philadelphia, PA, USA.

¹⁷ Department of Neurology and Neurosurgery, Unidade de Pesquisa e Tratamento das Epilepsias, Brasil

¹⁸ The Paediatric Neurosciences Research Group, Royal Hospital for Children, Glasgow, UK & College of Medicine, Veterinary & Life Sciences, University of Glasgow, United Kingdom

Corresponding author:

Robert S. Fisher, MD, PhD
Neurology, SNHC, Room 4865
213 Quarry Road
Palo Alto, CA 94304
robert.fisher@stanford.edu
Phone: (650) 721-5289
Fax: (650) 721-4865

Running title: Instruction manual for the ILAE 2017 seizure classification

Key Words: classification, seizures, focal, generalized, epilepsy (taxonomy)

Number of text pages: 23

Number of words (without figs, tables, text box): 4,841

Number of tables: 4

Number of figures: 2

Summary

This companion paper to the introduction of the International League Against Epilepsy (ILAE) 2017 classification of seizure types provides guidance on how to employ the classification.

This article is protected by copyright. All rights reserved

Illustration of the classification is enacted by tables, a glossary of relevant terms, mapping of old to new terms, suggested abbreviations and examples. Basic and extended versions of the classification are available, depending upon the desired degree of detail. Key signs and symptoms of seizures (semiology) are used as a basis for categories of seizures that are focal or generalized from onset or with unknown onset. Any focal seizure can further be optionally characterized by whether awareness is retained or impaired. Impaired awareness during any segment of the seizure renders it a focal impaired awareness seizure. Focal seizures are further optionally characterized by motor onset signs and symptoms: atonic, automatisms, clonic, epileptic spasms, hyperkinetic, myoclonic or tonic activity. Non-motor onset seizures can manifest as autonomic, behavior arrest, cognitive, emotional or sensory dysfunction. The earliest prominent manifestation defines the seizure type, which might then progress to other seizure types. Focal seizures can become bilateral tonic-clonic. Generalized seizures engage bilateral networks from onset. Generalized motor seizure characteristics comprise atonic, clonic, epileptic spasms, myoclonic, myoclonic-atonic, myoclonic-tonic-clonic, tonic or tonic-clonic. Nonmotor (absence) seizures are typical or atypical, or seizures that present prominent myoclonic activity or eyelid myoclonias. Seizures of unknown onset may have features that can still be classified as motor, non-motor, tonic-clonic, epileptic spasms or behavior arrest. This “users’ manual” for the ILAE 2017 seizure classification will assist the adoption of the new system.

Introduction

The International League Against Epilepsy (ILAE) has released a 2017 version of seizure type classification (accompanying manuscript). Revision of the classification that has been used in modified form since 1981¹ was motivated by several factors. Some seizure types, for example tonic seizures or epileptic spasms, can have either a focal or generalized onset. Lack of knowledge about the onset makes a seizure unclassifiable. Some terms used to classify seizures lack community acceptance or public understanding, including “dyscognitive,” “psychic,” “partial,” “simple partial,” “complex partial.” Determining whether a person has impaired consciousness during a seizure can be confusing for non-clinicians. Some important seizure types are not included in the 1981 classification. The new classification addresses these relevant issues. Material that follows explains how to apply the 2017 seizure type classification.

Methods

Classification of a seizure begins with historical elicitation or observation of certain symptoms and signs (sometimes referred to as the semiology of seizures) that are known to be associated with common seizures. The key symptoms and signs cannot be matched in one-to-one relationships with seizure types because some symptoms appear in more than one seizure type. Behavior arrest, for example, occurs in both focal impaired awareness seizures and absence seizures. Tonic-clonic activity can be present from onset in a generalized seizure or emerge in the course of a focal onset seizure. Conversely, a seizure type often associates with multiple symptoms. Naming a seizure type an “automatism seizure” would not allow the distinction between a focal seizure with impaired awareness and an absence seizure. Since these two seizure types are treated differently and have different prognoses, maintenance of distinct seizure types is useful, even though some interpretation beyond direct observation may be needed to classify the seizures. Distinction of seizure types usually can be made by recognizing a characteristic sequence of symptoms and other clinical observations. Typical absence seizures, for instance, show more rapid recovery of function than do focal impaired awareness seizures. In some instances, ancillary information from EEG, imaging or laboratory studies is needed to properly classify a seizure. For these cases, classification of seizure type begins to merge imperceptibly with diagnosis of epilepsy syndromes^{2; 3}. As we lack a fundamental pathophysiological understanding of differing seizure presentations, grouping of symptoms and signs into seizure types reflects an operational opinion about which groupings are sufficiently distinct and common as to merit a specific name.⁴ This classification is derived for practical clinical use, but it also can be used by researchers and other groups with specific purposes.

Results

The ILAE 2017 seizure classification presents basic and expanded versions, depending upon the desired degree of detail. The basic version is the same as the expanded version, but with collapse of the subcategories.

Basic Classification

FIGURE 1 NEAR HERE

Figure 1 shows the basic classification. Seizures are first categorized by type of onset. Focal onset seizures are defined as “originating within networks limited to one hemisphere. They may be discretely localized or more widely distributed. Focal seizures may originate in subcortical structures.” Generalized onset seizures are defined as “originating at some point within, and rapidly engaging, bilaterally distributed networks.”⁵ A seizure of unknown onset may still evidence certain defining motor (e.g., tonic-clonic) or non-motor (e.g., behavior arrest) characteristics. With further information or future observed seizures, a re-classification of unknown onset seizures into focal or generalized onset categories may become possible. Therefore, “unknown onset” is not a characteristic of the seizure, but a convenient placeholder for our ignorance. When a seizure type begins with the words “focal,” “generalized” or “absence,” then the word “onset” may be presumed.

Further classification is optional. The next level of focal seizure classification is by level of awareness. Awareness is operationally defined as knowledge of self and environment. Assay of awareness is a pragmatic surrogate marker used to determine whether or not level of consciousness is impaired. During a focal aware seizure, consciousness will be intact. Awareness specifically refers to awareness during a seizure, and not to awareness of whether or not a seizure has occurred. If awareness of the event is impaired for any portion of the seizure, then the seizure is classified as a focal seizure with impaired awareness. As a practical matter, a focal aware seizure implies ability for the person having the seizure to later verify retained awareness. Occasional seizures may produce transient epileptic amnesia⁶ with retained awareness, but classification of such seizures would require exceptionally clear documentation by observers. Some might use the shorthand “focal unaware.” In doing so, it is crucial to note that awareness may be impaired without being fully absent. Word order is not important, so “focal aware seizure” means the same thing as a “focal seizure with retained awareness.”

Responsiveness is a separate clinical attribute that can be either intact or impaired for seizures with or without retained awareness. Although responsiveness is an important descriptive aspect of seizures, it is not used in the ILAE 2017 classification to designate specific seizure

types. The basic classification further allows classification into motor onset or non-motor onset (for example, sensory) symptoms. Further specification invokes the expanded classification, discussed below.

The seizure type “focal to bilateral tonic-clonic” is in a special category because of its common occurrence and importance, even though it is reflective of a propagation pattern of seizure activity rather than a unique seizure type. The phrase “focal to bilateral tonic-clonic” replaces the older term “secondarily generalized tonic-clonic.” In the new classification, “bilateral” is used for propagation patterns of seizures and “generalized” for seizures of generalized onset.

Generalized onset seizures are divided into motor and non-motor (absence) seizures. Level of awareness is not used as a classifier for generalized seizures, since the large majority (although not all) of generalized seizures are associated with impaired awareness. By definition of the generalized branch of the classification, motor activity should be bilateral from the onset, but in the basic classification the type of motor activity need not be specified. In cases where bilateral onset of motor activity is asymmetrical, it may be difficult in practice to determine whether a seizure has focal or generalized onset.

Absence seizures (the prefix “generalized onset” may be assumed) present with a sudden cessation of activity and awareness. Absence seizures tend to occur in younger age groups, have more sudden start and termination and they usually display less complex automatisms than do focal seizures with impaired awareness, but the distinctions are not absolute. EEG information may be required for accurate classification. Focal epileptiform activity may be seen with focal seizures and bilaterally synchronous spike-waves with absence seizures.

Seizures of unknown onset can be categorized as motor, including tonic-clonic, non-motor or unclassified. The term unclassified comprises both seizures with patterns that do not fit into the other categories or seizures presenting insufficient information to allow categorization.

Expanded classification

The expanded classification (Figure 2) provides another level of seizure names, built upon the framework of the basic classification. The vertical organization of the focal onset category is not hierarchical, since naming the level of awareness is optional. A focal seizure can

be classified as focal aware (corresponding to the 1981 term “simple partial seizure”) or focal impaired awareness (corresponding to the 1981 term “complex partial seizure”). Focal aware or impaired awareness seizures can optionally be classified by adding one of the motor onset or non-motor onset terms below, reflecting the earliest prominent sign or symptom other than awareness. Alternatively, a focal seizure name can omit mention of awareness as being inapplicable or unknown and classify the focal seizure directly by the earliest motor or non-motor characteristic.

For focal onset seizures, the clinician should assay level of awareness as described for the basic classification. Ask the patient whether awareness for events occurring during the seizures was retained or impaired, even when the person seizing was unresponsive or unable to understand language. If someone walked into the room during a seizure, would that person’s presence later be recalled? Questioning witnesses may clarify the nature of behavior during the seizure. It is important to attempt to distinguish the ictal versus the postictal state, since awareness returns during the latter. If the state of awareness is uncertain, as for example, is usually the case for atonic or epileptic spasm seizures, then the seizure is classified as focal but awareness would not be specified. Description of level of awareness is optional and applied only when known. A “focal aware seizure,” with or without further characterization, corresponds to the old term “simple partial seizure” and a “focal impaired awareness seizure” to the old term “complex partial seizure.” Subsequent terms in the focal column of the expanded classification can further specify the type of focal aware and focal impaired awareness seizures. Alternatively, the degree of awareness can be left unspecified and a seizure classified as a focal seizure with one of the motor onset or non-motor onset characteristics listed in Figure 2.

FIGURE 2 NEAR HERE

Focal motor onset behaviors include these activities: atonic (focal loss of tone), tonic (sustained focal stiffening), clonic (focal rhythmic jerking), myoclonic (irregular, brief focal jerking), or epileptic spasms (focal flexion or extension of arms and flexion of trunk). The distinction between clonic and myoclonic is somewhat arbitrary, but clonic implies sustained, regularly spaced stereotypical jerks; whereas, myoclonus is less regular and in briefer runs. Other

less obviously focal motor behaviors include hyperkinetic (pedaling, thrashing) activity and automatisms. An automatism is a more or less coordinated purposeless repetitive motor activity. Observers should be asked whether the subject demonstrated repetitive purposeless fragments of behaviors that might appear normal in other circumstances. Some automatisms overlap other motor behaviors, for instance, pedaling or hyperkinetic activity, rendering classification ambiguous. The 2017 ILAE classification arbitrarily groups pedaling activity with hyperkinetic seizures, rather than with automatism seizures. Automatisms may be seen in focal seizures and in absence seizures.

A focal motor seizure with behavior arrest involves cessation of movement and unresponsiveness. Since brief behavioral arrest at the start of many seizures is common and difficult to identify, a focal behavioral arrest seizure should comprise behavioral arrest as the predominant aspect of the entire seizure. Focal autonomic seizures present with gastrointestinal sensations, a sense of heat or cold, flushing, piloerection (goosebumps), palpitations, sexual arousal, respiratory changes or other autonomic effects. Focal cognitive seizures can be identified when the patient reports or exhibits deficits in language, thinking or associated higher cortical functions during seizures and when these symptoms outweigh other manifestations of the seizure. Déjà vu, jamais vu, hallucinations, illusions and forced thinking are examples of induced abnormal cognitive phenomena. A more correct although less euphonious term would be “focal impaired cognition seizure,” but impaired cognition may be assumed, since seizures never improve cognitive function. Focal emotional seizures present with emotional changes, including fear, anxiety, agitation, anger, paranoia, pleasure, joy, ecstasy, laughing (gelastic) or crying (dacrystic). Some of these phenomena are subjective and must be recalled and reported by the patient or caregiver. Emotional symptoms comprise a subjective component; whereas, affective signs may or may not be accompanied by subjective emotionality. Impairment of awareness for events during the seizure does not classify the seizure as a focal cognitive seizure, because impairment of awareness can apply to any focal seizure. A focal sensory seizure can produce somatosensory, olfactory, visual, auditory, gustatory, hot-cold sense or vestibular sensations.

The clinician must decide whether an event is a unified single seizure, with evolving manifestations as the seizure propagates, or alternatively two separate seizures. Such a distinction can sometimes be difficult. A smooth, continuous evolution of signs, symptoms and EEG patterns (where available) favors the event being a single seizure. Repetition of a

stereotyped sequence of signs, symptoms and EEG changes at different times supports a unitary seizure type. Unitary focal seizures are named for the initial manifestation and presence or absence of altered consciousness at any point during the seizure. In contrast, discontinuous, interrupted or non-stereotyped events point to classification of more than one seizure type. Consider an event starting with déjà vu, repetitive purposeless lip-smacking, loss of awareness, forced version to the right and right arm stiffening. This steady evolution implies a unitary seizure, which would be classified as a focal impaired awareness cognitive seizure. It would be useful to append (as optional description, not a seizure type) information about the progression to automatisms and tonic version. In another scenario, the clinician might encounter a seizure with fear and loss of awareness. The patient recovers and 30 minutes later has an event with tingling in the right arm during clear awareness. Such a sequence reflects two separate seizures, the first being a focal impaired awareness emotional seizure and the second a focal aware sensory seizure.

Other focal seizure types are sometimes encountered, for example, focal tonic-clonic seizures, but not sufficiently often to be named as a specific seizure type. Rather than include the term “other” in each category, a decision was made to revert to nonspecific use of the larger category, such as motor onset or non-motor onset when the next level of detail is unclear or the seizure is not listed as a specific seizure type.

The classification of generalized onset seizures is similar to that of the 1981 classification, with addition of a few new types. Awareness usually is impaired with generalized onset seizures, so level of awareness is not used as a classifier for these seizures. The main subdivision is into motor and non-motor (absence) seizure types. The terms “motor” and “non-motor (absence)” are present in order to allow characterization of generalized onset motor or non-motor seizures about which nothing else can be said, but “motor” and “non-motor (absence)” may be omitted if the seizure name is unambiguous, for example, “generalized tonic seizure.” The word “generalized” can be omitted for seizures such as absence that present only with generalized onset.

Tonic-clonic remains the term replacing the “grand mal” seizure type, although popular usage of the old French phrase will undoubtedly persist. Since there is a new seizure type characterized by myoclonic movements preceding tonic (stiffening) and clonic (sustained rhythmic jerking) movements, it is important to document the early movements of a tonic-clonic

seizure as being tonic. The clonic phase of a tonic-clonic seizure typically shows regularly decreasing frequency of jerks over the course of the event. During a tonic-clonic seizure, awareness is lost before the stiffening and jerking movements. Some tonic-clonic seizures may invoke a nonspecific feeling of an impending seizure or a brief period of head or limb version, neither of which invalidates a generalized onset, since biological processes never exhibit perfect synchrony. The clinician has to judge whether a truly focal onset is present.

Generalized clonic seizures begin, progress and end with sustained rhythmical jerking of limbs on both sides of the body and often head, neck, face and trunk. Generalized clonic seizures are much less common than are tonic-clonic seizures, usually occur in infants, and should be distinguished from jitteriness or shuddering attacks.⁷

Generalized tonic seizures manifest as bilateral limb stiffening or elevation, often with neck stiffening. The classification presumes that the tonic activity is not followed by clonic movements. The tonic activity can be a sustained abnormal posture, either in extension or flexion, sometimes accompanied by tremor of the extremities. Tonic activity can be difficult to distinguish from dystonic activity, defined as sustained contractions of both agonist and antagonist muscles producing athetoid or twisting movements, which when prolonged, may produce abnormal postures.

Generalized myoclonic seizures can occur in isolation or in conjunction with tonic or atonic activity. Myoclonus differs from clonus by being briefer and not regularly repetitive. Myoclonus as a symptom has possible epileptic and non-epileptic etiologies.

Generalized myoclonic-tonic-clonic seizures begin with a few myoclonic jerks followed by tonic-clonic activity. These seizures are commonly seen in patients with juvenile myoclonic epilepsy⁸ and occasionally with other generalized epilepsies. It is arguable whether the initial jerks are myoclonic or clonic, but they are rarely sufficiently sustained to be considered clonic.

A myoclonic-atonic seizure involves brief jerking of limbs or trunk, followed by a limp drop. These seizures, previously called myoclonic-astatic seizures, are most commonly seen in Doose syndrome,⁹ but can also be encountered in Lennox-Gastaut and other syndromes.

Atonic means without tone. When leg tone is lost during a generalized atonic seizure, the patient falls on the buttocks or sometimes forward onto the knees and face. Recovery is usually within seconds. In contrast, tonic or tonic-clonic seizures more typically propel the patient into a backward fall.

Epileptic spasms previously were referred to as infantile spasms and the term “infantile spasms” remains suitable for epileptic spasms occurring at infantile age. An epileptic spasm presents as a sudden flexion, extension, or mixed extension-flexion of predominantly proximal and truncal muscles. They commonly occur in clusters and most often during infancy.

Generalized non-motor seizure types comprise several varieties of absence seizures. The Task Force retained the distinction between typical and atypical absence, because the two types of seizures usually are associated with different EEG findings, epilepsy syndromes, therapies and prognoses. According to the 1981 classification, which was based upon analysis of numerous video-EEG recordings ¹, absence seizures are considered atypical when they are associated with changes in tone that are more pronounced than in typical absence or the onset or cessation is not abrupt. An EEG may be required to secure the distinction between typical and atypical absence seizures.

A myoclonic absence seizure ¹⁰ refers to an absence seizure with rhythmic three-per-second myoclonic movements, causing ratcheting abduction of the upper limbs leading to progressive arm elevation, associated with three-per-second generalized spike-wave discharges. Duration is typically 10-60 seconds. Impairment of consciousness may not be obvious. Myoclonic absence seizures occur in a variety of genetic conditions and also without known associations.

Eyelid myoclonia are myoclonic jerks of the eyelids and upward deviation of the eyes, often precipitated by closing the eyes or by light. Eyelid myoclonia can be associated with absences, but also can be motor seizures without a corresponding absence, making them difficult to categorize. The 2017 classification groups them with non-motor (absence) seizures, which may seem counter-intuitive, but the myoclonia in this instance is meant to link with absence, rather than with non-motor. Absence seizures with eyelid myoclonia, seizures or EEG paroxysms induced by eye closure and photosensitivity constitutes the triad of Jeavons' syndrome ¹¹.

Seizures of unknown onset can be motor or non-motor. The most important use of this classification is for tonic-clonic seizures for which the beginning was obscured. Further information might allow reclassification as a focal or generalized onset seizure. Epileptic spasms and behavior arrest are other possible seizure types of unknown onset. Epileptic spasms may require detailed video-EEG monitoring to clarify the nature of onset, but doing so is important because a focal onset may correspond to a treatable focal pathology. An unknown onset behavior

arrest seizure could represent a *focal impaired awareness behavior arrest seizure* or an *absence seizure*. A seizure might be unclassified due to inadequate information or inability to place the seizure in other categories. If an event is not clearly a seizure, then it should not be called an unclassified seizure; rather, this classification is reserved for unusual events likely to be seizures, but not otherwise characterized.

Every seizure classification involves some degree of uncertainty. The Task Force adopted the general guideline of an 80% level of certainty that onset was focal or generalized; otherwise, the seizure should be listed as of unknown onset. The 80% level was arbitrarily chosen to match the commonly applied 80% false negative cut-off for statistical analysis.

Common descriptors

Focal seizures provoke a variety of potential sensations and behaviors too diverse to be incorporated into a classification. In order to facilitate a common terminology about seizures, the Task Force listed some common descriptors of behaviors during focal seizures (Table 1), but these are not intrinsic to the classification. In other words, the common descriptors can be added to the seizure classification to clarify the manifestations of individual seizures, but the descriptors do not define unique seizure types in this classification. Descriptors are therefore at a “lower level” than are signs, such as tonic, that define a seizure type. Laterality is a special type of descriptor, but an important one in clinical practice. The Task Force acknowledged the importance of a detailed individual free-text description of a seizure, in addition to the classification.

Table 1 NEAR HERE: Common descriptors of behaviors during and after seizures

Glossary

Table 2 provides a glossary of terms used in this and the accompanying paper. The definitions are not universal, but focused on the aspects of language pertinent to seizures. For

instance, sensory is defined in terms of sensory seizures, not all sensation. Wherever possible, prior accepted definitions from the ILAE glossary of 2001¹² were maintained, in order to support continuity of usage, but this glossary updates some terminology. Reference can be made to earlier literature for definitions of old terms. Terms no longer recommended for use are omitted.

TABLE 2 NEAR HERE: GLOSSARY

Mapping old to new terms

Table 3 provides mapping of old official and popular terms to the 2017 seizure type classification.

TABLE 3 NEAR HERE

Abbreviations

Table 4 provides suggested abbreviations for the main seizure types.

TABLE 4 NEAR HERE: Abbreviations

Summary of Rules for classifying seizures

Author Manuscript

Rules for Classifying Seizures

1. Onset: Decide whether seizure onset is focal or generalized, using an 80% confidence level. Otherwise, onset is unknown.
2. Awareness: For focal seizures, decide whether to classify by degree of awareness or to omit awareness as a classifier. *Focal aware seizures* correspond to the old *simple partial seizures* and *focal impaired awareness seizures* to the old *complex partial seizures*.
3. Impaired awareness at any point: A focal seizure is a *focal impaired awareness seizure* if awareness is impaired at any point during the seizure.
4. Onset predominates: Classify a focal seizure by its first prominent sign or symptom. Do not count transient behavior arrest.
5. Behavior arrest: A *focal behavior arrest seizure* shows arrest of behavior as the prominent feature of the entire seizure.
6. Motor/Non-motor: A *focal aware or impaired awareness seizure* maybe further sub-classified by motor or non-motor characteristics. Alternatively, a focal seizure can be characterized by motor or non-motor characteristics, without specifying level of awareness. Example, a *focal tonic seizure*.
7. Optional terms: Terms such as motor or non-motor may be omitted when the seizure type is otherwise unambiguous.
8. Additional descriptors: After classifying seizure type based on initial manifestations, it is encouraged to add descriptions of other signs and symptoms, suggested descriptors or free text. These do not alter the seizure type. Example: *focal emotional seizure* with tonic right arm activity and hyperventilation.
9. Bilateral vs. generalized: Use the term “bilateral” for tonic-clonic seizures that propagate to both hemispheres and “generalized” for seizures that apparently originate simultaneously in both hemispheres.
10. Atypical absence: Absence is atypical if it has slow onset or offset, marked changes in tone or EEG spike-waves at less than 3 per second.
11. Clonic vs. myoclonic: Clonic refers to sustain rhythmical jerking and myoclonic to a regular unsustained jerking.
12. Eyelid myoclonia: *Absence with eyelid myoclonia* refers to forced upward jerking of the eyelids during an absence seizure.

Examples

1. Tonic-clonic: A woman awakens to find her husband having a seizure in bed. The onset is not witnessed, but she is able to describe bilateral stiffening followed by bilateral shaking. EEG and MRI are normal. This seizure is classified as *unknown onset tonic-clonic*. There is no supplementary information to determine if the onset was focal or generalized. In the old classification, this seizure would have been unclassifiable with no further qualifiers.

2. Focal onset bilateral tonic-clonic: In an alternate scenario of case #1, the EEG shows a clear right parietal slow wave focus. The MRI shows a right parietal region of cortical dysplasia. In this circumstance, the seizure can be classified as *focal to bilateral tonic-clonic*, despite the absence of an observed onset, because a focal etiology has been identified, and the overwhelming likelihood is that the seizure had a focal onset. The old classification would have classified this seizure as partial onset, secondarily generalized.

3. Absence: A child is diagnosed with Lennox-Gastaut syndrome of unknown etiology. EEG shows runs of slow spike-wave. Seizure types include absence, tonic, and focal motor seizures. The absence seizures are prolonged, have indistinct onset and cessation and sometimes result in falls. In this case, the absence seizures are classified as *atypical absence* due to their characteristics, the EEG pattern and underlying syndrome. The absence seizures would have had the same classification in the old system.

4. Tonic: A child has brief seizures with stiffening of the right arm and leg, during which responsiveness and awareness are retained. This seizure is a *focal aware tonic seizure* (the words “motor onset” can be assumed). In the old system, the seizure would have been called *tonic*, with a perhaps incorrect assumption of generalized onset.

5. Focal impaired awareness: A 25-year-old woman describes seizures beginning with 30 seconds of an intense feeling that “familiar music is playing.” She can hear other people talking, but afterwards realizes that she could not determine what they were saying. After an episode, she

is mildly confused, and has to “reorient herself.” The seizure would be classified as *focal impaired awareness*. Even though the patient is able to interact with her environment, she cannot interpret her environment, and is mildly confused. Prior classification would have been complex partial seizure.

6. Autonomic: A 22-year-old man has seizures during which he remains fully aware, with the “hair on my arms standing on edge” and a feeling of being flushed. These are classified as *focal aware non-motor autonomic seizures*, or more succinctly *focal aware autonomic seizures*. The old classification would have called them simple partial autonomic seizures.

7. Focal clonic: A 1-month year-old boy has rhythmical jerking of the left arm that does not remit when repositioning the arm. Corresponding EEG shows right frontal ictal rhythms. These seizures are *focal motor onset clonic seizures*, or more parsimoniously, *focal clonic seizures*. Since the level of awareness cannot be ascertained, awareness is not involved in classifying this seizure. The old classification would not have had a name for this seizure.

8. Sequential seizure manifestations: A seizure begins with tingling in the right arm of a 75 year-old man. The patient says that it then progresses to rhythmic jerking of the right arm lasting about 30 seconds. He retains awareness and memory for the event. This seizure is a *focal (non-motor onset) sensory seizure*. Additional description would be useful, namely *focal sensory seizure* with somatosensory features progressing to right arm clonic activity. If the sensory and motor events were to be discontinuous or the clinician had reason to consider the event to be two separate (bifocal or multifocal) seizures, then each component would be classified as a separate seizure. The old classification would have called this a *simple partial sensorimotor seizure*. An advantage of the 2017 classification is specification of the sensory onset, which may have clinical importance.

9. Myoclonic-atic: A 4-year-old boy with Doose syndrome has seizures with a few arm jerks and then a rapid drop with loss of tone. These are now classified as *myoclonic atonic seizures*. Prior usage would have called these *myoclonic astatic seizures*.

10. Myoclonic-tonic-clonic seizures: A 13-year-old teenager with juvenile myoclonic epilepsy has seizures beginning with a few jerks, followed by stiffening of all limbs and then rhythmic jerking of all limbs. These would be classified as *myoclonic-tonic-clonic seizures*. No corresponding single seizure type existed in the old classification, but they might have been called myoclonic or clonic seizures followed by tonic-clonic seizures.

11. Focal epileptic spasms: A 14-month-old girl has sudden extension of both arms and flexion of the trunk for about 2 seconds. These seizures repeat in clusters. EEG shows hypsarrhythmia with bilateral spikes, most prominent over the left parietal region. MRI shows a left parietal dysplasia. Resection of the dysplasia terminated the seizures. Because of the ancillary information, the seizure type would be considered to be *focal epileptic spasms* (the term “motor onset” can be assumed). The previous classification would have called them infantile spasms, with information on focality not included. The term “infantile” can still be used when spasms occur in infancy.

12. Unclassified: A 75-year-old man known to have epilepsy reports an internal sense of body trembling and a sense of confusion. No other information is available. EEG and MRI are normal. This event is *unclassified*.

Discussion

This companion to the paper presenting the rationale and structure of the ILAE 2017 seizure classification provides an instructional manual for use of the classification. No amount of explanation can, however, eliminate the inherent ambiguities of a classification in real clinical use. For instance, generalized onset tonic-clonic seizures may be slightly asymmetrical with initial head version. How focal must an asymmetry be to imply a focal onset? The answer lies in individual judgment for each seizure. How uncertain must a clinician be about the nature of the onset to classify a seizure as being of unknown onset? The Task Force set a guideline of “80%” confidence to call a seizure focal or generalized, but this bright line will undoubtedly blur in practice.

Ambiguities arise when a seizure presents multiple signs and symptoms early in the event, for example, tonic arm stiffening and automatisms. The classifier should choose the earliest prominent symptom, but different observers might produce different seizure names depending upon the interpretation of reported or observed symptoms and signs. These ambiguities can be partially ameliorated by knowing the typical patterns of common seizures. A behavior arrest, followed by eye-blinking and head-nodding for five seconds, and then immediate recovery is likely to be a typical absence seizure, even though each individual symptom can occur in multiple seizure types. Appending optional descriptors after the seizure type may better communicate the nature of a seizure, for example, adding “with laughing” to a “focal impaired awareness emotional seizure.”

Several motor signs now appear in conjunction with either focal or generalized onset seizure types, but it cannot be assumed that the pathophysiology is the same for both categories. A focal tonic seizure may have a different mechanism from a generalized tonic seizure, and each seizure type may evidence different prognoses, responses to treatments, demographics and associations with epilepsy syndromes. Even within the focal category, focal tonic activity as part of a focal impaired awareness seizure (recall the common occurrence of twisting movements during complex partial seizures) may be a different entity from focal tonic seizures in a child with the Lennox-Gastaut syndrome. Identifying these new seizure types should facilitate learning more about them and the syndromes with which they are associated.

A learning and adoption curve will develop for those in the epilepsy community who use the 2017 classification. Over time, consensus will emerge regarding which seizure types are best representative of various important groups of symptoms and signs. Past experience forecasts gradual adoption of the new classification, with transient use of terms from multiple prior generations of classifications. Real-world use of the 2017 classification will likely motivate revisions. The desired outcome for the ILAE 2017 classification is greater ease of communication about seizure types among clinicians, the non-medical community and researchers. Future empirical classifications will be developed, until knowledge is sufficient to construct a classification based upon the fundamental reasons that there are different seizure types.

Key Points

- The ILAE provided a revised basic and expanded seizure type classification, with initial division into focal vs. generalized onset or unknown onset seizures.
- Focal seizures are optionally subdivided into focal aware and focal impaired awareness seizures. Specific motor and non-motor classifiers may be added.
- Generalized onset seizures can be motor: tonic-clonic, clonic, tonic, myoclonic, myoclonic-tonic-clonic, myoclonic-atonic, atonic, epileptic spasms.
- Generalized onset seizures can also be non-motor (absence): typical absence, atypical absence, myoclonic absence or absence with eyelid myoclonia.
- Additional descriptors and free text are encouraged to characterize the seizures. Mapping of old to new terms can facilitate adoption of the new terminology.

Attestation

We confirm that we have read the Journal's position on issues involved in ethical publication and affirm that this report is consistent with those guidelines

Acknowledgements

Funding for this study was provided by the International League Against Epilepsy. The lead author (RSF) was supported by the Maslah Saul MD Chair, the James & Carrie Anderson Fund for Epilepsy, the Susan Horngren Fund and the Steve Chen Research Fund.

Disclosures

Disclosures relevant to classification: Dr. Fisher has stock options from Avails Pharmaceuticals, Cerebral Therapeutics, Applied Neurometrics, Zeto, SmartMonitor and research grants from Medtronic and the NSF.

J. A. French discloses support via The Epilepsy Study Consortium, which pays Dr French's university employer for her consultant time related to Acorda, Alexza, Anavex, BioPharm Solutions, Concert, Eisai, Georgia Regents University, GW Pharma, Marathon, Marinus, Neurelis, Novartis, Pfizer, Pfizer-Neusentis, Pronutria, Roivant, Sage, SciFluor, SK Life Sciences, Takeda, Turing, UCB Inc., Ultragenyx, Upsher Smith, Xenon Pharmaceuticals, Zynerva grants and research from Acorda, Alexza, LCGH, Eisai Medical Research, Lundbeck, Pfizer, SK life sciences, UCB, Upsher-Smith, Vertex, grants from NINDS, Epilepsy Therapy Project, Epilepsy Research Foundation, Epilepsy Study Consortium; She is on the editorial board of Lancet Neurology, Neurology Today and Epileptic disorders, and was an Associate Editor of Epilepsia, for which she received a fee.

Sheryl Haut is a consultant for Acorda and Neurelis.

Edouard Hirsch has received honoraria for lectures and/or advice from Novartis, EISAI, and UCB.

Dr. Moshé is the Charles Frost Chair in Neurosurgery and Neurology and funded by grants from NIH NS43209, CURE, US Department of Defense, the Heffer Family and the Segal Family Foundations and the Abbe Goldstein/Joshua Lurie and Laurie Marsh/ Dan Levitz families and receives from Elsevier an annual compensation for his work as Associate Editor in Neurobiology of Disease and royalties from 2 books he co-edited. He received a consultant's fee from Lundbeck, Eisai and UCB.

Jukka Peltola has participated in clinical trials for Eisai, UCB, and Bial; received research grants from Eisai, Medtronic, UCB, and Cyberonics; received speaker honoraria from Cyberonics, Eisai, Medtronic, Orion Pharma, and UCB; received support for travel to congresses from Cyberonics, Eisai, Medtronic, and UCB; and participated in advisory boards for Cyberonics, Eisai, Medtronic, UCB, and Pfizer.

Dr Scheffer serves on the editorial boards of *Neurology* and *Epileptic Disorders*; may accrue future revenue on pending patent WO61/010176 (filed: 2008): Therapeutic Compound; has received speaker honoraria/consultant fees from GlaxoSmithKline, Athena Diagnostics, UCB, Eisai and Transgenomics. Dr Zuberi is Editor-in-Chief of the European Journal of Paediatric Neurology for which he receives an annual honorarium from Elsevier Ltd. He has received research funding from Dravet Syndrome UK, Epilepsy Research UK, UCB Pharma and Glasgow Childrens' Hospital Charity. The remaining authors listed no disclosures relevant to the classification of seizure types.

Carol D'Souza has nothing to disclose.

Andreas Schulze-Bonhage has received honoraria for lectures and advice from Cyberonics, Desitin, EISAI, Precisis, and UCB.

Ernest Somerville has nothing to disclose

M. Sperling contracts with Thomas Jefferson University to Eisai, UCB Pharma, Sunovion, SK Life Sciences, Marinus, Lundbeck, Medtronics, Visualase, Accorda, Upsher-Smith, Brain Sentinel, and Glaxo; research support from DARPA and NIH through Thomas Jefferson University; consulting: contract with Thomas Jefferson University to Medtronics.

E M Yacubian has nothing to disclose

FIGURE LEGENDS

Figure 1: The Basic ILAE 2017 Operational Classification of Seizure Types

Figure 2: The Expanded ILAE 2017 Operational Classification of Seizure Types. The following clarifications should guide the choice of seizure type. For focal seizures, specification of level of awareness is optional. Retained awareness means the person is aware of self and environment during the seizure, even if immobile. A focal aware seizure corresponds to the prior term simple partial seizure. A focal impaired awareness seizure corresponds to the prior term complex partial seizure, and impaired awareness during any part of the seizure renders it a focal impaired awareness seizure. Focal aware or impaired awareness seizures optionally may further be characterized by one of the motor-onset or non-motor onset symptoms below, reflecting the first prominent sign or symptom in the seizure. Seizures should be classified by the earliest prominent feature, except that a focal behavior arrest seizure is one for which cessation of activity is the dominant feature throughout the seizure. A focal seizure name also can omit mention of awareness when awareness is not applicable or unknown and thereby classify the seizure directly by motor onset or non-motor onset characteristics. Atonic seizures and epileptic spasms would usually not have specified awareness. Cognitive seizures imply impaired language or other cognitive domains or positive features such as déjà vu, hallucinations, illusions or perceptual distortions. Emotional seizures involve anxiety, fear, joy, other emotions or appearance of affect without subjective emotions. An absence is atypical because of slow onset or termination or significant changes in tone supported by atypical, slow, generalized spike and wave on the EEG. A seizure may be unclassified due to inadequate information or inability to place the type in other categories.

TABLE LEGENDS

Table 1: Common descriptors of behaviors during and after seizures (alphabetically)

Table 2: Glossary of Terms

Table 3: Mapping of old to new seizure classifying terms. Note that there is not a one-to-one correspondence, reflecting reorganization as well as renaming.

Table 4: Abbreviations for the most important seizure types

References

1. Proposal for revised clinical and electroencephalographic classification of epileptic seizures. From the Commission on Classification and Terminology of the International League Against Epilepsy. *Epilepsia* 1981;22:489-501.
2. Acharya JN, Wyllie E, Luders HO, et al. Seizure symptomatology in infants with localization-related epilepsy. *Neurology* 1997;48:189-196.
3. Fisher RS, Acevedo C, Arzimanoglou A, et al. A practical clinical definition of epilepsy. *Epilepsia* 2014;in press.
4. Fisher RS, Boas WV, Blume W, et al. Epileptic seizures and epilepsy: Definitions proposed by the International League against Epilepsy (ILAE) and the International Bureau for Epilepsy (IBE). *Epilepsia* 2005;46:470-472.
5. Berg AT, Millichap JJ. The 2010 revised classification of seizures and epilepsy. *Continuum (Minneapolis)* 2013;19:571-597.
6. Felician O, Tramon E, Bartolomei F. Transient epileptic amnesia: Update on a slowly emerging epileptic syndrome. *Rev Neurol (Paris)* 2015;171:289-297.
7. Luat AF, Kamat D, Sivaswamy L. Paroxysmal nonepileptic events in infancy, childhood, and adolescence. *Pediatr Ann* 2015;44:e18-23.
8. Wolf P, Yacubian EM, Avanzini G, et al. Juvenile myoclonic epilepsy: A system disorder of the brain. *Epilepsy Res* 2015;114:2-12.
9. Kelley SA, Kossoff EH. Doose syndrome (myoclonic-astatic epilepsy): 40 years of progress. *Dev Med Child Neurol* 2010;52:988-993.
10. Elia M, Guerrini R, Musumeci SA, et al. Myoclonic absence-like seizures and chromosome abnormality syndromes. *Epilepsia* 1998;39:660-663.

11. Striano S, Capovilla G, Sofia V, et al. Eyelid myoclonia with absences (Jeavons syndrome): a well-defined idiopathic generalized epilepsy syndrome or a spectrum of photosensitive conditions? *Epilepsia* 2009;50 Suppl 5:15-19.
12. Blume WT, Luders HO, Mizrahi E, et al. Glossary of descriptive terminology for ictal semiology: report of the ILAE task force on classification and terminology. *Epilepsia* 2001;42:1212-1218.

Author Manuscript

WORD	DEFINITION	SOURCE
absence, typical	a sudden onset, interruption of ongoing activities, a blank stare, possibly a brief up-ward deviation of the eyes. Usually the patient will be unresponsive when spoken to. Duration is a few seconds to half a minute with very rapid recovery. Although not always available, an EEG would show generalized epileptiform discharges during the event. An absence seizure is by definition a seizure of generalized onset. The word is not synonymous with a blank stare, which also can be encountered with focal onset seizures.	Adapted from ¹²
absence, atypical	an absence seizure with changes in tone that are more pronounced than in typical absence or the onset and/or cessation is not abrupt, often associated with slow, irregular, generalized spike-wave activity	Adapted from Dreifuss ¹
arrest	see behavior arrest	new
atonic	sudden loss or diminution of muscle tone without apparent preceding myoclonic or tonic event lasting ~1 to 2 s, involving head, trunk, jaw, or limb musculature.	¹²
automatism	a more or less coordinated motor activity usually occurring when cognition is impaired and for which the subject is usually (but not always) amnesic afterward. This often resembles a voluntary movement and may consist of an inappropriate continuation of preictal motor activity.	¹²
autonomic seizure	a distinct alteration of autonomic nervous system function involving cardiovascular, pupillary, gastrointestinal, sudomotor, vasomotor, and thermoregulatory functions.	Adapted from ¹²
aura	a subjective ictal phenomenon that, in a given patient, may precede an observable seizure (popular usage)	¹²
awareness	knowledge of self or environment	new
bilateral	both left and right sides, although manifestations of bilateral seizures may be symmetric or asymmetric	new

clonic	jerking, either symmetric or asymmetric, that is regularly repetitive and involves the same muscle groups	Adapted from ¹²
cognitive	pertaining to thinking and higher cortical functions, such as language, spatial perception, memory, praxis. The previous term for similar usage as a seizure type was psychic.	new
consciousness	a state of mind with both subjective and objective aspects, comprising a sense of self as a unique entity, awareness, responsiveness and memory	new
dacrystic	bursts of crying, which may or may not be associated with sadness	¹²
dystonic	sustained contractions of both agonist and antagonist muscles producing athetoid or twisting movements, which may produce abnormal postures.	Adapted from ¹²
emotional seizures	seizures presenting with an emotion or the appearance of having an emotion as an early prominent feature, such as fear, spontaneous joy or euphoria, laughing (gelastic) or crying (dacrystic)	new
epileptic spasms	a sudden flexion, extension, or mixed extension–flexion of predominantly proximal and truncal muscles that is usually more sustained than a myoclonic movement but not as sustained as a tonic seizure. Limited forms may occur: grimacing, head nodding or subtle eye movements. Epileptic spasms frequently occur in clusters. Infantile spasms are the best known form, but spasms can occur at all ages.	Adapted from ¹²
epilepsy	a disease of the brain defined by any of the following conditions 1. At least two unprovoked (or reflex) seizures occurring >24 h apart; 2. One unprovoked (or reflex) seizure and a probability of further seizures similar to the general recurrence risk (at least 60%) after two unprovoked seizures, occurring over the next 10 years; 3. Diagnosis of an epilepsy syndrome. Epilepsy is considered to be resolved for individuals who had an age-dependent epilepsy syndrome but are now past the applicable age or those who have remained seizure-free for the last 10 years, with no anti-seizure medicines for the last 5 years.	³
eyelid myoclonia	jerking of the eyelids at frequencies at least 3 per second, commonly with upward eye deviation, usually lasting less than 10 seconds, often	new

	precipitated by eye closure. There may or may not be associated brief loss of awareness.	
fencer's posture seizure	a focal motor seizure type with extension of one arm and flexion at the contralateral elbow and wrist, giving an imitation of swordplay with a foil. This has also been called a supplementary motor seizure.	new
figure-of-4 seizure	see fencer's posture seizure	new
focal	originating within networks limited to one hemisphere. They may be discretely localized or more widely distributed. Focal seizures may originate in subcortical structures.	⁵
focal onset bilateral tonic-clonic seizure	a seizure type with focal onset, with awareness or impaired awareness, either motor or non-motor, progressing to bilateral tonic-clonic activity. The prior term was seizure with partial onset with secondary generalization.	new
gelastic	bursts of laughter or giggling, usually without an appropriate affective tone.	¹²
generalized	originating at some point within, and rapidly engaging, bilaterally distributed networks	⁵
generalized tonic-clonic	bilateral symmetric or sometimes asymmetric tonic contraction and then bilateral clonic contraction of somatic muscles, usually associated with autonomic phenomena and loss of awareness. These seizures engage networks in both hemispheres at the start of the seizure.	Adapted from ⁵ , ¹²
hallucination	a creation of composite perceptions without corresponding external stimuli involving visual, auditory, somatosensory, olfactory, and/or gustatory phenomena. Example: "hearing" and "seeing" people talking.	¹²
behavior arrest	arrest (pause) of activities, freezing, immobilization, as in behavior arrest seizure	new
immobility	see activity arrest	new
impaired awareness	see awareness. Impaired or lost awareness is a feature of focal impaired awareness seizures, previously called complex partial	new

	seizures.	
impairment of consciousness	see impaired awareness	new
Jacksonian seizure	traditional term indicating spread of clonic movements through contiguous body parts unilaterally.	¹²
motor	involves musculature in any form. The motor event could consist of an increase (positive) or decrease (negative) in muscle contraction to produce a movement.	¹²
myoclonic	sudden, brief (<100 ms) involuntary single or multiple contraction(s) of muscles(s) or muscle groups of variable topography (axial, proximal limb, distal). Myoclonus is less regularly repetitive and less sustained than is clonus.	Adapted from ¹²
myoclonic-atonic	a generalized seizure type with a myoclonic jerk leading to an atonic motor component. This type was previously called myoclonic-astatic.	new
myoclonic-tonic-clonic	one or a few jerks of limbs bilaterally, followed by a tonic-clonic seizure. The initial jerks can be considered to be either a brief period of clonus or myoclonus. Seizures with this characteristic are common in juvenile myoclonic epilepsy	Derived from ¹
non-motor	focal or generalized seizure types in which motor activity is not prominent.	new
propagation	spread of seizure activity from one place in the brain to another or engaging of additional brain networks	new
responsiveness	ability to appropriately react by movement or speech when presented with a stimulus	new
seizure	a transient occurrence of signs and/or symptoms due to abnormal excessive or synchronous neuronal activity in the brain.	⁴
sensory seizure	a perceptual experience not caused by appropriate stimuli in the external world.	¹²
spasm	see epileptic spasm	
tonic	a sustained increase in muscle contraction lasting a few seconds to minutes.	¹²
tonic-clonic	a sequence consisting of a tonic followed by a clonic phase.	¹²

unaware	The term unaware can be used as shorthand for impaired awareness.	new
unclassified	referring to a seizure type that cannot be described by the ILAE 2017 classification either because of inadequate information or unusual clinical features. If the seizure is unclassified because the type of onset is unknown, a limited classification may still derive from observed features.	new
unresponsive	not able to react appropriately by movement or speech when presented with stimulation	new
versive	a sustained, forced conjugate ocular, cephalic, and/or truncal rotation or lateral deviation from the midline.	¹²

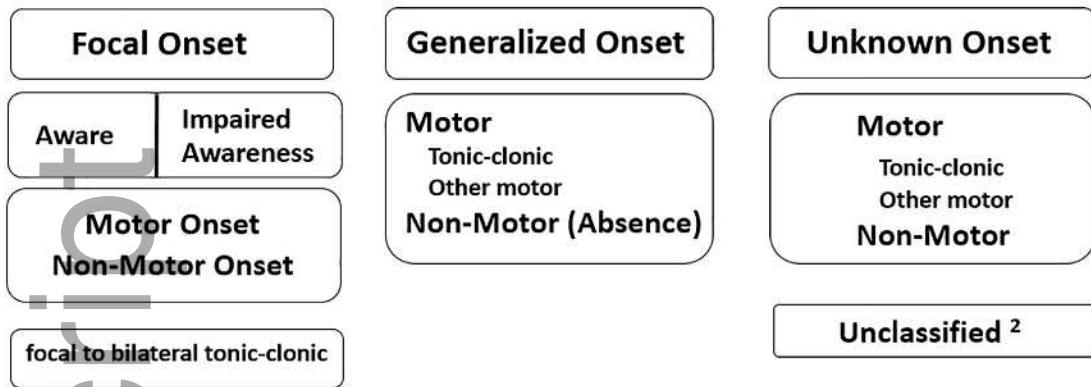
Old Term for SeizureNew Term for Seizure [choice] (optional)**The most important are in bold**

absence	(generalized) absence
absence, atypical	(generalized) absence, atypical
absence, typical	(generalized) absence, typical
akinetiC	focal behavior arrest, generalized absence
astatic	[focal/generalized] atonic
atonic	[focal/ generalized] atonic
aura	focal aware
clonic	[focal/generalized] clonic
complex partial	focal impaired awareness
convulsion	[focal/generalized] motor [tonic-clonic, tonic, clonic], focal to bilateral tonic-clonic
dacrystic	focal [aware or impaired awareness] emotional (dacrystic)
dialectic	focal impaired awareness
drop attack	[focal/generalized] atonic, [focal/generalized] tonic
fencer's posture (asymmetric tonic)	focal [aware or impaired awareness] motor tonic
figure-of-4	focal [aware or impaired awareness] motor tonic
freeze	focal [aware or impaired awareness] behavior arrest
frontal lobe *	focal
gelastic	focal [aware or impaired awareness] emotional (gelastic)
grand mal	generalized tonic-clonic, focal to bilateral tonic-clonic, unknown onset tonic-clonic
gustatory	focal [aware or impaired awareness] sensory (gustatory)
infantile spasms	[focal/generalized/unknown] onset epileptic spasms
Jacksonian	focal aware motor (Jacksonian)
limbic	focal impaired awareness
major motor	generalized tonic-clonic, focal onset bilateral tonic-clonic
minor motor	focal motor, generalized myoclonic
myoclonic	[focal/generalized] myoclonic
neocortical *	focal aware or focal impaired awareness
occipital lobe *	focal
parietal lobe *	focal
partial	focal
petit mal	absence
psychomotor	focal impaired awareness
Rolandic	focal aware motor, focal to bilateral tonic-clonic
salaam	[focal/generalized/unknown onset] epileptic spasms
secondarily generalized tonic-clonic ..	focal to bilateral tonic-clonic
simple partial	focal aware
supplementary motor	focal motor tonic
Sylvian	focal motor
temporal lobe *	focal aware / impaired awareness
tonic	[focal/generalized] tonic
tonic-clonic	[generalized/unknown] onset tonic-clonic, focal to bilateral tonic-clonic
uncinate	focal [aware impaired awareness] sensory (olfactory)

* Anatomical classification may still be useful for some purposes, for example in evaluation for epilepsy surgery.

SEIZURE TYPE	ABRREVIATION
focal aware seizure	FAS
focal impaired awareness seizure	FIAS
Focal motor seizure	FMS
Focal non-motor seizure	FNMS
focal epileptic spasm	FES
focal to bilateral tonic-clonic seizure	FBTCS
generalized tonic-clonic seizure	GTCS
generalized absence seizure	GAS
generalized motor seizure	GMS
generalized epileptic spasm	GES
Unknown onset tonic-clonic seizure	UTCS

ILAE 2017 Classification of Seizure Types Basic Version ¹

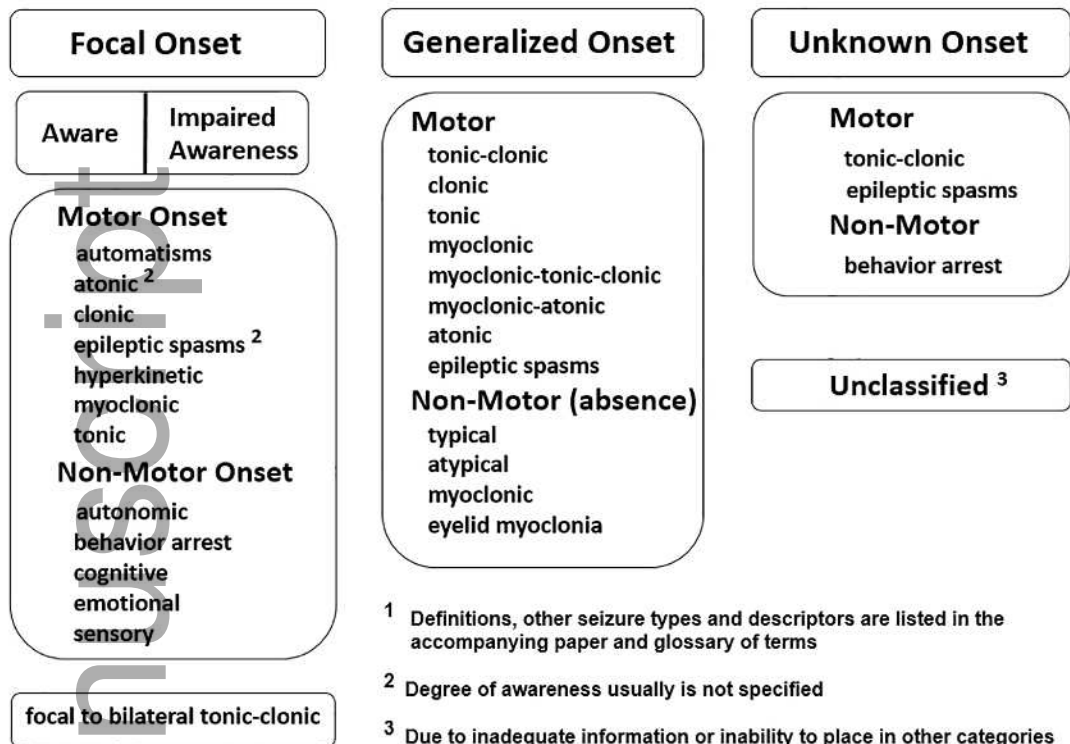


¹ Definitions, other seizure types and descriptors are listed in the accompanying paper & glossary of terms

² Due to inadequate information or inability to place in other categories

epi_13671_f1.tif

ILAE 2017 Classification of Seizure Types Expanded Version ¹



¹ Definitions, other seizure types and descriptors are listed in the accompanying paper and glossary of terms

² Degree of awareness usually is not specified

³ Due to inadequate information or inability to place in other categories

epi_13671_f2.tif