

Article type : Original Article

**Simultaneous pelvic exenteration and liver resection for primary rectal cancer with synchronous liver metastases: Results from the *PelvEx Collaborative***

***PelvEx Collaborative***

**Corresponding Authors:**

Michael E. Kelly

Centre of Colorectal Disease

St Vincent's University Hospital

Elm Park

Dublin 4, Ireland

+353 1 221 4000

School of Medicine, University College Dublin, Ireland

[Kellym11@tcd.ie](mailto:Kellym11@tcd.ie)

[@PelvExGroup](#)

**Keywords:**

Rectal Cancer

Liver metastasis

Survival Outcomes

Surgical Outcomes

International Collaboration

This is the author manuscript accepted for publication and has undergone full peer review but has not been through the copyediting, typesetting, pagination and proofreading process, which may lead to differences between this version and the [Version of Record](#). Please cite this article as [doi: 10.1111/CODI.15064](https://doi.org/10.1111/CODI.15064)

This article is protected by copyright. All rights reserved

**Word Count: 1,787**

**All authors declare no conflict of interest**

**All co-authors have seen and approved this submission**

**Figures and Tables to be printed in black & white**

**No funding disclosure relevant**

## **Abstract**

**Background:** 15-20% of patients with rectal cancer have synchronous liver metastases at presentation. There is limited evidence about the outcome for those with advanced rectal cancer who undergo pelvic exenteration and simultaneous liver resection.

**Methods:** Data from twenty international institutions that performed simultaneous pelvic exenteration and liver resection between 2007-2017 were accumulated. Primarily, we examined perioperative outcomes, morbidity and mortality. We also assessed the impact that margin status had on survival.

**Results:** Of 128 patients, 72(56.2%) were male with a median age of 60(IQR15) years. The median size of the liver oligo-metastatic deposits was 2cm (IQR1.8). Median(range) duration of surgery was 406(IQR 240) minutes, with a median blood loss of 1090 mls(IQR 2010 mls). A negative resection margin (R0 resection) was achieved in 73.5% of pelvic exenterations and 66.4% of liver resections. The 30-day mortality rate was 1.6%, and 32% of patients had a major post-operative complication. The five-year overall survival for patients in whom an R0 resection of both primary and metastatic disease was achieved was 54.6% compared with 20% for those with an R1/R2 resection( $p=0.006$ ).

**Conclusion:** Simultaneous pelvic exenteration and liver resection is feasible, with acceptable morbidity and mortality. Simultaneous resection should only be performed where an R0 resection of both pelvic and hepatic disease is anticipated.

**What do this paper add to the literature:**

This is the first publication to show that in selected patients with oligometastatic disease, pelvic exenteration with simultaneous liver resection is feasible with acceptable morbidity and mortality, and good long-term outcomes in those having clear margins of both primary and metastatic disease.

## Introduction

At the time of primary rectal cancer diagnosis, 15-20% of patients will have metastatic disease [1-2]. Additionally, 25% develop metastases during the course of their treatment [3-4]. In recent years, the management of synchronous colorectal liver metastases has evolved. In patients with metastatic rectal cancer involving the liver, long-term survival is possible when a multi-modality treatment strategy is employed [5-9].

Conventionally, surgical resection in patients with locally advanced or locally recurrent rectal cancer had been confined to patients without metastatic disease outside the pelvis [10]. However, patients with liver oligometastases (i.e. metastases in a limited number of sites) increasingly are being considered for a staged resection (approximately 1 in 4), with reported five-year survival rates of 30-50% in limited series [5-8].

Conversely, simultaneous resection when technically feasible (low-volume, favourable disease) and in patients with good performance status, has been reported sporadically [11]. The potential benefits of performing a combined resection include a single anaesthetic and operation and overall reduction in total length of stay in hospital [11-12]. However, this approach increases the complexity of the surgical procedure and duration of surgery, raising concerns about the perioperative safety and oncological outcomes [13].

The aim of this study was to determine the surgical and survival outcomes in patients with advanced rectal cancer who underwent combined pelvic exenteration and liver

(oligometastatic) resection. We hypothesized that simultaneous liver and primary resection in patients with oligometastatic disease could be performed with an acceptable safety profile and high-quality oncological outcomes for those patients with an R0 resection.

## **Methods:**

A retrospective international observational cohort study was performed to assess the outcomes of patients who underwent simultaneous pelvic exenteration and liver resection for oligometastatic disease over a 10-year period (from 2007-2017). Twenty international institutions provided data, each centre a recognized referral unit with specialist expertise (surgical oncologist, colorectal and/or hepatobiliary surgeon). All patients had been discussed at a dedicated multi-disciplinary meeting. A principal investigator from each participating centre submitted centrally anonymized data for analysis. Ethical approval was sought at an individual institutional level.

The diagnosis of locally advanced (primary) rectal cancer was based on histological assessment and radiological imaging. An agreed data set was pre-determined and completed by all participating institutions. Data were audited centrally by two reviewers (MK, DW). Any discrepancies were highlighted and reviewed by the relevant submitting institution for clarification.

Basic patient demographics (age, gender, body mass index), location of primary tumour, details of oligometastatic disease, type of pelvic exenteration and liver resection were documented. Histopathological assessment including resection margin (R-status), length of hospital stay, 30-day readmission rate, 30-day major complication rate (grade 3 or 4 Clavien- Dindo) and 30-day mortality rate were recorded as were data on recurrence and survival.

## *Definitions*

Total pelvic exenteration was defined as an *en bloc* resection of the rectum, genitourinary and reproductive internal organs, regional lymph nodes and associated peritoneum. Posterior pelvic exenteration was defined as resection of the rectum with removal of the internal reproductive organs, with preservation of the bladder [18]. Extended pelvic exenteration included any total or posterior exenteration that required bone or lateral pelvic side wall extended resection. Histopathological evaluation considered an R0 resection as a resection margin (CRM) of  $>1\text{mm}$ . R1 resection was the presence of microscopic residual disease defined as  $\text{CRM} \leq 1\text{mm}$ , while R2 resection indicated the presence of macroscopic residual disease [19].

### *Endpoints*

The primary endpoint was overall survival (OS). Secondary endpoints included the post-operative length of stay, complication (morbidity) rates, and 30-day mortality.

### *Statistical analysis*

Data were analyzed using Statistical Package for the Social Sciences (SPSS) (Version 22, IBM, USA). Descriptive analysis was undertaken to report variable frequencies. Survival was estimated by the Kaplan-Meier method. The duration of survival for each case was defined as the time from the month of surgery to either the month of death or to 31<sup>st</sup> December 2017.

## Results:

128 patients with advanced primary rectal cancer with synchronous liver metastases underwent simultaneous pelvic exenteration and liver resection over the 10-year period. Men were more common (n=72, 56.2%) and the median age of the patient was 60 years (IQR 15). Median (range) body mass index for the study cohort was 25.1 (IQR 6.4) The median American Society of Anesthesiologists (ASA) score was 2.

### *Operative Details and Histopathological Outcomes*

Posterior pelvic exenteration and total pelvic exenteration were the two most common procedures, accounting for 79% (n=101) of operative procedures for the primary rectal neoplasm. The remaining 21% (n=27) had an extended pelvic exenteration. Seventy-eight patients underwent a non-anatomical liver resection, forty had a segmental resection, six underwent hepatic lobectomy and four had a left lateral resection.

The median size of the oligometastatic deposits was 2cm (IQR 1.8cm) and the median number of liver metastases excised was 1 (1-6). The median duration of surgery for the cohort was 406 minutes (IQR 240). The median blood loss was 1090mls (IQR 2010) with a median blood transfusion requirement of 2 units (IQR 3).

An R0 resection was achieved in 94 patients (73.5%) undergoing pelvic exenteration, 32 patients (25%) had a R1 resection, and 2 patients (1.5%) had an R2 resection. R0 resection of the hepatic disease was achieved in 85 patients (66.4%), 19 patients (14.8%) had an R1 resection and 4 patients (3.1%) had an R2 resection. Oligometastatic margin status was unavailable in 20 patients (15.7%). These patients were excluded from survival analysis.

### *Surgical and Survival Outcomes*

The median post-operative length of hospital stay was 12 days (IQR 10). The 30-day mortality rate was 1.6% (2 patients). Forty-one (32%) patients had a major complication (Clavien-Dindo  $\geq 3$ ) within the first 30-days, the most common morbidity being a post-operative fluid collection of whom 24 patients (18.7%) required surgical re-intervention and 17 patients (13.3%) needed radiological intervention. Eighteen patients (14.1%) were re-admitted to hospital within 30-days of surgery.

During the follow-up period, 39 recurrences occurred (30.5%) of whom 27 (21.1%) had recurrent liver disease and 12 (9.3%) a local (pelvic) recurrence. Eight patients (6.2%) developed pulmonary metastatic disease.

At a median follow-up of 27 months (IQR 37.5), 50 patients (39.1%) had died due to disease progression and nine patients died (7%) due to other causes. The 5-year overall survival was 44%. The 5-year overall survival for patients in whom an R0 resection of both primary and metastatic disease was achieved was 54.6% compared with 20% for those with an R1/R2 resection ( $p=0.006$ ).



## Discussion:

This is the first publication to show that in selected patients with oligometastatic disease, pelvic exenteration with simultaneous liver resection is feasible with acceptable morbidity and mortality [14-15]. In those patients in whom an R0 resection was achieved at both sites there was a 5-year overall survival of 54.6%.

The concept of simultaneous rectal and liver resection was first reported in the early 1990's [16]. Over the last two decades a growing body of literature has shown that simultaneous resection is both feasible and safe, [11, 17-18] and is associated with a reduction in overall length of hospital stay and healthcare costs [17, 19]. Advances in operative and reconstructive techniques, combined with better pre-rehabilitation, perioperative care and centralization of services have facilitated radical surgical interventions such as combined pelvic exenteration and liver resection.

The most challenging factor in patients with locally advanced rectal cancer and simultaneous liver metastases is selection for surgical resection. The majority of patients receive induction chemotherapy (with or without a diversion stoma or stenting if symptomatic) [20-21] to down-stage potentially non-resectable tumours, increase R0 rates [9, 22] and identify those with adverse tumour biology whose

disease may progress during induction therapy. The present study clearly demonstrates the importance of achieving R0 resection margins at both pelvic and hepatic resection sites, as the 5-year overall survival rate was only 20% following an R1/2 resection.

The development of specialist multidisciplinary team meetings is vital, as it is difficult to adopt a “one size fits all” strategy in this complex group of patients, and subtle differences in patient presentations add to treatment conundrums [23]. Factors such as future liver remnant volume (and functional capacity), borderline resectability and the patient’s expectations must all be considered and individualized [24-25]. It is notable from this series that only 6 of 128 (4.6%) patients had a formal hepatic lobectomy, and median number of oligometastatic deposits was one, highlighting the selectiveness of this series.

We are conscious that this study focuses on a very select cohort of patients with favorable disease, from which it is not possible to ascertain individual indications for resection or account for heterogeneity in surgical approaches and chemo(radio)therapy regimens. Also, the overall denominator of patients considered for resection is not available. Although overall rates of morbidity and reintervention were at acceptable levels, quality of life data are not available for this cohort.

However, the study does reflect multicentre real-world outcomes of simultaneous pelvic exenteration and liver resection, and confirms that perioperative morbidity, re-intervention and mortality outcomes are broadly similar to those in whom pelvic exenteration alone is performed for locally advanced or recurrent rectal cancer [14-15].

## **Conclusion:**

Pelvic exenteration with liver resection is possible in a highly selected group of patients with a limited number of liver metastases and in whom an R0 resection of both sites is anticipated.

# Author Manuscript

## References:

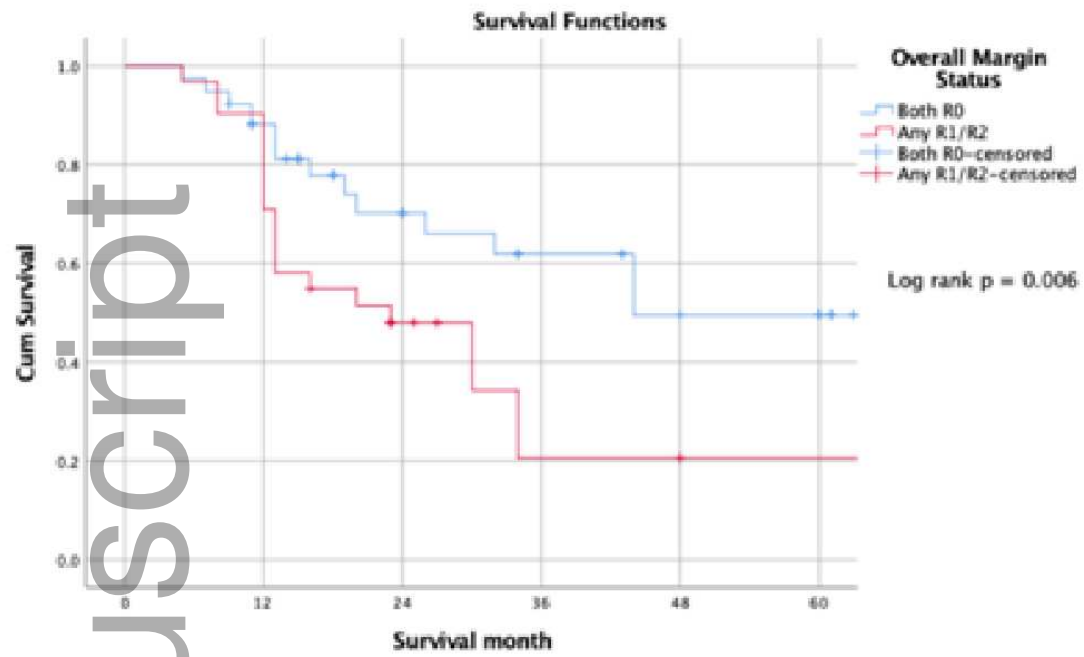
1. McMillan DC, McArdle CS. Epidemiology of colorectal liver metastases. Surg Oncol. 2007;16:3-5

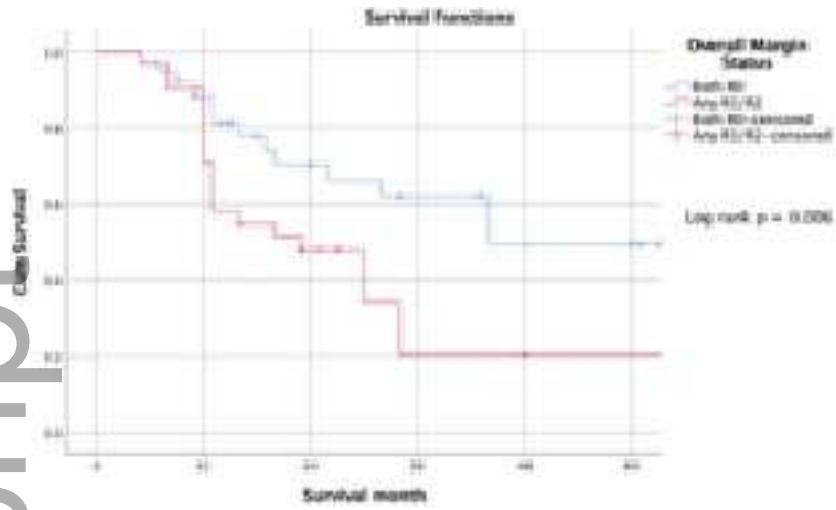
2. Van Cutsem E, Nordlinger B, Adam R, Kohne CH, Pozzo C, Poston G, Ychou M, Rougier P et al. Towards a pan-European consensus on the treatment of patients with colorectal liver metastases. *Eur J Cancer*. 2006;42:2212-2221
3. Boyle P, Ferlay J. Cancer incidence and mortality in Europe 2004. *Ann Oncol*. 2005;16(3):481-488
4. Haddad AJ, Hani MB, Pawlik TM, Cunningham SC. Colorectal liver metastases. *Int J Surg Oncol*. 2011;2011:285840. doi: 10.1155/2011/285840. Epub 2011 Jun 6
5. deJong MC, Pulitano C, Ribero D, Strub J, Mentha G, Schulick RD, Choti MA, Aldrighetti L, Capussotti L, Pawlik TM. Rates and patterns of recurrence following curative intent surgery for colorectal liver metastasis: an international multi-institutional analysis of 1669 patients. *Ann Surg*. 2009;250(3):440-448
6. Abdalla EK, Vauthey JN, Ellis LM, Ellis V, Pollock R, Broglio KR, Hess K, Curley SA. Recurrence and outcomes following hepatic resection, radiofrequency ablation and combined resection/ablation for colorectal liver metastasis. *Ann Surg*. 2004;239(6):818-825
7. Mavros MN, de Jong M, Dogeas E, Hyder O, Pawlik TM. Impact of complications on long-term survival after resection of colorectal liver metastases. *Br J Surg*. 2013;100(5):711-718
8. Simmonds PC, Primrose JN, Colquitt JL et al. Surgical resection of hepatic metastases from colorectal cancer: a systematic review of published studies. *Br J Cancer*. 2006;94:982-999
9. Pawlik TM, Choti MA. Surgical therapy for colorectal metastases to the liver. *J Gastrointest Surg*. 2007;11:1057-1077
10. Nielsen M, Rasmussen P, Lindegaard J, Laurberg S. A 10-year experience of total pelvic exenteration for primary advanced and locally recurrent rectal cancer based on a prospective database. *Colorectal Dis*. 2012;14:1076-1083

11. Kelly ME, Spolverato G, Le GN, Mavros MN, Doyle F, Pawlik TM, Winter DC. Synchronous colorectal liver metastasis: a network meta-analysis review comparing classical, combined and liver-first strategies. *J Surg Oncol* 2015;111(3):341-351
12. Lam VW, Laurence JM, Pang T, Johnston E, Hollands MJ, Pleass HCC, Richardson AJ. A systematic review of a liver-first approach in patients with colorectal cancer and synchronous colorectal liver metastases. *HPB*. 2014;16(2):101-108.
13. Ono Y, Saiura A, Arita J, Takahashi Y, Takahashi M, Inoue Y. Short-Term Outcomes after simultaneous colorectal and major hepatic resection for synchronous colorectal liver metastases. *Dig Surg*. 2017;34(6):447-454.
14. PelvEx Collaborative. Surgical and survival outcomes following pelvic exenteration for locally advanced primary rectal cancer: Results from an international collaboration. *Ann Surg*. 2019;269(2):315-32
15. PelvEx Collaborative. Factors affecting outcomes following pelvic exenteration for locally recurrent rectal cancer. *Br J Surg*. 2018;105(6):650-657.
16. Vogt P, Raab R, Ringe B, Pichlmayr R. Resection of synchronous liver metastases from colorectal cancer. *World J Surg*. 1991;15:62-67
17. Mayo SC, Pulitano C, Marques H, Lamelas J, Wolfgang CL, de Saussure et al. Surgical management of patient with synchronous colorectal liver metastasis: a multicenter international analysis. *J Am Coll Surg*. 2013;216:707-716
18. Silberhumer GR, Paty PB, Temple LK, Araujo RL, Denton B, Gonen M et al. Simultaneous resection for rectal cancer with synchronous liver metastasis is a safe procedure. *Am J Surg*. 2015;209:935-942
19. Muangkaew P, Cho JY, Han HS, Yoon YS, Choi Y, Jang JY et al. Outcomes of simultaneous major liver resection and colorectal surgery for colorectal liver metastases. *J Gastrointest Surg*. 2016;20:554-563
20. Tsoulfas G, Pramateftakis MG.

21. Cho H, Kim JE, Kim KP, Yu CS, Kim JC, Kim JH et al, Phase II Study of preoperative Capecitabine and Oxaliplatin-based intensified chemoradiotherapy with or without induction chemotherapy in patients with locally advanced rectal cancer and synchronous liver-limited resectable metastases. *Am J Clin Oncol*. 2016 Dec;39(6):623-629.
22. Simmonds PC, Primrose JN, Colquitt JL et al. Surgical resection of hepatic metastases from colorectal cancer: a systematic review of published studies. *Br J Cancer*. 2006;94:982-999
23. Pathak S, Nunes QM, Daniels IR, Smart NJ, Poston GJ, Pahlman L. Rectal cancer with synchronous liver metastases: Do we have a clear direction? *EJSO*. 2015; 41(12):1570-7.
24. Azoulay D, Castaing D, Krissat J, Smail A, Hargreaves GM, Lemoine A, Emile JF, Bismuth H. Percutaneous portal vein embolization increases the feasibility and safety of major liver resection for hepatocellular carcinoma in injured liver. *Ann Surg*. 2000 Nov;232(5):665-72.
25. Lutz MP, Zalcborg JR, Glynne-Jones R, Ruers T, Ducreux M, Arnold D, Aust D, Brown G, et al. Second St. Gallen European Organisation for Research and Treatment of Cancer Gastrointestinal Cancer Conference: consensus recommendations on controversial issues in the primary treatment of rectal cancer. *Eur J Cancer*. 2016 Aug;63:11-24.

Figure 1





codi\_15064\_f1.tiff