

# Accuracy of Point of Care Intestinal Ultrasound for Crohn's Disease

Running title: Intestinal Ultrasound for Crohn's Disease

Emily K Wright<sup>1,2</sup> PhD

Gastroenterologist

Ian Wang<sup>1</sup>, MD

Medical Registrar

Darren Wong<sup>1,2</sup> MD

Gastroenterologist

Sally J Bell<sup>1</sup> MD

Professor of Gastroenterology

William R Connell<sup>1</sup> MD

Associate Professor of Gastroenterology

Alexander J Thompson<sup>1,2</sup> PhD

Professor of Gastroenterology

Kerri L Novak<sup>3</sup> MD

Associate Professor of Gastroenterology

Michael A Kamm<sup>1,2</sup> PhD

Professor of Gastroenterology

<sup>1</sup> Department of Gastroenterology, St Vincent's Hospital, Melbourne, Australia.

<sup>2</sup> The University of Melbourne, Melbourne, Australia.

<sup>3</sup> Division of Gastroenterology, University of Calgary, Calgary, Alberta, Canada

This is the author manuscript accepted for publication and has undergone full peer review but has not been through the copyediting, typesetting, pagination and proofreading process, which may lead to differences between this version and the [Version of Record](#). Please cite this article as [doi: 10.1002/AJUM.12218](https://doi.org/10.1002/AJUM.12218)

This article is protected by copyright. All rights reserved

**AUTHOR CONTRIBUTIONS AND DECLARATION:** EKW and IW study concept and design; acquisition of data; analysis; data interpretation; drafting of the manuscript; critical revision of the manuscript for important intellectual content; statistical analysis; obtained funding. DW –statistical analysis. MAK, SJB, WRC, AT, KLN – acquisition of data and critical review of manuscript.

The authorship listing of this manuscript conforms with the authorship policy. All authors have agreed to the content of this submitted manuscript.

**ACKNOWLEDGEMENTS:** We wish to acknowledge AbbVie who provided the ultrasound equipment used for this study as part of an educational grant. No other specific funding for this project was received.

**DISCLOSURES:** EK Wright has received research support from AbbVie and Ferring and has acted as a speaker at symposiums sponsored by AbbVie, Janssen and Pfizer; I Wang, D Wong, WR Connell and AJ Thompson have no disclosures; SJ Bell has received speakers fees from AbbVie, Janssen and Shire; KL Novak has received research support from AbbVie, acted as speaker for AbbVie, Janssen and Pfizer; MA Kamm has acted as an advisor to Abbott and Janssen, has received research support from AbbVie, and has acted as a speaker at symposiums sponsored by AbbVie and Janssen.

**Author for Correspondence:**

Dr Emily K Wright  
St Vincent's Hospital  
Victoria Parade  
Fitzroy 3065  
Melbourne  
Australia

Tel: + 61 3 92312211

E: [Emily.Wright@svha.org.au](mailto:Emily.Wright@svha.org.au)

**Word Count: 2157 Words**

# Author Manuscript

Article type : Original Research

## Accuracy of Point of Care Intestinal Ultrasound for Crohn's Disease

### Abstract:

**Background:** Point of care ultrasound (POCUS), performed by a gastroenterologist, provides safe and convenient imaging allowing for immediate clinical decision in Crohn's disease. The minimum training required to gain competency, its accuracy and clinical utility require evaluation.

**Methods:** In this pilot study Crohn's disease activity and extent were assessed using POCUS (performed by a single gastroenterologist following the completion of 200 supervised scans), magnetic resonance enterography (MRE) and ileo-colonoscopy. The presence of complications were assessed by POCUS and MRE. Accuracy of POCUS was analysed with respect to MRE and ileo-colonoscopy. Agreement between modalities was assessed using kappa coefficient.

**Results:** 42 patients had a POCUS paired with MRE. 38 patients had a POCUS paired with ileo-colonoscopy. When compared to MRE, POCUS was accurate in the assessment of disease activity (sensitivity 87.5%, specificity 61.1%, ROC 0.74), extent (sensitivity 77.8%, specificity 83.3%, ROC 0.81) and complications (sensitivity 85.7%, specificity 94.3%, ROC 0.90). Agreement between POCUS and MRE was moderate (kappa estimates 0.50,  $P < 0.001$ , 0.61,  $P < 0.001$  and 0.76,  $P < 0.001$ ) for disease activity, extent and complications respectively. When compared to ileo-colonoscopy POCUS was accurate in the assessment of disease activity (sensitivity 72%, specificity 86%, ROC 0.79) and extent (sensitivity 85.7%, specificity 86%, ROC 0.86). For POCUS and ileo-colonoscopy kappa estimates were 0.55,  $P < 0.001$  for disease activity and 0.62,  $P < 0.001$  for disease extent.

**Conclusion:** POCUS performed by a gastroenterologist after completion of limited training is

accurate for assessing Crohn's disease activity, extent and the presence of complications.

**Keywords: Intestinal ultrasound, GIUS, POCUS, Crohn's Disease**

Author Manuscript

## Introduction

Crohn's disease (CD) is a progressive, inflammatory disease occurring in genetically predisposed patients. The incidence of CD has been reported as high as 29.3 per 100,000 in Australia and is increasing worldwide.<sup>1</sup> The development of new drugs and therapeutic treatment strategies in the management of inflammatory bowel disease (IBD) have raised patient and clinician expectations. A 'treat to target' approach is an accepted strategy for IBD care, wherein objective measures of disease activity are sought and used to guide subsequent management.<sup>2</sup> Achievement of mucosal healing, assessed with colonoscopy, is now the accepted target for treatment and is associated with reduced rates of clinical relapse, hospitalisation, and surgery.<sup>3-8</sup>

The limitations of colonoscopy, including safety, access, cost and patient preference, have increased the importance of cross-sectional imaging for the regular monitoring of intestinal inflammation.<sup>9, 10</sup> Computed tomography (CT) and magnetic resonance enterography (MRE) are the most available current imaging modalities for the assessment of active disease but CT is associated with ionising radiation exposure and therefore inappropriate for repeated use,<sup>11</sup> while MRE is costly and access difficult. MRE is, however, widely considered the gold standard cross-sectional imaging modality for identifying active disease, particularly in the small bowel.<sup>12</sup> Taylor et al, in a prospective study of patients with newly diagnosed Crohn's disease compared the accuracy of MRE and small bowel ultrasound, when performed by specialist radiologists. Both MRE and ultrasound were found to have high diagnostic accuracy and were valid first line investigations for disease assessment in the patients. The sensitivity and specificity of MRE was superior to ultrasound for small bowel, but not colonic disease.<sup>12</sup>

Gastrointestinal ultrasound (GIUS), performed by a gastroenterologist at the point-of-care (POCUS), is a cost effective, non-invasive, radiation-free imaging method, which allows transmural assessment of the bowel wall and adjacent structures. POCUS can be used to in immediate clinical decision making to optimise treatment.<sup>13</sup>

GIUS when performed by an experienced sonographer or gastroenterologist, in high volume centres, has been shown to have good sensitivity and specificity for the diagnosis of Crohn's disease and its complications including strictures, entero-enteric fistulae and abscesses.<sup>14-18</sup> There is increasing acceptance internationally of POCUS as an accurate and valuable tool in

the IBD imaging armamentarium,<sup>19, 20</sup> and much recent interest from gastroenterologists performing GIUS at the bedside as an extension of their examination of patients with Crohn's disease. A growing body of evidence supports POCUS as a viable method of disease evaluation in IBD.<sup>13, 21, 22</sup> A minimum training fulfilment of 150-200 supervised scans has been suggested<sup>23</sup>, although there are few data supporting the competency achieved by such training. It remains to be determined whether POCUS, performed by a gastroenterologist with specific and defined training in intestinal ultrasound, but without training in general ultrasound, provides acceptable diagnostic accuracy and clinical utility<sup>19</sup>.

We hypothesised that POCUS, performed by a gastroenterologist with a minimum of 200 supervised scans in patients with Crohn's disease, provides accurate and clinically useful information about the activity and extent of Crohn's disease and about the presence or absence of intestinal complications including strictures, fistulas, abscesses or enter-enteric fistulae.

## **Methods**

Ethics approval for this study was provided by the Quality and Risk Unit at our institution (approval QA 026/17). All ultrasound were performed as part of routine clinical care. Given the retrospective nature of the study patient consent was not required.

### **Patient Selection and Disease Assessment**

In this single specialist centre, retrospective pilot study, consecutive patients with a proven diagnosis of Crohn's disease who had a POCUS performed from February 2016 until October 2017 within three months of MRE, ileo-colonoscopy, or both were included. Disease activity, disease extent and the presence of complications were assessed by POCUS and MRE. Complications, for the purposes of this study, were defined as strictures (the presence of increased bowel wall thickness associated with fixed luminal narrowing) with pre-stenotic dilatation, enteric fistulas or the presence of a phlegmon or abscess. Only disease activity and extent were assessed using ileo-colonoscopy given the limitations of colonoscopy in the assessment of extra-mural complications. A single-gastroenterologist performed all POCUS scans within three months of either MRE or ileo-colonoscopy without intervening change in medical therapy.

### **POCUS Examination**

A single gastroenterologist (EW) performed all scans included. Immediately prior the

gastroenterologist had performed 200 supervised scans in patients with IBD at a high volume intestinal ultrasound centre (Foothills Medical Centre, Calgary, Canada).

A standardised approach was used starting the examination from the left lower quadrant, and examining the colon from the distal sigmoid to the cecum working proximally with examination of each colonic segment in turn. The terminal ileum was then evaluated, followed by systematic four-quadrant examination to include the remaining small bowel. All exams were completed using a Supersonic Aixplorer machine utilizing both a low frequency (4–9 mHz) curved probe and higher frequency (12–15 mHz) linear probe.

The presence of disease activity was defined as either “active” or “inactive.” Disease activity was deemed to be present if there was increased bowel wall thickness ( $>3$  mm) with or without the presence of any additional established indicators of active inflammation: increased color Doppler blood flow, loss of wall stratification, the presence of mesenteric inflammatory fat or the presence of lymph nodes.<sup>24</sup>

The extent of disease was recorded for the purposes of this study as being “limited”, defined at  $\leq 5$ cm, or “extensive”, defined as  $>5$ cm in length. Where multiple segment of bowel were involved this length is cumulative over the affected areas.

The presence or absence of complications as defined above were also recorded.

## **MRE**

Eligible scan reports were reviewed. All scans were performed at a single centre experienced with performing MRE in patients with Crohn’s disease. Disease was deemed to be active if there was bowel wall thickening with bowel wall enhancement, T2 wall hyper-signal or inflammatory change. The extent of disease was recorded for the purposes of this study as “limited”, defined at  $\leq 5$ cm, or “extensive”, defined as  $>5$ cm in length. The presence of absence of complications was also recorded.

## **Ileo-colonoscopy**

Eligible ileo-colonoscopy reports were reviewed. Colonoscopy results were reviewed to determine both disease activity and extent. Active disease was defined as any ulceration seen at colonoscopy. As for POCUS examination, the extent of disease was recorded for the purposes of this study as being “limited”, defined at  $\leq 5$ cm, or “extensive”, defined as  $>5$ cm in length.



## Statistical Analyses

Statistical analyses were performed using Stata 14.2 (StataCorp, College Station, TX). Summary data is reported as count (percentage). Contingency tables were constructed to compare pairs of the diagnostic modalities being examined in order to calculate sensitivity and specificity. These were then used to calculate the area under the receiver operating characteristic curves (AUROC). Cohen's kappa statistic was calculated, again comparing pairs of diagnostic modalities, to estimate interrater agreement.

## Results

A total of 65 patients were included in this study. Demographic and treatment details of the patients included are shown in Table 1. Patients were divided into the POCUS and MRE analysis (n=42) and the POCUS and Ileo-Colonoscopy analysis (n=38) depending on the data available. Some patients were included in both analyses as POCUS, MRE and ileo-colonoscopy data were all available.

### POCUS and MRE paired studies (Table 2, Figure 1)

Forty two patients (50% males) had a POCUS paired with MRE. Twenty-eight studies (67%) showed active disease on POCUS compared to 24 (57%) on MRE. When compared to MRE, POCUS was accurate in identifying active disease with a sensitivity 87.5%, specificity 61.1%, and AUROC 0.74.

Eighteen patients (43%) had active disease of >5cm on POCUS and 18 (43%) on MRE. POCUS identified extensive disease in comparison to MRE with a sensitivity of 77.8%, specificity of 83.3%, and AUROC 0.81.

Complications were identified in 8 (19%) on POCUS and 7 (17%) on MRE. POCUS identified complications in comparison with MRE with a sensitivity of 85.7%, specificity of 94.3% and AUROC 0.90.

Agreement between POCUS and MRE was moderate (kappa 0.50 (95% CI 0.24-0.76)  $P < 0.001$ , 0.61 (95% CI 0.37-0.85)  $P < 0.001$  and 0.76 (95% CI 0.50 – 1.00)  $P < 0.001$ ) for disease activity, extent and presence of complications respectively.

### **POCUS and Ileo-Colonoscopy paired studies (Table 3, Figure 2)**

Thirty eight patients (47% males) had a POCUS paired with ileo-colonoscopy. Active disease was identified in 20 (53%) patients on POCUS compared to 25 (66%) on ileo-colonoscopy. When compared to ileo-colonoscopy POCUS was accurate in the diagnosis of active disease with a sensitivity 72.0%, specificity 86.7%, and AUROC 0.79.

Ten (26%) patients had extensive disease on POCUS compared to 7 (18%) on ileo-colonoscopy. When compared to ileo-colonoscopy POCUS identified extensive disease with a sensitivity of 85.7%, specificity of 86.2% and AUROC 0.86.

In our study active disease was diagnosed more often at ileo-colonoscopy than at POCUS. Five patients had active disease seen at ileo-colonoscopy but not at POCUS. Of these, two had disease in the rectum, which cannot be viewed adequately using POCUS<sup>16</sup>, one had very mild terminal ileum disease, one had mild right sided colitis, and one had mild recurrence at an ileo-caecal anastomosis. Significant ileal or colonic disease was not missed by POCUS.

Agreement between POCUS and ileo-colonoscopy was moderate (kappa 0.55 (95% CI 0.30-0.80)  $P < 0.001$  for disease activity and 0.62 (95% CI 0.32 – 0.92)  $P < 0.001$  for disease extent.

### **Discussion:**

The benefits of intestinal ultrasounds performed by the gastroenterologist delivering patient care are numerous, particularly the capacity for involving the patient in management decisions at the bedside and the ability to escalate clinical care immediately from the clinic.<sup>13</sup> Physician-performed POCUS has been reported to strengthen rapport between doctors and patients in other chronic disease settings<sup>25, 26</sup> and allows acceptable diagnostic accuracy in the clinical context, without the need for formal radiology training or a full diagnostic knowledge and expertise in broader ultrasonography.<sup>26</sup> Data suggests a high level of satisfaction with this test among patients in inflammatory bowel disease.<sup>28</sup>

The learning curve for gastroenterologist-performed POCUS in IBD is not well established, despite increasing uptake by clinicians. We have not assessed different extents of supervised training, but chose a practical number of patients which was felt to be sufficiently large. POCUS, performed by a gastroenterologist with a minimum training of 200 supervised scans,

is accurate for assessing clinically important disease parameters including Crohn's disease activity, extent and the presence of complications. Moderate agreement between POCUS and MRE, and between POCUS and ileo-colonoscopy, was demonstrated.

Our results reflect the established accuracy of intestinal ultrasound in the diagnosis of Crohn's disease. Recent meta-analyses report good to excellent sensitivity and specificity of ultrasound for diagnosis of Crohn's disease when compared to CT, barium study, MRE or endoscopy.<sup>29-31</sup> The most recent meta-analysis, by Dong et al,<sup>29</sup> reviewed 15 prospective studies in which ultrasound was used to evaluate active Crohn's disease. Overall sensitivity was 88.0% and specificity 97.0% for identifying active Crohn's disease with an AUROC of 0.94, indicating good diagnostic accuracy. In more than half of the 15 included studies ultrasound was performed by experienced sonographers.

In the current study POCUS demonstrated modest specificity (61.1%) when compared to MRE for the diagnosis of active disease. The ability for POCUS to provide bedside disease assessment, to triage severity, and allow for immediate clinical decision making regarding further investigations or treatment, without the delays of MRE or ileo-colonoscopy is invaluable, and outweighs this modest reduction in specificity. In this study, active disease was identified more frequently on POCUS when compared to MRE. This may relate to the criterion that any bowel wall thickening, even without other ultrasound features of inflammation, was interpreted as showing active disease at POCUS but not on MRE, and also the likely superior sensitivity of POCUS for the diagnosis of low grade inflammation when compared to MRE.

The significance of low grade inflammation, often reflected by increased wall thickness in the absence of other radiological signs of inflammation, compared to complete normalisation of wall thickness and stratification (transmural healing) is controversial. Transmural healing is seen in only a minority (16%) of patients with Crohn's disease and only a proportion of patients with endoscopic mucosal healing. Whilst mild bowel wall thickness on imaging in the absence of any other features of active inflammation, may hold prognostic importance,<sup>32-34</sup> how accurately it reflects active Crohn's disease and future disease course is unknown and prospective studies are needed.

Strengths to this study include the use of a single gastroenterologist performing all included POCUS scans, and the comparison of POCUS results to both MRE and ileo-colonoscopy. MRE

scans included in this study were all performed using the same protocol at the same tertiary hospital by radiologists with extensive experience reading MRE in patients with Crohn's disease.

The major limitation of this study is the retrospective nature of the data. Larger, prospective studies are required to confirm these findings. This study used a simple definition for 'active' or 'inactive' disease and did not look at disease activity per bowel segment. A more sophisticated definition of disease activity at ultrasound, using a tool such as the simple ultrasonographic score for the assessment of Crohn's disease activity which has now been developed and validated<sup>27</sup> may improve the sensitivity of POCUS for the identification of active disease. The use of an endoscopic score such as the Simple Endoscopic Score for Crohn's Disease (SES-CD)<sup>35</sup> would have provided more detailed information with regards to disease activity at endoscopy which would have allowed for a more sophisticated analysis of any correlation between endoscopic and ultrasound.

Different stages of ultrasound training and experience need to be evaluated. Although patients undergoing changes to medical therapy during the investigation period were excluded it is possible that disease evolution or progress occurred during the time period between POCUS and ileo-colonoscopy or MRE. Same-day comparison of imaging modalities and ileo-colonoscopy would avoid such issues.

In summary, POCUS, performed by a gastroenterologist with limited training, is accurate, providing clinically useful information for the management of patients with Crohn's disease. Our data support gastroenterologist use of POCUS in the assessment and monitoring of these patients.

## References:

1. Wilson J, Hair C, Knight R, et al. High incidence of inflammatory bowel disease in Australia: a prospective population-based Australian incidence study. *Inflamm Bowel Dis* 2010;16:1550-6.
2. Peyrin-Biroulet L, Sandborn W, Sands BE, et al. Selecting Therapeutic Targets in Inflammatory Bowel Disease (STRIDE): Determining Therapeutic Goals for Treat-to-Target. *Am J Gastroenterol* 2015;110:1324-38.
3. Baert F, Moortgat L, Van Assche G, et al. Mucosal healing predicts sustained clinical remission in patients with early-stage Crohn's disease. *Gastroenterology* 2010;138:463-8; quiz e10-1.
4. Colombel JF, Rutgeerts P, Reinisch W, et al. Early mucosal healing with infliximab is associated with improved long-term clinical outcomes in ulcerative colitis. *Gastroenterology* 2011;141:1194-201.
5. D'Haens G, Baert F, van Assche G, et al. Early combined immunosuppression or conventional management in patients with newly diagnosed Crohn's disease: an open randomised trial. *Lancet* 2008;371:660-7.
6. Neurath MF, Travis SP. Mucosal healing in inflammatory bowel diseases: a systematic review. *Gut* 2012;61:1619-35.
7. Rutgeerts P, Diamond RH, Bala M, et al. Scheduled maintenance treatment with infliximab is superior to episodic treatment for the healing of mucosal ulceration associated with Crohn's disease. *Gastrointest Endosc* 2006;63:433-42; quiz 464.
8. Schnitzler F, Fidler H, Ferrante M, et al. Mucosal healing predicts long-term outcome of maintenance therapy with infliximab in Crohn's disease. *Inflamm Bowel Dis* 2009;15:1295-301.
9. Niewiadomski O, Studd C, Hair C, et al. Health Care Cost Analysis in a Population-based Inception Cohort of Inflammatory Bowel Disease Patients in the First Year of Diagnosis. *J Crohns Colitis* 2015;9:988-96.
10. Molodecky NA, Soon IS, Rabi DM, et al. Increasing incidence and prevalence of the inflammatory bowel diseases with time, based on systematic review. *Gastroenterology* 2012;142:46-54 e42; quiz e30.
11. Chatu S, Subramanian V, Pollok RC. Meta-analysis: diagnostic medical radiation exposure in inflammatory bowel disease. *Aliment Pharmacol Ther* 2012;35:529-39.

12. Taylor SA, Mallett S, Bhatnagar G, et al. Diagnostic accuracy of magnetic resonance enterography and small bowel ultrasound for the extent and activity of newly diagnosed and relapsed Crohn's disease (METRIC): a multicentre trial. *Lancet Gastroenterol Hepatol* 2018;3:548-558.
13. Novak K, Tanyingoh D, Petersen F, et al. Clinic-based Point of Care Transabdominal Ultrasound for Monitoring Crohn's Disease: Impact on Clinical Decision Making. *J Crohns Colitis* 2015;9:795-801.
14. Sonnenberg A, Erckenbrecht J, Peter P, et al. Detection of Crohn's disease by ultrasound. *Gastroenterology* 1982;83:430-4.
15. Parente F, Maconi G, Bollani S, et al. Bowel ultrasound in assessment of Crohn's disease and detection of related small bowel strictures: a prospective comparative study versus x ray and intraoperative findings. *Gut* 2002;50:490-5.
16. Parente F, Greco S, Molteni M, et al. Role of early ultrasound in detecting inflammatory intestinal disorders and identifying their anatomical location within the bowel. *Aliment Pharmacol Ther* 2003;18:1009-16.
17. Novak KL, Jacob D, Kaplan GG, et al. Point of Care Ultrasound Accurately Distinguishes Inflammatory from Noninflammatory Disease in Patients Presenting with Abdominal Pain and Diarrhea. *Can J Gastroenterol Hepatol* 2016;2016:4023065.
18. Calabrese E, Zorzi F, Onali S, et al. Accuracy of small-intestine contrast ultrasonography, compared with computed tomography enteroclysis, in characterizing lesions in patients with Crohn's disease. *Clin Gastroenterol Hepatol* 2013;11:950-5.
19. Panes J, Bouhnik Y, Reinisch W, et al. Imaging techniques for assessment of inflammatory bowel disease: joint ECCO and ESGAR evidence-based consensus guidelines. *J Crohns Colitis* 2013;7:556-85.
20. Panes J, Bouzas R, Chaparro M, et al. Systematic review: the use of ultrasonography, computed tomography and magnetic resonance imaging for the diagnosis, assessment of activity and abdominal complications of Crohn's disease. *Aliment Pharmacol Ther* 2011;34:125-45.
21. Calabrese E, Maaser C, Zorzi F, et al. Bowel Ultrasonography in the Management of Crohn's Disease. A Review with Recommendations of an International Panel of Experts. *Inflamm Bowel Dis* 2016;22:1168-83.
22. Bryant RV, Friedman AB, Wright EK, et al. Gastrointestinal ultrasound in inflammatory bowel disease: an underused resource with potential paradigm-changing application. *Gut* 2018;67:973-985.

23. Monteleone M, Friedman A, Furfaro E, et al. The learning curve of intestinal ultrasonography in assessing inflammatory bowel disease: preliminary results. *Journal Of Crohn's & Colitis* 2013;7:S64.
24. Sturm EJ, Cobben LP, Meijssen MA, et al. Detection of ileocecal Crohn's disease using ultrasound as the primary imaging modality. *Eur Radiol* 2004;14:778-82.
25. Terslev L, Hammer HB, Torp-Pedersen S, et al. EFSUMB minimum training requirements for rheumatologists performing musculoskeletal ultrasound. *Ultraschall Med* 2013;34:475-7.
26. Atkinson NS, Bryant RV, Dong Y, et al. WFUMB Position Paper. Learning Gastrointestinal Ultrasound: Theory and Practice. *Ultrasound Med Biol* 2016;42:2732-2742.
27. Novak KL, Kaplan GG, Panaccione R, et al. A Simple Ultrasound Score for the Accurate Detection of Inflammatory Activity in Crohn's Disease. *Inflamm Bowel Dis* 2017.
28. Buisson A, Gonzalez F, Poullenot F, et al. Comparative Acceptability and Perceived Clinical Utility of Monitoring Tools: A Nationwide Survey of Patients with Inflammatory Bowel Disease. *Inflamm Bowel Dis* 2017;23:1425-1433.
29. Dong J, Wang H, Zhao J, et al. Ultrasound as a diagnostic tool in detecting active Crohn's disease: a meta-analysis of prospective studies. *Eur Radiol* 2014;24:26-33.
30. Horsthuis K, Bipat S, Bennink RJ, et al. Inflammatory bowel disease diagnosed with US, MR, scintigraphy, and CT: meta-analysis of prospective studies. *Radiology* 2008;247:64-79.
31. Fraquelli M, Colli A, Casazza G, et al. Role of US in detection of Crohn disease: meta-analysis. *Radiology* 2005;236:95-101.
32. Buisson A, Hordonneau C, Deepak P. Transmural Healing and MRI Remission: New Promising Therapeutic Targets in Crohn's Disease. *Inflamm Bowel Dis* 2017;23:E44-E45.
33. Fernandes SR, Rodrigues RV, Bernardo S, et al. Transmural Healing Is Associated with Improved Long-term Outcomes of Patients with Crohn's Disease. *Inflamm Bowel Dis* 2017;23:1403-1409.
34. Castiglione F, Testa A, Rea M, et al. Transmural healing evaluated by bowel sonography in patients with Crohn's disease on maintenance treatment with biologics. *Inflamm Bowel Dis* 2013;19:1928-34.
35. Daperno M, D'Haens G, Van Assche G, et al. Development and validation of a new, simplified endoscopic activity score for Crohn's disease: the SES-CD. *Gastrointest Endosc* 2004;60:505-12.

**Table 1. Patient demographics**

<b>Demographics</b>	<b>POCUS and Paired MRE n (%)</b>	<b>POCUS and Paired Ileo- Colonoscopy n(%)</b>
<b>Total Patients</b>	42	38
<b>Males</b>	21 (50)	18 (47)
<b>Active Disease on POCUS</b>	28 (67)	19 (50)
<b>Drug Treatment</b>		
<b>Steroids</b>	10 (24)	10 (26)
<b>5-ASA</b>	4 (10)	6 (16)
<b>Methotrexate</b>	2 (5)	4 (11)
<b>Thiopurine</b>	17 (40)	11 (29)
<b>Antibiotics</b>	2 (5)	2 (5)
<b>Anti-TNF</b>	18 (43)	9 (24)
<b>Vedolizumab</b>	1 (2)	0 (0)

**Table 2.** POCUS and MRE paired examinations. Summary of results for disease assessment and accuracy.

Disease Assessment: POCUS vs MRE (n = 42)			
	POCUS		MRE
Active Disease n (%)	28 (67)		24 (57)
Extensive Disease n (%)	18 (43)		18 (43)
Disease complication n (%)	8 (19)		7 (17)
Accuracy: POCUS vs MRE			
	Sensitivity (%)	Specificity (%)	AUROC
Disease Activity	87.5	61.1	0.74
Disease Extent	77.8	83.3	0.81
Disease complications	85.7	94.3	0.90



**Table 3.** POCUS and ileo-colonoscopy paired examinations. Summary of results for disease assessment and accuracy.

Disease Assessment: POCUS vs Ileo-Colonoscopy (n = 38)			
	POCUS		Ileo-Colonoscopy
Active Disease n (%)	20 (53)		25 (66)
Extensive Disease n (%)	10 (26)		7 (18)
Accuracy: POCUS vs Ileo-Colonoscopy			
	Sensitivity (%)	Specificity (%)	AUROC
Disease Activity	72.0	86.7	0.79
Disease Extent	85.7	86.2	0.86

**Figure Legend:**

**Figure 1A.** Accuracy of POCUS compared to MRE in the diagnosis of active Crohn's disease.

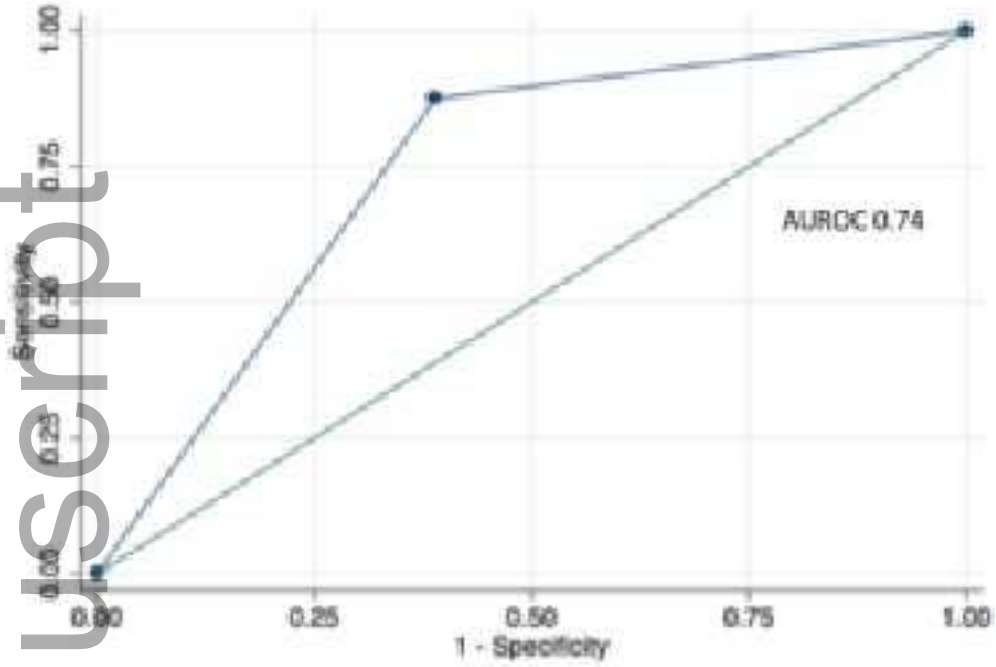
**Figure 1B.** Accuracy of POCUS compared to MRE in the assessment of Crohn's disease extent.

**Figure 1C.** Accuracy of POCUS compared to MRE in the diagnosis of complications.

**Figure 2A.** Accuracy of POCUS compared to ileo-colonoscopy in the diagnosis of active Crohn's disease.

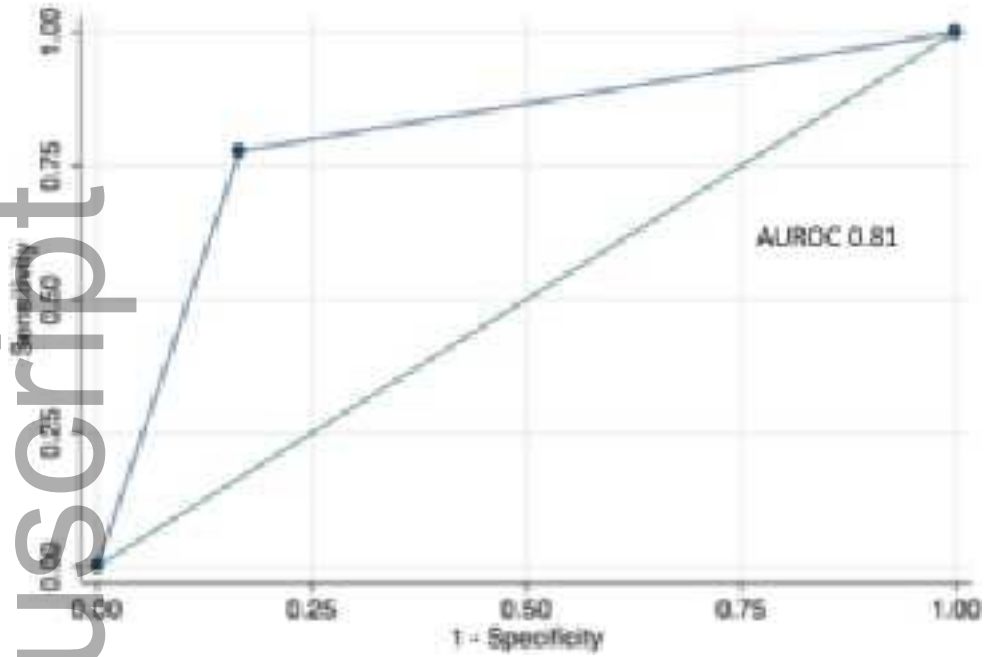
**Figure 2B.** Accuracy of POCUS compared to MRE in the assessment of Crohn's disease extent.

Diagnosis of Active Disease: POCUS vs MRE



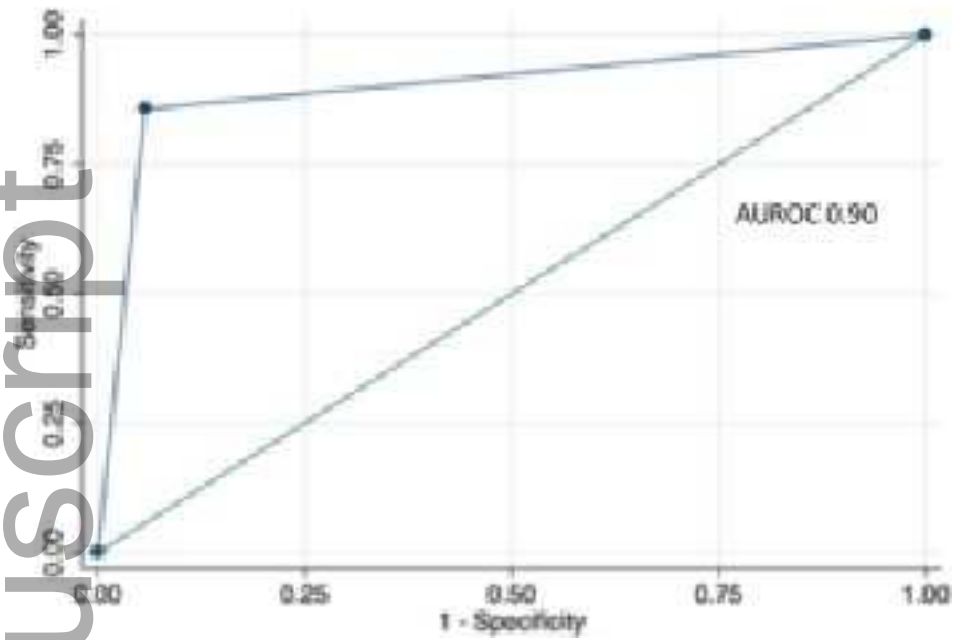
ajum\_12218\_f1a.tiff

Assessment of Disease Extent: POCUS vs MRE

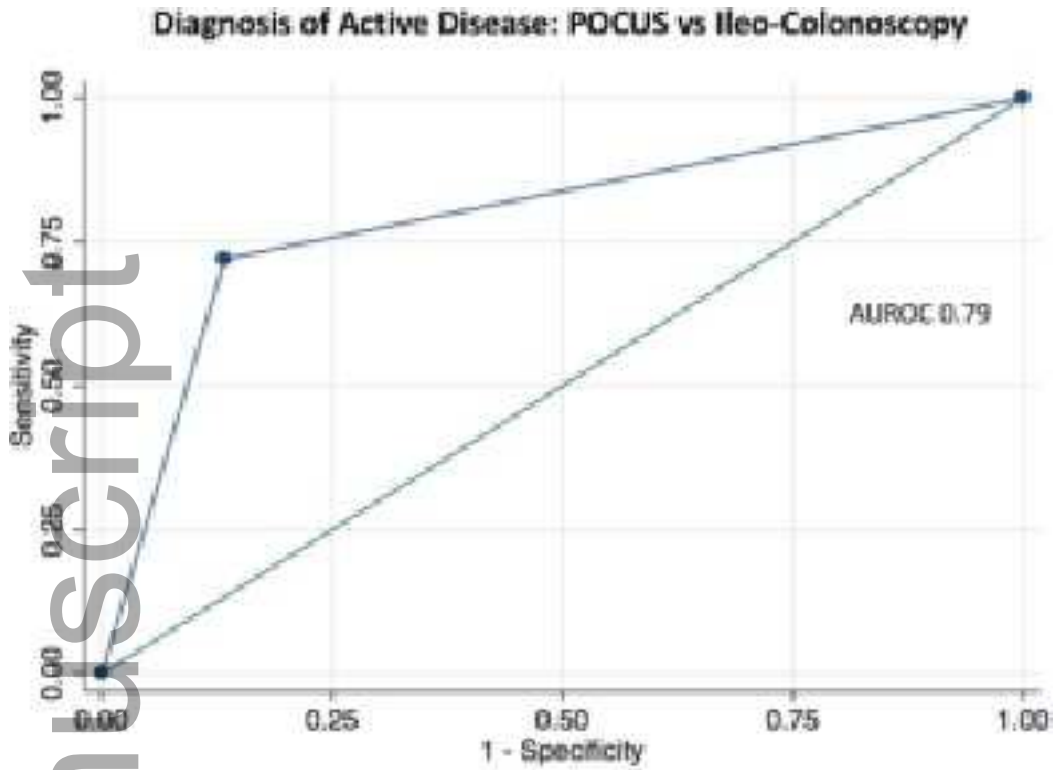


ajum\_12218\_f1b.tiff

# Diagnosis of Complications: POCUS vs MRE

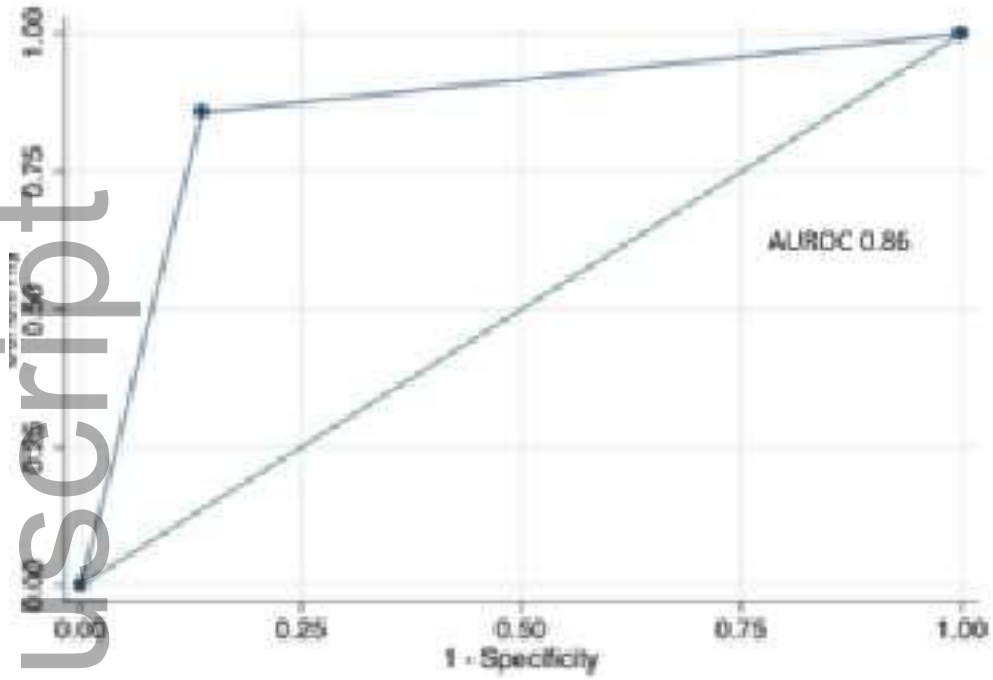


ajum\_12218\_f1c.tiff



ajum\_12218\_f2a.tiff

Assessment of Disease Extent: POCUS vs Ileo-Colonoscopy



ajum\_12218\_f2b.tiff