



Minerva Access is the Institutional Repository of The University of Melbourne

Author/s:

Behrenbruch, C;Hollande, F;Thomson, B;Michael, M;Warrier, SK;Lynch, C;Heriot, A

Title:

Treatment of peritoneal carcinomatosis with hyperthermic intraperitoneal chemotherapy in colorectal cancer

Date:

2017-09-01

Citation:

Behrenbruch, C., Hollande, F., Thomson, B., Michael, M., Warrier, S. K., Lynch, C. & Heriot, A. (2017). Treatment of peritoneal carcinomatosis with hyperthermic intraperitoneal chemotherapy in colorectal cancer. *ANZ Journal of Surgery*, 87 (9), pp.665-670. <https://doi.org/10.1111/ans.14077>.

Persistent Link:

<https://hdl.handle.net/11343/293124>

TITLE: Treatment of Peritoneal Carcinomatosis with Hyperthermic Intraperitoneal Chemotherapy in Colorectal Cancer

RUNNING TITLE Hyperthermic Intraperitoneal Chemotherapy – Evidence in Colorectal Cancer

AUTHORS AND AFFILIATIONS

Behrenbruch C<sup>1,4</sup>, Hollande F<sup>4</sup>, Thomson B<sup>1,3</sup>, Michael M<sup>2</sup>, Warriar SK<sup>1</sup>, Lynch AC<sup>15</sup>, Heriot A<sup>15</sup>.

<sup>1</sup>Division of Cancer Surgery, Peter MacCallum Cancer Centre, Victorian Comprehensive Cancer Centre, 305 Grattan St Melbourne, 3000, Australia

<sup>2</sup>Division of Cancer Medicine, Peter MacCallum Cancer Centre, Victorian Comprehensive Cancer Centre, 305 Grattan St Melbourne, 3000, Australia

<sup>3</sup>The University of Melbourne, Department of Surgery, Royal Melbourne Hospital, 300 Grattan St Parkville 3010, Australia.

<sup>4</sup>The University of Melbourne, Department of Pathology, Victorian Comprehensive Cancer Centre, 305 Grattan St Melbourne, 3000, Australia

<sup>5</sup>The University of Melbourne, Department of Surgery, St Vincent's Hospital, 41 Victoria Pde, Fitzroy, 3065, Australia

Corresponding Author: Corina Behrenbruch [cori.behrenbruch@petermac.org](mailto:cori.behrenbruch@petermac.org)

Division of Cancer Surgery, Peter MacCallum Cancer Centre, Victorian Comprehensive Cancer Centre, 305 Grattan St Melbourne, 3000, Australia

Phone: +61 3 8559 7666

Fax: +61 3 8559 7709

Authors Degrees

- Corina C Behrenbruch: MBBS, FRACS.
- Frédéric Hollande: MSc, PhD.
- Benjamin N Thomson: DMedSc, FRACS.
- Satish K Warriar: MS, FRACS
- AC Lynch: MMedSc, FRACS
- Michael Michael: MD, FRACP.
- Alexander G Heriot: MBA, MD, FRACS.

The corresponding author is a recipient of three research scholarships:

1. Australian Post Graduate Award, The University of Melbourne
2. Helen Macpherson Smith Scholarship. The University of Melbourne
3. Covidien Colorectal Research Fellowship

This paper has not been based on a previous communication to a society or meeting

Number of Figures: 2, Number of Tables: 2

Word count for Abstract: 127

Word count for text (excluding abstract, acknowledgments, figure legends and references): 2571

**This is the author manuscript accepted for publication and has undergone full peer review but has not been through the copyediting, typesetting, pagination and proofreading process, which may lead to differences between this version and the Version of Record. Please cite this article as doi: [10.1111/ans.14077](https://doi.org/10.1111/ans.14077)**

Author Manuscript

## ABSTRACT

The peritoneum is the second most common site of metastasis after the liver and the only site of metastatic disease in approximately 25% of patients with colorectal cancer<sup>1-3</sup>. In the past peritoneal carcinomatosis in colorectal cancer was thought equivalent to distant metastasis, however transcoelomic spread of malignant cells is an acknowledged alternative pathway<sup>4</sup>. Metastasectomy with curative intent is well accepted in patients with liver metastasis in colorectal cancer despite the paucity of randomised trials. Therefore there is rationale for local treatment with peritonectomy to eliminate macroscopic disease, followed by hyperthermic intraperitoneal chemotherapy (HIPEC) to destroy any residual free tumour cells within the peritoneal cavity<sup>1-3</sup>. The aim of this paper is to summarise the current evidence for cytoreduction and HIPEC in the treatment of peritoneal carcinomatosis in colorectal cancer.

Abstract Word Count: 127 words

Author Manuscript

# **Treatment of Peritoneal Carcinomatosis with Hyperthermic Intraperitoneal Chemotherapy in Colorectal Cancer**

## **BACKGROUND**

Peritoneal carcinomatosis (PC) was historically fatal according to the EVOCAPE study showing the mean survival in 370 patients with PC (non-gynecological origin) was only 6 months<sup>5</sup>. In the 1990's Paul Sugarbaker first described the "Sugarbaker technique" where HIPEC (hyperthermic intraperitoneal carcinomatosis) was combined with cytoreductive surgery (CRS), initially for pseudomyxoma peritonei (PMP) and later gastrointestinal and gynaecological malignancies<sup>6</sup>. The application of this technique to PC in colorectal cancer represents a paradigm shift, with survival rates following radical CRS with HIPEC approaching 30-45% at 5 years in carefully selected patients, similar to outcomes seen with resection of colorectal liver metastasis<sup>7-10</sup>.

## **METHODOLOGY**

A PubMed search of all articles containing the keyword " HIPEC" was performed including papers published up until the 5<sup>th</sup> May 2016, as treatment of PC from colorectal cancer (CRC) was often an etiological subgroup included in more general HIPEC papers. The search revealed 426 papers. All abstracts were read to identify randomised trials, systematic reviews and meta-analyses. Five studies were identified including one phase-II trial, one randomised controlled trial and 3 systematic reviews, one of which included a meta-analysis.

## **PRE-OPERATIVE INVESTIGATIONS and ASSESSMENT OF DISEASE EXTENT**

Prior to treatment with CRS and HIPEC a colonoscopy, combined PET/CT chest, abdomen and pelvis and tumour markers (CEA, Ca125, Ca19.9) are required, as well as administration of splenic vaccinations<sup>6</sup>. When assessing the extent of PC the radiological distribution including the CT peritoneal carcinoma index (PCI), intra-operative PCI, peritoneal surface disease severity score (PSDSS) and completeness of resection score (CCRS) are important.

CT scans underestimate the size of peritoneal deposits in 33 % of patients, therefore diagnostic laparoscopy by an experienced surgeon may have a role, as 20-40% of patients are found to be inoperable at the time of laparotomy<sup>6, 11, 12</sup>. To improve CT-PCI correlation with clinical findings and pre-operative determination of resectability, 8 additional CT-criteria have been proposed. These include small bowel/serosal mesenteric disease, small/large bowel obstruction, biliary obstruction, ureteric obstruction, ascites, omental caking, peri-hepatic nodules and peritoneal lesions >5cm. A score of 3 predicts for unresectability with a specificity of 80% and sensitivity of 62.5%<sup>13</sup>.

The PCI score remains the best estimate of disease bulk and is a reliable indicator of the possibility of complete cytoreduction. The score is a function of the distribution of tumor into 13 abdomino-pelvic regions (9 to 12 dividing the small bowel), with a lesion size score to give a score from 0-39. The lesion score LS-0 indicates no disease seen; LS-1 indicates peritoneal lesions up to 0.5cm, LS-2 lesions up to 5.0 cm and LS-3 lesions more than 5.0 cm or confluent (**FigureS1**)<sup>14</sup>. A linear correlation has been found between PCI and overall survival<sup>15</sup>. Recently Goéré et al suggested that CRS with HIPEC may be indicated for PCI <12 and contraindicated for PCI >17 as there is with no survival benefit in CRC if the

PCI is  $>17$ <sup>16</sup>. Between 12 and 17 decision for treatment depends on parameters such as performance status or presence of extraperitoneal metastases<sup>15</sup>.

Unlike PMP which requires simple stripping of peritoneum, PC being invasive requires actual tissue resection, or stripping with a higher powered diathermy<sup>17</sup>. In addition to the PCI, a newer score the PSDSS consists of 4 stages and includes PCI as well as clinical symptomatology and histopathology of the primary tumour<sup>18</sup>. This score correlates with resectability and survival of the patient following CRS and HIPEC. Following cytoreduction a completeness of cytoreduction score (CCRS) is assigned. The score is either complete (CC-0 or CC-1) or incomplete (CC-2 or CC-3). CC-0 implies absence of peritoneal disease, CC-1 indicates residual nodules  $< 2.5$  mm, CC-2 nodules between 2.5mm and 2.5 cm and CC-3 nodules  $>2.5$  cm or a confluence of an unresectable tumor nodule at any site within the abdomen or pelvis<sup>14</sup>.

#### CYTOREDUCTIVE SURGERY.

Removal of all visible peritoneal surface deposits (CC-O) is essential for long term survival<sup>19</sup>. Peritoneal deposits involve the visceral peritoneum at sites where the bowel is fixed to the retro-peritoneum with less motion of the visceral peritoneal surface, (recto-sigmoid colon, ileo-caecal region and the gastric antrum)<sup>19</sup>. Additionally PC involves sites of previous dissection, often from initial surgery. CRS involves peritoneal and visceral resections depending on extent of disease (**TableS1**)<sup>19</sup>.

#### PHARMACOLOGY AND PHARMACOKINETICS OF HIPEC

A differential response to hyperthermia exists between normal and malignant cells (range 41- 43C) due to increased sensitivity of mitochondria in malignant cells, with selective destruction of tumour cells<sup>4,20</sup>. Additionally, hyperthermia has a synergistic effect with the chemotherapy<sup>20</sup>. HIPEC allows a high local chemotherapy concentration targeting residual microscopic disease while minimizing side effects, administered peri-operatively to maximise exposure prior adhesions formation and trapping of tumour cells within scar. The penetration of HIPEC into peritoneal nodules (even with hyperthermia) is limited to 2 mm - 5 mm, so HIPEC is indicated in R0 and R1 resections<sup>20</sup>.

Chemotherapy must be cell cycle non-specific (allowing single administration), ideally have heat-synergistic cytotoxicity and exist in an active form i.e. pro-drugs will not have effect<sup>20</sup>. Carrier vehicles exhibit low diffusion coefficients, limiting the systemic absorption of the HIPEC improving the efficacy and side effect profile<sup>21</sup>. HIPEC is predominantly drained via the portal system, providing a first pass effect, as well as potential cytotoxicity to liver micrometastasis<sup>20</sup>. Bi-directional chemotherapy or concurrent HIPEC and intravenous administration of chemotherapy (e.g. 5-FU) is advocated in many centres<sup>22</sup>. The rationale for this regimen can be understood using a 3-compartment model comprising the plasma, peritoneal cavity and the third compartment the tumour bearing peritoneum, the target of the HIPEC<sup>23</sup>. The large peritoneal cavity containing HIPEC acts as a reservoir for the IV 5FU that is cleared from the peritoneal cavity by diffusing across the interstitium. Chemotherapy diffuses across the interstitium from two directions, from the capillary compartment and from the peritoneal cavity resulting in a high drug concentration at the peritoneal surface (**FigureS2**)<sup>20, 22</sup>. The agents most commonly used

in CRC include Mitomycin-C and oxaliplatin, however randomised trials have not determined the optimal drug.

## TECHNIQUES OF HIPEC DELIVERY

Administration of HIPEC is either via the open or closed technique, with no comparative trials. When utilizing the open coliseum technique, following CRS, the abdominal wall is sutured to a fixed retractor creating a coliseum containing the HIPEC within the peritoneal cavity. The skin is protected with synthetic drapes and inflow (pelvis) and outflow (above the liver) drains are then placed, as well as a thermometer and smoke-evacuator (**Figure1**). In the closed technique the skin is temporarily closed with the inflow and outflow tubing inserted through separate incisions. Some groups are using laparoscopy to perform limited CRS with instillation of HIPEC for restricted indications such as low grade and limited PMP from appendiceal disease with no small bowel involvement<sup>24, 25</sup>. Concerns are that laparoscopy may be inadequate to assess the PCI. More recently pressurized intra-peritoneal aerosol chemotherapy or PIPAC has been delivered in patients with colorectal cancer in conjunction with systemic chemotherapy, where the delivery of pressurized chemotherapy improves local bioavailability<sup>26, 27</sup>.

## CURRENT EVIDENCE FOR CRS + HIPEC in COLORECTAL CANCER

The recent evidence for CRS + HIPEC in CRC is summarized in **Table1**. The introduction of irinotecan- and oxaliplatin- based systemic chemotherapy (sCT) has resulted in increased median survival of patients with metastatic CRC from 6-8 months to 20 months, with a further increase up to 30 months survival with targeted agents and triplet chemotherapy combinations. However, large retrospective

series suggest that sCT and targeted agents are less effective in treating PC from CRC than haematogenous metastases<sup>28, 29</sup>.

In 1995 a Phase II trial by Sugarbaker et al (51 patients) achieved a 3-year survival of 36% for PC in CRC treated with CRS +HIPEC<sup>30</sup>. Bowel perforations or anastomotic leaks occurred in approximately 33% of patients. A trial in 2003 by Verwaal et al randomised patients to either standard sCT of 5FU/LV with or without palliative surgery, or to CRS with HIPEC followed by the same chemotherapy regimens for PC from CRC<sup>31</sup>. In a subgroup of patients where there was no residual macroscopic tumour, the results showed a 5-year survival equal to that of patients undergoing resection for CRLM (35-45%) of 45%<sup>9, 32</sup>. Disease free survival was almost double in the HIPEC group at 22.2 months compared with 12.6 months in the chemotherapy group. Unfortunately the study included 18 patients with appendiceal cancer and there was a high mortality of 8% (4 patients)<sup>33</sup>.

Three recent systematic reviews have analysed the use of CRS+HIPEC in patients with PC from CRC (**Table1**). Cao et al included 34 studies in the meta-analysis, with a significant improvement in OS associated with treatment by CRS and HIPEC compared with sCT and palliative surgery ( $P < 0.0001$ )<sup>34</sup>. Reviews by Chua and Baratti also showed an improvement in median OS and 5-year survival in the CRS + HIPEC group versus palliative surgery with or without sCT, and versus sCT alone. Baratti et al highlighted two studies where sCT resulted in a lower survival benefit in CRC-PC compared to non-PC metastases<sup>28</sup>. In particular a retrospective analysis of two pooled Dutch randomised trials (CAIRO and CAIRO2) showed a median survival of 10.4 months in the PC group compared to 17.3 months in those

without PC<sup>35</sup>.

There are no specific trials evaluating the individual components of CRS and HIPEC. The French trial Prodigé7 will investigate the benefit of HIPEC itself by comparing patients who have undergone CRS, followed by either HIPEC with sCT or sCT alone<sup>36</sup>. The COMBATAC trial (multicenter, single arm) aims to recruit 60 patients to perioperative sCT (FOLFOX or FOLFIRI with cetuximab) in combination with CRS, followed by bi-directional HIPEC containing oxaliplatin with 5FU, in patients with histologically proven wild-type KRAS CRC or appendiceal adenocarcinoma and synchronous or metachronous PC<sup>37</sup>. Given that there are currently no trials designed specifically to show the benefit of treating PC only with sCT, as well as concerns that patients with PC from CRC may have worse outcomes than expected from sCT, until more data is available the literature supports the use of CRS with HIPEC<sup>17</sup>.

TREATMENT OF PERITONEAL CARCINOMATOSIS with COLORECTAL LIVER METASTASIS  
Colorectal liver metastases (CRLM) have historically been viewed as exclusion criterion for CRS and similarly the presence of PC is thought to be a contraindication for resection of CRLM.<sup>9, 38</sup> There have been recent promising results combining CRS + HIPEC and resection of CRLM, however no there are no randomized trials. Elias et al devised a nomogram allowing preliminary estimation of the OS of patients with CRLM and PC undergoing optimal surgery from CRC. The number of CRLM ( $p = 0.037$ ) and the PCI ( $<0.0001$ ) were associated with survival<sup>7</sup>. There is evidence to support offering CRS with HIPEC in patients with a PCI $<12$  and  $<3$  resectable CRLM<sup>39</sup>.

Allard et al showed in 1340 patients who underwent metastasectomy for CRLM, 3% overall had unexpected PC<sup>40</sup>. Thirty patients subsequently underwent simultaneous resection of CRLM and limited PC (Median PCI 2), with an OS of 18% at 5 years (median 42 months). In 2013 de Cuba et al published a systematic review (6 studies, 139 patients, largest cohort 70 patients) and a meta-analysis (3 studies only) for CRS with HIPEC for PC combined with curative treatment of CRLM<sup>9</sup>. The median OS reported ranged from 6 to 36 months. Although there was a trend towards lower OS in patients with both PC and CRLM compared with PC alone, patients with showed a tendency towards increased median OS after CRS and HIPEC combined with resection of CRLM compared with sCT<sup>3</sup>. The studies included were heterogenous both in the techniques of CRS and HIPEC and treatment of the CRLM with limited detail on the nature/extent of the CRLM. Two further papers have demonstrated improved median survival and OS on subgroup analysis of low PCI and limited number of CRLM, with median OS 40 months (PCI < 12, <3 CRLM)<sup>41</sup> and 38.4 months (PCI d7 or LM d3), indicating the importance of patients selection<sup>38</sup>.

#### NOVEL INDICATIONS for HIGH RISK COLORECTAL CANCER

Patients with a high risk primary CRC (ovarian metastases, perforation, emergency presentations) have up to 50% chance of developing PC<sup>42</sup>. In 2000 a multi-centre RCT (total 267 patients) compared resection of CRC followed by intra peritoneal administration of 5FU (<38C) for 6 days versus resection alone, both groups also receiving IV 5FU. Stage II cancer patients who received the full dose of intra-peritoneal 5-FU had a 5-year DFS significantly higher than the control group (89% vs. 73% p=0.05)<sup>43</sup>. Two novel approaches to high-risk disease have been proposed; prophylactic/adjuvant HIPEC for high

risk primary CRC and second look laparotomy following resection of the primary tumour for consideration of prophylactic cytoreduction and HIPEC.

In 2014 a systematic review (12 studies, no RCTs) investigated the role of HIPEC as an adjuvant treatment to prevent PC of CRC origin, concluding that despite limited evidence and subjection to bias there was some indication of improved oncological outcomes, requiring further study with a randomized trial<sup>44</sup>. In a case control study by Sammartino et al, 25 patients with high risk T3/T4 colon cancer (mucinous or signet ring cancer) who underwent hemi-colectomy with limited CRS followed by HIPEC were compared with 50 patients who received standard resection of their primary tumour. PC developed in 4% of the experimental arm and 22% of the control arm<sup>45</sup>. The disease free survival was 36.8 months in the experimental group versus 21.9 months in the control group ( $p < 0.01$ ). At 48 months after the study closed the median OS was significantly longer in the study group (59.5 months) than the control group (52.0 months) ( $P < 0.04$ )<sup>46</sup>. The COLOPEC trial will assess the efficacy of adjuvant HIPEC following curative resection of T4 and perforated CRC, in preventing PC in addition to standard adjuvant sCT.

Small volume PC can be asymptomatic and imaging occult, therefore “second-look laparotomy” has been proposed to identify disease progression early in high risk, asymptomatic patients<sup>47</sup>. Elias et al published a series of 41 patients who underwent a second look laparotomy (SLL) for the purpose of treating limited PC early in patients with defined selection criteria (resected minimal synchronous macroscopic PC, synchronous ovarian metastasis and perforation). In 56% of patients imaging-occult PC was found and treated with CRS + HIPEC with a 5-year OS rate of 90%<sup>47, 48</sup>. This study has led to a

multi-centered randomized trial Prophylochip where following adjuvant sCT high-risk patients are randomized between simple surveillance and SLL, to clarify if results are due to lead-time bias. A randomized trial by Ripley et al will evaluate SLL followed by HIPEC and CRS vs. standard surveillance in high risk CRC<sup>49</sup>.

## MORBIDITY and MORTALITY

The morbidity from HIPEC with CRS is predominantly due to the surgery and includes anastomotic leak, IP sepsis/abscess, small bowel fistulae, pancreatic leaks, bleeding and rare reports of scrotal pain and ulceration<sup>50</sup>. A recent systematic review specifically for PC from CRC showed the weighted average of major morbidity and mortality rates for CRS/HIPEC to be 32.6% and 2.9% respectively<sup>28</sup>. A number of studies including cohort and adjusted model studies have reported on the learning curve (LC) required to achieve technical proficiency for CRS + HIPEC for peritoneal surface malignancy. Studies reporting an inflection point suggest a LC around 140-220 cases<sup>51</sup>. A multicenter study by Kusamura et al of 2451 patients concluded that at least 100 procedures per centre and 96 per surgeon are necessary for acquiring optimal expertise in the management of PMP<sup>52</sup>. Studies specific to PC from CRC include a cohort study of 800 patients by Huang et al that suggested more complete cytoreduction and less grade 4 complications occurred after 200 cases<sup>53</sup>. With expanding indications for CRS and HIPEC increasing pressure will be placed on these specialist resources.

## CONCLUSION

Few randomized trials assess the benefit of CRS and HIPEC in the treatment of peritoneal carcinomatosis from colorectal cancer. A number of large cohort series have shown improvement in

overall survival for selected patients with colorectal cancer when treated with cytoreduction and HIPEC, with a small series showing potential benefit of the technique prophylactically in high-risk cases. There is no doubt that cytoreduction and HIPEC is an essential strategy to be discussed as part of the total care of patients with peritoneal disease in colorectal cancer. The results of randomized trials and future molecular studies will serve to guide future management including refinements of patient selection.

#### REFERENCES

1. Ahmed S, Stewart JH, Shen P, Votanopoulos KI, Levine EA. Outcomes with cytoreductive surgery and HIPEC for peritoneal metastasis. *J Surg Oncol* 2014;**110**(5): 575-584.
2. Alzahrani N, Ferguson JS, Valle SJ, Liauw W, Chua T, Morris DL. Cytoreductive surgery and hyperthermic intraperitoneal chemotherapy: long-term results at St George Hospital, Australia. *ANZ journal of surgery* 2015.
3. Kerscher AG CT, Gasser M, Maeder U, Kunzmann V, Isbert C, Germer C, Pelz J. Impact of peritoneal carcinomatosis in the disease history of colorectal cancer management: a longitudinal experience of 2406 patients over two decades. *British Journal of Cancer* 2013;**108**: 1432-1439.
4. Sugarbaker PH, Van der Speeten K, Stuart OA. Pharmacologic rationale for treatments of peritoneal surface malignancy from colorectal cancer. *World Journal of Gastrointestinal Oncology* 2010;**2**(1): 19-30.
5. Sadeghi B, Arvieux C, Glehen O, Beaujard AC, Rivoire M, Baulieux J, Fontaumard E, Brachet A, Caillot JL, Faure JL, Porcheron J, Peix JL, Francois Y, Vignal J, Gilly FN. Peritoneal carcinomatosis from non-gynecologic malignancies: results of the EVOCAPE 1 multicentric prospective study. *Cancer* 2000;**88**(2): 358-363.
6. Ansari N, Chandrakumaran K, Dayal S, Mohamed F, Cecil TD, Moran BJ. Cytoreductive surgery and hyperthermic intraperitoneal chemotherapy in 1000 patients with perforated appendiceal epithelial tumours. *Eur J Surg Oncol* 2016;**42**(7): 1035-1041.
7. Elias D, Faron M, Goere D, Dumont F, Honore C, Boige V, Malka D, Ducreux M. A simple tumor load-based nomogram for surgery in patients with colorectal liver and peritoneal metastases. *Ann Surg Oncol* 2014;**21**(6): 2052-2058.
8. Chua TC, Yan TD, Saxena A, Morris DL. Should the treatment of peritoneal carcinomatosis by cytoreductive surgery and hyperthermic intraperitoneal chemotherapy still be regarded as a highly morbid procedure?: a systematic review of morbidity and mortality. *Ann Surg* 2009;**249**(6): 900-907.

9. de Cuba EM, Kwakman R, Knol DL, Bonjer HJ, Meijer GA, Te Velde EA. Cytoreductive surgery and HIPEC for peritoneal metastases combined with curative treatment of colorectal liver metastases: Systematic review of all literature and meta-analysis of observational studies. *Cancer Treat Rev* 2013;**39**(4): 321-327.
10. van Oudheusden TR, Nienhuijs SW, Luyer MD, Nieuwenhuijzen GA, Lemmens VE, Rutten HJ, de Hingh IH. Incidence and treatment of recurrent disease after cytoreductive surgery and intraperitoneal chemotherapy for peritoneally metastasized colorectal cancer: A systematic review. *Eur J Surg Oncol* 2015;**41**(10): 1269-1277.
11. Thomassen I, van Gestel YR, Aalbers AG, van Oudheusden TR, Wegdam JA, Lemmens VE, de Hingh IH. Peritoneal carcinomatosis is less frequently diagnosed during laparoscopic surgery compared to open surgery in patients with colorectal cancer. *Eur J Surg Oncol* 2014;**40**(5): 511-514.
12. Seshadri RA, E HR. Diagnostic Laparoscopy in the Pre-operative Assessment of Patients Undergoing Cytoreductive Surgery and HIPEC for Peritoneal Surface Malignancies. *Indian Journal of Surgical Oncology* 2016;**7**(2): 230-235.
13. Tan GH, Kwek JW, Hosseini R, Chanyaputhipong J, Tham CK, Soo KC, Teo MC. Proposed radiological criteria for pre-operative determination of resectability in peritoneal-based malignancies. *J Med Imaging Radiat Oncol* 2016;**60**(3): 337-343.
14. Sugarbaker PH. Surgical Management of Carcinomatosis from Colorectal Cancer. *Clinics in Colon and Rectal Surgery* 2005;**18**(3): 190-203.
15. Faron M, Macovei R, Goéré D, Honoré C, Benhaim L, Elias D. Linear Relationship of Peritoneal Cancer Index and Survival in Patients with Peritoneal Metastases from Colorectal Cancer. *Annals of Surgical Oncology* 2016;**23**(1): 114-119.
16. GoÉRÈ MD, PhD, Souadka MA, Faron MM, Cloutier MAS, Viana MB, HonorÈ MC, Dumont MF, Elias MD, PhD. Extent of Colorectal Peritoneal Carcinomatosis: Attempt to Define a Threshold Above Which HIPEC Does Not Offer Survival Benefit: A Comparative Study. *Annals of Surgical Oncology*; **22**(9): 2958-2964.
17. Mohamed F, Cecil T, Moran B, Sugarbaker P. A new standard of care for the management of peritoneal surface malignancy. *Current Oncology* 2011;**18**(2): e84-e96.
18. Esquivel J, Lowy AM, Markman M, Chua T, Pelz J, Baratti D, Baumgartner JM, Berri R, Bretcha-Boix P, Deraco M, Flores-Ayala G, Glehen O, Gomez-Portilla A, González-Moreno S, Goodman M, Halkia E, Kusamura S, Moller M, Passot G, Pocard M, Salti G, Sardi A, Senthil M, Spilioitis J, Torres-Melero J, Turaga K, Trout R. The American Society of Peritoneal Surface Malignancies (ASPSM) Multiinstitution Evaluation of the Peritoneal Surface Disease Severity Score (PSDSS) in 1,013 Patients with Colorectal Cancer with Peritoneal Carcinomatosis. *Annals of Surgical Oncology* 2014;**21**(13): 4195-4201.
19. Sugarbaker PH. Cytoreductive surgery using peritonectomy and visceral resections for peritoneal surface malignancy. *Translational Gastrointestinal Cancer* 2013;**2**(2): 54-74.

20. González-Moreno S, González-Bayón LA, Ortega-Pérez G. Hyperthermic intraperitoneal chemotherapy: Rationale and technique. *World Journal of Gastrointestinal Oncology* 2010;**2**(2): 68-75.
21. Van der Speeten K, Stuart OA, Sugarbaker PH. Pharmacokinetics and pharmacodynamics of perioperative cancer chemotherapy in peritoneal surface malignancy. *Cancer J* 2009;**15**(3): 216-224.
22. Valle SJ, Alzahrani NA, Liauw W, Sugarbaker PH, Bhatt A, Morris DL. Hyperthermic Intraperitoneal Chemotherapy (HIPEC) Methodology, Drugs and Bidirectional Chemotherapy. *Indian journal of surgical oncology* 2016;**7**(2): 152-159.
23. Cotte E, Colomban O, Guitton J, Tranchand B, Bakrin N, Gilly F-N, Glehen O, Tod M. Population Pharmacokinetics and Pharmacodynamics of Cisplatin During Hyperthermic Intraperitoneal Chemotherapy Using a Closed Abdominal Procedure. *The Journal of Clinical Pharmacology* 2011;**51**(1): 9-18.
24. Passot G, Bakrin N, Isaac S, Decullier E, Gilly FN, Glehen O, Cotte E. Postoperative outcomes of laparoscopic vs open cytoreductive surgery plus hyperthermic intraperitoneal chemotherapy for treatment of peritoneal surface malignancies. *Eur J Surg Oncol* 2014;**40**(8): 957-962.
25. Esquivel J, Averbach A, Chua TC. Laparoscopic cytoreductive surgery and hyperthermic intraperitoneal chemotherapy in patients with limited peritoneal surface malignancies: feasibility, morbidity and outcome in an early experience. *Ann Surg* 2011;**253**(4): 764-768.
26. Robella M, Vaira M, De Simone M. Safety and feasibility of pressurized intraperitoneal aerosol chemotherapy (PIPAC) associated with systemic chemotherapy: an innovative approach to treat peritoneal carcinomatosis. *World Journal of Surgical Oncology* 2016;**14**(1): 1-6.
27. Nadiradze G, Giger-Pabst U, Zieren J, Strumberg D, Solass W, Reymond MA. Pressurized Intraperitoneal Aerosol Chemotherapy (PIPAC) with Low-Dose Cisplatin and Doxorubicin in Gastric Peritoneal Metastasis. *Journal of gastrointestinal surgery : official journal of the Society for Surgery of the Alimentary Tract* 2016;**20**(2): 367-373.
28. Baratti D, Kusamura S, Pietrantonio F, Guaglio M, Niger M, Deraco M. Progress in treatments for colorectal cancer peritoneal metastases during the years 2010-2015. A systematic review. *Crit Rev Oncol Hematol* 2016;**100**: 209-222.
29. Ye L LT, Ren Li, Wei Y, Zhu D, Zai S, Ye Q, YuY, Xu B, Qin X, Xu J. Randomised controlled trial of cetuximab plus chemotherapy for patients with KRAS WT Unresectable Colorectal Liver-Limited Metastasis. *JCO* 2013;**31**(16): 1931-1938.
30. Sugarbaker PH, Jablonski KA. Prognostic features of 51 colorectal and 130 appendiceal cancer patients with peritoneal carcinomatosis treated by cytoreductive surgery and intraperitoneal chemotherapy. *Annals of Surgery* 1995;**221**(2): 124-132.
31. Verwaal VJ, van Ruth S, de Bree E, van Sloothen GW, van Tinteren H, Boot H, Zoetmulder FA. Randomized trial of cytoreduction and hyperthermic intraperitoneal chemotherapy versus systemic chemotherapy and palliative surgery in patients with peritoneal carcinomatosis of colorectal cancer. *Journal of clinical oncology : official journal of the American Society of Clinical Oncology* 2003;**21**(20): 3737-3743.

32. Verwaal VJ, Bruin S, Boot H, van Slooten G, van Tinteren H. 8-Year Follow-up of Randomized Trial: Cytoreduction and Hyperthermic Intraperitoneal Chemotherapy Versus Systemic Chemotherapy in Patients with Peritoneal Carcinomatosis of Colorectal Cancer. *Annals of Surgical Oncology* 2008;**15**(9): 2426-2432.
33. Sugarbaker PH, Ryan DP. Cytoreductive surgery plus hyperthermic perioperative chemotherapy to treat peritoneal metastases from colorectal cancer: standard of care or an experimental approach? *Lancet Oncol* 2012;**13**(8): e362-369.
34. Cao C, Yan TD, Black D, Morris DL. A Systematic Review and Meta-Analysis of Cytoreductive Surgery with Perioperative Intraperitoneal Chemotherapy for Peritoneal Carcinomatosis of Colorectal Origin. *Annals of Surgical Oncology* 2009;**16**(8): 2152-2165.
35. Klaver YLB, Simkens LHJ, Lemmens VEPP, Koopman M, Teerenstra S, Bleichrodt RP, de Hingh IHJT, Punt CJA. Outcomes of colorectal cancer patients with peritoneal carcinomatosis treated with chemotherapy with and without targeted therapy. *European Journal of Surgical Oncology (EJSO)* 2012;**38**(7): 617-623.
36. Management of Peritoneal Metastases (PM) from colorectal cancers: New Perspectives. [15/5/2016 2016].
37. Glockzin G, Rochon J, Arnold D, Lang SA, Klebl F, Zeman F, Koller M, Schlitt HJ, Piso P. A prospective multicenter phase II study evaluating multimodality treatment of patients with peritoneal carcinomatosis arising from appendiceal and colorectal cancer: the COMBATAC trial. *BMC Cancer* 2013;**13**(1): 1-10.
38. Alzahrani N, Ung L, Valle SJ, Liauw W, Morris DL. Synchronous liver resection with cytoreductive surgery for the treatment of liver and peritoneal metastases from colon cancer: results from an Australian centre. *ANZ journal of surgery* 2015.
39. Graziosi L, Marino E, Cavazzoni E, Donini A. Simultaneous surgical treatment for both colorectal liver metastases and peritoneal carcinomatosis. *European journal of surgical oncology : the journal of the European Society of Surgical Oncology and the British Association of Surgical Oncology* 2014;**40**(3): 366-367.
40. Allard MA, Adam R, Ruiz A, Vibert E, Paule B, Levi F, Sebah M, Guettier C, Azoulay D, Castaing D. Is unexpected peritoneal carcinomatosis still a contraindication for resection of colorectal liver metastases? Combined resection of colorectal liver metastases with peritoneal deposits discovered intra-operatively. *Eur J Surg Oncol* 2013;**39**(9): 981-987.
41. Maggiori L, Goere D, Viana B, Tzanis D, Dumont F, Honore C, Eveno C, Elias D. Should patients with peritoneal carcinomatosis of colorectal origin with synchronous liver metastases be treated with a curative intent? A case-control study. *Ann Surg* 2013;**258**(1): 116-121.
42. Ripley RT, Davis JL, Kemp CD, Steinberg SM, Toomey MA, Avital I. Prospective randomized trial evaluating mandatory second look surgery with HIPEC and CRS vs. standard of care in patients at high risk of developing colorectal peritoneal metastases. *Trials* 2010;**11**(1): 1-8.
43. Vaillant J-C, Nordlinger B, Deuffic S, Arnaud J-P, Pelissier E, Favre J-P, Jaeck D, Fourtanier G, Grandjean J-P, Marre P, Letoublon C. Adjuvant Intraperitoneal 5-Fluorouracil in High-Risk Colon Cancer: A Multicenter Phase III Trial. *Annals of Surgery* 2000;**231**(4): 449-456.

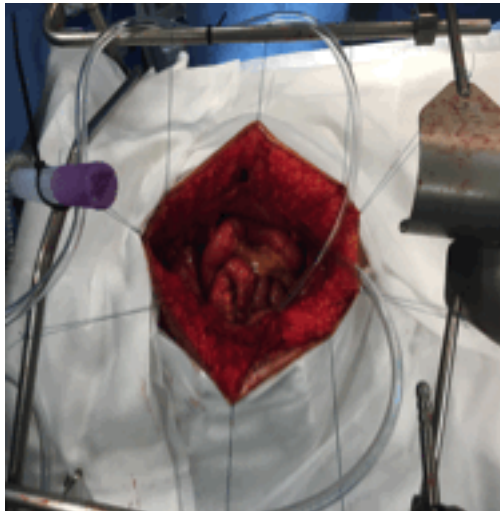
44. Sloothaak DAM, Mirck B, Punt CJA, Bemelman WA, van der Bilt JDW, D'Hoore A, Tanis PJ. Intraperitoneal chemotherapy as adjuvant treatment to prevent peritoneal carcinomatosis of colorectal cancer origin: a systematic review. *Br J Cancer* 2014;**111**(6): 1112-1121.
45. Sammartino P, Sibio S, Biacchi D, Cardi M, Accarpio F, Mingazzini P, Rosati MS, Cornali T, Di Giorgio A. Prevention of Peritoneal Metastases from Colon Cancer in High-Risk Patients: Preliminary Results of Surgery plus Prophylactic HIPEC. *Gastroenterol Res Pract* 2012;**2012**: 141585.
46. Li Y, Yu Y, Liu Y. Report on the 9(th) International Congress on Peritoneal Surface Malignancies. *Cancer Biology & Medicine* 2014;**11**(4): 281-284.
47. Baratti D, Kusamura S, Deraco M. Prevention and early treatment of peritoneal metastases from colorectal cancer: second-look laparotomy or prophylactic HIPEC? *J Surg Oncol* 2014;**109**(3): 225-226.
48. Elias D, Honore C, Dumont F, Ducreux M, Boige V, Malka D, Burtin P, Dromain C, Goere D. Results of systematic second-look surgery plus HIPEC in asymptomatic patients presenting a high risk of developing colorectal peritoneal carcinomatosis. *Ann Surg* 2011;**254**(2): 289-293.
49. Ripley RT, Davis JL, Kemp CD, Steinberg SM, Toomey MA, Avital I. Prospective randomized trial evaluating mandatory second look surgery with HIPEC and CRS vs. standard of care in patients at high risk of developing colorectal peritoneal metastases. *Trials* 2010;**11**: 62-62.
50. Abdul Aziz NHB, Wang W, Teo MCC. Scrotal Pain and Ulceration Post HIPEC: A Case Report. *Journal of gastrointestinal cancer* 2015;**46**(1): 60-63.
51. Rajeev R, Klooster B, Turaga KK. Impact of surgical volume of centers on post-operative outcomes from cytoreductive surgery and hyperthermic intra-peritoneal chemoperfusion. *Journal of Gastrointestinal Oncology* 2016;**7**(1): 122-128.
52. Kusamura S, Moran BJ, Sugarbaker PH, Levine EA, Elias D, Baratti D, Morris DL, Sardi A, Glehen O, Deraco M. Multicentre study of the learning curve and surgical performance of cytoreductive surgery with intraperitoneal chemotherapy for pseudomyxoma peritonei. *The British journal of surgery* 2014;**101**(13): 1758-1765.
53. Huang Y, Alzahrani NA, Liauw W, Morris DL. Learning curve for cytoreductive surgery and perioperative intraperitoneal chemotherapy for peritoneal carcinomatosis. *ANZ Journal of Surgery* 2017;**87**(1-2): 49-54.

Autho

## Supporting Information

1. Supplementary Table 1. **Peritonectomy and Visceral Resections in Cytoreduction**
2. Supplementary Figure 1. **Peritoneal Carcinoma Index**
3. Supplementary Figure 2. **Pharmacodynamics of Bidirectional Chemotherapy**

Author Manuscript



ANZ HIPEC Fig 1.gif

Table 1. Summary of current evidence for CRS + HIPEC for PC from Colorectal Cancer

NA = not applicable, NR= not recorded, RCT = randomised controlled trial, sCT= systemic chemotherapy

	Studies Included	Number of patients	Median OS (Months)	Median 5-year OS (%)
Phase II Trial-1995 Sugarbaker et al <sup>35</sup>	N/A	51 - CRS + HIPEC: 51	NR	- NR - 3 year survival 36%
RCT – 2003 (2008 update) Verwaal et al <sup>36, 37</sup>	N/A	105 (included 18 patients with appendiceal carcinoma) - sCT: 51 - CRS + HIPEC: 54	- sCT: 12.6 - CRS+HIPEC: 22.2 (p=0.028)	- sCT: NR - CRS + HIPEC: 20% - CRS+HIPEC with R1 resection:45%
Systematic Review+ Meta-analysis 2009 Cao et al <sup>39</sup>	47 studies - 4 comparative (2xRCT, one early termination due to poor accrual) - 43 observational	NR, only for meta-analysis: 271 - CRS +IP Chemo:136 - sCT: 135	- Not calculated, ranges only	- Not calculated, ranges only
Systematic Review - 2013 Chua et al <sup>56</sup>	18 studies - 2xRCTs - 2xPhase II - 14xObservational studies	2,492 - CRS+HIPEC: 1084, - Palliative surgery +/- sCT: 1408	- CRS + HIPEC:33 - CRS + HIPEC (R1)-resection: 48 - Palliative surgery +/-or sCT: 12.5	- CRS + HIPEC: 40% - Palliative surgery and/or sCT group: 13%
Systematic review 2016 Baratti et al <sup>24</sup>	32 studies - 19 x cohort - 13 x comparative - 6 x adjuvant HIPEC (9 trials with sCT, including subset of RCT)	NR	- sCT:Ox/Irinotecan: 10.1 - 15 - sCT/5FU: 9.0–11.0 s - Use of VEGF/EGF inhibitors: 15.2–18-2 - CRS +HIPEC: weighted average 31.6 months	- CRS + HIPEC weighted average: 31.0%.