

Lycium Barbarum Polysaccharides Rescue Neurodegeneration in an Acute Ocular Hypertension Rat Model Under Pre- and Posttreatment Conditions

Yamunadevi Lakshmanan,¹ Francisca Siu-Yin Wong,¹ Wing-Yan Yu,¹ Serena Zhe-Chuang Li,¹ Kai-Yip Choi,¹ Kwok-Fai So,^{2,3} and Henry Ho-Lung Chan¹

¹Laboratory of Experimental Optometry (Neuroscience), School of Optometry, The Hong Kong Polytechnic University, Hong Kong, China

²Department of Ophthalmology, Li Ka Shing Faculty of Medicine, The University of Hong Kong, Hong Kong, China

³Guangdong-Hongkong-Macau (GHM) Institute of CNS Regeneration, Jinan University, Guangzhou, China

Correspondence: Henry Ho-Lung Chan, School of Optometry, The Hong Kong Polytechnic University, 11 Yuk Choi Road, Hung Hom, Kowloon, Hong Kong SAR, China; henryhl.chan@polyu.edu.hk

Submitted: February 3, 2019

Accepted: April 2, 2019

Citation: Lakshmanan Y, Wong FS-Y, Yu W-Y, et al. Lycium barbarum polysaccharides rescue neurodegeneration in an acute ocular hypertension rat model under pre- and posttreatment conditions. *Invest Ophthalmol Vis Sci.* 2019;60:2023-2033. <https://doi.org/10.1167/iov.19-26752>

PURPOSE. To investigate the posttreatment neuronal rescue effects of *Lycium barbarum* polysaccharides (LBP) in an acute ocular hypertensive (AOH) model.

METHODS. Intraocular pressure (IOP) was elevated manometrically to 80 mm Hg (AOH) or 15 mm Hg (sham) for 120 minutes in adult Sprague-Dawley rats. Five experimental groups were considered: Three AOH groups were pretreated with PBS (vehicle) ($n = 9$), LBP 1 mg/kg ($n = 8$), or 10 mg/kg ($n = 13$), and one AOH group was posttreated with LBP 10 mg/kg ($n = 8$), once daily. The sham cannulation group ($n = 5$) received no treatment. Pretreatments commenced 7 days before and posttreatment 6 hours after AOH, and continued up through postcannulation day 28. All the animals underwent optical coherence tomography and electroretinogram measurements at baseline and postcannulation days 10 and 28. The ganglion cell layer (GCL) densities were quantified at day 28.

RESULTS. Both inner retinal layer thickness (IRLT) and positive scotopic threshold response (pSTR) underwent significant reduction ($\geq 50\%$ of thickness and amplitude) in the vehicle group ($P < 0.05$). Pretreatment with LBP 1 and 10 mg/kg retained $77 \pm 11\%$ and $89 \pm 8\%$ of baseline IRLT, respectively, and preserved pSTR functions. The posttreatment group showed a significant reduction in IRLT ($-35 \pm 8\%$, $P < 0.001$) and pSTR ($\sim 48\%$ of baseline, $P < 0.001$) on day 10. By day 28, there was an improvement in functional pSTR ($\sim 72\%$ of baseline, $P > 0.05$) with no significant further thinning ($-40 \pm 8\%$, $P = 0.15$) relative to day 10. GCL density was reduced in vehicle control ($P = 0.0001$), but did not differ between sham and pre- and posttreated AOH groups.

CONCLUSIONS. The rescue effect of LBP posttreatment was observed later, which arrested the secondary degeneration and improved the retinal function.

Keywords: lycium barbarum polysaccharides, neuronal rescue, posttreatment, acute ocular hypertension, rat model

Neuroprotection is considered as a potential treatment option for glaucoma due to the progressive nature of the disease with multifactorial contributions and because of the similarities it shares with other central nervous system disorders.^{1,2} In recent years, several possible neuroprotective agents have been identified for glaucoma treatment, which target factors other than the elevated intraocular pressure (IOP).^{3,4} However, only a few of these agents underwent clinical trials and none have so far been approved for clinical use.

The fruits of *Lycium barbarum*, also known as wolfberry, contain many bioactive substances including polysaccharides, carotenoids, flavonoids, amino acids, vitamins, fatty acids, and other trace elements.⁵ Interestingly, the polysaccharides of *L. barbarum* (LBP) have been shown to have positive effects on aging processes,^{6,7} fatigue,⁸ oxidative stress,⁹⁻¹² neurodegenerative disease,^{13,14} tumor growth,¹⁵ immune response,¹⁶ inflammation,¹⁷ irradiation,¹⁸ hyperglycemia,¹⁹ hyperlipidemia²⁰ and

other induced toxicities.^{17,21} The neuroprotective effects of LBP have been demonstrated in different experimental models of central nervous system disorders that include variants of optic neuropathies.²²⁻²⁹ The possible neuroprotective mechanisms of LBP in preserving the retinal ganglionic cells (RGC) have been investigated in rodent models of chronic ocular hypertension,²²⁻²⁴ acute ocular hypertension (AOH),^{26,29} partial optic nerve transection,^{25,27} and ischemic reperfusion injuries.²⁸ However, all these studies demonstrated the prophylactic effect of LBP by pretreating the animals from 1 week prior to the insult until the end of the study period. Only one of these studies applied functional testing,²⁵ the rest adopting structural end points, which were assessed using histologic techniques. While longitudinal data were collected by cross-sectional observation of animals killed at different time points, there have been no reports demonstrating the neuroprotective effect of LBP using in vivo longitudinal structural evaluation or combined structure-function tools.



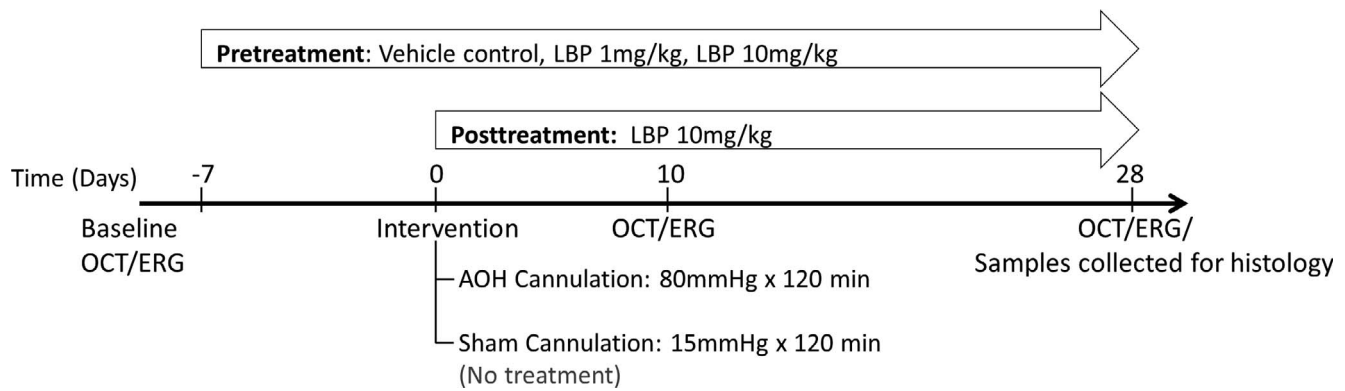


FIGURE 1. Schematic diagram showing the experimental study design. Following baseline OCT and ERG measurements, animals underwent either sham (15 mm Hg for 120 minutes) or AOH cannulation (80 mm Hg for 120 minutes). AOH animals were either pretreated (–7 to 28 days) with phosphate-buffered saline (vehicle control), LBP 1 mg/kg, or LBP 10 mg/kg or posttreated (0–28 days) with LBP 10 mg/kg. ERG and OCT measurements were repeated on postcannulation days 10 and 28, after which histologic analyses were performed.

Recently, there is an increasing trend of adopting bed- to bench-side techniques in preclinical research for longitudinal structural and functional assessment. Optical coherence tomography (OCT) has been reliably applied in small animals to study and longitudinally quantify retinal structure.^{30–32} Also, variations of electroretinogram (ERG) protocols have been tested to differentially measure the inner and outer retinal response in rodent experimental models.^{32–34} Importantly, the posttreatment efficacy of any neuroprotective drug should be explored at the level of preclinical research to simulate the conditions of clinical research in which the drug would be trialed in an established disease condition with varying severity. Consideration of studies using LBP revealed that its use appears to preserve the RGC in both IOP-dependent^{22,29} and IOP-independent optic neuropathy^{27,28} rodent models under pretreatment conditions. However, there are no reports on posttreatment efficacy of LBP incorporating the combined structure–function tools to longitudinally assess its neuroprotective effects in animal models of optic neuropathies. In view of these limitations, an AOH rat model was considered in this study to investigate the longitudinal neuroprotective efficacy of LBP using combined structural OCT and functional ERG measurements under pre- and posttreatment conditions.

METHODS

Animals

Adult female Sprague-Dawley (SD) rats were housed at room temperature (20°C) under normal lighting conditions (approximately 200 lux) with an alternating light/dark cycle (12 hours light/12 hours dark). Both food (PicoLab diet 20 (5053); PMI Nutrition International, Richmond, IN, USA) and water were supplied ad libitum. All experimental procedures and care involving the animals adhered to the ARVO Statement for the Use of Animals in Ophthalmic and Vision Research. The study was approved by the Animal Ethics Sub-committee of The Hong Kong Polytechnic University.

Experimental Design

Sixty 10-week-old rats (180–200 g) were randomly allocated into five experimental groups: (A) AOH vehicle control, pretreatment with phosphate-buffered saline (PBS); (B) AOH pretreatment with LBP 1 mg/kg; (C) AOH pretreatment with LBP 10 mg/kg; (D) AOH posttreatment with LBP 10 mg/kg; and

(E) sham control (Fig. 1). For pretreatment groups, animals were fed with LBP or PBS once daily, from 7 days prior to the AOH insult until the end of the study period at postcannulation day 28. For the posttreatment group, LBP feeding was initiated 6 hours after the AOH insult and continued until the end of the study period at day 28. All experimental groups underwent structural OCT and functional ERG measurements at baseline and postcannulation day 10 and day 28. Rats were killed at day 28 by inhalation of CO₂ and retinal sections were collected for morphologic examination.

Induction of Acute Ocular Hypertensions

Animals were anesthetized with a mixture of 60 mg/kg ketamine 10% (Alfasan International B.V., Woerden, Holland) and 5 mg/kg xylazine 2% (Alfasan International B.V.) via intraperitoneal injection. The anesthesia was maintained for 120 minutes by injecting half the initial dosage every 45 minutes via the same route. The animal's body temperature under anesthesia was maintained using a heating mat. Following the application of a drop of topical anesthetic (Provain-POS 0.5% wt/vol eye drops; URSAPHARM, Saarbrücken, Germany) and dilatation drops (Mydriacyl 1% eye drops; Alcon-Couvreur, Puurs, Belgium), the anterior chamber of one eye was cannulated using a 30-gauge needle attached to a tubing connected to a reservoir containing Gibco Hank's balanced salt solution (HBSS; Thermo-Fisher Scientific, Waltham, MA, USA) via a pressure transducer (60-3003; Harvard Apparatus, Holliston, MA, USA). The target IOP of either 15 mm Hg for the sham control group or 80 mm Hg for AOH groups for 120 minutes was achieved manometrically by adjusting the height of the reservoir (Fig. 2 shows representative pictures of anterior chamber cannulation and fundus photographs). The IOP was also monitored intermittently using the Tonolab Tonometer TV02 (Icare, Vantaa, Finland). To prevent corneal dehydration, Lacryvisc gel (Alcon, Rueil-Malmaison, France) was applied throughout the experimental period. Following the 120-minute AOH period, the pressure in the reservoir was gradually lowered to the IOP of 15 mm Hg and the needle was gently removed. The eyes were then treated with topical antibiotic eye drops (gentamycin; Gibco, Thermo-Fisher Scientific). Approximately 15% of the animals developed complications, including lens puncture, corneal haze, and vitreous hemorrhage; these were excluded from the study.

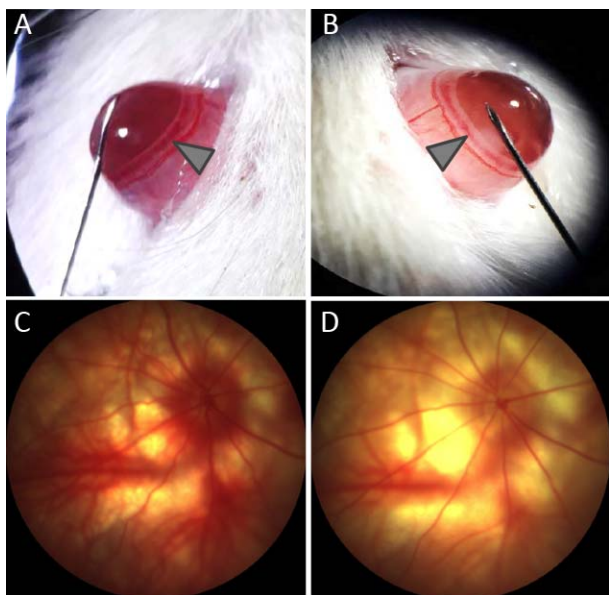


FIGURE 2. Anterior chamber of rats were cannulated with a 30-gauge needle (A, B), and fundus photographs (C, D) were captured immediately after sham (A, C) or AOH cannulation (B, D). When compared with sham, AOH cannulation showed distension of anterior chamber (due to fluid inflow), changes in iris color from pink to pale (arrows), and compromised retinal blood flow (D, pale appearance of fundus) and thinning of blood vessels.

Drug Administration

The process of extracting polysaccharides from *Lycium* fruits has been described in detail elsewhere.³⁵ The LBP (the polysaccharides of *Lycium barbarum*) solution was freshly prepared by dissolving the dried LBP powder in PBS. Animals that underwent sham cannulation received no feeding, whereas animals in the AOH cannulation groups were pre- or posttreated with PBS, 1 mg/kg LBP, or 10 mg/kg LBP solution once daily (between 10:30 and 11:30 AM) using a nasogastric feeding tube. The total treatment periods for pre- and posttreatments were 35 and 28 days, respectively.

Electroretinography

Electroretinal responses were measured using a full-field Ganzfeld (Q450; RETI Animal, Roland Consult, Brandenburg an der Havel, Germany). Animals were dark adapted overnight (>12 hours) prior to the ERG measurement. Preparation for ERG was done under dim red light to maintain the dark-adapted state of the animals. Following a similar anesthetic and

dilation regimen as for AOH induction, the animal was placed on a platform that was connected to a warm water bath to maintain the body temperature at around 37°C during the recording period. A drop of lubricating gel was applied on the corneal surface to prevent dehydration. The electrode placements for ERG recording were as follows: a pair of gold ring electrodes of 4 mm diameter (Roland Consult) placed on the corneal surface of both eyes serving as active electrodes; needle electrodes (Item No. U51-426; GVB-geliMED, Bad Segeberg, Germany) inserted into the lateral canthi of each eye to serve as references; needle electrode inserted into the base of the tail to serve as a ground electrode. An impedance of less than 10 KΩ active electrodes was maintained during the recording period.

White light-emitting diode (LED) light was chosen as source for flash stimuli. ERG responses were recorded for a subset of animals (n = 10) using flash intensities ranging from -5.7 to 1.5 log U (log U = log cd.s.m⁻²). The signals were recorded with bandpass filter ranging from 0.1 to 1000 Hz. Results from the subset of animals (Supplementary Fig. S1) showed that the positive scotopic threshold response (pSTR) was observed around -4.2 log U. Also, the maximum a- and b-wave responses were obtained from 1.5 log U. Subsequently, the experimental animals underwent STR recording from flash stimuli -4.8 to -4.05 log U followed by scotopic responses using 1.5 log U. The amplitudes and implicit time of pSTR and scotopic a- and b-wave responses were considered for the analysis.

Optical Coherence Tomography

Cross sections of the retina were imaged using a spectral-domain OCT (Micron IV; Phoenix Research Lab, Pleasanton, CA, USA). A circular B-scan with a radius of 0.51 mm, consisting of 1024 A-scans with axial and transverse resolution of 1.8 and 3.0 μm, was used to image the peripapillary retinal thickness (Fig. 3A). Following a similar anesthetic and dilation regimen, lubricating gel was applied on the corneal surface to improve the contact between the animal eye and objective lens. The B-scan image obtained was then analyzed using a semiautomated segmentation algorithm (Insight software, Phoenix Research Lab). The measurements of nerve fiber layer thickness (RNFLT), inner retinal layer thickness (IRLT), and outer retinal layer thickness (ORLT) were included in the analysis (Fig. 3B). IRLT was the sum of inner plexiform layer (IPL) and inner nuclear layer thickness (INL); ORLT was measured from outer plexiform layer to RPE. Mean thickness of each layer was determined by averaging data points (1024) that covered the circumference of the circle. During follow-up examinations, a circle scan was placed in close proximity to the baseline measurement by referring back to the baseline fundus image.

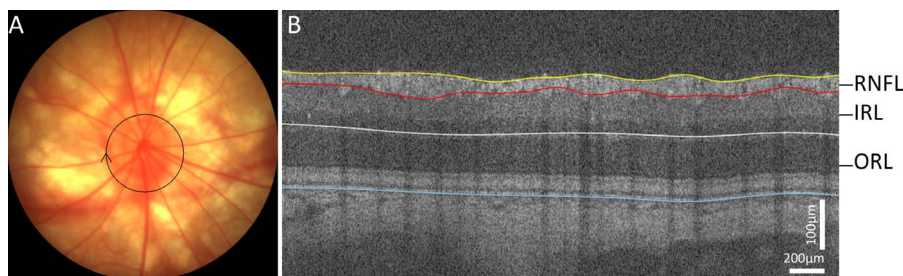


FIGURE 3. (A) Fundus image of a rat captured during OCT imaging, also showing the position of the peripapillary scan (radius 510 μm) indicated using black circle. (B) B-scan image of a circular scan showing the segmentation of retinal layers: RPE (blue), inner border of outer plexiform layer (white), outer border of RNFL (red) and inner limiting membrane (yellow). Thickness of the segmented layers, including the retinal nerve fiber layer (RNFL), inner retinal layer (IRL), and outer retinal layer (ORL), were analyzed.

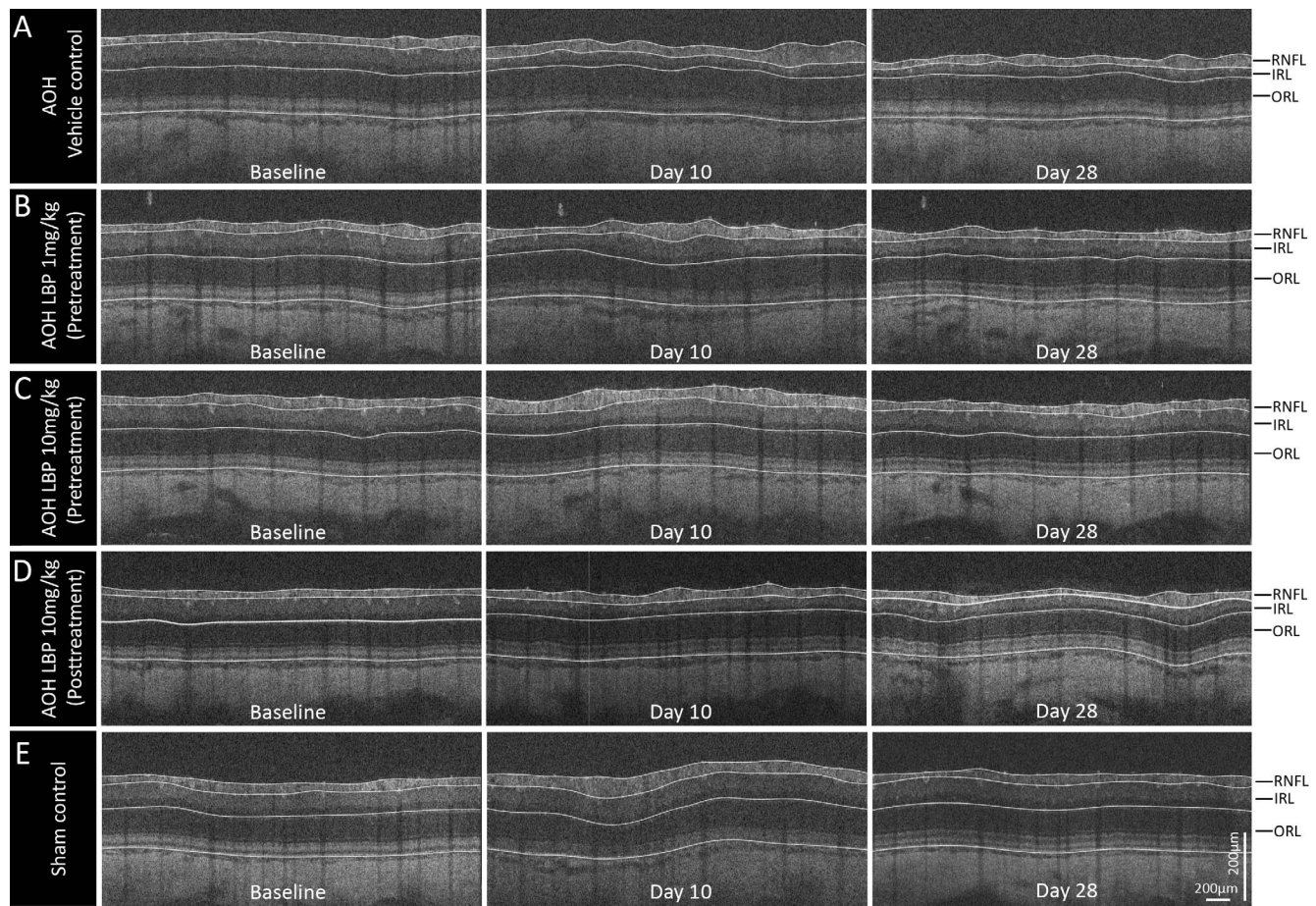


FIGURE 4. Segmented SD-OCT B scan images of one representative rat from each experimental group (A–E), imaged at baseline (*left*) and postcannulation days 10 (*center*) and 28 (*right*). (A–C) While the IRLT in vehicle control (A) showed a progressive thinning, rats pretreated with LBP 1 mg/kg (B) and LBP 10 mg/kg (C) showed a dose-dependent preservation up through day 28. (D) Posttreatment with LBP 10 mg/kg showed IRL thinning up through day 10, but it arrested subsequent thinning (secondary degeneration) from days 10 to 28. (E) Sham control remained similar throughout the study. The RNFL in all the groups showed a transient thickening up through day 10 and later recovered to baseline level at day 28. No obvious changes were observed in the ORL of all groups up through day 28.

Retinal Histology

After OCT and ERG measurements on day 28, the animals were euthanized by CO₂ asphyxiation. The eyes were enucleated and the eye cups were collected after removing the cornea and the lens. Eye cups were fixed in 4% paraformaldehyde in PBS at room temperature overnight before paraffin embedding. Sagittal sections of 5 µm parallel to the optic nerve were collected using a microtome and stained using hematoxylin and eosin (H&E). Sections were imaged using a light microscope at ×200 magnification (Nikon, Tokyo, Japan). Approximately 250 µm away from the scleral canal opening, regions of 500 × 500 µm of central retina were selected for morphologic analysis. Cells in the retinal ganglion layer of the selected regions were counted and the corresponding retinal length was measured using ImageJ (National Institutes of Health, Bethesda, MD, USA) for the calculation of ganglion cell layer (GCL) density/mm in retina.

Data Analysis

The data collection and quantification were performed and analyzed as blind. The results were normally distributed and are presented as means with SEM. All analysis was performed using SPSS 23.0 (IBM Corp., Armonk, NY, USA). The significance level was set at 0.05. Mixed-model ANOVA was

applied to test the difference in ERG parameters (amplitudes and implicit time) and OCT measured retinal thickness between the five groups and also within the groups measured over three time points with Bonferroni post hoc correction. Also, the retinal thicknesses are presented as percentage change from baseline.

RESULTS

Optical Coherence Tomography

Figure 4 presents typical peripapillary SD OCT B-scans of a rat from each experimental group, showing the longitudinal changes in RNFL, IRLT, and ORLT from baseline to postcannulation days 10 and 28. The thickness of RNFL, IRL, and ORL of the five cohorts measured at three points (baseline, postcannulation days 10 and 28) is given in Table 1. On differential OCT thickness analysis, the IRLT showed a significant difference among the treatment groups measured over time (mixed ANOVA: interaction: $P = 0.01$). Figure 5A shows the temporal changes in IRLT between the treatment groups, presented as mean percentage change in thickness from baseline. While the sham control showed a transient thickening of IRL at day 10 ($13.6 \pm 4\%$, $P > 0.05$, relative to baseline), the AOH vehicle control showed a significant thinning on both

TABLE 1. Differential OCT Thickness of the Experimental Groups Measured at Baseline and Postcannulation Days 10 and 28

Experimental groups, <i>N</i>	AoH-Vehicle Control, Pretreated, <i>n</i> = 9	AoH-LBP 1 mg/kg, Pretreated, <i>n</i> = 8	AoH-LBP 10 mg/kg, Pretreated, <i>n</i> = 13	AoH-LBP 10 mg/kg, Posttreated, <i>n</i> = 8	Sham Control, <i>n</i> = 6
IRLT, mean (SEM), μm					
Baseline	73.0 (1.4)	72.4 (0.8)	71.0 (0.9)	73.3 (1.6)	71.3 (1.8)
Day 10	47.2 (8.8)*‡	60.9 (8.0)	69.1 (5.1)	47.2 (5.2)*‡	81.1 (4.2)
Day 28	37.0 (8.1)*†‡§	55.7 (7.5)†	62.9 (5.7)†	43.3 (5.3)*	73.0 (2.0)
RNFLT, mean (SEM), μm					
Baseline	25.3 (1.0)	27.2 (1.3)	28.4 (0.9)	23.9 (1.5)	28.3 (0.7)
Day 10	37.1 (2.5)*	40.0 (2.2)*	42.9 (1.6)*	33.4 (4.5)*	37.7 (4.4)*
Day 28	29.6 (3.3)†	30.4 (2.0)†	33.8 (2.2)†	26.3 (3.0)†	27.4 (1.1)†
ORLT, mean (SEM), μm					
Baseline	125.5 (2.0)	122.3 (1.8)	123.7 (1.1)	120.4 (1.6)	119.4 (3.3)
Day 10	139.4 (3.0)*‡	131.7 (2.2)*	136.8 (2.2)*‡	132.9 (2.4)*	123.1 (3.3)
Day 28	126.8 (4.8)†	128.6 (4.2)	127.4 (1.4)†	121.8 (2.1)†	121.6 (2.4)

* $P < 0.001$ when compared to baseline.

† $P < 0.01$ when compared to day 10.

‡ $P < 0.05$ when compared to sham control.

§ $P < 0.05$ when compared to AOH pretreatment with 10 mg/kg LBP, Bonferroni post hoc test of mixed-model ANOVA.

day 10 ($-35.8 \pm 11.4\%$, $P = 0.001$, relative to baseline) and day 28 ($-49.7 \pm 10.7\%$, $P = 0.001$, relative to day 10 and baseline).

Under pretreatment conditions, both dosages of LBP (1 mg/kg, 10 mg/kg) slowed down the rate of IRL thinning on both day 10 and day 28, but at different rates. The LBP pretreatment of 10 mg/kg showed no significant change in thickness at day 10 ($-2.6 \pm 7.2\%$, $P > 0.05$, relative to baseline), whereas LBP 1 mg/kg showed a trend of thinning at day 10 ($-15.9 \pm 11.2\%$, $P = 0.27$, relative to baseline). On day 28, the rates of IRL thinning in pretreatment with LBP 1 and 10 mg/kg were $-23.0 \pm 10.5\%$ ($P = 0.04$, relative to day 10; $P = 0.05$, relative to baseline) and $-11.3 \pm 8.1\%$ ($P = 0.001$, relative to day 10; $P > 0.05$, relative to baseline) as compared to vehicle control ($-49.7 \pm 10.7\%$).

Under posttreatment condition of LBP 10 mg/kg, there was a significant thinning of IRL at day 10 ($-34.6 \pm 7.9\%$, $P = 0.001$, relative to baseline) that was comparable to the vehicle control. However, the rate of thinning slowed down from days 10 to 28 ($-39.8 \pm 8.0\%$, $P = 0.15$, relative to day 10), while this was still progressive in the vehicle control group ($P = 0.001$). On pairwise comparison, the thickness of vehicle control was significantly reduced compared to sham control (day 10: $P = 0.04$; day 28: $P = 0.02$) and pretreatment LBP 10 mg/kg (day 28: $P = 0.05$); the thickness with posttreatment with LBP 10 mg/kg was significantly less than in the sham control (day 10: $P = 0.02$; day 28: $P = 0.07$).

The effects of cannulation on RNFLT and ORLT of the five experimental groups, presented as percentage change from baseline, are shown in Figures 5B and 5C. Irrespective of sham or AOH cannulation under different treatment conditions, the RNFL (Fig. 5B) showed a transient thickening (ranging from 34% to 51% from baseline) at day 10 (mixed ANOVA: time effect: $P = 0.001$; between groups: $P = 0.07$; interaction effect: $P = 0.82$). While the sham control showed a complete recovery to baseline thickness on day 28, there was a residual RNFL thickening present in the other four AOH cannulated groups. However, this was not significantly different from their respective baselines or between groups. The ORLT (Fig. 5C) showed a significant change within the groups measured over time and a significant difference between groups at day 10 (mixed ANOVA: time: $P = 0.001$; between groups: $P = 0.02$; interaction effect: $P = 0.24$). The sham control showed a small, but nonsignificant thickening of ORL on both days 10 and 28, and the rest of the AOH groups showed a significant thickening at day 10 ($P = 0.001$) that recovered to baseline at day 28. Significant difference in thickness between groups was noted

only at day 10 ($P = 0.01$), with post hoc analysis showing increased thickness in vehicle control ($P = 0.01$) and pretreatment with LBP 10 mg ($P = 0.01$) as compared with sham control. However, there was no significant difference in ORLT between the pre- and posttreatment groups and also their respective baselines at day 28.

Electroretinography

Table 2 summarizes the parameters in the ERG measurements, namely, pSTR, scotopic b-wave, and a-wave amplitudes obtained from the five experimental groups at baseline, postcannulation days 10 and 28. The amplitudes of pSTR showed a significant difference among groups receiving different treatments (mixed ANOVA: time: $P = 0.06$; between groups: $P = 0.01$; interaction effect: $P = 0.15$). The pSTR traces of representative rats are displayed in Figure 6. The pSTR responses of the sham group remained stable over the study period, but the vehicle control group showed a reduction at day 10 that dropped significantly at day 28 ($P < 0.05$, relative to baseline). Under pretreatment conditions, both the LBP dosages (1 and 10 mg/kg) showed a preservation of pSTR responses on both days 10 and 28, which was comparable with their respective baselines and the sham control. Under the posttreatment condition of LBP 10 mg/kg, the pSTR responses showed an initial reduction at day 10 ($P < 0.05$, relative to baseline), which improved subsequently at day 28, showing no difference from its baseline. On pairwise comparison, the amplitude of vehicle control was reduced significantly compared with the sham control (day 10: $P = 0.02$; day 28: $P = 0.03$) and pretreatment LBP 1 mg/kg (day 28: $P = 0.05$). There was no difference in functional rescue effects between the two LBP dosages (1 and 10 mg/kg) studied under pretreatment conditions.

Scotopic ERG traces from one representative rat of each experimental group measured at baseline and postcannulation days 10 and 28 are shown in Figure 6. The a-wave responses (Table 2) remained similar across groups over the course of the study period (mixed ANOVA: time: $P = 0.75$; between groups: $P = 0.53$; interaction effect: $P = 0.33$). The amplitudes of b-wave (Table 2) showed a significant difference among the groups (mixed ANOVA: time: $P = 0.06$; between groups: $P = 0.001$; interaction effect: $P = 0.10$). On pairwise comparison, the responses of the vehicle control dropped significantly as compared to sham control (day 10: $P = 0.02$; day 28: $P = 0.04$) and pretreatment LBP 10 mg/kg (day 10, $P = 0.03$) groups. The

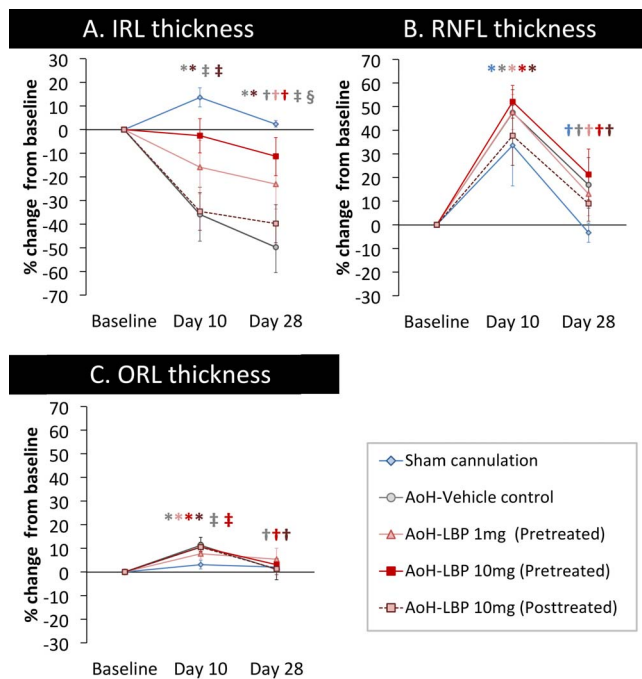


FIGURE 5. Mean peripapillary retinal thicknesses, namely, (A) IRLT, (B) RNFLT, and (C) ORLT were compared between the five experimental groups from baseline to postcannulation day 28. The data are presented as percentage change from baseline. Error bars: standard error of mean. * $P < 0.001$ versus baseline; † $P < 0.01$ versus day 10; ‡ $P < 0.05$ versus sham control; § $P < 0.05$ versus AOH pretreatment LBP 10 mg/kg (*†‡§Bonferroni post hoc test of mixed-model ANOVA).

amplitudes of posttreatment 10 mg/kg LBP were significantly lower than the pretreatment LBP 10 mg/kg at day 10 ($P = 0.03$), but gradually improved on day 28, showing no differences. There was no significant difference in functional rescue effect between the two pretreatment LBP dosages (1 and 10 mg/kg) and also between the pre- and posttreatment LBP conditions.

Table 3 provides the implicit time of pSTR, b-wave, and a-wave responses of the five experimental cohorts measured at baseline, postcannulation days 10 and 28. The implicit time of

pSTR showed an insignificant trend of delayed response ($P > 0.05$) in vehicle control and posttreated LBP 10 mg/kg on day 28 as compared to sham control or both pretreated LBP groups (mixed ANOVA: time: $P = 0.23$; between groups: $P = 0.06$; interaction effect: $P = 0.83$). The b-wave implicit time showed a significant time effect (mixed ANOVA: time: $P = 0.01$; between groups: $P = 0.81$; interaction effect: $P = 0.87$) that was found to be delayed at day 10 as compared to baseline recordings, with no difference on day 28. The a-wave implicit time showed a significant interaction effect ($P = 0.02$), which on pairwise comparison showed a delay in response in posttreated LBP 10 mg/kg on day 28 (8.6 ms, $P = 0.01$, relative to baseline of 7.9 ms). In general, the implicit time of all ERG parameters did not show any significant changes due to the AOH or under different LBP treatment conditions.

Histology

Figure 7A shows a representative histologic cross section from each experimental group collected at postcannulation day 28. The mean GCL density (cells/mm, mean \pm SEM), presented in Figure 7B, showed a significant difference between groups ($P < 0.001$, ANOVA). On pairwise comparison, the GCL density was significantly reduced in the vehicle control ($P < 0.001$) as compared to sham cannulation, pretreatment LBP 1 mg/kg, pretreatment 10 mg/kg, and posttreatment 10 mg/kg AOH groups. There was no difference in GCL density between sham and pre- and post-LBP-treated AOH groups.

DISCUSSION

The present study is the first to investigate the posttreatment efficacy of LBP on a model of optic neuropathy, while other studies have shown the pretreatment outcome of LBP.^{26,29} In addition, the study reports the longitudinal in vivo neuroprotective effect of LBP using combined structure-function approaches in an AOH rat model.

On longitudinal structural evaluation, AOH rats (80 mm Hg for 120 minutes) showed a progressive thinning of the inner retina with no drastic changes to the outer retinal thickness. On differential analysis of the inner retina into RNFL and IRL (IPL+INL), the IRL showed a progressive thinning. The RNFL showing a transient thickening (at day

TABLE 2. Amplitudes of pSTR, Scotopic b- and a-Wave Responses of the Experimental Groups Measured at Baseline and Postcannulation Days 10 and 28

Experimental Groups, N	AoH-Vehicle Control, Pretreated, n = 9	AoH-LBP 1 mg/kg, Pretreated, n = 8	AoH-LBP 10 mg/kg, Pretreated, n = 13	AoH-LBP 10 mg/kg, Posttreated, n = 8	Sham Control, n = 6
pSTR, mean (SEM), μ V					
Baseline	14.7 (2.7)	14.9 (2.7)	16.3 (2.1)	19.4 (2.3)	15.1 (2.4)
Day 10	6.4 (1.9)‡	11.8 (2.6)	14.4 (2.7)	9.3 (2.4)*	20.3 (3.0)
Day 28	6.7 (1.5)*‡	15.4 (2.6)	13.8 (2.0)	13.9 (1.8)	17.0 (2.4)
b-wave, mean (SEM), μ V					
Baseline	580.3 (82.6)	559.5 (78.0)	632.2 (57.6)	640.3 (96.0)	704.2 (132.3)
Day 10	266.8 (45.8)*‡§	541.0 (125.7)	719.5 (79.6)	355.9 (66.4)§	726.3 (112.1)
Day 28	313.7 (87.9)‡	548.3 (102.1)	540.7 (64.0)†	448.0 (64.0)	712.5 (103.6)
a-wave, mean (SEM), μ V					
Baseline	-257.3 (36.6)	-247.8 (25.4)	-260.0 (22.4)	-273.5 (40.5)	-280.5 (44.8)
Day 10	-237.3 (37.7)	-297.5 (40.9)	-334.9 (26.6)	-235.0 (31.1)	-269.1 (52.8)
Day 28	-212.9 (33.9)	-281.8 (32.4)	-244.5 (25.9)†	-276.6 (26.5)	-292.8 (25.5)

* $P < 0.001$ when compared to baseline.

† $P < 0.01$ when compared to day 10.

‡ $P < 0.05$ when compared to sham control.

§ $P < 0.05$ when compared to AOH pretreatment with 10 mg/kg LBP.

|| $P < 0.05$ when compared to AOH pretreatment with 1 mg/kg LBP, Bonferroni post hoc test of mixed-model ANOVA.

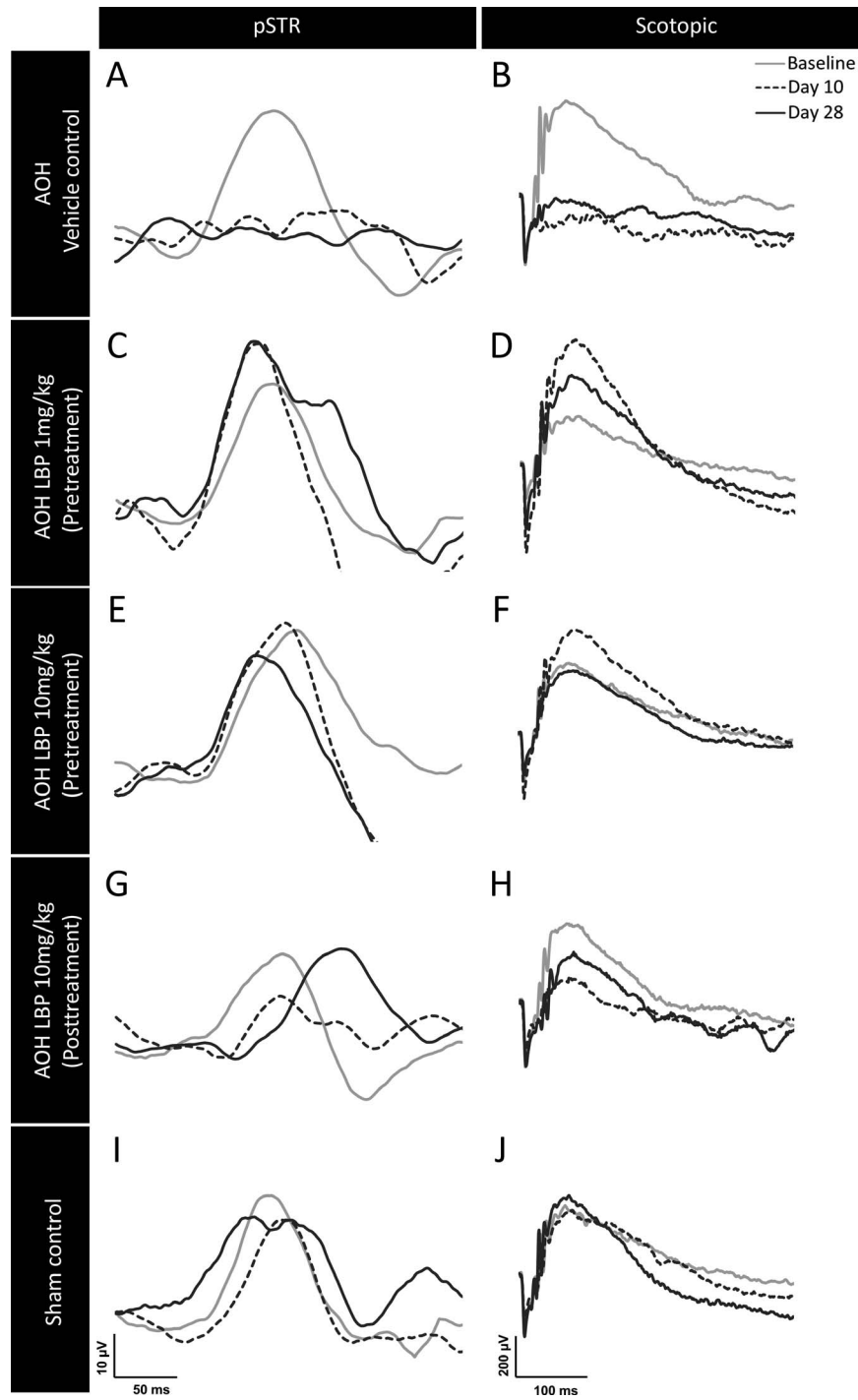


FIGURE 6. Traces of pSTR and scotopic responses of one representative rat from each experimental group measured at baseline (*solid gray trace*) and postcannulation days 10 (*dotted black trace*) and 28 (*solid black trace*). (A–F) The pSTR (A) and scotopic (B) responses were reduced in vehicle control, whereas rats pretreated with LBP 1 mg/kg (C, D) or LBP 10 mg/kg (E, F) showed preservation up through day 28. (G, H) The rats posttreated with LBP 10 mg/kg showed an initial reduction in responses at day 10 (*dotted lines*), then an improvement up through day 28 with a delay in implicit time (*solid black lines*). (I, J) The sham control responses remained stable up through day 28.

10) in both AOH and sham-cannulated rats suggests that this transitory effect is due to the inflammatory response triggered by the cannulation procedure itself.^{36,37} However, the GCL density in AOH rats shows a ~70% reduction in numbers. Complementing the structural changes, the functional measurement of RGC (in terms of pSTR) and bipolar cell (in terms of scotopic b-wave) responses also showed a

reduction (~50%) with little or no recovery at week 4. The a-wave response, which is related to the outer retinal layer, remained grossly normal. The observation of differential dysfunction of inner and outer retinal responses with a poor recovery of inner retinal component (pSTR) in the present study is in agreement with the findings of Bui et al.^{33,38} Those authors also reported a partial recovery of pSTR from IOP

TABLE 3. Implicit Time of pSTR, Scotopic b- and a-Wave Responses of the Experimental Groups Measured at Baseline and Postcannulation Days 10 and 28

Experimental Groups, N	AoH-Vehicle Control, Pretreated, n = 9	AoH-LBP 1 mg/kg, Pretreated, n = 8	AoH-LBP 10 mg/kg, Pretreated, n = 13	AoH-LBP 10 mg/kg, Posttreated, n = 8	Sham Control, n = 6
pSTR, mean (SEM), ms					
Baseline	113.9 (4.2)	118.3 (4.5)	113.7 (3.5)	122.5 (4.5)	121.0 (5.2)
Day 10	122.8 (4.9)	118.7 (5.2)	114.5 (4.1)	124.1 (5.2)	115.8 (6.0)
Day 28	127.3 (4.4)	119.9 (3.7)	119.5 (4.7)	131.4 (4.7)	116.4 (5.4)
b-wave, mean (SEM), ms					
Baseline	68.2 (3.2)	75.7 (3.4)	73.2 (2.7)	72.7 (3.4)	75.1 (3.9)
Day 10	81.0 (4.8)	83.4 (5.1)	81.8 (4.0)	78.2 (5.1)	84.4 (5.9)
Day 28	78.5 (5.0)	74.5 (5.3)	73.7 (4.1)	80.6 (5.3)	81.9 (6.1)
a-wave, mean (SEM), ms					
Baseline	8.0 (0.1)	7.9 (0.1)	8.0 (0.1)	7.9 (0.1)	8.1 (0.1)
Day 10	8.3 (0.1)	8.0 (0.2)	8.1 (0.1)	7.8 (0.2)	8.2 (0.2)
Day 28	8.0 (0.2)	8.0 (0.2)	8.2 (0.1)	8.6 (0.2)*†	7.9 (0.2)

* $P < 0.001$ when compared to baseline.

† $P < 0.01$ when compared to day 10.

elevation of 70 mm Hg to no recovery if IOP peaked at 100 mm Hg for 105 minutes.

Under pretreatment conditions, both the LBP dosages (1 and 10 mg/kg LBP) delayed the onset and slowed down the rate of IRL thinning as well as preserving the inner retinal function. The percentage at which the LBP 1 mg/kg retained the inner retinal thickness at day 10 was comparable to results from another report on a mouse AOH model (90 mm Hg for 60 minutes) at day 7.²⁹ As the procedure of the cannulation alone was known to induce transient RNFL thickening,³⁹ the measurements including RNFL may overestimate the IRL thickness. Therefore, the present study further differentiated the IRL thickness into RNFL and IPL+INL to minimize the chance of overstating the protective effect of LBP. Further-

more, both LBP dosages equally preserved the GCL density in AOH rats to the level of sham cannulation at week 4. He et al.,²⁶ using the same rat strain (SD rats) as the present study, showed that pretreatment with LBP 1 mg/kg preserved only 50% of RGC in AOH rats (130 mm Hg for 60 minutes) compared with 30% RGC survival in the PBS-treated group at day 7. The direct comparison of the neuroprotective outcome between these studies has certain limitations. The differences in the selection of IOP, duration of AOH, methods of investigation, and time of assessment between the studies are likely to account for the differential rate of structural loss or various neuroprotective effects being reported. As the present study did not evaluate the rate of RGC loss at the end of week 1, the OCT-measured IRLT (sum of IPL and INL) has to be

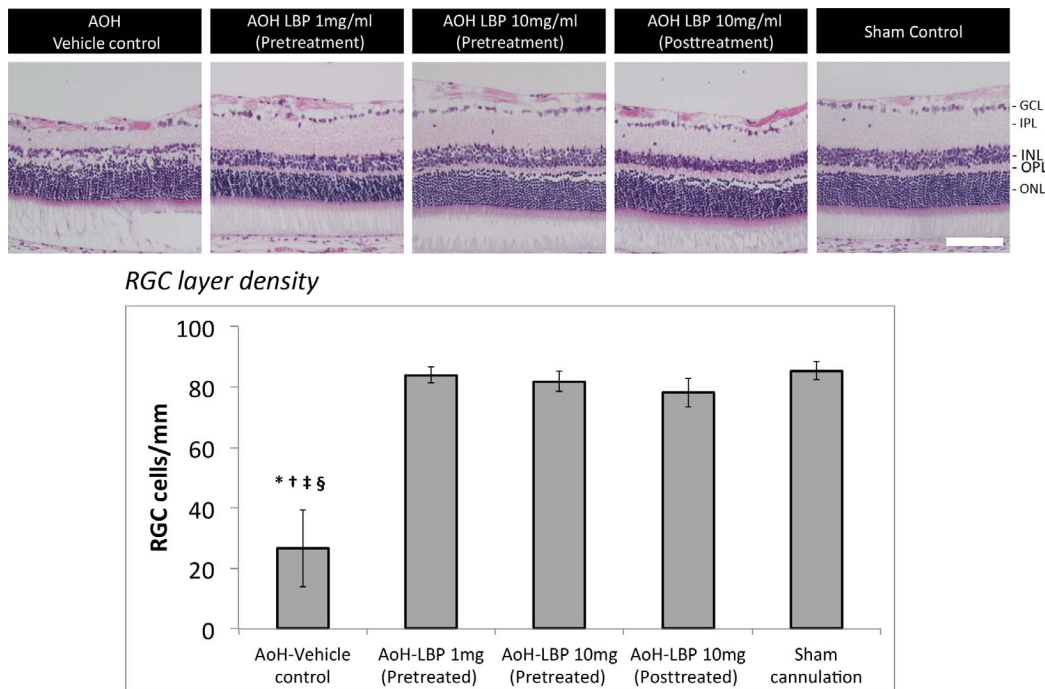


FIGURE 7. Morphologic rescue of LBP-treated rats. (A) Hematoxylin and eosin-stained retinal sections of one representative rat from each experimental group collected at the end of week 4. (B) Mean GCL density in these sections was quantified ($n = 6$). Error bars: standard error of mean. * $P < 0.001$ versus sham control; † $P < 0.001$ versus pretreatment LBP 1 mg/kg; ‡ $P < 0.001$ versus pretreatment LBP 10 mg/kg; § $P < 0.001$ versus posttreatment 10 mg/kg, Bonferroni post hoc test of 1-way ANOVA. OPL: outer plexiform layer, ONL: outer nuclear layer. Scale bar: 100 μ m.

approximated to the histology-based RGC data reported in the earlier study. Considering the chronological changes in the RGC following an AOH insult, dendrites are reported to be the first to undergo degeneration (around day 3), followed by axons and soma (around day 7) in an AOH mouse model (110 mm Hg for 90 minutes).⁴⁰ As the RGC dendrites are predominantly located in the IPL layer of the retina, where it synapses with the second-order neurons (bipolar cells), the OCT measurement of the inner retina (excluding RNFL) substantially comprised the IPL layer that can serve as a surrogate measure of RGC dendrites. Any loss in RGC dendrites will exhibit as thinning of IPL that eventually leads to axonal and soma loss. The present study shows that under pretreatment conditions, both the LBP dosages preserved the IPL, arrested the subsequent events, and retained the thickness of the layer and the GCL density. Though the pretreatment with LBP 10 mg/kg displayed a trend of better preservation of IRLT than that of 1 mg/kg, there was no difference in GCL density or functional rescue between the two dosages.

Distinct from the effect of pretreatment, posttreatment with LBP 10 mg/kg did not provide any evidence of structural preservation of IRL up through day 10. However, it subsequently slowed down the rate of progressive thinning of the inner retina from day 10 to day 28 and preserved the GCL density. In addition, both the pSTR and b-wave amplitudes that were reduced at day 10 improved at day 28. Previous longitudinal studies reported that neuronal loss in an AOH insult occurred as early as day 7 without obvious progressive damage,^{40,41} and the AOH vehicle control in the current study shows a trend of biphasic progressive thinning of inner retinal layers. There was a greater thinning of IRL (−36% from baseline) at day 10, followed by a slower progressive phase (−14% from day 10 to day 28). Considering IRL as a surrogate measure of RGC dendrites, progressive thinning of IRL likely indicates that the dendrites underwent continued degeneration and this is progressive in nature. Selles-Navarro and colleagues⁴² also reported a progressive reduction in RGC following an AOH insult (110 mm Hg for >60 minutes); ~50% loss of RGC on day 10 followed by additional ~45% loss occurred gradually up to day 30. Although posttreatment could not prevent or slow down the initial phase of degeneration, it evidently reduced the second phase of degeneration (IRL thinning from day 10 to day 28), maintained GCL density, and improved function in terms of ERG response amplitude.

Furthermore, there is no difference in GCL density between the pre- and posttreatment with LBP, despite a marked decrease in IRL in the posttreatment condition. As discussed earlier, RGC undergoes compartmentalized degeneration following an AOH insult in a particular sequence with dendritic shrinkage followed by dendritic, axonal, and soma loss.⁴⁰ The period during which each compartmentalized degeneration of RGC lasts can vary according to the peak IOP selection and duration of elevation, which may account for the difference in the rate of neuronal loss between studies. As there is a layover between the dendritic to soma loss, the time of treatment intervention may alter each phase of neuronal loss. In the case of pretreatment, LBP fed from 7 days prior to insult could limit the initial cascade of events by preserving the IRL and GCL density, whereas in posttreatment, LBP was initiated on the same day 6 hours after AOH insult. This duration was selected to allow animals a maximum recovery time from general anesthesia prior to oral gavage in order to avoid the risk of aspiration pneumonia. The results indicate that the posttreatment with LBP could not arrest the initial cascade of events resulting in dendritic shrinkage and loss. However, it could diminish the effects of later cascade of events arresting the secondary degeneration and preserving the GCL density, to an extent that was quite comparable to pretreatment with LBP. It

should be noted that the cell count computed from the H&E-stained GCL layer contains a comparable number of RGC and displaced amacrine cells.^{43,44} Sun et al.⁴⁵ showed that ~65% of H&E-stained cells were identified as RGC (immunostained with gamma synuclein) in both normal and optic nerve-crushed eyes of SD rats. Furthermore, both types of staining were able to reflect a similar percentage of RGC loss (~50%) following the insult (day 14), which approximated the RGC loss (~65%) quantified using anterograde tracer cholera toxin subunit B. Although the present study did not use any specific biomarkers for RGC labeling, we speculated that the pre- and posttreatments were able to achieve effective RGC rescue, as the GCL densities of sham and LBP-treated rats were similar.

An initial study investigating the dose response regarding LBP under pretreatment conditions, using an ocular hypertension rat model (induced by laser photocoagulation), revealed that 1 and 10 mg/kg LBP offered similar therapeutic effects.²² Later studies applied LBP 1 mg/kg to test the neuroprotective effects using variants of optic neuropathy.^{23–29} However, another study concluded that pretreatment with LBP 10 mg/kg offered relatively better neuroprotective effects than 1 mg/kg in an experimental stroke model.¹³ Thus, in this study, a dosage of LBP 10 mg/kg was chosen to investigate the neuroprotective effects under pre- and posttreatment conditions using combined structure–function tools as compared to the more commonly trialed dosage of pretreatment LBP 1 mg/kg. As the results could show the neuronal rescue effect of LBP under posttreatment condition, future studies should explore the dose response with LBP introduced at later time points (or) at different stages of the disease condition.

Previous studies have reported that LBP pretreatment in an AOH model activated the Nrf2/HO-1 antioxidant pathway by upregulation of nuclear factor erythroid 2-related factor (Nrf2) and heme oxygenase-1 (HO-1) expression to combat the effects of oxidative stress.²⁶ LBP also protected the retinal vasculature by downregulating the expression of endothelin-1, advanced glycation end products (AGE), receptor of AGE, and amyloid- β protein, thus maintaining the integrity of the blood-retinal barrier.²⁹ As the mechanism of neuroprotection in the posttreatment period may differ from that in pretreatment, further investigation of these processes is needed. Knowledge of the possible mechanisms of neuroprotection and evidence of the beneficial effects of pre- and posttreatments suggest that LBP can be a potential neuroprotective drug in similar cohorts. AOH models closely simulate the clinical conditions of acute angle closure glaucoma and other ischemic retinal conditions, such as retinal vein occlusion. In view of favorable results for posttreatment outcome, that is, slowing down secondary degeneration and improving the retinal function, LBP may be a prospective treatment option for patients with the above diseases.

While LBP therapy showed promising outcomes in preclinical animal trials, its effect on patients with ocular diseases remained largely unknown. Recently, a double-masked clinical trial showed that daily supplements of *Lycium barbarum* over 12 months in retinitis pigmentosa patients preserved macular thickness and visual acuity, thus exhibiting a cone rescue effect.⁴⁶ Even before any clinical study could be planned to test the neuroprotective effect of LBP on glaucoma patients, extensive preclinical studies are warranted to investigate the therapeutic efficacy of LBP posttreatments in experimental models of chronic glaucoma, with and without an IOP-lowering effect.

In summary, the present study differentiates the posttreatment efficacy of LBP from pretreatment outcomes using an AOH rat model. Under pretreatment conditions, the structural and functional rescue effects observed earlier in the course of study resulted in longitudinal preservation. In contrast, the

rescue effect with posttreatment was not evident initially; it subsequently slowed down secondary degeneration along with the improvement in function. Although pretreatment with LBP offers relatively better neuroprotection, the beneficial effect of posttreatment is still remarkable as compared with the untreated condition.

Acknowledgments

The authors thank Ricky Wing Kei WU, School of Medical and Health Sciences, Tung Wah College, Hong Kong, for making their laboratory facilities available for performing the histologic procedures. The authors also thank the University Research Facilities in Behavioral and Systems Neuroscience (UBSN) and in Life Sciences (ULS), The Hong Kong Polytechnic University, for technical and facility support.

Supported by the General Research Fund (PolyU 5605/13M, 151001/17M) from Research Grants Council, HKSAR, Central Research Grant (for Research Student), and Internal Research Grants (G-YBGC, Z0GF) from The Hong Kong Polytechnic University.

Disclosure: **Y. Lakshmanan**, None; **F.S.-Y. Wong**, None; **W.-Y. Yu**, None; **S.Z.-C. Li**, None; **K.-Y. Choi**, None; **K.-F. So**, None; **H.H.-L. Chan**, None

References

- Schwartz M. Lessons for glaucoma from other neurodegenerative diseases: can one treatment suit them all? *J Glaucoma*. 2005;14:321-323.
- Gupta N, Yücel YH. Glaucoma as a neurodegenerative disease. *Curr Opin Ophthalmol*. 2007;18:110-114.
- Mozaffarieh M, Flammer J. Is there more to glaucoma treatment than lowering IOP? *Surv Ophthalmol*. 2007;52:S174-S179.
- Chidlow G, Wood JP, Casson RJ. Pharmacological neuroprotection for glaucoma. *Drugs*. 2007;67:725-759.
- Amagase H, Farnsworth NR. A review of botanical characteristics, phytochemistry, clinical relevance in efficacy and safety of Lycium barbarum fruit (Goji). *Food Res Int*. 2011;44:1702-1717.
- Tang T, He B. Treatment of d-galactose induced mouse aging with Lycium barbarum polysaccharides and its mechanism study. *Afr J Tradit Complement Altern Med*. 2013;10:12-17.
- Li X, Ma Y, Liu X. Effect of the Lycium barbarum polysaccharides on age-related oxidative stress in aged mice. *J Ethnopharmacol*. 2007;111:504-511.
- Zhao R, Cai Y, Shao X, Ma B. Improving the activity of Lycium barbarum polysaccharide on sub-health mice. *Food Funct*. 2015;6:2033-2040.
- Wu H, Guo H, Zhao R. Effect of Lycium barbarum polysaccharide on the improvement of antioxidant ability and DNA damage in NIDDM rats. *Yakugaku Zasshi*. 2006;126:365-371.
- Li X-M. Protective effect of Lycium barbarum polysaccharides on streptozotocin-induced oxidative stress in rats. *Int J Biol Macromol*. 2007;40:461-465.
- Niu A-J, Wu J-M, Yu D-H, Wang R. Protective effect of Lycium barbarum polysaccharides on oxidative damage in skeletal muscle of exhaustive exercise rats. *Int J Biol Macromol*. 2008;42:447-449.
- Cheng D, Kong H. The effect of Lycium barbarum polysaccharide on alcohol-induced oxidative stress in rats. *Molecules*. 2011;16:2542-2550.
- Yang D, Li S-Y, Yeung C-M, et al. Lycium barbarum extracts protect the brain from blood-brain barrier disruption and cerebral edema in experimental stroke. *PLoS One*. 2012;7:e33596.
- Chen W, Cheng X, Chen J, et al. Lycium barbarum polysaccharides prevent memory and neurogenesis impairments in scopolamine-treated rats. *PLoS One*. 2014;9:e88076.
- Cui B, Chen Y, Liu S, et al. Antitumor activity of Lycium chinensis polysaccharides in liver cancer rats. *Int J Biol Macromol*. 2012;51:314-318.
- Gan L, Zhang SH, Yang XL, Xu HB. Immunomodulation and antitumor activity by a polysaccharide-protein complex from Lycium barbarum. *Int Immunopharmacol*. 2004;4:563-569.
- Xiao J, Liong EC, Ching YP, et al. Lycium barbarum polysaccharides protect mice liver from carbon tetrachloride-induced oxidative stress and necroinflammation. *J Ethnopharmacol*. 2012;139:462-470.
- Hai-Yang G, Ping S, Li J, Chang-Hong X, Fu T. Therapeutic effects of Lycium barbarum polysaccharide (LBP) on mitomycin C (MMC)-induced myelosuppressive mice. *J Exp Ther Oncol*. 2004;4:181-187.
- Zhu J, Liu W, Yu J, et al. Characterization and hypoglycemic effect of a polysaccharide extracted from the fruit of Lycium barbarum L. *Carbohydr Polym*. 2013;98:8-16.
- Luo Q, Cai Y, Yan J, Sun M, Corke H. Hypoglycemic and hypolipidemic effects and antioxidant activity of fruit extracts from Lycium barbarum. *Life Sci*. 2004;76:137-149.
- Xin Y, Zhang S, Gu L, et al. Electrocardiographic and biochemical evidence for the cardioprotective effect of antioxidants in acute doxorubicin-induced cardiotoxicity in the beagle dogs. *Biol Pharm Bull*. 2011;34:1523-1526.
- Chan H-C, Chang RC-C, Ip AK-C, et al. Neuroprotective effects of Lycium barbarum Lynn on protecting retinal ganglion cells in an ocular hypertension model of glaucoma. *Exp Neurol*. 2007;203:269-273.
- Chiu K, Chan H-C, Yeung S-C, et al. Modulation of microglia by Wolfberry on the survival of retinal ganglion cells in a rat ocular hypertension model. *J Ocul Biol Dis Infor*. 2009;2:47-56.
- Chiu K, Zhou Y, Yeung SC, et al. Up-regulation of crystallins is involved in the neuroprotective effect of wolfberry on survival of retinal ganglion cells in rat ocular hypertension model. *J Cell Biochem*. 2010;110:311-320.
- Chu PH, Li H-Y, Chin M-P, So K-F, Chan HH. Effect of lycium barbarum (wolfberry) polysaccharides on preserving retinal function after partial optic nerve transection. *PLoS One*. 2013;8:e81339.
- He M, Pan H, Chang RC-C, So K-F, Brecha NC, Pu M. Activation of the Nrf2/HO-1 antioxidant pathway contributes to the protective effects of Lycium barbarum polysaccharides in the rodent retina after ischemia-reperfusion-induced damage. *PLoS One*. 2014;9:e84800.
- Li H, Liang Y, Chiu K, et al. Lycium barbarum (wolfberry) reduces secondary degeneration and oxidative stress, and inhibits JNK pathway in retina after partial optic nerve transection. *PLoS One*. 2013;8:e68881.
- Li S-Y, Yang D, Yeung C-M, et al. Lycium barbarum polysaccharides reduce neuronal damage, blood-retinal barrier disruption and oxidative stress in retinal ischemia/reperfusion injury. *PLoS One*. 2011;6:e16380.
- Mi X-S, Feng Q, Lo ACY, et al. Protection of retinal ganglion cells and retinal vasculature by Lycium barbarum polysaccharides in a mouse model of acute ocular hypertension. *PLoS One*. 2012;7:e45469.
- Nagata A, Higashide T, Ohkubo S, Takeda H, Sugiyama K. In vivo quantitative evaluation of the rat retinal nerve fiber layer with optical coherence tomography. *Invest Ophthalmol Vis Sci*. 2009;50:2809-2815.
- Lozano DC, Twa MD. Quantitative evaluation of factors influencing the repeatability of SD-OCT thickness measure-

- ments in the rat. *Invest Ophthalmol Vis Sci.* 2012;53:8378-8385.
32. Liu H-H, Bui BV, Nguyen CT, Kezic JM, Vingrys AJ, He Z. Chronic ocular hypertension induced by circumlimbal suture in rats. *Invest Ophthalmol Vis Sci.* 2015;56:2811-2820.
 33. Bui BV, Batcha AH, Fletcher E, Wong VH, Fortune B. Relationship between the magnitude of intraocular pressure during an episode of acute elevation and retinal damage four weeks later in rats. *PLoS One.* 2013;8:e70513.
 34. Bui BV, Fortune B. Ganglion cell contributions to the rat full-field electroretinogram. *J Physiol.* 2004;555:153-173.
 35. Yu M-S, Lai CS-W, Ho YS, et al. Characterization of the effects of anti-aging medicine *Fructus lycii* on β -amyloid peptide neurotoxicity. *Int J Mol Med.* 2007;20:261-268.
 36. Kezic JM, Chrysostomou V, Trounce IA, McMenamin PG, Crowston JG. Effect of anterior chamber cannulation and acute IOP elevation on retinal macrophages in the adult mouse. *Invest Ophthalmol Vis Sci.* 2013;54:3028-3036.
 37. Zhang J, Cole RN, Lin P, Acosta ML, Green C, Danesh-Meyer H. Transiently raised IOP equivalent to that experienced during ocular surgery causes moderate inflammation but does not affect retinal function or result in retinal ganglion cell loss in an animal model. *J Ophthalmol Sci.* 2017;1:36-50.
 38. Bui BV, Edmunds B, Cioffi GA, Fortune B. The gradient of retinal functional changes during acute intraocular pressure elevation. *Invest Ophthalmol Vis Sci.* 2005;46:202-213.
 39. Abbott CJ, Choe TE, Lusardi TA, Burgoyne CF, Wang L, Fortune B. Evaluation of retinal nerve fiber layer thickness and axonal transport 1 and 2 weeks after 8 hours of acute intraocular pressure elevation in rats. *Invest Ophthalmol Vis Sci.* 2014;55:674-687.
 40. Li Z-W, Liu S, Weinreb RN, et al. Tracking dendritic shrinkage of retinal ganglion cells after acute elevation of intraocular pressure. *Invest Ophthalmol Vis Sci.* 2011;52:7205-7212.
 41. Leung CK-S, Lindsey JD, Chen L, Liu Q, Weinreb RN. Longitudinal profile of retinal ganglion cell damage assessed with blue-light confocal scanning laser ophthalmoscopy after ischemic reperfusion injury. *Br J Ophthalmol.* 2009;93:964-968.
 42. Selles-Navarro I, Villegas-Perez MP, Salvador-Silva M, Ruiz-Gomez JM, Vidal-Sanz M. Retinal ganglion cell death after different transient periods of pressure-induced ischemia and survival intervals. A quantitative in vivo study. *Invest Ophthalmol Vis Sci.* 1996;37:2002-2014.
 43. Perry V, Walker M. Amacrine cells, displaced amacrine cells and interplexiform cells in the retina of the rat. *Proc R Soc Lond B Biol Sci.* 1980;208:415-431.
 44. Schlamp CL, Montgomery AD, Mac Nair CE, Schuart C, Willmer DJ, Nickells RW. Evaluation of the percentage of ganglion cells in the ganglion cell layer of the rodent retina. *Mol Vis.* 2013;19:1387.
 45. Sun JC, Xu T, Zuo Q, et al. Hydrogen-rich saline promotes survival of retinal ganglion cells in a rat model of optic nerve crush. *PLoS One.* 2014;9:e99299.
 46. HH-I, Chan Lam H-I, Choi K-Y, et al. Delay of cone degeneration in retinitis pigmentosa using a 12-month treatment with *Lycium barbarum* supplement. *J Ethnopharmacol.* 2019;236:336-344.