



Minerva Access is the Institutional Repository of The University of Melbourne

Author/s:
Heggie, AA

Title:
Craniofacial disorders

Date:
2018-03-01

Citation:
Heggie, A. A. (2018). Craniofacial disorders. Australian Dental Journal, 63 (S1), pp.S58-S68. <https://doi.org/10.1111/adj.12591>.

Persistent Link:
<https://hdl.handle.net/11343/283809>

Article Type: Supplement Article

Craniofacial Disorders

A Heggie*

*Professor, University of Melbourne

Department of Paediatrics

Address for correspondence

Professor Andrew Heggie

Department of Plastic & Maxillofacial Surgery

Royal Children's Hospital of Melbourne

3W Clinical Offices, 50 Flemington Road

Parkville 3052

Phone: +61 3 9654 4844

Email: aheggie@bigpond.net.au

Keywords

Abbreviations and Acronyms

FOA Fronto-orbital advancement

CPAP Continuous positive airway pressure

CFM Craniofacial microsomia

Abstract

The complexity of the craniofacial patient mandates the cooperation of a multidisciplinary team that can

This is the author manuscript accepted for publication and has undergone full peer review but has not been through the copyediting, typesetting, pagination and proofreading process, which may lead to differences between this version and the [Version of Record](#). Please cite this article as [doi: 10.1111/adj.12591](https://doi.org/10.1111/adj.12591)

This article is protected by copyright. All rights reserved

systematically evaluate each individual and ensure that a protocol-driven pathway is undertaken for the best patient care. Oral and maxillofacial surgeons contribute to surgical care in this setting with specific knowledge of growth and development of the face. This enables optimum timing for early skeletal correction where appropriate, and definitive surgery following the cessation of growth to maximize function and aesthetics. This chapter will describe the major principles in managing patients with specific craniofacial anomalies and provide examples of the outcomes possible.

Introduction

The sub-speciality of craniofacial surgery emerged from the 1970's when Paul Tessier demonstrated that full exposure of the fronto-orbital skeleton was possible via a coronal scalp flap, thus providing access for correction of severe craniofacial deformities ^{1, 2}. This approach ushered in a wide range of surgical options to manage congenital, developmental and acquired deformities of the cranium and upper face. Together with other evolving osteotomy techniques of the maxilla-mandibular complex, particularly developed by maxillofacial surgeons in Western Europe, huge advances in normalising major and minor facial deformities became possible ³. Over the following decades, further significant advances and refinements in surgical techniques occurred that

enable the comprehensive correction of many cranial deformities in the first 2 years of life ⁴.

✦ The rapid advances in our understanding of the genetic causation of many craniofacial disorders has enabled better classifications and the option of genetic testing with beneficial implications for family counselling ⁵. There is now a recognition that, while phenotypic descriptions of related craniofacial anomalies remain useful and current, many craniofacial anomalies belong on a spectrum of disorders that already are, or will be, better understood when genetically characterized.

Craniofacial Centres are now present in most major cities of the developed world. There is general agreement that multidisciplinary teams that are informed by audit, research and the input of all specialist skills, provide the best outcomes. While there is variation in the craft groups that makeup the surgical teams, most Units comprise of plastic surgeons and/or maxillofacial surgeons who require a close collaboration with neurosurgeons in the conduct of trans-cranial surgery where calvarial segments need to be removed for repositioning. Ophthalmology and otolaryngology are essential for managing specific disorders in the craniofacial patient as are other key contributions from paediatric anaesthetists, paediatric dentists and orthodontists, speech therapists, paediatricians, nurse co-ordinators and psychologists who complement the team.

The spectrum of work is usually undertaken in a tertiary, paediatric hospital setting and includes the management of cleft lip and palate (presented in the paediatric oral & maxillofacial surgery chapter), craniofacial microsomia, the syndromic craniosynostoses, facial clefting disorders and other disorders associated with micrognathia (presented in the paediatric oral & maxillofacial surgery chapter) with airway compromise. Craniofacial trauma and a spectrum of pathology affecting children and infants also require the specialized expertise of the team.

It is the purpose of this chapter to provide an overview of the management of several conditions within a Craniofacial Unit from an oral and maxillofacial surgery perspective and to illustrate the management of craniofacial anomalies in the growing patient.

Craniosynostoses

The premature fusion of cranial sutures has been observed for millenia and may occur only in single sutures or even parts of sutures. When multiple sutures are involved, there is often a defined syndromic craniosynostosis such as Crouzon Syndrome, Apert Syndrome or Pfeiffer Syndrome. Animal models of craniosynostoses have been developed and the genetic basis for these pathological processes is being intensely researched. Specific genetic mutations are known in many of these conditions and often involve

mutations that result in faulty fibroblastic growth factor receptors ⁶.

In the first two years of life, the pressure of the rapidly growing infant cerebrum is responsible for expansion of the calvarium via the open sutures. Premature fusion of a suture restricts growth of the calvarium at right angles to the suture. This distorts the head shape that expands in a compensatory pattern where the sutures remain open to accommodate the developing brain. Hence, a unilateral coronal synostosis results in a supraorbital flattening and triangulation of the head shape, whereas a sagittal synostosis results in a long, thin head shape with frontal bossing and "bulleting" of the occiput, where growth of the cerebrum pushes antero-posteriorly (Fig 1, 2). Many procedures have been advocated for correction of the resultant skull deformity and complicated patterns of bone segment repositioning have been developed, particularly for scaphocephaly ⁷ (Fig 3).

When multiple sutures are involved, the restriction on cerebral growth is more pronounced and this may cause indentations on the inner table of the skull that can be seen on imaging ("copper beating") due to pressure from the developing brain (Fig 4). These patients are particularly at risk for raised intracranial pressure and if unrecognised and untreated, may have a serious impact on cognitive development. Additionally, in

the syndromic group, sutural synostoses may extend in to the base of the skull resulting in gross underdevelopment of the mid-face, often with a resultant restriction of upper airway space.

To address these deformities, either a fronto-orbital advancement (FOA) or a posterior calvarial decompression is undertaken. In a FOA, a specific pattern of bone removal is usually undertaken, leaving the underlying duramater intact. The fronto-orbital bar ("bandeaux") is repositioned into a more normal morphology with removal of the involved fused suture and repositioning of the segments to allow more normal brain growth (Fig 5). This is best undertaken under the age of 12 months as the osteogenic capacity is high and the risk of raised pressure is thus reduced. In severe cases, with restriction in the posterior cranial fossa resulting in a Chiari malformation, posterior calvarial decompression osteotomies have been performed and more recently, the preferred approach is distraction of the segment to increase posterior fossa volume⁸. In some centres, fronto-facial one-piece segment ("Monobloc") advancements are preferred to both increase intracranial volume and to advance the combined complex to minimise the deformity and, in the case of obstructive sleep apnoea, improve upper airway patency. Although successful, this surgery carries a higher risk of major complications and thus many Centres prefer to

delay mid-facial advancement until later towards puberty.

✦ Severe mid-facial hypoplasia continues to manifest during growth and surgical advancement of the mid-face is commonly undertaken around the age of 8-10 years to correct the deficient peri-orbital bony contours and to minimize the developing marked Class III malocclusion. Since the advent of distraction osteogenesis, mid-facial advancement at the Le Fort III level using this technique has become the procedure of choice. After osteotomies and mobilization of the facial skeleton, a "halo" frame is anchored to the calvarium. A central vertical rod then allows the attachment of wires from fixation points to the pyriform apertures of the nose and either the infraorbital or fronto-zygomatic regions (Fig 6). The segment is then slowly distracted by 1-2 mm per day by activating the appliance until the mid-face is sufficiently forward into a positive occlusal overjet and the infraorbital margins are in line with the anterior aspect of the ocular globes (Fig 7A, B). A significant proportion of patients with syndromic craniosynostoses develop severe obstructive sleep apnoea and until more recently, a tracheostomy or nocturnal continuous positive airway pressure (CPAP) was necessary to maintain sufficient oxygenation for normal development. Fortunately, distraction is also possible in the immature

skeleton at an earlier age to resolve upper airway obstruction.

Following this phase and with the eruption of the permanent dentition, continued growth is monitored, often with the return of a Class III skeletal relationship with a lack of normal mid-facial development and normal lower facial growth. Depending on the characteristics of each patient, a number of procedures are usually required for the best final outcome. Either staged or definitive orthognathic surgery is performed to correct the occlusion and provide the best facial balance. It is often necessary to perform a high-level mid-facial advancement together with mandibular repositioning and a genioplasty⁹. Finally, a cranioplasty is undertaken with alloplastic "bone cement" (hydroxylapatite) to contour the often irregular frontal region and to fill in the consequent temporal "hollowing", a legacy from early FOA surgery. Nasal asymmetry, deficiency and obstruction are common and a full-scale septorhinoplasty may be indicated to improve aesthetics and nasal airflow (Figs 8A-F).

Craniofacial Microsomia

Among the congenital disorders of the maxillofacial complex, craniofacial microsomia (CFM) is the next most common anomaly after cleft lip and/or palate with an incidence of 1 in 5-6000. This condition has been the subject of varying nomenclature for many years and has included:

Hemifacial microsomia, First and second branchial arch syndrome, Oto-mandibular dysostosis and Goldenhar syndrome. These descriptions have been based on the phenotypical facial features and reflect the wide variation in how this condition may present. Extra-craniofacial manifestations may also be present and can include vertebral anomalies, cardiac structural abnormalities, cerebral pathology and other pulmonary, renal and gastrointestinal anomalies. This strongly suggests a complex genetic basis to CFM as affected patients manifest a variable distribution of features. Hence, another favoured term used by many is "Oculo-auriculo-vertebral spectrum", the genetic basis of which remains to be elucidated ¹⁰.

CFM is often bilateral and may affect the formation of the following: the auricle of the ear, middle and inner ear structures, the ramus and condyle unit of the mandible, the zygomatico-orbital region, branches of the facial nerve and the muscles and soft tissues of the associated skeleton (Fig 9A, B). A number of classifications have therefore been proposed for descriptive purposes such as the SAT and OMENS systems ¹¹.

In infancy, skin tags may be noted at birth together with widening of the oral commissure(s). The skin tags may contain cartilage and are usually removed within the first few years of life as is repair of the macrostomia. In a small percentage of CFM, obstructive sleep apnoea is present and, if

sufficient bone is present, internal distraction osteogenesis of the mandible may be indicated to advance the tongue base forward to avert the need for a tracheostomy.

In practice, for the oral and maxillofacial surgeon, the degree of the mandibular deformity in each individual is pivotal in the sequencing of treatment. As the facial skeleton develops, the asymmetrical nature caused by lack of growth on the hypoplastic side appears to worsen the deformity. There has been much speculation as to whether the condition is progressive or whether the jaws simply grow to scale. However, it is clear that a deformity in one part of the mandible will have a field effect on the contralateral side and that the most severe congenital deformities will appear to progress in the teenage years.

The main decision for the surgeon is whether reconstruction of the condyle/ramus unit should be undertaken in order to provide a stable "neo-TMJ". Mandibular deformities were originally classified by Pruzanski into Types I, II and III and this was further subdivided by Kaban into Types IIA and IIB¹². This subsequent distinction was to provide a clinical guide between a condyle/ramus unit that was hypoplastic but functional with a glenoid fossa (IIA) or a condyle/ramus unit that was hypoplastic and medially placed with a poor or absent fossa structure (IIB). For Types IIB and III deformities, costo-chondral rib grafts have been

the most popular reconstruction to form a new joint structure to improve facial symmetry and to level the maxillary arch by creating an open bite on the affected side. This enables development of the alveolus with eruption of the maxillary teeth. The "neo-TMJ" also provides a stable joint that facilitates the ability to perform a final correction of the occlusal and facial deformity following the completion of growth. In our Institution, rib graft reconstruction is usually undertaken after the age of ten years using a 5th or 6th rib with a thin costal cartilage cap as described by Kaban¹³. It is inserted via pre-auricular and submandibular access incisions with a planned open bite on the ipsilateral side. An orthodontic appliance is progressively adjusted with the eruption of the maxillary permanent teeth (Figs 10A-F).

In the 1990's, with the advent of distraction osteogenesis, many craniofacial units began distracting the deficient mandible in unilateral young patients, noting a marked improvement in appearance in the short term. Minimising the deformity was considered an indication for psychological reasons. However, as the outcomes were further analysed, the facial asymmetry returned with further growth and enthusiasm for this technique therefore waned^{14,15}.

In young patients with microtia, autogenous auricular reconstruction from rib cartilage is

undertaken in patients' who are prepared to undergo this additional staged procedure. This is highly specialised surgery that strives to provide the most realistic replication of a normal ear. There are also middle ear procedures available to further modify the skeletal component of the bony ear canal to assist hearing and, more recently, a wide range of technological advances in facilitating bone conduction and amplification techniques to improve hearing. Craniofacial implants placed in the temporal region also remain an option for those with unsatisfactory ear reconstructions or for patients who primarily choose this approach. These fixtures enable the screw insertion of a fabricated substructure bar on to which an almost a perfect alloplastic copy of the contralateral ear made in silicone is attached to the framework by magnets.

On the eruption of the full dentition, orthodontic planning is commenced to align the arches and necessary extractions are undertaken to alleviate dental crowding in the hypoplastic mandible. Orthognathic surgery is usually undertaken at the completion of growth and usually involve levelling of the maxilla, advancement and rotation of the mandible and advancement and rotation of the chin. Additional procedures such as unilateral zygomatic osteotomies can be undertaken to improve the cheek prominence (Fig 11A-F).

Following the skeletal correction of the jaws, there is often a perceptible residual deficiency of the hard and soft tissues over the lateral mandibular body and cheek regions. In recent years, fat grafting of these areas has proved to be an excellent approach for contour augmentation. Adipose tissue is harvested from the abdomen or lateral thigh and injected in to small subcutaneous tunnels of the facial soft tissues to enable good vascularisation. In patients with marked residual lateral and inferior skeletal deficiency, onlay alloplastic materials such as Medpor # provides good contour and a solid foundation for subsequent fat transfer.

As with many craniofacial deformities, CFM in its moderate to severe manifestation, represents a major challenge for the surgeon with the need for careful individual planning of the treatment pathway.

Jaw Tumours

In children and infants, the spectrum of lesions affecting the maxillo-facial skeleton differs to those afflicting the adult population. Odontogenic cysts, pyogenic granulomas and giant cell lesions are more familiar lesions involving the jaws but there are also unusual congenital or acquired lesions that may present in the early years. Tumours requiring segmental or wide resection in childhood are relatively uncommon. There is a limited international literature on the

management of such conditions in the growing patient, often in the form of case reports or reviews with only small samples.

In the neonate, congenital lesions such as granula cell myoblastomas and the neuroectodermal tumour of infancy are occasionally reported (Fig 12). Aggressive infantile fibromatosis of the mandible presents as an enlarging firm mass that envelops and resorbs the lower border of the mandible ¹⁶. The onset is in infancy and may result in a degree of trismus due to muscular spasm. The rapidity of growth causes great concern to parents and clinicians alike, but the biological behaviour is unpredictable. The lesion comprises infiltrating fibrous proliferations of cells that are intermediate in behaviour between benign fibrous lesions and fibrosarcoma. While many Units around the world recommend and perform radical resections of this histologically benign fibrous neoplasm, debulking has also been described as an option and spontaneous resolution has also been observed with and without surgery (Fig 13A, B). Juvenile ossifying fibromas are benign lesions that may develop quickly and aggressively requiring enucleation and reconstruction. These lesions also share a relationship with aneurysmal bone cysts that have been noted to be present within the mass. Juvenile chronic mandibular osteomyelitis is an unusual disorder of unknown aetiology that arises in children and manifests as a facial swelling with

enlargement of mandibular bone. The disorder may be either unilateral or bilateral and imaging reveals patchy radiolucencies mixed with radio-dense areas (Fig 14A, B). It is also characterized by episodes of swelling of the overlying soft tissues, sometimes with erythema and trismus due to muscular involvement ¹⁷. This feature distinguishes this disease from fibrous dysplasia that is occasionally erroneously assigned to patients. An infective aetiology has been proposed but there has been no convincing causation from any specific microorganisms. The condition is generally managed with anti-inflammatory agents that shorten the episodes of pain and swelling to several days and occasionally decortication of the mandible is undertaken for contouring and also with the hope of initiating resolution of the disorder. It appears that the condition "burns out" following the teenage years. Many of these patients have been submitted to lengthy courses of antibiotic therapy, sometimes as in-patients where they have received intravenous therapy for several months before the nature of the condition is identified and explained to frustrated parents.

Benign tumours of the jaws with an increased potential for recurrence, such as odontogenic myxomas and ameloblastomas, are generally surgically resected with a margin. Extensive lesions in the maxilla or mandible require reconstruction with either a free or vascularised

bone graft for future rehabilitation. There are differing views as to whether reconstruction should be immediate or delayed but bone grafting should provide good contour and facilitate future implantology for occlusal reconstruction (Fig 15A-D). Odontogenic myxomas are occasionally seen in the first few years of life and, in selected cases, can be treated with aggressive curettage and a sclerosing agent to the cavity such as Carnoy solution ¹⁸.

Unlike carcinomas that are common in the adult population, malignant lesions arising in the maxillofacial region in the paediatric patient are usually mesenchymal in origin. Hence, rhabdomyosarcomas, osteosarcomas and rarely Ewing's sarcoma can occur and are treated by multimodal therapy: chemotherapy and/or radiotherapy, with or without surgery ¹⁹.

Primary surgery is undertaken for low-grade osteosarcomas depending on tumour staging. For the rare malignant lesions of the jaws such as Ewing's sarcoma, chemotherapy followed by resection of the involved bone is the treatment of choice with radiotherapy variably employed post-operatively. The prognosis of these lesions is generally good and hence it is the policy of our Unit to perform immediate reconstructive procedures to restore facial contour with the best occlusal reconstruction possible while minimising soft tissue scarring (Fig 16A-D). Free bone grafts from

the iliac crest in defects of 6-8cm or less maybe considered but for larger defects, free vascularised iliac crest or fibula bone flaps are indicated. With the advent of computer planning, CT scans enable the construction of biomodels and cutting guides that facilitate pre-operative rigid bone plate construction and accurate dimensions for resection and grafting (Fig 17A-D).

Macroglossia

Enlargement of the tongue may be caused by congenital lymphangiomas extending from the submental region into the body of the tongue or the infiltration of abnormal tissue as occurs in metabolic storage diseases such as Hurler or Hunter syndromes. Tongue reduction in these cases must be undertaken cautiously as there may be prolonged post-operative swelling and slow healing.

Macroglossia due to hyperplasia of the muscular elements occurs in Down syndrome and particularly, Beckwith Wiedemann syndrome. The latter is an uncommon anomaly with an incidence of 1:15,000 and in a percentage of patients has a genetic cause and epigenetic factors are also thought to be involved. These infants maybe born with abdominal wall defects and are at risk of developing embryonal tumours and hence require regular ultrasound surveillance.

Tongue reductions are now rarely performed in Down syndrome as the protrusion of the tongue is often mainly functional, but in the case of

Beckwith Wiedemann syndrome, tongue reductions are usually undertaken after the first year of life in those infants where the tongue constantly protrudes between the lips. In these cases, drooling may be present as well as deformation of the anterior dento-alveolus with splaying of the primary anterior teeth. Difficulties with speech add to the indications for reduction.

Multiple patterns of removal have been recommended but a modified keyhole approach with thinning at the new anterior tip is favoured by our Unit. The tongue is reduced to enable passive seating just posterior to the anterior dentition and this produces a permanent correction ²⁰ (Fig 18A - C).

Craniofacial Trauma

The management of facial trauma in children is challenging. Taking a history of the event may be unreliable and clinical examination is difficult due to limited co-operation. With developing tooth buds, there is a reduction in skeletal fixation points for plates and screws and the paranasal sinuses are developing. There are also developmental considerations of the facial skeleton as open procedures may influence growth in specific areas. At birth and infancy, the frontal region is almost in a 1:1 ratio to the maxillo-mandibular skeleton, but as facial growth continues to maturity, the ratio is closer to 1:2 (Fig 19).

Paediatric fractures differ to the adult population in that children have an increase in subcutaneous fat that provides a cushioning effect and due to an increase in cancellous bone, there is greater plasticity of the skeleton and this results in more "greenstick" and incomplete fractures and deformations rather than comminuted injuries. There are relatively few studies analysing series of paediatric craniofacial fractures but the fracture patterns depend on the age of the patient ^{21,22}.

Oblique and atypical craniofacial fracture patterns are seen together with orbital wall injuries that exhibit "trap-door" patterns.

Open reduction and internal fixation of mid-facial fractures is uncommon in the prepubertal or young patient unless there is severe trauma resulting in the displacement of major segments as in the case of a skull fracture and displacement of the orbital bones (Fig 20A - D). Nasal fractures are generally simply manipulated as closed reductions.

In the case of orbital wall fractures, specific patterns occur due to the hydraulic pressure of the associated soft tissues. The thin orbital roof may be fractured to the superior orbit due to transient pressure from the brain but rarely requires reduction. However, orbital floor "trap-door" fractures from pressure of the globe of the eye and buckling of the inferior orbital margin, may pinch the inferior rectus muscle or the associated soft

tissues causing ocular motility restriction in upward gaze (Fig 21A, B). This produces double vision (diplopia) and significant pain as well as nausea and vomiting associated with reflexive vagal responses. This type of orbital floor fracture is a surgical emergency and should be managed as quickly as possible by exploring the orbital floor and releasing the tissues. This is normally performed via a transconjunctival approach and the placement of a separating resorbable gel film²³. The longer the tissues remain incarcerated in the fracture, the more the ischaemic damage and potential for persistent diplopia.

For more severe craniofacial injuries involving significant displacements of the fronto-orbital skeleton, it remains preferable that autogenous bone be used for correction of the orbital volume in the growing patient rather than alloplastic materials.

Conclusion

The spectrum of craniofacial anomalies continues to be better understood due to major advances in genetic understanding and their treatment continues to improve by the collaboration of international treatment centres in sharing both experience and techniques. A multidisciplinary treatment approach is the key for providing the best overall care for these challenging patients.

References

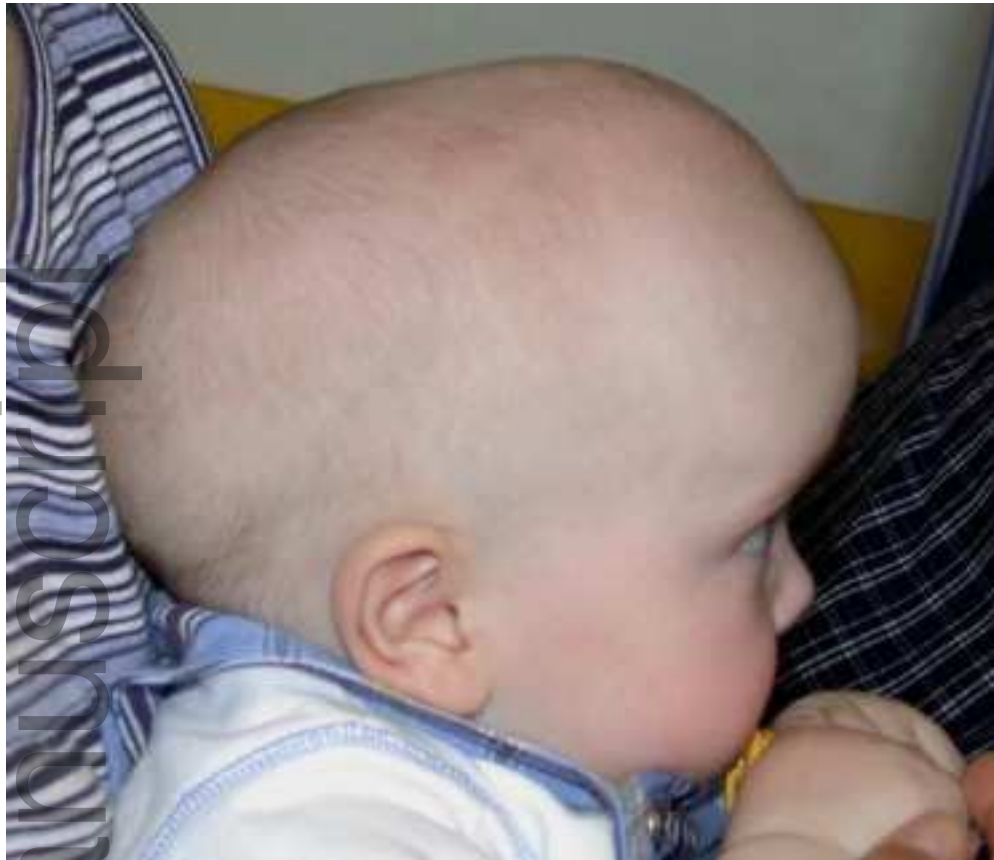1. Tessier P. The definitive plastic surgical treatment of the severe facial deformities of craniofacial dysostosis. Crouzon's and Apert's diseases. *Plast Reconstr Surg* 1971;48:419-42.
2. Tessier P. Total osteotomy of the middle third of the face for faciostenosis or for sequelae of Le Fort 3 fractures. *Plast Reconstr Surg* 1971;48:533-41.
3. Obwegeser HL. Surgical correction of small or retrodisplaced maxillae. The "dish- face" deformity. *Plast Reconstr Surg* 1969;43:351-65.
4. Marchac D, Renier D. The "floating forehead". Early treatment of craniofacial stenosis. *Ann Chir Plast* 1979;24:121-6.
5. Saal Hm. Genetic evaluation for Craniofacial Conditions. *Facial Plast surg Clin North Am* 2016;24:405-425.
6. Levi B, Wan DC, Wong VW, Nelson E, Hyun J, Longaker MT. Cranial suture biology: from pathways to patient care. *J Craniofac Surg* 2012;23:13-9.
7. Greensmith AL, Holmes AD, Lo P, Maxiner W, Heggie AA, Meara JG. Complete correction of severe scaphocephaly: The Melbourne method of total remodeling. *Plast Reconstr Surg* 2008;121:1300-1310.
8. McMillan K et al. Experiences in Performing Posterior Calvarial Distraction. *J Craniofac Surg* 2017;28:664-669.

9. Heggie AA, Holmes AD, Shand J. Skeletal correction of the mid-face in the adolescent craniofacial patient. *Int J Oral Maxillofac Surg* 2011;40:1091.
10. Beleza-Meireles A et al. Oculo-auriculo-vertebral spectrum: clinical and molecular analysis of 51 patients. *Eur J Med Genet* 2015;58:455-65.
11. Poon C-H, Meara JG, Heggie AA. Hemifacial Microsomia: use of the OMENS-Plus classification at the Royal Children's Hospital of Melbourne. *Plast Reconstr Surg* 2003;111:1011-8.
12. Murray JE, Kaban LB, Mulliken JB. Analysis and treatment of hemifacial microsomia. *Plast Reconstr Surg* 1984;74:186-99.
13. Kaban LB, Moses MH, Mulliken JB. Surgical correction of hemifacial microsomia in the growing child. *Plast Reconstr Surg* 1988;82:9-19.
14. Nagy K, Kuijpers-Jagtman AM, Mommaerts MY. No evidence for long-term effectiveness of early osteodistraction in hemifacial microsomia. *Plast Reconstr Surg* 2009;124:2061-71.
15. Ascenço AS¹, Balbinot P, Junior IM, D'Oro U, Busato L, da Silva Freitas R. Mandibular distraction in hemifacial microsomia is not a permanent treatment: a long-term evaluation. *J Craniofac Surg* 2014;25:352-4.
16. Ruparelia MS, Dhariwal DK. Infantile

- fibromatosis: a case report and review of the literature. *Br J Oral Maxillofac Surg* 2011;49:e30-2.
17. Heggie AA, Shand JM, Aldred MJ, Talacko AA. Juvenile mandibular chronic osteomyelitis: a distinct clinical entity. *Int. J Oral Maxillofac Surg* 2003;32:459-468.
18. Subramaniam SS, Heggie AA, Kumar R, Shand JM. Odontogenic myxoma in the paediatric patient: a review of 8 cases. *Int J Oral Maxillofac Surg* 2016;45:1614-1617.
19. Abramowicz S, Goldwaser BR, Troulis MJ, Padwa BL, Kaban LB. Primary jaw tumors in children. *J Oral Maxillofac Surg* 2013;71:47-52.
20. Heggie AA, Vujcich NJ, Portnof JE, Morgan AT. Tongue reduction for macroglossia in Beckwith Wiedemann syndrome: review and application of new technique. *Int J Oral Maxillofac Surg* 2013;42:185-191.
21. Gassner R, Tuli T, Hächl O, Moreira R, Ulmer H. Craniomaxillofacial trauma in children: a review of 3,385 cases with 6,060 injuries in 10 years. *J Oral Maxillofac Surg* 2004;62(4):399-407.
22. Imahara SD, Hopper RA, Wang J, Rivara FP, Klein MB. Patterns and outcomes of paediatric facial fractures in the United States: a survey of the National Trauma Data Bank. *J Am Coll Surg* 2008;207:710-6.

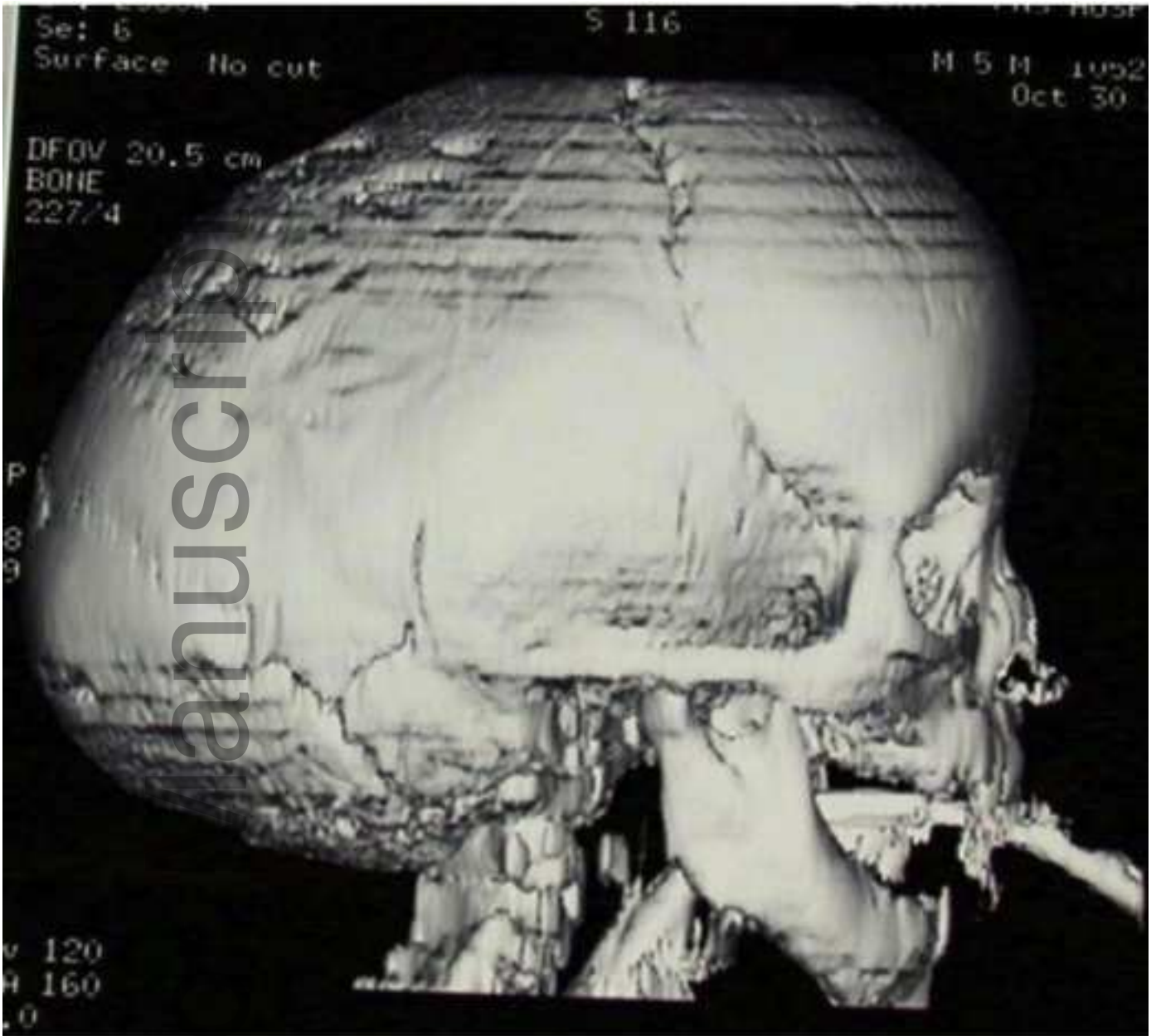
23. Heggie AA, Vujcich NJ, Shand JM, Bordbar P.
Isolated orbital floor fractures in the
paediatric patient: case series and review of
management. Int J Oral Maxillofac Surg
2015;44:1250-1254.

Author Manuscript



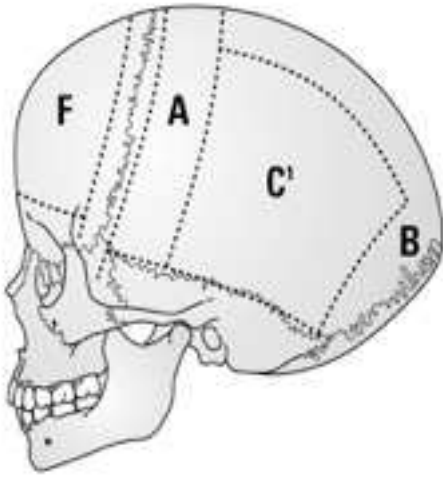
adj_12591_f1(a).jpg

Author Manuscript

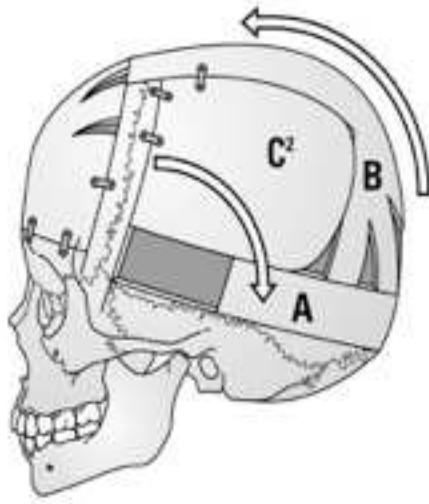


adj_12591_f1(b).jpg

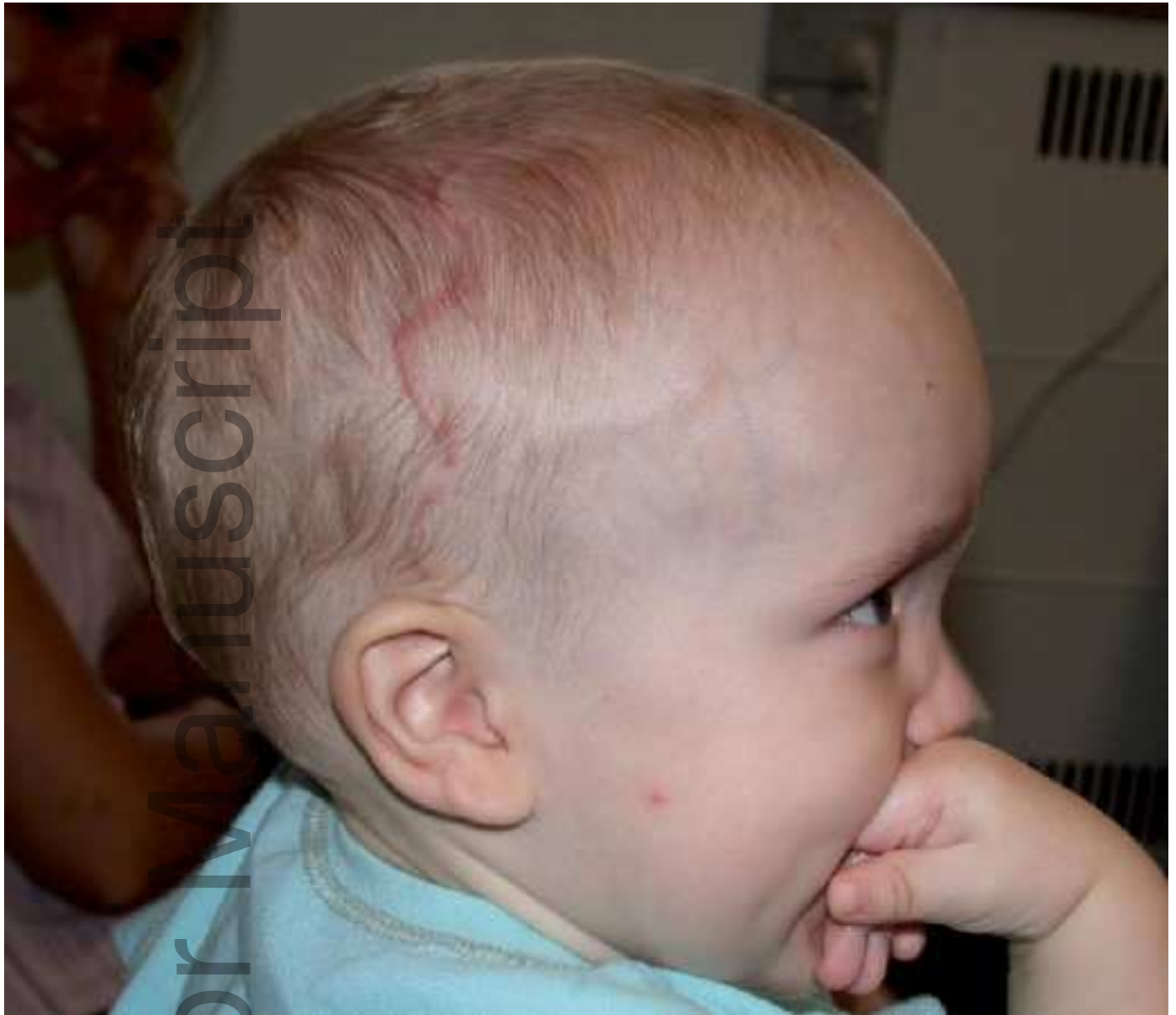Auth



adj_12591_f1(c) (i).jpg

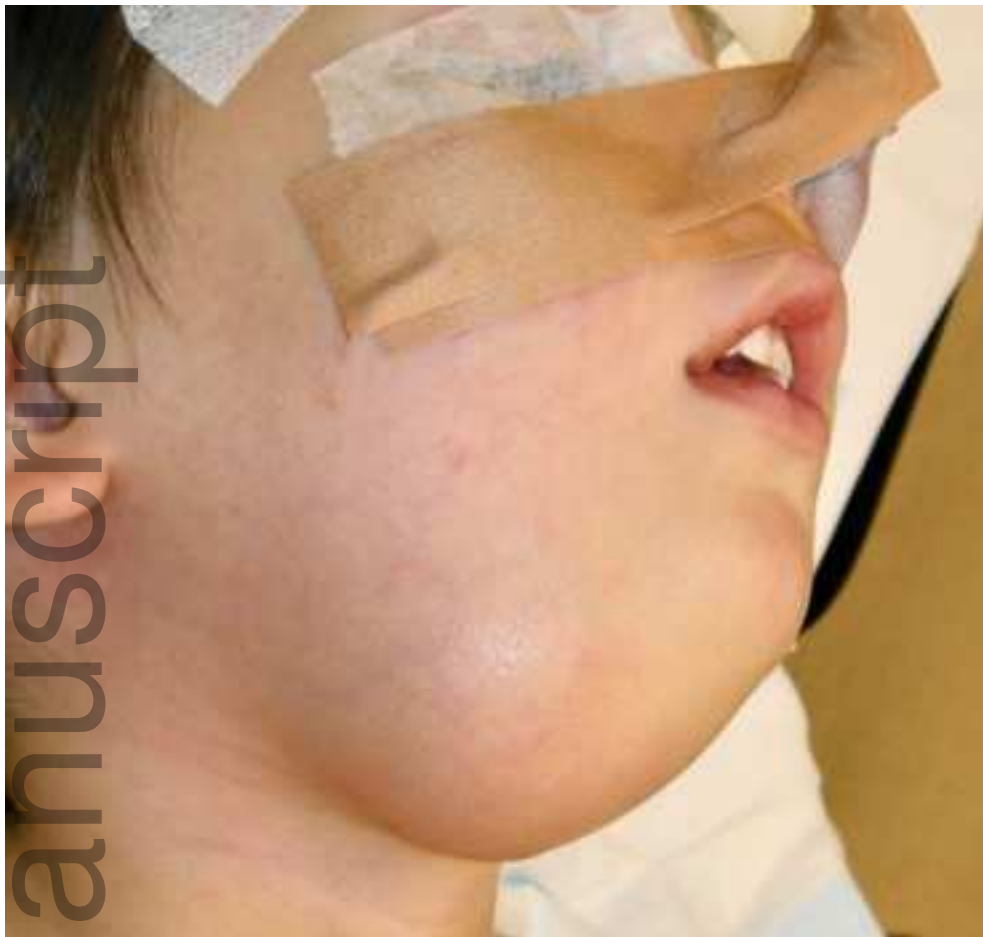

adj_12591_f1(c)(ii).jpg



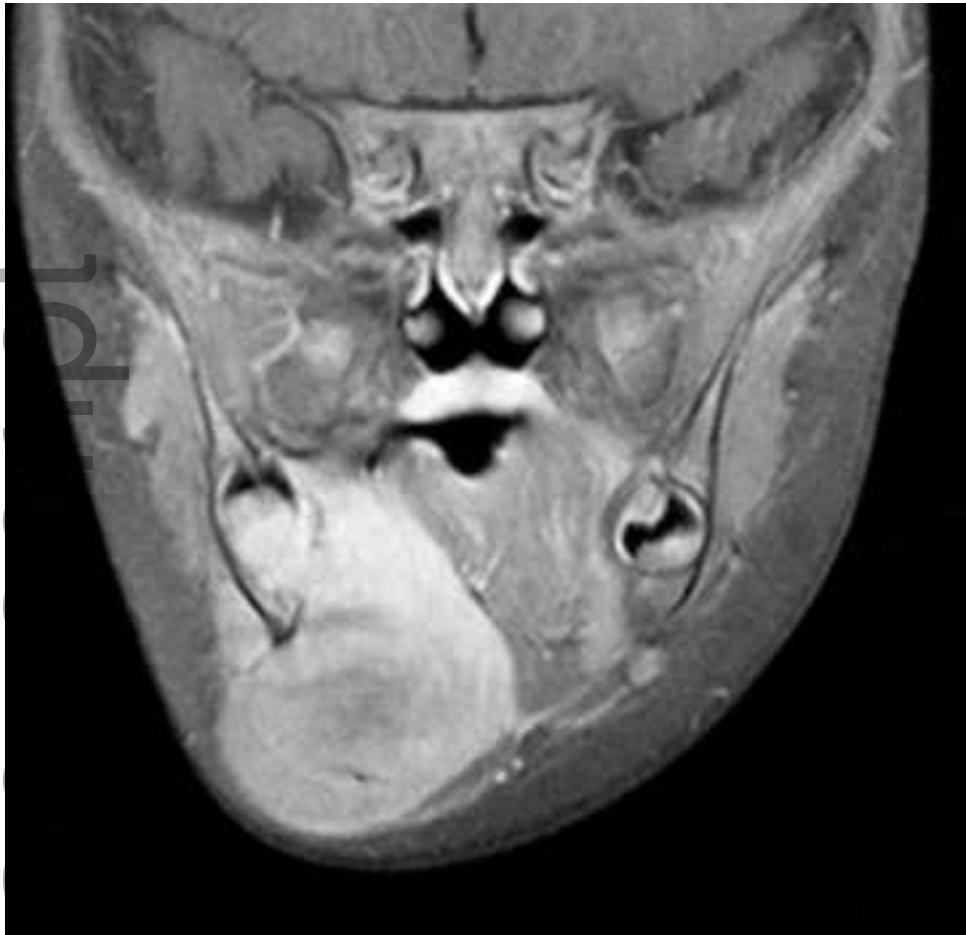adj_12591_f1(d).png

Author Manuscript

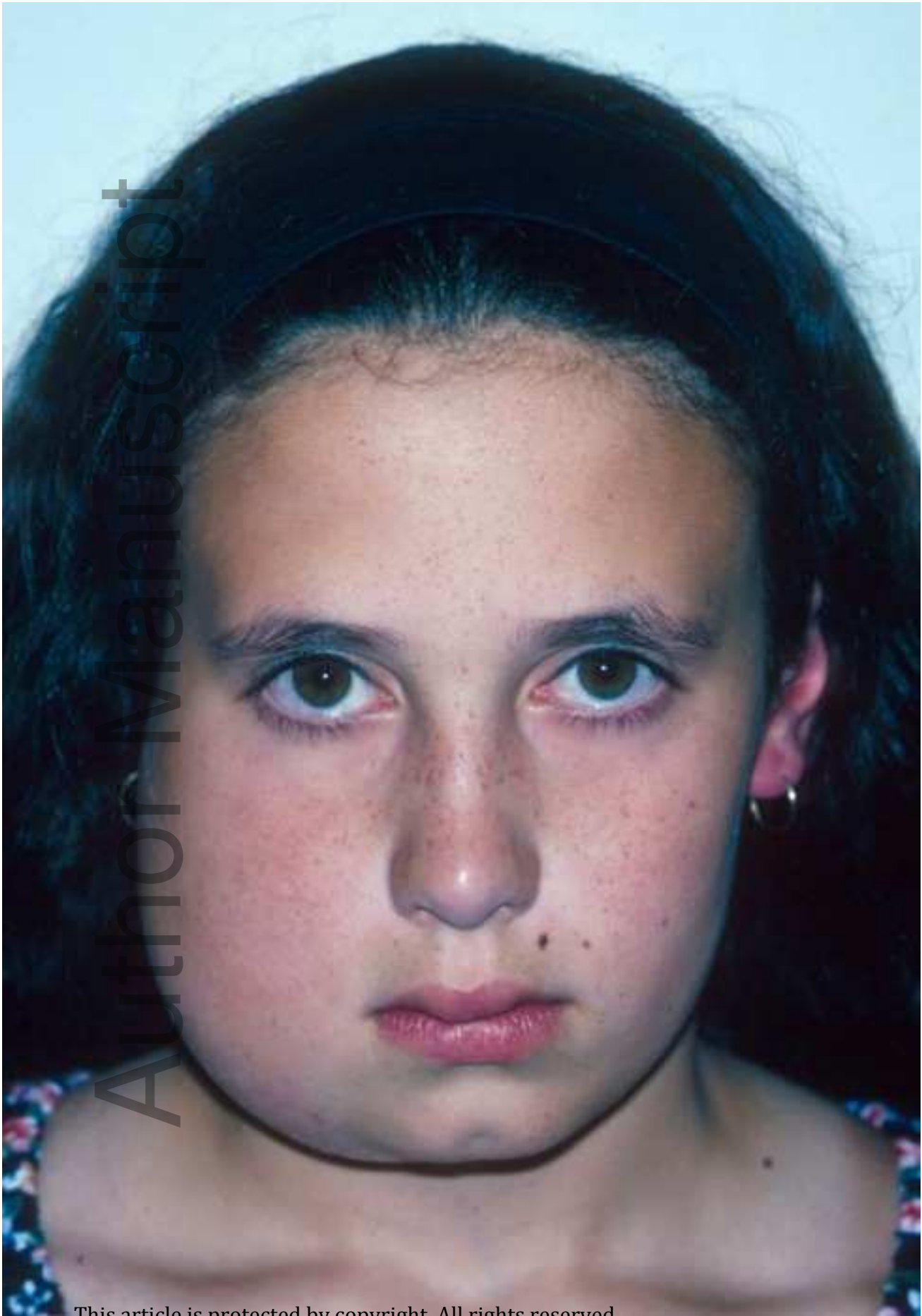

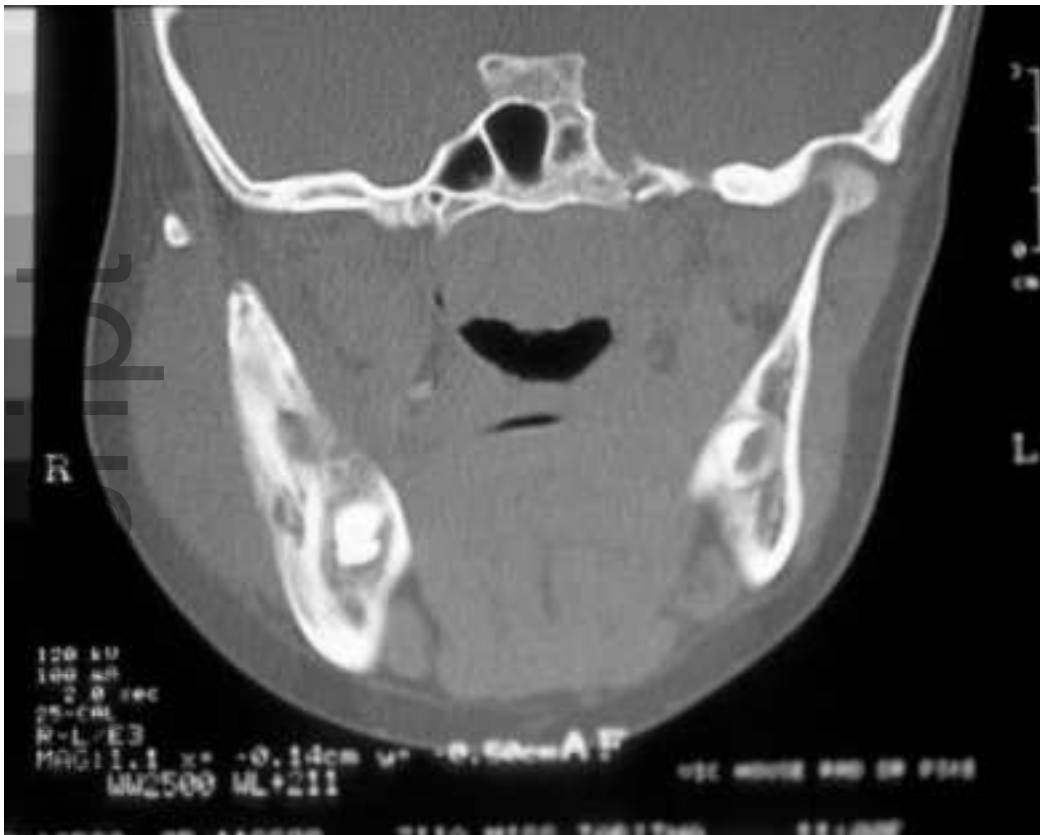adj_12591_f10(a).jpg

Author Manuscript



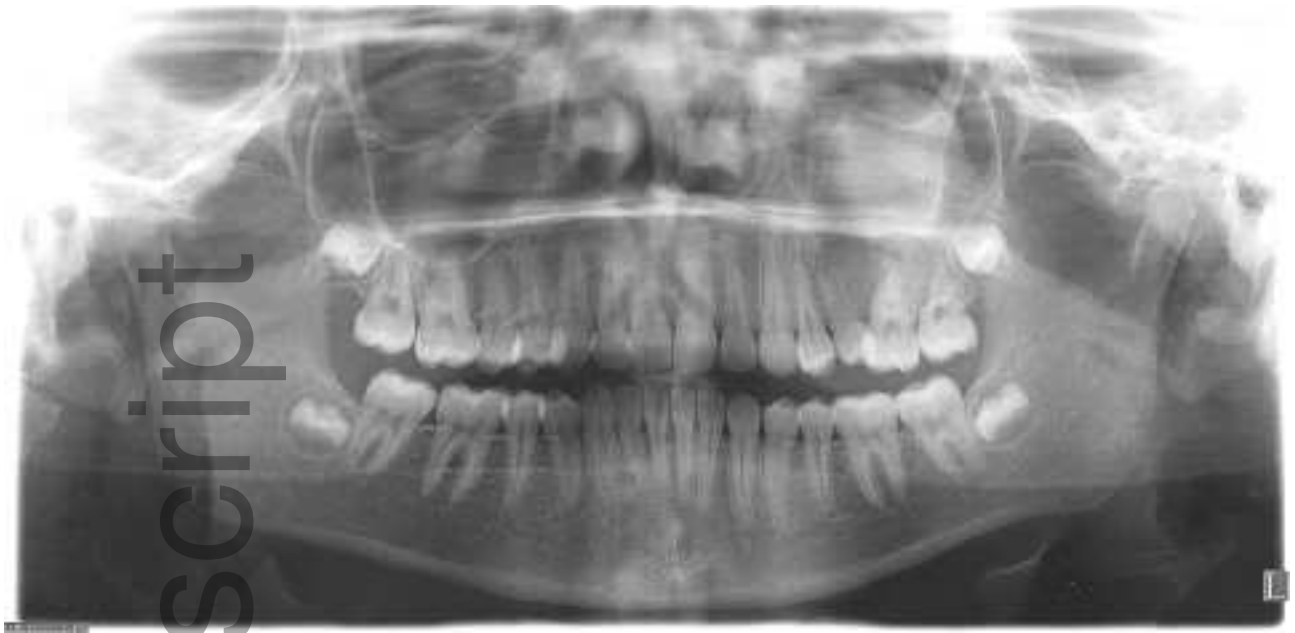adj_12591_f10(b).jpg



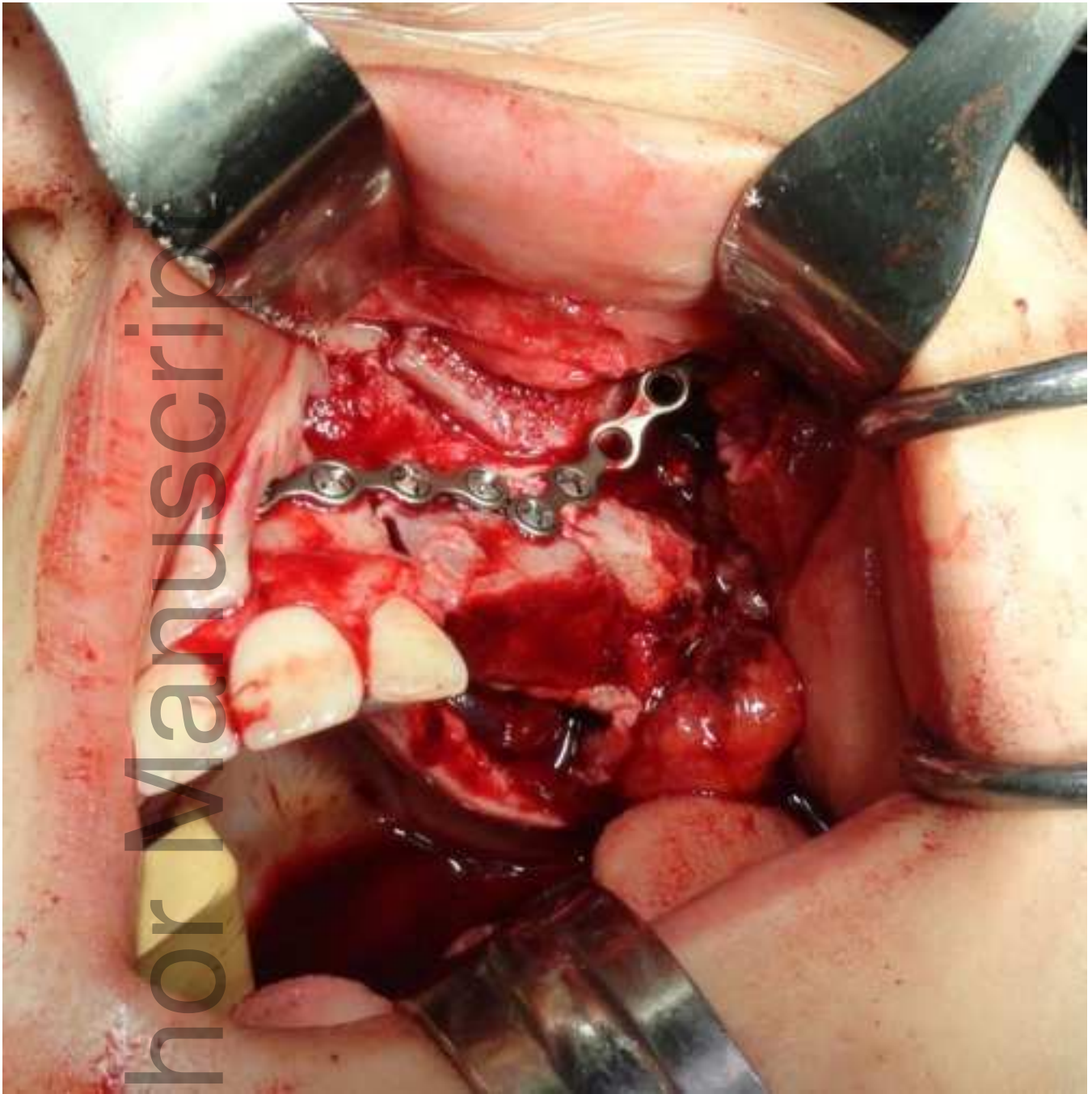


adj_12591_f11(b).jpg

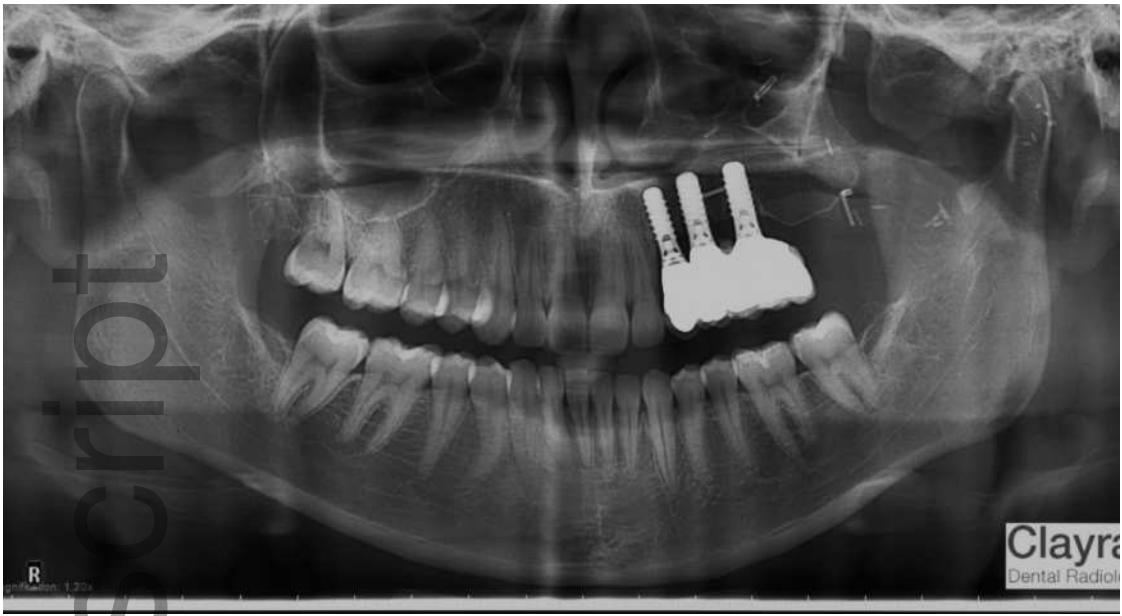Author Manuscript



adj_12591_f12(a).jpeg

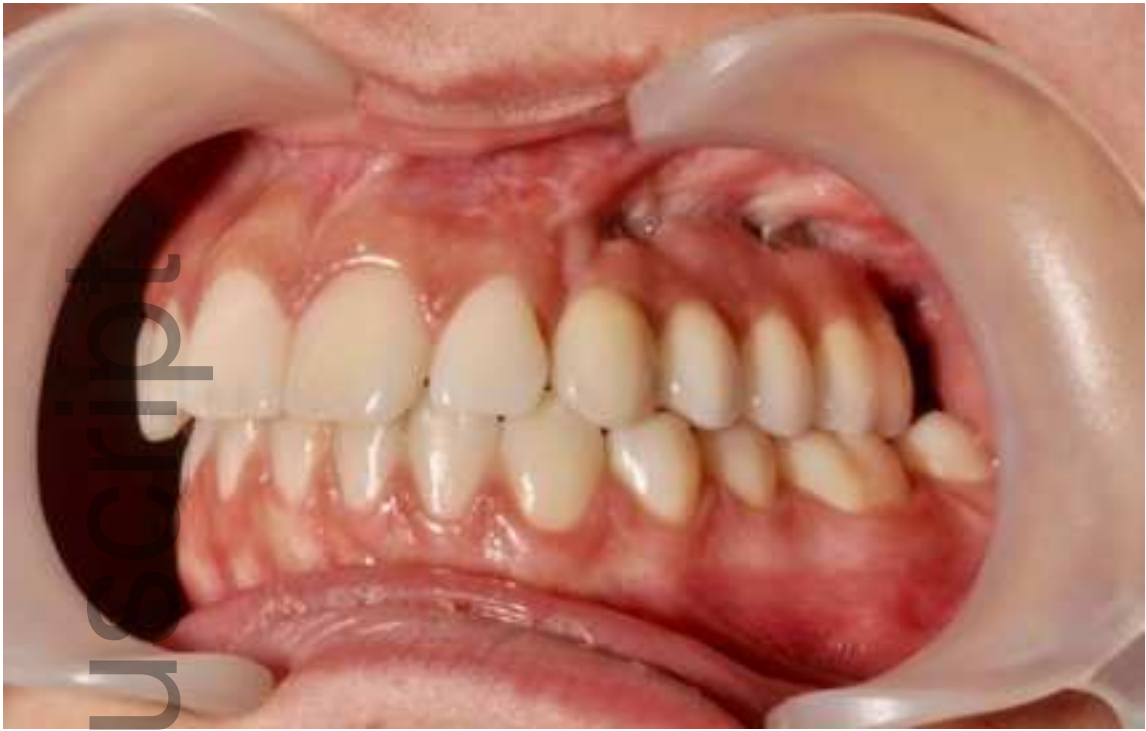

adj_12591_f12(b).jpg



adj_12591_f12(c).tiff

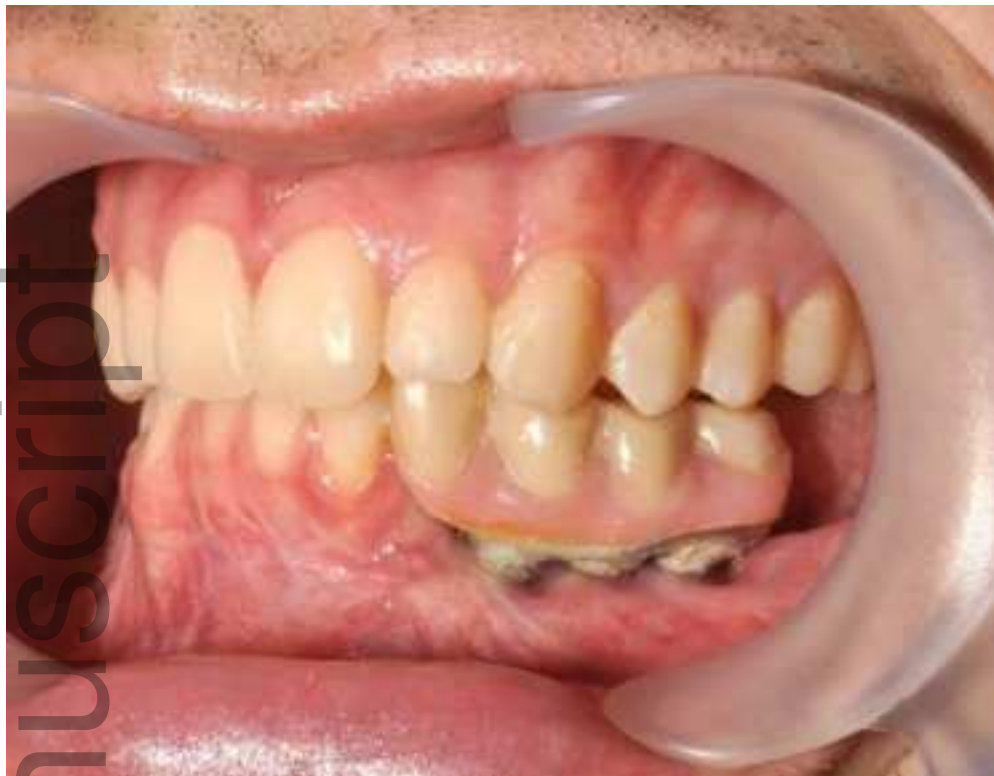Author Manuscript



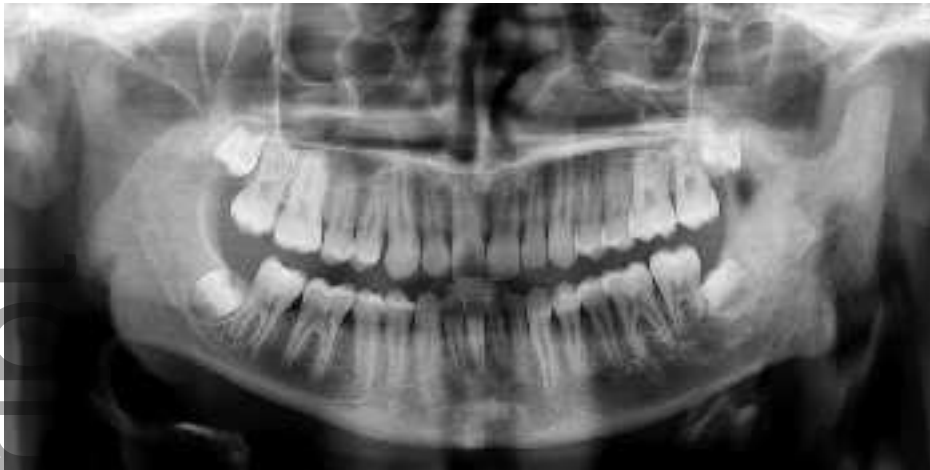adj_12591_f12(d).jpg

Author Manuscript

Author Manuscript

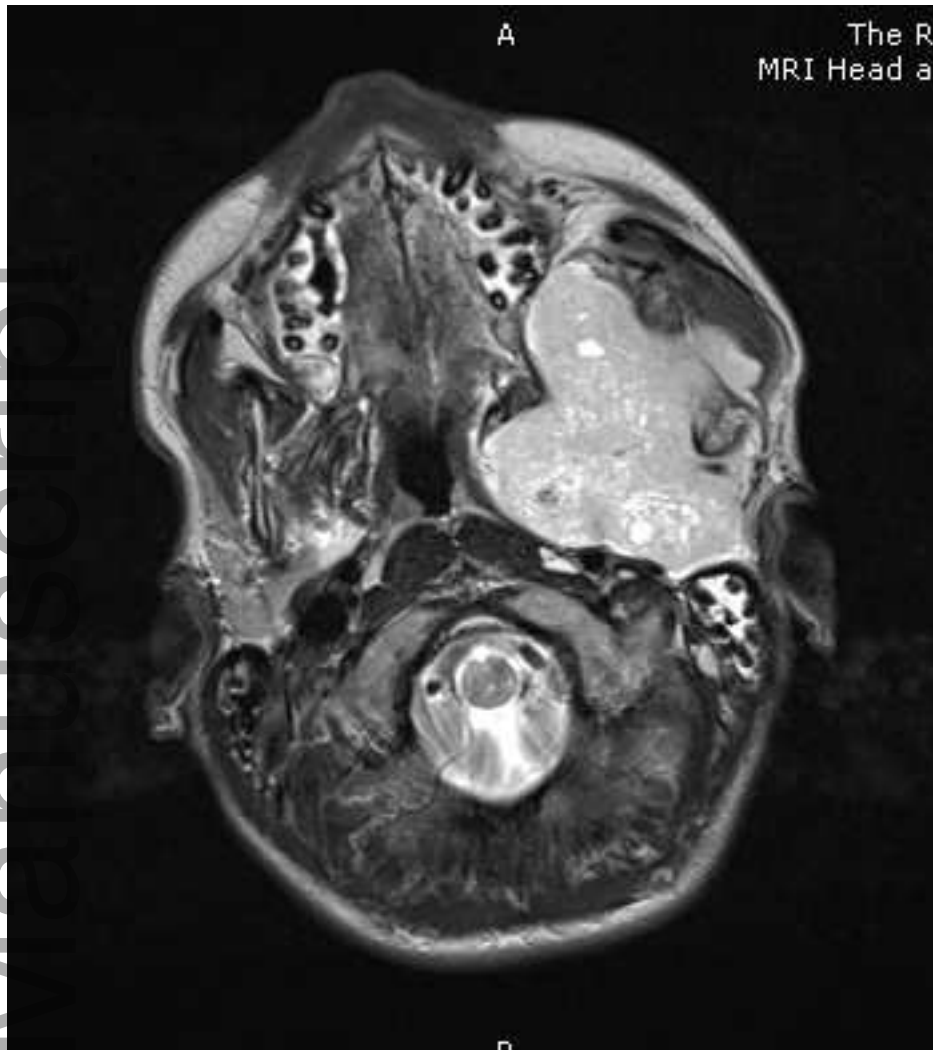


adj_12591_f130.jpg

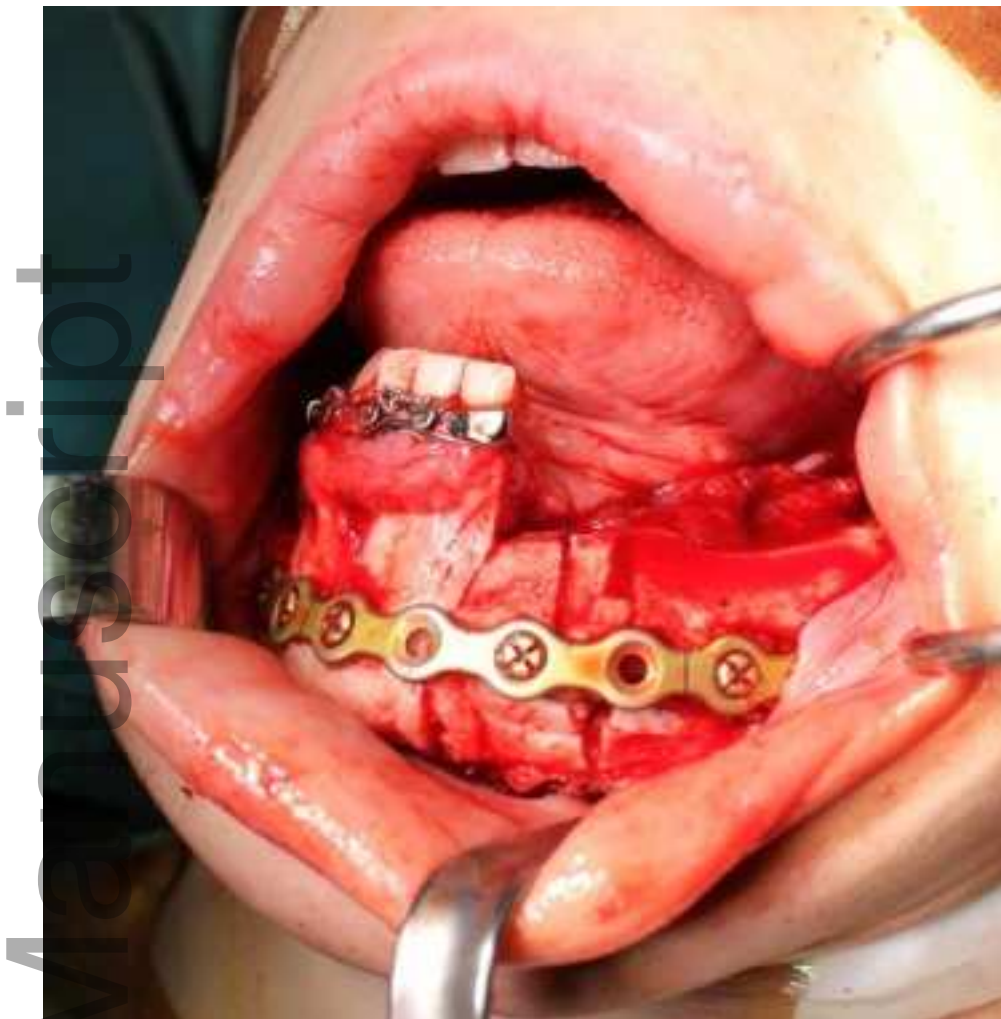


adj_12591_f13(a).jpg

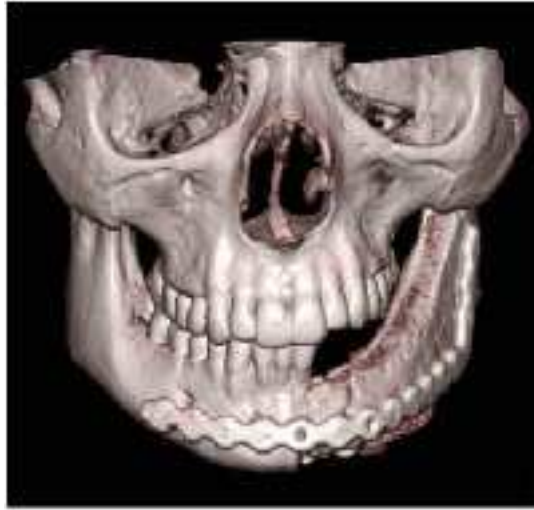Author



adj_12591_f13(b).tiff



adj_12591_f13(c).jpg



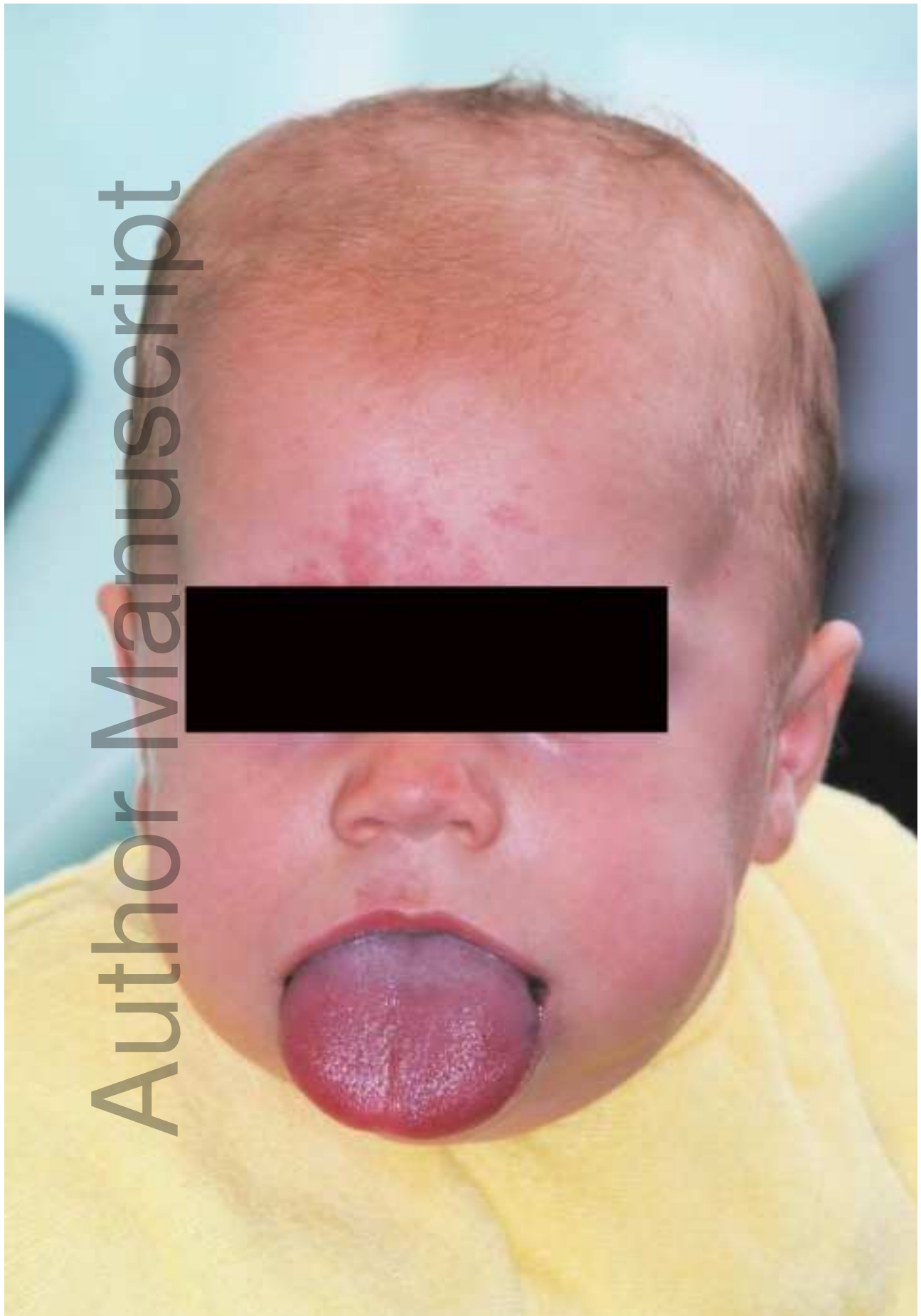adj_12591_f13(d).jpg

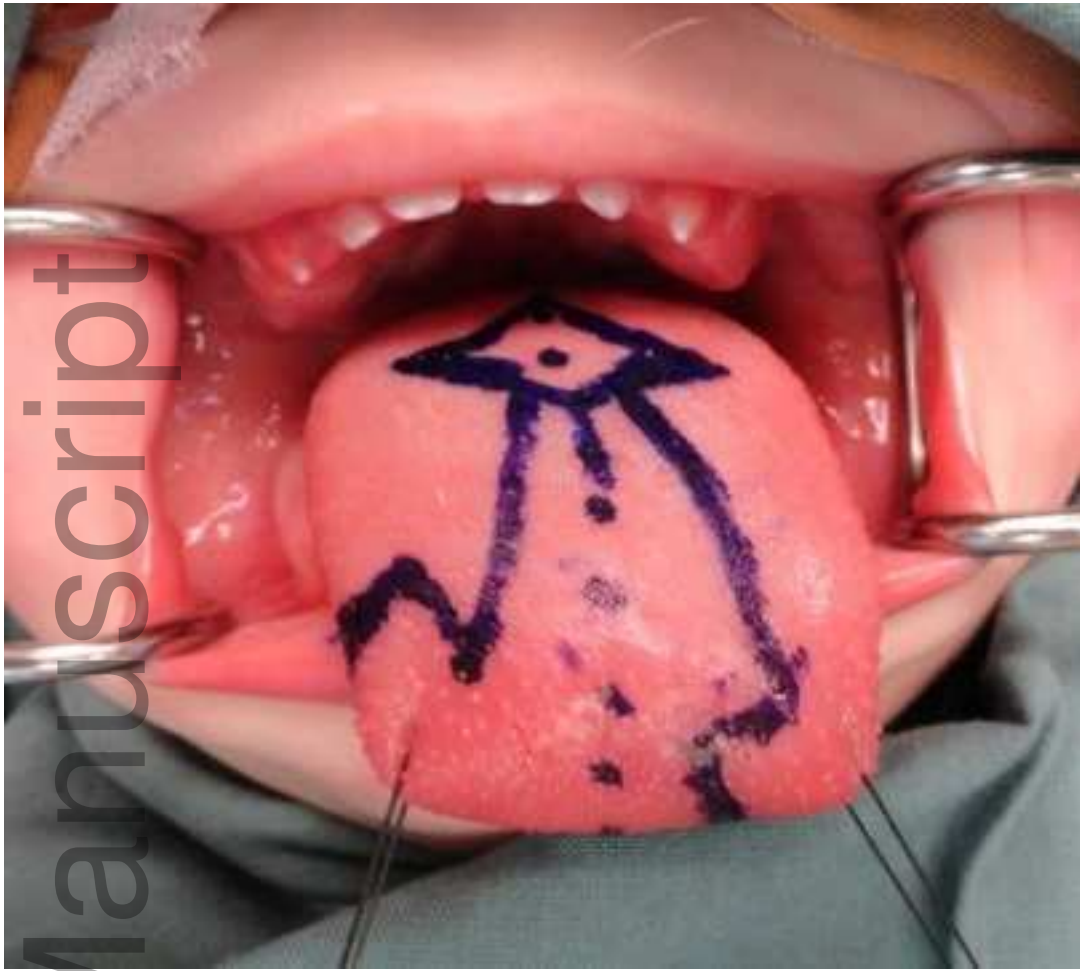

adj_12591_f13(e).jpg

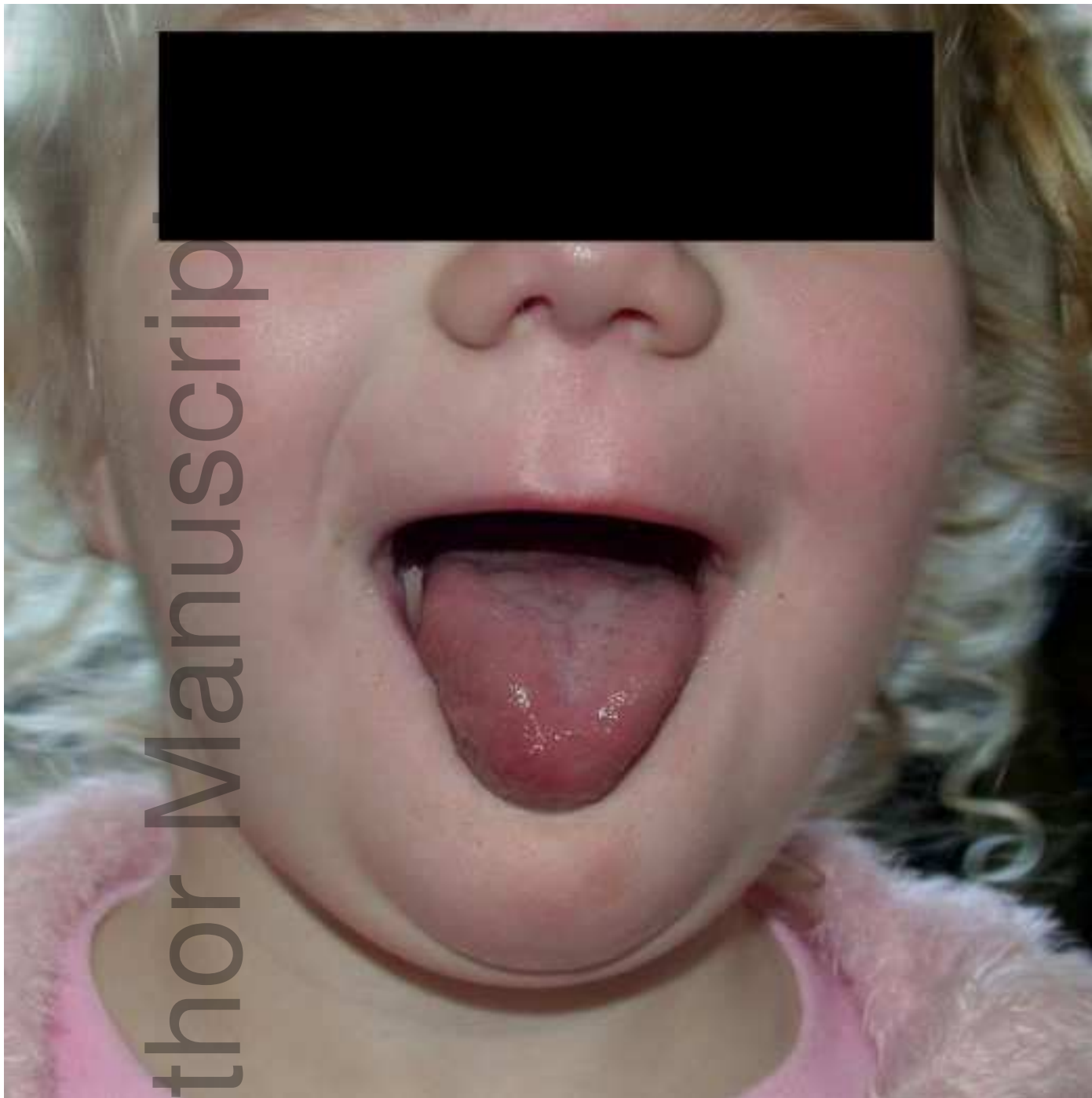This article is protected by copyright. All rights reserved

Author Manuscript



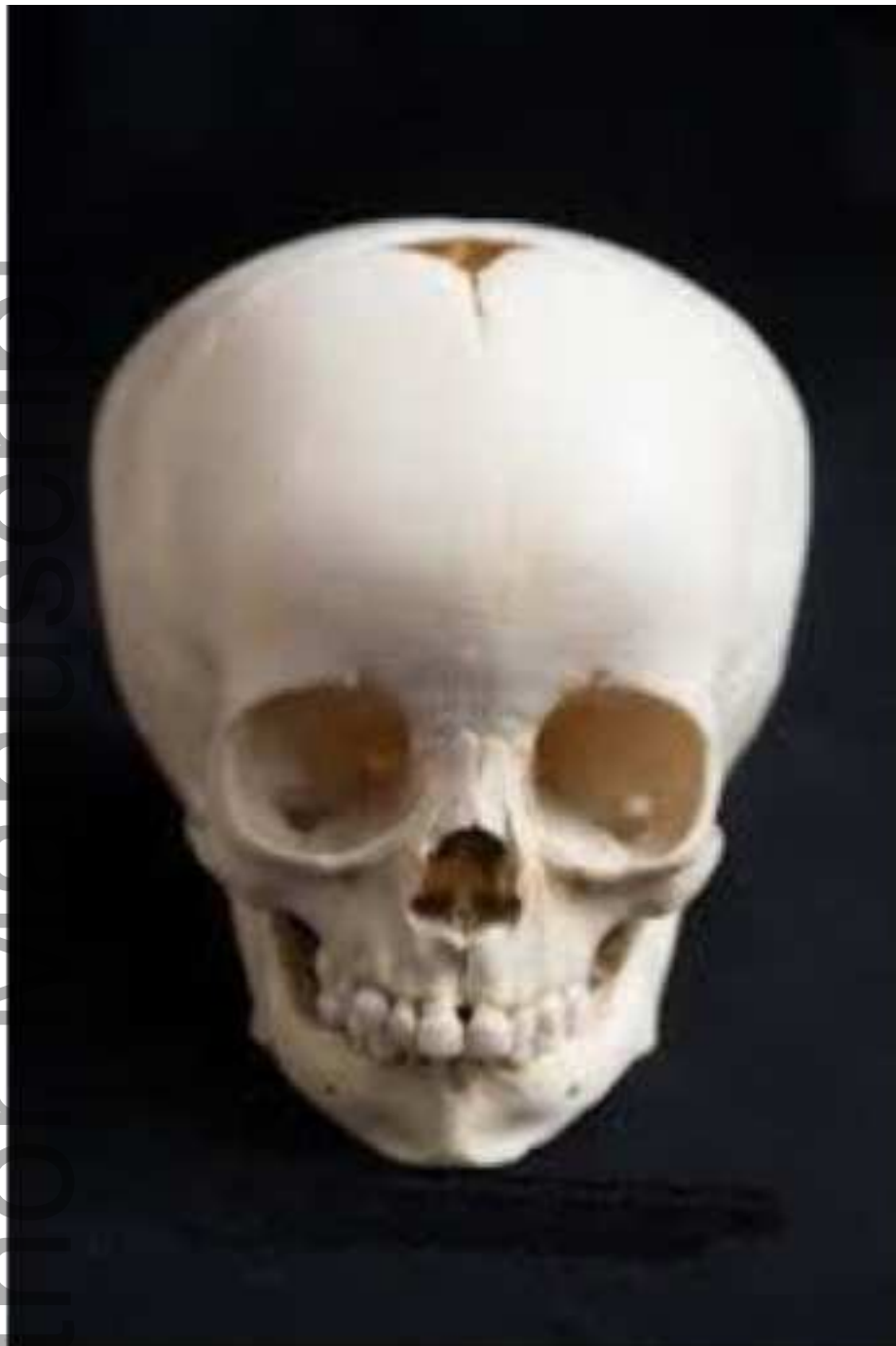

adj_12591_f14(b).jpg

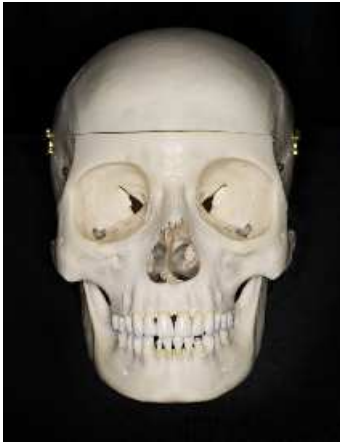

adj_12591_f14(c).jpg

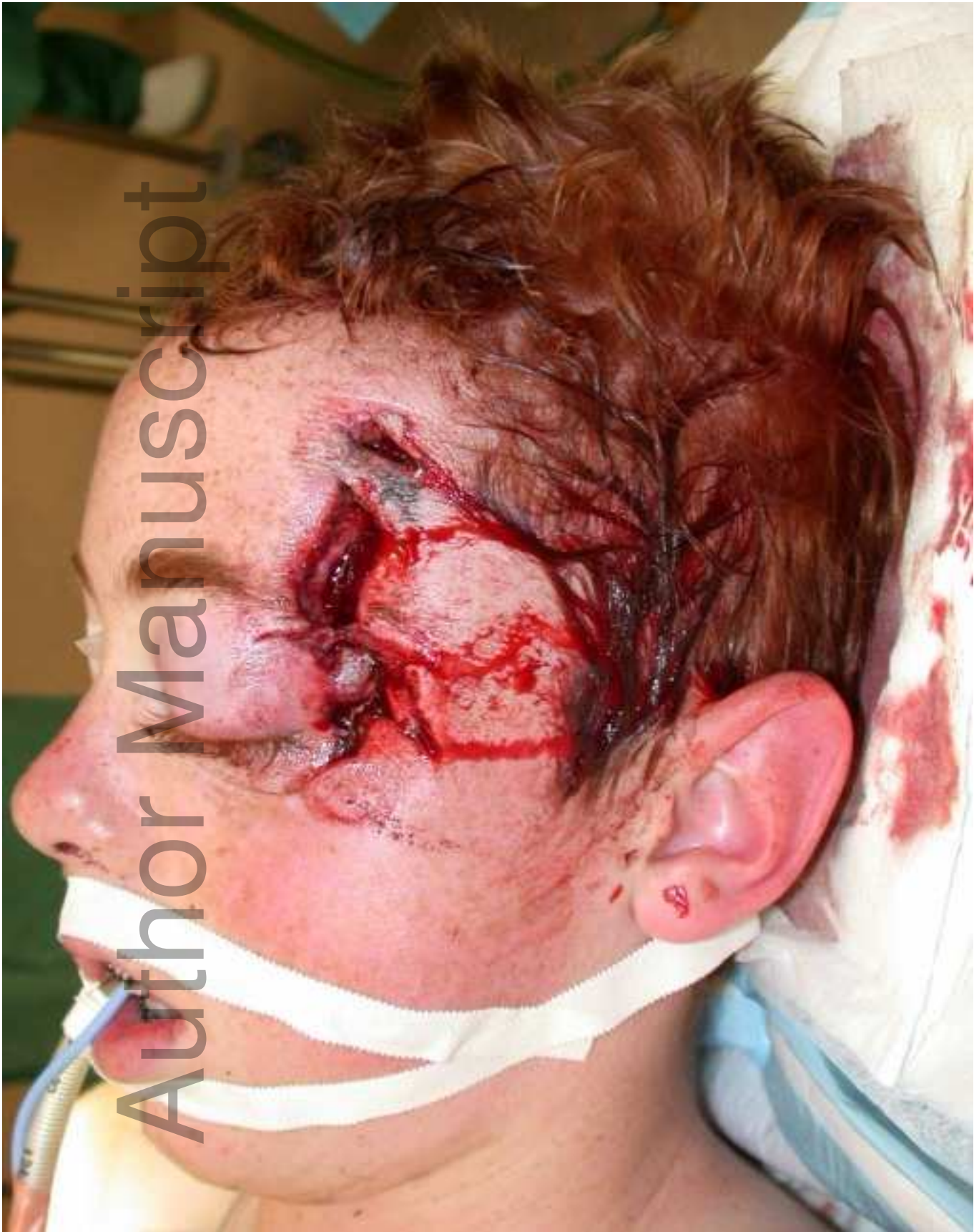Author Manuscript



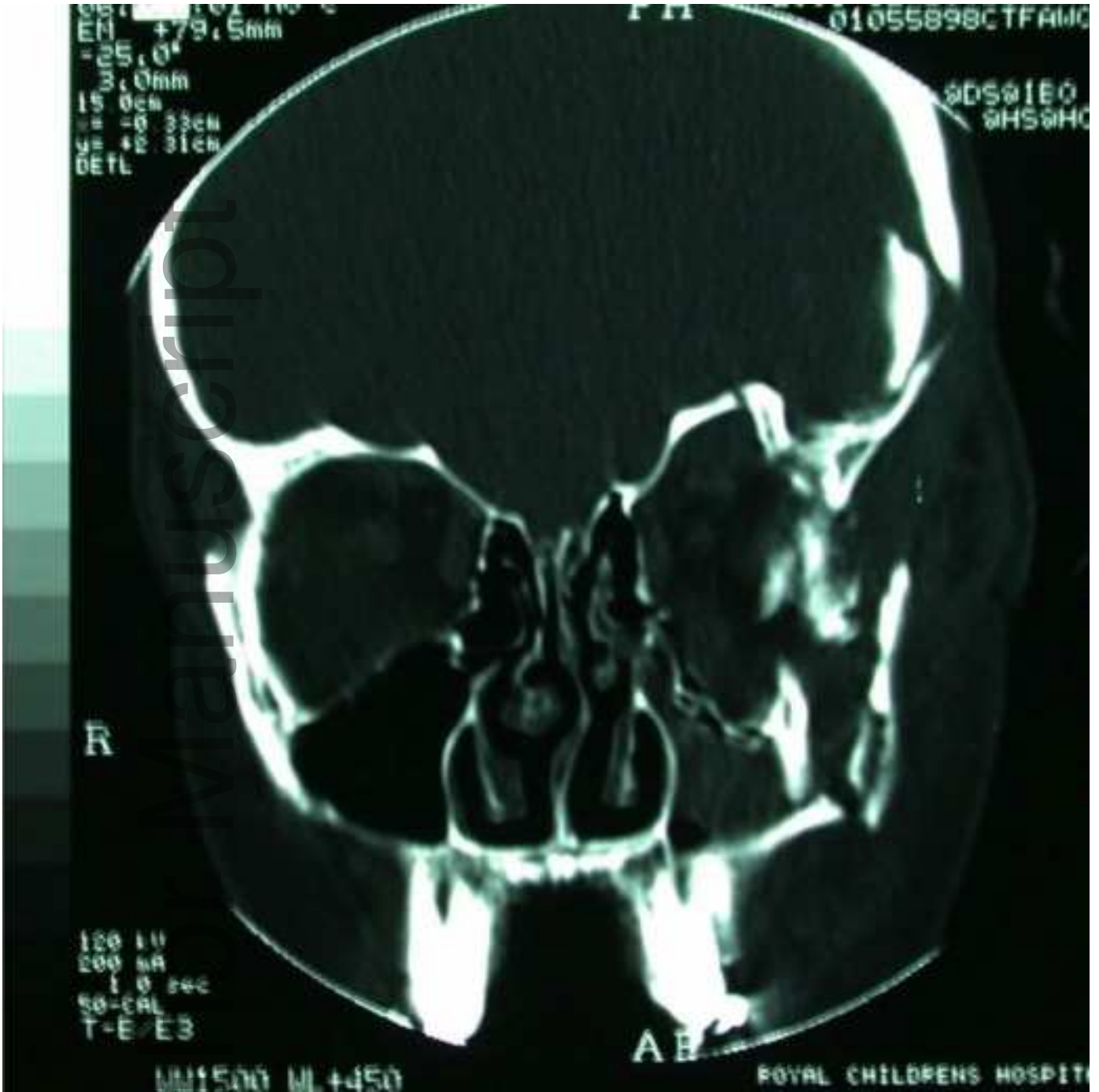
adj_12591_f15 (i).jpg



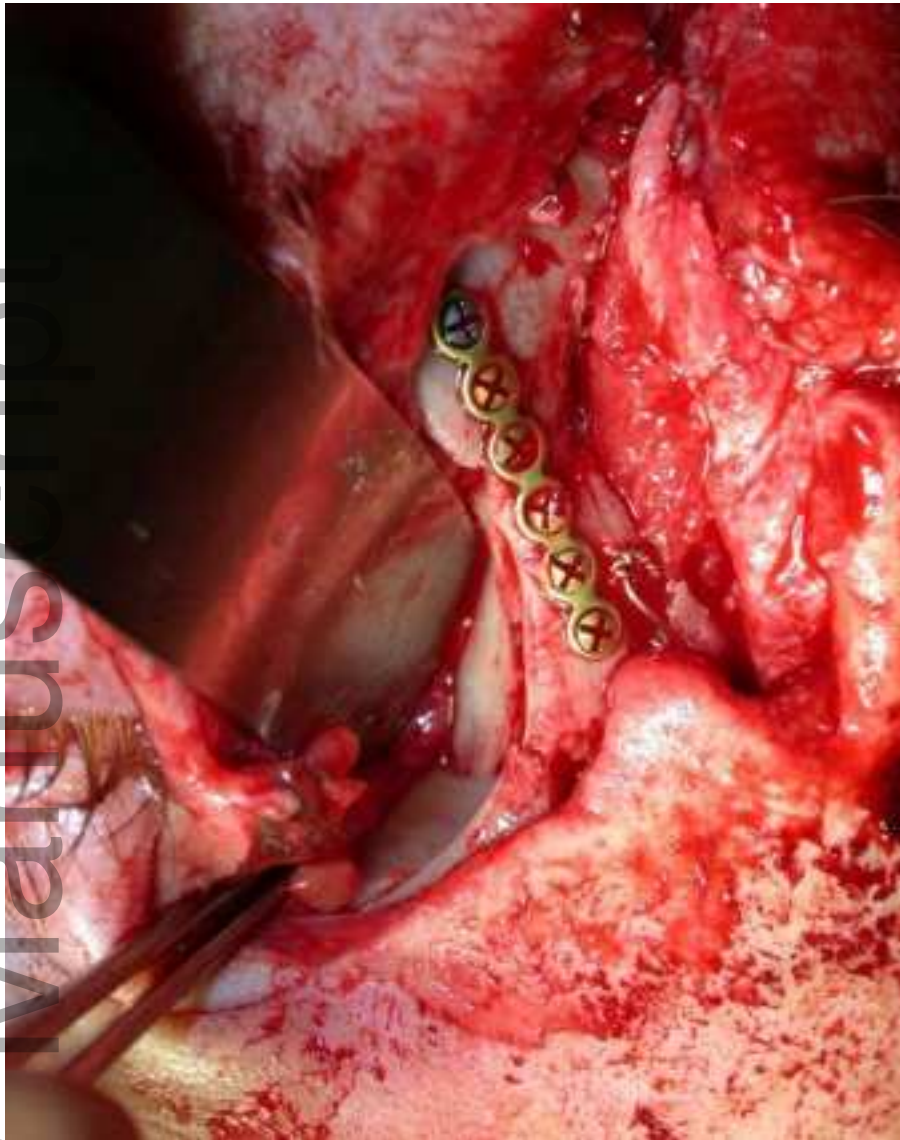adj_12591_f15 (ii).jpeg



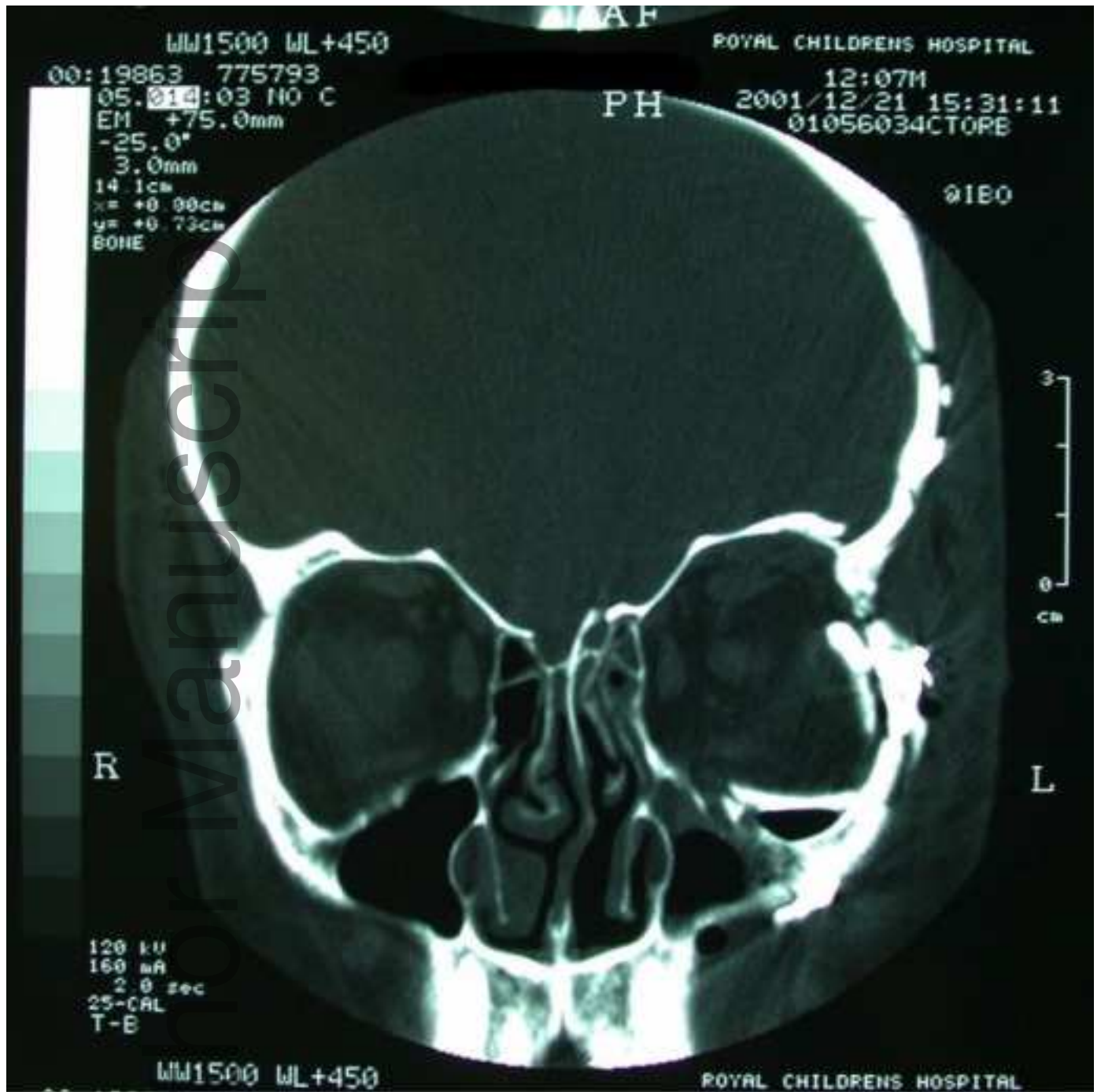
adj_12591_f16(a).jpg



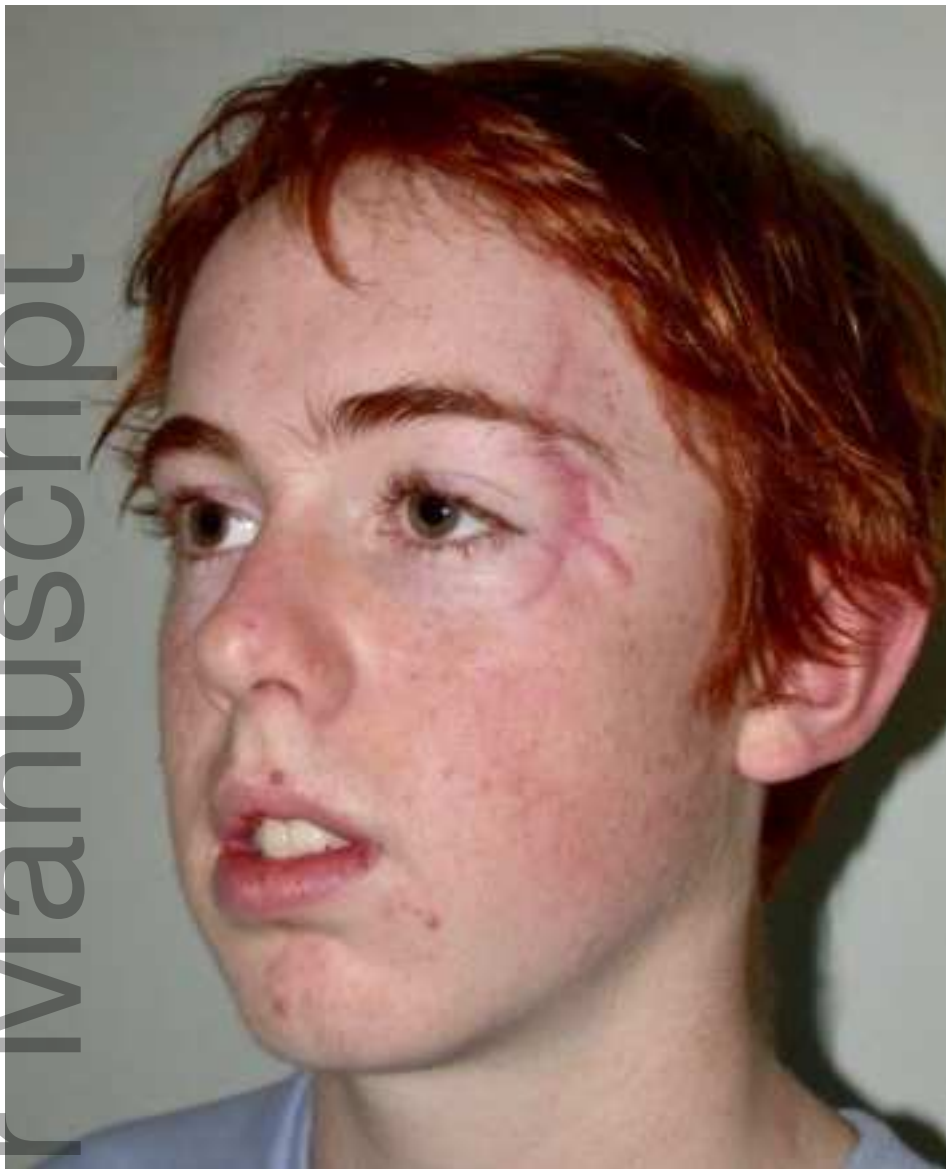adj_12591_f16(b).jpg



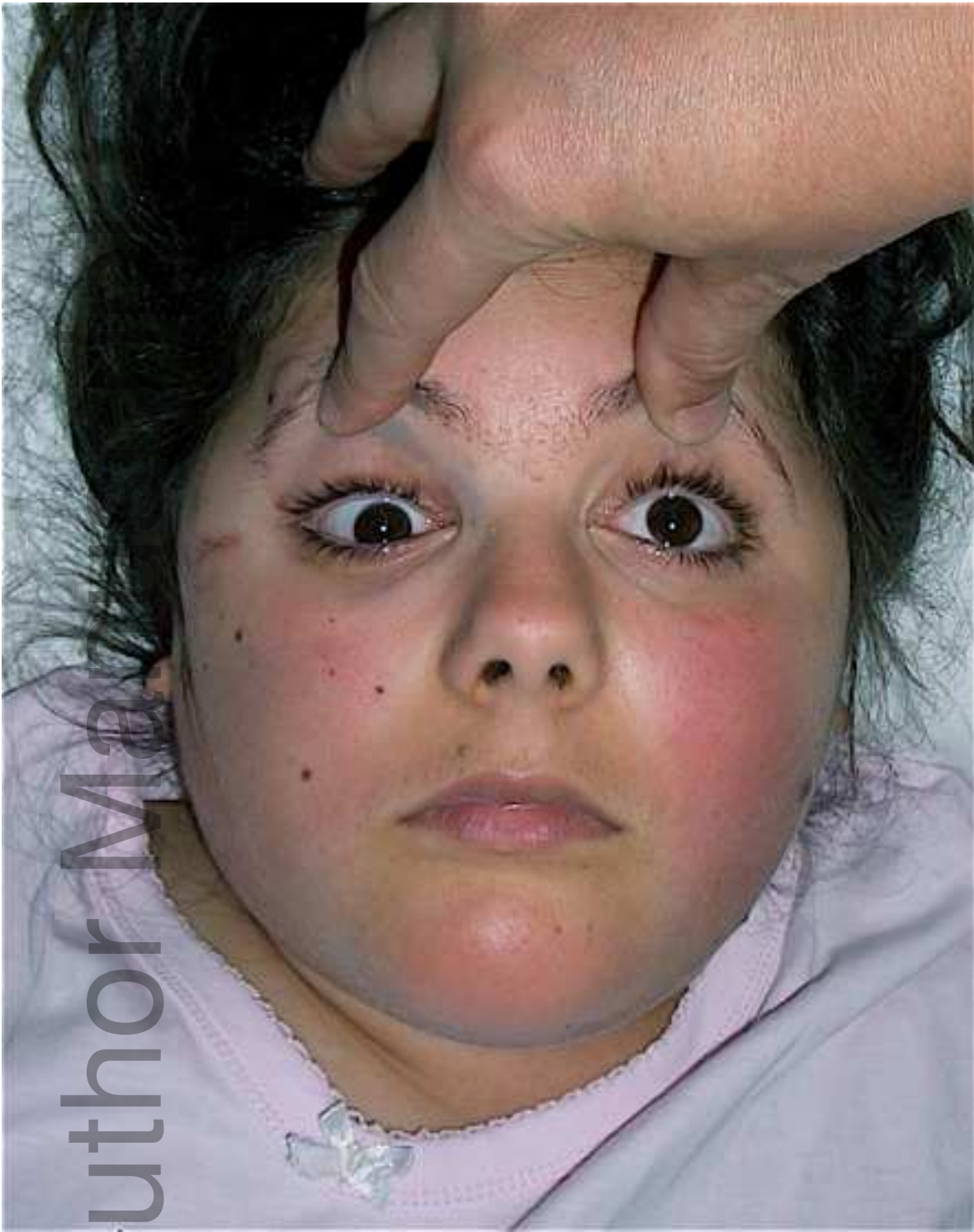adj_12591_f16(c).jpg



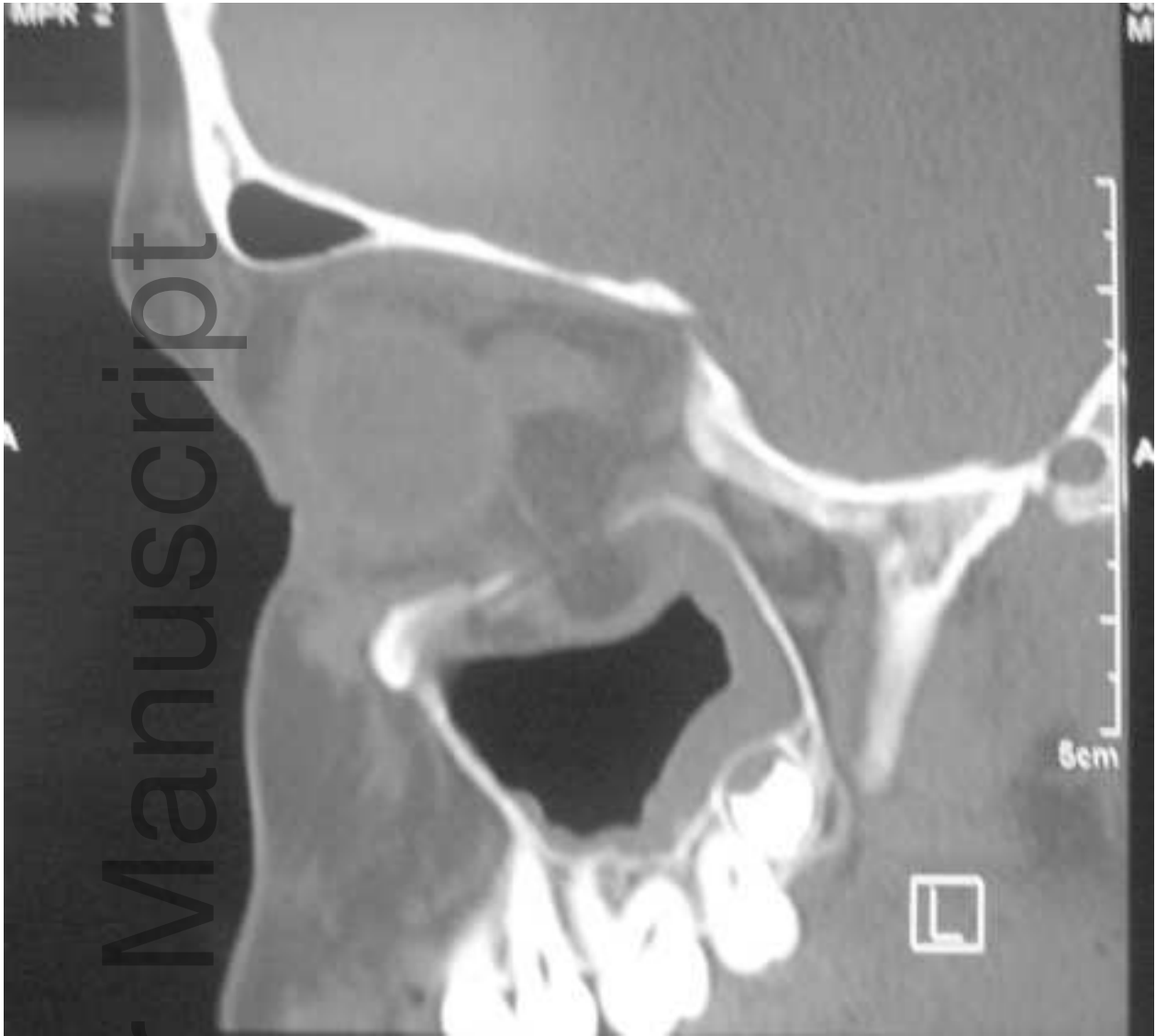adj_12591_f16(d).jpg



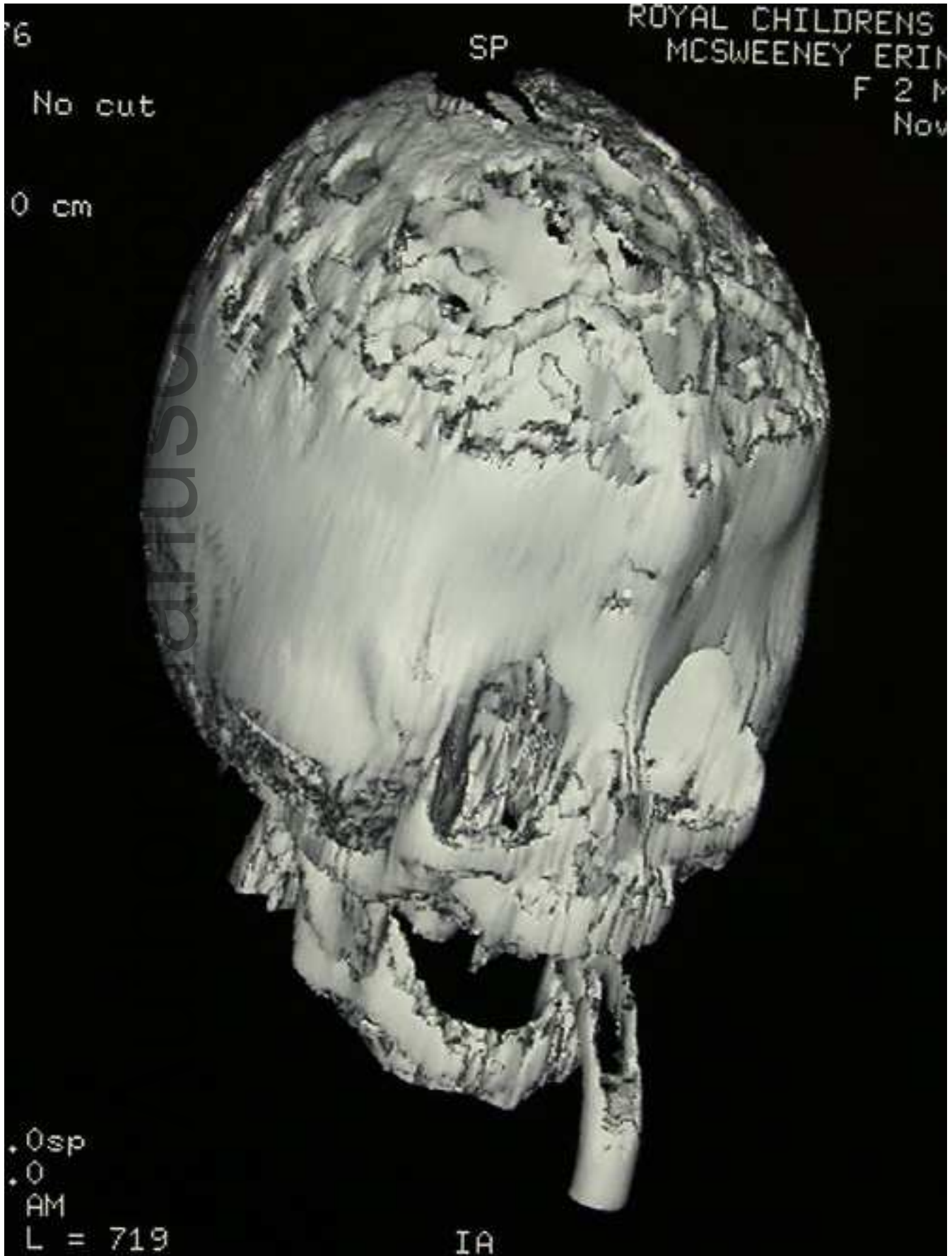
adj_12591_f16(e).jpg



adj_12591_f17(a).jpg

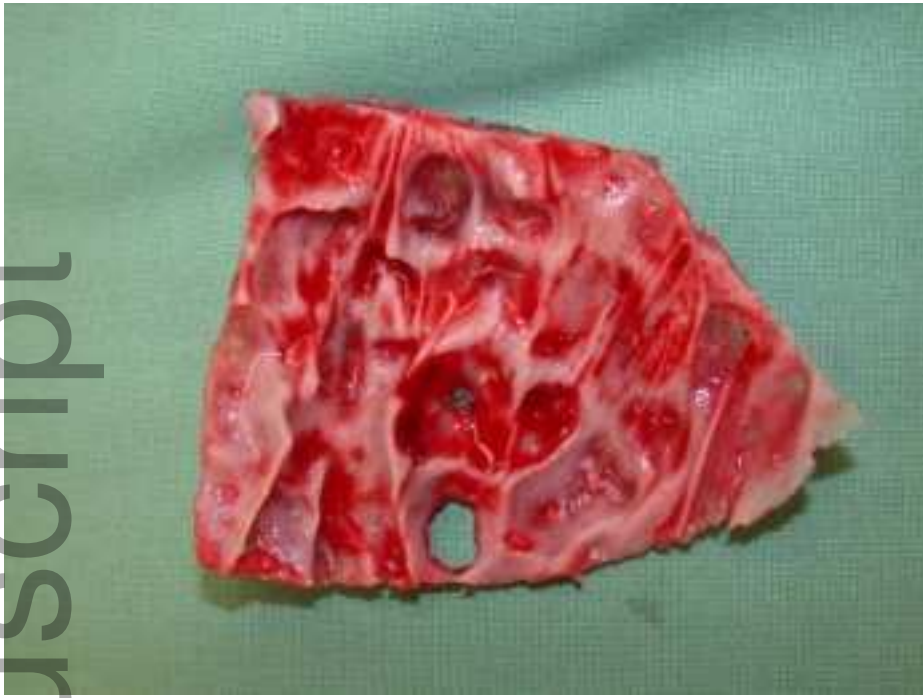

adj_12591_f17(b).jpg

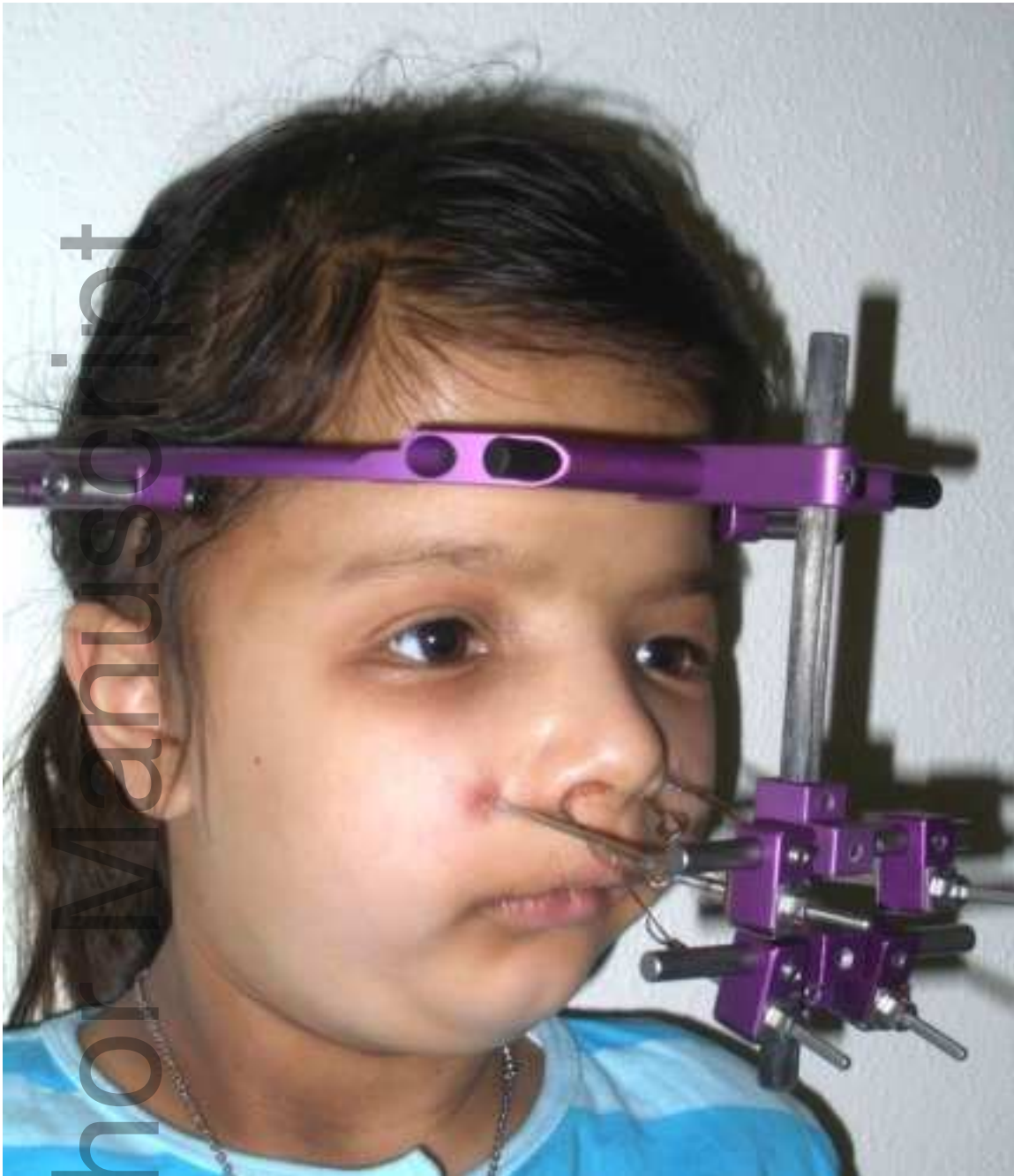


adj_12591_f2(a).jpg

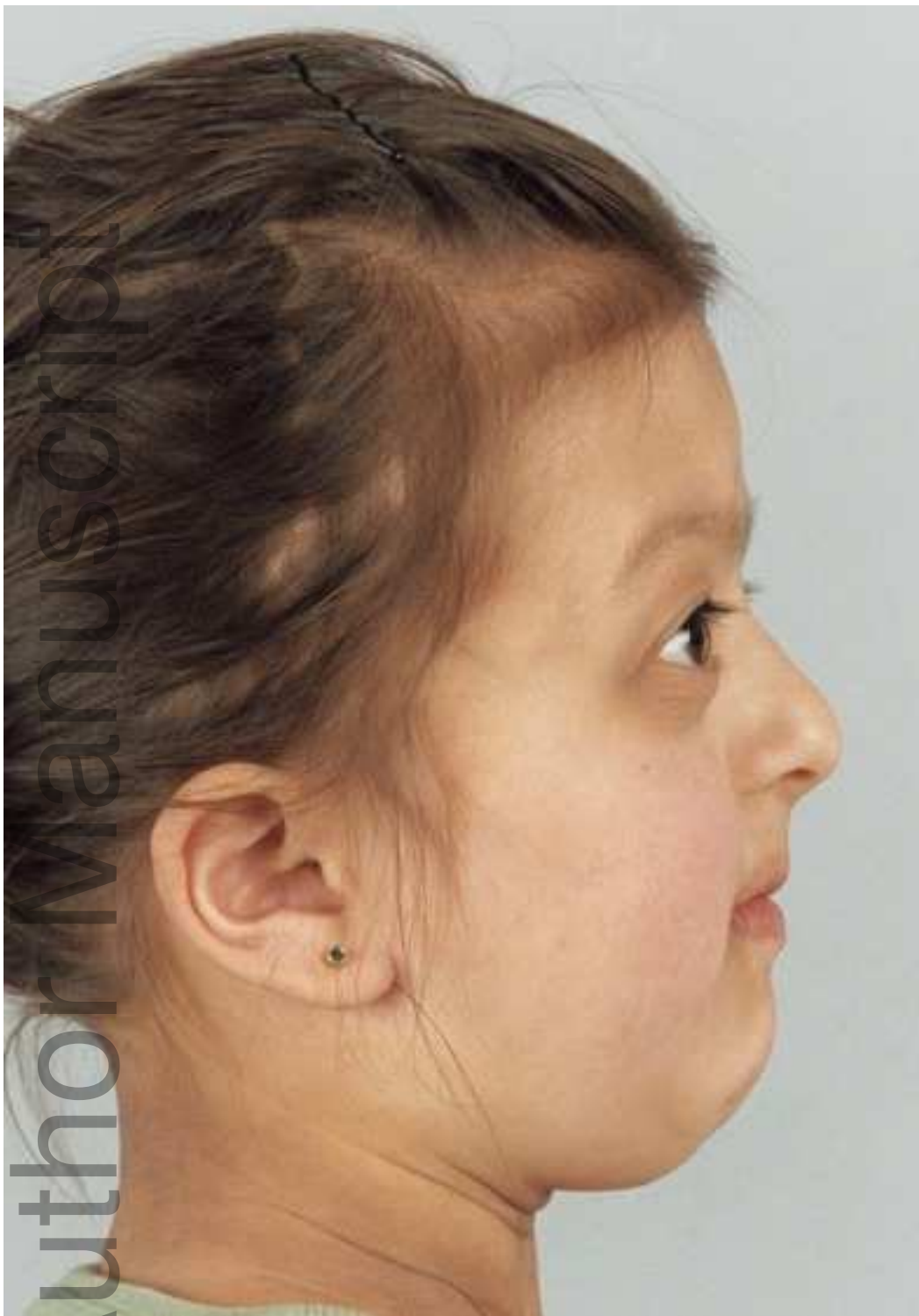This article is protected by copyright. All rights reserved



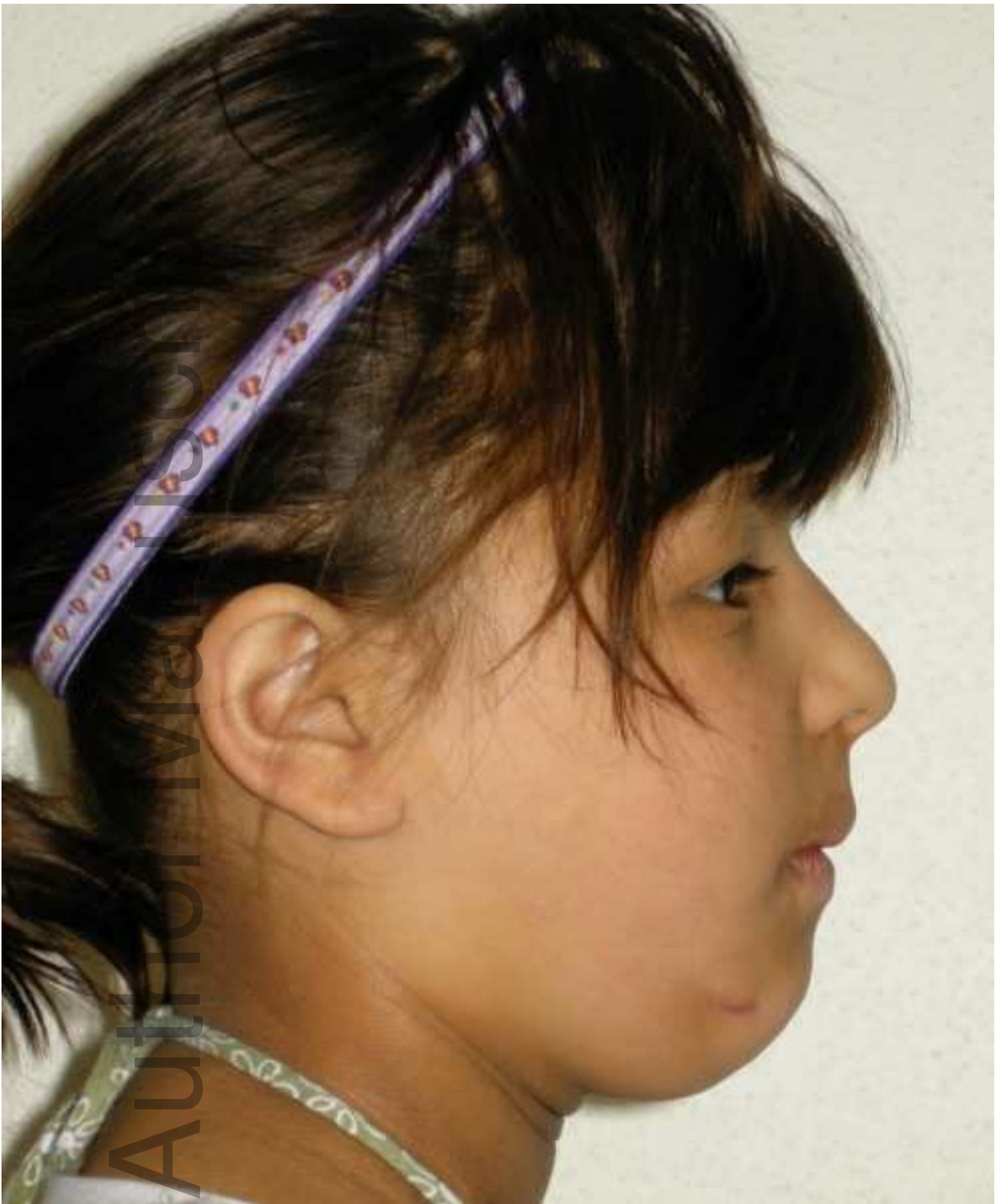adj_12591_f2(b).jpg



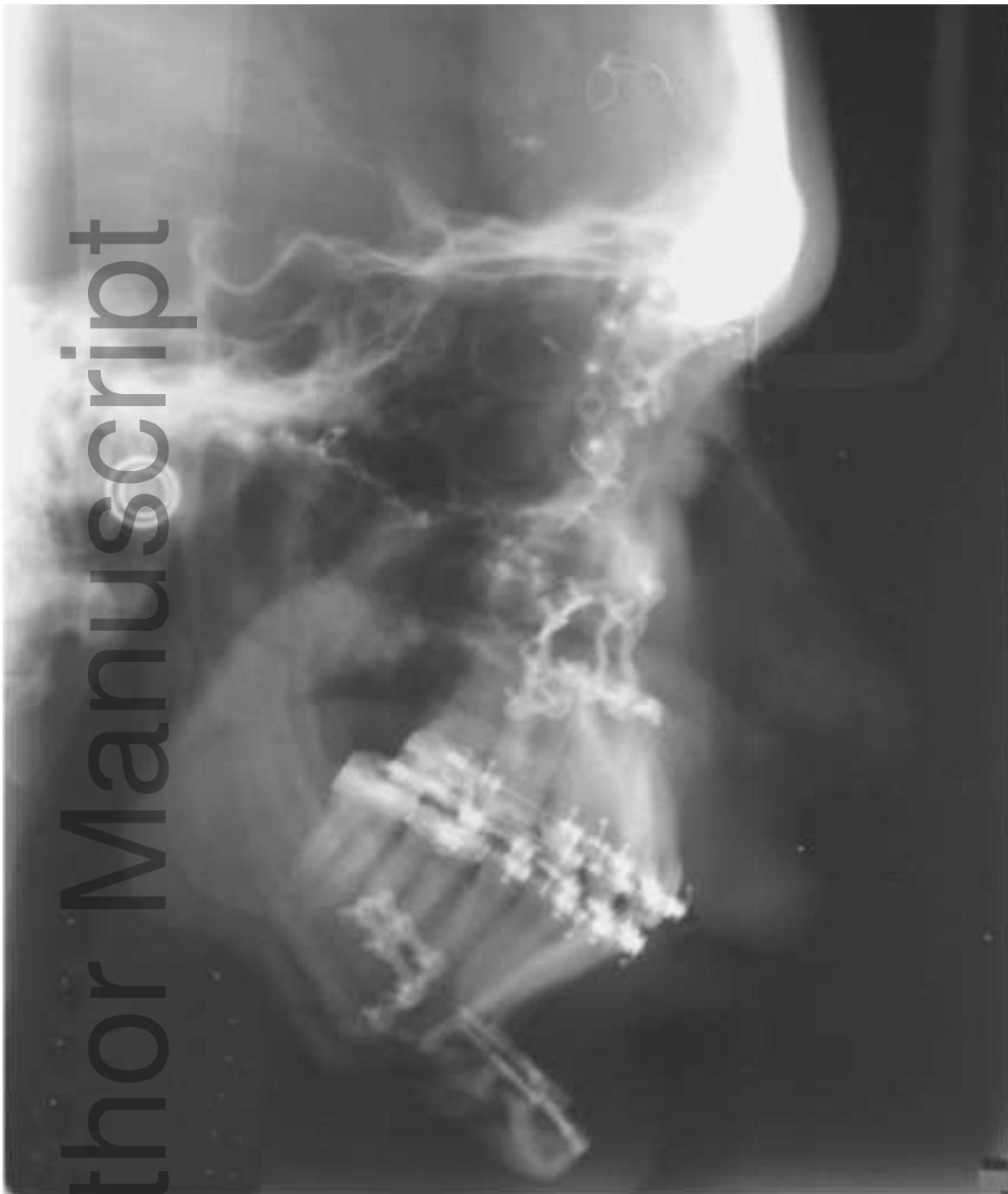adj_12591_f4(a).jpg



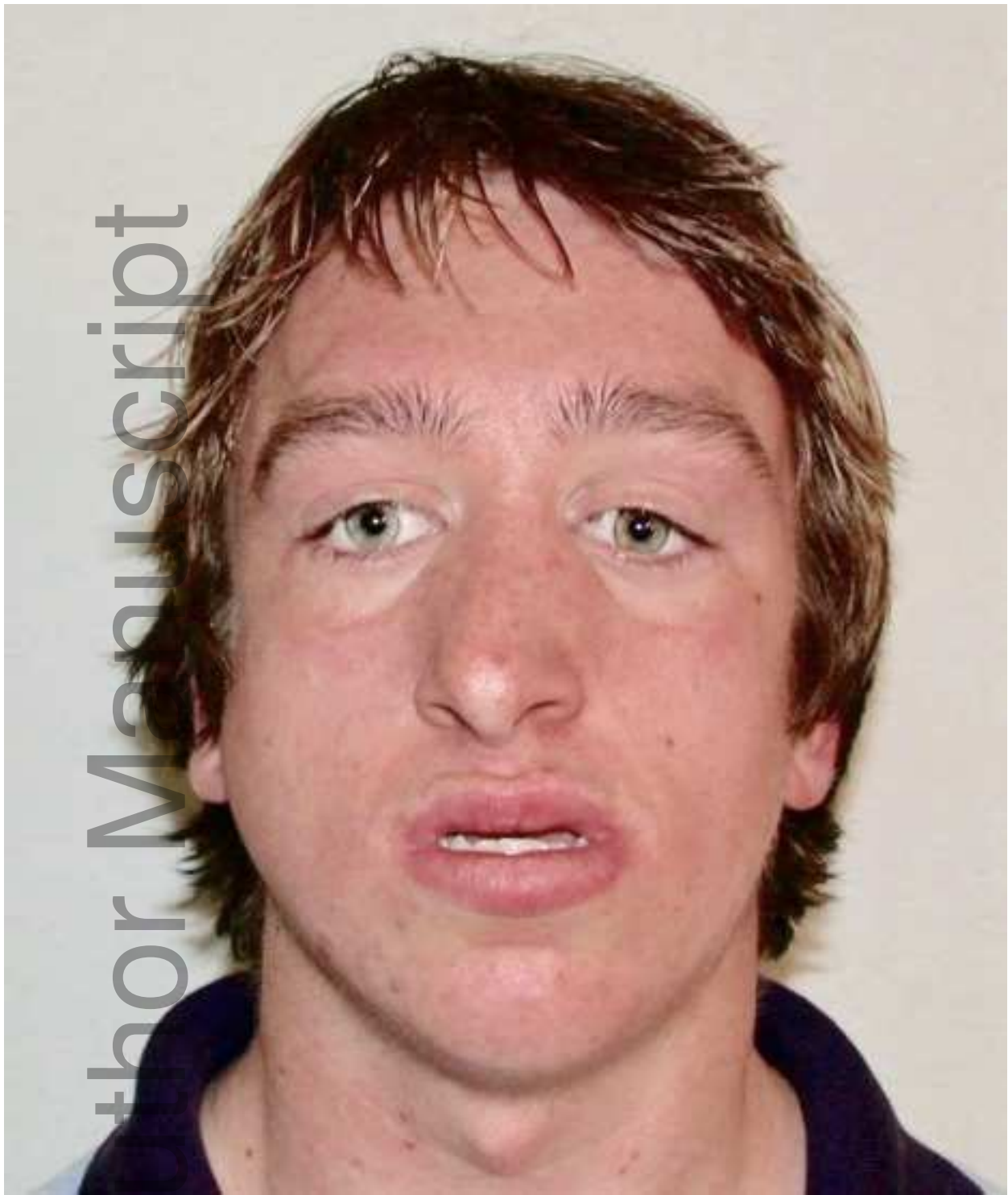adj_12591_f4(b).jpg



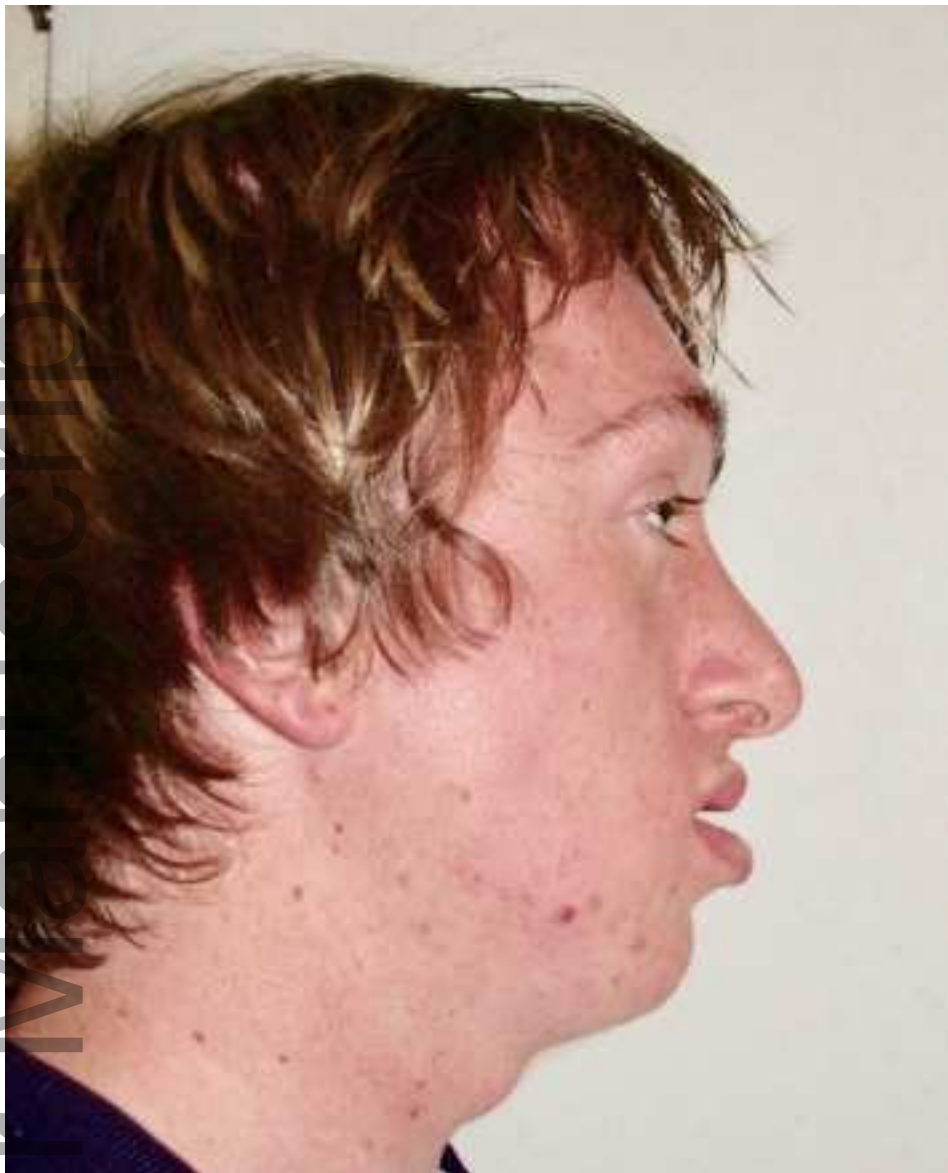adj_12591_f4(c).jpg



adj_12591_f50.jpg

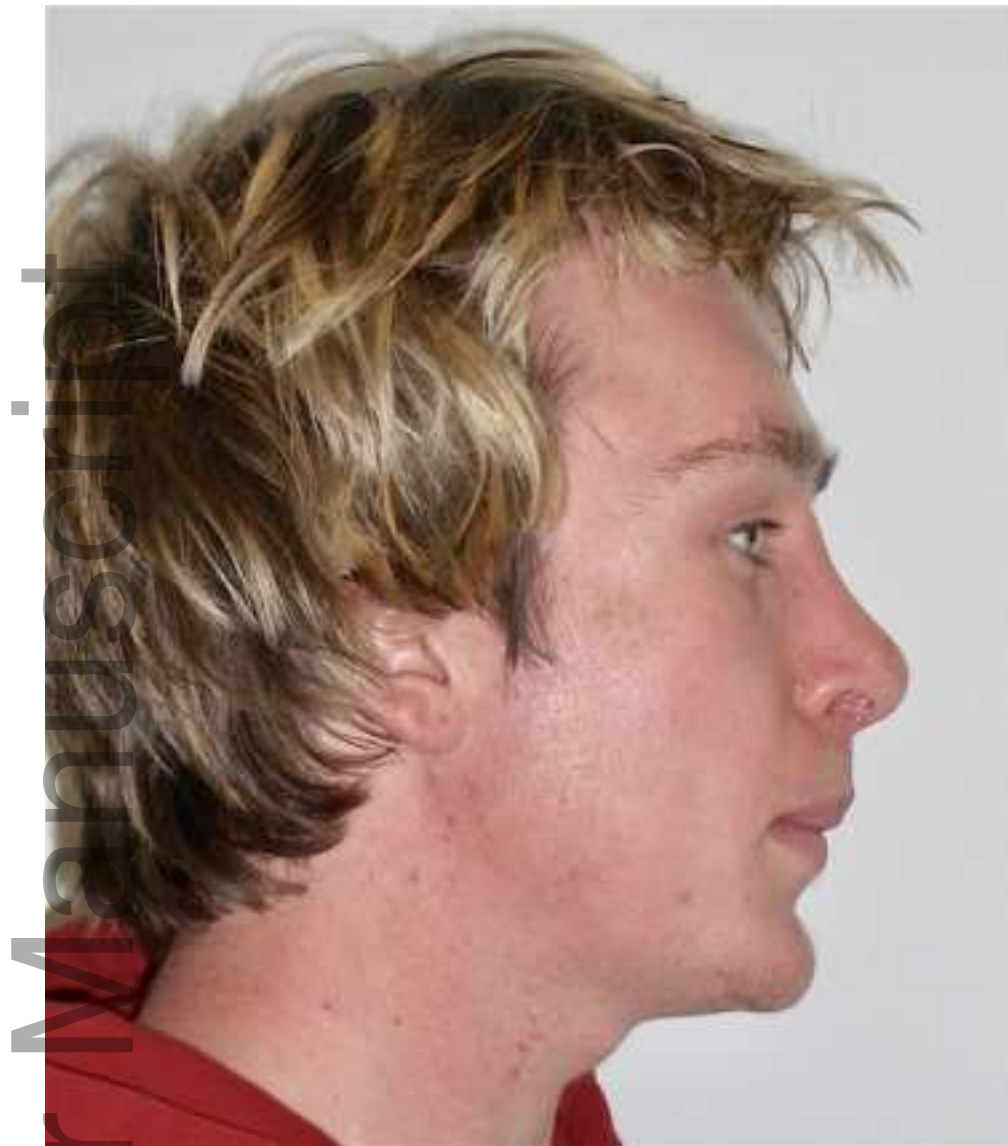

adj_12591_f5(a).jpg

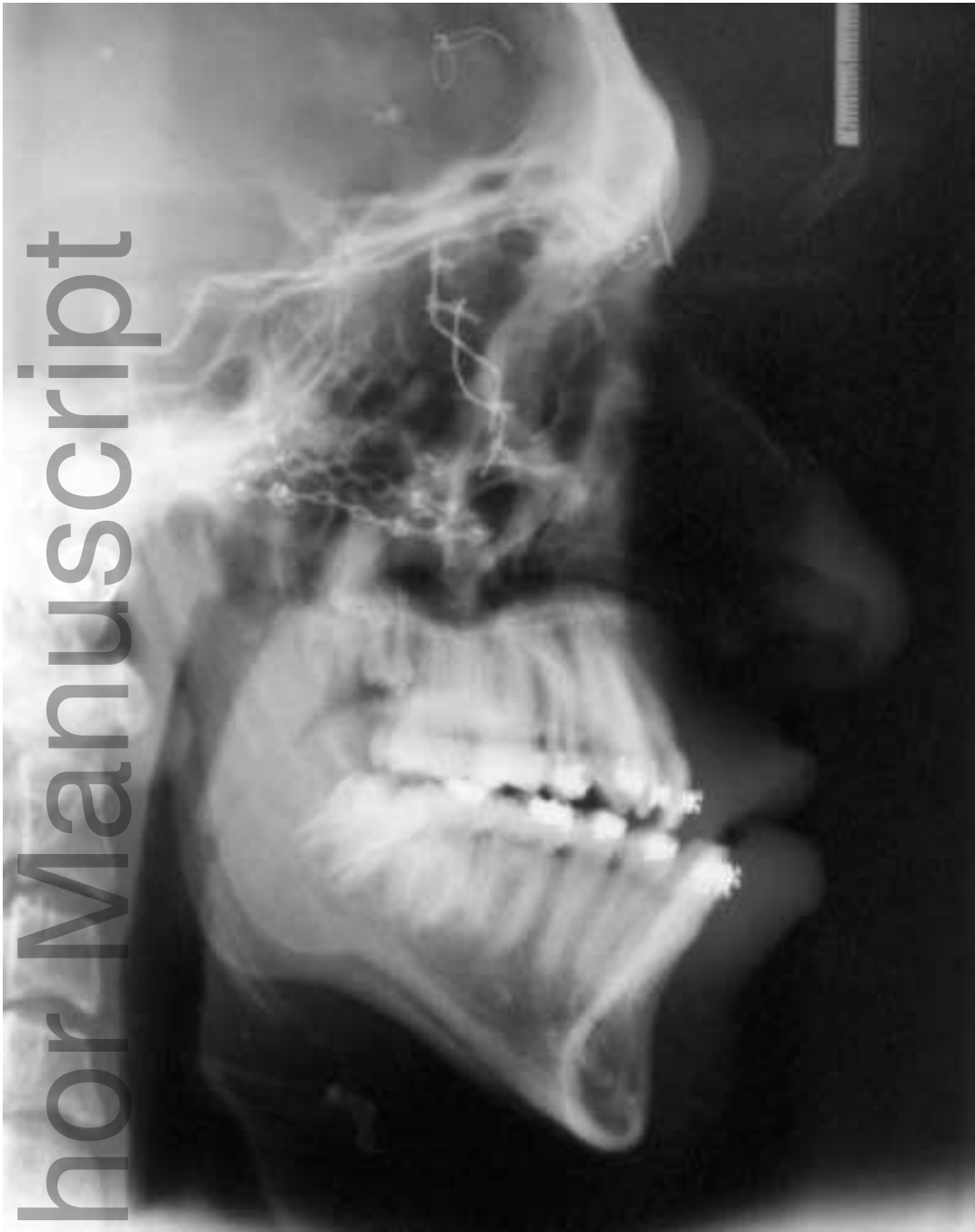

adj_12591_f5(b).jpg

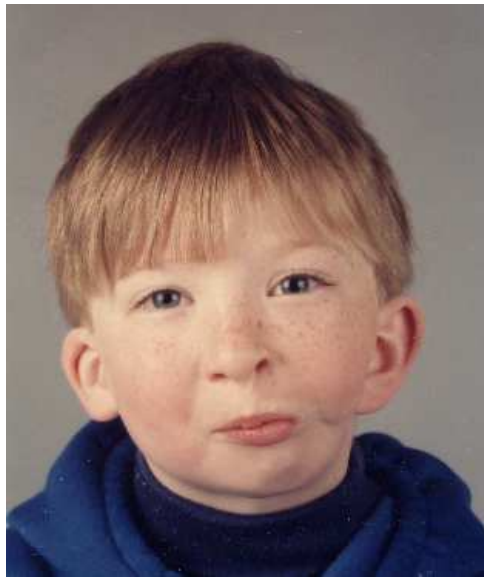



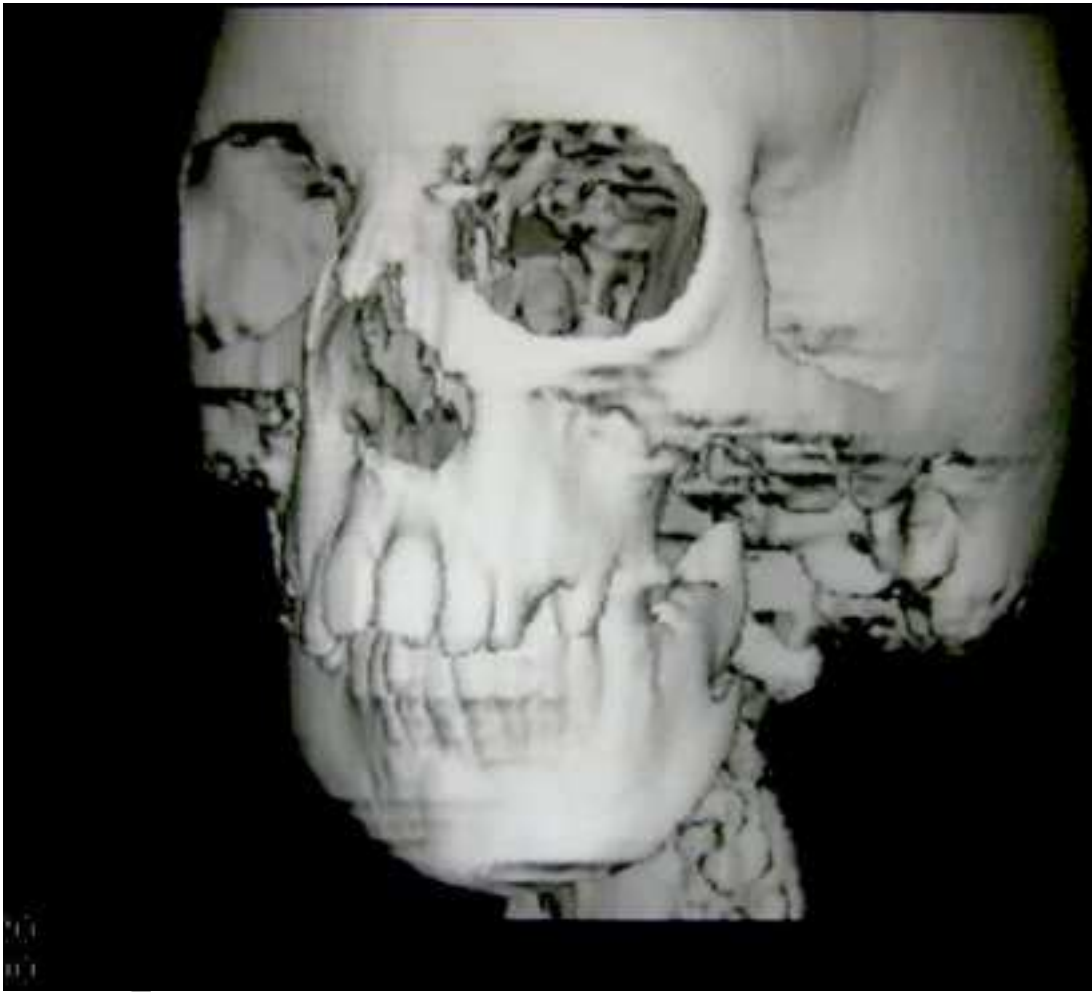
adj_12591_f5(d).jpg



adj_12591_f5(e).jpg



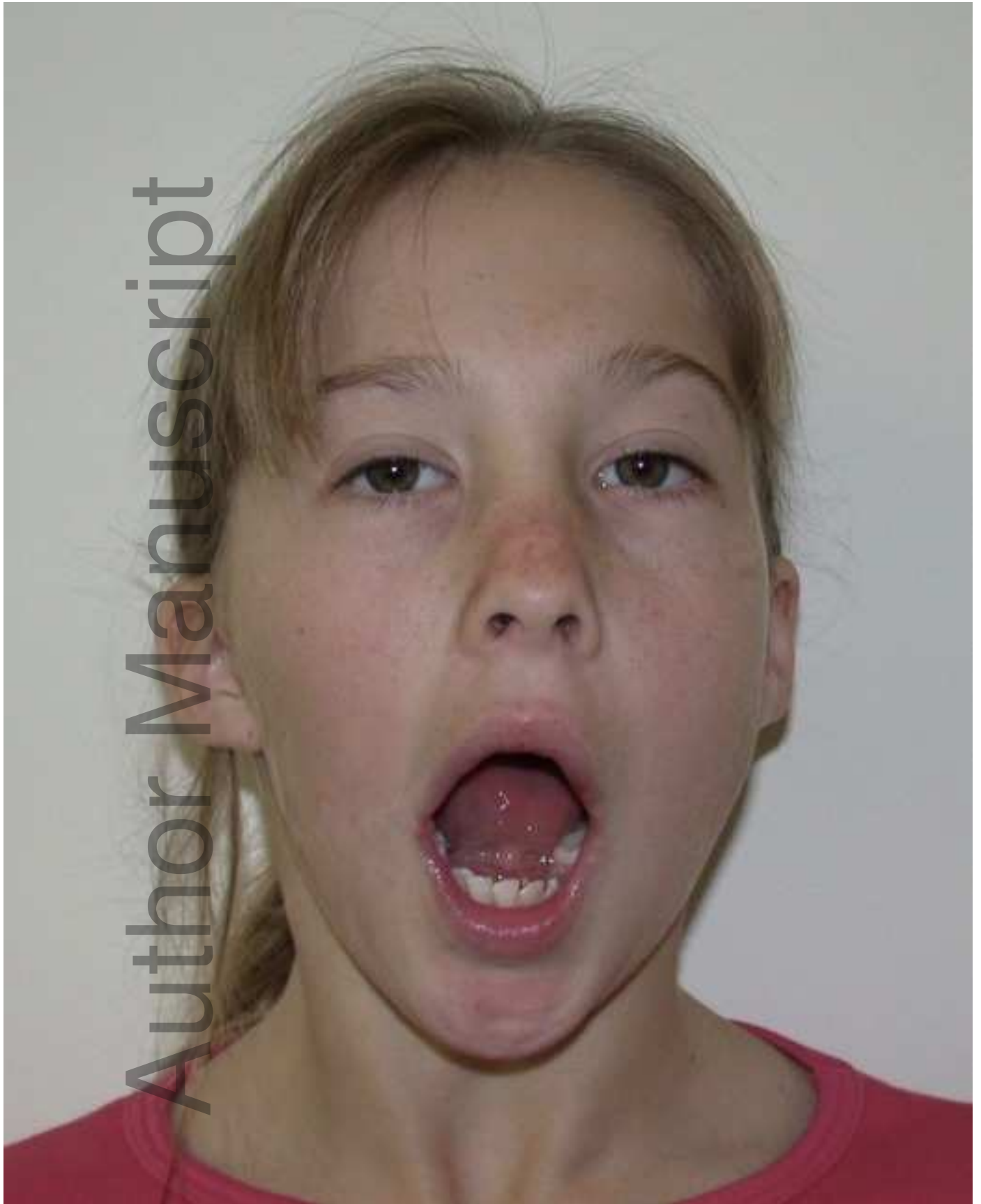adj_12591_f6(a).jpg



adj_12591_f6(b).jpg

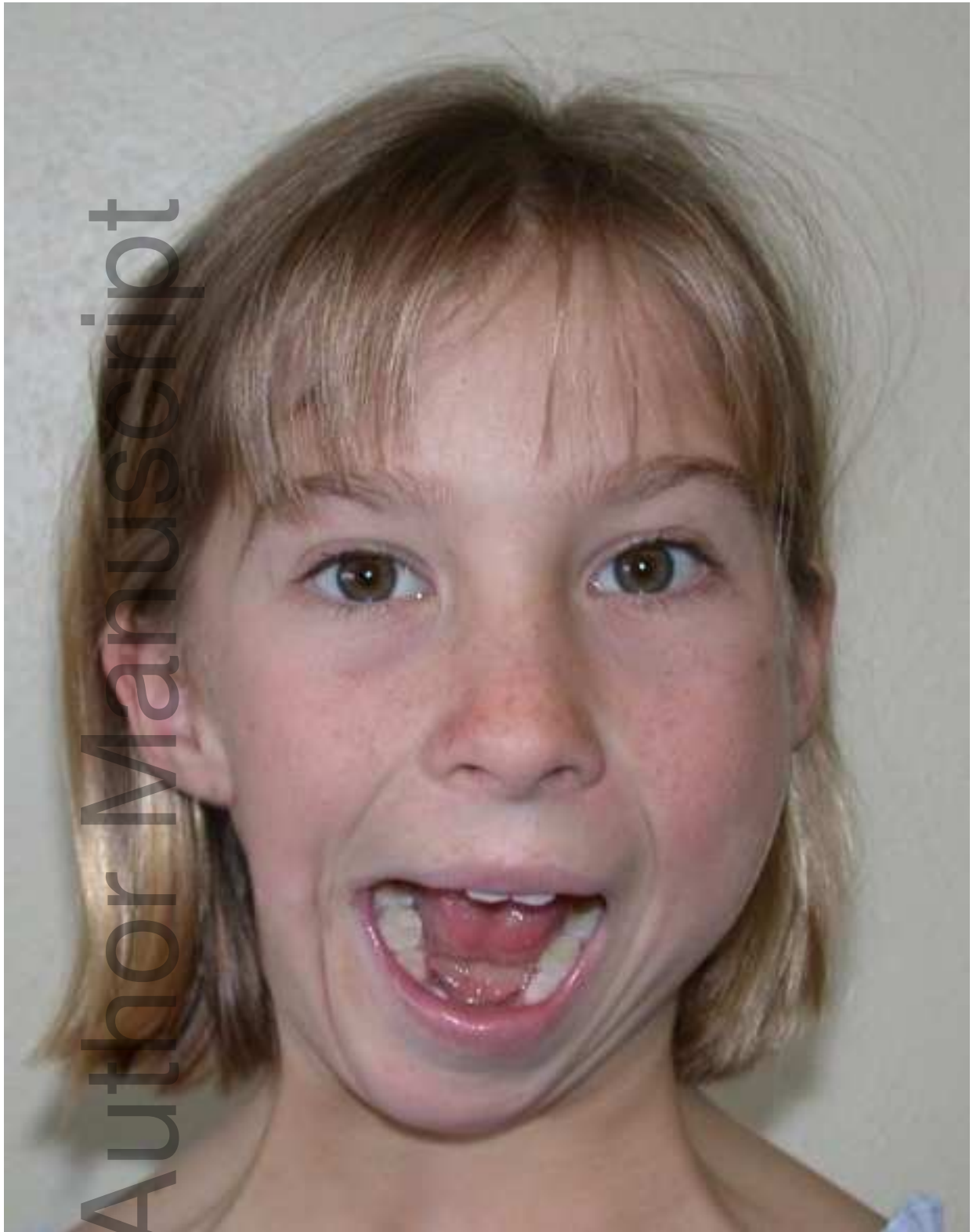Author N

Author Manuscript

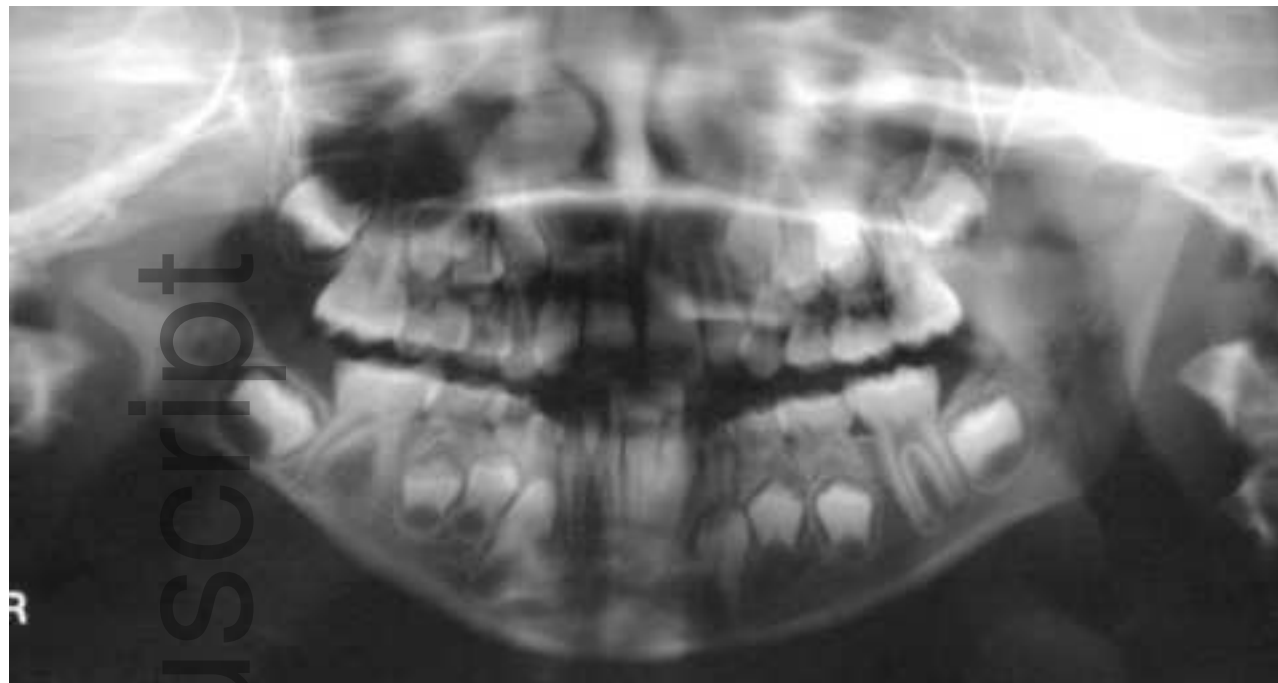


adj_12591_f70.jpg


This article is protected by copyright. All rights reserved



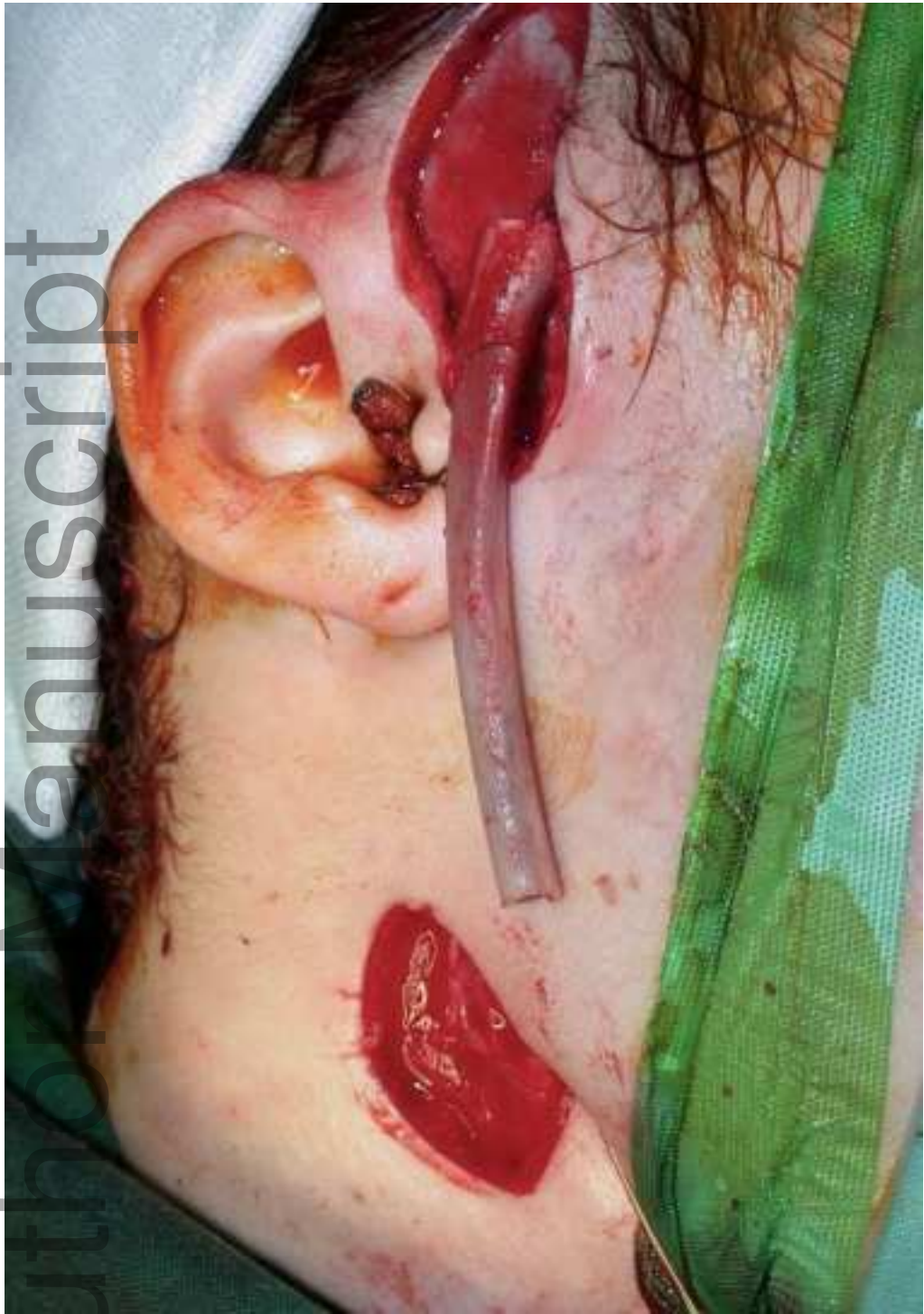adj_12591_f7(a).jpg



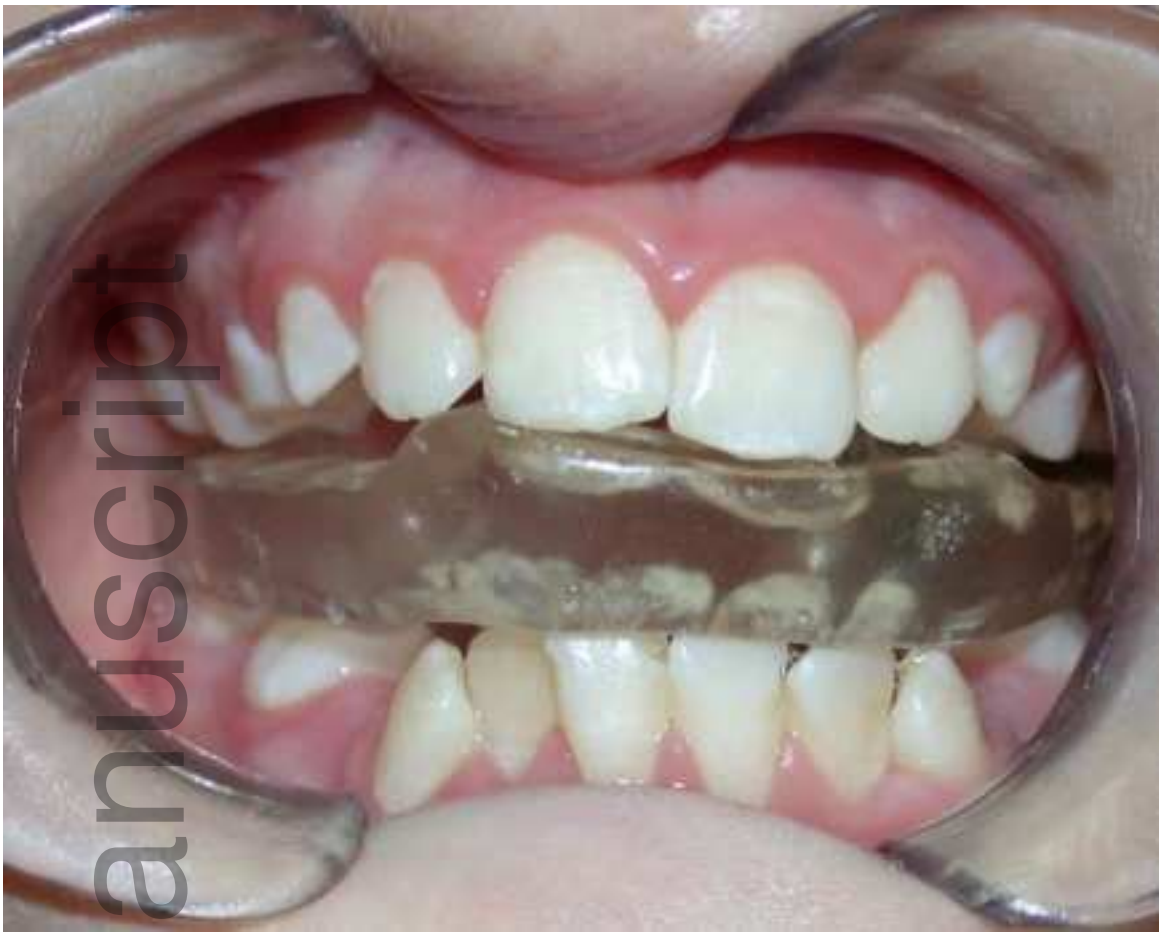adj_12591_f7(b).jpg



adj_12591_f7(c).jpg

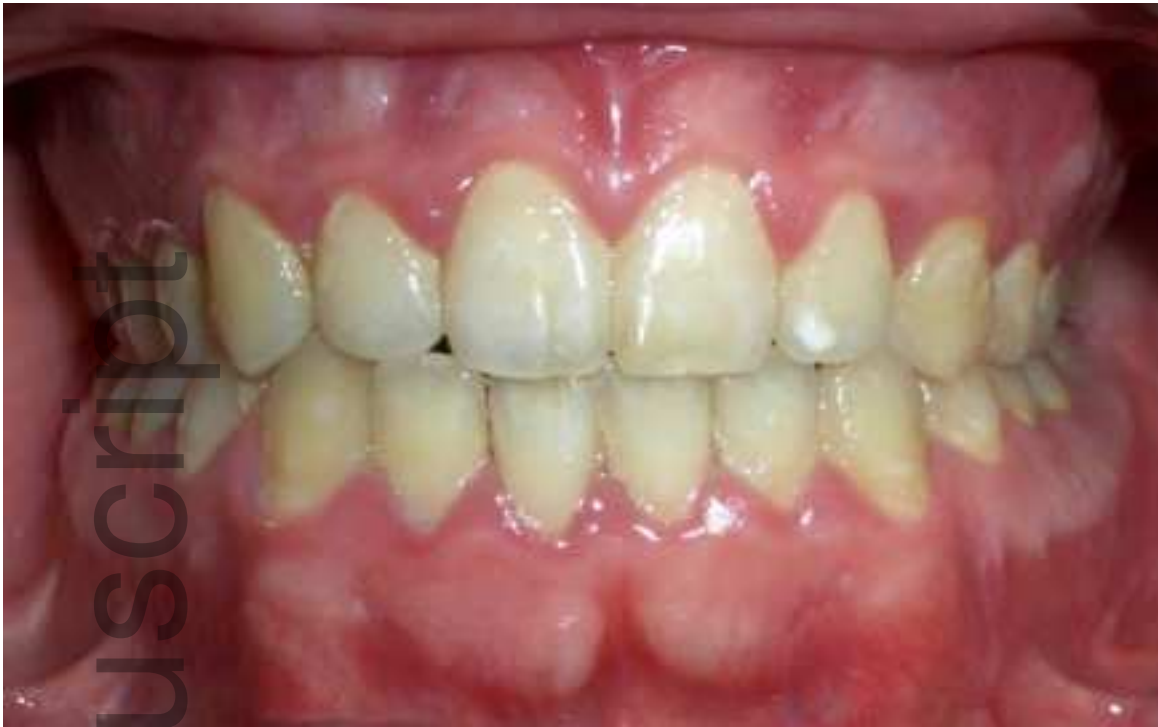

adj_12591_f7(d).jpg



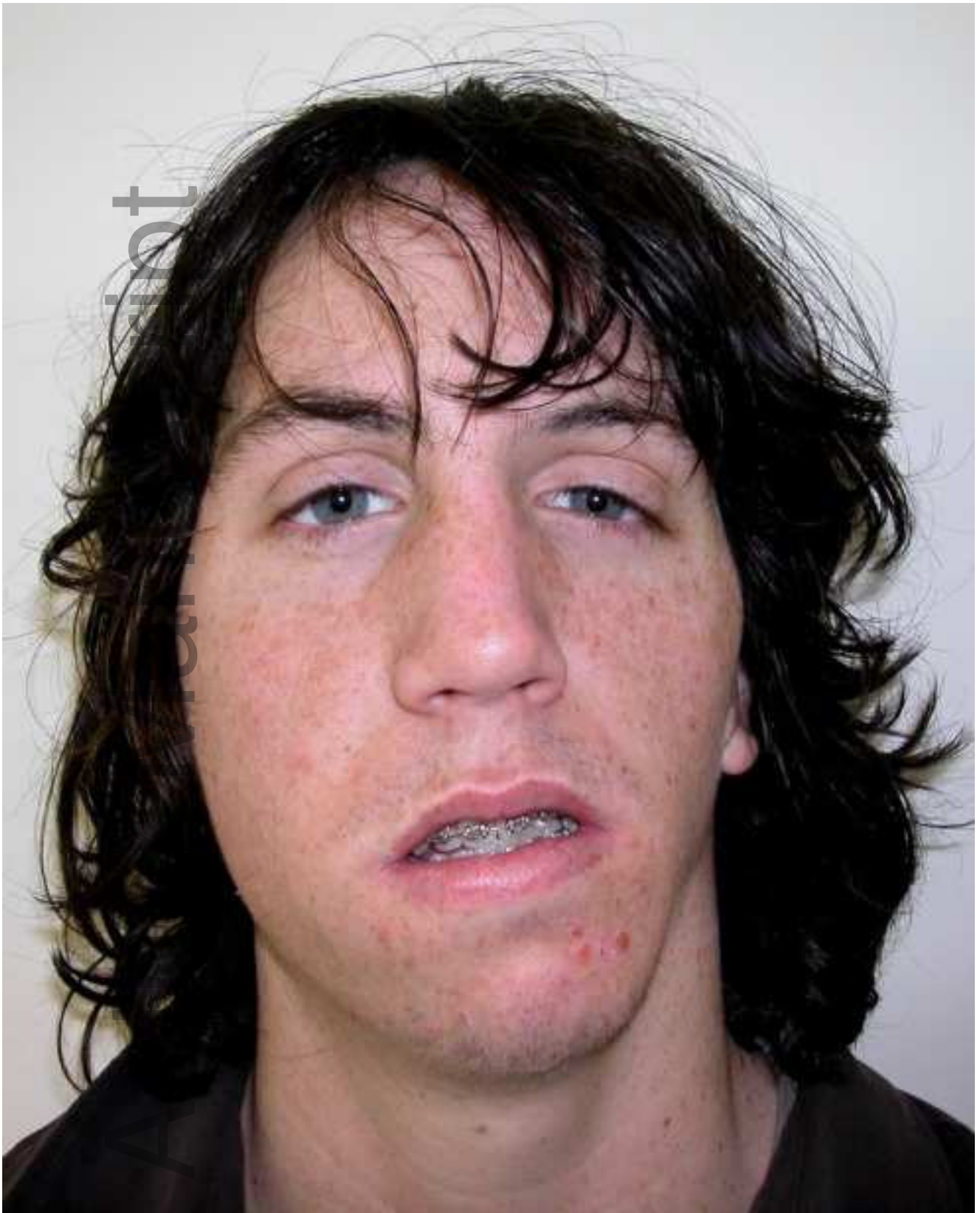
adj_12591_f7(e).jpg

Author Manuscript

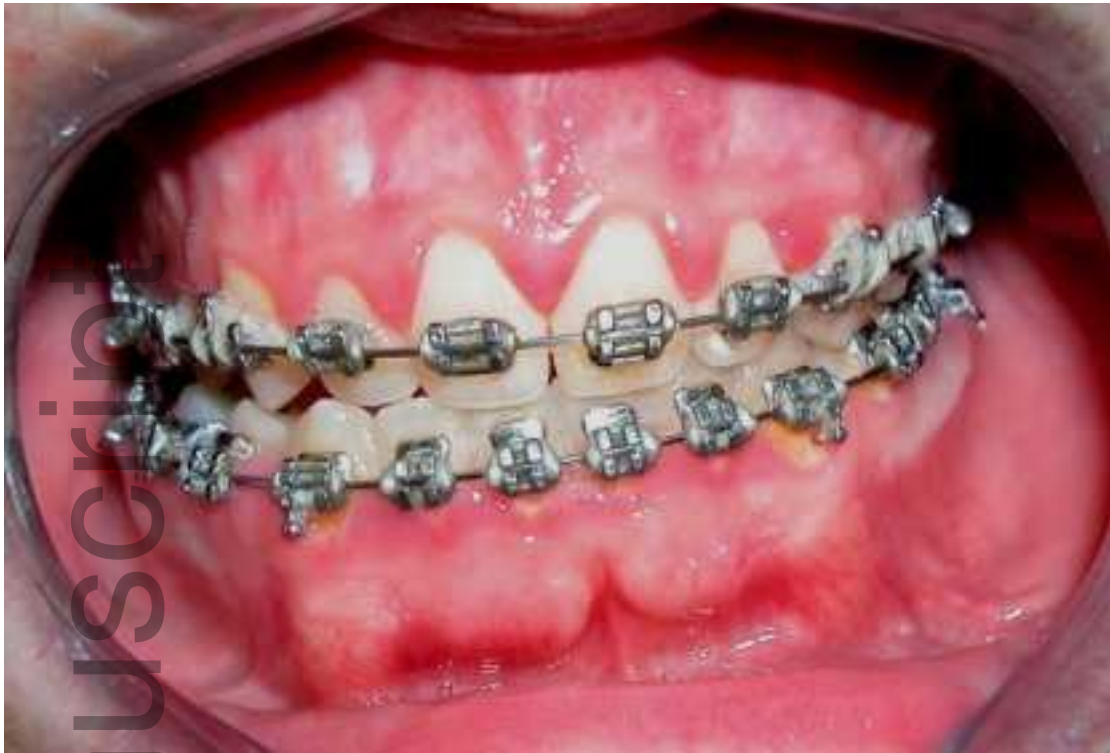

adj_12591_f80.jpg

Author Manuscript

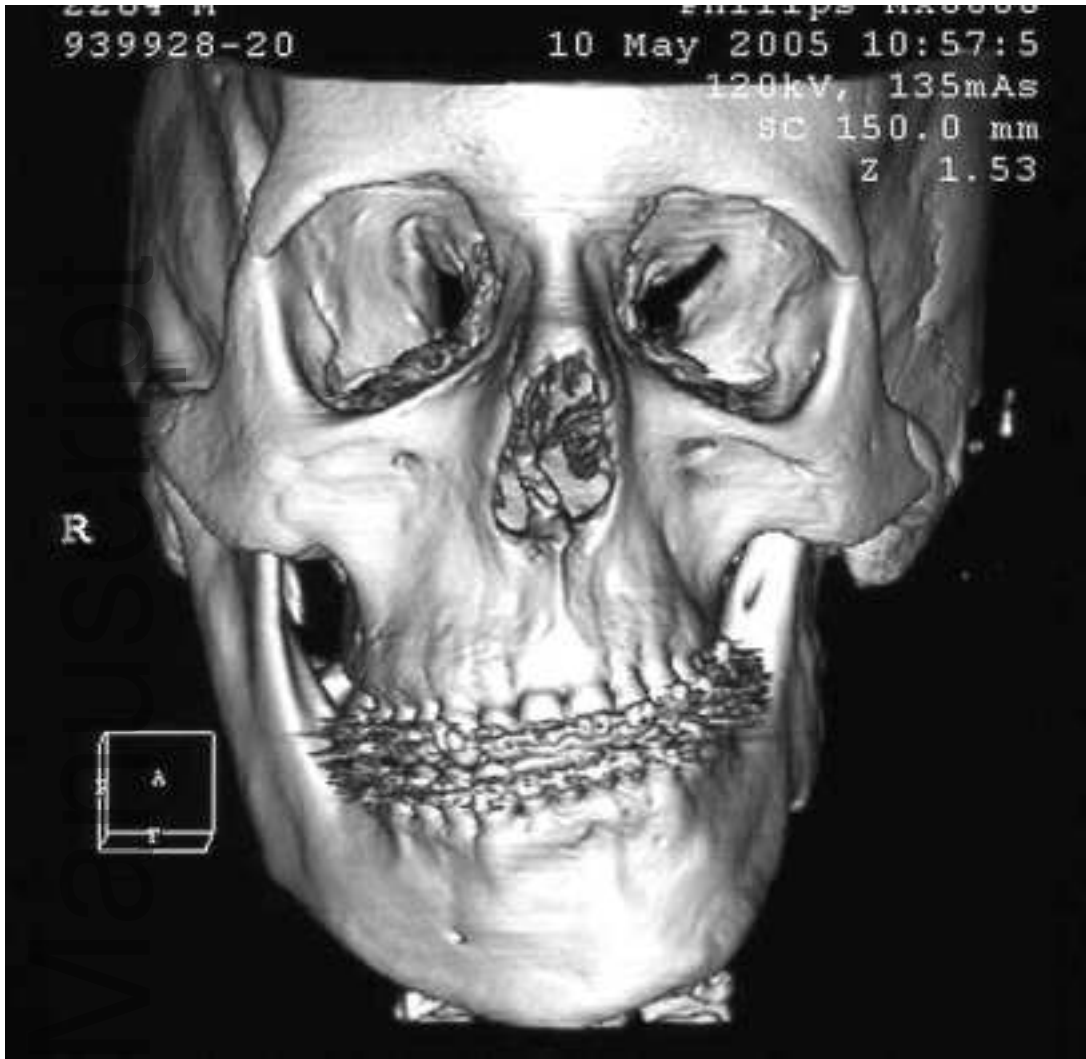

adj_12591_f8(a) (2).jpg



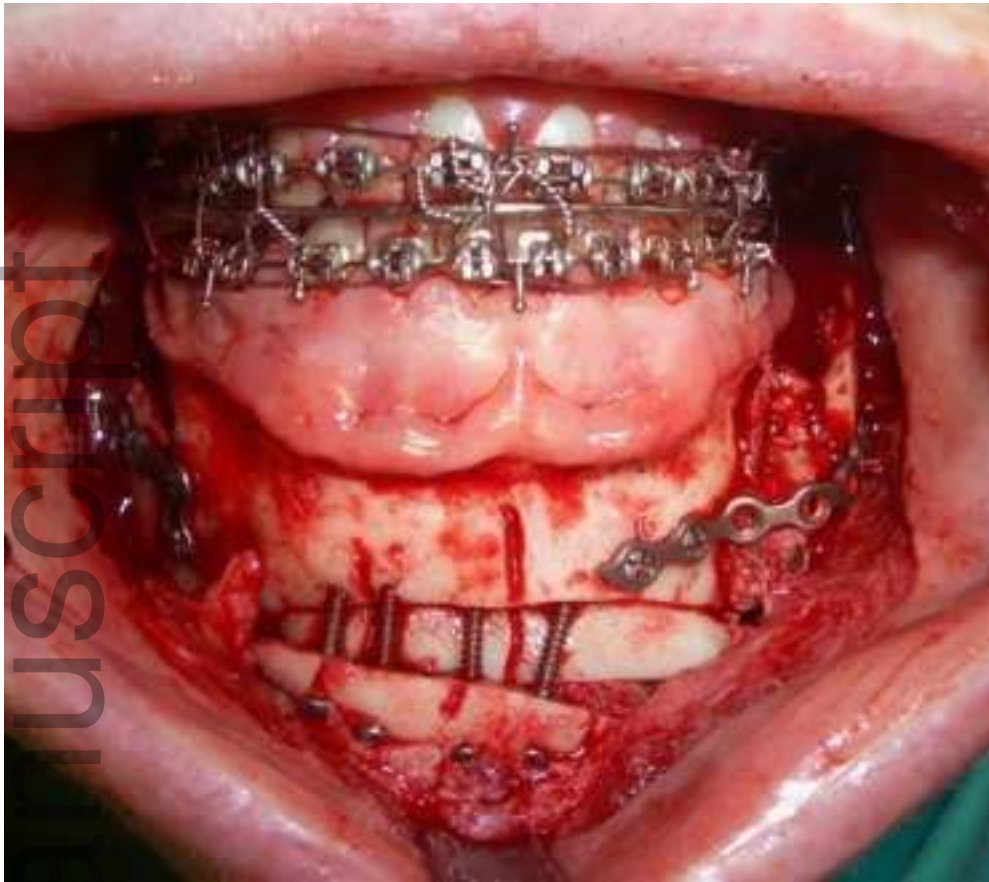
adj_12591_f8(b).jpg

Author Manuscript



adj_12591_f8(c).jpg

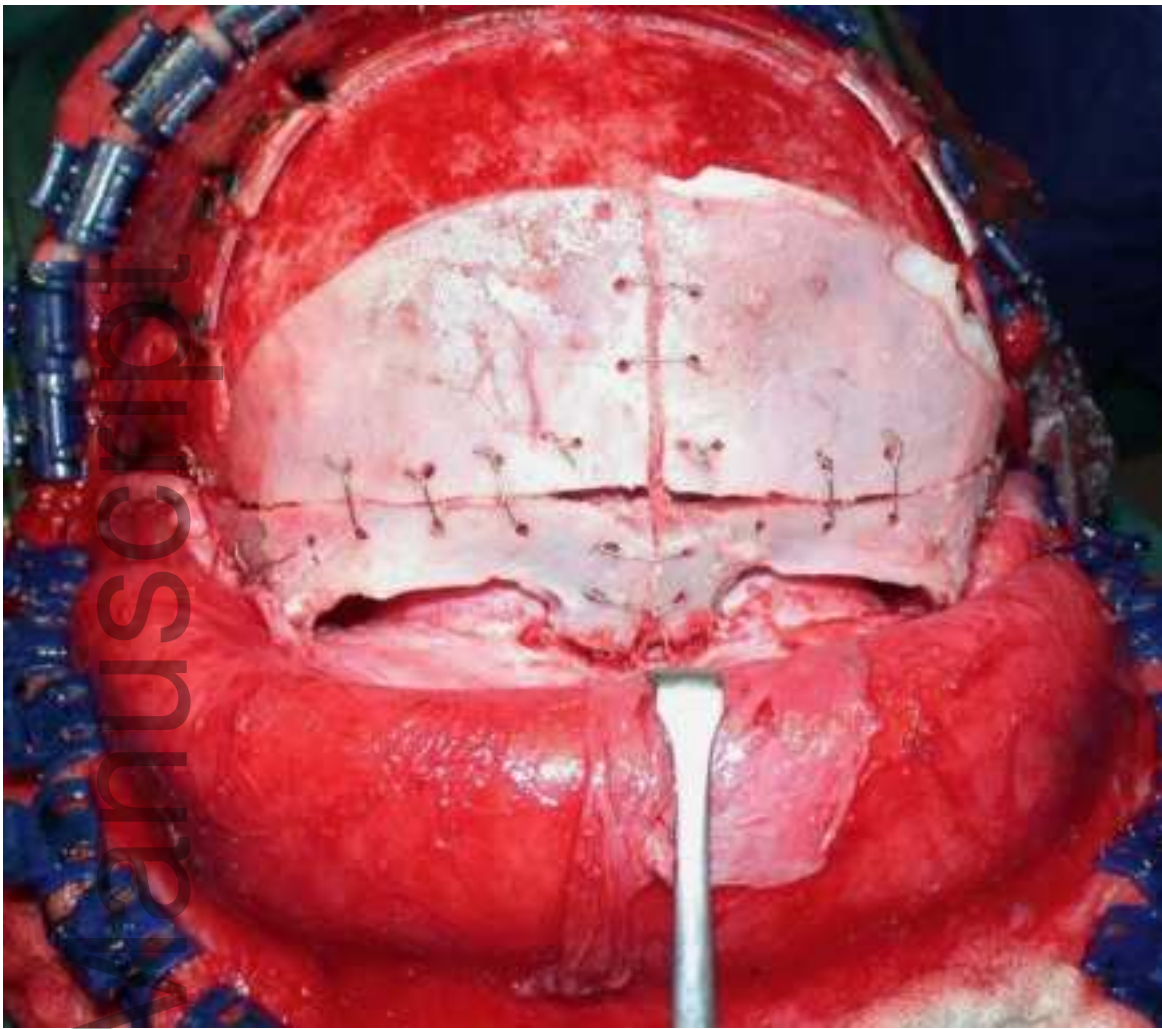
Author



adj_12591_f8(d).jpg



This article is protected by copyright. All rights reserved
adj_12591_f8(e).jpg



adj_12591_f3.jpg

Author Manuscript