



Minerva Access is the Institutional Repository of The University of Melbourne

Author/s:

Wong, MCG;Kalman, JM;Ling, LH;Medi, C;Teh, A;Lee, G;Kumar, S;Morton, JB;Kistler, PM

Title:

Left septal atrial tachycardias: Electrocardiographic and electrophysiologic characterization of a paraseptal Focus

Date:

2013-04-01

Citation:

Wong, M. C. G., Kalman, J. M., Ling, L. H., Medi, C., Teh, A., Lee, G., Kumar, S., Morton, J. B. & Kistler, P. M. (2013). Left septal atrial tachycardias: Electrocardiographic and electrophysiologic characterization of a paraseptal Focus. *Journal of Cardiovascular Electrophysiology*, 24 (4), pp.413-418. <https://doi.org/10.1111/jce.12049>.

Publication Status:

Accepted manuscript

Persistent Link:

<https://hdl.handle.net/11343/41867>

Left Septal Atrial Tachycardias: Electrocardiographic & Electrophysiologic Characterization of a Paraseptal Focus

Short Title: Left Septal Atrial Tachycardias

Michael C.G. Wong^{1,2,4}, MBBS, Jonathan M. Kalman^{1,2}, MBBS, PhD, Liang-Han Ling¹⁻⁴, MBBS, Caroline Medi^{1,2,4}, MBBS, Andrew Teh^{1,2}, MBBS, PhD, Geoffrey Lee^{1,2,4}, MBChB, Saurabh Kumar^{1,2}, BSc (Med)/MBBS, Joseph B. Morton¹, MBBS, PhD, Peter M. Kistler²⁻⁴, MBBS, PhD

¹The Department of Cardiology, Royal Melbourne Hospital

²The Department of Medicine, University of Melbourne, Parkville, Victoria

³The Baker IDI Research Institute, Melbourne

⁴The Heart Centre, The Alfred Hospital, Melbourne, Australia

Correspondence to: Associate Professor Peter Kistler, The Heart Centre, The Alfred Hospital, Commercial Road, Melbourne, Australia 3004, Phone: +61 3 9076 6525 Fax: +61 3 9076 2461, Email: peter.kistler@bakeridi.edu.au

This research is supported in part by the Victorian Government's Operational Infrastructure Funding.

Drs. Wong & Ling are supported by National Heart Foundation of Australia (NHF) Postgraduate Scholarships. Drs. Medi & Teh were supported by National Heart Foundation of Australia (NHF) Postgraduate Scholarships. Dr Lee is supported by an Australian National Health and Medical Research Council (NHMRC) Postgraduate Research Scholarship. Dr Kumar is supported by a co-funded NHMRC/NHF Postgraduate Scholarship (ID 628996). Associate Professor Kistler is supported by a practitioner fellowship from the Australian National Health and Medical Research Council (NHMRC). All other authors have reported that they have no financial relationships to disclose. This research is supported in part by the Victorian Government's Operational Infrastructure Funding.

No disclosures.

ABSTRACT

Objective: To characterize the electrocardiographic and electrophysiological features of focal atrial tachycardia (FAT) originating from the left septum (LS).

Background: FAT is recognised to occur at predefined anatomic locations rather than randomly throughout the atria. We describe the ECG and EP features of ATs originating from the LS as an important site for apparent perinodal tachycardias.

Methods: Nine patients presenting with LS FAT from a consecutive series of 384 underwent EP/RFA for symptomatic FAT.

Results: The mean age was 56 ± 12 years; 7F with symptoms for 36 ± 28 months. P wave morphology (PWM) was negative/positive in lead V1 and across the precordial leads and negative or negative/positive in inferior leads in all patients. Tachycardia was incessant in 6 out of 9 patients with a mean tachycardia cycle length was 421 ± 56 ms. His A was ahead of P wave in all patients (mean -15 ± 5 ms) and earlier than CS proximal (mean 4 ± 9 ms). Successful acute focal ablation achieved at a mean of 31 ± 12 ms ahead of Pwave with no recurrences at a mean follow up of 30 ± 28 months.

Conclusion: Although the left septum is an uncommon site for focal AT an awareness of this location for harboring foci is particularly important when mapping apparently right-sided septal tachycardias.

Key Words: atrial tachycardia, septal tachycardia, catheter ablation, focal atrial tachycardia, electroanatomical mapping

INTRODUCTION

Focal atrial tachycardia (AT) is an important cause of supraventricular tachycardia, which is more often incessant (1) and resistant to pharmacologic therapy than reentrant forms of SVT (2). It has become accepted that focal AT does not occur randomly throughout the atria but anchor to key anatomic sites determined by an interplay between atrial architecture and electrophysiology. Previous studies have defined common locations in the right atrium at the crista terminalis, tricuspid annulus and CS ostium and in the left atrium predominantly at PV ostia and the superior mitral annulus (2-7).

Successful ablation of focal tachycardias occurring in close vicinity to the interatrial septum may be challenging. Mapping is required in close vicinity to the AV node, and neighboring sites that require transseptal access or mapping of the aortic root must also be considered. The left septum although uncommon is an important foci that may masquerade as an apparent perinodal tachycardia. Although tachycardias arising from the left septum have been described in isolated case series, there is a lack of detailed information in a larger series (8, 9). In this study, we report the electrocardiographic and electrophysiological characteristics of AT arising from the left septum.

METHODS

Study population

We report 9 patients from a consecutive series of 384 patients undergoing RFA for symptomatic focal AT between 1997 and 2012. All patients had clinically documented paroxysmal or incessant AT referred for electrophysiological (EP) study and RFA after informed written consent. Patients were studied in the fasted awake state with minimal use of

sedation. Antiarrhythmic drugs were withheld at least five half-lives before EP study. There were 2 patients who had been taking amiodarone.

Baseline Electrophysiological Study

Catheter positioning and study technique used at our institution for focal AT ablation have previously been described (4). Catheters were positioned in the following manner: (1) CS catheter (10-pole, 2-5-2-mm interelectrode spacing) positioned with the proximal bipole at the ostium of the CS by best septal left anterior oblique projection; (2) His bundle electrogram catheter; and (3) mapping and ablation catheter (Figure 3). Standard electrophysiological criteria were applied to diagnose AT. Induction with atrial programmed extrastimulation and burst atrial pacing were attempted if AT did not occur spontaneously. If unsuccessful, isoproterenol infusion was commenced (1 to 6 $\mu\text{g}/\text{min}$). Mapping of the earliest site of endocardial activity relative to surface P wave was performed with a 4-mm-tip mapping and ablation catheter. Bipolar intracardiac electrograms were filtered between 30 and 500 Hz, recorded and stored digitally on a computerized system simultaneously with 12-lead surface electrocardiograms. Off-line analysis was performed using on screen digital callipers at 200 mm/s speed.

Mapping of Atrial Tachycardia

Anatomic localization of the atrial focus was performed during tachycardia or atrial ectopy by analysis of: 1) surface electrocardiogram P wave morphology; 2) atrial endocardial activation sequence during tachycardia and 3) point mapping to locate site of earliest endocardial activation relative to surface P wave onset with the mapping/ablation catheter. Transseptal access was achieved with a SL1 sheath and BRK-1 needle with a single dose of heparin 100U/kg administered following left atrial access. Three-dimensional

electroanatomic mapping using CARTO (Biosense Webster, Diamond Bar, CA, USA) or EnSite NavX (St Jude Medical, St Paul, MN, USA) was used in all patients.

Anatomic Definition (Figure 1)

The left septum was defined as the region immediately anterior to the transeptal access point into the left atrium with the ablation catheter directed counterclockwise to map the left atrial region as far as the atrial aspect of the septal mitral annulus. An annular signal was defined as A:V ratio of < 1 . Superiorly the region is bordered by the superior aspect of the vestibule of the mitral annulus. The superior mitral annulus (SMA) has previously been defined as an annular location between 11 and 1 o'clock when the mitral annulus is viewed in the LAO. The mitral-aortic continuity as described by Gonzalez et al. occur between 11 and 12 o'clock on the mitral annulus at least one centimeter above the His bundle. Therefore, the left septum is inferior and atrial to the mitral-aortic continuity. (3, 10).

P Wave Morphology

Surface 12-lead electrocardiographic P wave morphology (PWM) was assessed as previously described (2). P wave analysis was applied during periods of atrioventricular (AV) block or post-ventricular pacing (Figure 2). The P waves were described based on the deviation from baseline during the T-P interval as being: 1) positive (+): if there was a positive deviation from the isoelectric baseline; 2) negative (-): if there was a negative deviation; 3) isoelectric: arbitrarily defined when there was no P wave deviation from baseline of ≥ 0.05 mV; and 4) biphasic: if there were both positive and negative (+/- or -/+) deflections from baseline.

Atrial Endocardial Activation Sequence

The consistent deployment of a decapolar catheter in the CS, and a catheter in the His position allowed characterization of left atrial epicardial activation. Activation timing was

measured from the onset of the P wave in lead V1 of the surface ECG (arbitrarily assigned a time of 0 msec) to each of the intracardiac bipoles of these catheters. For point mapping a fiducial point on the coronary sinus was defined in relation to P wave onset as a reference. Activation times were measured in a standardized fashion to the onset of the first rapid deflection from the baseline.

Radiofrequency ablation and outcome

Radiofrequency ablation was performed with continuous temperature feedback control of power output aiming to achieve a target temperature of 50° and a maximum power of 50 W. Open irrigated 4 mm ablation catheters with a maximum power output of 30 W were used in cases where inadequate power delivery occurred with a standard ablation catheters. Acute procedural success was defined by the absence of tachycardia or ectopy 30 minutes after ablation including in response to isoproterenol infusion (up to 6 µg/min) and burst atrial pacing. Follow-up was at 3, 6, and 12 months with clinical assessment and a 12-lead electrocardiogram. If patients experienced recurrent symptoms, electrocardiography and 24-hour monitoring were performed.

Statistical analysis

All variables are expressed as mean \pm SD. The unpaired t test was used to compare mean endocardial activation times at adjacent AT locations. A p value < 0.05 was considered statistically significant.

RESULTS

Patient characteristics

Nine patients had an AT arising from the left septum out of a consecutive series of 384 undergoing RFA for AT. Seven of the 9 patients were female (mean age 56 ± 12 years; range 38-75 years). Symptoms associated with tachycardia had been present for 36 ± 29 months and patients had failed a mean of 2 antiarrhythmic medications. One patient developed tachycardia-mediated cardiomyopathy with moderate global left ventricular systolic dysfunction. No patients had significant valvular heart disease and or other cardiac arrhythmias.

Tachycardia characteristics

Tachycardia was incessant in 6 out of 9 patients with LS AT. Spontaneous atrial ectopy was present in 2 patients with atrial programmed extra-stimuli inducing AT in 1 patient. Sustained AT was evident in all patients with mean cycle length of 421 ± 56 ms.

P Wave Morphology (Table 1)

The PWM demonstrated a discrete negative then positive appearance in lead V1 in all patients. The PWM was negative/positive in 6/9 across the precordial leads and negative/positive or negative in the inferior leads in all 9 patients. The P wave amplitude demonstrated variable polarity in the limb leads but was generally low amplitude.

Atrial Endocardial Sequence Mapping

For left septal ATs the endocardial activation times relative to P wave onset were:

- His A earlier than P wave onset in all patients (mean -15 ± 5 ms);

- Proximal CS was late or on time relative to P wave onset (4 ± 9 ms).
- If detailed point by point mapping of right septal and CS ostial locations did not identify a site > 20 ms ahead of P wave onset or ablation was unsuccessful then transseptal access was obtained to allow mapping of neighbouring left atrial structures (Figure 3).
- Given the P wave morphology similarities and that His A is earlier than P wave in both LS and SMA ATs, detailed electroanatomic mapping is required to differentiate between these two sites.

Radiofrequency Catheter Ablation

Left atrial endocardial mapping was performed during tachycardia or with atrial ectopy in order to record the earliest activation signal. Radiofrequency application was attempted in 2 patients on the right interatrial septum without success prior to transseptal puncture. Uncomplicated transeptal access was achieved in all patients with point mapping identifying the earliest site 31 ± 12 ms ahead of P wave onset during tachycardia. The recorded electrogram at successful ablation sites was complex and fractionated in 3 patients. The mean number of radiofrequency applications was 8 ± 8 . Time to termination at successful site when RFA was performed during tachycardia was 5 ± 2 sec. During successful RFA, tachycardia was noted to accelerate in 7 patients including one case of junctional tachycardia during RFA and decelerate prior to termination in 2 patients. Successful ablation was achieved with nonirrigated 4mm tip ablation catheters in 6 and irrigated- ablation in 3 including one case in which power was inadequate with standard ablation.

The mean procedure time was 119 ± 29 minutes and the fluoroscopy time was 20 ± 8 minutes. There were no procedural complications.

Follow-up

Of the 9 patients who underwent successful ablation, one patient presented with recurrence 3 months post index procedure and underwent a successful second procedure. Long-term success was achieved at a mean follow-up of 30 ± 28 months in all patients off antiarrhythmic medications. No patients developed atrial fibrillation.

DISCUSSION

Although the left septum has been recognized as a site for focal atrial tachycardia (8, 9, 11), there have been limited detailed series describing the clinical, electrocardiographic and electrophysiologic characteristics at this location. An awareness of the left septum as a site harboring foci is particularly important when mapping apparent right-sided septal tachycardias. In the present series, the left septum was the site of origin in 9 of 384 (2.3%) cases of atrial tachycardia and represented 5% of all AT arising from the LA.

The left septum should be considered if the PWM is negative then positive in lead V1 and across the precordium, and His A is ahead of Pwave onset during tachycardia.

Prior studies

There are limited descriptions of tachycardia originating from the left septum. Chen et al. (8) previously described the electrocardiographic and electrophysiologic characteristics that distinguish free wall from septal ATs. Three of 49 septal ATs were reported to exit from the left septum; however, the ECG and EP characteristics of left septal sites was not reported. Yamada et al (12) reported 47 left atrial tachycardias with no sites identified at the left septum. Marrouche et al. (9) reported 5 left septal tachycardias including 2 patients who underwent RF application on the right septum prior to successful RF ablation on the

Accepted Article

immediately adjacent left side. Similarly, in the present study 2 patients underwent ablation at the right interatrial septum prior to mapping of the left septum highlighting the importance of recognizing the left septum as an important site of apparent right septal tachycardia.

P Wave Morphology

For left septal AT the PWM demonstrated a negative/positive appearance in lead V1 with a transition to a negative or negative/positive P wave across the precordium similar to neighboring sites at the CS ostium and SMA (3, 5). The SMA may be distinguished by the presence of a low amplitude positive P wave in the inferior leads compared with a negative or negative/positive P wave for LS and CS ostial sites. However, left septal and CS ostial sites cannot be reliably distinguished on the basis of P wave morphology alone(3, 5). Marrouche et al. earlier reported significant variation in PWM for left septal sites that may in part be explained by differences in methodology for P wave analysis with incomplete separation from the preceding T wave and in defining the anatomic boundaries of the left septum.

Activation Mapping and Radiofrequency Ablation

Activation mapping for ATs originating from the left septum identified the endocardial activation time at the His 15 ± 5 ms ahead of P wave onset. All LS AT cases were significantly earlier at the His location compared with endocardial activation at the CS ostium. In 2 patients RF was applied in a mid septal location prior to transseptal access with the earliest site later mapped to the left septum. This reinforced the importance of mapping the left septum and superior mitral annular locations in patients with apparent perinodal atrial tachycardias. Three-dimensional mapping was useful in mapping tachycardias in close vicinity to the compact AV node and common neighboring sites such as the right perinodal region(13), noncoronary aortic cusp, CS ostium and superior mitral annulus. In one patient junctional rhythm occurred during RF application at the successful site suggesting close

proximity to left-sided extensions of the slow pathway or AV nodal tissue. In general, adequate power could be achieved with a nonirrigated 4mm tip catheter although in one case an irrigated catheter was required due to inadequate power delivery.

AT from the left septum

The anatomic location of focal ATs is determined by a complex interplay between atrial anatomy and electrophysiology. The interatrial septum is a relatively limited structure composed of the floor of the fossa, the antero-inferior rim of the fossa abutting the tricuspid valve vestibule and the flap valve. By definition it is a structure that can be removed without exiting the atria and does not include the triangle of Koch. In the present study we defined the left septum as the region immediately anterior to the transseptal access point into the left atrium with the ablation catheter directed anticlockwise to map the left atrial region as far as the atrial aspect of the septal mitral annulus. The left septum has been recognized as a potentially arrhythmogenic site in patients undergoing catheter ablation for persistent atrial fibrillation. It is a common site for complex fractionated atrial electrograms (CFAEs) and dominant frequency in atrial fibrillation (14-16). Ablation at the left septum during atrial fibrillation has been reported to result in organization to atrial tachycardia and eventual restoration of sinus rhythm (14, 17-23).

Vaitkevicius et al. elegantly described the anatomic relations of the epicardial ganglia and the neural extensions. The middle dorsal and right atrial subplexus extend respectively within the inferior and superior region of the left septum(24). These neural structures have been suggested to play a role in the underlying mechanisms that precipitate atrial arrhythmias(25, 26).. Left atrial extensions have been reported in patients undergoing unsuccessful slow pathway ablation for AV nodal reentry with success achieved via a left atrial approach(27). In

the present study junctional rhythm occurred during ablation at the successful site in one patient with left septal tachycardia. The anatomic features that potentially predispose the left septum to arrhythmogenicity include complex fractionated activity, parasympathetic ganglia and left-sided extensions of the slow pathway.

CONCLUSION

Although the left septum is an uncommon site for focal AT, an awareness of this location for harboring foci is particularly important when mapping apparently right-sided septal tachycardias.

References

1. Medi C, Kalman JM, Haqqani H, Vohra JK, Morton JB, Sparks PB, Kistler PM. Tachycardia-mediated cardiomyopathy secondary to focal atrial tachycardia: long-term outcome after catheter ablation. *J Am Coll Cardiol* 2009 May 12;53(19):1791-7.
2. Kistler PM, Roberts-Thomson KC, Haqqani HM, Fynn SP, Singarayar S, Vohra JK, Morton JB, Sparks PB, Kalman JM. P-wave morphology in focal atrial tachycardia: development of an algorithm to predict the anatomic site of origin. *J Am Coll Cardiol* 2006 Sep 5;48(5):1010-7.
3. Kistler PM, Sanders P, Hussin A, Morton JB, Vohra JK, Sparks PB, Kalman JM. Focal atrial tachycardia arising from the mitral annulus: electrocardiographic and electrophysiologic characterization. *J Am Coll Cardiol* 2003 Jun 18;41(12):2212-9.
4. Kistler PM, Sanders P, Fynn SP, Stevenson IH, Hussin A, Vohra JK, Sparks PB, Kalman JM. Electrophysiological and electrocardiographic characteristics of focal atrial tachycardia originating from the pulmonary veins: acute and long-term outcomes of radiofrequency ablation. *Circulation* 2003 Oct 21;108(16):1968-75.
5. Kistler PM, Fynn SP, Haqqani H, Stevenson IH, Vohra JK, Morton JB, Sparks PB, Kalman JM. Focal atrial tachycardia from the ostium of the coronary sinus: electrocardiographic and electrophysiological characterization and radiofrequency ablation. *J Am Coll Cardiol* 2005 May 3;45(9):1488-93.
6. Morton JB, Sanders P, Das A, Vohra JK, Sparks PB, Kalman JM. Focal atrial tachycardia arising from the tricuspid annulus: electrophysiologic and electrocardiographic characteristics. *J Cardiovasc Electrophysiol* 2001;12:653-9.
7. Kalman JM, Olgin JE, Karch MR, Hamdan M, Lee RJ, Lesh MD. "Cristal tachycardias": origin of right atrial tachycardias from the crista terminalis identified by intracardiac echocardiography. *J Am Coll Cardiol* 1998 Feb;31(2):451-9.
8. Chen CC, Tai CT, Chiang CE, Yu WC, Lee SH, Chen YJ, Hsieh MH, Tsai CF, Lee KW, Ding YA, Chang MS, Chen SA. Atrial tachycardias originating from the atrial septum: electrophysiologic characteristics and radiofrequency ablation. *J Cardiovasc Electrophysiol* 2000;11:744-9.
9. Marrouche NF, SippensGroenewegen A, Yang Y, Dibs S, Scheinman MM. Clinical and electrophysiologic characteristics of left septal atrial tachycardia. *J Am Coll Cardiol* 2002 Sep 18;40(6):1133-9.
10. Gonzalez MD, Contreras LJ, Jongbloed MR, Rivera J, Donahue TP, Curtis AB, Bailey MS, Conti JB, Fishman GI, Schalij MJ, Gittenberger-de Groot AC. Left atrial tachycardia originating from the mitral annulus-aorta junction. *Circulation* 2004 Nov 16;110(20):3187-92.
11. Hachiya H, Ernst S, Ouyang F, Mavrakis H, Chun J, Bansch D, Antz M, Kuck KH. Topographic distribution of focal left atrial tachycardias defined by electrocardiographic and electrophysiological data. *Circ J* 2005 Feb;69(2):205-10.
12. Yamada T, Murakami Y, Yoshida Y, Okada T, Yoshida N, Toyama J, Tsuboi N, Inden Y, Hirai M, Murohara T, McElderry HT, Epstein AE, Plumb VJ, Kay GN. Electrophysiologic and electrocardiographic characteristics and radiofrequency catheter ablation of focal atrial tachycardia originating from the left atrial appendage. *Heart Rhythm* 2007 Oct;4(10):1284-91.
13. Iwai S, Badhwar N, Markowitz SM, Stambler BS, Keung E, Lee RJ, Chung JH, Olgin JE, Scheinman MM, Lerman BB. Electrophysiologic properties of para-Hisian atrial tachycardia. *Heart Rhythm* 2011 Aug;8(8):1245-53.

14. Nademanee K, McKenzie J, Kosar E, Schwab M, Sunsaneewitayakul B, Vasavakul T, Khunnawat C, Ngarmukos T. A new approach for catheter ablation of atrial fibrillation: mapping of the electrophysiologic substrate. *J Am Coll Cardiol* 2004 Jun 2;43(11):2044-53.
15. Sanders P, Berenfeld O, Hocini M, Jais P, Vaidyanathan R, Hsu LF, Garrigue S, Takahashi Y, Rotter M, Sacher F, Scavee C, Ploutz-Snyder R, Jalife J, Haissaguerre M. Spectral analysis identifies sites of high-frequency activity maintaining atrial fibrillation in humans. *Circulation* 2005 Aug 9;112(6):789-97.
16. Roux JF, Gojraty S, Bala R, Liu CF, Hutchinson MD, Dixit S, Callans DJ, Marchlinski F, Gerstenfeld EP. Complex fractionated electrogram distribution and temporal stability in patients undergoing atrial fibrillation ablation. *J Cardiovasc Electrophysiol* 2008;19:815-20.
17. Verma A, Patel D, Famy T, Martin DO, Burkhardt JD, Elayi SC, Lakkireddy D, Wazni O, Cummings J, Schweikert RA, Saliba W, Tchou PJ, Natale A. Efficacy of adjuvant anterior left atrial ablation during intracardiac echocardiography-guided pulmonary vein antrum isolation for atrial fibrillation. *J Cardiovasc Electrophysiol* 2007;18:151-6.
18. Oral H, Chugh A, Good E, Wimmer A, Dey S, Gadeela N, Sankaran S, Crawford T, Sarrazin JF, Kuhne M, Chalfoun N, Wells D, Frederick M, Fortino J, Benloucif-Moore S, Jongnarangsin K, Pelosi F, Jr., Bogun F, Morady F. Radiofrequency catheter ablation of chronic atrial fibrillation guided by complex electrograms. *Circulation* 2007 May 22;115(20):2606-12.
19. Oral H, Chugh A, Yoshida K, Sarrazin JF, Kuhne M, Crawford T, Chalfoun N, Wells D, Boonyapisit W, Veerareddy S, Billakanty S, Wong WS, Good E, Jongnarangsin K, Pelosi F, Jr., Bogun F, Morady F. A randomized assessment of the incremental role of ablation of complex fractionated atrial electrograms after antral pulmonary vein isolation for long-lasting persistent atrial fibrillation. *J Am Coll Cardiol* 2009 Mar 3;53(9):782-9.
20. Jais P, Sanders P, Hsu LF, Hocini M, Sacher F, Takahashi Y, Rotter M, Rostock T, Bordachar P, Reuter S, Laborderie J, Clementy J, Haissaguerre M. Flutter localized to the anterior left atrium after catheter ablation of atrial fibrillation. *J Cardiovasc Electrophysiol* 2006 Mar;17(3):279-85.
21. Takahashi Y, Takahashi A, Miyazaki S, Kuwahara T, Takei A, Fujino T, Fujii A, Kusa S, Yagishita A, Nozato T, Hikita H, Sato A, Hirao K, Isobe M. Electrophysiological characteristics of localized reentrant atrial tachycardia occurring after catheter ablation of long-lasting persistent atrial fibrillation. *J Cardiovasc Electrophysiol* 2009 Jun;20(6):623-9.
22. Heck PM, Rosso R, Kistler PM. The Challenging Face of Focal Atrial Tachycardia in the Post AF Ablation Era. *J Cardiovasc Electrophysiol* 2011;22:832-838.
23. Po SS, Nakagawa H, Jackman WM. Localization of left atrial ganglionated plexi in patients with atrial fibrillation. *J Cardiovasc Electrophysiol* 2009 Oct;20(10):1186-9.
24. Vaitkevicius R, Saburkina I, Rysevaite K, Vaitkeviciene I, Pauziene N, Zaliunas R, Schauerte P, Jalife J, Pauza DH. Nerve supply of the human pulmonary veins: an anatomical study. *Heart Rhythm* 2009 Feb;6(2):221-8.
25. Choi EK, Shen MJ, Han S, Kim D, Hwang S, Sayfo S, Piccirillo G, Frick K, Fishbein MC, Hwang C, Lin SF, Chen PS. Intrinsic cardiac nerve activity and paroxysmal atrial tachyarrhythmia in ambulatory dogs. *Circulation* 2010 Jun 22;121(24):2615-23.
26. Shen MJ, Choi EK, Tan AY, Lin SF, Fishbein MC, Chen LS, Chen PS. Neural mechanisms of atrial arrhythmias. *Nat Rev Cardiol* 2011;9(1):30-9.
27. Sorbera C, Cohen M, Woolf P, Kalapatapu SR. Atrioventricular nodal reentry tachycardia: slow pathway ablation using the transseptal approach. *Pacing Clin Electrophysiol* 2000 Sep;23(9):1343-9.

Figure legends:

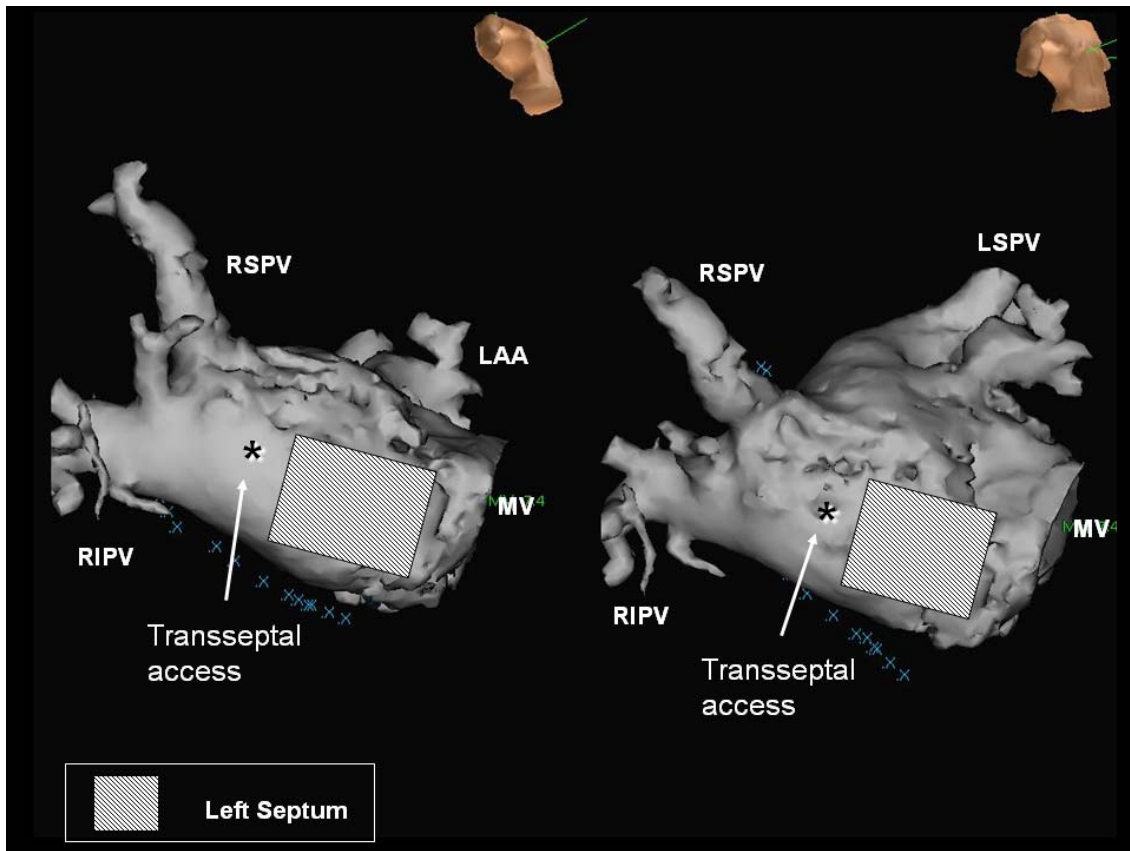


Figure 1:

Defined anatomical location of the left septal region in right anterior oblique (RAO) caudal and straight RAO projection (RSPV=right superior pulmonary vein; RIPV=right inferior pulmonary vein; LSPV=left superior pulmonary vein; LAA=left atrial appendage; MV=mitral valve).

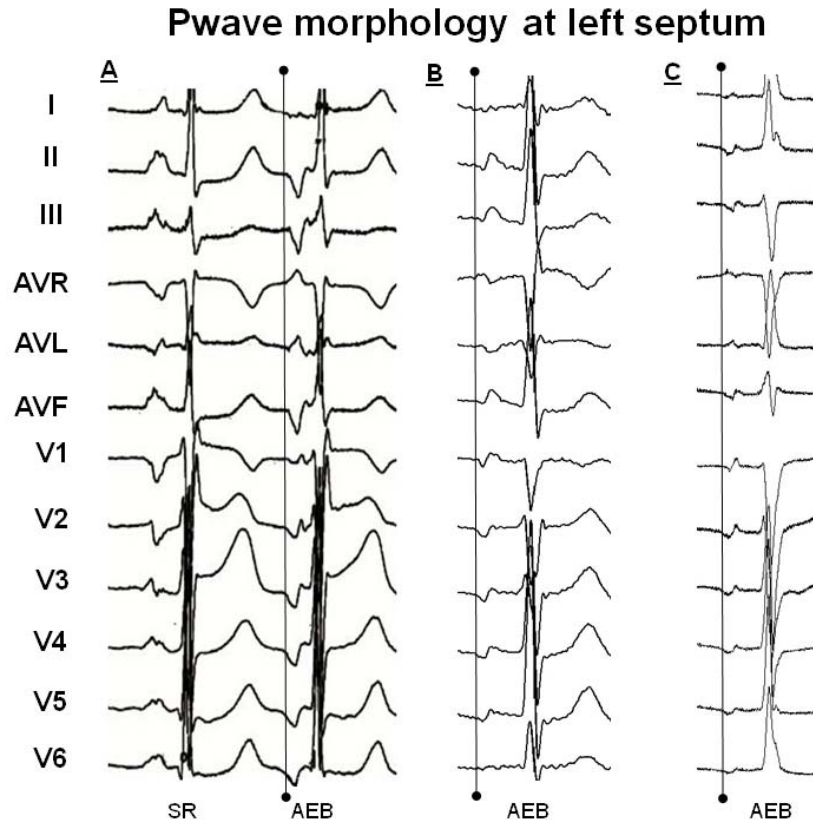


Figure 2:

P wave analysis – the unencumbered P wave (SR=sinus rhythm; AEB=atrial ectopic beat)

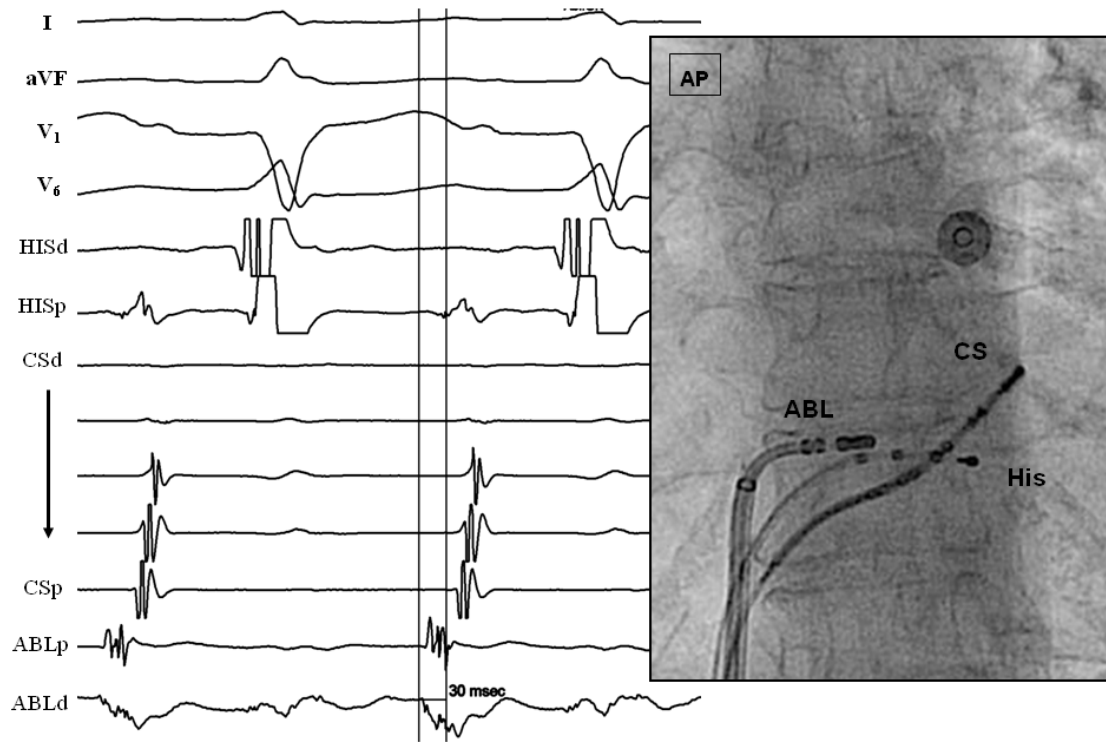


Figure 3:

Atrial endocardial sequence mapping in a patient with a left perinodal atrial tachycardia (AT) focus demonstrating early fractionated signal activation on the ablation mapping catheter. Fluoroscopy image shows catheter positions in the anterior-posterior (AP) projection (H=His; CS=coronary sinus; ABL=radiofrequency ablation catheters)

Table 1**P Wave Morphology**

ECG lead	I	II	aVL	aVR	V ₁	V ₂₋₅	V ₆
Left septum	iso(7)	-/(+)(7)	iso(3)	+(6)	-/(+)(9)	-/(+)(6)	-/(+)(6)
	+(1)	-(2)	+(4)	-(2)		-(3)	-(3)
	-(1)		-(2)	iso(1)			

ECG = electrocardiographic ; iso = isoelectric ; '-' = negative ; '+' = positive

Table 2**Clinical and procedural characteristics**

Patient	Age (years)	Sex	Duration of symptoms (months)	LA size (mm)	Earliest signal to P wave (msec)	His A to P wave (msec)	No. of RF applications
1	38	F	15	35	22	-10	2
2	54	M	15	28	35	-20	10
3	47	F	24	24	21	-17	10
4	66	F	36	25	30	-13	2
5	64	F	60	38	30	-11	2
6	75	M	36	28	13	-11	5
7	69	F	96	33	35	-22	25
8	60	F	24	31	52	-20	6
9	60	F	12	37	47	-7	8