



Minerva Access is the Institutional Repository of The University of Melbourne

Author/s:

Jenkins, DJ;Williams, T;Raidal, S;Gauci, C;Lightowlers, MW

Title:

The first report of hydatid disease (*Echinococcus granulosus*) in an Australian water buffalo (*Bubalus bubalis*)

Date:

2019-04-01

Citation:


Jenkins, D. J., Williams, T., Raidal, S., Gauci, C. & Lightowlers, M. W. (2019). The first report of hydatid disease (*Echinococcus granulosus*) in an Australian water buffalo (*Bubalus bubalis*). *International Journal for Parasitology Parasites and Wildlife*, 8, pp.256-259. <https://doi.org/10.1016/j.ijppaw.2019.03.011>.

Persistent Link:

<https://hdl.handle.net/11343/251200>

License:

[CC BY-NC-ND](#)



## The first report of hydatid disease (*Echinococcus granulosus*) in an Australian water buffalo (*Bubalus bubalis*)



D.J. Jenkins<sup>a,\*</sup>, T. Williams<sup>a</sup>, S. Raidal<sup>a</sup>, C. Gauci<sup>b</sup>, M.W. Lightowlers<sup>b</sup>

<sup>a</sup> School of Animal and Veterinary Sciences, Charles Sturt University, PO Box 588, Wagga Wagga, NSW, 2678, Australia

<sup>b</sup> Immunoparasitology Laboratory, Veterinary Clinical Centre, University of Melbourne, Princes Highway, Victoria, 3030, Australia

### ARTICLE INFO

#### Keywords:

*Echinococcus granulosus* s.s.  
Water buffalo  
Wildlife  
Australia

### ABSTRACT

A three year old female water buffalo was slaughtered for human consumption on a dairy buffalo farm in eastern New South Wales, Australia. Gross examination of the offal revealed four small, superficial hydatid cysts in the liver and two larger superficial cysts in one lung. All organs were sliced and no other cysts were found. Histology and PCR confirmed the cysts to be cysts of *Echinococcus granulosus* sensu stricto. None of the cysts contained protoscolexes. The source of infection is equivocal, but it is most likely from *E. granulosus* eggs passed in the faeces of wild dogs (dingoes and dingo-wild dog hybrids). Wild dogs are resident in the bush that abuts the farm boundary and from time to time wild dogs are seen in the buffalo paddocks on the farm. Sylvatic transmission of *E. granulosus* occurs commonly in eastern Australia through a predator/prey interaction between wild dogs and macropod marsupials.

### 1. Introduction

Water buffaloes (*Bubalus bubalis*) are not native to Australia. Eighty water swamp water buffaloes were introduced into Melville Island and the Cobourg Peninsula (Northern Territory) from Indonesia between 1825 and 1843 to provide meat and hides for remote northern settlements (Jesser et al., 2016). Later in the 1880s, riverine buffalo were introduced from India. These two types of buffalo differ in the diploid chromosome number. The swamp (eastern Asia) buffalo has 48 and riverine (Indian) buffalo has 50. They breed successfully together, the F1 hybrids having 49 chromosomes (Baker et al., 1997). The settlements in the Northern Territory were unsustainable, they were abandoned in the 1850s and the buffalo released into the bush.

The buffaloes became feral, multiplied, and in the 1970s there was a major attempt to reduce the wild population as part of the brucellosis and bovine tuberculosis eradication campaign (Jesser et al., 2016). Despite these attempts at population control, water buffaloes are now found across the floodplains in the Northern Territory, in adjacent parts of the Kimberley District of Western Australia and in Cape York, the northernmost part of Queensland (Jesser et al., 2016). Their current population in the Northern Territory is estimated to be approximately 70,000 animals, but the populations in Western Australia and Queensland are not known. More recently water buffalo have been re-domesticated and kept in small, self-sustaining herds on farms as a

source of milk for making mozzarella cheese and gelato ice cream, with small numbers slaughtered for human consumption. Dairy water buffalo can now be found on farms in the Northern Territory, Queensland, New South Wales and Victoria (Jesser et al., 2016).

*Echinococcus granulosus* is a cyclophyllidean cestode with an indirect life cycle, commonly infecting sheep as its intermediate host and dogs as definitive host. This parasite occurs widely in Australia, especially eastern Australia, where it is mainly maintained in a wildlife transmission pattern (Jenkins and Macpherson, 2003; Thompson and Jenkins, 2014). In many sheep rearing areas around the world, including Australia, *E. granulosus* is an important zoonosis. Human infection arises through accidental ingestion of *E. granulosus* tapeworm eggs passed in the faeces of infected domestic dogs. It is generally thought *E. granulosus* was introduced to Australia during European settlement with imported sheep and domestic dogs (Jenkins and Macpherson, 2003). There are two patterns of transmission of *E. granulosus* operating in Australia, a domestic pattern involving sheep and rural domestic dogs and a sylvatic pattern involving macropod marsupials (mainly wallabies) and wild dogs (dingoes and dingo-domestic dog hybrids) (Romig et al., 2017). Although *E. granulosus* is still found in sheep and rural dogs in Australia, the prevalence of transmission is less common than previously reported (Jenkins et al., 2014). The marked reduction in prevalence in rural domestic dogs, and also sheep, is the result of the highly effective cestocidal drug, praziquantel, being

\* Corresponding author.

E-mail address: [djenkins@csu.edu.au](mailto:djenkins@csu.edu.au) (D.J. Jenkins).

<https://doi.org/10.1016/j.ijppaw.2019.03.011>

Received 20 February 2019; Received in revised form 12 March 2019; Accepted 12 March 2019

2213-2244/© 2019 Published by Elsevier Ltd on behalf of Australian Society for Parasitology. This is an open access article under the CC BY-NC-ND license (<http://creativecommons.org/licenses/by-nc-nd/4.0/>).

included in readily available, cheap, generic, all-wormers for dogs and the development of inexpensive commercial dry dog food (Jenkins et al., 2014).

Much of the hydatid infection seen currently in sheep at slaughter is the likely result of transmission from wildlife definitive hosts since most farms with a hydatidosis problem about State Forests or National Parks containing populations of wild dogs infected with *E. granulosus* (Grainger and Jenkins, 1996). Hydatid disease also occurs in cattle and many of the hydatid-infected cattle identified at slaughter are from farms in eastern Australia. Cattle on these farms are commonly grazed on rougher pasture in bush areas associated with the Great Dividing Range, areas also inhabited by populations of *E. granulosus*-infected wild dogs (Durie and Riek, 1952).

Hydatid infection in water buffaloes has been reported from a number of countries around the world including Italy (Capuano et al., 2006), Turkey (Beyhan and Umur, 2011), Pakistan (Mirani et al., 2000), India (Aarif, 2015), Iran (Amin Pour et al., 2012) and Egypt (Abbas, 2016). Prevalence of hydatid infection increases with the age of the animals (Aarif et al., 2015), but the overall prevalence in buffalo populations can vary widely depending on where the buffaloes live, from below 5% (Abbas, 2016) to over 50% (Aarif et al., 2015). The presence of fertile cysts (those containing protoscolexes) in buffaloes is generally below 15% (Amin Pour et al., 2012; Abbas, 2016), however, fertility can be high in some populations and cyst fertility may vary depending on the site in which the cyst occurs (liver or lungs) (Aarif et al., 2015). Despite *E. granulosus* being present in wildlife in many parts of Australia, infection has, hitherto, never been reported in Australian water buffalo despite many being killed annually for hunting trophies, their skins, for pet food and by northern indigenous Australians, living in remote localities, as a readily available source of meat. Here we describe the first report of natural infection with *E. granulosus* in an Australian-born water buffalo.

## 2. Materials and methods

### 2.1. Animal and farm description

A 3 year old, female, water buffalo was shot on-farm by a registered slaughterman and processed in a licenced, mobile, commercial abattoir, for human consumption. The animal was bred and spent its life on a 120 ha property located in north-eastern New South Wales, about 20 km directly inland from the coast and surrounded by thick bushland (Fig. 1). The property has a herd of 88 milking buffaloes. Wild dogs are regularly seen on and around the property and often heard howling in the vicinity of the farm. Four domestic dogs live on the farm and are



Fig. 1. One of the buffalo grazing paddocks abutting State Forest containing populations of wild dogs (dingoes and/or dingo/domestic dog hybrids).

confined to a large fenced area around the house, having no access to the buffalo paddocks. The dogs are fed commercial dog food supplemented, occasionally, with offal from buffaloes slaughtered on the farm.

The climate, in the area where the farm is located, is temperate with an average annual temperature range of 16 °C - 25 °C and high rainfall, in excess of 1000 mm per year (Bureau of Meteorology, 2019).

### 2.2. Post mortem examination

The liver, lungs, heart, spleen and kidneys were collected and examined grossly for lesions by one of us (DJ). The lungs were also palpated, no additional cysts were found. All organs were then cut into slices 5–10 mm thick. All cystic lesions were collected into 70% ethanol.

#### 2.2.1. Tissue preparation for histology

The hydatid cyst tissue from both the liver and lung was processed using a Tissue-tek®VIP™ Jr tissue processor, embedded using a Thermo Electron Corporation Shandon Histocentre 3, sections were cut at 5 µm on a Leica®RM2125RT microtome and stained with either haematoxylin and eosin or PAS using a Leica® Autostainer XL.

### 2.3. DNA extraction

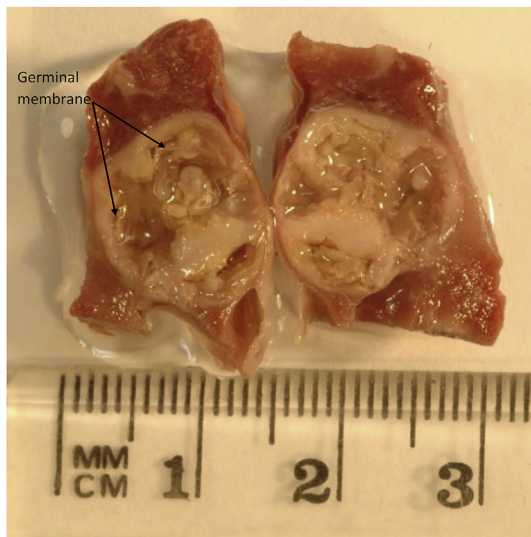
Following storage of the hydatid cyst in ethanol, the germinal membrane was removed using sterile forceps and washed with DNA extraction buffer (50 mM Tris pH 8.0, 50 mM EDTA, 100 mM NaCl, 0.5% SDS). DNA was extracted by digestion with Proteinase K (0.2 mg/ml, Promega) in DNA extraction buffer at 56 °C for 16 h. The DNA was purified by extraction with an equal volume mixture of phenol/chloroform and centrifugation at 18,000g for 15 min. The phenol/chloroform extraction was repeated, and residual phenol was removed by chloroform extraction and centrifugation. DNA was precipitated by the addition of two volumes of absolute ethanol, incubation at 4 °C for 1 h and centrifugation at 18,000g. The DNA pellet was washed with 70% ethanol, centrifuged, dried after removal of ethanol and dissolved in sterile deionized water. The DNA concentration was measured using a spectrophotometer (NanoDrop ND-1000, Thermo Scientific) and stored at –20 °C.

### 2.4. PCR analysis

The *E. granulosus* mitochondrial 12S ribosomal RNA gene was amplified by PCR using the following oligonucleotide primers originally described by Geysen et al. (2007): TaenF, 5' GTTTGCCACCTCGATGT TGACT 3' and ITMTnR, 5' CTCATAATAATCGAGGGTGACGG 3'. These primers contain highly conserved nucleotide sequence among *Echinococcus* and *Taenia* species, allowing species identification by targeting the 890 bp of the mitochondrial 12S ribosomal RNA gene. PCR amplification was based on methods also described by Busi et al. (2007) and Roelfsema et al. (2016), and was performed in a final volume of 25 µl with the following modifications: 1 µl template DNA (2 ng/µl), 5 µl 5X SuperFi Buffer (Invitrogen, including 7.5 mM MgCl<sub>2</sub>), 0.5 µl (10 mM) dNTP mix, 1.25 µl (10 µM) of each forward and reverse primer, 0.25 µl (2 U/µl) Platinum SuperFi DNA Polymerase (Invitrogen), and 15.75 µl sterile de-ionized water. The PCR reactions were performed in a Bio-Rad T100 thermal cycler using the following conditions: initial denaturation (98 °C, 30 s), followed by 35 cycles of denaturation (98 °C, 10 s), annealing (63 °C, 10 s) and extension (72 °C, 90 s), and a final extension step (72 °C, 5 min).

### 2.5. DNA sequencing

The PCR products were separated by electrophoresis in 1.2% agarose (50 mM Tris, 20 mM sodium acetate, 2 mM EDTA, pH 8.3), excised from the gel, purified using the Minelute purification kit



**Fig. 2.** Pulmonary hydatid cyst from a 3 year old female water buffalo from a farm in New South Wales, Australia.

(Qiagen) according to the manufacturer's recommendations and quantified using a NanoDrop spectrophotometer. DNA sequencing was performed by Micromon (Melbourne, Australia) using the same primers as were used in the PCR reactions and a BigDye Terminator Cycle Sequencing kit (Applied Biosystems). PCR products were sequenced in both directions, assembled and analysed using Geneious 11.1 (Biomatters, Auckland, New Zealand). BLAST was used to compare the PCR-derived sequence with reference sequences of *E. granulosus* mitochondrial genomes in the GenBank database.

### 3. Results

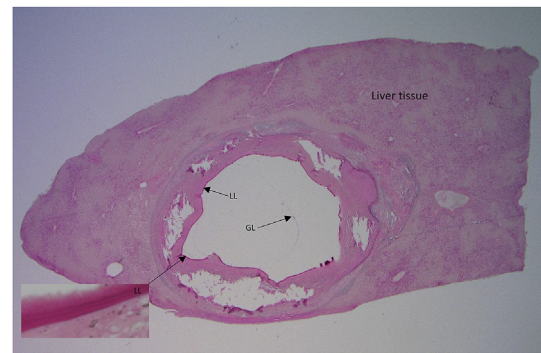
#### 3.1. Post mortem

Four small hydatid cysts 6–8 mm in diameter were found in the liver. All four hepatic hydatid cysts were visible grossly on the surface of the liver. No other cysts were found embedded in the liver tissue. Two hydatid cysts 12–14 mm in diameter were clearly visible in one of the lungs (Fig. 2). No other cysts were found in the other lung. All cysts were visible grossly on the surface of the lung, no other cysts were identified when the lungs were palpated and sliced. All cysts contained cyst fluid and a germinal membrane. Protoscoleces were not recovered from any of the cysts.

#### 3.2. Histology

**Liver cyst** - The tissue was composed of liver tissue with variable sized, mostly unilocular cystic structures with an outer layer of spindle cells and extracellular matrix, a discrete PAS-positive laminated membrane and a thicker adventitial, pericystic, layer of columnar macrophages, resting on a mineralising membrane. A diffuse mild infiltration with lymphocytes, macrophages plasma cells and granulocytes was also present. Areas of dystrophic mineralisation were also present in these areas (Fig. 3).

**Lung cyst** - The tissue was composed of connective tissue with variable sized, multilocular cystic structures with an outer layer of spindle cells and extracellular matrix, a discrete adventitial, pericystic layer of columnar macrophages, plasma cells and granulocytes was also present. Areas of dystrophic mineralisation were also present in these areas.



**Fig. 3.** Section of a PAS-stained hepatic hydatid cyst from a 3 year old female water buffalo from a farm in New South Wales, Australia (LL = laminated layer; GL = germinal layer (detached, normally closely applied to the laminated layer).

#### 3.3. PCR

Amplification of the mitochondrial 12S ribosomal RNA gene from the buffalo cyst DNA, using the TaenF and ITMTnR oligonucleotide primers as described by Geysen et al. (2007), resulted in an 890bp PCR product. DNA sequence determination of the PCR amplification product confirmed that the cyst was caused by *E. granulosus*. A BLAST search of GenBank with the nucleotide sequence of the PCR product from the buffalo cyst identified hits with the *E. granulosus* G1 genotype or common sheep strain (GenBank accession AY462129) and the *E. granulosus* G3 genotype or buffalo strain (Genbank accession DQ822451). The Australian buffalo cyst had nucleotides identical to the G1 or common sheep strain at position 166 (T in G1/sheep strain compared with G in G3/buffalo strain) and at position 205 (A in sheep strain compared with G in buffalo strain). The presence of these nucleotides within the 12S or *rnmS* gene are consistent with the Australian buffalo cyst being identified as the common sheep strain of *E. granulosus*, according to criteria set by Busi et al. (2007) and Mitrea et al. (2014).

### 4. Discussion

The source of the infection for this buffalo is equivocal, but it is highly likely to have been from eggs in faeces passed by wild dogs living in the adjacent bush. Currently in eastern Australia there is a major wildlife reservoir for *E. granulosus* cycling between wild dogs (dingoes and dingo/domestic dog hybrids) and macropodid marsupials, mainly wallabies (Romig et al., 2017). The owner of the property from which the buffalo specimens were obtained regularly hears wild dogs howling in the bush surrounding the farm and has, from time to time, seen wild dogs in the buffalo paddocks. There are four dogs living on the farm and when a buffalo is slaughtered they may be fed some of the offal but, according to the farmer, feeding offal to the dogs occurs rarely. However, the property owner informed us he has never seen hydatid lesions in offal from any of his slaughtered buffalo until the ones described in this study. Even if the farm dogs were inadvertently fed offal containing hydatid cysts, because the buffalo are still young when killed, it is highly unlikely any cysts would have attained a sufficient size to contain protoscoleces infective to dogs. In addition the dogs are regularly dewormed with a product containing praziquantel.

Wild dogs are currently the major source of hydatid infection in Australian livestock, having previously been identified as the main source of hydatid infection for sheep on farms that abut Crown Land in Victoria (Grainger and Jenkins, 1996) and for cattle grazed in coastal areas of eastern Australia and along the Great Dividing Range in Victoria, New South Wales and Queensland (Banks et al., 2006).

In Australia, *E. granulosus* infections in both sheep and macropod marsupials have been found to correspond to what is now understood as

*E. granulosus sensu stricto* (Romig et al., 2017), commonly transmitted world-wide by sheep (Bowles et al., 1992; Cardona et al., 2013) and responsible for approximately 88% of human cases of cystic echinococcosis (Alvarez Rojas et al., 2014). *E. granulosus sensu stricto* incorporates the genotype G3 originally described by Bowles et al. (1992) as Buffalo strain, however other genotypes have subsequently been found as common infections in buffaloes as well as the G3 genotype being found commonly in sheep. Our findings here show that the parasite infecting a water buffalo in Australia corresponded to *E. granulosus sensu stricto* is consistent with previous descriptions of this species as being the only *Echinococcus* species present in Australia.

None of the *E. granulosus* cysts found in the Australian water buffalo was fertile. In an extensive review of cystic echinococcosis infecting production animals, Cardona and Camena (2013) reported that cyst fertility rates of 26% (range: 3–84%) had been described for buffalo, with high fertility in domestic water buffalo reported in Asia but not in Europe (Romig et al., 2017). The animal examined in our studies was three years of age and hence the cysts could have been no older than this. *E. granulosus* can be very slow to develop and become fertile. Gemmell et al. (1986) found that in sheep the majority of cysts were not fertile until more than 5 years after infection, although a small proportion of cysts can be fertile as early as 2 years after infection. In Australia, hydatid cysts in cattle are most commonly found to be infertile, even in cattle up to 7 years of age (Banks et al., 2006). Given the reports of fertile cysts in water buffalo in other parts of the world, it seems likely that these animals could present a risk for transmission of the infection, perhaps more so in the animals slaughtered at an older age than the individual examined in this study.

The climate of the area where the buffalo farm is located is temperate with warm summers and mild winters, no nights below freezing, and high rainfall, conditions perfect for the prolonged infectivity of *E. granulosus* eggs in the environment. In addition, the eggs become distributed around the environment. It has been reported eggs of *E. granulosus* can spread 80 m in 10 days by agents such as wind, rain, birds, feet of animals etc (Gemmell and Lawson, 1986). Eggs may be spread equally in all directions irrespective of grass height but particularly down wind. Coprophagus flies may be of particular importance in distributing eggs of *E. granulosus* around the environment because they can ingest up to 860 eggs, with 82.4% eggs excreted within 24hrs still infective. Within 24 h of release, flies are within 1.6 km of release point and it has been postulated an area of 10 ha around faecal deposits becomes contaminated with eggs (Gemmell and Lawson, 1986).

The data presented are modest but clearly identify Australian water buffalo as an additional, potential, intermediate host in the *E. granulosus* transmission cycle. However, from a transmission perspective, adult buffalo, like cattle, are unlikely to be of major importance in transmission of *E. granulosus* in wildlife because at the age when they may be infected with fertile hydatid cysts (more than three years old) they are far too big to be a prey item for wild dogs. There is the chance of wild dogs scavenging carcasses of older animals that may have been killed by hunters or died of natural causes. However, until the prevalence of hydatid disease has been determined in wild populations of water buffaloes in northern Australia, the importance of wild dogs scavenging carcasses in the transmission *E. granulosus* cannot be determined.

#### Declarations of interest

None.

#### Funding

The data presented in this paper are incidental findings from a study

of intestinal helminths in Australian farmed buffalo funded by AgriFutures Australia.

#### Acknowledgements

The authors sincerely thank the owner of the property where this study was undertaken for his co-operation and enthusiastic support. Also grateful thanks to Professor Alessandro Massolo for permission to use his picture of the dingo in our graphical abstract.

#### References

- Aarif, K., Suhani, K.N., Sharma, R.L., Makhdoomi, D.M., Nazir, A., Maria, A., Mehraj-U-Din, 2015. Retrospective study of hydatidosis in buffaloes slaughtered in mirha exports private limited in Punjab, India. *Buffalo Bull* 34, 231–240.
- Abbas, I., 2016. Molecular epidemiological updates of cystic echinococcosis infecting water buffaloes in Egypt. *Vet. World. EISSN* 9, 1355–1363.
- Alvarez Rojas, C.A., Romig, T., Lightowlers, M.W., 2014. *Echinococcus granulosus sensu lato* genotypes infecting humans - review of current knowledge. *Int. J. Parasitol.* 44, 9–18.
- Amin Pour, A., Hosseini, S.H., Shayan, P., 2012. The prevalence and fertility of hydatid cysts in buffaloes from Iran. *J. Helminthol.* 86, 373–377.
- Baker, J.S., Moore, S.S., Hertzler, D.J.S., Evans, D., Byrne, K., 1997. Genetic diversity of Asian water buffalo (*Bubalus bubalis*) microsatellite variation and a comparison with protein-coding loci. *Anim. Genet.* 28, 103–115.
- Banks, D.J., Copeman, D.B., Skerratt, L.F., Molina, E.C., 2006. *Echinococcus granulosus* in northern Queensland. 1. Prevalence in cattle. *Aust. Vet. J.* 84, 303–307.
- Beyhan, Y.E., Umur, Ş., 2011. Molecular characterization and prevalence of cystic echinococcosis in slaughtered buffaloes in Turkey. *Vet. Parasitol.* 181, 174–179.
- Bureau of Meteorology, 2019. [www.bom.gov.au](http://www.bom.gov.au).
- Busi, M., Snábel, V., Varcasia, A., Garippa, G., Perrone, V., De Liberato, C., D'Amelio, S., 2007. Genetic variation within and between G1 and G3 genotypes of *Echinococcus granulosus* in Italy revealed by multilocus DNA sequencing. *Vet. Parasitol.* 150, 75–83.
- Capuano, F., Rinaldi, L., Maurelli, M.P., Perugini, A.G., Veneziano, V., Garippa, G., Genchi, C., Musella, V., Cringoli, G., 2006. Cystic echinococcosis in water buffaloes: epidemiological survey and molecular evidence of ovine (G1) and buffalo G3) strains. *Vet. Parasitol.* 137, 262–268.
- Cardona, G.A., Carmena, D., 2013. A review of the global prevalence, molecular epidemiology and economics of cystic echinococcosis in production animals. *Vet. Parasitol.* 192, 10–32.
- Durie, P.H., Riek, R.F., 1952. The role of the dingo and wallaby in the infestation of cattle with hydatids (*Echinococcus granulosus* (Batch 1786) Rudolphi, 1805). *Aust. Vet. J.* 28, 249–254.
- Gemmell, M.A., Lawson, J.R., 1986. Chapter 7 - epidemiology and control of hydatid disease. In: Thompson, R.C.A. (Ed.), *The Biology of Echinococcus and Hydatid Disease*. RCA Thompson Pub. George Allen and Unwin Ltd, London UK, pp. 189–216.
- Gemmell, M.A., Lawson, J.R., Roberts, M.G., 1986. Population dynamics in echinococcosis and cysticercosis: biological parameters of *Echinococcus granulosus* in dogs and sheep. *Parasitology* 92, 599–620.
- Geysen, D., Kanobana, K., Victor, B., Rodríguez-Hidalgo, R., De Borchgrave, J., Brandt, J., Dorny, P., 2007. Validation of meat inspection results for *Taenia saginata* cysticercosis by PCR-restriction fragment length polymorphism. *J. Food Prot.* 70, 236–240.
- Grainger, H.J., Jenkins, D.J., 1996. Transmission of hydatid disease from wild dogs to sheep in Victoria, Australia. *Int. J. Parasitol.* 26, 1263–1270.
- Jenkins, D.J., Lievaart, J.J., Boufana, B., Lett, W., Bradshaw, H., Armua-Fernandes, M.T., 2014. *Echinococcus granulosus* and other intestinal helminths in rural dogs from eastern Australia, the current situation. *Aust. Vet. J.* 92, 292–298.
- Jenkins, D.J., Macpherson, C.N.L., 2003. Transmission ecology of *Echinococcus granulosus* in wildlife in Australia and Africa. *Parasitology* 127, S63–S72.
- Jesser, P., Markula, A., Csurhes, S., 2016. Invasive Animal Risk Assessment: Water Buffalo (*Bababulus bubalis*). Department of Agriculture and Fisheries, Biosecurity Queensland.
- Mirani, A.H., Aktar, N., Brohe, M.A., Oad, F.C., 2000. Hydatidosis in buffaloes at Larkana slaughter house. *Pakistan J. Biol. Sci.* 3, 1311–1312.
- Mitreá, I.L., Ionita, M., Costin, I.I., Predoi, G., Avram, E., Rinaldi, L., Maurelli, M.P., Cringoli, G., Genchi, C., 2014. Occurrence and genetic characterization of *Echinococcus granulosus* in naturally infected adult sheep and cattle in Romania. *Vet. Parasitol.* 206, 159–166.
- Roelfsema, J.H., Nozari, N., Pinelli, E., Kortbeek, L.M., 2016. Novel PCRs for differential diagnosis of cestodes. *Exp. Parasitol.* 161, 20–26.
- Romig, T., Deplazes, P., Jenkins, D., Giraudoux, P., Massolo, A., Craig, P.S., Wassermann, M., Takahashi, K., de la Rue, M., 2017. Ecology and life cycle patterns of *Echinococcus* species. In: Thompson, R.C.A., Deplazes, D., Lymbery, A.J. (Eds.), *Adv. Parasitol.* Academic Press, pp. 275–279.
- Thompson, R.C.A., Jenkins, D.J., 2014. *Echinococcus* as a model system: biology and epidemiology. *Int. J. Parasitol.* 44, 865–877.