



Minerva Access is the Institutional Repository of The University of Melbourne

Author/s:

Abduo, J;Lyons, KM

Title:

Interdisciplinary interface between fixed prosthodontics and periodontics

Date:

2017-06-01

Citation:

Abduo, J. & Lyons, K. M. (2017). Interdisciplinary interface between fixed prosthodontics and periodontics. *Periodontology 2000*, 74 (1), pp.40-62. <https://doi.org/10.1111/prd.12189>.

Persistent Link:

<https://hdl.handle.net/11343/292791>

Article Type: Review Article

# Interdisciplinary interface between fixed prosthodontics and periodontics

## Authors

Jaafar Abduo

BDS, DCLinDent, PhD, MRACDS (Pros)

Senior Lecturer in Prosthodontics

School of Dentistry, Melbourne University

720 Swanston Street, Carlton

Melbourne, Victoria, 3010

Phone: 0061 3 9035 8998

Fax: 0061 8 9341 1599

Email: [jaafar\\_abduo@hotmail.com](mailto:jaafar_abduo@hotmail.com)

Karl Lyons

BDS, MDS, PhD, FRACDS

Professor and Chair in Restorative Dentistry

Department of Oral Rehabilitation, Faculty of Dentistry, University of Otago

310 Great King Street, Dunedin, 9054, New Zealand

Phone: 0064 3 479 7122

Fax: 0064 3 479 0673

Email: [karl.lyons@otago.ac.nz](mailto:karl.lyons@otago.ac.nz)

This is the author manuscript accepted for publication and has undergone full peer review but has not been through the copyediting, typesetting, pagination and proofreading process, which may lead to differences between this version and the [Version of Record](#). Please cite this article as [doi: 10.1111/prd.12189](https://doi.org/10.1111/prd.12189)

This article is protected by copyright. All rights reserved

# Running title: Prosthodontic and periodontic interface

## Abstract

Although periodontal factors do not usually have a direct effect on the survival of a fixed prosthesis, harmony between the prosthesis and the periodontium is critical otherwise aesthetics, the longevity of the prosthesis and the periodontium will be compromised. A close interdisciplinary relationship between periodontics and prosthodontics is therefore necessary to avoid an unsatisfactory treatment outcome, requiring extensive and expensive re-treatment. The design of the prosthesis, the number and quality of the abutment teeth, the preparation and the pontic, the occlusion and material choice needs to be considered when planning prosthodontic treatment. The location of the preparation margin and the contour and emergence profile of the prosthesis will influence the response of the gingival tissues to the prosthesis. Pontic design and cleansibility also contribute to the response of the gingival tissues as well as the clinical and aesthetic outcome. Even an ideal pontic design will not prevent inflammation of the mucosa adjacent to the pontic if pontic hygiene is not maintained by removal of plaque. Case selection and the patients ability be able to carry out adequate oral hygiene are therefore essential for longevity of the prosthesis, and regular reviews provide an opportunity for early detection and treatment of failures.

## Interdisciplinary interface between fixed prosthodontics and periodontics

Prosthodontic treatment should enhance patient comfort, function, health and aesthetics. Equally important, treatment should not induce damage to the periodontal structures. It is important that periodontal tissues are healthy prior to the commencement of prosthodontic treatment, and additional periodontal treatment is commonly indicated to facilitate improved prosthodontic treatment outcomes. Predictable prosthesis longevity is dependent on the cleansability of the restored tooth or teeth and the relationship between prosthodontics and periodontics when planning and performing the prosthodontic treatment.

Today patients are aesthetically conscious and have high dental expectations. Further, clinical procedures in dentistry appear to be increasingly market-driven. When these factors are combined with the regular release of new dental materials and fabrication techniques, the clinician is confronted with a plethora of treatment options to address a specific dental problem. As the mean population age is increasing and the tendency is to retain the teeth, it is now common to encounter difficult clinical presentations such as severe tooth tissue loss, advanced periodontal disease, tooth loss and significant aesthetic problems. Prosthodontic treatment must provide a solution to the dental problems with acceptable longevity.

Historically, a major emphasis was placed on the mechanical features of prostheses. Although this has been shown to be beneficial in several laboratory studies, a large proportion of the clinical complications in fixed prosthodontics have been biological in nature, such as caries and periodontal disease (38, 48, 62, 135). Further, it appears that as the complexity of the prosthodontic work increases, there is an increase in biological complications (26). The contemporary literature pertaining to fixed prosthodontic treatment reflects the close relationship with periodontal parameters and promotes the concept of a biologically driven prosthodontic practice (30, 65, 74).

To ensure patient satisfaction, multidisciplinary treatment is essential. This includes simultaneous and coordinated periodontal and prosthodontic care to ensure a favourable outcome for patients with complex prosthodontic and/or periodontal presentations. It is the purpose of this article to outline the areas of overlap between prosthodontics and periodontics that dictate the interdisciplinary treatment. Six periodontal-prosthodontic interfaces will be discussed in detail as they relate to conventional fixed prosthodontic treatment:

1. Gingival level and contour.
2. Edentulous area.
3. Magnitude of periodontal support.
4. Abutment tooth preparation.

5. Prosthesis morphology.
6. Prosthesis material.

## 1. Gingival level and contour

Gingival morphology is critical in prosthodontics because it determines the outlines and extensions of the dental prosthesis (30) and can contribute significantly to the final dental and facial aesthetics (68, 133). Several authors have referred to the gingival morphological variables that can influence all phases of prosthodontic treatment (133) (Table 1). Nevertheless, there is controversy regarding the importance of these variables in relation to oral health and aesthetics (17, 92). Because significant physiological variation exists between individuals, gingival morphological variables may be better considered as guidelines for treatment planning that could aid in achieving optimal health and aesthetics, rather than rigid criteria.

Histologically, the biologic width is the combination of the averages of 1 mm of connective tissue attachment and 1 mm of epithelial attachment (47). Coronal to the biologic width is the gingival sulcus that is on average 0.69 mm (47). Patients with a thick and flat gingival biotype tend to have greater biologic width than those with a thin and profoundly scalloped gingival biotype. Likewise, the biologic width varies in height and orientation around different teeth and even around the same tooth. For example, the biologic width on the mesial and distal aspects of a tooth is located coronally to the facial and lingual aspects.

Although the exact dimensions have been disputed (94), for the last few decades the biologic width has been used as a guide for clinicians. During margin placement for fixed prostheses, the prosthodontist should ideally follow the gingival contour and not extend more than 0.5 mm into the sulcus (13, 69, 73). Likewise, the periodontist uses the dimensions of the biologic width when recontouring the gingival level (30). As a 2 mm biologic width has been widely accepted, it has been recommended that at least 3 mm of sound tooth structure should be preserved between the prosthesis margin and alveolar bone. In situations where such dimensions cannot be achieved, increases in gingival inflammation, attachment loss (19, 96, 106, 153) and gingival recession (39, 130, 148) are frequently observed.

There are several periodontal procedures that can modify the gingival contour. They can be classified into two categories: subtractive and additive. To select the most suitable approach for any situation, a comprehensive extraoral and intraoral examination supplemented with a radiographic analysis is

necessary. It is critical to evaluate the evenness of the gingival margin and the extension of the planned gingival modifications. If periodontal disease is present, the treatment can be included with the gingival contour modifications. The initial tooth anatomy should be evaluated to determine the impact of treatment on aesthetic, hygienic and biomechanical requirements. Further, the presence of skeletal abnormalities can affect the treatment selection. For complex cases, clinicians should consider additional diagnostic tools that can provide the patient with an insight into the expected outcome (79-81).

## Subtractive methods

The subtractive methods are used more commonly and are generally simpler and more predictable than the additive methods (97). Subtractive methods involve increasing the clinical crown length by removing soft tissues with or without osseous modifications (65). These procedures are indicated to re-establish a physiological biologic width in cases where a fracture line, perforation or the restorative margin are located subgingivally. Complying with these principles preserves the health of tissues and facilitates the subsequent prosthodontic procedures (73). Further, lengthening a short clinical crown enhances the retention and resistance forms that can be achieved in a crown preparation. This is necessary if the clinical crown height is less than 3 mm (1). An additional advantage of crown lengthening surgery is the elimination of periodontal pockets (43). Aesthetically, subtractive methods can increase tooth display and resolve uneven gingival contour.

Nevertheless, these procedures can result in loss of hard and soft tissues as well as an increase in root sensitivity and in the crown to root ratio. When several teeth are involved, there will be a risk of loss of interdental papillae and development of black triangles. The alteration of tooth emergence profile and narrowing of the cervical tooth portion will accentuate this. Crown lengthened teeth have also been found to be more susceptible to recession and furcation involvement compared with control teeth (28). An increase in the crown to root ratio might induce tooth mobility, however there is a lack of compelling evidence to support this assumption (88). If subtractive methods are indicated to manage gingival hyperplasia without osseous modification, it is likely that a fixed prosthesis will not be required if the teeth are intact (18, 65). However, following generalized crown lengthening with osseous reduction, the root surface of the involved teeth will be exposed. Subsequently, full coverage prostheses become necessary to improve aesthetics and patient comfort.

To overcome these problems, modifications to the surgery have been proposed. For example, aesthetic crown lengthening surgery aims to minimise bone reduction interproximally (65). This can be

advantageous when a distance of 4-5 mm remains between the bone crest and contact point. Such a distance is more likely to allow an intact interdental papilla to be maintained than if the distance is greater than 5 mm (21, 143). Likewise, excessive interproximal bone removal between tapering roots will increase the horizontal separation. Distances up to 1.5 mm between the adjacent roots are sufficient to ensure an adequate interdental papilla (21). Some authors have discussed multi-staged crown lengthening surgery as a method to localise osseous re-contouring and minimise interdental papilla alterations (81, 133).

The aetiology of the dental problem will dictate the approach of the crown lengthening procedure in terms of extension, invasiveness and sequence. The first question to be answered is whether combined periodontal and prosthodontic procedures will manage the patients concerns. Significant gingival exposure due to face height or lip length for example, might not be manageable by periodontal or prosthodontic procedures only. Instead, orthognathic and/or plastic surgical procedures would need to be considered. Alternatively, the patient may accept a compromised outcome. If the indication for crown lengthening is management of gingival enlargement, and the teeth are intact, it is possible to confine the surgery to the soft tissues without altering the alveolar bone crests. In such cases, the cement-enamel junction will be used as a landmark for the contour modifications (18). So long as root surface is not exposed, additional prosthodontic procedures are not likely to be necessary.

A clinical dilemma arises when simultaneous crown lengthening is indicated in conjunction with prosthodontic treatment. In terms of treatment sequencing, which treatment should be completed first? In cases of confined and minimal biologic width violation in less aesthetically demanding situations, a tooth can be prepared to the final extension and restored with a provisional prosthesis. Subsequently, the preparation extension will guide the periodontist when re-contouring the soft and hard tissues (132). This will ensure that the crown lengthening procedure is driven by the tooth preparation. Conservative surgery confined to the area of defect is possible. Unnecessary root or furcation exposure may be avoided. This treatment sequence is more applicable for posterior teeth where the evenness of the gingival contour is less critical.

Where multiple teeth are involved in the aesthetic area, or where a more invasive surgical procedure is needed, the crown lengthening should be completed prior to the tooth preparation. This may occur for example when crown lengthening of several teeth is necessary prior to restoring a worn dentition (Fig. 1). The teeth can be prepared following soft tissue maturation, biologic width re-establishment and attainment of anatomical architecture, which can take up to 6 months (14, 31, 76, 159). Completion of crown lengthening prior to tooth preparation will allow improved visualization during the tooth

preparation procedure. However, the extent of crown lengthening should be determined prior to the surgery. This is accomplished with a diagnostic wax-up, bone sounding or a combination of both. These techniques will ensure that crown lengthening is prosthodontically driven. Consequently, the potential implications of crown lengthening can be estimated prior to any irreversible treatment, and revision surgical procedures may also be avoided (2, 84).

## The diagnostic wax-up

A diagnostic wax-up aims to simulate the planned prosthodontic treatment on articulated dental models. In general, this process will validate the feasibility, practicality and aesthetics of the final treatment (69, 70, 79). Prosthodontic, periodontic and orthodontic treatment can be incorporated into the diagnostic wax-up. Since it allows visualization of the anticipated treatment outcome, it is an ideal communication tool between the clinician and the patient (79). The need for a diagnostic wax-up increases as the complexity of the prosthodontic treatment increases. Gingival morphological modifications can be incorporated into the wax-up by extending the wax teeth to the anticipated postsurgical gingival margin. The completed wax-up will serve as a 3D blueprint for the definitive treatment and outline the extension of the definitive gingival level. Eventually, the information obtained from the wax-up can be transferred intraorally with the aid of templates that will guide the surgical re-contouring of hard and soft tissues (154). When this occurs, the alveolar bone should be located 3 mm apical to the anticipated restorative margin to allow a physiological biologic width to be established.

## Bone sounding and 3D imaging

The information obtained from the diagnostic wax-up can be further augmented by bone sounding, which aims to determine the osseous architecture under the covering gingival tissues (81). Under local anaesthesia, a sharp instrument is inserted in the soft tissues and gingival sulci, labially and interproximally. Subsequently, the thickness of the soft tissues, proximity of the underlying bone and the implications of the surgical procedure can be evaluated. The amount of bone reduction required to attain the planned gingival level can then be quantified. Different biotypes will result in a different bone sounding outcome. Bone dehiscence and fenestration can be difficult to detect and a thick gingival biotype will result in a more accurate assessment than a thin gingival biotype (81).

As 3D dental imaging is becoming more popular, digital bone sounding is an option to detect and quantify bone defects (Fig. 2) (93). In comparison with conventional radiography, CT scanning has been found to be more accurate in recording bone morphology (45). When compared with conventional bone sounding, 3D dental imaging allows an accurate, practical, non-invasive 3D evaluation of the alveolar bone without traumatising the overlying soft tissues (44, 109). Further, root anatomy, and bone dehiscence and fenestration can be accurately outlined. The 3D image can be coupled with a scanned dental model to allow quantification of the soft tissue thickness. As more information is obtained from 3D imaging, it could be speculated that the consequences of the definitive treatment will be more accurately estimated.

## Alternative methods to achieve longer teeth

If crown lengthening is being considered primarily to provide longer teeth, an increase in tooth display will reliably occur if the lip line is higher than average. Alternatively, longer teeth can also be achieved by increasing the vertical tooth length (Fig. 3). This can be accomplished prosthodontically by increasing the vertical dimension of occlusion or by retruding the mandible to centric relation position (1). The latter approach will increase the overjet between the anterior teeth that facilitates the restoration of the maxillary teeth at a greater length. These approaches have the advantages of increasing tooth display, reorganizing the occlusion, avoidance of surgical procedures, and reduction of tooth structure loss as no incisal reduction is needed. Because surgical procedures may be avoided, loss of interdental papillae is unlikely. Further, they can be suitable options for the worn dentition, where all the teeth in at least one arch need to be restored. Confining the management to the prosthodontic option might also provide the patient with an immediate solution and aesthetic improvements. Because the root surface is not exposed, partial coverage or bonded restorations are still an option. In many cases however, a combination of surgical and restorative options can be considered and crown lengthening is likely to be necessary if the tooth vertical height is 3 mm or less (1).

Some patients might present with localised anterior subgingival defects. Surgical crown lengthening alone might not provide an acceptable result because gingival evenness is affected. In such cases, forced eruption combined with localized fibrotomy and thorough root planing or limited crown lengthening may be indicated (60, 61, 112). A surgical intervention will also be needed to prevent disharmony of the gingival margins associated with overeruption of a tooth or teeth. Because tooth roots are tapered to varying degrees, a tooth that has been extruded will have a decreased root diameter at the level of the

gingival margin of adjacent teeth. As a result, extruded teeth exhibit greater taper from the incisal edge to the gingival margin. Therefore teeth with a small taper at the coronal third of the root are better candidates for extrusion than those with more pronounced tapering.

## Additive methods

Additive methods correct gingival level and contour by augmenting the gingival tissues and reducing the height of the clinical crown (17). In general, these methods are indicated to improve the dentogingival aesthetics, by increasing the width of attached gingiva. In addition, they are indicated to alleviate dentine sensitivity. The available techniques are a free gingival graft, a connective tissue graft or a coronally positioned flap. All of them aim to achieve an even band of attached gingiva and maintain coverage of roots. They should be completed well before the prosthodontic treatment.

Clinically, it is desirable to have an even, thick band of attached gingiva about 5 mm wide. It is believed that attached gingiva provides an effective barrier to resist damage from physical, chemical, thermal and bacterial stimuli. The role of the attached gingiva however remains controversial (17, 92) and it has been postulated that as long as the patient maintains a good level of plaque control, more recession is not likely even with the absence of attached gingiva (157). Nevertheless, the presence of attached gingiva around teeth may improve patient comfort, facilitate cleaning, reduce dentine sensitivity, improve aesthetics and facilitate prosthodontic treatment (92).

The use of additive techniques should be restricted to confined recession lesions, where an adequate blood supply is available (17). Prosthodontic treatment can however be completed without gingival augmentation procedures by modifying tooth morphology without altering the gingival contour. As a result, the overall clinical crown length cannot be decreased but the emergence profile can be modified to create a perception of correct dental proportion. Other authors have discussed the application of gingivally coloured ceramic to conceal gingival deficiencies, (Fig. 4) which, although useful, are limited in their ability to obtain ideal aesthetics (152). The patient should be fully aware of this anticipated aesthetic outcome.

## 2. Edentulous area

Assessing the edentulous area where a fixed prosthesis is to be placed is important to minimise potential problems that may otherwise occur during fabrication or placement of the fixed dental prosthesis (FDP). This includes assessment of the residual ridge location, height, width, and contour, and the edentulous area span. When a FDP is planned, the prosthesis components to be considered are the pontics and the connectors because they influence the aesthetics and durability of the prosthesis as well as the soft tissue health

Biologically, a pontic must have a hygienic design. It has been proposed that pontics should exhibit pressure-free contact on keratinized attached tissue and should not allow food accumulation or prevent plaque control. This was assumed to prevent tissue inflammation and ulceration (6). However, more recent studies have indicated that controlled pressure might be beneficial by providing a seal and preventing saliva leakage and food impaction. One study showed that there were no negative consequences clinically or histologically as long as soft tissue pressure did not prevent seating of the FDP and the pontic fitting surface was convex and smooth (147). The same study showed that the most common factor contributing to soft tissue inflammation was oral hygiene practice. Similarly, it has been found that pontic design does not predict tissue inflammation. Instead, regular plaque and calculus removal has been shown to ensure tissue health (131, 146). Following mucosal biopsy under pontics with minimal tissue pressure, Zitzmann et al. reported histological changes with increased inflammatory cells and thinning of the keratinized layer (165), however, clinically, this was not found to be significant. Their conclusion was that minimal pressure was not associated with negative clinical sequelae as long as good plaque control was maintained. In another study, the impact of the pontic material selection was found to be insignificant on compressed tissues, as long as the pontic was highly polished with a convex tissue surface (104). Therefore, prosthesis cleansibility and patient home care appears to be more critical for tissue health than material selection and tissue contact. Further, this endorses the importance of open and rounded embrasure contours as a way of facilitating patient cleaning of the FDP (Fig. 5).

From the mechanical perspective, it is accepted that the pontic and connector should be rigid enough to withstand occlusal forces. This is primarily achieved by material selection and framework design. The need for a rigid framework is especially important for the long-span FDP that is more susceptible to deflection from occlusal forces. For these reasons, the minimal cross-section recommended for metal FDP frameworks is 3 x 3 mm, and for ceramic frameworks is 4 x4 mm (114).

Historically, reducing the buccolingual width of the pontic has been suggested as a way of reducing the load on the abutment teeth, however there is very little evidence to support this claim. In fact, narrowing the pontic width may make it more difficult to achieve good aesthetics and a functional

occlusal relationship. Further it can increase the possibility of food impaction around the pontics (Fig. 6) (6).

In order to provide the best aesthetic outcome, the pontic dimensions should be similar to the space vacated by the missing tooth. This is, however, dictated by the gingival contour and the pontic space shape. Ideally the residual ridge contour should be regular and smooth, covered with attached gingiva and at similar level to the gingival margin of the adjacent teeth. Such a presentation will allow a FDP pontic to mimic the natural tooth emerging from the gingiva and maintain the interdental papillae (33). It is not uncommon however, that following tooth loss, a morphological ridge deficiency may develop such as severe resorption. In such instances, surgical modification with hard and soft tissue grafts may be necessary (75, 116, 124, 125). These procedures, when performed correctly can produce excellent results, though are potentially unnecessary if ridge preservation techniques are utilized. An alternative to surgical treatment involves prosthetic camouflaging. This involves the inclusion of a root form at the cemento-enamel junction or use of gingival-coloured ceramic to recreate gingival contours. The aim of the gingival-coloured ceramic is to obtain a harmonious gingival contour, however this frequently results in pontics that have increased tissue contact (23, 46). When the gingival-coloured ceramic is applied, the cervical extension of ceramic toward the gingival embrasure spaces may be limited by the path of insertion of the retainer and the adjacent tooth, which could result in a prominent black triangle (66). This problem can be reduced by widening the contact areas of the adjacent unprepared teeth. Overall, this camouflaging design can produce an acceptable outcome if the patient does not have high aesthetic expectations, if the pontic location is not in a visible area and if the patient has a low smile line. Where there is excessive bone loss, a satisfactory aesthetic outcome may be better achieved with a removable prosthesis.

In some cases, adjacent teeth might move leading to a pontic space width reduction and loss of dental symmetry. Such presentations might result in the need for orthodontic repositioning. Minor space discrepancies can be managed by prosthodontic treatment alone. To do this, the pontic can be proportioned to minimise the size discrepancy and the space difference can be corrected for by altering the shape of the proximal areas.

To provide an ideal edentulous space restoration, several pontic designs have been proposed. While none of them addresses all of the requirements, knowing the rationale of each design allows the clinician to select the ideal pontic for a given scenario. In the anterior region, aesthetics is a primary consideration and the pontic should be well adapted to the tissues to give the appearance of a tooth emerging from the gingiva. In the posterior regions, the design may be modified to facilitate better oral hygiene control.

The pontics used most commonly for the anterior regions are the ridge lap, modified ridge lap and ovate designs (Fig. 7). The ridge lap pontic provides good aesthetics and a natural emergence profile, however the design is not recommended because the concave gingival surface cannot be cleaned. To overcome this problem, the modified ridge lap pontic was developed and is recommended for most anterior situations. The modified ridge lap design combines the aesthetics and ease of cleaning by overlapping the ridge on the buccal side to provide the appearance of a tooth emerging from the gingiva, but remains clear of the tissues on the palatal side. The advantages of this design are that it can restore lost bucco-lingual width by overlapping the residual ridge so that the cervical aspect is in front of the ridge. This can cover changes in the ridge form that may have occurred following tooth extraction. Oral hygiene is facilitated because the tissue surface contours are smooth, convex and open on the palatal aspect. Disadvantages with this pontic design occur if an accurate seal is not achieved. If this occurs, it can cause food entrapment on the palatal aspect, there may be saliva leakage and phonetic difficulties due to air leakage may occur.

An alternative pontic to consider when aesthetics are of particular importance is the ovate design (Fig. 8). Because it is placed into a tissue recess, the pontic appears to emerge from the gingiva, overcoming some of the disadvantages of the modified ridge lap. Further, the ovate pontic enhances maintenance of the papillae by supporting the soft tissues laterally. It is thought that the ovate pontic also prevents loss of gingival architecture following tooth extraction by controlling tissue healing (63, 137, 138, 147). In addition to aesthetics, the ovate design is not as susceptible to plaque accumulation as the modified ridge lap pontic. This is attributed to the convex tissue surface design of the pontic and the controlled pressure exertion that ensures an adequate seal (137, 138). The disadvantages of this design are the likelihood of the need for a surgical intervention to create a tissue recession, prolonging treatment time. There is also a need for a wide ridge.

It is therefore best to plan for an ovate pontic application prior to extraction of the tooth. Following minimally traumatic tooth extraction, an immediate provisional prosthesis should be provided with the gingival surface of the provisional prosthesis, well polished, and inserted 2-3 mm into the extraction socket. The area should be regularly reviewed for 3-6 months, and after complete maturation of the extraction area, the definitive prosthesis can be provided (32, 63, 147). An ovate pontic can also be provided for a healed edentulous area. A soft tissue recess of 1-2 mm can be established by electrosurgery, laser treatment or a rotary instrument, followed by immediate placement of a provisional prosthesis (63, 87). Prior to soft tissue modifications, it is recommended to perform bone sounding to ensure at least 1 mm distance between the crestal bone and the pontic.

For the posterior locations, the most suitable pontics are the sanitary, conical and modified ridge lap designs (Fig. 9). The sanitary design facilitates plaque control because the tissue surface remains clear from the gingiva. Although food could be trapped under the pontic, it is easily accessible for cleaning by the patient. Due to its poor aesthetics, it is reserved for restoration of missing mandibular molars. The modified ridge lap pontic is useful for the replacement of posterior teeth because it is aesthetic, restores the buccal tooth profile and is cleaned relatively easily. The modified ridge lap design is more suitable for replacing premolars and maxillary molars, where the pontic-ridge discrepancy is minimal. However, if the residual ridge is narrow, there could be a significant discrepancy between the pontic contour and the ridge resulting in food collection and patient discomfort. In such situations the conical design can be considered. Since the conical pontic is less aesthetic than the modified ridge lap, it is best used to replace mandibular molars where the convex gingival surface contacts the residual ridge at the centre of the crest, making it relatively easy for the patient to keep clean.

### 3. Magnitude of periodontal support

Evaluation of the magnitude of periodontal support is relevant for patients who have a history of periodontitis, which can manifest clinically as an increase in the crown-to-root ratio and/or a loss of teeth (108).

Crown-to-root ratio is the ratio of the portion of the tooth coronal to the alveolar bone to the portion of the tooth within the alveolar bone, as determined by radiograph (51). This ratio has been described as a prognostic tool to evaluate the suitability of an abutment tooth to support a FDP (56). It is speculated that alveolar bone loss and tooth mobility may occur when alveolar support is no longer adequate to withstand functional forces (86, 108). A crown-to-root ratio of 1:2 has therefore been considered ideal, but because this ratio can be difficult to observe clinically a ratio of 1:1.5 has been deemed suitable and a ratio of 1:1 is considered minimal (56, 117).

The impact of crown-to-root ratio on treatment planning is controversial and, to date, there is no definitive recommendation on what constitute an ideal crown-to-root ratio (56, 90). After evaluation of 100 patients treated for periodontal disease over 5 years, McGuire & Nunn (91) could not find a relationship between the crown-to-root ratio and a prognosis for the teeth. Increased mobility is not always observed for teeth with an increased crown-to-root ratio (126). Instead, different periodontal treatments may result in a reduction in tooth mobility, even if the crown-to-root ratio is not altered (50). Further, tooth mobility on its own is not a pathological condition and indeed several authors have

considered it a physiological adaptation to altered function (34, 35, 85, 140). It should therefore be acknowledged that periodontal support cannot be determined by the linear measurement of the crown-to-root ratio alone, but should also consider the anatomy and configuration of the root and the periodontal health (82, 98, 102, 117).

Another factor contributing to periodontal support is the number of abutment teeth, which is particularly relevant when considering a multi-unit FDP. In this regard, the literature commonly discusses Ante's Law that mandates that the combined peri-cemental area of all abutment teeth supporting a FDP should be equal to or greater in peri-cemental area than the tooth or teeth to be replaced (3). The rationale of this law has seen its implementation as a guide to safe prosthodontic design for the multi-unit FDP (88). Consequently, a recommendation was developed that in situations where the area of the edentulous span was greater than the adjacent abutment teeth, additional precautions should be considered, such as splinting adjacent abutment teeth. Splinting multiple abutment teeth controls mobility and enhances stability by transferring the horizontal forces to multiple teeth (36). Wylie and Caputo established that splinting two adjacent periodontally involved abutment teeth was also beneficial in reducing alveolar bone stresses (160). This was confirmed by Yang et al. who used a finite element study to show that splinting multiple abutment teeth for long span FDPs reduced the stress in the teeth and alveolar bone (161). Both of these studies however found that increasing the number of splinted abutment teeth did not result in a proportional reduction in stress in the supporting structures (160, 161). Translating such findings clinically is also challenging because splinting abutment teeth results in other problems such as hindering efficient cleaning and predisposing the abutment teeth to biological deterioration (40). Ensuring parallelism of all the prepared abutment teeth can also be invasive and may explain the higher proportion of endodontic complications in splinted abutment teeth (7).

Although Ante's Law constitutes a reasonable guideline, it has been challenged from two perspectives: the lack of a clinical method to quantify the peri-cemental area and the lack of clinical evidence (5, 37, 88). Ante's Law emphasises the importance of the peri-cemental area, the number of teeth to be replaced and the number of abutment teeth, but there is lack of emphasis on the importance of the remaining periodontal tissues supporting the abutment teeth (77). For example, multi-rooted teeth are less affected by bone resorption than single rooted teeth (82). Further, prognostic criteria on the sustainability of abutment teeth to withstand occlusal forces applied to wide FDPs are yet to be determined.

Clinical studies have consistently shown that there is little relationship between Ante's Law, the longevity and the function of FDPs (88). A series of long-term studies in Scandinavia revealed that

abutment teeth with a periodontal ligament area far less than the periodontal ligament area of the teeth being replaced still provided adequate support for long span and cross-arch FDPs (98-101). In these studies, only 8% of FDPs fulfilled the requirements of Ante's Law, and 57% of the FDPs had an abutment tooth periodontal ligament area that was less than 50% of the periodontal ligament area of the teeth being replaced. Despite this, the studies found no loss in clinical attachment or periodontal bone support, widening of the periodontal ligament space or increased mobility after 11 years. Although a history of periodontal disease was common for their patients, the outcome can be attributed to an absence of periodontitis, a rigorous maintenance protocol and patients' oral hygiene practices, hygienic prosthesis designs, and preservation of strategic abutment teeth (4, 88). In another cross-sectional study, 41% of the FDPs did not satisfy Ante's Law and around 4% of the FDP failures were attributed to periodontal overloading and mobility (37).

From the functional perspective, since no correlation has been found between the number of abutment teeth and the magnitude of the occlusal forces during chewing or maximal biting, FDPs that violate Ante's Law can withstand physiological occlusal forces without altering chewing patterns (77, 78). This is true for fully supported cross-arch prostheses (77) and cantilevered unilateral prostheses (78).

Biologically, although violation of Ante's Law has not been shown to cause deterioration of the abutment support, long term clinical studies investigating FDPs have confirmed that the longer the span, the greater the number of complications particularly when compared with shorter span FDPs. Leempoel et al. found that FDPs that did not comply with Ante's Law exhibited a higher rate of fracture than those fulfilling Ante's Law (83) and De Backer et al., reported that the survival rate of short span FDPs (3 to 4 units) was significantly higher than the survival rate of long span FDPs ( $\geq 5$  units) (26). The main reasons for failure were caries, prosthesis fracture and loss of retention; there were few reported failures for periodontal reasons. It appears therefore, that implementing Ante's Law is not fully justified in the literature and is not necessarily beneficial to periodontal support, however it should be appreciated that long span prostheses are more demanding to construct and have a higher level of complications.

It can therefore be concluded that so long as prosthodontic treatment is preceded by appropriate periodontal therapy, and that periodontal health is well maintained, it is unlikely that periodontal support will deteriorate with function when periodontal pockets are under 4 mm. The clinician should be aware however, that increasing the span of the FDP will increase the risk of non-periodontal complications.

## 4. Abutment tooth preparation

Whenever a tooth is prepared, the aim is to achieve enough clearance to accommodate a durable and physiological restoration, without over sacrificing natural tooth structure. Ideal tooth preparation is achieved by controlled tooth surface reduction, maintaining occlusal surface morphology, obtaining minimal preparation taper and preserving vertical preparation height (54). Adhering to these principles ensures mechanical durability by allowing adequate material thickness and adequate retention and resistance form in the abutment tooth preparation. Adequate thickness also allows for optimal aesthetics of the prosthesis while minimising unnecessary tooth reduction.

Whenever alteration to the tooth morphology is planned, it is recommended that a diagnostic wax-up is utilized. The need for a diagnostic wax-up increases as the complexity of the treatment increases (25, 89). The prime objective of the diagnostic wax-up is to assist with planning the most feasible, achievable, conservative and practical treatment option. The outcome of this “trial” treatment can be shown to the patient for approval or for suggested modifications so that the patient is informed of the treatment options and the proposed final outcome. Subsequently, the diagnostic wax-up facilitates an outcome-based treatment, which implies that the tooth preparation is dictated by the aims of the final outcome rather than the initial tooth morphology (57, 89). Provisional prostheses can be fabricated following the diagnostic wax-up and, should the provisional outcome satisfy the patient, the definitive prostheses will be fabricated to resemble the diagnostic wax-up (57, 89).

However, the most critical feature of the periodontic and prosthodontic relationship is the preparation margin. In general, margin quality is considered a critical feature to determine the acceptability of a fixed prosthesis. Having a minimal marginal opening is important to reduce the exposed cement line and subsequent leakage (62) that will result in bacterial penetration and adherence and, eventually, the development of caries and gingival inflammation (16, 64, 105).

Although crown margin accuracy has been a subject of extensive research, the clinical parameters of what constitutes an acceptable margin have not been established (69). Two questions remain to be answered; what constitutes an acceptable margin, and what is the implication of a marginal opening? Microscopically, all margins are open by about 100  $\mu\text{m}$ , which is sufficient for bacterial penetration (42, 95). Despite this, many of these margins can be considered clinically successful. The lack of a direct relationship between the development of disease and marginal opening (12, 158) suggests that a marginal opening that is not clinically detected is not necessarily associated with caries or periodontal complications. Nevertheless, a dentist must aim for the smallest possible marginal discrepancy to minimise the risk of disease development.

In terms of crown margin design, the three determining features are vertical location, horizontal width and shape.

## Vertical placement

The severity of gingival inflammation is related to the vertical location of the crown margin (74). Whenever possible margins should be supragingival because this is the most accessible location for assessment and hygiene maintenance. Supragingival margins are also advantageous in being easier to prepare, atraumatic (74), simple to record in an impression (103), and to evaluate the fit of the prosthesis and to maintain by the patient and clinician (22). Supragingival margins have been found to be associated with the lowest gingival index scores (8, 127, 130), while subgingival margins had the highest gingival index scores (127). Further, subgingival crown margins have also been found to be associated with loss of periodontal support, pocket development and gingival recession (39, 67, 127-129, 150, 151). This could be due to preparation trauma, constant irritation, microbial biofilm formation, and difficulties in maintaining a good level of hygiene at the margin. Since the prosthesis to tooth junction can be rough, it may facilitate microbial adhesion enhancing the risk of caries development. Valderhaug & Heloe (149) for example found significantly more caries around subgingival preparation margins (30%) than around supragingival margins (15%) after 5 years.

The advantages of supragingival margins are offset by their unaesthetic appearance. This is due to two reasons: the exposure of the tooth-prosthesis junction and an incomplete tooth profile alteration. Several authors have proposed solutions to the exposed tooth-prosthesis junction such as using collarless metal ceramic retainers (53). This is a viable option if the existing tooth structure is intact and it is possible to shade match the restoration with the remaining tooth. Subgingival margin placement can be considered where deficiencies exist subgingivally, where additional retention and resistance form is needed, where the whole contour of the tooth needs to be modified, and for aesthetic reasons. To minimise the risk of trauma to the gingival attachment some authors have recommended completion of the preparation when the gingival margins are retracted. A slightly subgingival margin (0.5 mm) will not interfere with the supracrestal fibre attachment or the biologic width and is very likely to be accessible by the patient for cleaning (96). As long as the restoration margin exhibits minimal opening, its location is minimally subgingival (0.5 mm) and it is fabricated with a biocompatible material, clinical problems are very unlikely to occur (52).

## Horizontal width

The width of the prepared margin will influence the material bulk, which dictates mechanical durability, contour and aesthetics. In general, the wider the margin, the more aesthetic and the better contoured the prosthesis can be. It is easier to achieve a natural appearance where the ceramic layer is thick enough to mask the metal and develop colour without overcontouring the prosthesis. An underprepared margin is much more likely to render the final prosthesis unaesthetic and unhygienic because of being overcontoured.

In general, the prepared margin tends to be the thinnest portion of the tooth preparation. An invasive margin preparation implies that the rest of the preparation will be overprepared, increasing the risk of iatrogenic damage. The clinician can manipulate the thickness of the margin by altering the materials used. For example, a metal margin requires a minimal reduction in the range of 0.3-0.5 mm, whereas ceramic requires 1-1.5 mm and metal-ceramic requires 1.2 mm (Fig. 10). The clinician might therefore opt to place thinner margins in non-aesthetic regions and reserve the wider margin for the aesthetic regions. For the labial aspect of anterior teeth, a more bulky contour may be acceptable (139) because it is easier to clean than less accessible areas. To facilitate an aesthetic outcome without over-preparing the abutment tooth, a labial ceramic margin can be considered (Fig. 11). This applies to the all-ceramic crown and the collarless metal-ceramic crown margin, where the metal core is relieved 1 mm from the margin and the entire margin is composed of ceramic.

A clinical dilemma can arise in situations where the teeth are elongated due to gingival recession. This can manifest clinically as narrower teeth cervically. In this situation, standard margin preparation, although feasible, will result in significant loss of dentine rendering the tooth preparation narrow and mechanically compromised. In this situation, the clinician should consider a more conservative preparation or in some cases, where emergence profile alteration is indicated, bulky crown contour can be achieved with a conservative tooth preparation. A similar problem could arise in situations where the furcation area is exposed. In this situation a narrow metal margin could be a suitable option to avoid creating plaque retentive features (6).

## Margin design

The available margin designs are chamfer, shoulder and feather-edge (Fig. 12). There is debate about the best margin design in terms of accuracy and fit. In general, the claims have anecdotal support and there is

no strong evidence that any specific design is better in terms of improving the fit of the prosthesis (16, 118, 141).

Overall, the chamfer and shoulder margins share similar features. Both involve the establishment of a 90 degree cavo-surface margin horizontal preparation surface. The chamfer margin is more conservative because of the curvature between the axial (vertical) and marginal (horizontal) preparation surfaces. They are easy to prepare, even if a thin margin is planned (0.5 mm), and are readable on the preparation, impression and master model. For metal-ceramic prostheses, both the chamfer and the shoulder exhibit a similar level of accuracy of fit for the metal framework after ceramic application (58, 119, 142).

There is evidence that a shoulder margin increases the accuracy of fit for ceramic prostheses produced by CAD/CAM. Bindl and Mormann found that the shoulder preparation yielded a smaller marginal gap (32  $\mu\text{m}$ ) than the chamfer preparation (71  $\mu\text{m}$ ) (11). In the same study however, both margin designs produced prostheses that exhibited clinically acceptable fit. Another study found that a shoulder preparation produced a smaller marginal discrepancy (28  $\mu\text{m}$ ) than the deep chamfer (65  $\mu\text{m}$ ) and the narrow chamfer (100  $\mu\text{m}$ ) (136). Likewise, a different investigation found that a shoulder margin had a better fit than a beveled shoulder (49). On the contrary, Komine et al. (71) found that the shoulder (73  $\mu\text{m}$ ) and chamfer (61  $\mu\text{m}$ ) preparations had a minimal effect on marginal fit and Comlekogu et al. (24) confirmed a similar level of fit with the two margin designs (114  $\mu\text{m}$  for shoulder and 144  $\mu\text{m}$  for chamfer). Since it was established that a marginal opening of between 100 and 150  $\mu\text{m}$  is clinically acceptable (42, 95), the statistical difference reported in various studies is most likely of little clinical significance.

The feather-edge margin is the least destructive margin preparation because it involves only axial reduction. This design could therefore be recommended if the preparation is to extend to the root surface. The feather-edge margin is also ideal for periodontally involved teeth with gingival recession (29). In these cases, it is common to observe recession at the gingival margin where the tooth is relatively narrow. Other margin designs would require the removal of a substantial amount of tooth structure, possibly compromising the long term prognosis of the tooth. Problems with the feather-edge margin include difficulties in reading margins, an increased risk of over-contouring the cervical portion of the prosthesis, and a risk of distorting the thin metal sections of the margin during fabrication. There is also no clinical evidence showing a negative biological consequence from well-fitting prostheses with feather-edge margins (9, 19, 74).

In general, a feather-edge margin has been considered only when a metal margin is planned (48). Recently however, the advent of high strength zirconia ceramic has resulted in further investigations into the use of the feather-edge preparation (24). Early studies have found that feather-edge margins do not appear to affect the durability of a zirconia coping (9, 115), and some clinical studies have suggested that

zirconia crowns with a feather-edge preparation have an acceptable performance in comparison with crowns with other margin designs (107, 111, 123).

Some authors have therefore suggested the provision of a smooth preparation margin, without irregularities and unsupported enamel, rather than recommending a specific margin geometry. Irregularities compromise the subsequent clinical and laboratory steps, increasing the likelihood of discrepancies (10, 163).

## 5. Prosthesis morphology

### Contour

The contour and profile of a prosthesis contribute to whether the prosthesis will blend harmoniously with the adjacent teeth (Fig. 13). The emergence profile, which is the axial contour of the prosthesis from the base of the gingival sulcus and through the gingiva, should produce a straight profile in the gingival third to facilitate oral hygiene. When considering the dimensions of the anterior teeth, the maxillary central incisor is the widest followed by the canine and the lateral incisor, although from a frontal view the apparent size of the teeth becomes progressively smaller from the midline distally. The long axis of the incisors is inclined so the incisal portion is more mesial than the gingival portion, in comparison with the remaining teeth that have a more of a lingual inclination. The height of contour of the posterior teeth occurs on the cervical third on the buccal surface, but on the middle third of the lingual surface. The height of contour and the mesiodistal inclination of the prosthesis should follow the contour of the adjacent teeth. The most common problem with axial contour is an excessive convexity or bulge (Fig. 14). Overcontoured prostheses with large convexities result in food accumulation and gingival inflammation (121, 134). Interestingly, while it has been shown that overcontouring produces gingival inflammation, undercontouring does not (121).

### Furcation considerations

Furcation involvement is challenging because of the potential for plaque accumulation and its consequences, particularly if the gingival third of the axial surface of the prosthesis is overcontoured. A number of treatment options may be considered with the periodontist to manage a tooth with furcation involvement, including resection, tissue regeneration, a combination of both or extraction of the tooth

(20). When preparing teeth with furcation involvement, consideration needs to be given to the root anatomy and the coronal tooth structure. In particular, the furcation undercut needs to be considered when preparing these teeth so that the preparation will facilitate gingival health by not collecting plaque or making hygiene access difficult. In the furcation area, the root trunk has an anatomical concavity that increases in an apical direction until there is separation of the roots. Because of this, the curvature of the teeth is not effective at directing food away from the cervical area following gingival recession that exposes the furcation. The crown contours must therefore be re-established to minimise plaque collection. A maxillary or mandibular molar with a Class 1 furcation requires a margin preparation that includes the furcation, or is far enough coronal to the furcation that it is not involved with the crown preparation (6). The fabricated crown form should have a flat emergence profile coronally so that there is no undercut to trap food or plaque (6, 162), and the crown should re-create the contours of the furcation, to merge or blend with the coronal aspects of the crown to minimise cleaning difficulty in these areas.

## Interproximal contacts

Interproximal contacts on anterior teeth are located progressively closer to the gingiva the more distal they are from the midline, and the incisal embrasures become larger from the central incisor to the canine. Interproximal contacts on posterior teeth are located in the occlusal third of the crown, except for contacts between the maxillary first and second molars, which are located in the middle third (145). The interproximal contacts must not be too tight, too loose or open. Prostheses with interproximal contacts that are too tight are difficult to seat, produce discomfort to the patient and are difficult to floss; contacts that are too loose or open allow food impaction. Contacts that are too narrow can also result in food wedging between the teeth and contacts that are too wide do not properly deflect food from the gingiva. Because of this, the contact should be more than a just a point occlusogingivally, but should not extend to encroach on the gingival embrasure (Fig. 15). The interproximal contacts are placed slightly to the buccal of the middle of the posterior teeth, except for the contact between the maxillary first and second molar which is placed mid-buccolingually (15). The axial surface below the contact point should be flat to facilitate the use of floss.

## Management of recession and long teeth

Teeth that have been saved by periodontal treatment frequently have reduced supporting bone height, and if teeth have been lost because of periodontal disease, there may be a moderate to severe loss of residual ridge. One solution to manage recession and long teeth, whether for a pontic or a natural tooth is to simulate the normal crown or root and emphasise the cemento-enamel junction, with staining to simulate exposed root. A way of simulating the gingival tissues is to use gingivally coloured ceramic. Gingivally coloured ceramic can also be added to the gingival embrasure area where there are black triangles to simulate interdental papilla, although the shade of the gingivally coloured ceramic rarely matches the hue of the patient's gingiva (152). Because of this, the use of this ceramic can be satisfactory when replacing molars and mandibular incisors where the gingiva is not in a high aesthetic area, but is more difficult in high aesthetic areas, such as the maxillary incisors. Restoring the gingival embrasures may also reduce or stop soft tissue proliferation, however the metal framework must support the gingival extension of ceramic otherwise there is a risk that the ceramic will fracture (113).

## 6. Prosthesis material

A prosthesis must have sufficient strength so that it does not deform in function. Deformation may occur because of incorrect material selection, insufficient tooth preparation and/or unsatisfactory framework design. The aesthetic expectations of the patient are important. Most patients prefer their prostheses to look as natural as possible, but this should not take priority over prognostic factors such as remaining tooth structure, function, interocclusal space and other occlusal considerations. Material choice will be a major contributing factor to the extent of tooth preparation necessary for the proposed prosthesis. Table 2 provides a summary of the indications, advantages and disadvantages of the most commonly used materials in fixed prosthodontics.

Metal-ceramic prostheses have been widely used for restoring anterior and posterior teeth since the 1960s, and because of their success, they are the gold standard to which alternatives such as all-ceramic prostheses are compared. A limitation is that they are not metal free, which is a preference for some patients. Tooth preparation is also not as conservative as the preparation for gold and some monolithic ceramic prostheses because of the need to mask the opaque metal coping.

All-ceramic prostheses can provide excellent aesthetic results because they can mimic the original, or adjacent, tooth colour better than other options (27, 55). Ceramics are brittle materials however and at risk of fracture, particularly when functioning on molar teeth. Feldspathic, leucite reinforced and lithium disilicate ceramics are suitable for crowning anterior teeth and have excellent aesthetics (41, 144).

Lithium disilicates are also suitable for crowning premolars and for short span anterior FDPs (144). Ceramics with high strength cores such as alumina or zirconia are suitable for crowning posterior teeth (110). In addition, zirconia is suitable for short span posterior FDPs (122). To date, the limited available literature suggests that zirconia is the most suitable all-ceramic option suitable for restoring molars and for short span FDPs that include molar teeth (27). Crown preparations for bilayered ceramics are not conservative however because of the need for material space for the ceramic core (approximately 0.4 mm) and the overlying veneering ceramic (up to 1 mm).

Ceramics for high strength cores are opaque and should have a veneering layer to provide a tooth coloured appearance (59). More recently, zirconia has been used to manufacture monolithic crowns (164). Further, translucent zirconia that accepts staining has been proposed to overcome the aesthetic limitations (120).

## Allergy and biocompatibility

All materials used in the oral cavity must be biocompatible. The materials should also be able to be handled safely in the clinical and laboratory environment. There are unlikely to be health issues with high gold, or high palladium alloys used in metal and metal-ceramic prostheses, or with ceramic materials (155, 156). There are possible health hazards with alloys containing nickel, which must be avoided in patients with a nickel allergy.

Although rare, the majority of the documented hypersensitivity reactions to dental materials are delayed hypersensitivity reactions. Clinically, these commonly present as a contact dermatitis or a mucositis. For cases that present with an allergic reaction, it is mandatory to document the clinical reaction, and identify and remove the source of allergen. In documented cases of allergy, reactions often subside in a few weeks. However in patients with lichenoid or erosive lesions topographically related to the prosthesis, replacement of the prosthesis should be considered. Before undertaking any extensive replacement of prostheses, careful evaluation should be carried out in collaboration with a specialist in the field such as a dermatologist (69).

## Conclusion

A healthy periodontium is a prerequisite for success with fixed prosthodontic treatment. Without a strong interdisciplinary relationship between periodontics and prosthodontics the aesthetic, functional and/or biological outcome may be compromised and necessitate extensive and expensive re-treatment. When planning prosthodontic treatment, consideration should be given to factors such as the design of the prosthesis, the preparation and the pontic, the number and quality of the abutment teeth, and material choice while considering the patient's concerns and expectations. Abutment selection, tooth position, residual ridge form and occlusion should also be evaluated before treatment. The location of the margin and the contour and emergence profile of the prosthesis will influence the response of the gingival tissues to the prosthesis. Although periodontal factors do not usually have a direct effect on the survival of a fixed prosthesis, harmony between the prosthesis and the periodontium is critical otherwise aesthetics, the longevity of the prosthesis and the periodontium will be compromised. Pontic design and cleansability also contribute to the response of the gingival tissues as well as the clinical and aesthetic outcome. Even an ideal pontic design will not prevent inflammation of the mucosa adjacent to the pontic if pontic hygiene is not maintained by removal of plaque. Case selection is therefore essential, with patient compliance and motivation to maintain a disease-free mouth being particularly important. Patients need to be able to carry out adequate oral hygiene and should be educated how to care for and maintain their fixed prosthesis. Regular recalls will also allow an opportunity for review and early detection and treatment of failures.

## References

1. Abduo J, Lyons K. Clinical considerations for increasing occlusal vertical dimension: a review. *Aust Dent J* 2012; **57**: 2-10.
2. Allen EP. Use of mucogingival surgical procedures to enhance esthetics. *Dent Clin North Am* 1988; **32**: 307-330.
3. Ante IH. The fundamental principles, design and construction of crown and bridge prosthesis. *Dent Item Int* 1928; **50**: 215-232.
4. Axelsson P, Nystrom B, Lindhe J. The long-term effect of a plaque control program on tooth mortality, caries and periodontal disease in adults. Results after 30 years of maintenance. *J Clin Periodontol* 2004; **31**: 749-757.
5. Balevi B. Ante's law is not evidence based. *J Am Dent Assoc* 2012; **143**: 1011-1012.

6. Becker CM, Kaldahl WB. Current theories of crown contour, margin placement, and pontic design. *J Prosthet Dent* 1981; **45**: 268-277.
7. Bergenholtz G, Nyman S. Endodontic complications following periodontal and prosthetic treatment of patients with advanced periodontal disease. *J Periodontol* 1984; **55**: 63-68.
8. Bergman B, Hugoson A, Olsson CO. Periodontal and prosthetic conditions in patients treated with removable partial dentures and artificial crowns. A longitudinal two-year study. *Acta Odontol Scand* 1971; **29**: 621-638.
9. Beuer F, Aggstaller H, Edelhoff D, Gernet W. Effect of preparation design on the fracture resistance of zirconia crown copings. *Dent Mater J* 2008; **27**: 362-367.
10. Beuer F, Schweiger J, Edelhoff D. Digital dentistry: an overview of recent developments for CAD/CAM generated restorations. *Br Dent J* 2008; **204**: 505-511.
11. Bindl A, Mormann WH. Fit of all-ceramic posterior fixed partial denture frameworks in vitro. *Int J Periodontics Restorative Dent* 2007; **27**: 567-575.
12. Bjorn AL, Bjorn H, Grkovic B. Marginal fit of restorations and its relation to periodontal bone level. I. Metal fillings. *Odontol Revy* 1969; **20**: 311-321.
13. Block PL. Restorative margins and periodontal health: a new look at an old perspective. *J Prosthet Dent* 1987; **57**: 683-689.
14. Bragger U, Lauchenauer D, Lang NP. Surgical lengthening of the clinical crown. *J Clin Periodontol* 1992; **19**: 58-63.
15. Burch JG, Miller JB. Evaluating crown contours of a wax pattern. *J Prosthet Dent* 1973; **30**: 454-458.
16. Byrne G. Influence of finish-line form on crown cementation. *Int J Prosthodont* 1992; **5**: 137-144.
17. Camargo PM, Melnick PR, Kenney EB. The use of free gingival grafts for aesthetic purposes. *Periodontol 2000* 2001; **27**: 72-96.
18. Camargo PM, Melnick PR, Pirih FQ, Lagos R, Takei HH. Treatment of drug-induced gingival enlargement: aesthetic and functional considerations. *Periodontol 2000* 2001; **27**: 131-138.
19. Carnevale G, Sterrantino SF, Di Febo G. Soft and hard tissue wound healing following tooth preparation to the alveolar crest. *Int J Periodontics Restorative Dent* 1983; **3**: 36-53.
20. Carnevale G, Pontoriero R, Hurzeler MB. Management of furcation involvement. *Periodontol 2000* 1995; **9**: 69-89.
21. Cho HS, Jang HS, Kim DK, Park JC, Kim HJ, Choi SH, Kim CK, Kim BO. The effects of interproximal distance between roots on the existence of interdental papillae according to the distance from the contact point to the alveolar crest. *J Periodontol* 2006; **77**: 1651-1657.
22. Christensen GJ. Marginal fit of gold inlay castings. *J Prosthet Dent* 1966; **16**: 297-305.

23. Coachman C, Salama M, Garber D, Calamita M, Salama H, Cabral G. Prosthetic gingival reconstruction in fixed partial restorations. Part 3: laboratory procedures and maintenance. *Int J Periodontics Restorative Dent* 2010; **30**: 19-29.
24. Comlekoglu M, Dundar M, Ozcan M, Gungor M, Gokce B, Artunc C. Influence of cervical finish line type on the marginal adaptation of zirconia ceramic crowns. *Oper Dent* 2009; **34**: 586-592.
25. Davies SJ, Gray RM, Whitehead SA. Good occlusal practice in advanced restorative dentistry. *Br Dent J* 2001; **191**: 421-434.
26. De Backer H, Van Maele G, De Moor N, Van den Berghe L. Long-term results of short-span versus long-span fixed dental prostheses: an up to 20-year retrospective study. *Int J Prosthodont* 2008; **21**: 75-85.
27. Della Bona A, Kelly JR. The clinical success of all-ceramic restorations. *J Am Dent Assoc* 2008; **139**: Suppl: 8-13.
28. Dibart S, Capri D, Kachouh I, Van Dyke T, Nunn ME. Crown lengthening in mandibular molars: a 5-year retrospective radiographic analysis. *J Periodontol* 2003; **74**: 815-821.
29. DiFebo G, Carnevale G, Sterrantino SF. Treatment of a case of advanced periodontitis: clinical procedures utilizing the "combined preparation" technique. *Int J Periodontics Restorative Dent* 1985; **5**: 52-62.
30. Donovan TE, Cho GC. Predictable aesthetics with metal-ceramic and all-ceramic crowns: the critical importance of soft-tissue management. *Periodontol 2000* 2001; **27**: 121-130.
31. Dowling EA, Maze GI, Kaldahl WB. Postsurgical timing of restorative therapy: a review. *J Prosthodont* 1994; **3**: 172-177.
32. Dylina TJ. Contour determination for ovate pontics. *J Prosthet Dent* 1999; **82**: 136-142.
33. Edelhoff D, Spiekermann H, Yildirim M. A review of esthetic pontic design options. *Quintessence Int* 2002; **33**: 736-746.
34. Ericsson I, Lindhe J. Lack of effect of trauma from occlusion on the recurrence of experimental periodontitis. *J Clin Periodontol* 1977; **4**: 115-127.
35. Ericsson I, Lindhe J. Lack of significance of increased tooth mobility in experimental periodontitis. *J Periodontol* 1984; **55**: 447-452.
36. Faucher RR, Bryant RA. Bilateral fixed splints. *Int J Periodontics Restorative Dent* 1983; **3**: 8-37.
37. Fayyad MA, Al-Rafee MA. Failure of dental bridges. IV. Effect of supporting periodontal ligament. *J Oral Rehabil* 1997; **24**: 401-403.
38. Felton DA, Kanoy BE, Bayne SC, Wirthman GP. Effect of in vivo crown margin discrepancies on periodontal health. *J Prosthet Dent* 1991; **65**: 357-364.

39. Flores-de-Jacoby L, Zafiropoulos GG, Ciancio S. Effect of crown margin location on plaque and periodontal health. *Int J Periodontics Restorative Dent* 1989; **9**: 197-205.
40. Foster LV. The relationship between failure and design in conventional bridgework from general dental practice. *J Oral Rehabil* 1991; **18**: 491-495.
41. Fradeani M, Redemagni M. An 11-year clinical evaluation of leucite-reinforced glass-ceramic crowns: a retrospective study. *Quintessence Int* 2002; **33**: 503-510.
42. Fransson B, Oilo G, Gjeitanger R. The fit of metal-ceramic crowns, a clinical study. *Dent Mater* 1985; **1**: 197-199.
43. Fugazzotto PA. Restorative considerations: comprehensive management of the embrasure space. *J Mass Dent Soc* 1998; **46**: 18-36.
44. Fuhrmann RA, Bucker A, Diedrich PR. Assessment of alveolar bone loss with high resolution computed tomography. *J Periodontol Res* 1995; **30**: 258-263.
45. Fuhrmann RA, Bucker A, Diedrich PR. Furcation involvement: comparison of dental radiographs and HR-CT-slices in human specimens. *J Periodontol Res* 1997; **32**: 409-418.
46. Garcia LT, Verrett RG. Metal-ceramic restorations--custom characterization with pink porcelain. *Compend Contin Educ Dent* 2004; **25**: 242-246.
47. Gargiulo AW, Wentz FM, Orban B. Dimensions and relations of the dentogingival junction in humans. *J Periodontol* 1961; **32**: 261-267.
48. Gavelis JR, Morency JD, Riley ED, Sozio RB. The effect of various finish line preparations on the marginal seal and occlusal seat of full crown preparations. *J Prosthet Dent* 1981; **45**: 138-145.
49. Giannetopoulos S, van Noort R, Tsitrou E. Evaluation of the marginal integrity of ceramic copings with different marginal angles using two different CAD/CAM systems. *J Dent* 2010; **38**: 980-986.
50. Giargia M, Lindhe J. Tooth mobility and periodontal disease. *J Clin Periodontol* 1997; **24**: 785-795.
51. The glossary of prosthodontic terms. *J Prosthet Dent* 2005; **94**: 10-92.
52. Goldberg PV, Higginbottom FL, Wilson TG. Periodontal considerations in restorative and implant therapy. *Periodontol 2000* 2001; **25**: 100-109.
53. Goodacre CJ, Van Roekel NB, Dykema RW, Ullmann RB. The collarless metal-ceramic crown. *J Prosthet Dent* 1977; **38**: 615-622.
54. Goodacre CJ, Campagni WV, Aquilino SA. Tooth preparations for complete crowns: an art form based on scientific principles. *J Prosthet Dent* 2001; **85**: 363-376.
55. Gracis S, Fradeani M, Celletti R, Bracchetti G. Biological integration of aesthetic restorations: factors influencing appearance and long-term success. *Periodontol 2000* 2001; **27**: 29-44.
56. Grossmann Y, Sadan A. The prosthodontic concept of crown-to-root ratio: a review of the literature. *J Prosthet Dent* 2005; **93**: 559-562.

57. Gurel G. Porcelain laminate veneers: minimal tooth preparation by design. *Dent Clin North Am* 2007; **51**: 419-431.
58. Hamaguchi H, Cacciatore A, Tueller VM. Marginal distortion of the porcelain- bonded-to-metal complete crown: an SEM study. *J Prosthet Dent* 1982; **47**: 146-153.
59. Heffernan MJ, Aquilino SA, Diaz-Arnold AM, Haselton DR, Stanford CM, Vargas MA. Relative translucency of six all-ceramic systems. Part I: core materials. *J Prosthet Dent* 2002; **88**: 4-9.
60. Ingber JS. Forced eruption: part II. A method of treating nonrestorable teeth--Periodontal and restorative considerations. *J Periodontol* 1976; **47**: 203-216.
61. Ingber JS. Forced eruption: alteration of soft tissue cosmetic deformities. *Int J Periodontics Restorative Dent* 1989; **9**: 416-425.
62. Jacobs MS, Windeler AS. An investigation of dental luting cement solubility as a function of the marginal gap. *J Prosthet Dent* 1991; **65**: 436-442.
63. Jacques LB, Coelho AB, Hollweg H, Conti PC. Tissue sculpturing: an alternative method for improving esthetics of anterior fixed prosthodontics. *J Prosthet Dent* 1999; **81**: 630-633.
64. Jahangiri L, Wahlers C, Hittelman E, Matheson P. Assessment of sensitivity and specificity of clinical evaluation of cast restoration marginal accuracy compared to stereomicroscopy. *J Prosthet Dent* 2005; **93**: 138-142.
65. Jorgensen MG, Nowzari H. Aesthetic crown lengthening. *Periodontol 2000* 2001; **27**: 45-58.
66. Kamalakidis S, Paniz G, Kang KH, Hirayama H. Nonsurgical management of soft tissue deficiencies for anterior single implant-supported restorations: a clinical report. *J Prosthet Dent* 2007; **97**: 1-5.
67. Karlson K. Gingival reactions to dental restorations. *Acta Odontol Scand* 1970; **28**: 895-904.
68. Kois JC. Altering gingival levels: the restorative connection. Part I: biologic variables. *J Esthet Dent* 1994; **6**: 3-9.
69. Kois JC. The restorative-periodontal interface: biological parameters. *Periodontol 2000* 1996; **11**: 29-38.
70. Kois JC, Phillips KM. Occlusal vertical dimension: alteration concerns. *Compend Contin Educ Dent* 1997; **18**: 1169-1177.
71. Komine F, Iwai T, Kobayashi K, Matsumura H. Marginal and internal adaptation of zirconium dioxide ceramic copings and crowns with different finish line designs. *Dent Mater J* 2007; **26**: 659-664.
72. Lang NP, Loe H. The relationship between the width of keratinized gingiva and gingival health. *J Periodontol* 1972; **43**: 623-627.
73. Lang NP, Kiel RA, Anderhalden K. Clinical and microbiological effects of subgingival restorations with overhanging or clinically perfect margins. *J Clin Periodontol* 1983; **10**: 563-578.

74. Lang NP. Periodontal considerations in prosthetic dentistry. *Periodontol 2000* 1995; **9**: 118-131.
75. Langer B, Calagna LJ. The subepithelial connective tissue graft. A new approach to the enhancement of anterior cosmetics. *Int J Periodontics Restorative Dent* 1982; **2**: 22-33.
76. Lanning SK, Waldrop TC, Gunsolley JC, Maynard JG. Surgical crown lengthening: evaluation of the biological width. *J Periodontol* 2003; **74**: 468-474.
77. Laurell L, Lundgren D. Periodontal ligament areas and occlusal forces in dentitions restored with cross-arch bilateral end abutment bridges. *J Clin Periodontol* 1985; **12**: 850-860.
78. Laurell L, Lundgren D. Periodontal ligament areas and occlusal forces in dentitions restored with cross-arch unilateral posterior two-unit cantilever bridges. *J Clin Periodontol* 1986; **13**: 33-38.
79. Lee EA, Jun SK. Achieving aesthetic excellence through an outcome-based restorative treatment rationale. *Pract Periodontics Aesthet Dent* 2000; **12**: 641-648.
80. Lee EA, Jun SK. Aesthetic design preservation in multidisciplinary therapy: philosophy and clinical execution. *Pract Proced Aesthet Dent* 2002; **14**: 561-569.
81. Lee EA. Aesthetic crown lengthening: classification, biologic rationale, and treatment planning considerations. *Pract Proced Aesthet Dent* 2004; **16**: 769-778.
82. Lee HE, Wang CH, Chang GL, Chen TY. Stress analysis of four-unit fixed bridges on abutment teeth with reduced periodontal support. *J Oral Rehabil* 1995; **22**: 705-710.
83. Leempoel PJ, Kayser AF, Van Rossum GM, De Haan AF. The survival rate of bridges. A study of 1674 bridges in 40 Dutch general practices. *J Oral Rehabil* 1995; **22**: 327-330.
84. Lie T. Periodontal surgery for the maxillary anterior area. *Int J Periodontics Restorative Dent* 1992; **12**: 72-81.
85. Lindhe J, Ericsson I. The influence of trauma from occlusion on reduced but healthy periodontal tissues in dogs. *J Clin Periodontol* 1976; **3**: 110-122.
86. Lindhe J, Nyman S. The role of occlusion in periodontal disease and the biological rationale for splinting in treatment of periodontitis. *Oral Sci Rev* 1977; **10**: 11-43.
87. Liu CL. Use of a modified ovate pontic in areas of ridge defects: a report of two cases. *J Esthet Restor Dent* 2004; **16**: 273-281.
88. Lulic M, Bragger U, Lang NP, Zwahlen M, Salvi GE. Ante's (1926) law revisited: a systematic review on survival rates and complications of fixed dental prostheses (FDPs) on severely reduced periodontal tissue support. *Clin Oral Implants Res* 2007; **18**: 63-72.
89. Magne P, Belser UC. Novel porcelain laminate preparation approach driven by a diagnostic mock-up. *J Esthet Restor Dent* 2004; **16**: 7-16.
90. McGuire MK. Prognosis versus actual outcome: a long-term survey of 100 treated periodontal patients under maintenance care. *J Periodontol* 1991; **62**: 51-58.

91. McGuire MK, Nunn ME. Prognosis versus actual outcome. III. The effectiveness of clinical parameters in accurately predicting tooth survival. *J Periodontol* 1996; **67**: 666-674.
92. Mehta P, Lim LP. The width of the attached gingiva--much ado about nothing? *J Dent* 2010; **38**: 517-525.
93. Misch KA, Yi ES, Sarment DP. Accuracy of cone beam computed tomography for periodontal defect measurements. *J Periodontol* 2006; **77**: 1261-1266.
94. Mishkin DJ, Gellin RG. Re: Biologic width and crown lengthening. *J Periodontol* 1993; **64**: 920.
95. Molin M, Karlsson S. A 3-year clinical follow-up study of a ceramic (Optec) inlay system. *Acta Odontol Scand* 1996; **54**: 145-149.
96. Nevins M, Skurow HM. The intracrevicular restorative margin, the biologic width, and the maintenance of the gingival margin. *Int J Periodontics Restorative Dent* 1984; **4**: 30-49.
97. Nowzari H. Aesthetic osseous surgery in the treatment of periodontitis. *Periodontol 2000* 2001; **27**: 8-28.
98. Nyman S, Lindhe J, Lundgren D. The role of occlusion for the stability of fixed bridges in patients with reduced periodontal tissue support. *J Clin Periodontol* 1975; **2**: 53-66.
99. Nyman S, Lindhe J. Persistent tooth hypermobility following completion of periodontal treatment. *J Clin Periodontol* 1976; **3**: 81-93.
100. Nyman S, Lindhe J. Prosthetic rehabilitation of patients with advanced periodontal disease. *J Clin Periodontol* 1976; **3**: 135-147.
101. Nyman S, Ericsson I. The capacity of reduced periodontal tissues to support fixed bridgework. *J Clin Periodontol* 1982; **9**: 409-414.
102. Nyman SR, Lang NP. Tooth mobility and the biological rationale for splinting teeth. *Periodontol 2000* 1994; **4**: 15-22.
103. O'Leary TJ, Standish SM, Bloomer RS. Severe periodontal destruction following impression procedures. *J Periodontol* 1973; **44**: 43-48.
104. Orsini G, Murmura G, Artese L, Piattelli A, Piccirilli M, Caputi S. Tissue healing under provisional restorations with ovate pontics: a pilot human histological study. *J Prosthet Dent* 2006; **96**: 252-257.
105. Padilla MT, Bailey JH. Margin configuration, die spacers, fitting of retainers/crowns, and soldering. *Dent Clin North Am* 1992; **36**: 743-764.
106. Pama-Benfenati S, Fugazzotto PA, Ferreira PM, Ruben MP, Kramer GM. The effect of restorative margins on the postsurgical development and nature of the periodontium. Part II. Anatomical considerations. *Int J Periodontics Restorative Dent* 1986; **6**: 64-75.
107. Patroni S, Chiodera G, Caliceti C, Ferrari P. CAD/CAM technology and zirconium oxide with feather-edge marginal preparation. *Eur J Esthet Dent* 2010; **5**: 78-100.

108. Penny RE, Kraal JH. Crown-to-root ratio: its significance in restorative dentistry. *J Prosthet Dent* 1979; **42**: 34-38.
109. Pinsky HM, Dyda S, Pinsky RW, Misch KA, Sarment DP. Accuracy of three-dimensional measurements using cone-beam CT. *Dentomaxillofac Radiol* 2006; **35**: 410-416.
110. Pjetursson BE, Sailer I, Zwahlen M, Hammerle CH. A systematic review of the survival and complication rates of all-ceramic and metal-ceramic reconstructions after an observation period of at least 3 years. Part I: Single crowns. *Clin Oral Implants Res* 2007; **18**: 73-85.
111. Poggio CE, Dosoli R, Ercoli C. A retrospective analysis of 102 zirconia single crowns with knife-edge margins. *J Prosthet Dent* 2012; **107**: 316-321.
112. Pontoriero R, Celenza F, Jr., Ricci G, Carnevale G. Rapid extrusion with fiber resection: a combined orthodontic-periodontic treatment modality. *Int J Periodontics Restorative Dent* 1987; **7**: 30-43.
113. Porter CB, Jr.. Anterior pontic design: a logical progression. *J Prosthet Dent* 1984; **51**: 774-776.
114. Raigrodski AJ. Contemporary materials and technologies for all-ceramic fixed partial dentures: a review of the literature. *J Prosthet Dent* 2004; **92**: 557-562.
115. Reich S, Petschelt A, Lohbauer U. The effect of finish line preparation and layer thickness on the failure load and fractography of ZrO<sub>2</sub> copings. *J Prosthet Dent* 2008; **99**: 369-376.
116. Remagen W, Prezmecky L. Bone augmentation with hydroxyapatite: histological findings in 55 cases. *Implant Dent* 1995; **4**: 182-188.
117. Reynolds JM. Abutment selection for fixed prosthodontics. *J Prosthet Dent* 1968; **19**: 483-488.
118. Rich-Snapp K, Aquilino S, Svare C, Turner K. Change in marginal fit as related to margin design, alloy type, and porcelain proximity in porcelain-fused-to-metal restorations. *J Prosthet Dent* 1988; **60**: 435-439.
119. Richter-Snapp K, Aquilino SA, Svare CW, Turner KA. Change in marginal fit as related to margin design, alloy type, and porcelain proximity in porcelain-fused-to-metal restorations. *J Prosthet Dent* 1988; **60**: 435-439.
120. Rinke S, Fischer C. Range of indications for translucent zirconia modifications: clinical and technical aspects. *Quintessence Int* 2013; **44**: 557-566.
121. Sackett BP, Gildenhuis RR. The effect of axial crown overcontour on adolescents. *J Periodontol* 1976; **47**: 320-323.
122. Sailer I, Pjetursson BE, Zwahlen M, Hammerle CH. A systematic review of the survival and complication rates of all-ceramic and metal-ceramic reconstructions after an observation period of at least 3 years. Part II: Fixed dental prostheses. *Clin Oral Implants Res* 2007; **18**: 86-96.

123. Schmitt J, Wichmann M, Holst S, Reich S. Restoring severely compromised anterior teeth with zirconia crowns and feather-edged margin preparations: a 3-year follow-up of a prospective clinical trial. *Int J Prosthodont* 2010; **23**: 107-109.
124. Seibert JS. Reconstruction of deformed, partially edentulous ridges, using full thickness onlay grafts. Part I. Technique and wound healing. *Compend Contin Educ Dent* 1983; **4**: 437-453.
125. Seibert JS. Reconstruction of deformed, partially edentulous ridges, using full thickness onlay grafts. Part II. Prosthetic/periodontal interrelationships. *Compend Contin Educ Dent* 1983; **4**: 549-562.
126. Shefter GJ, McFall WT, Jr.. Occlusal relations and periodontal status in human adults. *J Periodontol* 1984; **55**: 368-374.
127. Silness J. Periodontal conditions in patients treated with dental bridges. 3. The relationship between the location of the crown margin and the periodontal condition. *J Periodontal Res* 1970; **5**: 225-229.
128. Silness J. Periodontal conditions in patients treated with dental bridges. *J Periodontal Res* 1970; **5**: 60-68.
129. Silness J. Periodontal conditions in patients treated with dental bridges. 2. The influence of full and partial crowns on plaque accumulation, development of gingivitis and pocket formation. *J Periodontal Res* 1970; **5**: 219-224.
130. Silness J. Fixed prosthodontics and periodontal health. *Dent Clin North Am* 1980; **24**: 317-329.
131. Silness J, Gustavsen F, Mangersnes K. The relationship between pontic hygiene and mucosal inflammation in fixed bridge recipients. *J Periodontal Res* 1982; **17**: 434-439.
132. Smukler H, Chaibi M. Periodontal and dental considerations in clinical crown extension: a rational basis for treatment. *Int J Periodontics Restorative Dent* 1997; **17**: 464-477.
133. Sonick M. Esthetic crown lengthening for maxillary anterior teeth. *Compend Contin Educ Dent* 1997; **18**: 807-819.
134. Sorensen JA. A rationale for comparison of plaque-retaining properties of crown systems. *J Prosthet Dent* 1989; **62**: 264-269.
135. Sorensen SE, Larsen IB, Jorgensen KD. Gingival and alveolar bone reaction to marginal fit of subgingival crown margins. *Scand J Dent Res* 1986; **94**: 109-114.
136. Souza RO, Ozcan M, Pavanelli CA, Buso L, Lombardo GH, Michida SM, Mesquita AM, Bottino MA. Marginal and internal discrepancies related to margin design of ceramic crowns fabricated by a CAD/CAM system. *J Prosthodont* 2012; **21**: 94-100.
137. Spear F. Implants or pontics: decision making for anterior tooth replacement. *J Am Dent Assoc* 2009; **140**: 1160-1166.
138. Spear FM. The use of implants and ovate pontics in the esthetic zone. *Compend Contin Educ Dent* 2008; **29**: 72-80.

139. Sundh B, Kohler B. An in vivo study of the impact of different emergence profiles of procera titanium crowns on quantity and quality of plaque. *Int J Prosthodont* 2002; **15**: 457-460.
140. Svanberg G, Lindhe J. Vascular reactions in the periodontal ligament incident to trauma from occlusion. *J Clin Periodontol* 1974; **1**: 58-69.
141. Syu J, Byrne G, Laub L, Land M. Influence of finish-line geometry on the fit of crowns. *Int J Prosthodont* 1993; **6**: 25-30.
142. Syu JZ, Byrne G, Laub LW, Land MF. Influence of finish-line geometry on the fit of crowns. *Int J Prosthodont* 1993; **6**: 25-30.
143. Tarnow DP, Magner AW, Fletcher P. The effect of the distance from the contact point to the crest of bone on the presence or absence of the interproximal dental papilla. *J Periodontol* 1992; **63**: 995-996.
144. Taskonak B, Mecholsky JJ, Jr., Anusavice KJ. Fracture surface analysis of clinically failed fixed partial dentures. *J Dent Res* 2006; **85**: 277-281.
145. Tjan AH, Freed H, Miller GD. Current controversies in axial contour design. *J Prosthet Dent* 1980; **44**: 536-540.
146. Tolboe H, Isidor F, Budtz-Jorgensen E, Kaaber S. Influence of oral hygiene on the mucosal conditions beneath bridge pontics. *Scand J Dent Res* 1987; **95**: 475-482.
147. Tripodakis AP, Constandtinides A. Tissue response under hyperpressure from Convex pontics. *Int J Periodontics Restorative Dentist* 1990; **10**: 408-414.
148. Valderhaug J, Birkeland JM. Periodontal conditions in patients 5 years following insertion of fixed prostheses. Pocket depth and loss of attachment. *J Oral Rehabil* 1976; **3**: 237-243.
149. Valderhaug J, Heloe LA. Oral hygiene in a group of supervised patients with fixed prostheses. *J Periodontol* 1977; **48**: 221-224.
150. Valderhaug J. Periodontal conditions and carious lesions following the insertion of fixed prostheses: a 10-year follow-up study. *Int Dent J* 1980; **30**: 296-304.
151. Valderhaug J. A 15-year clinical evaluation of fixed prosthodontics. *Acta Odontol Scand* 1991; **49**: 35-40.
152. Vryonis P. Esthetics and function in multiple unit bridges. *Quintessence Dent Technol* 1981; **5**: 237-241.
153. Waerhaug J. Subgingival plaque and loss of attachment in periodontosis as observed in autopsy material. *J Periodontol* 1976; **47**: 636-642.
154. Walker M, Hansen P. Template for surgical crown lengthening: fabrication technique. *J Prosthodont* 1998; **7**: 265-267.
155. Wataha JC. Principles of biocompatibility for dental practitioners. *J Prosthet Dent* 2001; **86**: 203-209.

156. Wataha JC. Alloys for prosthodontic restorations. *J Prosthet Dent* 2002; **87**: 351-363.
157. Wennstrom JL. Lack of association between width of attached gingiva and development of soft tissue recession. A 5-year longitudinal study. *J Clin Periodontol* 1987; **14**: 181-184.
158. White SN, Ingles S, Kipnis V. Influence of marginal opening on microleakage of cemented artificial crowns. *J Prosthet Dent* 1994; **71**: 257-264.
159. Wise MD. Stability of gingival crest after surgery and before anterior crown placement. *J Prosthet Dent* 1985; **53**: 20-23.
160. Wylie RS, Caputo AA. Fixed cantilever splints on teeth with normal and reduced periodontal support. *J Prosthet Dent* 1991; **66**: 737-742.
161. Yang HS, Lang LA, Felton DA. Finite element stress analysis on the effect of splinting in fixed partial dentures. *J Prosthet Dent* 1999; **81**: 721-728.
162. Yuodelis RA, Weaver JD, Sapkos S. Facial and lingual contours of artificial complete crown restorations and their effects on the periodontium. *J Prosthet Dent* 1973; **29**: 61-66.
163. Zena R, Khan Z, Fraunhofer J. Shoulder preparations for collarless metal ceramic crowns: Hand planning as opposed to rotary instrumentation. *J Prosthet Dent* 1989; **62**: 273-277.
164. Zhang Y, Lee JJ, Srikanth R, Lawn BR. Edge chipping and flexural resistance of monolithic ceramics. *Dental Mater* 2013. In press.
165. Zitzmann NU, Marinello CP, Berglundh T. The ovate pontic design: a histologic observation in humans. *J Prosthet Dent* 2002; **88**: 375-380.

# Interdisciplinary interface between fixed prosthodontics and periodontics

## List of tables

**Table 1.** Gingival morphological variables

<b>Variable</b>	<b>Description and ideal criteria</b>
Attached gingiva	Continuous and at least 2 mm even width (72)
Gingival display	Varies between individuals Dependent on the lip line during function: <ul style="list-style-type: none"><li>• High lip line: most challenging to manage clinically</li><li>• Average lip line: considered to be the most aesthetic</li><li>• Low lip line: the least demanding</li></ul>
Colour and surface texture	Pink and firmly bound down to the necks of the teeth
	The surface texture of the gingival tissues is stippled, with an orange-peel appearance
Interdental papilla	Firm and knife-edged
	Occupies the interdental space made by a contact point and the interdental embrasure
Contour	Symmetrical
	Follows the contour of the upper lip
	The gingival height should match on the central incisors and canines
	The gingival height on the lateral incisor should be slightly more incisal (about 1.5 mm) than on the central incisors
	The peak of gingival margin convexity should be positioned distal to the long axis of the tooth on the labial surface of the maxillary anterior teeth

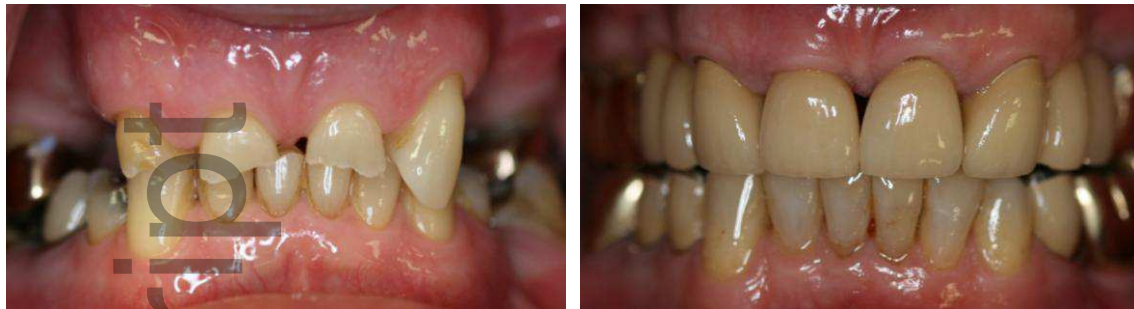# Author Manuscript

**Table 2.** Description of materials used in fixed prosthodontics

Material		Applications					Advantages	Disadvantages
		Anterior veneers	Anterior crowns	Posterior crowns	Anterior FDPs	Posterior FDPs		
Glass ceramic	Fledspathic glass	Yes	Yes	Yes	No	No	Highly aesthetic	Should be adhesively cemented
							Can be stained and glazed	Cementation is technique sensitive
							Etchable	Weakest ceramic
							Conservative	
	Leucite reinforced	Yes	Yes	Yes	No	No	Highly aesthetic	Should be adhesively cemented
							Can be stained and glazed	Cementation is technique sensitive
							Etchable	Weaker than lithium disilicate
							Conservative	
	Lithium disilicate	Yes	Yes	Yes	No	No	Highly aesthetic	Should be adhesively cemented
							Can be stained and glazed	Cementation is technique sensitive
							Etchable	
							Conservative	
High strength ceramic	Aluminium oxide	No	Yes	Yes	Yes	No	White coloured	Adhesive cementation is difficult
							Aesthetic when veneered	Less aesthetic than glass ceramics
							Can be conventionally cemented	More invasive than glass ceramics
	Zirconium dioxide	No	Yes	Yes	Yes	Yes	White coloured	Adhesive cementation is difficult
							Aesthetic when veneered	Less aesthetic than glass ceramics
							Can be conventionally cemented	More invasive than glass ceramics
Metal-ceramic		No	Yes	Yes	Yes	Yes	Relatively aesthetic	Adhesive cementation is difficult
							Very good track record	Less aesthetic than ceramics
								Invasive
Metal	Noble metal	No	No	Yes	No	Yes	Conservative	Unaesthetic

Base metal	No	No	Yes	No	Yes	Versatile	Adhesive cementation is difficult
						Very good track record	
						Durable in thin sections	
						Conservative	Unaesthetic
						Etchable	Risk of allergic reactions
						Can be conventionally or adhesively cemented	Less accurate than noble metal
						Durable in thin sections	

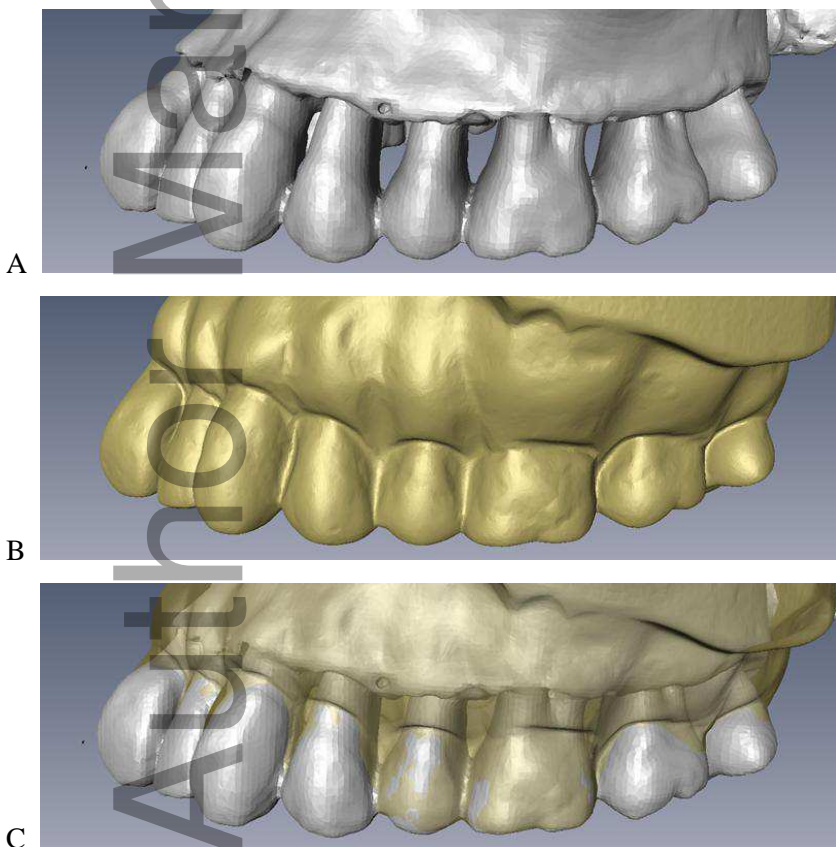
## List of Figures



A

B

**Fig. 1. Clinical images of crown lengthening surgery that facilitated the prosthodontic treatment of a worn dentition. The surgery was completed before the prosthodontic treatment. (A) Worn anterior dentition. (B) Completed treatment.**



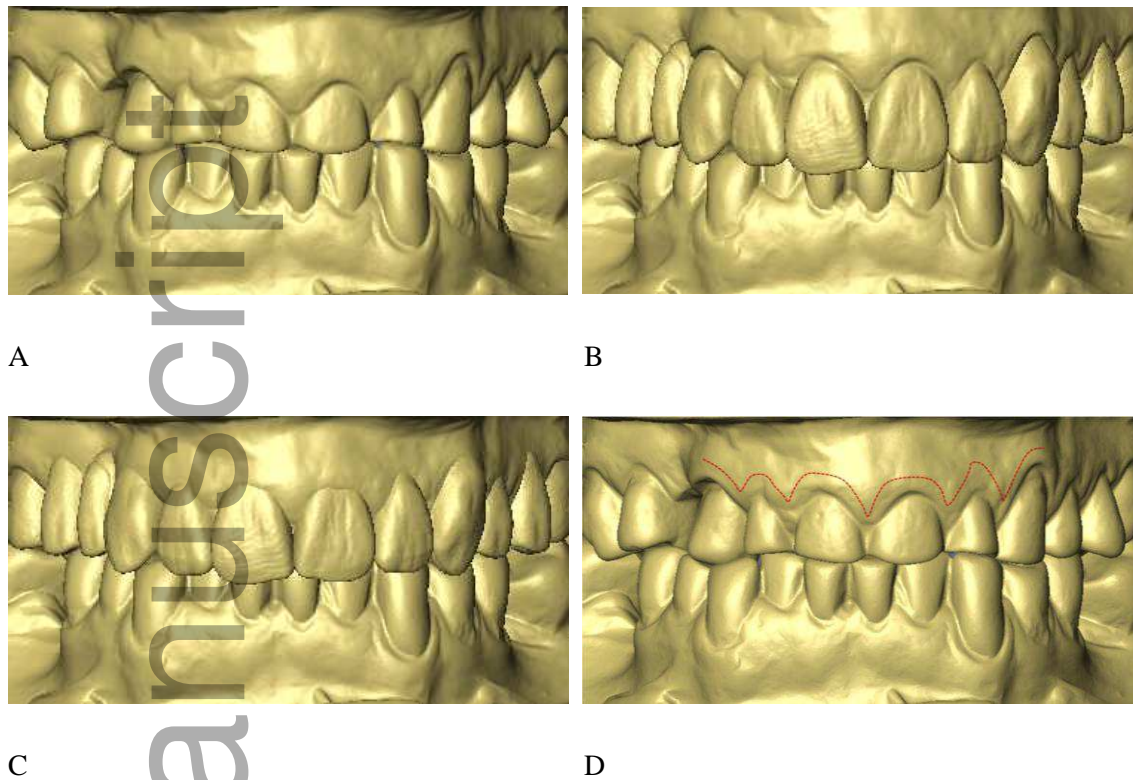
A

B

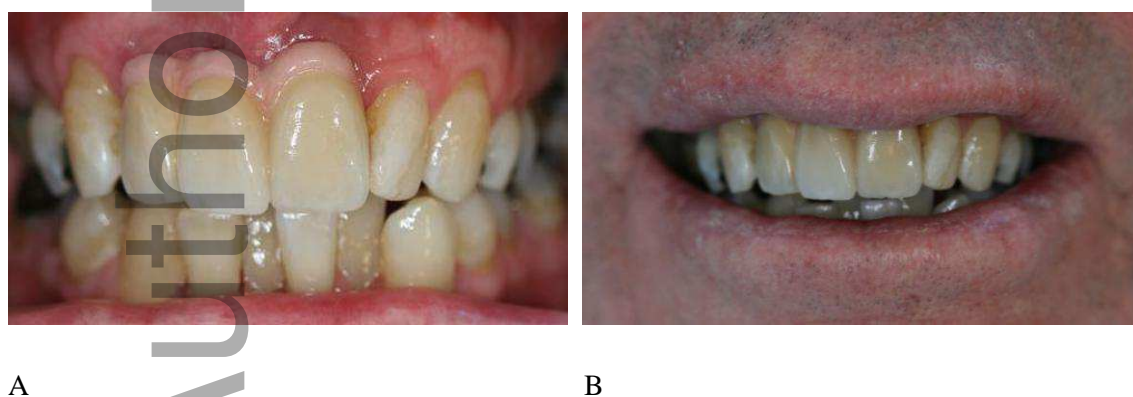
C

**Fig. 2. Example of digital bone sounding where the relationship between bone level and soft tissue contour can be clearly visualized. (A) Reconstructed 3D maxilla from multi-slice CT**

scanning. (B) 3D virtual maxillary arch model generated by surfacing scanning. (C) Superimposition of the virtual 3D models clearly outlines the soft tissue volume.



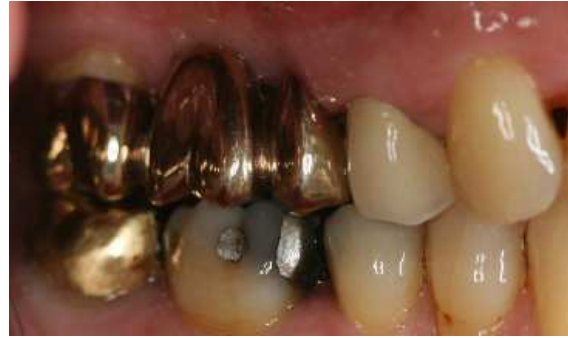**Fig. 3.** A hypothetical example of the management of generalized tooth wear (A). (B) The first treatment was completed by increasing the vertical dimension of occlusion, while the second treatment (C) involved planning for crown lengthening surgery. The last image (D) indicates the amount of the gingival tissues that will be removed at crown lengthening surgery.



**Fig. 4.** Clinical example of gingival coloured ceramic application. (A) Although the colour discrepancy between the gingival margin and the gingival coloured ceramic is very clear, for this patient, the average smile line (B) masked this discrepancy. The interdental papillae were predictably restored.

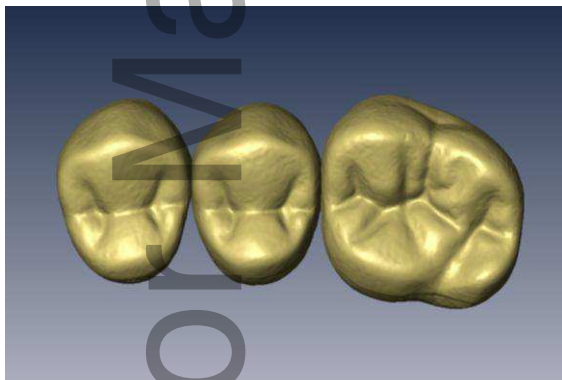


A

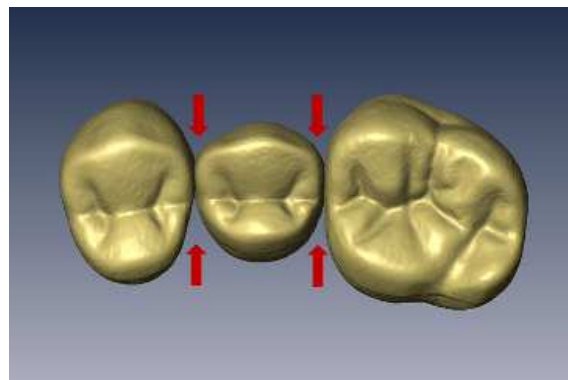


B

**Fig. 5. Clinical presentation of modified ridge lap pontics to replace a missing second premolar and first molar (A). (B) The embrasures were well cleared to facilitate patient home care.**



A



B

**Fig. 6. The impact of altering the buccolingual pontic dimensions. (A) Ideal pontic dimensions should follow the contour of the adjacent teeth. In addition to the aesthetic appearance, this facilitates deflection of food from the proximal aspect. (B) A narrow abutment will contribute food impaction at the proximal aspect and reduce the self-cleansing abilities.**

# Interdisciplinary interface between fixed prosthodontics and periodontics

## List of tables

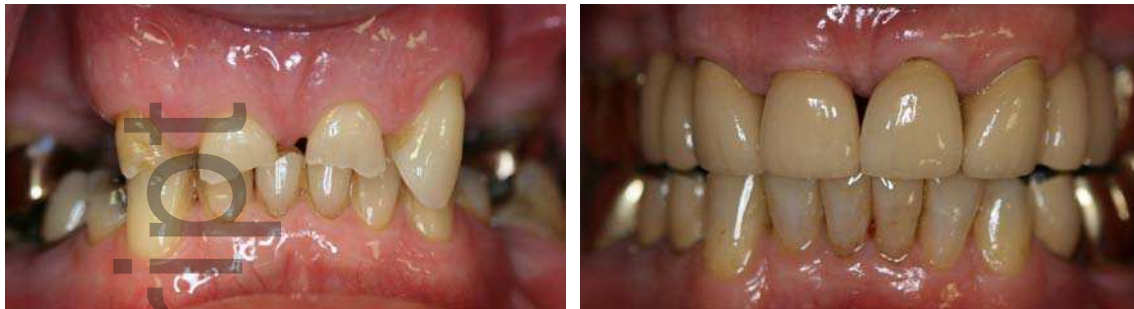**Table 1.** Gingival morphological variables

<b>Variable</b>	<b>Description and ideal criteria</b>
Attached gingiva	Continuous and at least 2 mm even width (72)
Gingival display	Varies between individuals Dependent on the lip line during function: <ul style="list-style-type: none"> <li>• High lip line: most challenging to manage clinically</li> <li>• Average lip line: considered to be the most aesthetic</li> <li>• Low lip line: the least demanding</li> </ul>
Colour and surface texture	Pink and firmly bound down to the necks of the teeth The surface texture of the gingival tissues is stippled, with an orange-peel appearance
Interdental papilla	Firm and knife-edged Occupies the interdental space made by a contact point and the interdental embrasure
Contour	Symmetrical Follows the contour of the upper lip The gingival height should match on the central incisors and canines The gingival height on the lateral incisor should be slightly more incisal (about 1.5 mm) than on the central incisors The peak of gingival margin convexity should be positioned distal to the long axis of the tooth on the labial surface of the maxillary anterior teeth

**Table 2.** Description of materials used in fixed prosthodontics

Material		Applications					Advantages	Disadvantages	
		Anterior veneers	Anterior crowns	Posterior crowns	Anterior FDPs	Posterior FDPs			
Glass ceramic	Feldspathic glass	Yes	Yes	Yes	No	No	Highly aesthetic	Should be adhesively cemented	
							Can be stained and glazed	Cementation is technique sensitive	
							Etchable	Weakest ceramic	
							Conservative		
	Leucite reinforced	Yes	Yes	Yes	No	No	Highly aesthetic	Should be adhesively cemented	
							Can be stained and glazed	Cementation is technique sensitive	
							Etchable	Weaker than lithium disilicate	
							Conservative		
	Lithium disilicate	Yes	Yes	Yes	No	No	Highly aesthetic	Should be adhesively cemented	
							Can be stained and glazed	Cementation is technique sensitive	
							Etchable		
							Conservative		
High strength ceramic	Aluminium oxide	No	Yes	Yes	Yes	No	White coloured	Adhesive cementation is difficult	
							Aesthetic when veneered	Less aesthetic than glass ceramics	
							Can be conventionally cemented	More invasive than glass ceramics	
	Zirconium dioxide	No	Yes	Yes	Yes	Yes	White coloured	Adhesive cementation is difficult	
							Aesthetic when veneered	Less aesthetic than glass ceramics	
							Can be conventionally cemented	More invasive than glass ceramics	
	Metal-ceramic		No	Yes	Yes	Yes	Yes	Relatively aesthetic	Adhesive cementation is difficult
								Very good track record	Less aesthetic than ceramics
									Invasive
	Metal	Noble metal	No	No	Yes	No	Yes	Conservative	Unaesthetic
Versatile								Adhesive cementation is difficult	
Very good track record									
Durable in thin sections									
Base metal		No	No	Yes	No	Yes	Conservative	Unaesthetic	
							Etchable	Risk of allergic reactions	
							Can be conventionally or adhesively cemented	Less accurate than noble metal	
							Durable in thin sections		

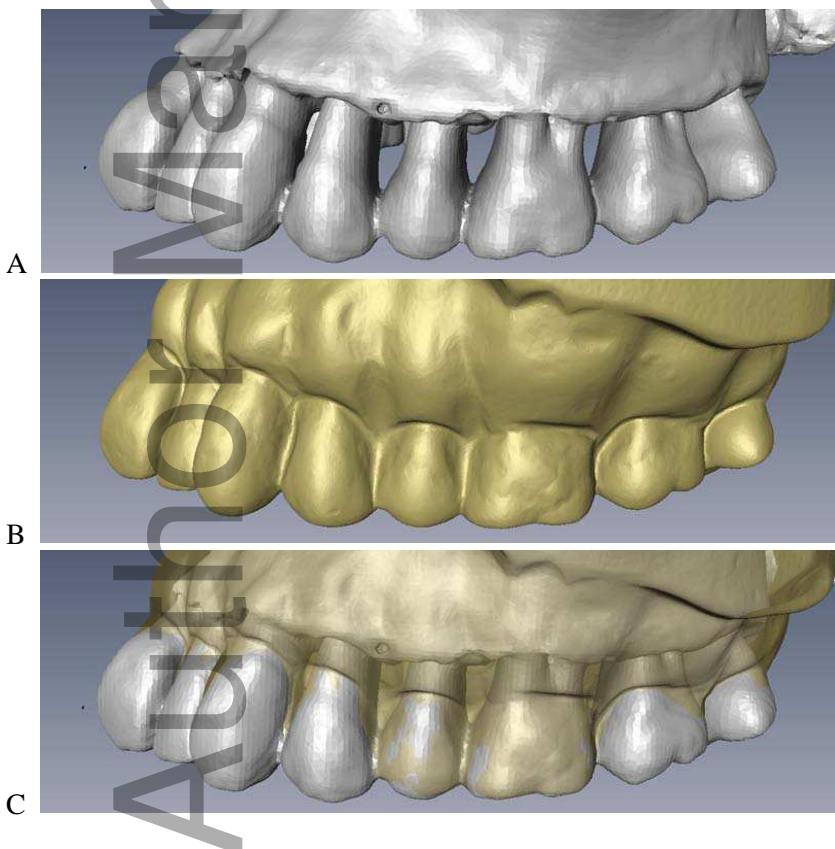
## List of Figures



A

B

**Fig. 1. Clinical images of crown lengthening surgery that facilitated the prosthodontic treatment of a worn dentition. The surgery was completed before the prosthodontic treatment. (A) Worn anterior dentition. (B) Completed treatment.**

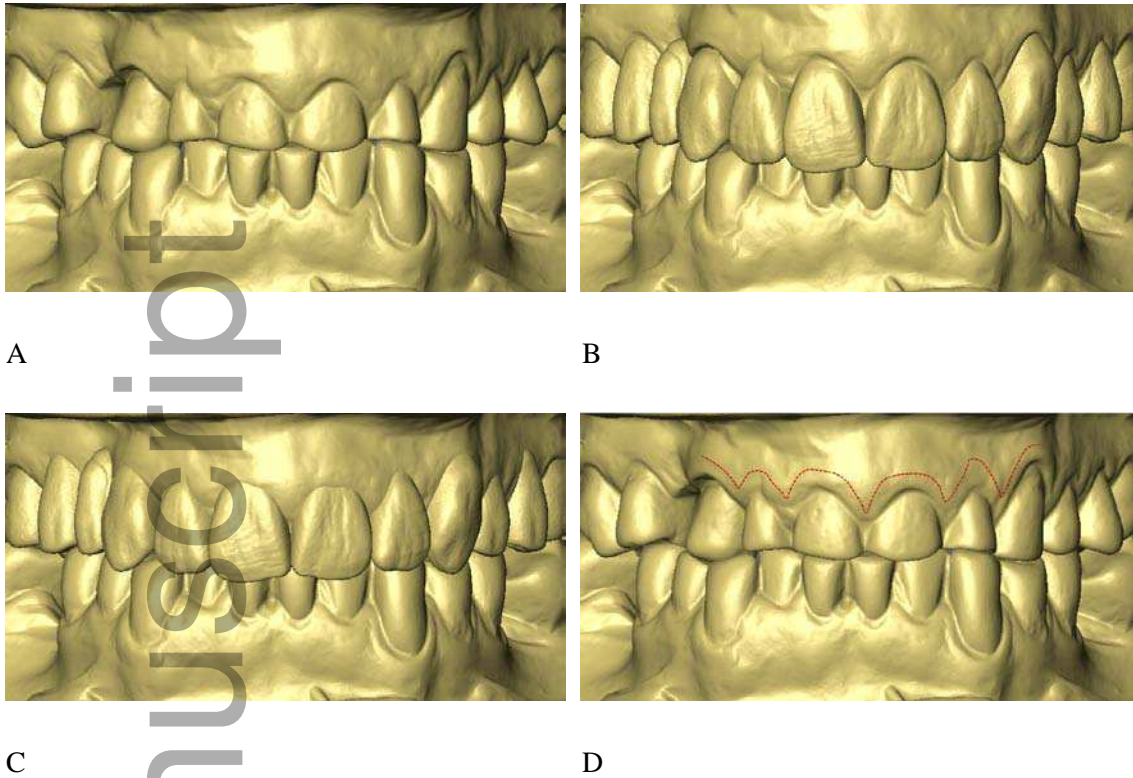


A

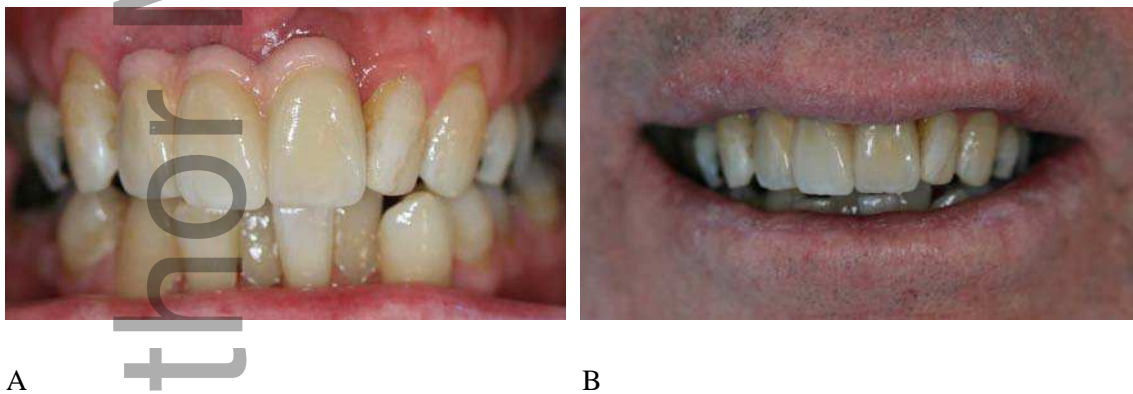
B

C

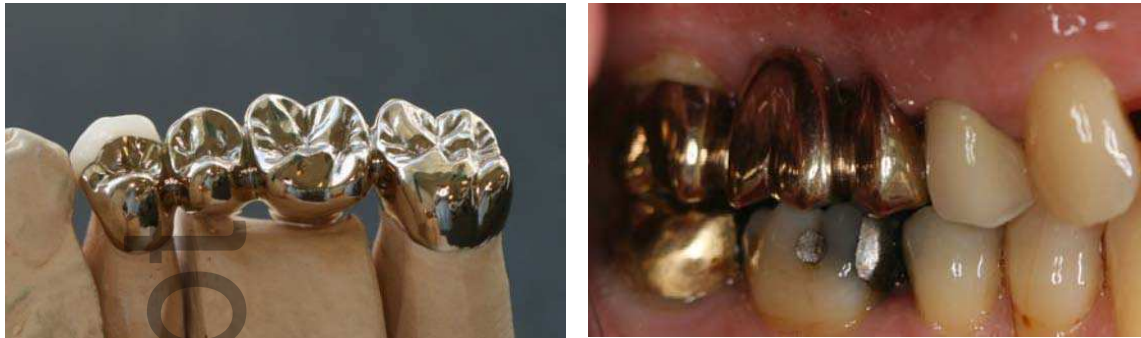**Fig. 2. Example of digital bone sounding where the relationship between bone level and soft tissue contour can be clearly visualized. (A) Reconstructed 3D maxilla from multi-slice CT scanning. (B) 3D virtual maxillary arch model generated by surfacing scanning. (C) Superimposition of the virtual 3D models clearly outlines the soft tissue volume.**



**Fig. 3.** A hypothetical example of the management of generalized tooth wear (A). (B) The first treatment was completed by increasing the vertical dimension of occlusion, while the second treatment (C) involved planning for crown lengthening surgery. The last image (D) indicates the amount of the gingival tissues that will be removed at crown lengthening surgery.



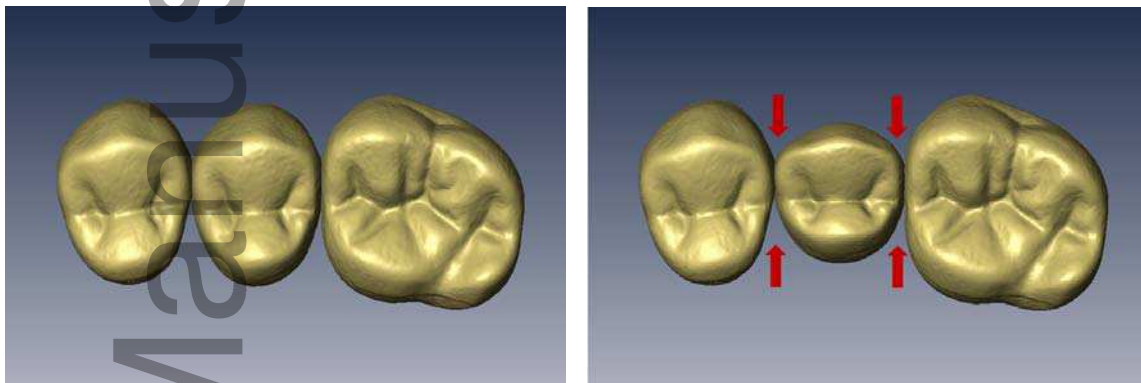
**Fig. 4.** Clinical example of gingival coloured ceramic application. (A) Although the colour discrepancy between the gingival margin and the gingival coloured ceramic is very clear, for this patient, the average smile line (B) masked this discrepancy. The interdental papillae were predictably restored.



A

B

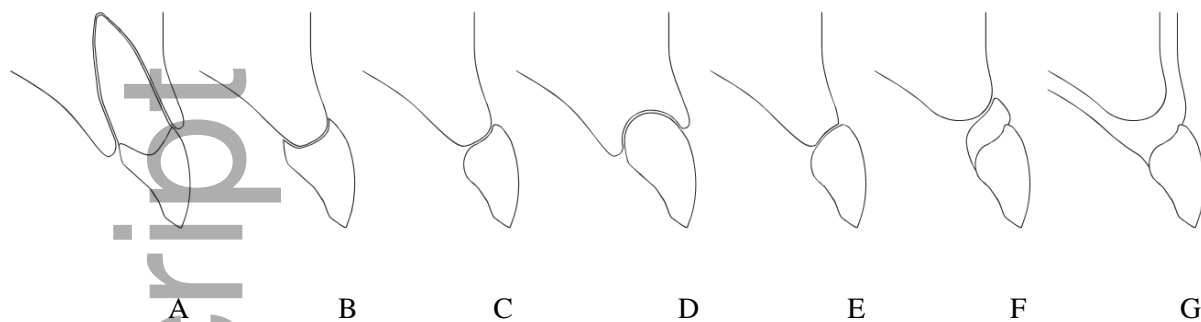
**Fig. 5. Clinical presentation of modified ridge lap pontics to replace a missing second premolar and first molar (A). (B) The embrasures were well cleared to facilitate patient home care.**



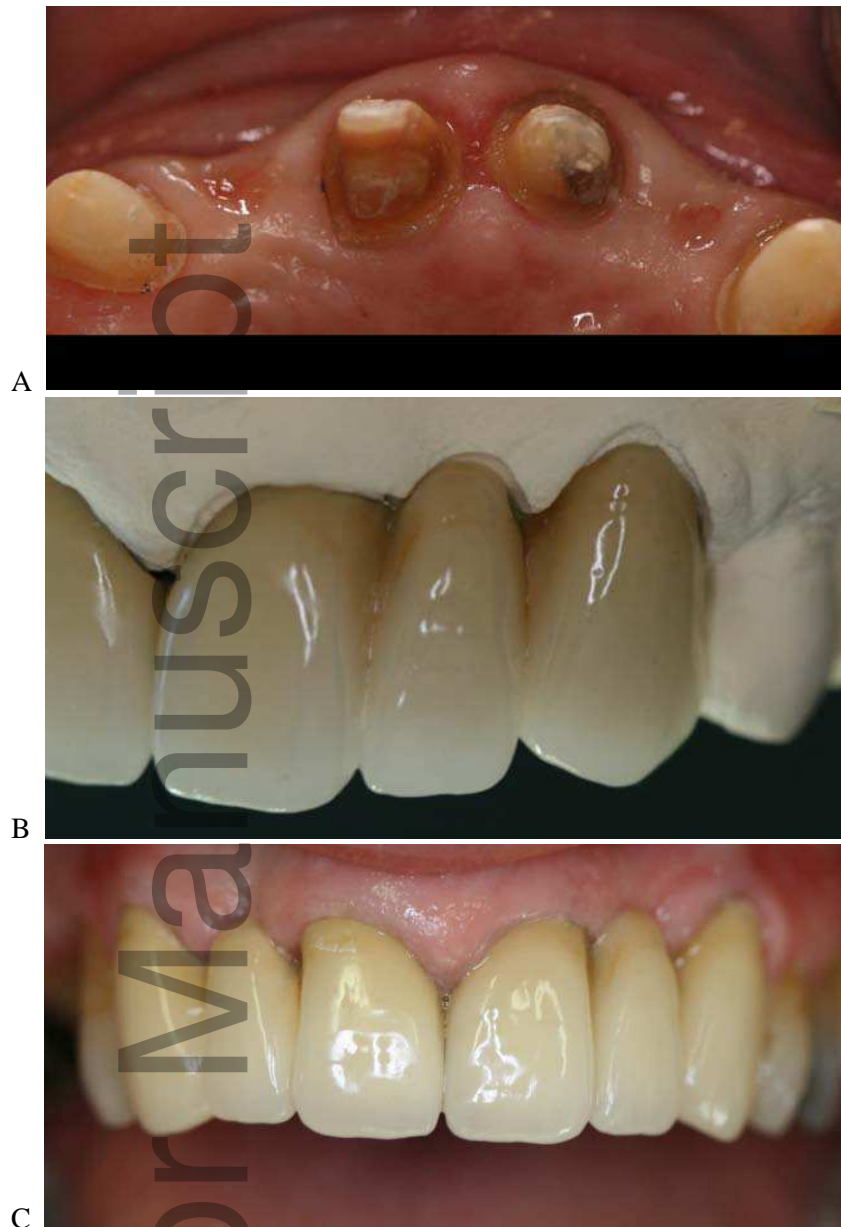
A

B

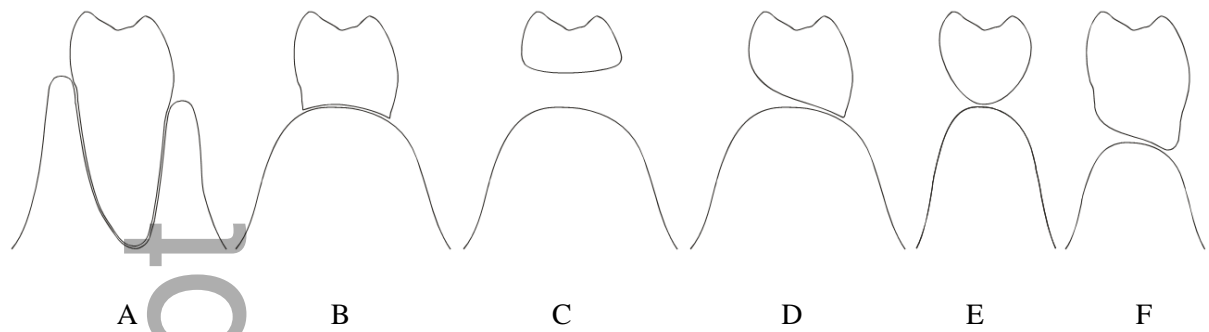
**Fig. 6. The impact of altering the buccolingual pontic dimensions. (A) Ideal pontic dimensions should follow the contour of the adjacent teeth. In addition to the aesthetic appearance, this facilitates deflection of food from the proximal aspect. (B) A narrow abutment will contribute food impaction at the proximal aspect and reduce the self-cleansing abilities.**



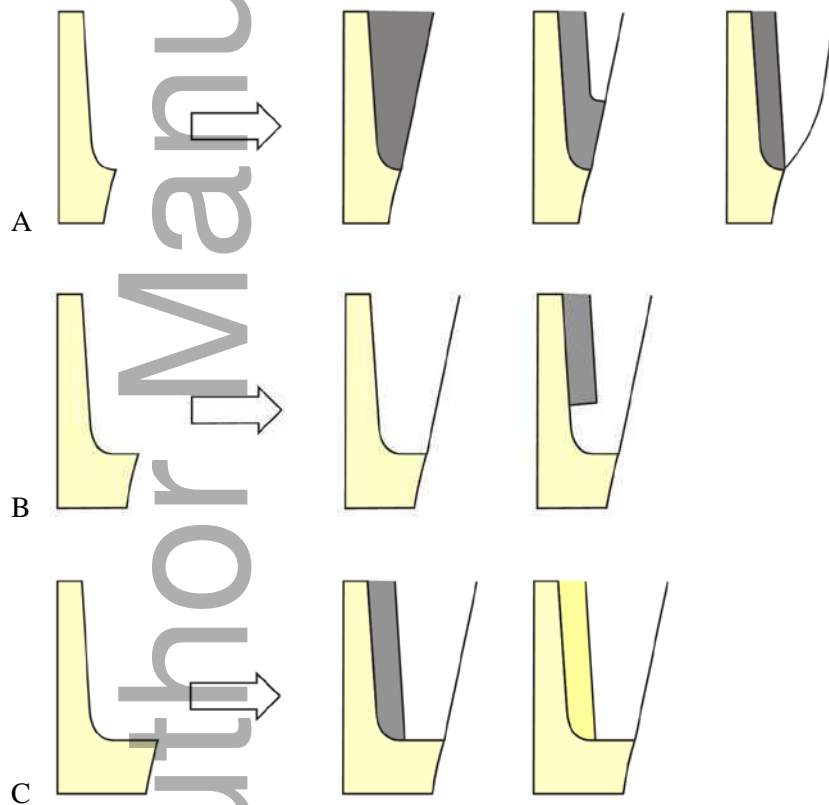
**Fig. 7. Pontic designs for replacement of an anterior tooth. (A) Natural tooth. (B) Ridge lap pontic will produce a surface that cannot be cleaned by the patient. (C) Modified ridge lap pontic can be an aesthetic and cleansable option. (D) Ovate pontic has the advantage of mimicking natural tooth emergence. (E) Modified ovate pontic for narrow ridge. (F) Pontic with gingival coloured ceramic can be considered in situations where the ridge deficiencies are prominent. (G) Removable partial denture provides reliable management of severely compromised ridge.**



**Fig. 8. Clinical example of an ovate pontic to replace missing lateral incisors. (A) Soft tissue depressions were established using provisional prostheses. (B) The pontic aesthetics were enhanced by staining the embrasure areas. (C) Final outcome.**

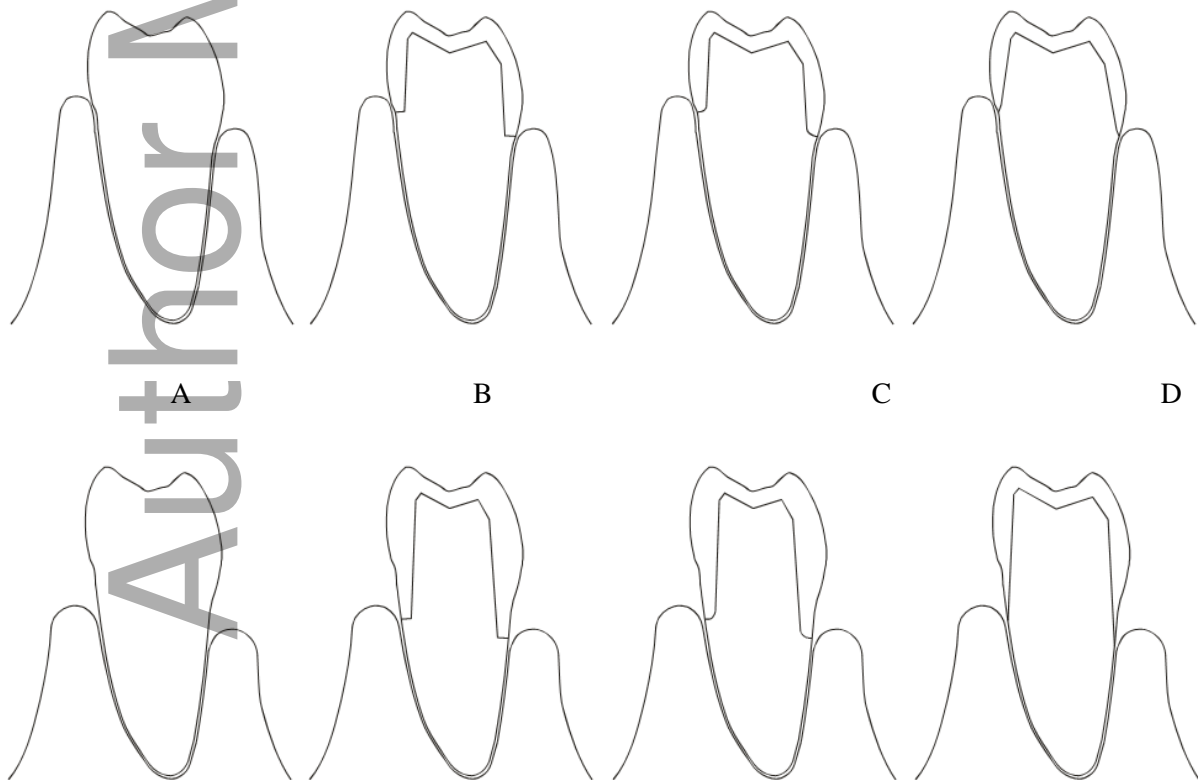
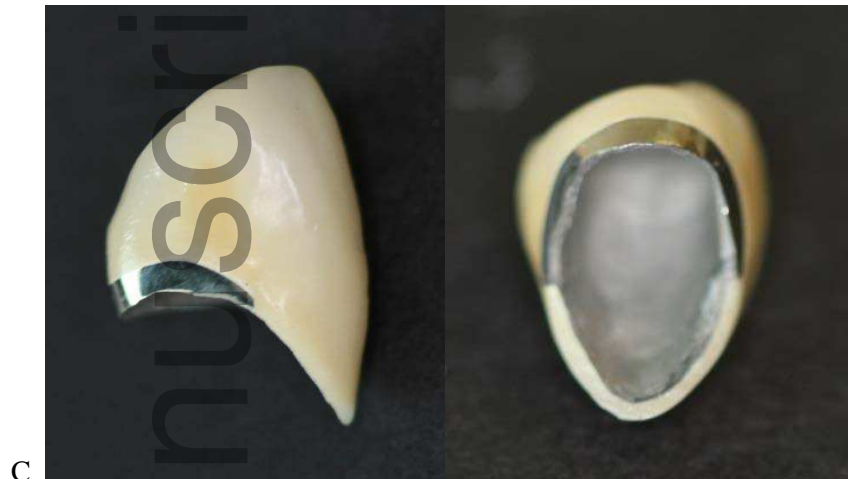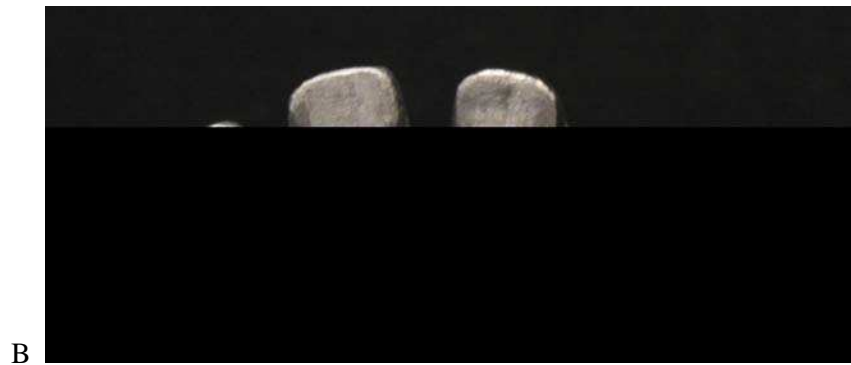


**Fig. 9. Pontic designs for posterior tooth replacement. (A) Natural tooth. (B) Ridge lap pontic can restore the natural tooth contour but cannot be reliably cleaned. (C) Sanitary pontic. (D) Modified ridge lap pontic is a suitable option for the wide ridge. (E) Conical pontic is more suitable for the narrow ridge. (F) Ridge lap pontic with root form.**



**Fig. 10. Effect of altering margin width on material selection. (A) Conservative margin (0.5 mm) mandates the use of metal margin. Masking all the metal with ceramic might cause overcontouring of the prosthesis. (B) 1 mm wide margin is ideal for all ceramic margins. This is applicable for all ceramic crowns or collarless metal-ceramic crowns. (C) Wide margin (1.2-1.5 mm) can be used for metal ceramic margin or for high strength ceramic copings.**

A



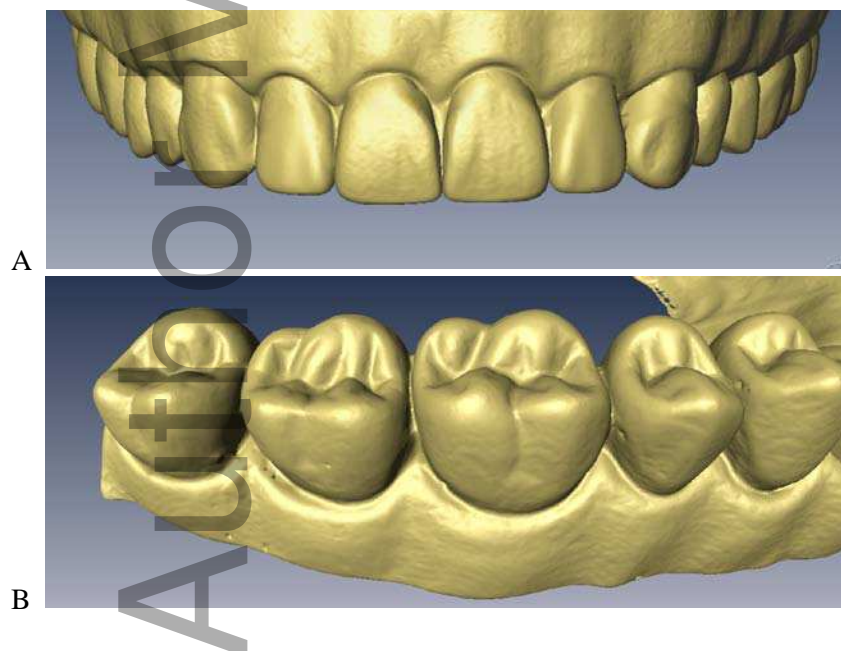
E

F

G

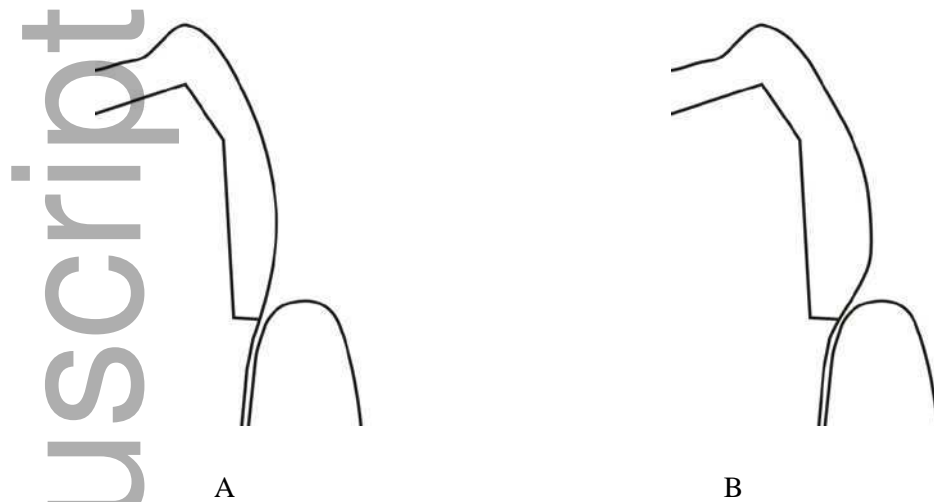H

**Fig. 12. (A-H) Margin designs for teeth with a normal gingiva level and teeth with gingival recession. Shoulder margin (B) and chamfer margin preparations (C) are generally suitable options for teeth without gingival recession. (D) Feather-edge margin for teeth without gingival recession can however over taper the preparation. (E) Teeth with recession require special consideration. Shoulder margin and chamfer margin preparations will be very invasive for the elongated teeth. (H) Feather-edge margin will be a conservative option for such teeth by preventing significant axial reduction.**

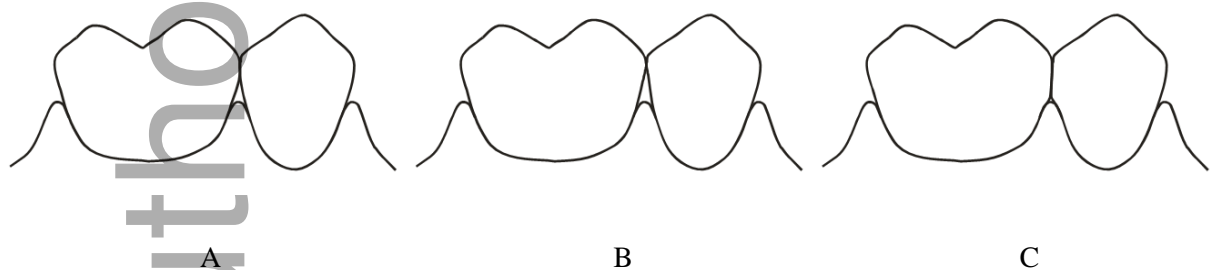


**Fig. 13. Each tooth should fit in harmony with the adjacent teeth. (A) The labial surfaces of all the teeth exhibit a parallel orientation. The long axis of the incisors ideally should be angled**

mesially. (B) The occlusal surfaces and cuspal inclination of posterior teeth have similar parallelism.



**Fig. 14. (A) A straight profile in the gingival third facilitates establishing a properly contoured prosthesis. (B) Widening the profile gingivally is associated with overcontoured prostheses.**



**Fig. 15. (A) Properly contoured interproximal contact in the occlusal third. (B) Very high interproximal contact can cause food impaction. (C) Wide and gingivally located interproximal contact will prevent food deflection and contribute to gingival inflammation.**