



Minerva Access is the Institutional Repository of The University of Melbourne

Author/s:

Chen, ST;Darby, I

Title:

The relationship between facial bone wall defects and dimensional alterations of the ridge following flapless tooth extraction in the anterior maxilla

Date:

2017-08-01

Citation:

Chen, S. T. & Darby, I. (2017). The relationship between facial bone wall defects and dimensional alterations of the ridge following flapless tooth extraction in the anterior maxilla. *Clinical Oral Implants Research*, 28 (8), pp.931-937. <https://doi.org/10.1111/clr.12899>.

Persistent Link:

<https://hdl.handle.net/11343/291942>

Received Date : 13-Feb-2016

Revised Date : 08-May-2016

Accepted Date : 12-May-2016

Article type : Original Research

The relationship between facial bone wall defects and dimensional alterations of the ridge following flapless tooth extraction in the anterior maxilla

Stephen T. Chen, BDS, MDS, PhD, FRACDS¹

Ivan Darby, BDS, PhD, FRACDS (Perio)²

¹Clinical Associate Professor, Periodontics, Melbourne Dental School, The University of Melbourne, Parkville, VIC, Australia

²Professor, Periodontics, Melbourne Dental School, The University of Melbourne, Parkville, VIC, Australia

Correspondence to:

Dr Stephen Chen, 223 Whitehorse Road, Balwyn, VIC 3013, Australia.

Email: schen@melbourneperio.com.au

Keywords: Extraction, flapless, wound healing, dehiscence defect, fenestration defect

This is the author manuscript accepted for publication and has undergone full peer review but has not been through the copyediting, typesetting, pagination and proofreading process, which may lead to differences between this version and the [Version of Record](#). Please cite this article as [doi: 10.1111/clar.12899](https://doi.org/10.1111/clar.12899)

This article is protected by copyright. All rights reserved

Abstract

Purpose: To evaluate the relationship between defects of the facial socket wall at extraction and dimensional changes 8 weeks later in maxillary central and lateral incisor sockets.

Materials and Methods: 34 consecutive patients requiring single tooth implants in the anterior maxilla (27 central and 7 lateral incisors) were evaluated. Orofacial soft ridge and bone dimensions, and the location of the socket bone crest were measured at extraction and again 8.5 ± 2.91 weeks later. The status of the facial bone wall was recorded at the same time points.

Results: At extraction, 16/34 sites (47%) had intact facial bone. There were fenestration defects at 9/34 sites (26.5%) and dehiscence defects at 9/34 sites (26.5%). A significant reduction ($p < 0.001$) in the external orofacial ridge dimension occurred (mesial 1.4 ± 1.30 mm or 12.1%, facial 2.5 ± 1.46 mm or 22.2%, distal 1.1 ± 0.83 mm or 10.5%), with greatest change at dehiscence (3.3 ± 1.80 mm or 28.4%) and fenestration sites (2.8 ± 1.40 mm or 24.9%). A significant reduction in orofacial bone dimension occurred (mesial 0.8 ± 0.80 mm or 9.3% $p < 0.001$; facial 1.2 ± 1.03 mm or 18.3% $p < 0.001$; distal 0.4 ± 0.65 mm or 5.5% $p < 0.01$). Vertical resorption of the bone crest was most marked at the midfacial aspect (1.4 ± 1.94 mm, $p < 0.001$). Initial fenestration defect sites demonstrated the greatest vertical dimensional change (2.9 ± 2.67 mm; $p = 0.008$). Of 16 sites with initially intact facial bone, 9 sites (56.3%) developed dehiscences after 8 weeks. 5 (55.6%) of the 9 initial sites with fenestration defects turned into dehiscence defects. All 9 sites with initial dehiscence defects healed with persistence of the dehiscence.

Conclusions: 8 weeks after flapless extraction of maxillary central and lateral incisors, a reduction in the orofacial dimensions of the ridge were observed due to resorption of the facial bone of the socket. Tooth type (maxillary central incisor) and thin tissue phenotype significantly influenced outcomes. The dimensional alterations were most pronounced at sites that initially had fenestration and dehiscence defects of the facial bone.

Introduction

After tooth extraction, the alveolar bone heals by regeneration of bone within the socket and external resorption of the socket bone walls, with the most marked changes affecting the facial wall of the socket (Araujo & Lindhe 2005). This results in a reduction in the vertical height and horizontal width of the alveolar bone (Van der Weijden et al. 2009, Tan et al. 2012). The post-extraction dimensional changes are of particular relevance in the anterior maxilla, where loss of hard and soft tissue volume can adversely affect esthetic outcomes with implant treatment (Saadoun & Landsberg 1997).

It has been reported that most dimensional alteration takes place relatively soon after tooth removal (Farmer & Darby 2014). In a longitudinal study that evaluated sequential study casts of posterior extraction sites, the external buccolingual dimension of the ridge reduced by 50% over a 12 month observation period, with about two-thirds of the total change taking place within the first 3 months (Schropp, et al. 2003). In a recent systematic review of human studies with re-entry, rapid reductions in alveolar bone volume were reported and by 3 months, the horizontal bone dimensions had reduced by 32% (Tan et al. 2012). Thus, the first 3 months after tooth extraction may be a critical time to place implants before resorption of the alveolar bone becomes too advanced.

Several clinical studies have documented the dimensional alterations to the facial bone wall of the socket by direct measurements at the time of extraction and at surgical re-entry. The majority of the studies, however, report on outcomes 6 months or more after tooth extraction (Lekovic et al. 1997, Lekovi, et al. 1998, Camargo et al. 2000, Iasella et al. 2003, Serino et al. 2003, Barone et al. 2008, Pelegrine et al. 2010). Two studies provided re-entry data between 6 weeks and 3 months, both reporting significant dimensional alterations in this relatively short post-extraction healing phase (Farmer & Darby 2014, Aimetti et al. 2009). The data from the aforementioned studies is difficult to interpret, as most report on a combination of anterior and posterior extraction sockets which have different morphological characteristics which may influence resorption. In the anterior maxilla, the majority of teeth present with thin facial bone walls, whereas posterior sites have significantly thicker facial bone (Huynh-Ba et al. 2010, Braut et al. 2011, Zekry et al. 2014). This distinction is relevant, as it has been shown that the thickness of the facial bone at the time of extraction is an important predictor for resorption, with several studies

demonstrating that thin bone resorbs to a greater extent than thick bone (Chen et al. 2007, Ferrus et al. 2010, Chappuis et al. 2013).

Although it is generally observed that the rate and pattern of resorption may be increased if the facial bone wall of the socket is thin, damaged or missing at the time of extraction (Nevins, et al. 2006) there is limited data documenting the relationship between the condition of the facial bone wall and pattern of post-extraction dimensional alterations.

The aim of this study was to evaluate the relationship between defects of the facial bone wall at the time of extraction and the dimensional changes and pattern of bone resorption after 8 weeks in maxillary central and lateral incisor sockets.

Materials and Methods

Inclusion and exclusion criteria

Ethics approval for this study was granted by the University of Melbourne (Ethics ID 1442646) and was performed in accordance with the principles established in the Declaration of Helsinki. All patients provided written consent to participate. The study was designed as a prospective case series study. Consecutive patients requiring extraction of a single maxillary central or lateral incisor teeth in a private practice setting were included in the study, according to the following inclusion criteria:

- Medically healthy or with mild controlled systemic disease, and able to undergo minor oral surgical procedures under local anaesthesia (ASA I and II; American Society of Anesthesiologists, Schaumburg, Illinois, USA)
- Single maxillary central or lateral incisors adjacent to natural teeth.
- Dental implants were planned for replacement of the teeth.
- Sites were included irrespective of the condition of the tooth to be extracted.
- Adjacent natural teeth were periodontally sound with no periodontal attachment loss, and had healthy dental pulps.
- If adjacent teeth were endodontically treated, only teeth with a satisfactory endodontic status were included.

Patients were excluded if they smoked cigarettes.

Surgical procedures

Prior to extraction, customized removable measuring jigs consisting of a stainless steel wire positioned at the incisal edges of adjacent teeth and embedded in acrylic were constructed. Care was taken to ensure that the measuring jigs attached firmly to the adjacent teeth without movement.

A horizontal reference line was established 5 mm from the mid-facial and mid palatal gingival margins of the tooth to be extracted (Fig 1). The distance of this reference line to the measuring jig was recorded. Following administration of local anesthesia (Lignospan, Septodont, USA), the following were recorded:

- The tissue phenotype was classified as thin or thick according to the criteria of Kan et al. (Kan, et al. 2003) by placing a periodontal probe into the midfacial gingival sulcus. If the metal probe could be seen through the mucosa, then the phenotype was classified as thin. If the probe could not be visualized, the phenotype was recorded as thick.
- At the horizontal reference line, the orofacial dimensions of the ridge at the surface of the mucosa at the mesial, midfacial and distal of the tooth to be extracted was recorded to the nearest millimeter with a surgical measuring caliper (Salvin Ridge Mapping Caliper, Salvin, USA).
- At the same 3 positions, the orofacial dimensions of the alveolar bone were measured with the same calipers by penetrating the mucosal surface to bone facially and palatally. These measurements characterized the orofacial bone width at the mesial, midfacial and distal of the extraction sites. Midfacial measurements could not be obtained in the presence of dehiscence defects where bone was missing at the horizontal reference line.

Intrasulcular incisions to bone crest were made circumferentially and the teeth extracted without flap elevation. Delivery of the teeth was assisted by the careful use of periostomes and fine luxators applied only to the palatal aspects of the teeth. Fine tipped forceps were used with rotational movements only, with care taken not to induce any facially directed pressure on the socket wall. Apart from careful

debridement of the sockets to remove obvious soft tissue tags or remnants of granulation tissue, no other treatment of the socket walls was performed.

After extraction of the teeth, the internal aspect of the sockets were examined visually and with a periodontal probe to determine the presence of defects in the facial bone wall. The condition of the facial bone wall was classified as intact or damaged. Sites with damaged facial bone were further classified as having either dehiscence or fenestration defects. Dehiscence defects were characterized by loss of bone at the midfacial crest of the bone. Fenestration defects were characterized by loss of the facial bone in the central or apical region of the socket, with an intact bridge of facial bone at the crest.

The apicocoronal distance between the measuring jig and the bone crest on the mesiofacial, midfacial, distofacial, mesiopalatal, midpalatal and distopalatal of the socket were recorded to the nearest millimeter with a calibrated probe. The position of the midfacial bone crest in dehiscence defects was determined to be at the zenith of the defect.

Patients were then scheduled for implant surgery between 6 to 10 weeks after extraction, depending upon patient preference and availability of treatment times. After administration of local anesthesia, the orofacial dimension of the ridge and the orofacial dimension of the alveolar bone were measured with the surgical caliper at the same locations determined prior to extraction. After reflection of full thickness mucoperiosteal flaps, the apicocoronal distance between the measuring jig and the bone crest at the 6 predetermined positions were recorded.

Data analysis

The sample size was calculated post hoc. 9 patients with fenestration defects were required to provide a study power of 80% with a type I/II error rate of 0.05.

Descriptive methods were used to summarize patient demographics, reasons for tooth extraction, facial bone thickness and facial bone defects. For continuous data, residuals for individual parameters were plotted to confirm normality of the distributions. Differences between pretreatment and re-entry data were analysed with the paired Student's t-test. Differences between groups were evaluated with analysis of variance (ANOVA). Multiple comparison testing using the Tukey's simultaneous test was performed when significant differences between groups were found. For

categorical data, the chi-squared test was used to determine correlations. Logistic regression with backwards elimination was used to examine trends that age, gender, tooth type, defect type at extraction, facial bone thickness and phenotype might have on outcomes. The level of significance was set at 0.05. All analyses were carried out using the statistical package Minitab (Minitab 16, Minitab Inc., Philadelphia, USA).

Results

Patient demographics

A total of 34 consecutive patients who fulfilled the inclusion criteria were included in the study. Patient demographics are presented in table 1. There were 19 female (55.9%) and 15 male (44.1%) patients, with an average age of 44.6 ± 12.74 years (range 20.7 – 68.3 years). Each patient contributed one extraction site, representing 27 (79.4%) maxillary central incisors and 7 (20.6%) maxillary lateral incisors. The reasons for extraction were loss of retention/loss of structural integrity of a previously crowned or restored tooth (32.4%), endodontic failure (17.6%), external root resorption (23.5%) and vertical root fracture (26.5%). The gingival phenotype was thin at 18 sites (52.9%) and thick at 16 sites (47.1%). At the time of extraction, the facial bone wall was recorded as thin (<1 mm thick at the crest) at 29 sites (85.3%) and thick (≥ 1 mm) at 5 sites (14.7%). A strong correlation was found between thin phenotype and thin facial bone (Chi-sq 6.595; $p = 0.010$). There were 16 sites (47%) with intact facial bone walls. A total of 18 sites (53%) had defects on the facial bone; 9 (26.5%) of these were dehiscence defects and 9 (26.5%) were fenestration defects. Teeth that were extracted due to loss of crown retention and/or lack of structural integrity of the remaining tooth had predominantly intact facial bone (10/11 sites) at the time of extraction whereas teeth that were removed because of vertical root fracture had mainly dehiscence defects (5/9 sites) of the facial bone (table 2). Teeth that were extracted because of endodontic failure had predominately fenestration defects of the facial bone (5/6 sites).

Clinical outcomes and residual bone defects

All extraction sites healed uneventfully, and all patients proceeded with the next stage of treatment involving the placement of implants. The mean time between

extraction and surgical re-entry was 8.5 ± 2.91 weeks. All sites demonstrated resorption of the ridge with slight loss of ridge height on the facial side and a reduction in orofacial ridge width. At the center of the ridge crest, the soft tissues showed varying stages of healing ranging from the presence of immature granulation tissue to complete epithelialization. No site demonstrated complete mucosal healing, with invagination of the soft tissues at the center of the ridge crest being the predominant finding.

On reflection of surgical flaps, resorption of the facial bone wall to a varying extent was observed (Fig 1a-d). Some sites (9/34 or 26.4%) had an intact facial bone, but the majority demonstrated a combination of apicocoronal and orofacial resorption of the facial bone. Dehiscence defects of the facial bone were the predominant bone defect observed at re-entry (23/34 or 67.7% of sites), with the pattern being an inverted V or U shape defect. The condition of the facial bone at extraction and the resultant bone defects at re-entry are tabulated in table 3. All 9 sites with dehiscence defects at the time of extraction presented with dehiscence defects at re-entry. Of the 9 sites with fenestration defects at the time of extraction, 55.6% (5/9 sites) had developed dehiscence defects due to resorption of the facial bone. In 4 sites with initial fenestration defects, 2 sites (22.2%) had persistent fenestration defects and 2 sites had healed with closure of the fenestration defects. Of the 16 sites which initially had intact facial bone walls, 56.3% (9/16 sites) were found to have dehiscence defects at the time of re-entry. 43.7% (7/16) of the initially intact sites had intact facial bone at the time of re-entry.

Partial bone regeneration within the extraction sockets was noted, with no sites demonstrating complete bone fill. Sufficient bone volume was present to allow implants to be placed in every case. All sites required bone grafts to repair residual peri-implant defects and for augmentation of the contour of the ridge.

Intra-operative measurements

Alterations in the external dimensions of the ridge and dimensions of the bone are presented in table 4.

A significant reduction in the orofacial dimension of the ridge was found at all 3 measurement points on the mesial (1.4 ± 1.30 ; range 0 - 5.0 mm), facial (2.5 ± 1.46 ; range 0 - 7.0 mm) and distal (1.1 ± 0.83 range; 0 - 3.0 mm) aspects of the extraction

sites representing a reduction of 12.1%, 22.2% and 10.5% of the original ridge width respectively ($p < 0.001$). When considering the condition of the facial bone wall at the time of extraction, the differences between defect types mesially and distally were not statistically significant. **At the midfacial position, however, there was a significant difference between the defect types with dehiscence defect sites undergoing more orofacial reduction than intact sites (3.3 ± 1.80 mm vs. 1.9 ± 1.03 mm; $p = 0.038$).** The orofacial ridge width diminished by 17.1% at sites with intact facial bone walls, compared to a reduction of 28.4% and 24.9% at sites with dehiscence and fenestration defects respectively. Regression analysis revealed a statistically significant influence of dehiscence defect and tooth site (central incisor) on change of the orofacial ridge width ($p = 0.010$; R-Sq = 31.28%).

Between extraction and surgical re-entry, there was significant apicocoronal reduction in height of bone at the facial (1.4 ± 1.94 mm; $p < 0.001$), mesiopalatal (0.6 ± 1.10 mm; $p < 0.01$), palatal (0.6 ± 1.13 mm; $p < 0.01$) and distopalatal (0.4 ± 1.02 mm; $p < 0.05$) aspects of the socket. Vertical resorption of 0.3 ± 0.86 mm and 0.1 ± 1.08 mm was recorded at the mesiofacial and distofacial aspects of the socket, however the change from baseline was not statistically significant. On the facial aspect, sites with intact bone, dehiscence defects and fenestration defects recorded apicocoronal resorption of 0.5 ± 0.34 mm, 1.4 ± 0.88 and 2.9 ± 2.67 mm respectively ($p = 0.008$). The difference between sites with intact bone and fenestration defects was significant ($p = 0.006$).

A significant reduction in the orofacial width of bone on the mesial (0.8 ± 0.8 mm; $p < 0.001$) and distal (0.4 ± 0.65 mm; $p < 0.01$) aspects of the socket was observed. However, these changes were clinically small, amounting to 9.3% and 5.5% reduction in the original bone width respectively. On the facial aspect (excluding sites that initially had dehiscence defects), a significant reduction in the orofacial dimension was also recorded (1.2 ± 1.03 mm; $p < 0.001$) representing a change of 15.3%. The differences between defect types was not statistically significant at all 3 reference points. Thin phenotype sites had significantly greater reduction in internal ridge width on the mesial (0.9 ± 0.73 mm vs 0.4 ± 0.81 mm; $p = 0.038$) and facial (1.8 ± 1.52 mm vs 0.9 ± 0.89 mm; $p = 0.045$) compared to thick phenotype (table 5). These results should be interpreted with caution due to the relatively large p-values and the number of statistical tests performed. Regression analysis indicated that tooth site (central incisor) and phenotype (thick) had a statistically significant

influence on change in internal ridge width on the facial aspect ($p = 0.008$, $R\text{-Sq} = 26.65\%$).

Discussion

In this study, defects of the facial bone wall were a common occurrence at extracted maxillary central and lateral incisor sites, with 53% of sites presenting as either fenestration or dehiscence defects. This study confirmed the clinical observation that the type of bone defect is related to the reason the tooth is extracted. Teeth with failed endodontic therapy tended to present with fenestration defects whereas teeth with vertical root fractures usually presented with dehiscence defects of the facial socket wall. A high proportion of teeth that were extracted due to loss of crown retention and/or structural integrity of the remaining tooth, as well as teeth with external root resorption had mainly intact socket walls. The orofacial dimension of the ridge reduced by 22.2% at the midfacial region of the healing socket 8 weeks after tooth extraction. This is consistent with a previous clinical report that reported on a reduction of 15% in the orofacial ridge with of 12 patients 6 to 8 weeks after extraction (Farmer & Darby 2014). The extent of the orofacial ridge reduction was dependent on the condition of the underlying facial bone of the socket at the time of extraction. Sites with dehiscence and fenestration defects had a greater orofacial reduction in ridge width in the midfacial region of the extraction site compared to sites with intact facial bone, thus confirming the clinical observation that defects in the facial bone are a risk factor for orofacial ridge resorption. The regression analysis showed a trend for central incisor sites and dehiscence defects at the time of extraction to influence the reduction in orofacial ridge width. Due to the small sample size, these results should be interpreted cautiously, but are consistent with clinical observations of the dimensional changes observed following tooth extraction in the presence of these 2 factors. Compared to maxillary lateral incisors, central incisor sockets are dimensionally larger and exhibit greater dimensional change particularly when the facial bone is missing. The reduction in orofacial ridge dimension on the mesial and distal aspects of the extraction socket was independent of the condition of the mid facial bone. It may be speculated that the presence of natural teeth adjacent to a single tooth extraction site limits the magnitude of resorption in the proximal regions. These findings are consistent with a previous study that demonstrated that minimal resorption of the proximal bone occurred at the natural teeth next to an

extraction socket, whereas the bone on the mesial and distal sides of the extraction socket reduced significantly in height (Schropp et al. 2003).

In the present study, it was noted that the predominant defect (67.7%) encountered at surgical re-entry was a dehiscence defect of the facial bone. More than half of the extraction sites with intact facial bone or fenestration defects were found to have dehiscence defects at re-entry. This finding supports the bundle bone concept of Araujo & Lindhe which theorizes that bundle bone, being a tooth dependent tissue, is rapidly resorbed after tooth extraction (Araujo & Lindhe 2005). The facial bone wall, which is almost entirely composed of bundle bone in the coronal region, is rapidly resorbed thereby leading to a reduction in height of the facial bone.

The predominant tissue phenotype of the patients in this study was thin, and a strong correlation between thin phenotype and thin facial bone was noted. This corroborates the findings of a previous study that compared tissue phenotype to CBCT evaluation of facial bone thickness (Cook, et al. 2011).

Healing of the socket 8 weeks after extraction was characterized by a marked reduction in height of the facial bone compared to the palatal and proximal bone. Over an 8 week period the facial bone reduced in height by an average of 1.4 mm, which is similar to previous reports with observation periods of 6 months or more (Lekovic et al. 1997, Lekovic et al. 1998, Camargo et al. 2000, Iasella et al. 2003, Pelegrine et al. 2010). Thus it seems that the apicocoronal resorption of the facial bone occurs rapidly after tooth extraction, confirming the findings of Aimetti et al. who reported 1.2 mm of height reduction 3 months after extraction in non-grafted sockets (Aimetti et al. 2009). A recent CBCT study that compared dimensional alterations of sockets at extraction and 8 weeks later suggested that more than 50% of the change took place within the first 2 weeks (Chappuis, et al. 2015). The type of facial bone defect at the time of extraction had a significant effect on the reduction in height of the facial bone. Sites with dehiscence defects, in which the crestal bone was already diminished in height, demonstrated additional vertical resorption 3 times that of sites with initially intact facial bone. Sites with fenestration defects at the time of extraction exhibited the greatest amount of height reduction, of a magnitude almost 6 times that of sites with intact facial bone. The risk of significant reduction in the height of bone in the presence of fenestration defects has not been reported previously. At the majority of fenestration sites, the intact bridge of bone near the crest resorbed rapidly despite flapless extraction of the teeth. This has implications for the placement of implants

into fresh extraction sockets in the presence of fenestration defects. The rapid resorption of the facial bone may complicate healing by allowing dispersion of particulate bone grafts, loss of facial bone dimension and incomplete bone regeneration in the coronal portion of the socket. Previous studies of immediate implants placed with grafting of the peri-implant defect followed by surgical re-entry have shown that residual peri-implant bone defects are commonly observed at surgical re-entry (Chen et al. 2007, Juodzbalys & Wang 2007). The majority of extraction sites in the present study had thin facial bone, an observation reported by others in relation to teeth in the anterior maxilla at which thin facial bone predominates. (Huynh-Ba et al. 2010, Braut et al. 2011). Thin facial bone has been shown to be a risk factor for vertical resorption with thin bone resorbing about three times more than thick bone (Chen et al. 2007, Tomasi et al. 2010).

Although the bone on the mesial, distal and palatal aspects of the sockets demonstrated significant vertical reduction when compared to baseline, the extent of the reduction was clinically small, ranging from 0.1 to 0.7 mm. This change was similar to the proximal bone height reduction reported in a recent systematic review in which the weighted mean vertical reduction of the proximal bone (based on 6 studies) was 0.64 mm (Van der Weijden et al. 2009). The same systematic review, however, reported a much greater reduction in the palatal bone height of 2.03 mm compared to the findings of the present study. The difference could be due to the shorter observation period (8 weeks) in the present study compared to the longer observation periods studies included in the systematic review (6 months and greater) or to differences in extraction techniques employed and the degree of trauma that results from application of elevators and luxators to the palatal side of the tooth to be extracted.

The change in orofacial bone width was greatest on the midfacial aspect and was significantly influenced by phenotype. Thin phenotype was associated with twice the amount of orofacial bone width change compared to thick phenotypes and therefore represents a risk for increased ridge resorption as previously reported by others (Chappuis et al. 2015). The change of 1.2 mm (or 15.3% of the original ridge width) reported in the present study was less than that reported in a systematic review in which a weighted mean reduction of 3.87 mm was calculated from 6 studies with longer observation periods compared to the present study (Van der Weijden et al. 2009). This suggests that the resorptive processes leading to horizontal reduction in bone width have only just commenced within the first 8 weeks, and may be

anticipated to continue over a further period of time. Schropp and co-workers reported that although the majority of the post-extraction reduction in horizontal ridge dimension occurred in the first 3 months, an additional 30% loss took place over the following 9 months.(Schropp et al. 2003) In the present study, minimal dimensional change was observed in the orofacial bone width mesially and distally confirming the observation that at 8 weeks following tooth extraction, the proximal bone width has not undergone significant dimensional alteration (Buser et al. 2008)

Conclusions

In this study, dimensional alterations to the alveolar bone 8 weeks following flapless extraction of maxillary central and lateral incisors were investigated.

A significant reduction in the orofacial dimension of the ridge and underlying bone was observed at the midfacial aspect of the ridge. At the mesial and distal aspects of the extraction sites, however, statistically significant but clinically minimal orofacial dimensional change occurred. Similarly, statistically significant but clinically minimal apicocoronal reduction of the height of bone was recorded at the mesiofacial, distofacial, mesio palatal, palatal and distopalatal locations at the periphery of the extraction socket. In contrast, the reduction in mid-facial height of the facial socket wall was statistically significant and clinically relevant. The tooth type (maxillary central incisor), thin tissue phenotype and condition of the facial bone wall at the time of extraction influenced the magnitude of the vertical resorption. Sites with initially intact facial bone demonstrated an average vertical height reduction of 0.5 mm, with approximately half of the sites healing with the formation of dehiscence defects of the facial bone. Sites with dehiscence defects at the time of extraction experienced additional vertical height reduction 3 times that of intact sites. The majority of sites with fenestration defects at the time of extraction lost the crestal bridge of bone during healing, resulting in a reduction in vertical bone height 6 times that of sites with initially intact bone facial bone walls.

It may be concluded that dimensional alterations to the facial bone wall takes place soon after tooth extraction. These changes have clinical relevance and have implications for implants placed into fresh extraction sockets or soon after extraction. Defects in the facial bone at the time of extraction influences dimensional changes. Steps need to be taken to compensate for resorption of the facial bone wall in order to provide functionally and esthetically stable implant reconstructions in the anterior maxilla.

The authors report no conflict of interest.

Author Manuscript

References

- Araujo, M.G. & Lindhe, J., (2005) Dimensional ridge alterations following tooth extraction. An experimental study in the dog. *J Clin Periodontol* **32**: 212-218.
- Van der Weijden, F., Dell'Acqua, F. & Slot, D.E., (2009) Alveolar bone dimensional changes of post-extraction sockets in humans: A systematic review. *J Clin Periodontol* **36**: 1048-1058.
- Tan, W.L., Wong, T.L., Wong, M.C. & Lang, N.P., (2012) A systematic review of post-extractoral alveolar hard and soft tissue dimensional changes in humans. *Clin Oral Implants Res* **23 Suppl 5**: 1-21.
- Saadoun, A.P. & Landsberg, C.J., (1997) Treatment classifications and sequencing for postextraction implant therapy: A review. *Pract Periodontics Aesthet Dent* **9**: 933-941; quiz 942.
- Farmer, M. & Darby, I., (2014) Ridge dimensional changes following single-tooth extraction in the aesthetic zone. *Clin Oral Implants Res* **25**: 272-277.
- Schropp, L., Wenzel, A., Kostopolous, L. & Karring, T., (2003) Bone healing and soft tissue contour changes following single-tooth extraction: A clinical and radiographic 12-month prospective study. *International Journal of Periodontics & Restorative Dentistry* **23**: 313-323.
- Lekovic, V., Kenney, E.B., Weinlaender, M., Han, T., Klokkevold, P., Nedic, M. & Orsini, M., (1997) A bone regenerative approach to alveolar ridge maintenance following tooth extraction. Report of 10 cases. *J Periodontol* **68**: 563-570.
- Lekovic, V., Camargo, P.M., Klokkevold, P.R., Weinlaender, M., Kenney, E.B., Dimitrijevic, B. & Nedic, M., (1998) Preservation of alveolar bone in extraction sockets using bioabsorbable membranes. *J Periodontol* **69**: 1044-1049.
- Camargo, P.M., Lekovic, V., Weinlaender, M., Klokkevold, P.R., Kenney, E.B., Dimitrijevic, B., Nedic, M., Jancovic, S. & Orsini, M., (2000) Influence of bioactive glass on changes in alveolar process dimensions after exodontia. *Oral Surg Oral Med Oral Pathol Oral Radiol Endod* **90**: 581-586.
- Lasella, J.M., Greenwell, H., Miller, R.L., Hill, M., Drisko, C., Bohra, A.A. & Scheetz, J.P., (2003) Ridge preservation with freeze-dried bone allograft and a collagen membrane compared to extraction alone for implant site development: A clinical and histologic study in humans. *J Periodontol* **74**: 990-999.
- Serino, G., Biancu, S., Iezzi, G. & Piattelli, A., (2003) Ridge preservation following tooth extraction using a polylactide and polyglycolide sponge as space filler: A clinical and histological study in humans. *Clin Oral Implants Res* **14**: 651-658.

- Barone, A., Aldini, N.N., Fini, M., Giardino, R., Calvo Guirado, J.L. & Covani, U., (2008) Xenograft versus extraction alone for ridge preservation after tooth removal: A clinical and histomorphometric study. *J Periodontol* **79**: 1370-1377.
- Pelegrine, A.A., da Costa, C.E., Correa, M.E. & Marques, J.F., Jr., (2010) Clinical and histomorphometric evaluation of extraction sockets treated with an autologous bone marrow graft. *Clin Oral Implants Res* **21**: 535-542.
- Aimetti, M., Romano, F., Griga, F.B. & Godio, L., (2009) Clinical and histologic healing of human extraction sockets filled with calcium sulfate. *Int J Oral Maxillofac Implants* **24**: 902-909.
- Huynh-Ba, G., Pjetursson, B.E., Sanz, M., Cecchinato, D., Ferrus, J., Lindhe, J. & Lang, N.P., (2010) Analysis of the socket bone wall dimensions in the upper maxilla in relation to immediate implant placement. *Clin Oral Implants Res* **21**: 37-42.
- Braut, V., Bornstein, M.M., Belser, U. & Buser, D., (2011) Thickness of the anterior maxillary facial bone wall-a retrospective radiographic study using cone beam computed tomography. *International Journal of Periodontics & Restorative Dentistry* **31**: 125-131.
- Zekry, A., Wang, R., Chau, A.C. & Lang, N.P., (2014) Facial alveolar bone wall width - a cone-beam computed tomography study in Asians. *Clin Oral Implants Res* **25**: 194-206.
- Chen, S.T., Darby, I.B. & Reynolds, E.C., (2007) A prospective clinical study of non-submerged immediate implants: Clinical outcomes and esthetic results. *Clin Oral Implants Res* **18**: 552-562.
- Ferrus, J., Cecchinato, D., Pjetursson, E.B., Lang, N.P., Sanz, M. & Lindhe, J., (2010) Factors influencing ridge alterations following immediate implant placement into extraction sockets. *Clin Oral Implants Res* **21**: 22-29.
- Chappuis, V., Engel, O., Reyes, M., Shahim, K., Nolte, L.P. & Buser, D., (2013) Ridge alterations post-extraction in the esthetic zone: A 3d analysis with cbct. *J Dent Res* **92**: 195S-201S.
- Nevins, M., Camelo, M., De Paoli, S., Friedland, B., Schenk, R.K., Parma-Benfenati, S., Simion, M., Tinti, C. & Wagenberg, B., (2006) A study of the fate of the facial wall of extraction sockets of teeth with prominent roots. *International Journal of Periodontics & Restorative Dentistry* **26**: 19-29.
- Kan, J.Y., Rungcharassaeng, K., Umezumi, K. & Kois, J.C., (2003) Dimensions of peri-implant mucosa: An evaluation of maxillary anterior single implants in humans. *J Periodontol* **74**: 557-562.
- Cook, D.R., Mealey, B.L., Verrett, R.G., Mills, M.P., Noujeim, M.E., Lasho, D.J. & Cronin, R.J., Jr., (2011) Relationship between clinical periodontal biotype and labial

plate thickness: An in vivo study. *International Journal of Periodontics & Restorative Dentistry* **31**: 345-354.

Chappuis, V., Engel, O., Shahim, K., Reyes, M., Katsaros, C. & Buser, D., (2015) Soft tissue alterations in esthetic postextraction sites: A 3-dimensional analysis. *J Dent Res* **94**: 187S-193S.

Juodzbaly, G. & Wang, H.L., (2007) Soft and hard tissue assessment of immediate implant placement: A case series. *Clin Oral Implants Res* **18**: 237-243.

Tomasi, C., Sanz, M., Cecchinato, D., Pjetursson, B., Ferrus, J., Lang, N.P. & Lindhe, J., (2010) Bone dimensional variations at implants placed in fresh extraction sockets: A multilevel multivariate analysis. *Clin Oral Implants Res* **21**: 30-36.

Buser, D., Chen, S.T., Weber, H.P. & Belser, U.C., (2008) Early implant placement following single-tooth extraction in the esthetic zone: Biologic rationale and surgical procedures. *International Journal of Periodontics & Restorative Dentistry* **28**: 441-451.

Table 1- Demographics

		N (%)	N (%)	N (%)
Gender	Total	Male	Female	
	34	15 (44.1)	19 (55.9)	
Gingival phenotype		Thick	Thin	
	34	16 (47.1)	18 (52.9)	
Site		Maxillary central incisor	Maxillary lateral incisor	
		27 (79.4)	7 (20.6)	

Facial bone		Thick	Thin	
	34	5 (14.7)	29 (52.9)	
Facial bone condition		Intact	Dehiscence	Fenestration
	34	16 (47.0)	9 (26.5)	9 (26.5)
		Mean (\pm sd)	Mean (\pm sd)	
Age (years)	All	Male	Female	
	44.6 (\pm 12.74)	44.7 (\pm 13.07)	44.6 (\pm 12.84)	

Table 2 – Reason for extraction and condition of the facial bone at the time of extraction

Reason for extraction	Condition of the facial bone at the time of extraction – N			
	Dehiscence	Fenestration	Intact	All
loss of crown retention/loss of structural integrity of a previously restored tooth	1	0	10	11
Endodontic failure	1	5	0	6
External root resorption	2	1	5	8
Vertical root fracture	5	3	1	9
All	9	9	16	34

Table 3 – Facial bone defect at the time of extraction and after 8 weeks

Bone defect at extraction	Re-entry bone defect			
	Dehiscence	Fenestration	Intact	All
Intact	9	0	7	16
Dehiscence	9	0	0	9
Fenestration	5	2	2	9
	23	2	9	34

Table 4 – Reduction in the external (soft tissue) and internal (bone) horizontal ridge width between extraction and 8 weeks

		All mm ± sd (% change)	Condition of the facial bone at the time of extraction				
			Intact mm ± sd (% change)	Dehiscence mm ± sd (% change)	Fenestration mm ± sd (% change)		
No. of sites		34	16	9	9		
Change in orofacial (soft tissue) ridge dimension	Mesial	1.4 ± 1.30 (12.1%) *	1.0 ± 1.03 (9.1%)	1.7 ± 1.69 (14.6%)	1.7 ± 1.32 (15.1%)	p = 0.338	
	Facial	2.5 ± 1.46 (22.2%) *	1.9 ± 1.03 (17.1%)	3.3 ± 1.80 (28.4%)	2.8 ± 1.40 (24.9%)	p = 0.040 (sig)	Dehiscence vs Intact p = 0.038
	Distal	1.1 ± 0.83 (10.5%) *	0.9 ± 0.81 (8.5%)	1.1 ± 1.05 (10.5%)	1.4 ± 0.53 (14.1%)	p = 0.264	
Change in	Mesial	0.8 ± 0.80	0.8 ± 0.86	0.4 ± 0.73	0.8 ± 0.83	p = 0.614	

orofacial bone dimension		(9.3%) *	(9.7%)	(6.9%)	(11.0%)		
	Facial	1.2 ± 1.03 (15.3%) *	1.1 ± 0.93 (13.7%)	n/a	1.3 ± 1.23 (18.1%)	p = 0.430	
	Distal	0.4 ± 0.65 (5.5%) **	0.4 ± 0.73 (5.9%)	0.4 ± 0.72 (6.9%)	0.2 ± 0.44 (3.4%)	p = 0.704	
Change in apicocoronal position of the bone crest	Mesiofacial	0.3 ± 0.86	0.3 ± 0.87	0.1 ± 0.60	0.3 ± 0.22	p = 0.832	
	Facial	1.4 ± 1.94 *	0.5 ± 0.34	1.4 ± 0.88	2.9 ± 2.67	p = 0.008 (sig)	Fenestration vs intact p = 0.006
	Distofacial	0.1 ± 1.08	0.1 ± 1.09	0.2 ± 0.97	0.3 ± 1.23	p = 0.580	
	Mesiopalatal	0.6 ± 1.10 **	0.6 ± 1.26	0.2 ± 0.97	1.2 ± 0.67	p = 0.309	
	Palatal	0.6 ± 1.13 **	0.5 ± 0.97	0.7 ± 1.23	0.6 ± 1.42	p = 0.992	
	Distopalatal	0.4 ± 1.02 ***	0.3 ± 1.01	0.6 ± 1.24	0.6 ± 0.88	p = 0.843	

n/a denotes no measurement of the horizontal bone width was obtained due to the presence of a facial dehiscence.

* denotes p < 0.001 between baseline and re-entry

** denotes p < 0.01 between baseline and re-entry

*** denotes $p < 0.05$ between baseline and re-entry

Author Manuscript

Table 5 - Reduction in the external (soft tissue) and internal (bone) horizontal ridge width between extraction and 8 weeks in relation to tissue phenotype

		Thin phenotype mm ± sd	Thick phenotype mm ± sd	
Change in orofacial (soft tissue) ridge dimension	Mesial	1.6 ± 0.38	1.1 ± 0.81	p = 0.343
	Facial	2.8 ± 1.77	2.2 ± 0.98	p = 0.246
	Distal	1.1 ± 0.94	1.1 ± 0.72	p = 0.812
Change in orofacial bone dimension	Mesial	0.9 ± 0.73	0.4 ± 0.81	p = 0.038 (sig)
	Facial	1.8 ± 1.52	0.9 ± 0.89	p = 0.045 (sig)
	Distal	0.4 ± 0.61	0.4 ± 0.72	p = 0.952

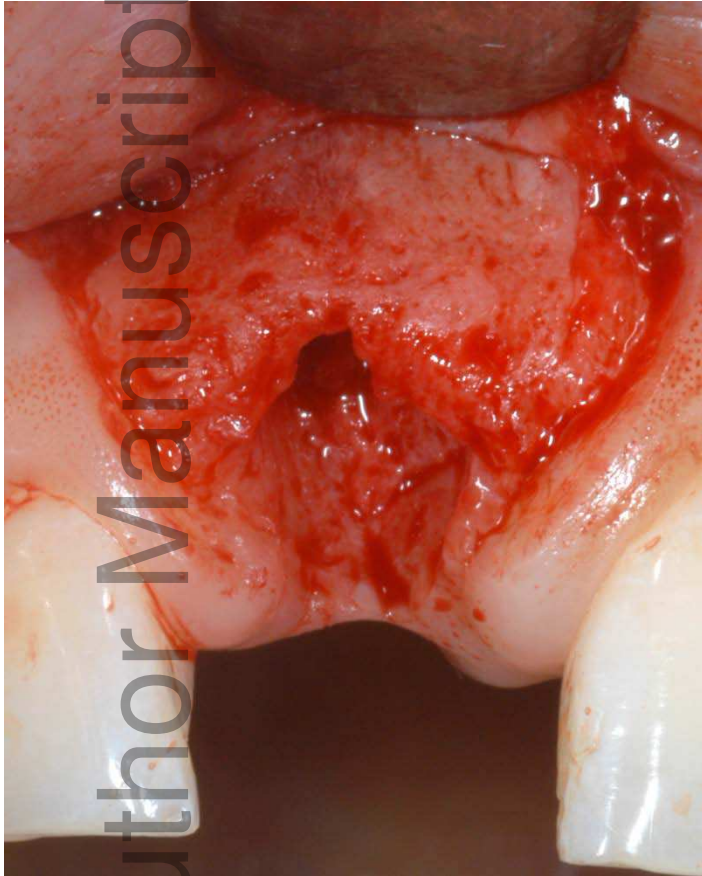

Fig 1a

Surgical re-entry of a maxillary central incisor site that initially had intact facial bone. At re-entry, the facial bone was largely intact although vertical (apicocoronal) resorption at the mid-facial region is evident.

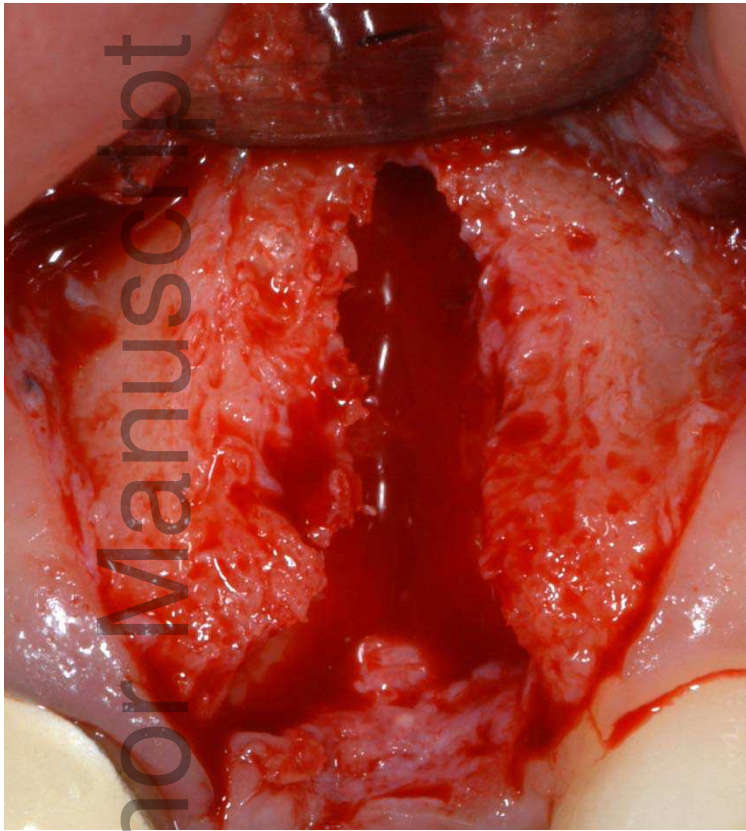


Fig 1b

In this central incisor site, an apical fenestration with intact bridge of bone at the facial crest was noted at the time of extraction. At surgical re-entry, the site had developed a large dehiscence defect following resorption of the crestal bone.

Author Manuscript

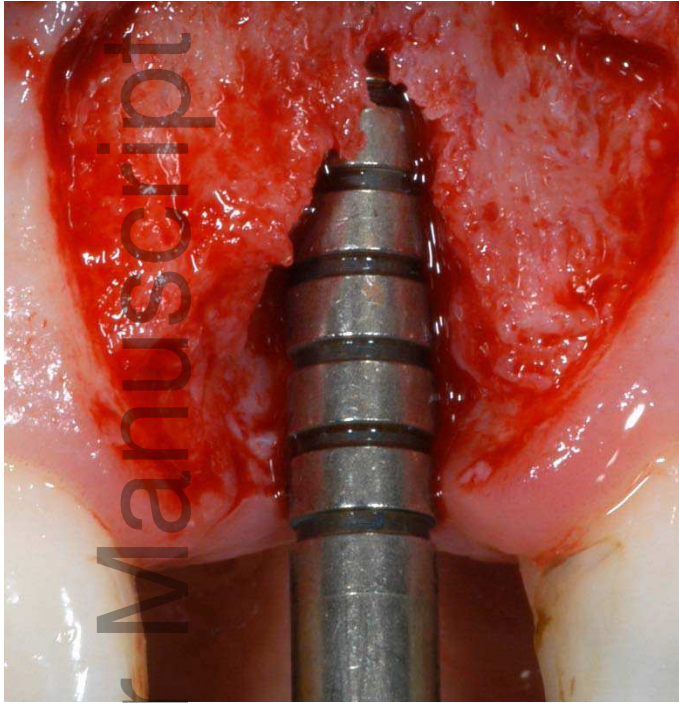


Fig 1c

In this maxillary central incisor site, the facial bone was intact at the time of extraction. At re-entry, resorption of the facial bone resulted in a V-shaped dehiscence defect.

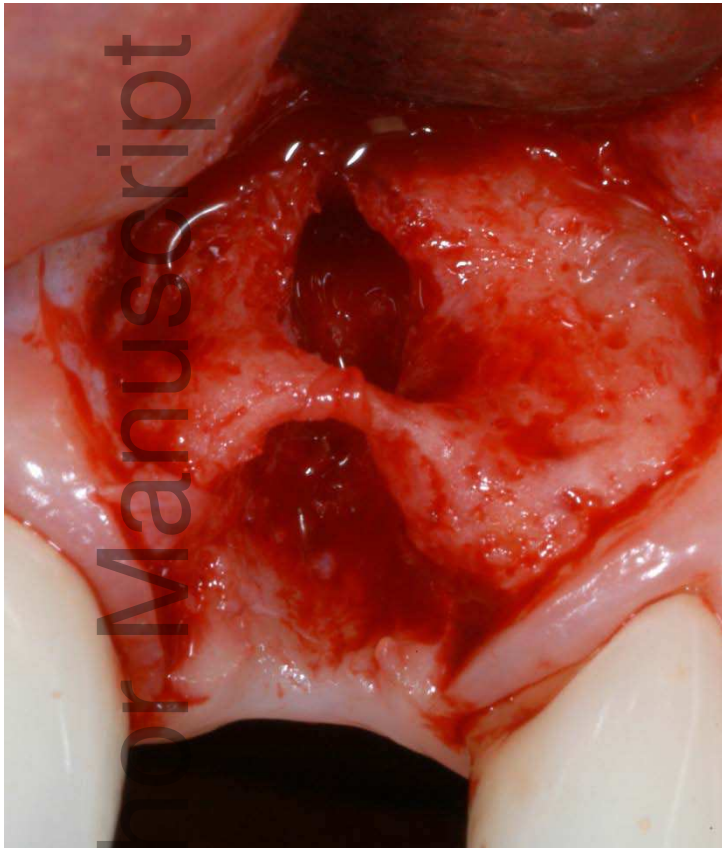


Fig 1d

In a maxillary central incisor site, a fenestration defect of the facial bone was evident at the time of extraction. At re-entry, the bridge of facial crestal bone was retained resulting in persistence of the fenestration defect.