



Minerva Access is the Institutional Repository of The University of Melbourne

Author/s:

Loh, Z;Manning, TG;O'Brien, JS;Perera, M;Lawrentschuk, N

Title:

Mesenteric metastases from mature teratoma of the testis: A case report

Date:

2020-07-01

Citation:

Loh, Z., Manning, T. G., O'Brien, J. S., Perera, M. & Lawrentschuk, N. (2020). Mesenteric metastases from mature teratoma of the testis: A case report. *Asian Journal of Urology*, 7 (3), pp.322-325. <https://doi.org/10.1016/j.ajur.2018.05.007>.

Persistent Link:

<https://hdl.handle.net/11343/271722>

License:

[CC BY-NC-ND](#)



Case Report

Mesenteric metastases from mature teratoma of the testis: A case report

Zoe Loh ^{a,b}, Todd G. Manning ^{a,b,*}, Jonathan S. O'Brien ^{a,b},
Marlon Perera ^{a,b,c}, Nathan Lawrentschuk ^{a,c,d,e}



^a Department of Surgery, University of Melbourne, Austin Health, Melbourne, Australia

^b The Young Urology Researchers Organisation (YURO), Australia

^c Faculty of Medicine, University of Queensland, Brisbane, Australia

^d Department of Surgical Oncology, Peter MacCallum Cancer Centre, Melbourne, Australia

^e Olivia Newton-John Cancer Research Institute, Melbourne, Australia

Received 12 January 2018; received in revised form 16 March 2018; accepted 3 April 2018

Available online 5 June 2018

KEYWORDS

Nonseminomatous germ cell tumour;
Retroperitoneal lymph node dissection;
Mesentery;
Metastases;
Testicular cancer

Abstract Metastatic spread of testicular cancer has been well documented, with 95% of cases involving para-aortic retroperitoneal lymph nodes. Mesenteric lymphatic basins do not lie within the canonical drainage pathway of the testes and represent a rare site of metastasis. Various mechanisms of spread to the mesentery have been described, including direct extension and haematogenous dissemination. We present a case of a previously-well 43-year-old man who presented with right scrotal discomfort and intermittent lower back pain, who was found to have mesenteric metastases from a non-seminomatous germ cell tumour of the testis. Managing lymphadenopathy that lies outside of standard resection templates remains a complex surgical challenge. Here we present the first case in the English medical literature with co-existing supradiaphragmatic axillary and mediastinal nodal disease.

© 2020 Editorial Office of Asian Journal of Urology. Production and hosting by Elsevier B.V. This is an open access article under the CC BY-NC-ND license (<http://creativecommons.org/licenses/by-nc-nd/4.0/>).

1. Introduction

Testicular cancer remains the most common solid organ malignancy in young males, with peak incidence from age 25–29 years [1]. The majority of testicular primaries arise

from germ cell tumours (GCTs), which are histologically divided into seminomas or non-seminomatous (NSGCT). Mature teratomas are a subtype of NSGCT which are characterised by well-differentiated elements of at least

* Corresponding author. Department of Surgery, Austin Health, Melbourne, Australia.

E-mail address: doctor.tmanning@gmail.com (T.G. Manning).

Peer review under responsibility of Second Military Medical University.

two germ cell layers, and often form complex circumscribed masses.

GCTs are unique solid organ malignancies because they are often metastatic at diagnosis. These aggressive tumours are often highly responsive to treatment and have a 5-year survival greater than 95% [1]. Metastatic spread often occurs in a stepwise pattern following the primary lymphatic drainage of the testes. Lymphadenopathy of the para-aortic, paracaval and inter-aortocaval nodes of the retroperitoneum is observed prior to involvement of the iliac and mediastinal nodes and systemic disease [2]. Extra nodal metastases are thought to arise from hematological dissemination and commonly involve the liver, brain and lungs.

Retroperitoneal tumour deposits that are refractory to chemotherapy require surgical debulking via retroperitoneal lymph node dissection (RPLND). The goal of this invasive procedure is to perform template resection of para-aortic lymph nodes to clear the remaining tumour burden post orchiectomy. The procedure relies upon standardized templates to guide the excision of diseased lymph tissue. However, there is limited evidence to guide operative plans when metastatic disease is identified in atypical sites. In these cases, the goals of surgery are to maximize the volume of tumour resection within the realms of patient safety.

Metastatic spread outside of conserved lymphatic and hematological pathways in testicular cancer is unusual but has been reported in heart, soft tissue and skin. Mesenteric neoplasms are observed more commonly secondary to gastrointestinal, breast and lung malignancies [3]. We present the multidisciplinary management of concurrent supradiaphragmatic axillary and mediastinal nodal deposits from a primary NSGCT teratoma.

2. Case report

A 43-year-old male with no significant past medical history presented to our tertiary health service with right scrotal discomfort and intermittent lower back pain radiating to the right inguinal region. On physical examination, a discreet, firm mass was observed in the right testicle. All further findings were normal and no palpable lymphadenopathy was appreciated. Subsequent scrotal ultrasound identified a 5 mm complex solid mass in the right testicle. Initial tumour markers demonstrated a beta-human chorionic gonadotropin (β HCG) of 16 000 IU/mL (reference range 0–5 IU/mL), alpha-feto protein (AFP) of 34.4 ng/mL (0.5–12.0 ng/mL), and lactate dehydrogenase (LDH) of 261 U/L (120–250 U/L). Staging computed tomography (CT) with intravenous contrast identified diffuse lymphadenopathy, with large, centrally-hypodense lymph nodes in the retroperitoneum and mesentery. The total diameter of the abdominal mass was 180 mm (Fig. 1A). Lymphadenopathy involving the left superior mediastinum, supraclavicular region and left axilla was evident. Several poorly enhancing hepatic lesions, consistent with liver metastases were detected. No pleural or bony disease was identified.

A right orchiectomy was undertaken and the testis was sent for histopathological analysis. A mixed germ cell tumour (seminoma 90%, mature teratoma 10%) was

identified. Surgical excision margins were clear, and there was no invasion of the lymphovascular system, tunica vaginalis or spermatic cord. The patient subsequently received four cycles of chemotherapy with bleomycin, etoposide and cisplatin. At completion of chemotherapy, the patient's back pain had resolved and β HCG had fallen to 55 IU/mL. LDH continued to rise with a peak of 287 U/L. Repeat CT demonstrated persistent retroperitoneal and mesenteric lymphadenopathy with reduced size (Fig. 1B). There was no change in size of the supradiaphragmatic nodes, the largest of which measured 36 mm \times 23 mm in neck, and 25 mm \times 25 mm in axilla. There was interval stability in the size and location of the liver lesions.

In the setting of persistent elevated β HCG, LDH and residual tumour burden at completion chemotherapy, the case was discussed at an institutional multidisciplinary meeting. The recommended management was for open RPLND. The procedure involved a full para-aortic template dissection. Mesenteric lymphadenopathy was identified in multiple locations both proximal and distal to the main para-aortic and para-caval tumour burden. Intraoperatively, there was complete resection of the mesenteric masses (Fig. 2 and Fig. 3) and five liver lesions. A limited small bowel resection was also undertaken due to proximity of mesenteric deposits.

There were no significant intraoperative or perioperative complications. Histopathology confirmed numerous deposits of multicystic mature teratomas in the mesenteric specimen, the largest of which was 165 mm in maximal dimension. Similar tumour characteristics were identified in the retroperitoneal, aortic and para-aortocaval nodes. There was no evidence of metastatic disease in the small bowel, and the liver lesions were histologically characterized as benign haemangiomas. The β HCG level returned to normal in post-surgical follow-up.

Three months postoperatively, the patient underwent secondary resection of the left supraclavicular and mediastinal masses. He also underwent left sided axillary dissection. Histology from these resections demonstrated mature teratoma in the primary mediastinal specimen and 21 of the 32 axillary nodes demonstrating evidence of disease.

CT imaging at 6 months post-initial operation demonstrated a small mediastinal recurrence. The patient subsequently underwent an uncomplicated re-resection led by a team of thoracic surgeons. Follow-up with serial CT imaging and serum β HCG at 12 and 18 months revealed a disease-free abdomen and normalized tumour markers. At the time of publication, the patient remains well with no postoperative or oncological complications and continues review with our service.

3. Discussion

Metastatic testicular cancer involving mesenteric lymph nodes has only been described in two previous case reports in the English literature. Donkol et al. [4] and Djaladat et al. [5] reported cases of large mesenteric metastases with bulky retroperitoneal disease from testicular NSGCT. Both teams described performing a complete resection of primary teratomas and concomitant nodal deposits.

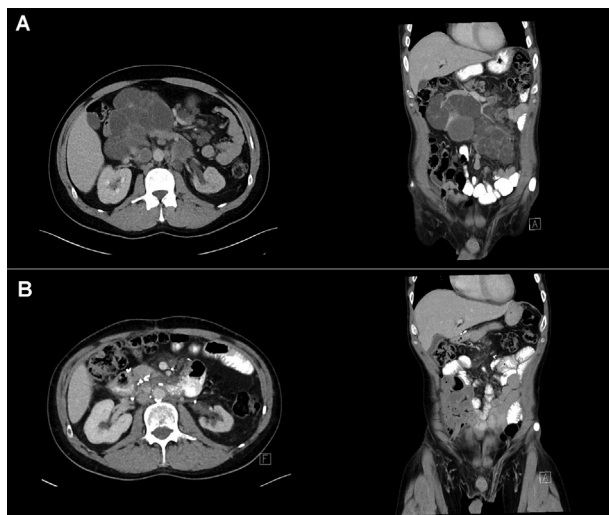


Figure 1 Pre- and postoperative imaging results. (A) Computed tomography (CT) images of the abdomen prior to chemotherapy show markedly enlarged, centrally hypodense lymph nodes in the retroperitoneum and mesentery; (B) Post-operative CT images demonstrate complete resection of abdominal masses.

Our case represents the first description of co-existing mesenteric and supradiaphragmatic disease in the English literature.

Various theoretical mechanisms of mesenteric spread have been proposed, including serosal deposits invading the bowel via transperitoneal seeding, direct infiltration of nodes at the root of mesentery and embolic haematogenous spread [6]. Gastrointestinal tract (GIT) metastases from testis have been reported more frequently than mesenteric nodal metastasis in the literature. Sweetenham et al. [7] identified six cases of GIT metastases from primary testicular carcinoma. These authors attributed three cases to direct extension from retroperitoneal lymphadenopathy and the other three to haematogenous spread. A larger series of 487 GCTs suggested the rate of GIT metastases was

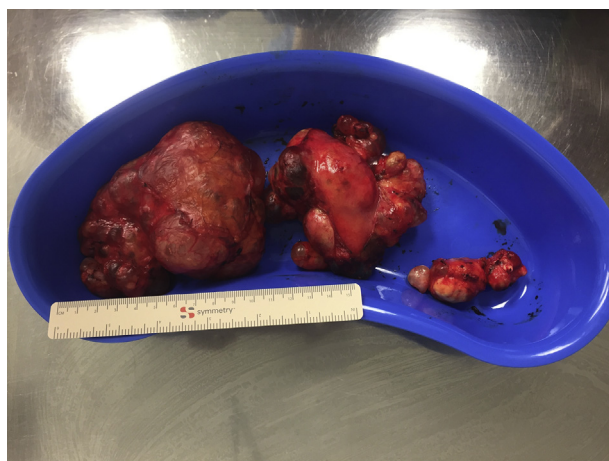

Figure 2 Photo of resected mesenteric lymph nodes. The largest was 165 mm in width.

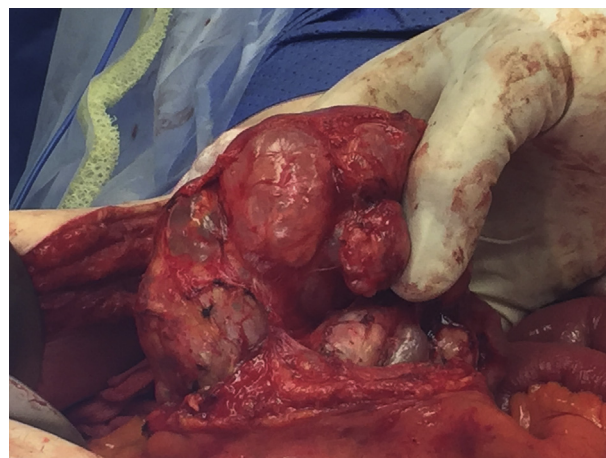


Figure 3 Intraoperative image of the mesenteric tumour resection.

5%; the majority of these (84%) had evidence of direct invasion of adjacent tumour, although the authors did suggest concurrent modes of spread were possible [8].

Our case demonstrated extensive retroperitoneal lymphadenopathy, varied mesenteric nodal involvement and absence of extranodal disease. Given this anatomical context, we hypothesise that the most likely mechanism of invasion is via lymphatic communication between the retroperitoneum and the root of the mesentery.

The importance of aggressive surgical management in chemotherapy-resistant advanced NSGCT is well established [9]. Long-term survival rates of >90% have been achieved when residual tumours are completely excised. However, patients with incomplete resections often require additional chemotherapy and experience significantly lower survival rates [10]. RPLND justifiably serves a prognostic, diagnostic and therapeutic role in management of metastatic NSGCT. In cases where atypical lymphadenopathy is present extended non-canonical dissection within the margins of patient safety is potentially a lifesaving intervention.

4. Conclusion

Mesenteric lymphadenopathy from testicular GCT is a rare phenomenon. The etiology of this disease presentation is unknown but likely due to either hematological sources via the mesenteric root vessels or via direct spread from adjacent lymph nodes. The latter is particularly relevant in large bulky retroperitoneal disease.

The positive response and early prognosis of our patient indicate that while NSGCT can present with significant nodal disease outside the usual drainage sites, complete surgical resection is possible and should be considered to maximize the patient's chances of disease-free survival and provide diagnostic closure.

Author contributions

Study design: Nathan Lawrentschuk.

Data acquisition: Zoe Loh, Todd G. Manning.

Data analysis: Zoe Loh.

Drafting of manuscript: Zoe Loh.

Critical revision of the manuscript: Todd G. Manning, Jonathan S. O'Brien, Marlon Perera.

Conflicts of interest

The authors declare no conflict of interest.

References

- [1] Stevenson SM, Lowrance WT. Epidemiology and diagnosis of testis cancer. *Urol Clin N Am* 2015;42:269–75.
- [2] Pano B, Sebastia C, Bunesch L, Mestres J, Salvador R, Macias NG, et al. Pathways of lymphatic spread in male urogenital pelvic malignancies. *Radiographics* 2011;31:135–60.
- [3] Sheth S, Horton KM, Garland MR, Fishman EK. Mesenteric neoplasms: CT appearances of primary and secondary tumors and differential diagnosis. *Radiographics* 2003;23:457–73. quiz 535–6.
- [4] Donkol RH, Monib S, Eltounsi I. Occult testicular teratoma presenting with solid mesenteric metastasis. *J Ultrasound Med* 2007;26:675–8. <https://doi.org/10.1016/j.urology.2013.11.003>.
- [5] Djaladat H, Movassaghi K, Ahmadi H, Nichols CR, Daneshmand S. Mesenteric lymphadenopathy in testicular germ cell tumor. *Urology* 2014;83:e7–8.
- [6] Park JM, Charnsangavej C, Yoshimitsu K, Herron DH, Robinson TJ, Wallace S. Pathways of nodal metastasis from pelvic tumors: CT demonstration. *Radiographics* 1994;14:1309–21.
- [7] Sweetenham JW, Whitehouse JM, Williams CJ, Mead GM. Involvement of the gastrointestinal tract by metastases from germ cell tumors of the testis. *Cancer* 1988;61:2566–70.
- [8] Chait MM, Kurtz RC, Hajdu SI. Gastrointestinal tract metastasis in patients with germ-cell tumor of the testis. *Am J Dig Dis* 1978;23:925–8.
- [9] Heidenreich A, Pfister D. Retroperitoneal lymphadenectomy and resection for testicular cancer: an update on best practice. *Ther Adv Urol* 2012;4:187–205.
- [10] Hartmann JT, Schmoll HJ, Kuczyk MA, Candelaria M, Bokemeyer C. Postchemotherapy resections of residual masses from metastatic non-seminomatous testicular germ cell tumors. *Ann Oncol* 1997;8:531–8.