University Library

MINERVA ACCESS

A gateway to Melbourne's research publications

Minerva Access is the Institutional Repository of The University of Melbourne

Author/s:
Smithers, BM;Saw, RPM;Gyorki, DE;Martin, RCW;Atkinson, V;Haydon, A;Roberts-Thomson, R;Thompson, JF

Title:
Contemporary management of locoregionally advanced melanoma in Australia and New Zealand and the role of adjuvant systemic therapy

Date:
2021-08-01

Citation:
Smithers, B. M., Saw, R. P. M., Gyorki, D. E., Martin, R. C. W., Atkinson, V., Haydon, A., Roberts-Thomson, R. & Thompson, J. F. (2021). Contemporary management of locoregionally advanced melanoma in Australia and New Zealand and the role of adjuvant systemic therapy. ANZ Journal of Surgery, 91 (S2), pp.3-13. https://doi.org/10.1111/ans.17051.

Persistent Link:
https://hdl.handle.net/11343/298762

Smithers Mark (Orcid ID: 0000-0002-8333-8685)
Gyorki David (Orcid ID: 0000-0002-3165-4694)
Thompson John (Orcid ID: 0000-0002-2816-2496)

 Final

Title: Contemporary management of locoregionally advanced melanoma in Australia and New Zealand and the role of adjuvant systemic therapy.

Running Title: Regional metastatic melanoma management

Authors:

B Mark Smithers (MBBS, FRACS)[1]

Robyn PM Saw (MBBS, MS, FRACS)[2]

David E Gyorki (MBBS, MD, FRACS)[3]

Richard CW Martin (MBChB, FRACS, ChM)[4]

Victoria Atkinson (MBBS, FRACP)[1]

Andrew Haydon (MBBS, FRACP)[5]

Rachel Roberts-Thomson (MBBS, FRACP)[6]

John F Thompson (MBBS, MD, FRACS)[2]

Author Affiliations

1. Queensland Melanoma Project, Faculty of Medicine, University of Queensland and Princess Alexandra Hospital, Brisbane, QLD, Australia

2. Melanoma Institute Australia, The University of Sydney and Royal Prince Alfred Hospital, Sydney, NSW, Australia

3. Peter MacCallum Cancer Centre, Melbourne, VIC, Australia

4. New Zealand Melanoma Unit, Takapuna, Auckland, New Zealand

5. Alfred Hospital, Melbourne, VIC, Australia

6. The Queen Elizabeth Hospital, Adelaide, SA, Australia

This is the author manuscript accepted for publication and has undergone full peer review but has not been through the copyediting, typesetting, pagination and proofreading process, which may lead to differences between this version and the Version of Record. Please cite this article as doi: 10.1111/ans.17051

This article is protected by copyright. All rights reserved.

Author Manuscript

Corresponding author's full contact details:

Name: Professor Mark Smithers

Address: The University of Queensland, Brisbane, QLD 4072

Phone: 0721765309

Email: m.smithers@uq.edu.au

Number of Figures and Tables: 2 Figures and 3 Tables

Abstract Word Count: 196

Main text word Count: 4, 842

Author Manuscript

Abstract

Australia and New Zealand have the highest incidence and mortality rates for melanoma in the world. Local surgery is still the standard treatment of primary cutaneous melanoma, and it is therefore important that surgeons understand the optimal care pathways for patients with melanoma. Accurate staging is critical to ensure a reliable assessment of prognosis and to guide treatment selection. Sentinel node biopsy (SNB) plays an important role in staging and the provision of reliable prognostic estimates for patients with cutaneous melanoma.

Patients with stage III melanoma have a substantial risk of disease recurrence following surgery, leading to poor long-term outcomes. Systemic immunotherapies and targeted therapies, known to be effective for stage IV melanoma, have now also been shown to be effective as adjuvant post-surgical treatments for resected stage III melanoma. These patients

should be made aware of this and preferably managed in an integrated multidisciplinary model of care, involving the surgeon, medical oncologists and radiation oncologists.

This review considers the impact of a recent update to the American Joint Committee on Cancer (AJCC) staging system, the role of SNB for patients with high-risk primary melanoma and recent advances in adjuvant systemic therapies for high-risk patients.

Key Words: cutaneous melanoma, sentinel node biopsy, staging, adjuvant drug therapy, immunotherapy, targeted therapy.

Author Manuscript

Author Manuscript

Introduction

The incidence of primary cutaneous melanoma continues to rise in most Caucasian populations globally, with Australia and New Zealand having a large burden of disease. In Australia and New Zealand, melanoma is the third most common cancer in both men and women. The highest age-specific melanoma rates are observed in the elderly (> 80 years) and are projected to continue rising in all age groups.[1]

For patients with primary cutaneous melanoma, adequate local surgery is the standard treatment.[2, 3] They are staged according to whether they have localised disease with no evidence of metastasis (stage I-II), regional node disease (stage III) or distant metastatic disease (stage IV), according to the guidelines provided in the most recent (8th) edition of the American Joint Committee on Cancer (AJCC) Cancer Staging Manual.[4] Although 10-year survival rates of 75-98% are achieved with surgery alone for patients with stage I and II melanoma, those with stage III melanoma are a very heterogenous cohort, with 10-year survival rates ranging from 24% to 88% following surgery alone.[4] Many of these patients will have disease recurrence following surgery, leading to poor long-term outcomes.[5] The introduction of systemic immunotherapies and targeted therapies have resulted in significant improvements in outcomes for patients with stage IV melanoma.[6-9] Having been proven to have efficacy for stage IV disease, these therapies have subsequently been assessed in trials incorporating patients with earlier stages of melanoma, and they are now being utilised as adjuvant post-surgical treatments for patients with resected stage III melanoma.

Assessment of the appropriateness of adjuvant systemic therapy is guided by accurate disease staging, so that the appropriate high-risk patients are selected for treatment. In this review we consider the impact of recent updates to the AJCC staging system (8th edition), noting particularly the changes to stage III subclassifications, the role of sentinel node biopsy (SNB) and its contribution to staging and prognosis, the evidence for avoiding a completion node

dissection in SN-positive patients, as well as recent advances in adjuvant systemic therapies for high-risk patients.

Melanoma Staging

Accurate staging of patients with cutaneous melanoma is essential to ensure a reliable assessment of prognosis and to guide treatment selection.[4] Current melanoma staging uses the internationally-accepted AJCC staging system. The criteria outlined in the most recently published (8th edition) of the AJCC Staging Manual were developed to provide more accurate prognostic estimates to align with the rapidly evolving advances in the understanding of biological and pathological processes that occur in cutaneous melanoma. Together, both non-anatomical and anatomical factors contribute important prognostic information and as a result, there have been changes to the AJCC stage I and stage III subgroupings.[4] Staging of the primary disease (Stages I and II) is based on outcomes from over 23,000 patients. Using the T staging as per Figure 1, Stage I has two groups: Stage 1A (T1a, T1b) and Stage 1B (T2a). Stage 2 has three groups: Stage 2A (T2b, T3a); Stage 2B (T3b and T4a) and Stage 2C (T4b). All patients with a melanoma greater than 1mm in Breslow thickness (T2-T4) had a SNB.[4] This has led to better stratification and assessment of the prognosis for T stage groups. For example, a comparison of the AJCC 7th edition with the 8th edition of 10-year survival rates for Stages IA and IIC were 93% and 39%, compared with 98% and 75%, respectively.[4, 10] AJCC 8th edition has also separated patients staged clinically (by clinical examination only) and pathologically (with SNB), with changes made for stage I melanoma (≤ 1mm Breslow thickness) better reflecting survival of those patients with pathologically-negative nodes. Patients with pathological T1b N0 melanomas (i.e. a negative SNB) are now included in pathological stage IA (rather than stage IB as in the 7th edition). However, patients with clinical T1b N0 melanomas who have not had a SNB are still classified as Stage IB.[4]

Author Manuscript

For stage III melanoma, the stratification in the AJCC 7th edition staging related to the degree of regional lymph node involvement and tumour ulceration. In the 8th edition, stage III groups now include T-category factors (ulceration and tumour thickness), the extent of nodal involvement - clinically occult (SNB-positive) or clinically detected, and the presence of microsatellite, satellite and/or in-transit disease. This created eight pathological subgroups which were combined to create four staging groups, adding stage IIID to stages IIIA, IIIB and IIIC (Figure 1).[4] Stage IIID includes patients with a thick and ulcerated primary tumour (T4b), and either four or more tumour-involved regional nodes (N3a or N3b) or two or more tumour-involved nodes with evidence of microsatellite, satellite or in-transit disease (N3c). These four subgroups capture the heterogeneity of survival rates of patients with stage III melanoma. The 10-year melanoma-specific survival (MSS) rate ranges from 88% in patients with stage IIIA (micro-metastatic disease, SNB-positive) disease to 24% for patients with stage IIID disease. These differences in survival rates have important implications for clinical decision making.[4]

The Role of Sentinel Node Biopsy (SNB)

SNB plays an important role in providing accurate staging and informing prognostic outcomes for patients with cutaneous melanoma, as evidenced by its integral role in the AJCC 8th edition staging system. SNB involves lymphatic mapping to identify "sentinel" nodes, which are any regional nodes that receive lymph drainage directly from the site of the primary melanoma, and surgical retrieval and thorough pathological examination of these nodes. Several studies have shown that SN status is an important prognostic indicator for patients with clinically-localised primary cutaneous melanomas.[11-13] Although SNB is now recommended for patients with T2, T3 and T4 primary melanomas,[4] there is strong evidence that supports prognostic stratification by means of SNB in patients with melanomas between 0.8 and 1mm, with or without the presence of ulceration in the primary lesion (T1b).[4, 14]

Author Manuscript

Melanoma management guidelines published by the Australian Cancer Council, and the New Zealand Ministry of Health (now Cancer Control Agency/Te Aho o Te Kahu*) which are currently under review, recommend that SNB should be considered for patients with tumours less than 1mm thick when there are adverse pathological features such as ulceration or a mitotic rate greater than 1/mm^2.[3, 15] In addition, it is recommended that SNB be performed in a centre with expertise in the procedure, and at the same time as definitive wide local excision (WLE) because lymphatic mapping is likely to be inaccurate if conducted after WLE, preventing reliable SN identification.[15] Reported complication rates after SNB vary from 5.9-13.8% and are significantly lower than complication rates after completion or therapeutic lymphadenectomy. The most frequent complications are seromas and wound infections which are usually minor, easy to manage, and of limited duration.[16, 17]

SNB remains the gold standard for regional node assessment at the time of primary cutaneous melanoma presentation, compared to other less invasive technologies. For example, ultrasonography (US) detected only 6.6% of SN-positive patients when used in the screening phase of the second Multicentre Selective Lymphadenectomy Trial (MSLT-II). Computed tomography (CT) and positron emission tomography/computed tomography (PET/CT) scans have even lower sensitivity rates for detecting metastatic nodal disease that is not clinically apparent.[18] Nodal basin ultrasound can however be used for surveillance of patients who are eligible for but do not undergo SNB.[19] Patients should be made aware that there is a 15-20% chance that regional node metastasis is present, and that if this becomes clinically apparent, a full regional node clearance will be recommended.

The recent introduction of adjuvant systemic therapies (molecular targeted therapies and immunotherapies) has highlighted further advantages for SNB, besides providing purely prognostic information. The presence of lymph node involvement upstages the disease to stage III in 5% to 40% of patients who present with a T1b, T2, T3 or T4 melanoma,[19]

Author Manuscript

introducing the potential for those patients to be considered for adjuvant systemic therapy options.

Sentinel Node Risk Calculators

Predictive nomograms have been developed, using parameters other than thickness and ulceration of the primary melanoma, in order to better predict the potential risk of SNB-positivity. The original nomogram was developed at the Memorial Sloan Kettering Cancer Centre (MSKCC)[13] 15 years ago. Recently Melanoma Institute Australia (MIA) has published an updated online risk calculator which has a higher predictive accuracy.[20] This nomogram was developed using an Australian population of over 3000 melanoma patients, and took into account the additional parameters of patient age and tumour histological subtype. It was validated using data from 3496 patients treated at the MD Anderson Cancer Center in the United States (US). The calculator is easy to use and is freely available online (www.melanomarisk.org.au).[21] It has the potential to reduce the number of patients undergoing SNB and also enables clinicians to have a more informed discussion with patients about the likelihood of SN metastasis.

The Role of Completion Lymph Node Dissection

Until recently completion lymph node dissection (CLND) was the standard treatment recommendation for patients found to be SN-positive, based on evidence from the first Multicentre Selective Lymphadenectomy Trial (MSLT-I).[12] However, the approach to the management of patients with a positive SN has completely changed since the publication of two landmark clinical trials, MSLT-II and DeCOG-SLT, in both of which patients with a positive SN were randomised to immediate CLND or active surveillance.[22, 23] The results of these trials indicated that although immediate CLND reduced the risk of regional recurrence, it failed to improve MSS. The studies also found that CLND resulted in a substantial risk of

Author Manuscript

adverse events such as lymphoedema, with complication rates ranging from 20% to 60%.[19, 22, 23] At the present time, the default position for a patient with a positive SN is observation with regular ultrasound surveillance of the relevant node field as well as careful clinical review.[24]

Further Staging in Sentinel Node-positive Patients

Although CT and PET/CT scans may be useful in patients with clinically-evident stage III disease, it is uncommon for metastatic disease to be detected in patients who have no evidence of regional node metastases on physical examination.[25, 26] The long-term safety of CT and PET/CT scans is also a concern, particularly in younger patients, as cumulative radiation exposure from repeated CT and nuclear imaging tests may be associated with an increased risk of cancer.[27] The evidence in relation to staging tests for patients found to be SN-positive is outlined in the Australian and New Zealand Guidelines.[28, 29]

Management of Clinically-Evident Metastatic Disease in Regional Lymph Nodes

In the last decade, in spite of more widespread use of SNB, it has been reported that 50% of node-positive patients still present with palpable or imaging-detected regional disease (AJCC 8th ed Stage IIIB, IIIC, IIID).[30] The present management of this patient group is outlined in the Australian Melanoma Management guidelines.[31] In summary, the current standard of care is a complete regional node dissection; this offers regional disease control and in an older study was reported to have a potential impact on survival.[32] For the axilla it is recommended that patients have a dissection of levels I-III.[33] For the groin, patients should have a minimum of a superficial (sub-inguinal) node dissection, with a pelvic node dissection if imaging indicates iliac or obturator node involvement. There are some who recommend routine removal of the pelvic nodes with the inguinal nodes because of the risk of occult disease, but this risk is low, in the order of 9-18%.[34, 35] For the neck, a modified neck dissection, based on

Author Manuscript

the site of the primary melanoma, is acceptable, reserving removal of the sternocleidomastoid muscle, internal jugular vein and accessory nerve for when they are involved or for access to ensure complete resection of metastatic disease.[36] For each site, there are guidelines for an adequate dissection using the number of nodes removed as a surrogate for the quality of surgery.[37-39]

Management of In-Transit Metastases

In-transit metastases (ITMs) develop in 3-10% of patients who have been treated for a primary cutaneous melanoma.[40, 41] This form of loco-regional tumour spread rarely occurs in patients with other types of cutaneous malignancy. With melanoma, ITM presentation is heterogenous, varying from small single or a few deposits, to multiple deposits of varying size, commonly manifest initially as loco-regional disease only. Typically the disease consists of one or a few small deposits, with a slowly progressive course, but ITMs may grow rapidly in size and number, early or late in the disease process.[42-44] Where imaging, at ITM presentation, does not reveal distant disease, the AJCC 8th edition classifies patients into stages IIIB, IIIC and IIID dependent upon the regional nodal status and the primary tumour characteristics (Figure 1). Where the disease can be removed the patient should be considered for adjuvant therapy post-operatively.

When complete resection is not possible, and the disease is localised to a limb, there is a wide range of treatment options available; these have been summarised in recent reviews.[42-44] Patients will be offered systemic therapy when staging imaging at presentation with ITMs reveals distant metastatic disease (stage IV). More recently, patients are also offered systemic therapy for extensive loco-regional disease when loco-regional therapies have been unsuccessful or are not considered appropriate.

Author Manuscript

Because of the heterogeneity of this disease and the multiplicity of treatment options for patients, some of which are only available in specialist melanoma treatment centres, discussion of each patient with a multidisciplinary melanoma team, prior to treatment, is highly desirable, whenever possible.

Adjuvant Radiotherapy

A randomised trial, based in Australia and New Zealand, in patients with resected stage III melanoma with high-risk factors for local recurrence, compared observation with adjuvant radiotherapy (RT). RT significantly reduced regional recurrence, however, there was no survival benefit.[45] Presently, the Australian Melanoma Management Guidelines recommend consideration of adjuvant RT for patients with histopathological high-risk features such as extra-nodal tumour extension, following regional lymph node dissection, if potentially effective systemic therapy is not available.[46] Adjuvant RT may also be considered in selected patients with positive margins, after therapeutic regional dissection, where further surgical clearance is not feasible (e.g. parotid disease) and where further recurrence occurs after surgery. Whenever possible, this decision should be made in a multidisciplinary forum so that all options for therapy (surgery, RT, systemic therapy) can be discussed.[46]

Adjuvant Systemic Therapy for Resected Loco-regional Disease

Adjuvant systemic therapy aims to reduce disease recurrence and ultimately improve the potential for survival, by eliminating micro-metastatic disease following surgical resection of known loco-regional disease.[47] The last decade has witnessed a paradigm shift in the treatment of metastatic melanoma, with the advent of targeted therapies and immunotherapies. The immunotherapies focus non-specifically on the up-regulation of the host immune response or better recognition of the abnormal tissue by the host. The role of oncogenic molecular pathways in melanoma has led to the identification of mutations that

Author Manuscript

have become a target for therapies. Mutations of the BRAF gene are found in about 40% of advanced melanomas.[48] This genetic mutation causes spontaneous activation of the mitogen-activated protein kinase (MAPK) pathway that incorporates RAS/RAF/MEK/ERK genes. This molecular pathway has been identified as a therapeutic target in melanoma.

Role of Testing for the BRAF V600 Mutation - In Australia and New Zealand, BRAF V600 mutation testing is available for patients with stage III or IV metastatic cutaneous melanoma, to assess eligibility for the drugs targeting this mutation. If the patient's BRAF status is unknown, it is recommended that this be requested from the reporting pathologist, for all patients with a positive sentinel node or resected metastatic melanoma, so that timely discussions can be had in relation to adjuvant treatment options.

Bringing these systemic therapies, as indicated, into the post-surgical setting has been a logical step. The results of three important adjuvant therapy trials have recently been reported.[49-51]

Immunotherapies

Ipilimumab is a monoclonal antibody that activates the immune system by targeting CTLA-4 to block its effect and allow upregulation of T cells. Its effectiveness in stage III melanoma was demonstrated in a phase III trial[52, 53] comparing ipilimumab (10 mg/kg) to placebo, in patients with completely resected stage III disease. The overall survival rate was 65.4% at five years post resection in the treatment arm compared to 54.4% in the placebo arm (hazard ratio (HR) 0.72, 95% confidence interval (CI) 0.58 to 0.88; p-value < 0.001).[52, 53] Recently updated results report an ongoing RFS benefit of 8.3% and overall survival benefit of 8.7% after seven years follow-up.[54] The rate of adverse events was significant, however, with grade 3 to 5 related events reported in 54.1% of patients in the treatment arm, resulting in a third of

Author Manuscript

patients discontinuing treatment and five treatment-related deaths.[52-54] Ipilimumab is not currently approved as an adjuvant treatment in Australia or New Zealand.

Antibodies that block the interaction between programmed death 1 (PD-1) with programmed death ligand 1 (PD-L1) on the tumour cells have the potential to allow those cells to be more recognisable to a patient's T cells, and have also proved to be efficacious in the treatment of metastatic melanoma.[7] Two monoclonal antibodies targeting this checkpoint inhibitory pathway, pembrolizumab and nivolumab, have demonstrated effective and sustained impacts on recurrence-free survival (RFS) in patients with resected stage III melanoma in two separate phase III studies, CheckMate 238, and Keynote 054. Recent updates of these studies have been reported.[49, 50] The CheckMate 238 study used AJCC 7th edition staging and compared nivolumab to high dose ipilimumab, including patients who had complete resection of stage IIIB and IIIC disease as well as resected stage IV melanoma.[55, 49] After four years follow-up, RFS rates were 52% for nivolumab and 41% for ipilimumab (HR 0.71, 95% CI 0.60 to 0.86, p-value = 0.0003). There was a benefit in all subgroups.[49] At four years, there was a lower distant disease rate, although the overall survival rates were similar at 77.9% vs 76.6%, for the two treatment groups. Nivolumab was well tolerated, with only 14% of patients suffering grade 3 or 4 adverse events and no treatment-related deaths, compared to 45.9% of patients suffering grade 3 or 4 adverse events in the ipilimumab group, including two deaths due to an immune-related adverse event.[55]

The Keynote 054 trial compared pembrolizumab (200 mg every three weeks for 12 months) with placebo as adjuvant therapy in patients with resected, AJCC 7th edition stage IIIA, IIIB and IIIC melanoma. For SN positive patients, the tumour deposit needed to be 1 mm or greater in diameter. Patients receiving placebo who developed recurrence were allowed to cross-over to unblinded pembrolizumab for up to 24 months.[56] A higher 3-year RFS rate of 63.7% was observed in the pembrolizumab group compared with 44.1% for placebo (HR

Author Manuscript

0.56, 95% CI: 0.47 to 0.68; p < 0.001).[50] Treatment-related adverse events of grade 3 to 5 were reported in 14.7% of patients in the pembrolizumab group and 3.4% in the placebo group. The impact was greatest in patients with AJCC stages IIIB and IIIC. When the results were re-analysed using AJCC 8th edition staging the number of patients in the Stage IIIA group reduced from 152 to 82 patients, with the difference in RFS at three years being 82.6% in the treatment group and 67.4% in patients who had placebo (p=0.063). Given the in-built cross-over, longer term follow-up will be needed to address the important question of whether pembrolizumab is more effective and gives an equivalent overall survival, as an adjuvant or as first line therapy if metastatic disease develops.[50] Due to the improvements in RFS, PD-1 inhibitor adjuvant treatment, funded by the Pharmaceutical Benefits Scheme (PBS), is now available in Australia, for patients following resection of stage III B/C/D melanoma. Nivolumab is available as adjuvant therapy for stage IV patients, where all disease has been resected (Table 1).[47] Pharmac in New Zealand has to date declined to fund adjuvant anti-PD1 therapies based on RFS alone, regarding overall survival as the criterion by which success should be measured.

Molecular Targeted Therapies

A focus on the MAPK pathway led to the development of vemurafenib, dabrafenib and encorafenib, selective inhibitors of the BRAF V600-mutated kinase, and trametinib, cobimetinib and binimetinib, inhibitors of the downstream MEK kinase.[57] BRAF and MEK inhibitors used together enhance the inhibition of the MAPK signalling pathway, which has led to improved outcomes for patients with metastatic BRAF-mutant melanoma.[57]

The Phase III COMBI-AD clinical trial explored the combination of dabrafenib and trametinib in patients with completely resected AJCC 7th edition stage IIIA (limited to lymph-node metastasis of >1 mm), IIIB and IIIC melanoma with BRAF V600E or V600K genetic mutations. Patients were randomised to receive either dabrafenib / trametinib or

Author Manuscript

placebo for 12 months.[58, 51] After five years follow-up, the RFS rate was 52% in the combination treatment arm compared to 36% in the placebo arm, with a HR for relapse or death of 0.51 (95% CI: 0.42 to 0.61). The overall survival favoured dabrafenib and trametinib with a HR of 0.57 at the first interim analysis, however, the p-value did not meet the pre-specified significance value. The overall survival results will not be re-analysed until the trial meets its primary end-points.[58, 59] At the primary analysis, grade 3 or 4 adverse events were 41% in the combination arm and 14% in the placebo arm. The combination treatment was stopped early in 26% of patients due to an adverse event, however, there were no treatment-related deaths.[58] There was no difference in the long term incidence of adverse events,[51] indicating that the short term effects of these events occur while on treatment, which is different from the potential long term, permanent effects that may occur following immunotherapy, albeit in a small percentage of patients.[47] Presently, in Australia, this form of therapy is available as adjuvant therapy for patients with BRAF V600 mutation-positive stage IIIB-D disease (Table 1), but is not available in New Zealand (Table 2).

Vemurafenib, an alternative first-generation BRAF inhibitor, was compared to placebo in the BRIM8 Phase III study in patients who had resected stage IIC and stage III melanoma and a BRAF V600E mutation. The results did not show a significant difference in disease-free survival,[60] which may have been due to the statistical design as well as the likely requirement for dual agent therapy for the successful blockade of the MAP kinase pathway.[61]

Stage IIIA disease and adjuvant therapy: The clinical trials discussed above classified all tumours using the 7th edition of the AJCC staging system. Post-hoc analysis of the COMBI-AD and Keynote 054 studies was undertaken where patients were reclassified according to the AJCC 8th edition to assess whether the improvement of RFS remained consistent across all subgroups, when compared to placebo. Ten percent of patients enrolled into the COMBI-AD trial and 8% of patients in the Keynote 054 trial had stage IIIA (micro-metastatic) disease

Author Manuscript

according to the AJCC 8th edition.[62, 63] Thus for this stage of disease, in Australia, the Pharmaceutical Benefits Advisory Committee (PBAC) assessment was that the impact on RFS was inadequate to offer government funding for these therapies. As previously stated, Pharmac in New Zealand awaits the overall survival impact before considering funding for these therapies. Therefore, outside of the supported funding pathways, recommendations for adjuvant therapy for patients with stage IIIA disease should be carefully considered, particularly adjuvant immunotherapy, which has the potential to cause long-term immune-related side effects.[47] Close clinical and imaging review at regular intervals is recommended for these patients, whether they receive adjuvant drug therapy or not.

Multidisciplinary Care in the Treatment of Melanoma

Given that the initial care of patients with high-risk primary cutaneous melanoma is likely to be undertaken by a surgeon, it is important that he or she understands the optimal care pathways for delivering consistent, evidence-based care.[64] Staging serves as the basis for discussion within multidisciplinary teams, and also informs and educates patients on their disease pathology, biology and prognosis.[4] For patients with stage III or IV melanoma, a fully integrated multidisciplinary model of care is recommended whenever possible, involving all specialists (including surgical oncologists, medical oncologists, radiation oncologists) to meet and discuss the best treatment options and formulate a personalised care plan.[65]

Selection of a specific adjuvant systemic therapy for patients with resected advanced loco-regional melanoma depends on many factors, including risk of recurrence, clinical benefit, potential toxicities, BRAF mutation status, patient preferences, patient age and comorbidities. As well, the current PBS restrictions regarding the use of immunotherapies and targeted therapies in the adjuvant setting mandates that if a patient recurs on or within six months of their last dose of adjuvant drug therapy, the patient is unable to ever have funded access to the same class of drug in later lines of therapy, including systemic metastatic disease. Thus, it

Author Manuscript

is recommended that these patients should discuss the possible benefits and potential toxicities of adjuvant systemic therapy with a medical oncologist experienced with these therapies, preferably one who is part of a multidisciplinary melanoma management team.

Table 1 details the adjuvant systemic therapies that are now approved by the Australian Therapeutic Goods Administration (TGA) and are listed for reimbursement on the Australian PBS. Table 2 shows the situation regarding funded adjuvant treatments in New Zealand. Figure 2 shows a care pathway algorithm for patients with stage I to stage III melanoma.

Table 3 outlines the changes that have occurred with the regional management of cutaneous melanoma concurrently with publication of the new AJCC 8th edition staging system.

The Future Treatment of Loco-regional Melanoma

Further trials are currently in progress to investigate combination therapies and to determine if adjuvant therapy may be beneficial in earlier disease stages. Studies exploring the role of adjuvant PD-1 therapy in stage IIB/C melanoma are ongoing.

The positive impact of adjuvant therapy in patients with clinical stage III (IIIB-D) disease and resected stage IV disease has led to trials assessing the use of these therapies as neoadjuvant therapies (i.e. as first line treatment, followed by surgery).[66, 67] Neoadjuvant therapy allows assessment of tumour response to the treatment, providing patients with important prognostic information at the time of their surgery, based on their pathologic response. The ongoing trials will seek to identify markers of response, which may allow decision making in the future with respect to the extent of surgery, and the role of further post-operative therapy.[66] At present, for patients with clinically-evident stage III nodal disease, it is still recommended that a complete regional node resection be performed to achieve local control before the commencement of systemic therapy. Alternatively, for a

Author Manuscript

subset of patients with advanced stage III disease, referral to a centre participating in neoadjuvant trials may be considered.

Conclusions

Adequate local surgery is still the standard treatment of primary cutaneous melanoma and the delivery of consistent, evidence-based care for those with cutaneous melanoma primarily resides with the treating surgeon, in the first instance. Staging according to the recent AJCC 8th edition offers clinicians and patients a better perspective on prognosis for each stage designation and guides management. SNB plays an important role in the treatment of primary cutaneous melanomas by establishing precise pathological staging and indicating prognostic outcomes; it identifies a group of patients with high-risk primary melanomas who have micro-metastatic disease in regional nodes, who may benefit from adjuvant systemic therapy.

Adjuvant immunotherapy or targeted therapy is also an option for patients with clinically-evident nodal disease who have had regional nodal clearance, and for patients with resected stage IV disease (nivolumab only). Targeted therapy is only available for patients whose tumour is BRAF-mutant. The rapidly evolving advances that have occurred and continue to be made in the treatment of patients with cutaneous melanoma highlight the importance of multidisciplinary management for patients with this disease.

Author Manuscript

Acknowledgments

The authors thank Theresa Wade of WriteSource Medical Pty Ltd, Sydney, Australia, for providing medical writing support by developing the first draft of the manuscript based on input from co-authors during an initial teleconference, with subsequent finalisation of the manuscript after all authors had had the opportunity to comment and edit subsequent versions. The medical writing support was funded by Novartis, Sydney, Australia in accordance with Good Publication Practice (GPP3) guidelines.

Disclosure Statements

BMS has no disclosures to declare.

RPMS has received honoraria for advisory board participation from MSD, Novartis and Qbiotics and speaking honoraria from BMS

DEG has been on advisory boards for Amgen, Q Biotics and Bayer.

RCWM has received honoraria for advisory board participation from MSD (NZ).

VA has been on advisory boards for BMS, MSD, Merck, Novartis, Pierre Fabre, Roche and Nektar, has received speaker fees for BMS, MSD, Merck, Novartis, Roche, and travel support from BMS and Oncosec.

AH has been on advisory boards for BMS, MSD, Novartis, Qbiotics and Pierre-Fabre

RRT has been on advisory boards for Novartis, has received speaker fees from BMS, Novartis, Roche, MSD, AstraZeneca.

JFT has received honoraria for advisory board participation from BMS Australia, MSD Australia, GSK and Provectus Inc, and travel support from GSK and Provectus Inc.

Author Manuscript

References

[1] Whiteman DC, Green AC, Olsen CM. The Growing Burden of Invasive Melanoma: Projections of Incidence Rates and Numbers of New Cases in Six Susceptible Populations through 2031. *J Invest Dermatol*. 2016; 136:1161-71.

[2] Cancer Council Australia Melanoma Guidelines Working Party. *Clinical practice guidelines for the diagnosis and management of melanoma*. Cancer Council Australia, [cited 16 November 2020].Available from: https://wiki.cancer.org.au/australia/Guidelines:Melanoma

[3] National Melanoma Tumour Standards Working Group. Standards of Service Provision for Melanoma Patients in New Zealand – Provisional. Wellington, New Zealand: Ministry of Health, 2013.

[4] Gershenwald JE, Scolyer RA, Hess KR, et al. Melanoma staging: Evidence-based changes in the American Joint Committee on Cancer eighth edition cancer staging manual. *CA Cancer J Clin*. 2017; 67:472-92.

[5] McKean MA, Amaria RN. Multidisciplinary treatment strategies in high-risk resectable melanoma: Role of adjuvant and neoadjuvant therapy. *Cancer Treat Rev*. 2018; 70:144-53.

[6] Wolchok JD, Chiarion-Sileni V, Gonzalez R, et al. Overall Survival with Combined Nivolumab and Ipilimumab in Advanced Melanoma. *N Engl J Med*. 2017; 377:1345-56.

[7] Larkin J, Chiarion-Sileni V, Gonzalez R, et al. Five-Year Survival with Combined Nivolumab and Ipilimumab in Advanced Melanoma. *N Engl J Med*. 2019; 381:1535-46.

[8] Long GV, Flaherty KT, Stroyakovskiy D, et al. Dabrafenib plus trametinib versus dabrafenib monotherapy in patients with metastatic BRAF V600E/K-mutant melanoma: long-term survival and safety analysis of a phase 3 study. *Ann Oncol*. 2017; 28:1631-9.

[9] Grob JJ, Amonkar MM, Karaszewska B, et al. Comparison of dabrafenib and trametinib combination therapy with vemurafenib monotherapy on health-related quality of life in patients with unresectable or metastatic cutaneous BRAF Val600-mutation-positive melanoma (COMBI-v): results of a phase 3, open-label, randomised trial. *Lancet Oncol*. 2015; 16:1389-98.

[10] Balch CM, Gershenwald JE, Soong SJ, et al. Final version of 2009 AJCC melanoma staging and classification. *J Clin Oncol*. 2009; 27:6199-206.

[11] Gershenwald JE, Thompson W, Mansfield PF, et al. Multi-institutional melanoma lymphatic mapping experience: the prognostic value of sentinel lymph node status in 612 stage I or II melanoma patients. *J Clin Oncol*. 1999; 17:976-83.

[12] Morton DL, Thompson JF, Cochran AJ, et al. Final trial report of sentinel-node biopsy versus nodal observation in melanoma. *N Engl J Med*. 2014; 370:599-609.

Author Manuscript

[13] Wong SL, Kattan MW, McMasters KM, Coit DG. A nomogram that predicts the presence of sentinel node metastasis in melanoma with better discrimination than the American Joint Committee on Cancer staging system. *Ann Surg Oncol*. 2005; 12:282-8.

[14] Egger ME, Stevenson M, Bhutiani N, et al. Should Sentinel Lymph Node Biopsy Be Performed for All T1b Melanomas in the New 8th Edition American Joint Committee on Cancer Staging System? *J Am Coll Surg*. 2019; 228:466-72.

[15] Gyorki D, Teddy L, Barbour A, Mar V, Sandhu S, Hanikeri M. When is a sentinel node biopsy indicated? *In: Cancer Council Australia Melanoma Guidelines Working Party Clinical practice guidelines for the diagnosis and management of melanoma Cancer Council Australia*. Sydney: Cancer Council Australia, 2020.

[16] Roaten JB, Pearlman N, Gonzalez R, Gonzalez R, McCarter MD. Identifying risk factors for complications following sentinel lymph node biopsy for melanoma. *Arch Surg*. 2005; 140:85-9.

[17] Kretschmer L, Thoms KM, Peeters S, Haenssle H, Bertsch HP, Emmert S. Postoperative morbidity of lymph node excision for cutaneous melanoma-sentinel lymphonodectomy versus complete regional lymph node dissection. *Melanoma Res*. 2008; 18:16-21.

[18] Thompson JF, Haydu LE, Uren RF, et al. Preoperative Ultrasound Assessment of Regional Lymph Nodes in Melanoma Patients Does not Provide Reliable Nodal Staging: Results from a Large Multicenter Trial. *Ann Surg*. 2019.

[19] National Comprehensive Cancer Network. NCCN Guidelines. Cutaneous Melanoma, Version 4., 2020.

[20] Lo SN, Ma J, Scolyer RA, et al. Improved Risk Prediction Calculator for Sentinel Node Positivity in Patients With Melanoma: The Melanoma Institute Australia Nomogram. *J Clin Oncol*. 2020; 38:2719-27.

[21] Melanoma Institute Australia. *Risk Prediction Tools*. [cited 14 October 2020].Available from: www.melanomarisk.org.au.

[22] Leiter U, Stadler R, Mauch C, et al. Complete lymph node dissection versus no dissection in patients with sentinel lymph node biopsy positive melanoma (DeCOG-SLT): a multicentre, randomised, phase 3 trial. *The Lancet Oncology*. 2016; 17:757-67.

[23] Faries MB, Thompson JF, Cochran AJ, et al. Completion Dissection or Observation for Sentinel-Node Metastasis in Melanoma. *N Engl J Med*. 2017; 376:2211-22.

[24] Spillane A, McCormack C, Howle J, Smithers M, Gyorki D, Bruscino-Raiola F. Should all patients with a positive sentinel lymph node biopsy have a complete node dissection? . *In Cancer Council Australia Melanoma Guidelines Working Party Clinical practice guidelines for the diagnosis and management of melanoma*. Sydney: Cancer Council Australia, 2018.

Author Manuscript

[25] Nijhuis AAG, Dieng M, Khanna N, et al. False-Positive Results and Incidental Findings with Annual CT or PET/CT Surveillance in Asymptomatic Patients with Resected Stage III Melanoma. *Ann Surg Oncol*. 2019; 26:1860-8.

[26] Lim W-Y, Turner RM, Morton RL, et al. Use of shared care and routine tests in follow-up after treatment for localised cutaneous melanoma. *BMC Health Serv Res*. 2018; 18:477.

[27] Martin A, Einstein A, Saw RPM, et al. Radiation risk from computed tomography surveillance imaging in asymptomatic adults treated for stage III melanoma: A simulation modelling study. *World Congress of Melanoma*. Brisbane, 2017.

[28] Saw R, Menzies A, McArthur G, Spillane J, Haydon A. What investigations should be performed when in transit and/or regional node disease (Stage III melanoma) is diagnosed? *In Cancer Council Australia Melanoma Guidelines Working Party Clinical practice guidelines for the diagnosis and management of melanoma*. Sydney: Cancer Council Australia, 2018.

[29] Franci V, Sehji T, Barnett MH, Martin RCW. Radiological imaging of Melanoma: A review to guide clinical practice in New Zealand. *New Zealand Medical Journal*. In Press.

[30] Spillane AJ, Pasquali S, Haydu LE, Thompson JF. Patterns of recurrence and survival after lymphadenectomy in melanoma patients: clarifying the effects of timing of surgery and lymph node tumor burden. *Ann Surg Oncol*. 2014; 21:292-9.

[31] Henderson M, Spillane J, Hughes TM, Spillane A, Smithers M. What is the appropriate treatment for macroscopic (i.e. detectable clinically or by ultrasound) nodal metastasis? . *In Cancer Council Australia Melanoma Guidelines Working Party Clinical practice guidelines for the diagnosis and management of melanoma*. Sydney: Cancer Council Australia, 2018.

[32] Balch CM, Durant JR, Bartolucci AA. The impact of surgical quality control in multi-institutional group trials involving adjuvant cancer treatments. *Ann Surg*. 1983; 198:164-7.

[33] Kretschmer L, Preusser KP. Standardized axillary lymphadenectomy improves local control but not survival in patients with palpable lymph node metastases of cutaneous malignant melanoma. *Langenbecks Arch Surg*. 2001; 386:418-25.

[34] Allan CP, Hayes AJ, Thomas JM. Ilioinguinal lymph node dissection for palpable metastatic melanoma to the groin. *ANZ J Surg*. 2008; 78:982-6.

[35] West CA, Saleh DB, Peach H. Combined clearance of pelvic and superficial nodes for clinical groin melanoma. *J Plast Reconstr Aesthet Surg*. 2014; 67:1711-8.

[36] Supriya M, Narasimhan V, Henderson MA, Sizeland A. Managing regional metastasis in patients with cutaneous head and neck melanoma - is selective neck dissection appropriate? *Am J Otolaryngol*. 2014; 35:610-6.

[37] Rossi CR, Mozzillo N, Maurichi A, et al. Number of excised lymph nodes as a quality assurance measure for lymphadenectomy in melanoma. *JAMA Surg*. 2014; 149:700-6.

Author Manuscript

[38] Spillane AJ, Cheung BL, Winstanley J, Thompson JF. Lymph node ratio provides prognostic information in addition to american joint committee on cancer N stage in patients with melanoma, even if quality of surgery is standardized. *Ann Surg*. 2011; 253:109-15.

[39] Nahab F, Harman R, Martin R. Quality measures in cervical lymphadenectomy for cutaneous malignancy by head and neck trained general surgeons. . *New Zealand Medical Journal*. 2020; 133:50-60.

[40] Read RL, Haydu L, Saw RPM, et al. In-transit Melanoma Metastases: Incidence, Prognosis, and the Role of Lymphadenectomy. *Ann Surg Oncol*. 2014; 22:475-81.

[41] Sloot S, Speijers MJ, Bastiaannet E, Hoekstra HJ. Is there a relation between type of primary melanoma treatment and the development of intralymphatic metastasis? A review of the literature. *Cancer Treat Rev*. 2016; 45:120-8.

[42] Thompson JF. Local and regional therapies for melanoma: many arrows in the quiver. *J Surg Oncol*. 2014; 109:295.

[43] Thompson JF, Mozzillo N, Ross MI. Local Melanoma Recurrence, Satellitosis, and In-transit Metastasis: Incidence, Outcomes, and Selection of Treatment Options. In: Balch CM, Atkins MB, Garbe C, Gershenwald JE, Halpern AC, Kirkwood JM, et al., (eds) *Cutaneous Melanoma*. Cham: Springer International Publishing, 2020; 867-94.

[44] Read T, Lonne M, Sparks DS, et al. A systematic review and meta-analysis of locoregional treatments for in-transit melanoma. *J Surg Oncol*. 2019; 119:887-96.

[45] Henderson MA, Burmeister BH, Ainslie J, et al. Adjuvant lymph-node field radiotherapy versus observation only in patients with melanoma at high risk of further lymph-node field relapse after lymphadenectomy (ANZMTG 01.02/TROG 02.01): 6-year follow-up of a phase 3, randomised controlled trial. *The Lancet Oncology*. 2015; 16:1049-60.

[46] Stevens G, Taing C, Burmeister B, Fogarty G, Henderson M. Is adjuvant radiotherapy of value following resection of involved lymph nodes? *In: Cancer Council Australia Melanoma Guidelines Working Party Clinical practice guidelines for the diagnosis and management of melanoma* Sydney: Cancer Council Australia, 2018.

[47] Samuel E, Moore M, Voskoboynik M, Shackleton M, Haydon A. An update on adjuvant systemic therapies in melanoma. *Melanoma Manag*. 2019; 6:MMT28.

[48] Cheng L, Lopez-Beltran A, Massari F, MacLennan GT, Montironi R. Molecular testing for BRAF mutations to inform melanoma treatment decisions: a move toward precision medicine. *Mod Pathol*. 2018; 31:24-38.

[49] Ascierto PA, Del Vecchio M, Mandalá M, et al. Adjuvant nivolumab versus ipilimumab in resected stage IIIB-C and stage IV melanoma (CheckMate 238): 4-year results from a multicentre, double-blind, randomised, controlled, phase 3 trial. *The Lancet Oncology*. 2020; 21:1465-77.

[50] Eggermont AMM, Blank CU, Mandala M, et al. Longer Follow-Up Confirms Recurrence-Free Survival Benefit of Adjuvant Pembrolizumab in High-Risk Stage III

Author Manuscript

Melanoma: Updated Results From the EORTC 1325-MG/KEYNOTE-054 Trial. *J Clin Oncol*. 2020:JCO2002110.

[51] Dummer R, Hauschild A, Santinami M, et al. Five-Year Analysis of Adjuvant Dabrafenib plus Trametinib in Stage III Melanoma. *N Engl J Med*. 2020; 383:1139-48.

[52] Eggermont AMM, Chiarion-Sileni V, Grob J-J, et al. Adjuvant ipilimumab versus placebo after complete resection of high-risk stage III melanoma (EORTC 18071): a randomised, double-blind, phase 3 trial. *The Lancet Oncology*. 2015; 16:522-30.

[53] Eggermont AMM, Chiarion-Sileni V, Grob J-J, et al. Prolonged Survival in Stage III Melanoma with Ipilimumab Adjuvant Therapy. *New England Journal of Medicine*. 2016; 375:1845-55.

[54] Eggermont AMM, Chiarion-Sileni V, Grob JJ, et al. Ipilimumab versus placebo after complete resection of stage III melanoma: Long-term follow-up results the EORTC 18071 double-blind phase 3 randomized trial. *J Clin Oncol*. 2019; 37:2512-.

[55] Weber J, Mandala M, Del Vecchio M, et al. Adjuvant Nivolumab versus Ipilimumab in Resected Stage III or IV Melanoma. *N Engl J Med*. 2017; 377:1824-35.

[56] Eggermont AMM, Blank CU, Mandala M, et al. Adjuvant Pembrolizumab versus Placebo in Resected Stage III Melanoma. *N Engl J Med*. 2018; 378:1789-801.

[57] Cohen JV, Sullivan RJ. Developments in the Space of New MAPK Pathway Inhibitors for BRAF-Mutant Melanoma. *Clin Cancer Res*. 2019; 25:5735-42.

[58] Long GV, Hauschild A, Santinami M, et al. Adjuvant Dabrafenib plus Trametinib in Stage IIIBRAF-Mutated Melanoma. *New England Journal of Medicine*. 2017; 377:1813-23.

[59] Hauschild A, Dummer R, Schadendorf D, et al. Longer Follow-Up Confirms Relapse-Free Survival Benefit With Adjuvant Dabrafenib Plus Trametinib in Patients With Resected BRAF V600-Mutant Stage III Melanoma. *J Clin Oncol*. 2018; 36:3441-9.

[60] Maio M, Lewis K, Demidov L, et al. Adjuvant vemurafenib in resected, BRAF V600 mutation-positive melanoma (BRIM8): a randomised, double-blind, placebo-controlled, multicentre, phase 3 trial. *The Lancet Oncology*. 2018; 19:510-20.

[61] Bhave P, Haydon A. Treatment of High Risk Resected Melanoma in Australia: Current Landscape and Practises. *Australas J Dermatol*. 2020; 61:203-9.

[62] Eggermont AMM, Blank CU, Mandala M, et al. Prognostic and predictive value of AJCC-8 staging in the phase III EORTC1325/KEYNOTE-054 trial of pembrolizumab vs placebo in resected high-risk stage III melanoma. *Eur J Cancer*. 2019; 116:148-57.

[63] Larkin JMG, Hauschild A, Santinami M, et al. Dabrafenib plus trametinib (D + T) as adjuvant treatment of resected BRAF-mutant stage III melanoma: Findings from the COMBI-AD trial analyzed based on AJCC 8 classification. *J Clin Oncol*. 2018; 36:9591-.

[64] Reeves ME, Coit DG. Melanoma. *Surg Clin North Am*. 2000; 80:581-601.

Author Manuscript

[65] Thompson JF, Williams G, Taing C. Is multidisciplinary care of value in the management of melanoma? . *In: Cancer Council Australia Melanoma Guidelines Working Party Clinical practice guidelines for the diagnosis and management of melanoma* Sydney: Cancer Council Australia. , 2019.

[66] Lee AY, Brady MS. Neoadjuvant immunotherapy for melanoma. *J Surg Oncol*. 2020; n/a.

[67] Amaria RN, Menzies AM, Burton EM, et al. Neoadjuvant systemic therapy in melanoma: recommendations of the International Neoadjuvant Melanoma Consortium. *Lancet Oncol*. 2019; 20:e378-e89.

[68] Australian Government Department of Health. *Pharmaceutical Benefits Scheme*. [cited.Available from: http://www.pbs.gov.au/pbs/home

Author Manuscript

Table 1: Australian PBS-funded adjuvant post-operative systemic therapies for melanoma[68]

Therapy	**Resected Stage**	**Key Clinical Criteria**
Dabrafenib and Trametinib	IIIB, IIIC, or IIID	• The condition must be positive for a BRAF V600 mutation • Patient must have a WHO performance status of 1 or less • Patient must be receiving PBS-subsidised trametinib and dabrafenib concomitantly for this condition • Patient must not have received prior PBS treatment for this condition • Treatment must commence within 12 weeks of complete resection
Nivolumab	IIIB, IIIC, IIID or IV	• Patient must have a WHO performance status of 1 or less • The treatment must be the sole PBS-subsidised therapy for this condition • Patient must not have received prior PBS treatment for this condition • Treatment must commence within 12 weeks of complete resection
Pembrolizumab	IIIB, IIIC, or IIID	• Patient must have a WHO performance status of 1 or less • The treatment must be the sole PBS-subsidised therapy for this condition • Patient must not have received prior PBS treatment for this condition • Treatment must commence within 12 weeks of complete resection

Abbreviations PBS: Pharmaceutical Benefits Scheme; WHO: World Health organisation

Author Manuscript

Table 2: New Zealand Pharmac-funded therapies for melanoma

Therapy	**Resected melanoma**	**Unresected melanoma**
Dabrafenib/Trametinib	Not funded†	Not funded†
Nivolumab	Not funded‡	Funded for unresectable Stage III and IV melanoma
Pembrolizumab	Not funded‡	Funded for unresectable Stage III and IV melanoma

†Available if self-funded by patients (approximately NZ$60,000 for 1 year)

‡Available if self-funded by patients (approximately NZ$120,000 for 1 year)

Table 3: Summary of Recent Changes to Regional Management of Cutaneous Melanoma

	Previous management	Current management
AJCC Staging	7th Edition	8th Edition†
SNB	Discuss SNB if >1mm melanoma or 0.75-1mm with adverse features	Discuss SNB if >1mm melanoma or 0.8-1mm with adverse features
Positive SN	Completion dissection	Ultrasound monitoring of positive SN field Discuss adjuvant drug therapy (stage IIIB,C,D)
Palpable nodal involvement or surgically resectable in-transit disease	Therapeutic dissection / complete resection of in-transit disease	Therapeutic dissection / complete resection of in-transit disease Discuss adjuvant drug therapy (stage IIIB,C,D)

†Patients being considered for adjuvant therapy should have BRAF testing which can be performed on the primary lesion or the positive node.
Abbreviations SNB: sentinel node biopsy

Author Manuscript

Figure 1: AJCC 8th edition staging system for stage III melanoma†

Author Manuscript

Figure 2. Care pathway algorithm for patients with primary cutaneous melanoma

†

Author Manuscript

Author Manuscript

AJCC Eighth Edition
Melanoma Stage III Subgroups

N Category	T Category								
	T0	T1a	T1b	T2a	T2b	T3a	T3b	T4a	T4b
N1a	N/A	A	A	A	B	B	C	C	C
N1b	B	B	B	B	B	B	C	C	C
N1c	B	B	B	B	B	B	C	C	C
N2a	N/A	A	A	A	B	B	C	C	C
N2b	C	B	B	B	B	B	C	C	C
N2c	C	C	C	C	C	C	C	C	C
N3a	N/A	C	C	C	C	C	C	C	D
N3b	C	C	C	C	C	C	C	C	D
N3c	C	C	C	C	C	C	C	C	D

Instructions
(1) Select patient's N category at left chart.
(2) Select patient's T category at top of chart.
(3) Note letter at the intersection of T&N on grid.
(4) Determine patient's AJCC stage using legend.

N/A=Not assigned

Legend

A	Stage IIIA
B	Stage IIIB
C	Stage IIIC
D	Stage IIID

†Copied from Gershenwald JE, Scolyer RA, Hess KR, et al. Melanoma staging: Evidence-based changes in the American Joint Committee on Cancer eighth edition cancer staging manual. *CA Cancer J Clin*. 2017; 67:472-92 with the permission of John Wiley and Sons.

Abbreviations:

Definition of Primary Tumour (T)			Definition of Regional Lymph Node (N)		In-transit, Satellite, and/or Microsatellite Metastasis
T0	No melanoma cells at primary site		N1a	One clinically occult (detected by SLN biopsy)	No
T1a	<0.8 mm	Without ulceration	N1b	One clinically detected	No
T1b	<0.8 mm	With ulceration	N1c	No regional lymph node disease	Yes
T2a	>1.0-2.0 mm	Without ulceration	N2a	Two or three clinically occult (detected by SLN biopsy)	No
T2b	>1.0-2.0 mm	With ulceration	N2b	Two or three, at least one of which was clinically detected	No
T3a	>2.0-4.0 mm	Without ulceration	N2c	One clinically occult, or one clinically detected	Yes
T3b	>2.0-4.0 mm	With ulceration	N3a	Four or more clinically occult (i.e. detected by SLN biopsy)	No
T4a	>4.0 mm	Without ulceration	N3b	Four or more, at least one or which was clinically detected, or the presence of any number of matted nodes	No
T4b	>4.0 mm	With ulceration	N3c	Two or more clinically occult or clinically detected	Yes

Author Manuscript

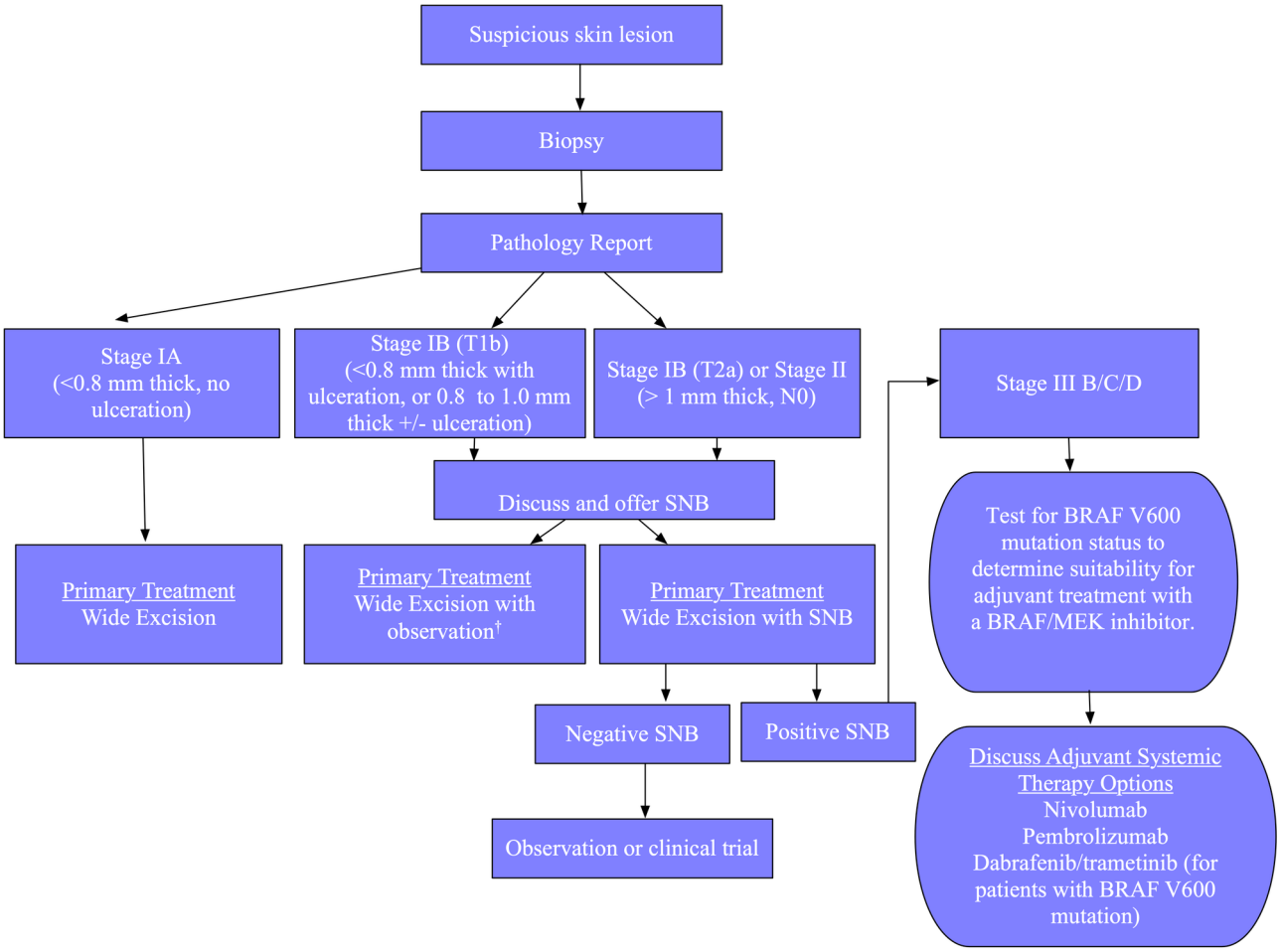

†Observation may include SN identification with pre-operative lymphoscintigraphy, then directed ultrasound follow-up of those SNs or, if no pre-operative lymphoscintigraphy, regular ultrasound surveillance of the entire draining node field.

Abbreviations SNB: sentinel node biopsy

ANS_17051_ANS_17051_Figure 2. Melanoma Flow diagram Final 12 Jan 2021.tiff

Author Manuscript

Title: Contemporary management of locoregionally advanced melanoma in Australia and New Zealand and the role of adjuvant systemic therapy.

Running Title: Regional metastatic melanoma management

Authors:

B Mark Smithers (MBBS, FRACS)[1]

Robyn PM Saw (MBBS, MS, FRACS)[2]

David E Gyorki (MBBS, MD, FRACS)[3]

Richard CW Martin (MBChB, FRACS, ChM)[4]

Victoria Atkinson (MBBS, FRACP)[1]

Andrew Haydon (MBBS, FRACP)[5]

Rachel Roberts-Thomson (MBBS, FRACP)[6]

John F Thompson (MBBS, MD, FRACS)[2]

Author Affiliations

1. Queensland Melanoma Project, Faculty of Medicine, University of Queensland and Princess Alexandra Hospital, Brisbane, QLD, Australia

2. Melanoma Institute Australia, The University of Sydney and Royal Prince Alfred Hospital, Sydney, NSW, Australia

3. Peter MacCallum Cancer Centre, Melbourne, VIC, Australia

4. New Zealand Melanoma Unit, Takapuna, Auckland, New Zealand

5. Alfred Hospital, Melbourne, VIC, Australia

6. The Queen Elizabeth Hospital, Adelaide, SA, Australia

Corresponding author's full contact details:

Name: Professor Mark Smithers

Address: The University of Queensland, Brisbane, QLD 4072

Phone: 0721765309

Email: m.smithers@uq.edu.au

Number of Figures and Tables: 2 Figures and 3 Tables

Abstract Word Count: 196

Main text word Count: 4, 842

Author Manuscript