



Minerva Access is the Institutional Repository of The University of Melbourne

Author/s:

Bokhari, L;Sinclair, R

Title:

Treatment of alopecia universalis with topical Janus kinase inhibitors – a double blind, placebo, and active controlled pilot study

Date:

2018-12-01

Citation:

Bokhari, L. & Sinclair, R. (2018). Treatment of alopecia universalis with topical Janus kinase inhibitors – a double blind, placebo, and active controlled pilot study. *International Journal of Dermatology*, 57 (12), pp.1464-1470. <https://doi.org/10.1111/ijd.14192>.

Persistent Link:

<https://hdl.handle.net/11343/284538>

PROF. RODNEY SINCLAIR (Orcid ID : 0000-0001-6751-1428)

Article type : Report

Title: Treatment of alopecia universalis with topical Janus Kinase inhibitors – a double blind, placebo and active controlled pilot study

Short title: Treatment of Alopecia Areata with topical JAK inhibitors.

Keywords: Tofacitinib, ruxolitinib, clobetasol, JAK, JAK inhibitors, alopecia areata

Authors:

Laita Bokhari (MPhil Med)

Rodney Sinclair (MBBS, MD, FACD)

Corresponding author:

Laita Bokhari

2 Wellington Parade

East Melbourne, VIC 3002

Email: laita.bokhari@sinclairdermatology.com.au

This is the author manuscript accepted for publication and has undergone full peer review but has not been through the copyediting, typesetting, pagination and proofreading process, which may lead to differences between this version and the [Version of Record](#). Please cite this article as [doi: 10.1111/ijd.14192](https://doi.org/10.1111/ijd.14192)

This article is protected by copyright. All rights reserved

Funding Source:

A research project grant from the Australia Alopecia Areata Foundation

Conflicts of interest: None

Manuscript word count: 1853 (excluding abstract)

Table count: 1

Figure count: 5

Abstract

Background: Oral Janus Kinase (JAK) inhibitors are currently being investigated in phase II and phase III clinical trials for several inflammatory skin diseases including alopecia areata (AA). Topical JAK inhibitors have been investigated in atopic dermatitis, psoriasis and alopecia areata. While a number of case series using topical JAK inhibitors in AA have been published, to-date there have been no randomized controlled clinical trials.

Methods: We conducted a phase 1, 28-week prospective, placebo-controlled, double-blind study in patients with alopecia universalis investigating hair regrowth with 2 topical JAK inhibitors, 2% tofacitinib and 1% Ruxolitinib. Topical clobetasol dipropionate 0.005% was the active comparator while vehicle was used as the placebo control. 16 patients were recruited for the study.

Results: Six patients demonstrated partial hair regrowth in areas treated with 2% tofacitinib ointment applied twice daily. Five patients demonstrated partial hair regrowth in the areas treated with 1% Ruxolitinib ointment. Ten patients demonstrated partial hair regrowth in the areas treated with clobetasol dipropionate 0.05% ointment. No regrowth was observed in the placebo treated area. Interestingly, generalised hair regrowth was observed in two patients. One patient had 100% regrowth over his entire scalp and eyebrows by week 24 but relapsed after 12 weeks. A second patient also experienced generalised scalp regrowth and significant eyebrow growth and continued to maintain growth 14 weeks later.

Conclusion: Our findings suggest that topical JAK inhibitors could be developed as a potential new treatment for AA and alternative to clobetasol dipropionate 0.05% ointment.

Word Count: 240

Introduction

Alopecia Areata (AA) is a chronic, relapsing and remitting, inflammatory disease of terminal anagen hair follicles. AA produces one or more lesions of complete hair loss ranging in severity from a small thumbprint-sized bald patches to total baldness of the scalp or universal loss of every terminal hair on the body ^{1,2}. The lifetime risk of alopecia areata is 1.7% and 10% of affected individuals develop severe disease as defined by >50% hair loss. Persistent moderate-to-severe AA causes significant disfigurement and psychological distress in affected individuals ³⁻⁵. There are no evidence-based treatments for AA ⁴, yet various treatments are offered, most commonly topical and intralesional steroids, which have limited efficacy.

AA has a complex polygenetic aetiology and more than 17 gene polymorphisms have been identified in population gene association studies. These genes polymorphisms implicate in both innate and adaptive immune responses.

The pathogenesis involves activation of the Janus Kinase and signal transducer and activator of transcription (JAK/STAT) inflammatory pathway, collapse of hair bulb immune privilege and subsequent autoimmune attack of the hair bulb by IFN- γ -producing NKG2D-bearing CD8⁺ cytotoxic T lymphocytes ^{6,7} (Figure 1).

There are 4 JAK isoforms; JAK1, JAK2, JAK3 and Tyrosine Kinase-2. Activated CD8+ NKG2D+T releases IFN- γ which bind to receptors on the hair follicle bulb, resulting in an increased signalling of JAK1 and JAK2. This promotes the production of IL-15, a regulator of T and natural killer cell activation and proliferation, which binds to its receptor on the CD8+ T cell surface. This subsequently results in increased signalling of JAK1 and JAK3, further enhancing the production of IFN- γ (Figure 2). This positive feedback loop was described by Divito and Kupper in 2014 ⁸.

Therapeutic targeting of Janus Kinase (JAK) in AA, has been shown to reverse AA in C3H/HeJ mice ⁹ as well as adult and adolescent humans ¹⁰⁻¹³. Ruxolitinib and tofacitinib are small-molecule JAK inhibitors that work on both hair follicles and on CD8+ NKG2D+T cells. Ruxolitinib is an oral dual inhibitor of the JAK1 and 2 enzymes that is currently FDA and TGA approved for the treatment of myeloproliferative disorders. Tofacitinib is an oral

inhibitor of the JAK 3 enzyme that is currently FDA and TGA approved for the treatment of rheumatoid arthritis. Both these inhibitors have been shown to alleviate the symptoms of AA.

Tofacitinib in a dose of 5mg twice daily orally has been shown in phase II clinical trials to be effective in the treatment of psoriasis and atopic dermatitis^{10, 12, 14, 15}. Tofacitinib 2% ointment applied twice daily and Ruxolitinib 1% ointment applied twice daily have both been examined in phase I clinical trials in the treatment of psoriasis and tofacitinib intra-ocular eye drops have been trialled for the treatment of iritis. No safety issues were identified with either ointment or eye-drop preparations.

While there have been a number of case series reporting hair regrowth following treatment of alopecia areata with topical JAK inhibitors, to date, there have been no placebo controlled, double blind studies examining hair regrowth with topical JAK inhibitors in patients with AA universalis.

We conducted an investigator initiated, 28-week, prospective, double-blind placebo controlled, pilot study comparing Ruxolitinib 1% ointment and Tofacitinib 2% ointment to clobetasol dipropionate 0.05% ointment (active comparator) to ointment base (placebo).

Methods

This study was approved by Epworth Healthcare Ethics Committee (HREC No.672-15). All procedures and visits were conducted in accordance with The International Conference on Harmonisation's (ICH) Guideline for Good Clinical Practice (GCP).

The study duration was 28 weeks with a 12-week treatment period followed by another 12-week follow-up period after the last dose. Each volunteer with alopecia universalis were supplied with 4 tubes of ointment. Each tube contained either Ruxolitinib 1% ointment, Tofacitinib 2% ointment, the active comparator clobetasol dipropionate 0.05% ointment or the placebo (ointment base). To maintain blind, tubes were labelled with designated region of ointment application only. The first tube was labelled right eyebrow. The second tube was labelled left eyebrow. The third tube was labelled right temple and the fourth tube was labelled left temple. Subjects were instructed to apply the ointment to each designated area

twice a day. The pharmacist used a random number generator to determine which ingredient was in each tube. Neither the subjects nor clinical investigators knew which ingredient was in each tube.

Qualitative assessment of the efficacy of topical JAK inhibitors were determined by changes in global photography, 4-point scale for investigator's and patient's global assessment (IGA and PtGA respectively) at baseline and over time up to the final visit (Week 0 2, 4, 6, 8, 12, 18, 24). Qualitative assessment of changes in hair growth was monitored through global photography on a standardised photography equipment. Photographs of patient's scalp vertex and frontal scalp were captured at every visit and assessed by an independent assessor. The description for the 4-point scale for IGA and PtGA are as follows: 1 denotes poor/no growth/no non-vellus hair observed; 2 denotes fair or sparse growth of vellus hair observed in treatment areas; 3 denotes good or considerable growth of non-vellus and terminal hair observed in treatment areas and 4 denotes very good, excellent or significant regrowth of terminal hair observed in treatment areas. IGA was performed by the same physician at all visit to maintain consistency of reported outcomes.

Results

16 patients with a clinical diagnosis of Alopecia Universalis were enrolled in the study. Six patients demonstrated partial hair regrowth in the area treated with 2% Tofacitinib ointment applied twice daily. Five patients demonstrated partial hair regrowth in the area treated with 1% Ruxolitinib ointment applied twice daily. Ten out of 16 patients demonstrated partial hair regrowth in the areas treated with Clobetasol dipropionate 0.05% ointment applied twice daily. Regrowth was reported as early as 4 weeks following commencement of treatment. The IGA indicated that gradual regrowth was observed up to end of treatment, 12 weeks after commencement of topical study medication (Graph 1). 2% tofacitinib resulted in more significant regrowth compared to 1 % Ruxolitinib. However, areas treated with 0.05% Clobetasol showed the most significant regrowth.

Interestingly, two patients developed generalised hair regrowth on the scalp and eyebrows during the treatment period that went beyond the area of ointment application. Qualitative assessments of global photographs are represented in Figures 3-5. Table 1 represents the Investigator's global assessment of hair regrowth for both Patients 1 and 2. Patient 1 began presenting with regrowth on the scalp six weeks following the first application of the study medication and progressed to a full head of hair by the last application (Figure 3). The hair

regrowth reversed within the 12-week follow-up period. This hair regrowth and eventual fall out may be attributed to the inhibitory role of the JAK inhibitors. After completion of the trial, Patient 1 was commenced on oral tofacitinib 5 mg daily and achieved complete hair regrowth over a 9-month period (Figure 4). In contrast, Patient 2 continued to demonstrate generalised hair regrowth 14 weeks after the last topical application without further medication (Figure 5).

While regrowth was seen in the placebo area in 2 patients, both patients experienced generalised regrowth over their entire scalp. No patient experienced regrowth just in the placebo treated area or in the area treated with just the active comparator.

No dermal atrophy or side-effects were identified hence the topical application of JAK inhibitors is considered safe. In addition, patient's blood pressure, physical examination and safety assessments were conducted throughout the duration of the study. No significant findings were reported.

Conclusion

Our findings suggest that topical use of the JAK inhibitors, tofacitinib and ruxolitinib may have a role in the treatment of AA. Response rates are likely to be improved by use of higher concentrations of the active ingredient or vehicles that enhance penetration into the dermis. Based on findings with oral JAK inhibitors in AA, we also believe that a longer duration of JAK inhibition will increase the response rate. It is likely that prolonged treatment will be required to maintain response.

In essence, the generalised regrowth could be a result of the systemic synergistic effect of the topical absorption of ruxolitinib, tofacitinib and clobetasol. Specifically, this would be the transient suppression of the JAK enzymes by tofacitinib and ruxolitinib and enhancement by Clobetasol. It may be beneficial to study the effect of topical JAK inhibitors with separate placebo and treatment groups in order to investigate the individual effect of each medication. Additionally, the depigmented regrowth we observed have been previously documented elsewhere in AA patients¹⁶⁻¹⁸.

Pharmacokinetic studies that measure tissue and serum concentrations following topical application of JAK inhibitors should be employed to guide the development of topical JAK inhibition treatment of AA.

Finally, patient reported outcomes (PROs) such as DLQI and Kingsley Alopecia Profile were not included in this pilot study. PROs play a vital role in providing a useful insight into patients' clinical satisfaction, particularly in the treatment and management of hair and skin condition. Thus, including such questionnaires in future studies will provide beneficial information.

Acknowledgements

This work was supported by a research grant by the Australia Alopecia Areata Foundation.

Legends:

Table 1. Investigator's global assessment of hair regrowth in Patients 1 & 2 across the 24-week study. The most significant observed improvement in regrowth was reported at Visit 8 coinciding with the end of treatment (EOT) visit. * indicates end of topical application of study medications.

Figure 1. Proposed pathogenesis of Alopecia areata. Cytokines and cellular factors thought to be responsible for maintaining immune privilege such as TGF- β 1 and IGF-1 are listed in the left box. Factors such as Substance P and IFN- γ believed to mediate loss of immune privilege and subsequently initiation of disease are listed in the middle box. Loss of immune privilege is associated with increased expression of MHC class I molecules, which are capable of presenting hair follicle autoantigens to T lymphocytes. Consequently, autoimmune events that may result in the amplification of the pathology of AA including activation of CD4+ T cells are listed in the right box. Image courtesy of Gilhar et al (2007)

Figure 2. Positive feedback loop in Alopecia areata. Xing et al. showed that CD8+ NKG2D+T cells infiltrate the dermis and localize to the hair follicle bulb, forming immune synapses with follicular epithelial cells through major histocompatibility complex (MHC) class I-peptide complexes and NKG2DL. Activated CD8+ T cells release IFN- γ binding to its receptor on the surface of the follicular epithelial cell. This in turn signals JAK1 and JAK2 to promote production of IL-15, a mediator of CD8+ T cell induction, and its chaperone IL-15R α . This binds the IL-15R complex (IL-2R β and γ c) on the CD8+ T cell surface, causing signaling via JAK1 and JAK3 to enhance the production of IFN- γ and amplify the feedback

loop. Ruxolitinib and tofacitinib are small-molecule JAK inhibitors that interfere with this feedback loop. Ruxolitinib inhibits JAK1 and JAK2 while tofacitinib inhibits JAK3 more strongly than JAK1. Both these inhibitors have been shown to alleviate the symptoms of Alopecia areata. STAT1, signal transducer and activator of transcription-1; TCR, T cell receptor; STAT5, signal transducer and activator of transcription-5. Extracted from Divito et al 2014.

Figure 3. Patient 1 demonstrated a full regrowth by the end of the 12-week topical treatment period. Generalized regrowth was observed over the scalp. Facial hair was also reported by patient.

Figure 4. Complete regrowth following nine months of treatment with oral tofacitinib 5mg daily.

Figure 5. Patient 2 demonstrated significant regrowth by the end of the 12-week treatment period and progressively continued regrowth up to 14 weeks after the last topical application of the study medication.

References

1. Perera E, Yip L, Sinclair R. Alopecia areata. Current problems in dermatology. 2015;47:67-75.
2. Price V. Alopecia areata: clinical aspects. . The Journal of investigative dermatology. 1991;96(5).
3. Amin S, Sachdeva S. Alopecia Areata: an update. Journal of Pakistan Association of Dermatologists. 2013;23(2).
4. K S. Prevalence of alopecia areata in the First National Health and Nutrition Examination Survey. Archives of dermatology. 1992;128(5).
5. Kyriakis K, Paltatzidou K, Kosma E, Sofouri E, Tadros A, Rachioti E. Alopecia areata prevalence by gender and age. Journal of the European Academy of Dermatology and Venereology. 2009;23(5).

6. Xing L, Dai Z, Jabbari A, Cerise JE, Higgins CA, Gong W, et al. Alopecia areata is driven by cytotoxic T lymphocytes and is reversed by JAK inhibition. *Nature Medicine*. 2014;20:1043.
7. Petukhova L, Duvic M, Hordinsky M, Norris D, Price V, Shimomura Y. Genome-wide association study in alopecia areata implicates both innate and adaptive immunity. *Nature*. 2010;466(7302).
8. Divito SJ, Kupper TS. Inhibiting Janus kinases to treat alopecia areata. *Nature Medicine*. 2014;20:989.
9. Sundberg JP, Berndt A, Silva KA, Kennedy VE, Sundberg BA, Everts HB, et al. Alopecia areata: updates from the mouse perspective. *The journal of investigative dermatology Symposium proceedings*. 2013;16(1):S23-4.
10. Craiglow B, King BA. Killing Two Birds with One Stone: Oral Tofacitinib Reverses Alopecia Universalis in a Patient with Plaque Psoriasis. *Journal of Investigative Dermatology*.134(12):2988-90.
11. Craiglow BG, Liu LY, King BA. Tofacitinib for the treatment of alopecia areata and variants in adolescents. *Journal of the American Academy of Dermatology*. 2017;76(1):29-32.
12. Damsky W, King BA. JAK inhibitors in dermatology: The promise of a new drug class. *Journal of the American Academy of Dermatology*.76(4):736-44.
13. Anzengruber F, Maul J, Kamarachev J, Trüeb R, French L, Navarini A. Transient Efficacy of Tofacitinib in Alopecia Areata Universalis. *Case Reports in Dermatology*. 2016;8(1):102-6.
14. Vesely M, Imaeda S, King B. Tofacitinib citrate for the treatment of refractory, severe chronic actinic dermatitis. *JAAD Case Rep* 2016;3(1).
15. Alves de Medeiros AK, Speeckaert R, Desmet E, Van Gele M, De Schepper S, Lambert J. JAK3 as an Emerging Target for Topical Treatment of Inflammatory Skin Diseases. *PLOS ONE*. 2016;11(10):e0164080.

16. Dinh Q, Chong A. A case of widespread non-pigmented hair regrowth in diffuse alopecia areata. *Australasian Journal of Dermatology*. 2007;48(4):221-3.
17. Jalalat S, Kelsoe J, Cohen P. Alopecia areata with white hair regrowth: case report and review of poliosis. *Dermatol Online J* 2014;20(9).
18. Wade M, Sinclair R. Persistent depigmented regrowth after alopecia areata. *J Am Acad Dermatol* 2002;46(4):2.
19. Gilhar A, Paus R, Kalish RS. Lymphocytes, neuropeptides, and genes involved in alopecia areata. *Journal of Clinical Investigation*. 2007;117(8):2019-27.

Author Manuscript

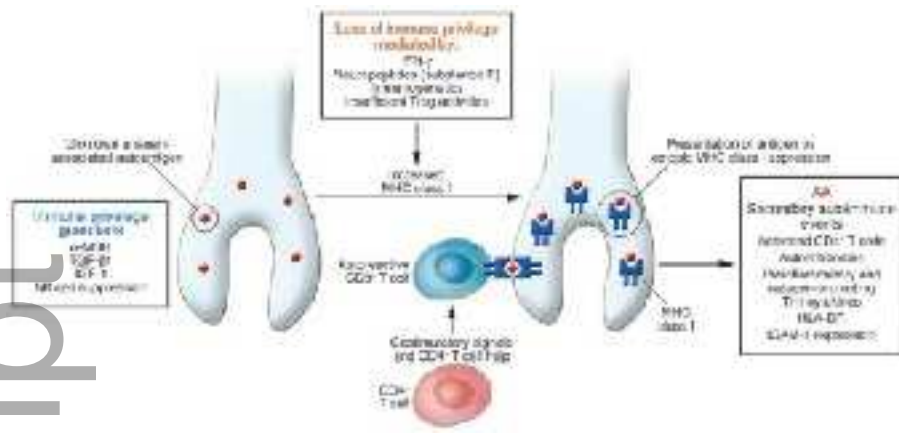
	Patient	Visit 1 (Screening)	Visit 2 (Wk 0/SOT)	Visit 3 (Wk 2)	Visit 4 (Wk 4)	Visit 5 (Wk 6)	Visit 6 (Wk 8)	Visit 7 (Wk 10)	Visit 8 (Wk 12/ EOT) *	Visit 9 (Wk 18/ FU1)	Visit 10 (Wk 24/ FU2)
A - 1% RUXOLITINIB	P1	1	1	1	1	1	1	1	4	3	1
	P2	1	1	1	2	2	2	1	3	3	3
B - 2% TOFACITINIB	P1	1	2	1	1	1	1	1	4	2	1
	P2	1	1	1	2	2	2	1	3	3	3
C - 0.05% CLOBETASOL	P1	1	2	1	1	3	3	3	4	2	1
	P2	1	1	1	2	2	2	1	4	3	3
D - PLACEBO	P1	1	1	1	1	2	2	2	4	2	1
	P2	1	1	1	2	2	2	1	3	3	3

non-

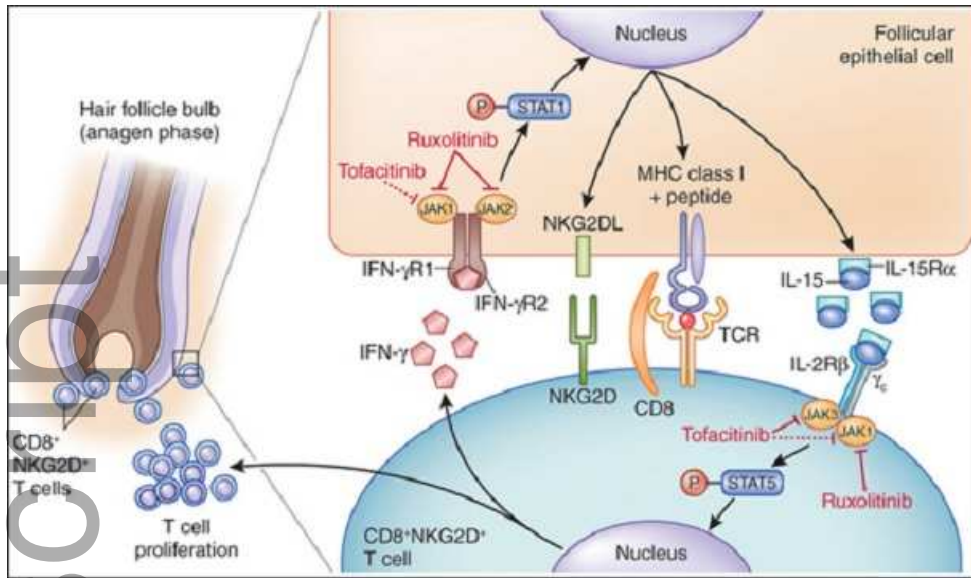
fair/sparse growth of vellus hair observed in treatment areas; **3** = Good/considerable growth of

non-vellus and terminal hair observed in treatment areas; **4**= very good/excellent/significant regrowth of terminal hair observed in treatment areas

1= poor/no growth/no vellus hair observed; **2**=

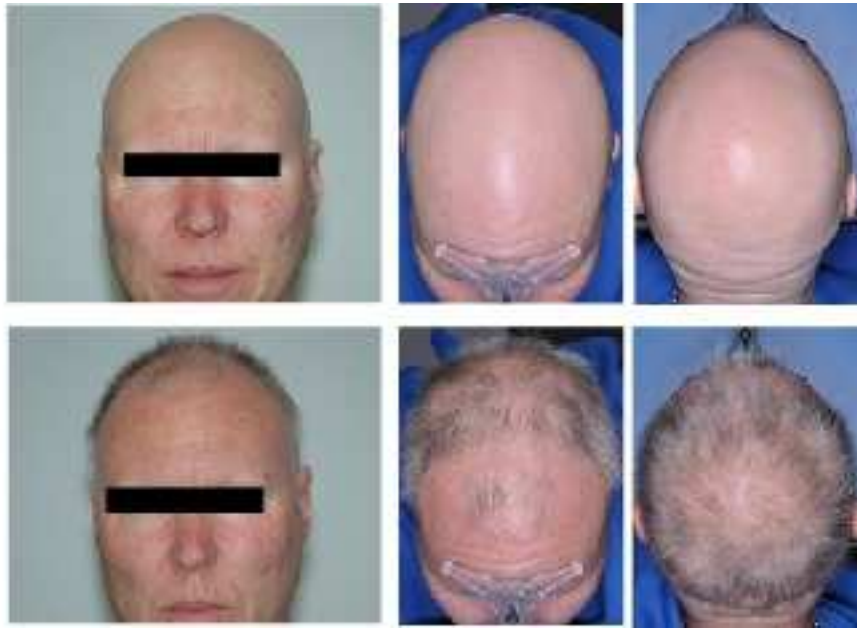

ijd_14192_f1.jpg

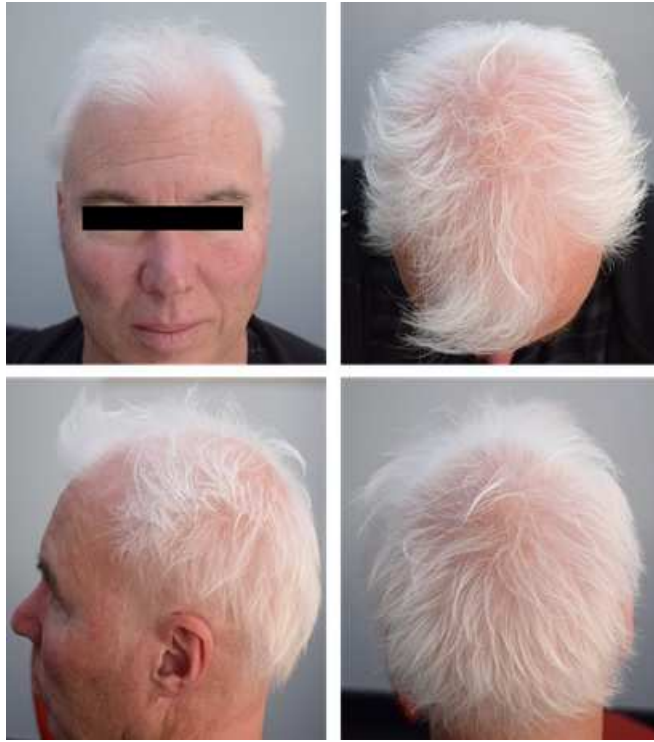

ijd_14192_f2.jpg

Author Manuscript

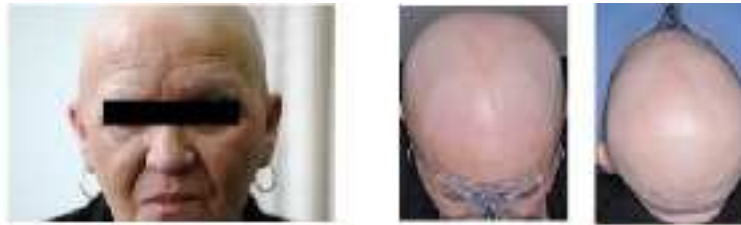

ijd_14192_f3.jpg

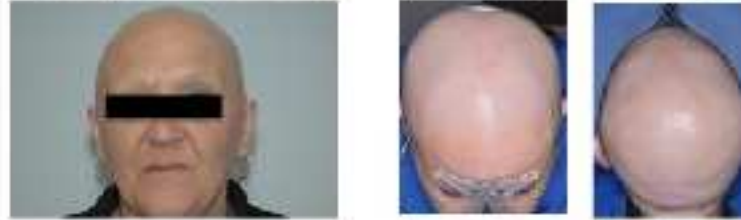

ijd_14192_f4.jpg

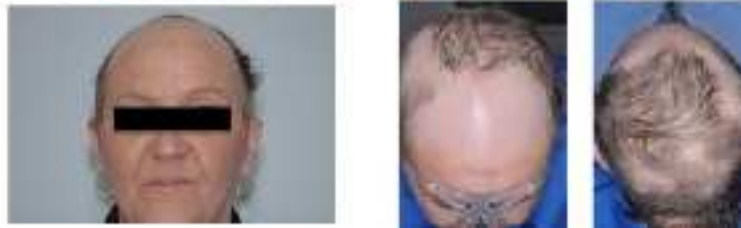Baseline



After 12 weeks of topical treatment



18 weeks after last topical application



ijd_14192_f5.jpg