



Minerva Access is the Institutional Repository of The University of Melbourne

Author/s:

Mathias, RM;Goodsall, TM;Parker, CE;Day, AS;An, YK;Baraty, B;Basnayake, C;Begun, J;Boyapati, RK;Burgell, R;Dolinger, MT;Maconi, G;Novak, KL;Sagami, S;Smith, RL;Srinivasan, AR;Taylor, SA;Jairath, V;Ma, C;Bryant, RV

Title:

Expert Position Statement: Defining the Role of Intestinal Ultrasound in Assessing Constipation and Faecal Loading

Date:

2025-10-01

Citation:

Mathias, R. M., Goodsall, T. M., Parker, C. E., Day, A. S., An, Y. K., Baraty, B., Basnayake, C., Begun, J., Boyapati, R. K., Burgell, R., Dolinger, M. T., Maconi, G., Novak, K. L., Sagami, S., Smith, R. L., Srinivasan, A. R., Taylor, S. A., Jairath, V., Ma, C. & Bryant, R. V. (2025). Expert Position Statement: Defining the Role of Intestinal Ultrasound in Assessing Constipation and Faecal Loading. *Alimentary Pharmacology and Therapeutics*, 62 (8), pp.799-808. <https://doi.org/10.1111/apt.70250>.

Persistent Link:










<https://hdl.handle.net/11343/362605>

License:

[CC BY-NC](#)

## ORIGINAL ARTICLE OPEN ACCESS

# Expert Position Statement: Defining the Role of Intestinal Ultrasound in Assessing Constipation and Faecal Loading

Ryan M. Mathias<sup>1,2,3</sup>  | Thomas M. Goodsall<sup>4,5</sup> | Claire E. Parker<sup>6</sup> | Alice S. Day<sup>1,2,3</sup>  | Yoon K. An<sup>7,8</sup> | Brandon Baraty<sup>9,10</sup> | Chamara Basnayake<sup>11,12</sup>  | Jakob Begun<sup>7</sup>  | Ray K. Boyapati<sup>13,14</sup> | Rebecca Burgell<sup>15</sup> | Michael T. Dolinger<sup>16</sup> | Giovanni Maconi<sup>17</sup>  | Kerri L. Novak<sup>18</sup>  | Shintaro Sagami<sup>19</sup>  | Rebecca L. Smith<sup>20</sup> | Ashish R. Srinivasan<sup>21,22,23</sup>  | Stuart A. Taylor<sup>24</sup> | Vipul Jairath<sup>6,25,26</sup> | Christopher Ma<sup>18</sup>  | Robert V. Bryant<sup>1,2,3</sup>

<sup>1</sup>Inflammatory Bowel Disease Service, The Queen Elizabeth Hospital, Adelaide, South Australia, Australia | <sup>2</sup>School of Medicine, Faculty of Health and Medical Sciences, The University of Adelaide, Adelaide, South Australia, Australia | <sup>3</sup>Inflammatory Bowel Disease Research Group, The Basil Hetzel Institute for Translational Health Research, Adelaide, South Australia, Australia | <sup>4</sup>Department of Gastroenterology, Inflammatory Bowel Disease Service, John Hunter Hospital, Newcastle, New South Wales, Australia | <sup>5</sup>School of Medicine, The University of Newcastle, Newcastle, New South Wales, Australia | <sup>6</sup>Alimentiv Inc. London, London, Ontario, Canada | <sup>7</sup>Department of Gastroenterology, Mater Hospital, Brisbane, Queensland, Australia | <sup>8</sup>Mater Research Institute, University of Queensland, Brisbane, Queensland, Australia | <sup>9</sup>Department of Gastroenterology and Liver Services, Concord Hospital, Sydney, New South Wales, Australia | <sup>10</sup>Faculty of Medicine and Health, University of Sydney, Sydney, New South Wales, Australia | <sup>11</sup>Department of Gastroenterology, St Vincent's Hospital Melbourne, Melbourne, Victoria, Australia | <sup>12</sup>Faculty of Medicine, Dentistry and Health Sciences, Melbourne Medical School, The University of Melbourne, Melbourne, Victoria, Australia | <sup>13</sup>Department of Gastroenterology, Monash Health, Clayton, Victoria, Australia | <sup>14</sup>Faculty of Medicine, Nursing and Health Sciences, Monash University, Clayton, Victoria, Australia | <sup>15</sup>Department of Gastroenterology, Central Clinical School, Monash University and Alfred Health, Melbourne, Victoria, Australia | <sup>16</sup>Division of Pediatric Gastroenterology, NYU Grossman School of Medicine, New York, New York, USA | <sup>17</sup>Department of Biomedical and Clinical Science, Gastroenterology Unit, 'L.Sacco' University Hospital, University of Milan, Milan, Italy | <sup>18</sup>Division of Gastroenterology and Hepatology, Department of Medicine and Community Health Sciences, University of Calgary, Calgary, Alberta, Canada | <sup>19</sup>Center for Advanced IBD Research and Treatment, Kitasato University Kitasato Institute Hospital, Tokyo, Japan | <sup>20</sup>Department of Gastroenterology, Alfred Hospital, Melbourne, Victoria, Australia | <sup>21</sup>Department of Gastroenterology, Austin Health, Melbourne, Victoria, Australia | <sup>22</sup>Faculty of Medicine, Dentistry and Health Sciences, The University of Melbourne Medical School, Melbourne, Victoria, Australia | <sup>23</sup>Department of Gastroenterology, Eastern Health, Melbourne, Victoria, Australia | <sup>24</sup>Centre for Medical Imaging, University College London, London, UK | <sup>25</sup>Division of Gastroenterology, Department of Medicine, Western University, London, Ontario, Canada | <sup>26</sup>Department of Epidemiology and Biostatistics, Western University, London, Ontario, Canada

**Correspondence:** Ryan M. Mathias ([ryan.mathias@sa.gov.au](mailto:ryan.mathias@sa.gov.au)) | Robert V. Bryant ([robert.bryant@sa.gov.au](mailto:robert.bryant@sa.gov.au))

**Received:** 18 March 2025 | **Revised:** 3 May 2025 | **Accepted:** 17 June 2025

**Handling Editor:** Richard Gearry

**Funding:** Michell McGrath Fellowship and funding through the Hospital Research Foundation.

**Keywords:** constipation | disorder of gut-brain interaction | faecal loading | intestinal ultrasound

## ABSTRACT

**Background:** Intestinal ultrasound has been proposed as a tool to assess non-inflammatory functional gastrointestinal disorders, including constipation and faecal loading. However, well-defined sonographic criteria for these conditions are currently lacking.

**Aim:** To identify and establish specific sonographic parameters that could be used to assess constipation and faecal loading with intestinal ultrasound.

**Methods:** We conducted a Research and Development/University of California Los Angeles appropriateness method exercise. A multidisciplinary, international panel comprising 14 experts in adult and paediatric gastroenterology and one radiologist experienced in gastrointestinal imaging rated the appropriateness of 57 statements using a 9-point Likert scale over two rounds of voting. Based on the median panel rating and level of disagreement, statements were categorised as appropriate, inappropriate or uncertain.

This is an open access article under the terms of the [Creative Commons Attribution-NonCommercial](https://creativecommons.org/licenses/by-nc/4.0/) License, which permits use, distribution and reproduction in any medium, provided the original work is properly cited and is not used for commercial purposes.

© 2025 The Author(s). *Alimentary Pharmacology & Therapeutics* published by John Wiley & Sons Ltd.

**Results:** 43 statements were deemed appropriate after two rounds of voting, while three were rated as inappropriate and five as uncertain. Intestinal ultrasound was determined to be an appropriate modality for the assessment of faecal loading. Posterior acoustic shadowing and echogenic reflections were considered important sonographic parameters for the assessment of faecal loading. A rectal diameter of 30 mm was considered appropriate to define faecal loading in paediatric patients, although no recommendation was made for adult patients due to a paucity of data.

**Conclusion:** The expert panel considered intestinal ultrasound an appropriate modality for evaluating constipation and faecal loading. Further prospective research is required, especially in adult patients, to define sonographic metrics of luminal contents to broaden its application in the assessment of functional gastrointestinal disorders.

## 1 | Introduction

Intestinal ultrasound (IUS) is an imaging modality widely used to examine patients with gastrointestinal disorders [1]. Within inflammatory bowel disease (IBD), IUS is a cost-effective, non-invasive, accurate, and reproducible method to assess disease activity and complications [2]. However, the role of IUS in the assessment of disorders of gut brain interaction (DGBI) is less established.

DGBI are a group of gastrointestinal conditions, defined by chronic, patient-reported symptoms that substantially impact quality of life. These disorders are attributed to alterations in gastrointestinal function that are primarily driven by altered interactions between neuroimmune pathways, the enteric nervous system, and gut microbiota [3]. Epidemiological studies estimate that up 40% of individuals meet the diagnostic criteria for at least one DGBI [4].

Due to the nonspecific nature of the symptoms associated with DGBIs, thorough clinical evaluation is required to differentiate these conditions from organic pathology. Accordingly, patients are often exposed to invasive procedures and ionising radiation before a DGBI diagnosis is confirmed [5]. Furthermore, functional symptoms are common in patients with established pathology such as IBD, introducing additional diagnostic uncertainty, leading to potentially avoidable investigations and therapeutic escalation. The overlap between functional and organic gastrointestinal disorders underscores the need for refined diagnostic algorithms to elucidate the aetiology of symptoms.

IUS is a potentially valuable diagnostic tool in the evaluation of DGBI. In addition cost-effectiveness and safety, this imaging modality can rule out inflammation and characterise luminal contents [6]. Moreover, IUS has demonstrated utility in assessing functional constipation among paediatric populations, with evidence suggesting a correlation between objective sonographic properties of faecal loading and the presence of constipation [6, 7]. While the correlation between faecal loading and constipation is imperfect, identification plays a valuable role in the evaluation of DGBI. This is particularly significant in differentiating patients with underlying constipation disorders from more sinister pathology [8].

Guidance exists to support the application of IUS in the assessment of DGBI. However, formal evidence-based recommendations are limited due to small, retrospective studies or those in which there may have been significant bias in results [9, 10].

While available evidence regarding sonographic assessment of faecal loading and constipation has been summarised in a recent systematic review, the majority of the data were derived from paediatric cohorts [6]. Adult studies are limited and the available evidence in this cohort is from retrospective reports or small case series [6].

The aim of this study was to develop a comprehensive set of expert recommendations on IUS for assessing constipation and faecal loading using a modified Research and Development/University of California Los Angeles appropriateness method (RAM) exercise.

## 2 | Methods

### 2.1 | Modified Research and Development/University of California Los Angeles Appropriateness Method

The RAM uses a modified Delphi approach to combine the best available evidence with expert opinion; this technique aims to determine statement appropriateness without forcing consensus [11]. Five co-authors developed an initial list of statements based on a previously published systematic review that identified 24 studies using IUS to evaluate intestinal contents in the context of constipation [6]. A panel of 15 experts (14 gastroenterologists and 1 radiologist) from 6 countries was subsequently assembled. Panellists were invited to participate based on their clinical expertise in the field of gastroenterology or radiology and experience in using IUS to assess IBD and DGBI. Of the 14 gastroenterologists, 1 specialised in paediatric patients, and 12 were accredited in IUS. Of those who performed IUS, 8 panellists had practiced for between 5 and 10 years and 4 had performed IUS for more than 10 years; all reported performing more than 10 scans per week in routine practice and while not quantified, all admitted to performing contents assessment routinely. Two gastroenterologists were DGBI experts but did not routinely perform IUS however worked in a clinic employing IUS for assessment of DGBI including constipation assessment and management. These individuals did not vote on questions pertaining to technical aspects of IUS assessment.

### 2.2 | First Round Panel Voting

After receiving background information on the RAM, study objectives, and current literature, the initial statement list was circulated to panellists via an online survey. Each

panellist anonymously rated statements using a 9-point Likert scale (1 = strongly inappropriate; 9 = strongly appropriate).

Statement appropriateness was determined based on the median rating of each statement and presence of disagreement [11]. Statements were classified as inappropriate (median 1 to  $\leq 3.5$  without disagreement), uncertain (median  $> 3.5$  and  $< 6.5$  or any median with disagreement), and appropriate (median  $\geq 6.5$ –9 without disagreement). Disagreement was considered present when  $\geq 5$  panellists provided a rating in each extreme end of the scale (1–3 and 7–9). The median absolute deviation (MAD) was also calculated.

### 2.3 | Second Round Panel Voting

Following the initial round of voting, results were analysed, distributed to the panellists, and reviewed in a moderated video conference. Statements with disagreement or uncertainty without disagreement were prioritised. Panellists were encouraged to engage in open discussion with no focus on reaching consensus. The initial statement list was subsequently modified with the addition of 2 statements and removal of 13 statements. Most of the removed statements pertained to the clinical assessment of DGBI, considered beyond the scope due to established Rome criteria [12]. The revised statement list was then circulated via a second online survey. Statements were rated and appropriateness was determined as described. All Statistical analyses were performed using GraphPad Prism 10.2.2 for MacOS, GraphPad Software, Boston, Massachusetts USA.

## 3 | Results

In the first of voting round, 67% (38/57) statements were rated as appropriate, 11% (6/57) were rated as inappropriate, and 23% (13/57) were rated as uncertain.

A total of 46 statements were included in the final survey, with 93% (43/46) of statements rated as appropriate, 4% (2/46) of statements rated as inappropriate, and 9% (5/46) of statements rated as uncertain. Rating distributions are available in Table S1.

### 3.1 | Clinical Assessment of Constipation

The panel felt it appropriate to define FC by established Rome criteria and that organic causes of constipation and secondary diseases be excluded (Table 1) [12]. History and examination were considered appropriate in the workup of constipation, which was accepted to feature in both patients with ulcerative colitis and Crohn's disease. Uncertain items included the role of radiology in diagnosing constipation and the reliance on clinical history and examination alone in evaluating constipation among IBD patients.

### 3.2 | Faecal Loading Assessment

The definition of faecal loading, the role of radiographic studies (including IUS), and the inaccuracy of physical examination to diagnose faecal loading were considered appropriate by

**TABLE 1** | Items relating to the clinical assessment of constipation in both healthy and IBD patients.

Item	Median (MAD)	Rating
Functional constipation is a diagnosis defined by the Rome criteria and implies the absence of organic or secondary causes	9 (0.53)	Appropriate
History and examination are adequate to assess constipation in patients without alarm symptoms	8 (0.73)	Appropriate
Rectal examination should form part of the physical examination for suspected constipation	8 (1.00)	Appropriate
Radiological assessment is necessary for diagnosing constipation	5 (1.80)	Uncertain
Radiological assessment is contributory to the management of constipation	8 (1.33)	Appropriate
History and examination are adequate to diagnose constipation in patients with IBD	6 (2.00)	Uncertain
Ulcerative colitis is associated with proximal constipation	7 (1.20)	Appropriate
Constipation is more common in patients with ulcerative colitis but can be seen in patients with Crohn's disease	8 (0.80)	Appropriate

Abbreviations: IBD, inflammatory bowel disease; MAD, median absolute deviation.

panellists (Table 2). There was uncertainty regarding the appropriateness of computed tomography (CT), X-ray, and IUS, and magnetic resonance imaging (MRI) was considered inappropriate. Colonic motility studies were considered inappropriate within the context of limitations (regional variations in practice, lack of access, and local expertise).

### 3.3 | Adequacy of Intestinal Ultrasound

In line with previously published consensus guidelines, IUS was considered to be appropriate for diagnosing DGBI (Table 3) [9]. In general, the panel considered IUS appropriate in the assessment of faecal loading in all segments of the colon, including the rectum, the caveat being that rectal assessment required pre-defined criteria to be met to ensure accuracy.

### 3.4 | Luminal Contents Assessment

Characterisation of faecal contents by IUS was considered feasible by panel members (Table 4). Including differentiation of solid and liquid stool. Colonic gas was also considered to be accurately assessed using IUS with the pattern of echogenicity suggesting

**TABLE 2** | Items relating to the assessment of faecal loading.

Item	Median (MAD)	Rating
Faecal loading is defined as retention of faecal material with distension of the colonic wall when assessed radiologically	8 (0.87)	Appropriate
Physical examination is sufficient to diagnose faecal loading	3 (1.33)	Inappropriate
Radiological assessment is necessary for diagnosing faecal loading	7 (1.00)	Appropriate
X-ray is the preferred modality for evaluating faecal loading	4 (1.86)	Uncertain
CT is the preferred modality for evaluating faecal loading	4 (1.27)	Uncertain
MRI is the preferred modality for evaluating faecal loading	2 (1.40)	Inappropriate
Colonic motility studies are the preferred modality for evaluating faecal loading	2 (1.13)	Inappropriate
IUS is the preferred modality for evaluating faecal loading	5 (1.27)	Uncertain

Abbreviations: CT, computed tomography; IUS, intestinal ultrasound; MAD, median absolute deviation; MRI, magnetic resonance imaging.

the type of stool consistency. Posterior acoustic shadowing was considered appropriate for defining solid luminal contents such as hard or impacted stool; however, it was acknowledged that in some cases this finding could be mimicked by gas (Figure 1).

### 3.5 | Colonic Architecture Assessment

IUS assessment of the shape of the colonic wall and the loss of haustrations due to faecal loading were considered appropriate statements (Table 5). However, further studies were recommended by panellists to evaluate the correlation between faecal loading and haustral appearances. The panellists accepted that haustral loss is not always associated with faecal loading (Figure 1).

### 3.6 | Sonographic Assessment of the Rectum

Established sonographic approaches and equipment for transabdominal assessment of the rectum, including patient positioning, were considered appropriate [13] (Table 6). In paediatric patients, a rectal diameter cutoff of 30mm was considered a predictor of faecal loading. The panel noted that anatomical variations across ages should be taken into consideration when interpreting this threshold, as demonstrated by two studies showing differences in the rectal sizes in infants

**TABLE 3** | Items relating to the adequacy of intestinal ultrasound in the assessment of faecal loading.

Item	Median (MAD)	Rating
IUS is an appropriate modality for assessing functional gastrointestinal disorders	7 (1.13)	Appropriate
IUS is an appropriate modality for assessing IBD	9 (0.33)	Appropriate
IUS is an appropriate modality for differentiating symptoms of constipation from inflammation in patients with IBD	9 (0.93)	Appropriate
IUS is an appropriate modality for evaluating faecal loading in the caecum	7 (1.00)	Appropriate
IUS is an appropriate modality for evaluating faecal loading in the ascending colon	7 (1.07)	Appropriate
IUS is an appropriate modality for evaluating faecal loading in the transverse colon	7 (1.40)	Appropriate
IUS is an appropriate modality for evaluating faecal loading in the descending colon	8 (0.80)	Appropriate
IUS is an appropriate modality for evaluating faecal loading in the sigmoid colon	8 (0.93)	Appropriate
IUS may be an appropriate modality for evaluating faecal loading in the rectum in selected adult and paediatric patients	8 (0.73)	Appropriate

Abbreviations: IBD, inflammatory bowel disease; IUS, intestinal ultrasound; MAD, median absolute deviation.

and in young children [14, 15]. Transperineal ultrasound was considered to be an appropriate tool for assessing the rectum in centres with suitably trained sonographers and appropriate equipment. An example of a transabdominal approach to visualising the rectum through a distended bladder in an adult is seen in Figure 2.

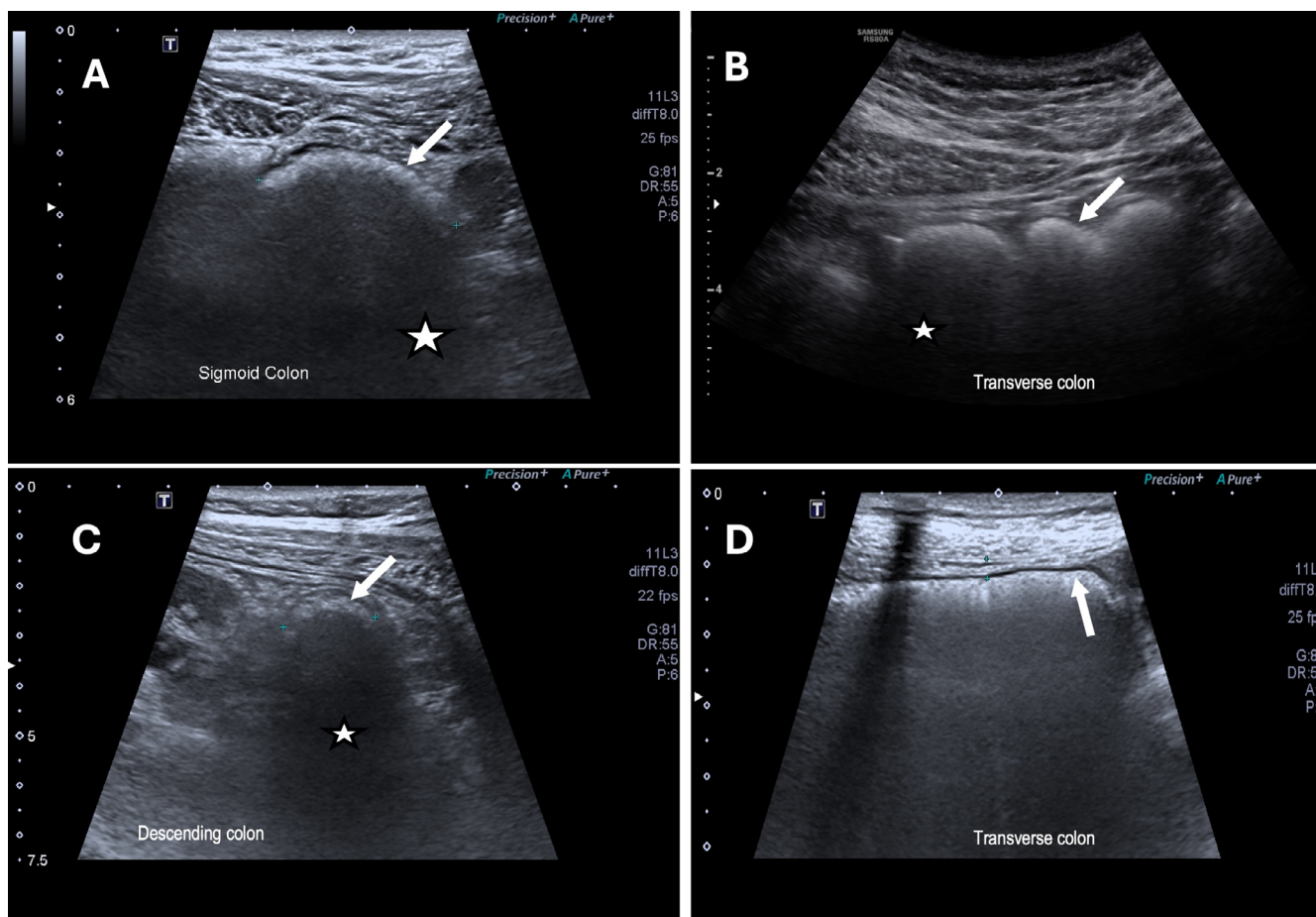
## 4 | Discussion

This RAM exercise examined the use of IUS for evaluating constipation and luminal contents in DGBI. IUS was deemed an appropriate tool for the evaluation of faecal loading and constipation. Specific sonographic parameters, alternate imaging modalities, and consideration of limitations of adult and paediatric cohorts were also considered. In general, a lack of data was identified, illuminating a need for further research to clarify and define the utility of IUS in assessing constipation and faecal loading.

**TABLE 4** | Items relating to the assessment of intraluminal contents via intestinal ultrasound.

Item	Median (MAD)	Rating
Solid and liquid contents can be differentiated when evaluated using IUS	8 (0.77)	Appropriate
Solid stool within the colon is represented as echogenic foci when evaluated using IUS	8 (0.92)	Appropriate
Posterior acoustic shadowing may represent solid luminal contents when evaluated using IUS	8 (0.77)	Appropriate
Liquid stool within the colon is represented by anechoic areas when evaluated using IUS	8 (0.77)	Appropriate
Gas within the colon is represented by highly echogenic foci when evaluated using IUS	8 (0.69)	Appropriate
Multiple highly echogenic foci within grey shadowing represents colonic gas within <i>solid</i> stool when evaluated using IUS	8 (0.85)	Appropriate
Multiple highly echogenic foci within anechoic regions represents colonic gas bubbles within <i>liquid</i> stool when evaluated using IUS	8 (0.85)	Appropriate
Solid stool can be represented as a crescent shaped echogenic focus in the colonic lumen when evaluated using IUS	8 (0.92)	Appropriate

Abbreviations: IUS, intestinal ultrasound; MAD, median absolute deviation.



**FIGURE 1** | Posterior acoustic shadowing (star) and hyperechoic crescents (arrow) with associated faecal loading. A cross-sectional view of a patient with ulcerative colitis and faecal loading of the sigmoid colon demonstrated with a hyperechoic crescent followed by a darkened shadow (A). Faecal loading was confirmed on the same day in this patient by a CT scan performed as part of a clinical trial. A patient generalised abdominal pain with faecal loading of the transverse colon with a hyperechoic crescent, posterior acoustic shadowing and visualised haustra (B). This patient was treated with aperients and fibre supplementation with clinical improvement. A patient mild distal proctitis and faecal loading of the descending colon with a posterior acoustic shadow (C). A patient without other gastrointestinal medical history, admitted with abdominal pain and noted to have pan-colonic faecal loading most pronounced in the transverse colon with the absence of haustral markings, a finding that was also seen on CT (D).

**TABLE 5** | Items relating to defining the colonic architecture via intestinal ultrasound.

Item	Median (MAD)	Rating
The shape of the colonic wall can be evaluated using IUS	7 (0.92)	Appropriate
Haustra are part of the normal colon and can be visualised when evaluated using IUS	8 (1.08)	Appropriate
Shape of the colonic wall can suggest the degree of faecal loading when evaluated using IUS	7 (0.92)	Appropriate
Distension due to faecal loading may be associated with loss of haustral markings when assessed during IUS	8 (1.33)	Appropriate

Abbreviations: IUS, intestinal ultrasound; MAD, median absolute deviation.

**TABLE 6** | Items relating to the assessment of the rectum via intestinal ultrasound and transperineal ultrasound.

Item	Median (MAD)	Rating
A low frequency using a convex 3-5Mhz curvilinear probe can be used to assess the rectum using a transabdominal approach	9 (1.08)	Appropriate
A distended bladder is necessary to assess the rectum via a transabdominal approach	7 (1.69)	Appropriate
The rectum is visualised by placing the probe 2.5 cm above the pubic symphysis and angling the probe 15°–20° caudally to obtain views through a distended bladder	7 (1.31)	Appropriate
Rectal diameter is a marker of faecal impaction	8 (1.08)	Appropriate
Rectal diameter may be associated with faecal loading in adult and paediatric patients	8 (0.60)	Appropriate
A rectal diameter greater than 30mm is associated with faecal loading in the rectum of paediatric patients	7 (1.23)	Appropriate
The rectum can be adequately visualised by TPUS	8 (1.00)	Appropriate
Microconvex, linear and convex probes are all adequate to assess the rectum via a transperineal approach but are dependent on operator skill and experience	8 (1.00)	Appropriate
The patient should be placed in the left lateral position with the probe placed over the anus in the sagittal plane when performing transperineal ultrasound	8 (0.69)	Appropriate

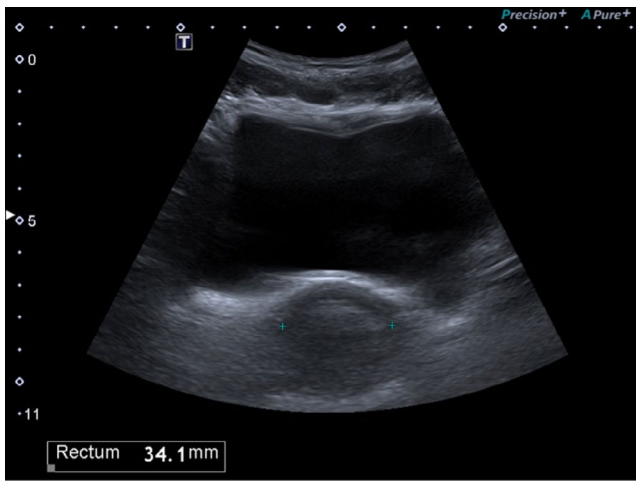
Abbreviations: MAD, median absolute deviation; TPUS, transperineal ultrasound.

The results of this RAM demonstrated that identifying faecal loading may aid in the diagnosis of constipation. Faecal loading is characterised by an accumulation of stool within the colon and the presence of distension, which is often defined as a small bowel diameter greater than 25mm and colonic diameter greater than 50mm [16]. Investigations such as X-rays, for assessing constipation are discouraged in paediatric populations due to inconsistent reporting and ionising radiation exposure [17]. In contrast, there is conflicting guidance on the role of radiology in the evaluation of constipation in adults. Accordingly, practices vary widely, and abdominal X-rays continued to be commonly used [18].

IUS represents a promising, non-invasive, and safe modality for assessing constipation according to the results of this study. It was found to be particularly suitable for evaluating constipation in active ulcerative colitis, where proximal faecal loading and inflammation has been observed in patients with left-sided ulcerative colitis [19]. Early data suggest that IUS may outperform conventional imaging in assessing faecal loading in these patients [20]. Although IUS is not yet be considered standard of care for constipation and faecal loading assessment, its safety and tolerability strengthen its potential application [21]. Further

studies evaluating accuracy and reliability in clinical assessment with regards to faecal loading are warranted.

This RAM exercise highlights the importance of evaluating the rectum when assessing constipation and faecal loading. Transabdominal ultrasound for evaluating constipation in paediatrics is well-documented in both ambulatory and emergency settings [6]. A recent expert consensus aimed to establish a protocol for detecting faecal loading via transabdominal rectal imaging [10]. While this was an important addition to the literature, its recommendations were isolated to the rectum and comments on other colonic segments were not stated. The accuracy of IUS rectal imaging depends on factors such as a body mass index, bladder fullness, and operator expertise [10]. Recent evidence published after the current study was conducted demonstrates high accuracy in detecting faecal loading in the rectum via IUS compared to CT, reinforcing the panel's findings [22]. Rectal diameter was determined to be a useful metric for assessing faecal loading in children, with a cut-off of 30mm, acknowledging age-related and anatomical variability [6, 14, 23]. However, specific rectal diameter cut-off values in adults are lacking [6]. Transperineal ultrasound is appealing for routine



**FIGURE 2** | Transabdominal view of the rectum hyperechoic crescent seen in an adult patient through a distended bladder. The transverse rectal diameter measured by IUS (34.1 mm) was confirmed subsequently on CT scan (31.5 mm) performed on the same day.

assessment of rectal content, but panellists cautioned that this technique requires a deep understanding of rectal anatomy that may be beyond the basic skillset of IUS operators.

The current study highlights the need for validated approaches to assessing luminal content using IUS. The panel concluded that IUS can effectively differentiate between solid and liquid stool and identify gas within stool. Posterior acoustic shadowing, a very commonly described sonographic feature of stool consistency, was felt to represent solid luminal contents, although it may occasionally represent gas [10, 22, 24, 25]. It is recognised that posterior shadowing in some instances can also represent gaseous collections on ultrasound [26]. A single prospective study evaluating the agreement between CT and IUS with respect to faecal loading in the rectum was published after this RAM exercise. The authors found a high degree of agreement between both modalities, where posterior shadowing and hyperechoic crescents were used to define faecal loading with IUS [22].

IUS can evaluate colonic shape and architecture, with changes in haustral patterns potentially indicating faecal loading. However, the exact characteristics of a loaded colon remain poorly defined, and data on the relationship between faecal loading and haustral shape are limited. One study compared faecal loading on IUS and CT, suggesting that haustral markings correlate more with stool hardness than the presence of faecal loading alone [24]. Haustral markings may also be lost with inflammation in patients with inflammatory bowel disease; however, associated features such as submucosal prominence or increased wall layer accentuation may suggest an alternate explanation for this finding [27]. While it was considered appropriate that colonic distension is associated with faecal loading, a definitive cut-off diameter was not able to be defined, and the accepted cutoff of 50 mm was derived from studies of toxic megacolon rather than faecal loading [16].

Uncertainty regarding the role of X-ray in the assessment of faecal loading and constipation was due mainly to inter-rater variability in scoring tools for both paediatric and adult patients

as well as recommendations against this form of assessment in paediatric constipation [28–31]. There was uncertainty among panellists about the role of CT in evaluating constipation, likely due to radiation risks rather than the accuracy of the modality [5, 32]. However, consistent with current evidence, panellists felt it appropriate that CT can help exclude pathologies such as strictures and malignancy when clinical assessment indicates potential secondary causes of constipation [33, 34]. The authors also acknowledge, however, that the gold standard for evaluating colonic strictures and malignancy remains colonoscopy; in order of least invasive investigation, however, CT and colonoscopy were discussed in addition to IUS. The uncertainty surrounding IUS stems largely from the heterogeneity of current studies and lack of prospective trials in adults, preventing generalisable recommendations to IUS as a whole [6, 35]. The panel recognises the importance of further, well-designed, prospective trials in both adults and paediatrics to further define the capabilities of IUS on constipation assessment. While colonic motility studies were not considered useful for defining faecal loading, colonic motility correlates well with symptoms in adults and children [36, 37]. Although the panel considered it inappropriate to use motility studies in the assessment of faecal loading, they did acknowledge the accuracy of this test in the literature. However, the use of colonic motility studies in diagnosing constipation was not commonly used by many panellists, likely due to regional differences in access and expertise. MRI was considered inappropriate as a tool in the assessment of faecal loading due to cost and accessibility, although dynamic pelvic MRI was considered useful in the assessment of anorectal and pelvic floor pathology such as dyssynergic defecation [38, 39].

This study had several strengths and weaknesses. The results were derived from an international, multi-disciplinary panel of IUS experts experienced in adult and paediatric gastroenterology and DGBI management. Statements were informed by a recent systematic review of luminal content assessment using IUS [6]. One paediatric gastroenterologist was included in the panel; however, given this panellist's expertise in IUS, it was felt that their contribution regarding the role in paediatrics, especially limitations of age-related anatomic variability, were important contributions to discussion. The study findings were partially limited by a lack of robust and prospective, validated data evaluating the role of IUS in constipation assessment. Most data were from retrospective or unblinded studies where sonographic parameters are extrapolated for clinical use. Whether the identification of faecal loading results in clinically meaningful changes following therapy was not discussed in this RAM. Available literature on response to therapy is limited in study design and heterogeneity in findings, limiting the ability of this panel to make firm recommendations [35]. One prospective study did not find a correlation between IUS-diagnosed faecal loading and patient-reported symptoms; the authors, however, commented on the ability of IUS to differentiate the phenotypes of irritable bowel syndrome and avoid suspected constipation rather than diarrhoea, a relevant clinical use [8]. Here may lie the strengths in using IUS as an adjunct tool in the assessment of suspected constipation rather than wholly replacing conventional scoring tools and history taking. The statements generated by the panel are to serve as a guide for clinicians who utilise IUS to identify factors consistent with faecal loading.

In conclusion, the findings of this RAM study on the use of IUS to assess constipation and luminal contents provide a framework for clinical practice and have illuminated the need for further research in the area. While IUS holds promise as a non-invasive and cost-effective tool in the assessment of DGBI, future well-designed prospective clinical trials are needed to validate and define the optimal clinical application of IUS in DGBI.

### Author Contributions

**Ryan M. Mathias:** conceptualization, formal analysis, visualization, writing – original draft, writing – review and editing, methodology. **Thomas M. Goodsall:** conceptualization, writing – review and editing, supervision, methodology. **Claire E. Parker:** writing – review and editing, formal analysis. **Alice S. Day:** writing – review and editing, supervision. **Yoon K. An:** writing – review and editing, methodology. **Brandon Baraty:** methodology, writing – review and editing. **Chamara Basnayake:** methodology, writing – review and editing. **Jakob Begun:** methodology, writing – review and editing. **Ray K. Boyapati:** methodology, writing – review and editing. **Rebecca Burgell:** methodology, writing – review and editing. **Michael T. Dolinger:** methodology, writing – review and editing. **Giovanni Maconi:** methodology, writing – review and editing. **Kerri L. Novak:** methodology, writing – review and editing. **Shintaro Sagami:** methodology, writing – review and editing. **Rebecca L. Smith:** methodology, writing – review and editing. **Ashish R. Srinivasan:** methodology, writing – review and editing. **Stuart A. Taylor:** methodology, writing – review and editing. **Vipul Jairath:** conceptualization, methodology. **Christopher Ma:** conceptualization, methodology. **Robert V. Bryant:** conceptualization, methodology, writing – review and editing, supervision, formal analysis.

### Acknowledgements

The primary author would like to thank The Hospital Research Foundation for their generous support of this work, both through the Michell McGrath Fellowship as well as through procurement of the intestinal ultrasound machine at The Queen Elizabeth Hospital. Open access publishing facilitated by The University of Adelaide, as part of the Wiley - The University of Adelaide agreement via the Council of Australian University Librarians.

### Conflicts of Interest

R.M.M. has received travel support from Dr. Falk Pharma and speaker fees from Johnson and Johnson (Janssen). T.M.G. has received grant support from GENIUS and Janssen; and speaker fees from Janssen and Abbvie. C.E.P. is an employee of Alimentiv Inc. A.S.D. no disclosures. Y.K.A. has received consulting and speaker fees from AbbVie, Alimentiv, Bristol Myers Squibb, Eli Lilly, Dr. Falk, Ferring, GlaxoSmith Kline, Janssen, Pfizer, Samsung, Sandoz, Shire, and Takeda Pharmaceuticals; advisory board fees from AbbVie, Bristol Myers Squibb, Chiesi, Janssen, Microba, NPS Medicine Wise, the Council of Therapeutic Advisory Group (CATAG), and Takeda Pharmaceuticals; and research and educational support from AbbVie, Bristol Myers Squibb, Cannon, Celltrion, Chiesi, Dr. Falk, Ferring, Janssen, Pfizer, Samsung, Sandoz, Siemen, and Takeda Pharmaceuticals. B.B. no disclosures. C.B. has served as a speaker for Ferring Pharmaceuticals, Dr. Falk Pharmaceuticals, Takeda Pharmaceuticals and Dr. Reddy's Pharmaceuticals. J.B. has received honoraria, research grants or consulting fees from Abbvie, Janssen, Takeda, Pfizer, Ferring, Bristol Myers Squibb, Gilead, Tillott's, Sandoz, Celltrion, Chiesi, Dr. Falk, Microba, Glaxo Smith Klein, Antara, Suono, Therpeutic Guidelines, Research Review, NHMRC, US Department of Defence, The Gutsy Foundation, The Gastroenterological Society of Australia, The University of Queensland, The Viertel Foundation, and The Mater Foundation. R.K.B. has received speaker fees from Abbvie and Takeda. Education grant from Dr. Falk Pharma. R.B. speakers fees for Bayer and Dr. Falk

Pharma. M.T.D. is a consultant for Neurologica Corp., a subsidiary of Samsung Electronics Co Ltd., Pfizer, and Johnson and Johnson. G.M. has received fees from Abbvie, Arena Pharmaceuticals, Alfa-Wasserman, Fresenius-Kabi, Gilead, Jansen Cilag, and Roche. Support from Takeda, Abbvie, and Alfa-Wasserman. K.L.N. has served as an advisory board member or speaker for Pfizer, AbbVie, Eli Lilly, Johnson and Johnson Pharmaceuticals, Takeda Pharmaceutical Co., Bristol Myers Squibb, Amgen, Fresenius Kabi, and Celltrion and has received research grants from Pfizer and Johnson Pharmaceuticals. S.S. has served as an advisory board member or speaker for AbbVie, Alimentiv, Eli Lilly, Janssen Pharmaceutical K.K., Gilead Sciences Inc., JIMRO Co. Ltd., KISSEI Pharmaceutical Co. Ltd., Kyorin Pharmaceutical Co. Ltd., Mitsubishi Tanabe Pharma Corporation, EA Pharma Co., Takeda Pharmaceutical Co. Ltd., Nippon Kayaku Co. Ltd., and Zeria Pharmaceutical Co. Ltd. and has received research grants from Gilead Sciences, Bristol-Myers Squibb, and Ferring Pharmaceuticals. R.L.S. has received speaker honoraria from AbbVie. A.R.S. AS has served as a speaker for Sandoz and Arrowtex Pharmaceuticals, and received advisory fees from Abbvie, Amgen, Arrotex Pharmaceuticals, Pfizer, Takeda Pharmaceuticals, and Dr. Falk Pharmaceuticals. S.A.T. has received a research grant from Takeda and is a research consultant AstraZeneca. He is a share holder for Motilent. V.J. consults/advises for AbbVie, Alimentiv, Altrubio, Amgen, AnaptysBio, Arena Pharmaceuticals, Asahi Kasei Pharma, Asieris, Astra Zeneca, BiomeBank, Boehringer Ingelheim, Bristol Myers Squibb, Calluna Pharma, Celltrion, Eli Lilly, Endpoint Health, Ensho Therapeutics, Entera, Exeliom Biosciences, Ferring, Flagship Pioneering, Fresenius Kabi, GlaxoSmithKline, Genentech, Gilead, Janssen, Merck, MRM Health, Nxera Therapeutics, Pandion, Pendopharm, Pfizer, Protagonist, Reistone Biopharma, Roche, Roivant, Sandoz, Sanofi, Second Genome, Sorriso, Spyre Therapeutics, Takeda, Teva, Tillotts, Ventyx, Vividion and has received speaker fees for AbbVie, Ferring, Fresenius Kabi, Bristol Myers Squibb, Galapagos, Janssen, Pfizer, Takeda, Tillotts. C.M. Christopher Ma has received consulting fees from AbbVie, Alimentiv, Amgen, AVIR Pharma Inc., Bristol Myers Squibb, Celltrion, Eli Lilly, Ferring, Forte Biosciences, Fresenius Kabi, Gilead, Janssen, McKesson, Mirador Therapeutics, Mylan, Pendopharm, Pfizer, Prometheus Biosciences Inc., Roche, Sanofi, Takeda, Tillotts Pharma; speaker's fees from AbbVie, Amgen, AVIR Pharma Inc., Alimentiv, Bristol Myers Squibb, Eli Lilly, Ferring, Fresenius Kabi, Janssen, Merck, Organon, Pendopharm, Pfizer, Sanofi, Takeda, Tillotts Pharma; royalties from Springer Publishing; research support from AbbVie, Eli Lilly, Ferring, Pfizer. R.V.B. has received grant/research support/speaker honoraria/advisory board fees from AbbVie, Ferring, Janssen, Shire, Takeda, GlaxoSmithKline, Bristol Myers Squibb, and Emerge Health; and is a shareholder in Biomebank.

### Data Availability Statement

Data, analytic methods, and study materials may be made available to other researchers on a case-by-case basis by contacting the corresponding author.

### References

1. J. Ilvemark, T. Hansen, T. M. Goodsall, et al., "Defining Transabdominal Intestinal Ultrasound Treatment Response and Remission in Inflammatory Bowel Disease: Systematic Review and Expert Consensus Statement," *Journal of Crohn's & Colitis* 16, no. 4 (2022): 554–580.
2. R. V. Bryant, A. B. Friedman, E. K. Wright, et al., "Gastrointestinal Ultrasound in Inflammatory Bowel Disease: An Underused Resource With Potential Paradigm-Changing Application," *Gut* 67, no. 5 (2018): 973–985.
3. D. A. Drossman and W. L. Hasler, "Rome IV-Functional GI Disorders: Disorders of Gut-Brain Interaction," *Gastroenterology* 150, no. 6 (2016): 1257–1261.
4. A. D. Sperber, S. I. Bangdiwala, D. A. Drossman, et al., "Worldwide Prevalence and Burden of Functional Gastrointestinal Disorders,

- Results of Rome Foundation Global Study," *Gastroenterology* 160, no. 1 (2021): 99–114.e3.
5. Y. B. Hadi, A. A. Khan, S. F. Z. Naqvi, S. Khan, J. Thompson, and J. T. Kupec, "Are we Overradiating Patients With Irritable Bowel Syndrome?," *Inflammatory Intestinal Diseases* 6, no. 1 (2021): 32–37.
6. R. M. Mathias, M. K. W. Chu, S. Edwards, et al., "Meta-Analysis: Intestinal Ultrasound to Evaluate Colonic Contents and Constipation," *Alimentary Pharmacology & Therapeutics* 60, no. 1 (2024): 6–16.
7. S. Oenkedkacnk, "Ultrasonography Evaluation of Constipation in Paediatric Age Group," *Pediatric Radiology* 53, no. 2 (2023): 139–473.
8. C. Brick, H. Su, K. Taylor, et al., "Moving Beyond Symptom Criteria to Diagnose and Treat Functional Disorders: Patient-Reported Symptoms of Functional Lower Gastrointestinal Disorders Correlate Poorly With Objective Assessment of Luminal Contents Seen on Intestinal Ultrasound," *Journal of Clinical Medicine* 13, no. 16 (2024): 4759, [https://mdpi-res.com/d\\_attachment/jcm/jcm-13-04759/article\\_deploy/jcm-13-04759.pdf?version=1723543179](https://mdpi-res.com/d_attachment/jcm/jcm-13-04759/article_deploy/jcm-13-04759.pdf?version=1723543179).
9. G. Maconi, T. Hausken, C. F. Dietrich, et al., "Gastrointestinal Ultrasound in Functional Disorders of the Gastrointestinal Tract – EFSUMB Consensus Statement," *Ultrasound Int Open* 7, no. 1 (2021): E14–e24.
10. M. Matsumoto, N. Misawa, M. Tsuda, et al., "Expert Consensus Document: Diagnosis for Chronic Constipation With Faecal Retention in the Rectum Using Ultrasonography," *Diagnostics (Basel, Switzerland)* 12, no. 2 (2022): 300.
11. K. Fitch, S. J. Bernstein, M. D. Aguilar, et al., *The RAND/UCLA Appropriateness Method User's Manual* (RAND Corporation, 2001).
12. D. A. Drossman and J. Tack, "Rome Foundation Clinical Diagnostic Criteria for Disorders of Gut-Brain Interaction," *Gastroenterology* 162, no. 3 (2022): 675–679.
13. A. J. Klijn, M. Asselman, M. A. W. Vijverberg, et al., "The Diameter of the Rectum on Ultrasonography as a Diagnostic Tool for Constipation in Children With Dysfunctional Voiding," *Journal of Urology* 172, no. 5 Pt 1 (2004): 1986–1988.
14. C. Gatzinsky, U. Sillén, H. Borg, H. Boström, K. Abrahamsson, and S. Sjöström, "Transabdominal Ultrasound of Rectal Diameter in Healthy Infants: A Prospective Cohort Study During the First Year of Life," *Journal of Paediatrics and Child Health* 59, no. 9 (2023): 1021–1027.
15. A. M. Hamdy, H. M. Sakr, I. S. Boules, and Y. M. M. Awad, "The Role of Rectal Ultrasound in Children With Functional Constipation," *Journal of Paediatrics and Child Health* 59, no. 3 (2023): 533–536.
16. G. Maconi, C. Rigazio, and E. Ercole, "Bowel Ultrasound: Investigation Technique and Normal Findings," in *Ultrasound of the Gastrointestinal Tract*, ed. G. Maconi and G. Bianchi Porro (Springer Berlin Heidelberg, 2014), 1–6.
17. L. Pensabene, C. Buonomo, L. Fishman, D. Chitkara, and S. Nurko, "Lack of Utility of Abdominal x-Rays in the Evaluation of Children With Constipation: Comparison of Different Scoring Methods," *Journal of Pediatric Gastroenterology and Nutrition* 51, no. 2 (2010): 155–159.
18. T. J. Barloon and C. C. Lu, "Diagnostic Imaging in the Evaluation of Constipation in Adults," *American Family Physician* 56, no. 2 (1997): 513–520.
19. R. Smith, K. Taylor, A. Friedman, et al., "The Assessment of Faecal Loading in Patients With Ulcerative Colitis Is Comparable Between Gastroenterologists Who Perform Gastrointestinal Ultrasound," *Journal of Gastroenterology and Hepatology (Australia)* 35, no. Suppl 1 (2020): 113–114.
20. R. P. Luber, K. M. Taylor, H. Y. Su, et al., "Superior Performance of Gastrointestinal Ultrasound Over Abdominal x-Ray in the Assessment of Constipation," *Gastroenterology* 156, no. 6 (2019): S-594–S-595.
21. T. M. Goodsall, R. Noy, T. M. Nguyen, S. P. Costello, V. Jairath, and R. V. Bryant, "Systematic Review: Patient Perceptions of Monitoring Tools in Inflammatory Bowel Disease," *Journal of the Canadian Association of Gastroenterology* 4, no. 2 (2021): e31–e41.
22. N. Misawa, M. Matsumoto, M. Tsuda, et al., "Diagnostic Ability of Ultrasonography Compared With Computed Tomography for Assessing Rectal Feces," *Journal of the Anus, Rectum and Colon* 8, no. 2 (2024): 126–131.
23. G. Doğan, M. KeÇEİİ, S. Yavuz, et al., "Measurement of Rectal Diameter and Anterior Wall Thickness by Ultrasonography in Children With Chronic Constipation," (2021).
24. K. Yabunaka, J. Matsuo, A. Hara, et al., "Sonographic Visualization of Fecal Loading in Adults: Comparison With Computed Tomography," *Journal of Diagnostic Medical Sonography* 31, no. 2 (2015): 86–92.
25. S. Tanaka, K. Yabunaka, M. Matsumoto, et al., "Fecal Distribution Changes Using Colorectal Ultrasonography in Older People With Physical and Cognitive Impairment Living in Long-Term Care Facilities: A Longitudinal Observational Study," *Healthcare (Basel)* 6, no. 2 (2018): 55.
26. F. G. Sommer and K. J. Taylor, "Differentiation of Acoustic Shadowing due to Calculi and Gas Collections," *Radiology* 135, no. 2 (1980): 399–403.
27. A. Kellar, M. Dolinger, K. L. Novak, M. Chavannes, M. Dubinsky, and H. Huynh, "Intestinal Ultrasound for the Pediatric Gastroenterologist: A Guide for Inflammatory Bowel Disease Monitoring in Children: Expert Consensus on Behalf of the International Bowel Ultrasound Group (IBUS) Pediatric Committee," *Journal of Pediatric Gastroenterology and Nutrition* 76, no. 2 (2023): 142–148.
28. D. A. Rodriguez, G. Dahlwi, M. Gould, M. Marcon, and M. Benninga, "The Diagnostic Accuracy of Abdominal X-Ray in Childhood Constipation: A Systematic Review of the Literature," *Gastrointestinal Disorders* 6, no. 1 (2024): 94–102.
29. B. E. Driver, C. Chittineni, G. Kartha, et al., "Utility of Plain Abdominal Radiography in Adult ED Patients With Suspected Constipation," *American Journal of Emergency Medicine* 38, no. 6 (2020): 1092–1096.
30. M. M. Tabbers, C. DiLorenzo, M. Y. Berger, et al., "Evaluation and Treatment of Functional Constipation in Infants and Children: Evidence-Based Recommendations From ESPGHAN and NASPGHAN," *Journal of Pediatric Gastroenterology and Nutrition* 58, no. 2 (2014): 258–274.
31. S. Cowlam, R. Vinayagam, U. Khan, et al., "Blinded Comparison of Faecal Loading on Plain Radiography Versus Radio-Opaque Marker Transit Studies in the Assessment of Constipation," *Clinical Radiology* 63, no. 12 (2008): 1326–1331.
32. A. N. Desmond, S. McWilliams, M. M. Maher, F. Shanahan, and E. M. Quigley, "Radiation Exposure From Diagnostic Imaging Among Patients With Gastrointestinal Disorders," *Clinical Gastroenterology and Hepatology* 10, no. 3 (2012): 259–265.
33. M. Haraikawa, T. Takeda, S. Oki, et al., "Correlation Between Constipation Symptoms and Abdominal CT Imaging: A Cross-Sectional Pilot Study," *Journal of Clinical Medicine* 12, no. 1 (2023): 20230101.
34. S. Gryspeerdt and P. Lefere, "Chronic Diverticulitis vs. Colorectal Cancer: Findings on CT Colonography," *Abdominal Imaging* 37, no. 6 (2012): 1101–1109.
35. J. Vos, M. N. Bloem, A. de Geus, et al., "Accuracy of Transabdominal Ultrasound to Diagnose Functional Constipation and Fecal Impaction in Children: A Systematic Review and Meta-Analysis," *Pediatric Radiology* 54, no. 13 (2024): 2227–2242.
36. V. Machado, E. Fonseca, A. Monteiro, et al., "Colonic Transit Time in Children and Adolescents With Bowel and Bladder Dysfunction," *Neurourology and Urodynamics* 33, no. 6 (2014): 844–845.
37. Y. S. Nam, A. J. Pikarsky, S. D. Wexner, et al., "Reproducibility of Colonic Transit Study in Patients With Chronic Constipation," *Diseases of the Colon and Rectum* 44, no. 1 (2001): 86–92.

38. S. S. Rao, R. Ozturk, and L. Laine, "Clinical Utility of Diagnostic Tests for Constipation in Adults: A Systematic Review," *American Journal of Gastroenterology* 100, no. 7 (2005): 1605–1615.

39. J. G. Fletcher, R. F. Busse, S. J. Riederer, et al., "Magnetic Resonance Imaging of Anatomic and Dynamic Defects of the Pelvic Floor in Defecatory Disorders," *American Journal of Gastroenterology* 98, no. 2 (2003): 399–411.

### **Supporting Information**

Additional supporting information can be found online in the Supporting Information section.