



Minerva Access is the Institutional Repository of The University of Melbourne

Author/s:

Navalón, P;Cañada, Y;Merizalde, M;Sierra, P;García-Blanco, A;Domínguez-Carabantes, A;Berk, M

Title:

A case of antibiotic-associated mania in a 67-year-old woman

Date:

2019-11-01

Citation:

Navalón, P., Cañada, Y., Merizalde, M., Sierra, P., García-Blanco, A., Domínguez-Carabantes, A. & Berk, M. (2019). A case of antibiotic-associated mania in a 67-year-old woman. *Bipolar Disorders*, 21 (7), pp.670-672. <https://doi.org/10.1111/bdi.12823>.

Persistent Link:

<https://hdl.handle.net/11343/286390>

DR. PABLO NAVALÓN (Orcid ID : 0000-0001-6860-4837)

DR. PILAR SIERRA (Orcid ID : 0000-0001-6132-5608)

Article type : Clinical Curiosity

A case of antibiotic associated mania in a 67-years-old woman.

An example of antibiomania.

Pablo Navalón¹, Yolanda Cañada¹, Milton Merizalde¹, Pilar Sierra^{1,2}, Ana García-Blanco³, Alberto Domínguez¹, Michael Berk^{4,5}.

¹Department of Psychiatry and Clinical Psychology. Hospital Universitario y Politécnico La Fe. (Valencia, Spain).

²Universidad de Valencia (Valencia, Spain)

³Instituto de Investigación Sanitaria (IIS) La Fe. (Valencia, Spain).

⁴IMPACT Strategic Research Centre (Barwon Health, Geelong, Victoria, Australia)

⁵Orygen, The Centre of Excellence in Youth Mental Health, the Department of Psychiatry and the Florey Institute of Neuroscience and Mental Health, The University of Melbourne, Australia.

Corresponding author:

Pablo Navalón.

Hospital Universitari i Politécnic La Fe, Av. de Fernando Abril Martorell, 106 46026

Valencia (Spain)

Telephone: +34 961245553

¹ Dr. Pablo Navalón and Dr. Yolanda Cañada should be considered joint first author.

This is the author manuscript accepted for publication and has undergone full peer review but has not been through the copyediting, typesetting, pagination and proofreading process, which may lead to differences between this version and the [Version of Record](#). Please cite this article as [doi: 10.1111/BDI.12823](https://doi.org/10.1111/BDI.12823)

e-mail: ipablonavalon@gmail.com

Key message

Antibiomania is the term introduced to describe antibiotic associated mania. Antituberculous agents, macrolides, and quinolones have been previously related to antibiomania, and clarithromycin seems to be the antibiotic most commonly implicated. Here, we present a case of a 67-years-old woman who suffered a first manic episode after taking *Helicobacter Pylori* eradicating treatment.

Introduction

Antibiotic associated manic episodes, “antibiomania”, have been previously documented in the literature. In a recent review of antibiomania¹, twelve different antibacterial agents were implicated. Among them, antituberculous agents, macrolides, and quinolones were the most common treatments. However, causal links and the pathophysiological mechanism of antibiomania remains elusive. Clarithromycin seems to be the antibiotic most frequently associated with antibiomania, followed by ciprofloxacin and ofloxacin. Antibiomania has also been related to treatment of *Helicobacter Pylori*.

Case Presentation

A 67-years-old woman without previous contact with psychiatric services was admitted to the psychiatric ward with a five-day history of behavioral disturbance. She had been taking lorazepam 1mg/day for chronic insomnia prescribed by her General Practitioner for more than ten years. She suffered from hypertension, and was taking amlodipine and olmesartan. Four years previously, she had been diagnosed with a malignant melanoma,

received chemotherapy and at the time of the admission was free of disease. Her brothers and mother had histories of depressive disorder and her father had alcohol use disorder.

Two months before the admission, she received eradicating treatment for *Helicobacter Pylori* with metronidazole 125mg, bismuth 140mg, and tetracycline 125mg. This treatment was ineffective so she started a new regimen with clarithromycin 500 mg/12h, metronidazole 500 mg/12h and amoxicillin 100 mg/12h ten days before her admission in the psychiatric ward.

Five days after the introduction of the new treatment, the patient attended the emergency service with anxiety symptoms. The symptoms were interpreted as side effects of the antibiotics, so the treatment was withdrawn, she was discharged and no psychopharmacologic treatment was added. However, over the following days, the patient became worse. Her sleep diminished, she began to feel increasingly energetic, elated, and her family found her strangely talkative, euphoric, and irritable. Three days later, the patient became aggressive, suffered from total insomnia, and started to develop psychotic symptoms. She began to read the Bible intensely and to feel self-referent with the texts. Messianic grandiose delusional ideas appeared; she claimed to be the new messiah. Therefore, her family brought her to the emergency service again. After psychiatric evaluation, 10mg of intramuscular Olanzapine was given because of aggression. Soliloquies were observed and she reported clearly hearing God, suggesting auditory hallucinations. Physical examination was normal and no cognitive signs of confusion or disorientation were present. Alcohol and substance consumption were not confirmed by history nor by blood and urine testing. The Young Mania Rating Scale (YMRS) was done with a score of 46 (mania). An initial diagnosis of a manic episode was made and the patient was admitted to the psychiatric ward.

During hospitalization, a head CT scan, an EEG, blood and urine tests (including TSH and cortisol levels) and chest X-ray were carried out, with no pathological findings. She was also screened for cognitive impairment showing normal performance (MMSE=27). Oral olanzapine 10mg/day was administered, with clear improvement within 48 hours. By the third day she was in clinical remission, therefore the antipsychotic was

withdrawn. However, insomnia and anxiety reappeared, so olanzapine was reintroduced at a dose of 5mg.

A week after the admission, her YMRS was 6 (signifying euthymia). She was discharged on Olanzapine 5mg without a mood stabilizer. The patient was diagnosed with a probable manic episode induced by antibiotics (probably clarithromycin) and she was referred to the Psychiatric Clinic. After three months follow-up, her treating psychiatrist discontinued Olanzapine and introduced Quetiapine 50mg to control chronic sleep disturbances. No other affective episodes have appeared since then. Figure 1 shows the clinical course of the patient.

Discussion

Although it is difficult to differentiate the side effects of a treatment from primary neuropsychiatric symptoms, there are details which suggest a causal relation between clarithromycin and the patient's symptoms. Firstly, a first manic episode in older adults is frequently secondary to toxic or medical reasons. A neurological, endocrinological, infectious or oncologic origin had been ruled out, so a toxic origin was suspected. Secondly, a temporal causal frame is plausible, as the eradicating treatment for *Helicobacter Pylori* was introduced five days before the onset of symptoms. Thirdly, the clinical features of the illness match with previous descriptions; psychiatric symptoms tend to appear less than a week after the administration of the antibiotic, the most frequent early symptoms are irritability and insomnia, 60% of patients show psychotic features, the median age is 60 years old, and this adverse event occurs more frequently in women². Finally, clarithromycin has been previously associated with side effects such as mania and agitation.

Clarithromycin has documented neurobiological effects that overlap in part with the known pathophysiology of bipolar disorder. It has been demonstrated that clarithromycin increases excitability in CA3 pyramidal neurons. These changes are associated with its influence on inhibitory synaptic inputs and/or the blocking of tonic inhibition generated from extrasynaptic GABA receptors³. Changes in the local microbiota, neurotoxic effects or drug-interactions have been also proposed among other possible explanations¹. Clarithromycin has immune modulatory effects which may

be salient given the role of immune dysregulation in bipolar disorder. Moreover, other antibiotics have known mood elevating effects, such as metronidazole, although previous use in this patient did not induce any effect. The first antidepressant, iproniazid, was serendipitously discovered after observations of mood elevation in people treated for tuberculosis, and minocycline has meta-analytic level evidence that it elevates mood in depressed individuals⁴. These findings suggest the potential of some antibiotics as treatments for unipolar and bipolar depression, albeit carrying a risk of mania induction in vulnerable individuals.

However, caveats are necessary. Association is not causation. The patient was on other antibiotics as well as an angiotensin agent, which may itself increase mood, either alone or synergistically with other agents⁵. Finally, the rapid onset of the psychiatric symptoms after the introduction of the treatment, clinical remission after discontinuation without requiring a mood stabilizer, and the absence of other clear causal factors in an older adult without psychiatric history, questions the presence of medication-induced manic episode (possibly secondary to clarithromycin).

Acknowledgements

MB is supported by a National Health and Medical Research Council (NHMRC) Senior Principal Research Fellowship (APP1059660 and APP1156072).

PN and YC are supported by a Spanish Foundation of Psychiatry and Mental Health (FEPSM) Training Abroad Fellowship.

References

1. Lambrichts S, Van Oudenhove L, Sienaert P. Antibiotics and mania: A systematic review. *J Affect Disord.* 2017. doi:10.1016/j.jad.2017.05.029.
2. Neufeld NH, Mohamed NS, Grujich N, Shulman K. Acute Neuropsychiatric Symptoms Associated With Antibiotic Treatment of Helicobacter Pylori Infections: A Review. *J Psychiatr Pract.* 2017;23(1):25-35. doi:10.1097/PRA.000000000000205.

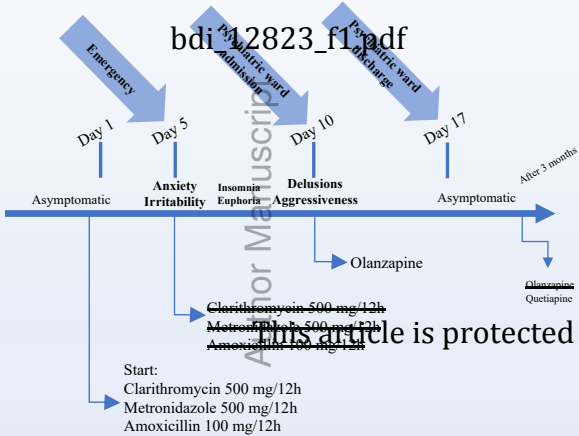
3. Bichler EK, Elder CC, García PS. Clarithromycin increases neuronal excitability in CA3 pyramidal neurons through a reduction in GABAergic signaling. *J Neurophysiol.* 2017;117(1):93-103. doi:10.1152/jn.00134.2016.
4. Rosenblat JD, McIntyre RS. Efficacy and tolerability of minocycline for depression: A systematic review and meta-analysis of clinical trials. *J Affect Disord.* 2018;227:219-225. doi:10.1016/j.jad.2017.10.042.
5. Williams LJ, Pasco JA, Kessing L V, Quirk SE, Fernandes BS, Berk M. Angiotensin Converting Enzyme Inhibitors and Risk of Mood Disorders. *Psychother Psychosom.* 2016;85(4):250-252. doi:10.1159/000444646.

Figure legends.

Figure 1. Clinical course of the patient.

Statement of informed consent

The patient gave her permission to report the case in a publication.



Author Manuscript

~~Clarithromycin 500 mg/12h~~
~~Metronidazole 500 mg/12h~~
~~Amoxicillin 100 mg/12h~~

Start:
Clarithromycin 500 mg/12h
Metronidazole 500 mg/12h
Amoxicillin 100 mg/12h

This article is protected by copyright. All rights reserved.