



Minerva Access is the Institutional Repository of The University of Melbourne

Author/s:

Dean, S;McCracken, J;Kosmider, S;Herath, D

Title:

Lambert–Eaton myasthenic syndrome developing post-diagnosis of small-cell lung cancer

Date:

2018-12-01

Citation:

Dean, S., McCracken, J., Kosmider, S. & Herath, D. (2018). Lambert–Eaton myasthenic syndrome developing post-diagnosis of small-cell lung cancer. *Internal Medicine Journal*, 48 (12), pp.1541-1542. <https://doi.org/10.1111/imj.14128>.

Persistent Link:

<https://hdl.handle.net/11343/285008>

Dean Samantha (Orcid ID: 0000-0001-8183-4119)

1

Title: A case of Lambert-Eaton Myasthenic Syndrome developing post-diagnosis of small-cell lung cancer

Authors:

1. Dr Samantha Dean
Basic Physician Trainee
Sunshine Hospital, Western Health
2. Dr James McCracken
Medical Oncology Registrar
Sunshine Hospital, Western Health
3. Dr Suzanne Kosmider
Medical Oncologist
Sunshine Hospital, Western Health
4. Dr Dishan Herath
Medical Oncologist
Sunshine Hospital, Western Health

All of the above named people contributed to the conception, writing and editing of the letter/correspondence in accordance to ICMJE guidelines.

Correspondence author details:

Address: The Royal Melbourne Hospital, 300 Grattan Street, Parkville VIC 3050

Email: Samantha.Dean@mh.org.au

Phone: (03) 9342 7000

Acknowledgements: none

Word count of main text: 610

Key words:

1. Lambert-Eaton Myasthenic Syndrome
2. Small-cell lung cancer
3. Voltage-gated calcium channel antibodies
4. Myalgia
5. Muscle stiffness

This is the author manuscript accepted for publication and has undergone full peer review but has not been through the copyediting, typesetting, pagination and proofreading process, which may lead to differences between this version and the Version of Record. Please cite this article as doi: [10.1111/imj.14128](https://doi.org/10.1111/imj.14128)

Lambert-Eaton Myasthenic Syndrome (LEMS) is an autoimmune disorder characterised by proximal muscle weakness, reduced reflexes and autonomic symptoms thought to be mediated by autoantibodies targeting the voltage-gated calcium channels (VGCCs) at the pre-synaptic neuromuscular junction¹.

Approximately 50% of LEMS cases are tumour-related and almost exclusively due to small cell lung cancer (SCLC). Diagnosis of LEMS usually precedes the diagnosis of SCLC^{1,2}. Maddison et al found a survival advantage for patients with SCLC diagnosed with LEMS that remained after taking into account independent prognostic variables³. It is unclear whether this survival advantage is due to lead-time bias⁴. We report an interesting case of a 65-year-old man presenting with LEMS after diagnosis of SCLC with aggressive disease and a poor prognosis. To the best of our knowledge this is the first case reported in the literature where the signs and symptoms of LEMS developed post initiation of chemotherapy for SCLC.

Our patient was diagnosed with extensive-stage SCLC after an acute presentation with chest pain and haemoptysis. He had no significant past medical history and prior to his diagnosis he was working full-time. His performance status was ECOG 1. The chest pain and haemoptysis resolved after commencing first-line palliative chemotherapy (Carboplatin and Etoposide). His re-staging scan after cycle two demonstrated a partial response. Despite initial clinical and radiological

improvement, he began to decline soon after completing cycle two. He described generalised myalgia and his mobility deteriorated; requiring the use of a single-point stick. Despite the imaging findings, it was felt that these symptoms were a manifestation of disease progression.

Prior to cycle three, he continued to decline, having falls where he described his entire body locking up like a board. He was subsequently admitted to hospital. His predominant symptom was generalised stiffness. He was not taking any regular medications (specifically neither metoclopramide nor anti-cholinergics). Relevant neurological examination findings on admission included marked rigidity in upper and lower limbs, with 4/5 power in hip flexion and normal reflexes. He had no abnormal cranial nerve findings. MRI spine and brain were normal.

Although reflexes were initially normal, subsequently they were reduced in the lower limbs in the morning before he had a chance to mobilise. Exercising after a period of rest resulted in brisk knee jerks consistent with an incrementing response. Nerve conduction studies showed low compound motor action potential (CMAP) amplitudes at baseline with normal sensory studies. There was a decremental pattern on low frequency (3Hz) repetitive nerve stimulation (RNS) testing suggesting a neuromuscular junction disorder. However, on rapid frequency (24Hz) RNS testing there was only a slight incremental pattern that did not meet significance. After

exercise there was a > 60% increase in right medial CMAP amplitude with a change in the wrist to adductor pollicis brevis (APB) amplitude from 4.6mV to 7.4mV (see figure 1). Although an increment of >100% is currently considered gold standard some patients with LEMS do not meet this threshold and it has been suggested that a 60% increment may be a better diagnostic criterion⁵. The positive VGCC antibody result of 192 pM (reference range: <30 pM) further supported the diagnosis of LEMS. Serum anti-glutamic-acid-decarboxylase and anti-amphiphysin antibodies were negative making the differential of Stiff-Person syndrome unlikely. The neurology team were consulted and agreed with the diagnosis of LEMS.

There was clinical improvement initially with dexamethasone 8mg daily and continuation of chemotherapy. However, as was suspected, the presentation of LEMS coincided with disease progression, which was confirmed on subsequent restaging. The profound and disabling myalgia and stiffness returned and he could neither physically or psychologically cope with further chemotherapy. The decision was made to shift management to best supportive care. He was admitted for end-of-life care only 5 months after the diagnosis of SCLC.

This case highlights the importance of considering LEMS in the differential diagnosis of patients who develop new neurological symptoms, including muscle stiffness even after the diagnosis of SCLC is made. In a series of 50 patients, muscle ache or

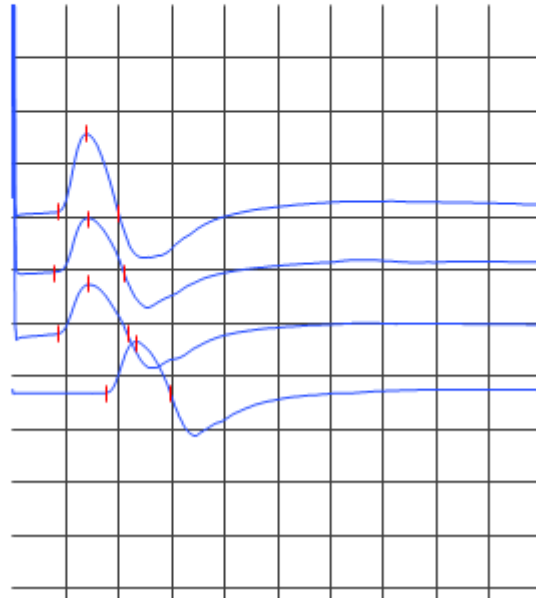
stiffness was the presenting symptom in 18%¹. Although some studies suggest there is a survival advantage with SCLC associated LEMS^{3,4}, our patient had aggressive disease with the development of LEMS as a paraneoplastic phenomenon of disease progression, whilst on treatment.

References:

1. O'Neill JH, Murray NM, Newsom-Davis J. The Lambert-Eaton myasthenic syndrome – a review of 50 cases. *Brain* 1988; **111**: 577–596.
2. Titulaer MJ, Wirtz PW, Willems LN, Van Kralingen KW, Smitt PA, Verschuuren JJ. Screening for small-cell lung cancer: A follow-Up study of patients with Lambert-Eaton Myasthenic syndrome. *J Clin Oncol* 2008; **28**: 4276 – 4281.
3. Maddison P, Gozzard P, Grainge MJ, Lang B. Long-term survival in paraneoplastic Lambert-Eaton myasthenic syndrome. *Neurology* 2017; **88**: 1334-1339.
4. Wirtz PW, Lang B, Graus F, Van Den Maagdenberg AM, Saiz A, De Koning Gans PA, et al. P/Q-type calcium channel antibodies, Lambert-Eaton myasthenic syndrome and survival in small cell lung cancer. *J Neuroimmunol* 2005; **164**: 161 – 165.

5. Oh SJ, Kurokawa K, Claussen GC, Ryan HF. Electrophysiological diagnostic criteria of Lambert-Eaton myasthenic syndrome. *Muscle Nerve* 2005; **32**: 515–520.

Right Medianus Motor			
	Lat	Amp	CV
	ms	mV	m/s
Wrist post 1min Exercise - APB	4.29	7.4	
Wrist - APB	4.37	4.6	
Wrist - APB	3.94	5.1	
Elbow-Wrist	8.75	4.8	60.1



Title: A case of Lambert-Eaton Myasthenic Syndrome developing post-diagnosis of small-cell lung cancer

Authors:

1. Dr Samantha Dean
Basic Physician Trainee
Sunshine Hospital, Western Health
2. Dr James McCracken
Medical Oncology Registrar
Sunshine Hospital, Western Health
3. Dr Suzanne Kosmider
Medical Oncologist
Sunshine Hospital, Western Health
4. Dr Dishan Herath
Medical Oncologist
Sunshine Hospital, Western Health

All of the above named people contributed to the conception, writing and editing of the letter/correspondence in accordance to ICMJE guidelines.

Correspondence author details:

Address: The Royal Melbourne Hospital, 300 Grattan Street, Parkville VIC 3050

Email: Samantha.Dean@mh.org.au

Phone: (03) 9342 7000

Acknowledgements: none

Word count of main text: 610

Key words:

1. Lambert-Eaton Myasthenic Syndrome
2. Small-cell lung cancer
3. Voltage-gated calcium channel antibodies
4. Myalgia
5. Muscle stiffness

Current address of author Samantha Dean: The Royal Melbourne Hospital, 300 Grattan Street, Parkville VIC 3050