



Minerva Access is the Institutional Repository of The University of Melbourne

**Author/s:**

Donadeu, M;Gauci, CG;Poudel, I;Sah, K;Singh, DK;Jabbar, A;Lightowlers, MW

**Title:**

A hyperendemic focus of porcine cystic echinococcosis in the Banke District of Nepal

**Date:**

2020-01-01

**Citation:**

Donadeu, M., Gauci, C. G., Poudel, I., Sah, K., Singh, D. K., Jabbar, A. & Lightowlers, M. W. (2020). A hyperendemic focus of porcine cystic echinococcosis in the Banke District of Nepal. *Acta Tropica*, 201, <https://doi.org/10.1016/j.actatropica.2019.105203>.

**Persistent Link:**

<https://hdl.handle.net/11343/258580>

2

3 A hyperendemic focus of porcine cystic echinococcosis in the Banke  
4 District of Nepal

5

6 Meritxell Donadeu<sup>a,b</sup>, Charles G. Gauci<sup>b</sup>, Ishab Poudel<sup>c</sup>, Keshav Sah<sup>d</sup>, Dinesh Kumar Singh<sup>e</sup>,  
7 Abdul Jabbar<sup>b</sup>, Marshall W. Lightowlers<sup>b,\*</sup>

8

9 <sup>a</sup> Initiative for Neglected Animal Diseases (INAND); PO Box 27, Carshwald, Kyalami 1684, South Africa

10 <sup>b</sup> Faculty of Veterinary and Agricultural Sciences, University of Melbourne, 250 Princes Highway, Werribee Victoria 3030, Australia

11 <sup>c</sup> Department of Poultry Science, College of Agriculture and Life Sciences, 46 old Bully, Mississippi State University, MS 39762 USA

12 <sup>d</sup> Heifer International, G.P.O. Box 6043, Kathmandu, Nepal, <sup>e</sup> Department of Pathology and Clinics (HOD), Tribhuvan University, Institute  
13 of Agriculture and Animal Science, Rampur Campus, Chitwan, Nepal

14

15

---

16 \* Corresponding author at: Faculty of Veterinary and Agricultural Sciences, University of Melbourne,  
17 250 Princes Highway, Werribee Victoria 3030, Australia

18 *E-mail address:* [marshall@unimelb.edu.au](mailto:marshall@unimelb.edu.au) (M.W. Lightowlers)

19

20 Short title: Porcine cystic echinococcosis in Banke District, Nepal

21

22 ABSTRACT

23 Detailed post mortem analyses of 68 free-ranging, slaughter-age pigs from two sites in the  
24 Banke District of Nepal identified 36% as being infected with *Echinococcus granulosus*. The  
25 cysts ranged from infertile, immature cysts a few millimetres in diameter to fertile cysts >10  
26 centimetres in diameter. PCR RFLP and DNA sequencing identified the cysts as being *E.*  
27 *granulosus sensu stricto*. The Banke district has recently been identified as having a high  
28 prevalence of porcine cysticercosis. These data suggest that cestode zoonoses in this, and  
29 possibly other parts of Nepal may be a serious concern for human health. An assessment of the  
30 level of human cystic echinococcosis and neurocysticercosis, in the region is warranted and the  
31 introduction of control measures are required to limit the parasites' transmission.

32

33 *Keywords: Echinococcus granulosus, pig; Nepal*

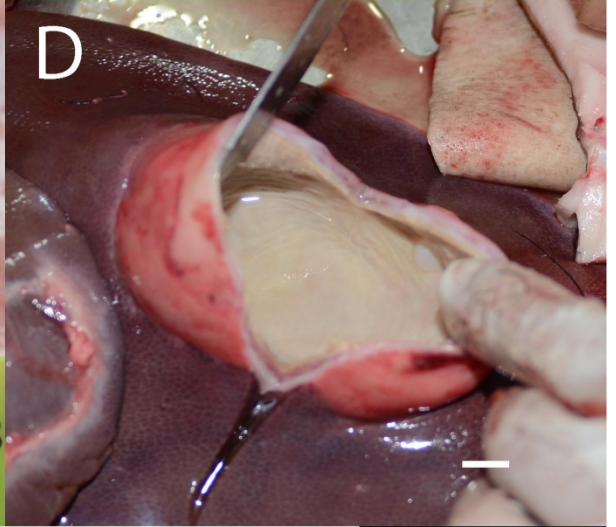
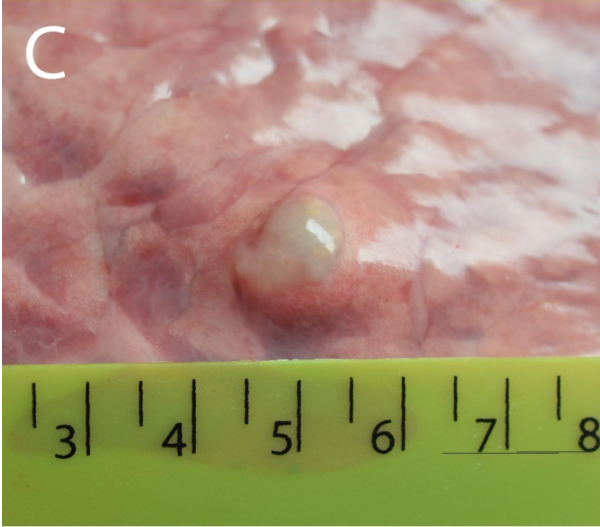
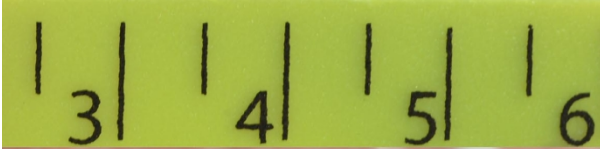
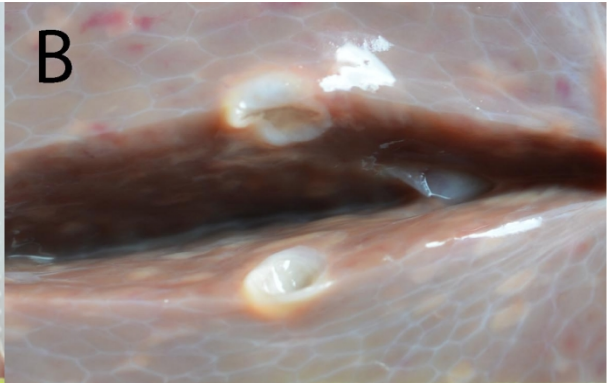
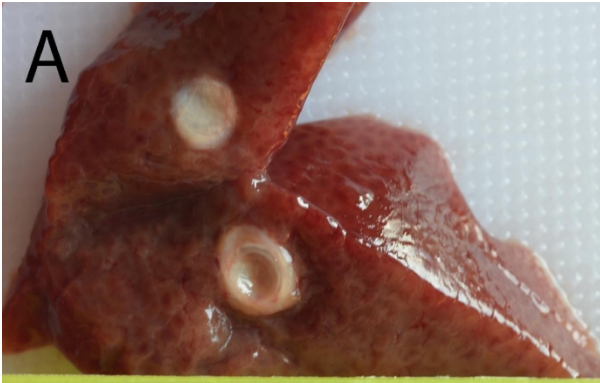
34 Cystic echinococcosis is a zoonotic disease with a worldwide distribution. The disease is most  
35 prevalent in pastoral communities, often transmitted by sheep as intermediate hosts (Deplazes  
36 et al., 2017). However, the disease may be transmitted by a wide variety of domestic livestock  
37 and wild animals (Thompson, 2017). The aetiological agent of 88% of human cystic  
38 echinococcosis is *Echinococcus granulosus sensu stricto* (Alvarez Rojas et al., 2014). Almost  
39 all the remaining proportion of human cystic echinococcosis is caused by a closely related  
40 species within the *E. granulosus sensu lato* group, *Echinococcus canadensis* (genotypes G6  
41 and G7). Pigs are one of the principal animal intermediate hosts for *E. canadensis* (genotype  
42 G7), although they may also be infected with *E. granulosus sensu stricto* ([Cardona & Camino,](#)  
43 [2013](#)).

44 Several reports have identified Nepal as being endemic for cystic echinococcosis (CE).  
45 Joshi et al. (1997) reviewed studies undertaken as early as 1973 on echinococcosis in Nepal,  
46 particularly in abattoirs and hospitals in Kathmandu city, Nepal. Hydatid cysts were found in  
47 slaughtered animals, including in 5% of water buffalos, 3% goats, 8% sheep, and 7% pigs.  
48 During 1994/5, 120 operations for CE were carried out in Kathmandu hospitals and high levels  
49 of serological positivity in tests for hydatid disease were found in Nepalese people (Joshi et al.,  
50 1997).

51 Detailed necropsy investigations were undertaken by Poudel et al. (2019) on 68 free-  
52 roaming, slaughter-age pigs from two areas of the Banke District of Nepal, 33 from Udaypur  
53 Village Development Committee (VDC) and 35 from Hirminiya & Betahani VDC  
54 [enumerating infections with \*Taenia solium\*. Here we report the findings of these necropsies in](#)  
55 [relation to \*E. granulosus\* infections.](#) The necropsies included palpation and slicing at  
56 approximately 5 mm of both the liver and the lungs. Twenty-five animals (36%) were  
57 identified as having CE cysts by macroscopic appearance, thirteen from Udaypur VDC, and  
58 twelve from Hirminiya & Betahani VDC. [The average age of the infected animals was 18](#)

59 months (range 10-34 months). Similar infection rates were seen in both males and females.

60 Twenty animals were found to have cysts exclusively in the lungs, two had cysts exclusively  
61 in the liver and three had cysts in both lungs and liver. Cysts ranged in size from a few  
62 millimetres to more than 8 centimetres in diameter (Fig. 1). Not all specimens were



63

64

65 Fig. 1. Representative images of cystic echinococcus cysts (A-F) identified in the liver or lungs  
66 of free-ranging, slaughter-age pigs from the Banke District of Nepal. Fertile cysts are shown  
67 in panels D and E; protoscolices shown in panel F and insert.

68

69 investigated to identify the presence of protoscolices, however protoscolices and brood  
70 capsules were noted in some of the larger cysts (Fig. 1F). DNA samples from 16 animals  
71 were analysed by PCR RFLP as previously described by Gauci et al. (2019) and were  
72 confirmed to have been *E. granulosus sensu stricto* (genotype G1).

73 There are few reports of *E. granulosus sensu lato* occurring in Nepal. Zhang et al.  
74 (2000) investigated the genotype of cystic echinococcosis in specimens from Nepal and found  
75 both the G1 genotype (*E. granulosus sensu stricto*) and the G5 genotype (*Echinococcus*  
76 *orthleppi*) in buffalo, sheep and goats. Two human cysts were studied, both of which were the  
77 G6 genotype (*E. canadensis*). Zhang and colleagues did not investigate parasite samples from  
78 pigs. Joshi and Yamasaki (2010) reported the presence of two pancreatic CE cysts in Nepalese  
79 pigs which were identified as being *E. granulosus sensu stricto* (genotype G1).

80 Nepal is a developing country with a GDP ranking of 162 out of 187 nations globally  
81 ranked by the International Monetary Fund (<https://www.imf.org/en/Countries/NPL>). The  
82 Nepalese population suffers from a substantial burden of parasitic zoonoses, including CE  
83 (Devleeschauwer et al., 2014). Joshi and Yamasaki (2010) reported a nation-wide prevalence  
84 of CE in Nepal of 55 per 100,000 population based on hospital in-patient records. Little is  
85 known about regional differences in the prevalence of CE in Nepal, however the high  
86 prevalence of *E. granulosus sensu stricto* in pigs in the Banke District warrants further  
87 investigation of human CE cases in the region and, possibly, implementation of control  
88 measures. Two zoonotic diseases that are highly prevalent in free-ranging pigs in the Banke  
89 District of Nepal are caused by cestode parasites, *E. granulosus* and *T. solium*. There are

90 effective and commercially-produced vaccines against both infections (Craig et al., 2017;  
91 Poudel et al., 2019). Potentially, a program of pig vaccination may reduce the incidence of  
92 both CE and neurocysticercosis in communities in this region.

93

#### 94 **Author's contributions**

95 MD, IP, KS, DKS and MWL undertook the necropsies. CGG and AJ undertook the genotyping.

96 All authors contributed to drafting the manuscript.

97

#### 98 **Financial support**

99 Funding is acknowledged from the Australian National Health and Medical Research Council  
100 grant GTN1105448 (MWL)(<https://www.nhmrc.gov.au/>). The funder had no role in study  
101 design, data collection and analysis, decision to publish, or preparation of the manuscript.

102

#### 103 **Conflict of interest**

104 The authors declare that there is no conflict of interest.

#### 105 **References**

106 Alvarez Rojas, C.A., Romig, T., Lightowlers, M.W., 2014. *Echinococcus granulosus sensu*  
107 *lato* genotypes infecting humans - review of current knowledge. *Int.J.Parasitol.* 44, 9-18.

108 [Cardona, G.A., Carmena, D., 2013. A review of the global prevalence, molecular](#)  
109 [epidemiology and economics of cystic echinococcosis in production animals. \*Vet\*](#)  
110 [\*Parasitol\* 192, 10-32.](#)

111 Craig, P.S., Hegglin, D., Lightowlers, M.W., Torgerson, P.R., Wang, Q., 2017.

112 Echinococcosis: control and prevention. *Adv. Parasitol.* 96, 55-158.

113 Deplazes, P., Rinaldi, L., Alvarez Rojas, C.A., Torgerson, P.R., Harandi, M.F., Romig, T.,

114 Antolova, D., Schurer, J.M., Lahmar, S., Cringoli, G., Magambo, J., Thompson, R.C.,

115 Jenkins, E.J., 2017. Global Distribution of alveolar and cystic echinococcosis. Adv.  
116 Parasitol. 95, 315-493.

117 Devleeschauwer, B., Ale, A., Torgerson, P., Praet, N., Maertens de Noordhout, C., Pandey,  
118 B.D., Pun, S.B., Lake, R., Vercruyse, J., Joshi, D.D., Havelaar, A.H., Duchateau, L.,  
119 Dorny, P., Speybroeck, N., 2014. The burden of parasitic zoonoses in Nepal: a  
120 systematic review. PLoS Negl Trop Dis 8, e2634.

121 Gauci, C.G., Ayebazibwe, C., Nsadha, Z., Rutebarika, C., Poudel, I., Sah, K., Singh, D.K.,  
122 Setent, A., Colston, A., Donadeu, M., Lightowers, M.W., 2019. Accurate diagnosis of  
123 lesions suspected of being caused by *Taenia solium* in body organs of pigs with naturally  
124 acquired porcine cysticercosis PLoS Negl Trop Dis 13, e0007408

125 Joshi, D.D., Joshi, A.B., Joshi, H., 1997. Epidemiology of echinococcosis in Nepal. Southeast  
126 Asian J. Trop. Med. Public Health 28 Suppl 1, 26-31.

127 Joshi, D.D., Yamasaki, H., 2010. Histopathological and molecular confirmation of porcine  
128 cystic echinococcosis (CE)/hydatidosis in Nepal. J Inst Med 32, 54-58.

129 Poudel, I., Sah, K., Subedi, S., Kumar Singh, D., Kushwaha, P., Colston, A., Gauci, C.G.,  
130 Donadeu, M., Lightowers, M.W., 2019. Implementation of a practical and effective pilot  
131 intervention against transmission of *Taenia solium* by pigs in the Banke district of Nepal.  
132 PLoS Negl Trop Dis 13, e0006838.

133 Thompson, R.C., 2017. Biology and systematics of echinococcus. Adv. Parasitol. 95, 65-109.

134 Zhang, L.H., Joshi, D.D., McManus, D.P., 2000. Three genotypes of *Echinococcus*  
135 *granulosus* identified in Nepal using mitochondrial DNA markers. Trans R Soc Trop  
136 Med Hyg 94, 258-260.

137

138