



Minerva Access is the Institutional Repository of The University of Melbourne

Author/s:

Ng, KL;Nixon, RL;Grills, C;Tam, MM

Title:

Solution using Stomahesive® wafers for allergic contact dermatitis caused by isobornyl acrylate in glucose monitoring sensors

Date:

2022-02-01

Citation:

Ng, K. L., Nixon, R. L., Grills, C. & Tam, M. M. (2022). Solution using Stomahesive® wafers for allergic contact dermatitis caused by isobornyl acrylate in glucose monitoring sensors. *Australasian Journal of Dermatology*, 63 (1), pp.e56-e59. <https://doi.org/10.1111/ajd.13675>.

Persistent Link:

<https://hdl.handle.net/11343/311083>

Title Page:

A SOLUTION USING STOMAHESIVE® WAFERS FOR ALLERGIC CONTACT DERMATITIS CAUSED BY ISOBORNYL ACRYLATE IN GLUCOSE MONITORING SENSORS

Running Head: Glucose Sensor Contact Dermatitis

Authors:

Kay Lin Ng (corresponding author), Rosemary L Nixon, Claire Grills, Mei Mui Tam

Kay Lin Ng (BSc)

Affiliation: Skin Health Institute, Carlton, Victoria, Australia¹

Email address: ngkaylin@gmail.com

ORCID Number: 0000-0002-1338-0634

Rosemary L Nixon (MBBS, FACD)

Affiliation: Occupational Dermatology and Research and Education Centre, Skin Health Institute, Carlton, Victoria, Australia

Email address: rnixon@occderm.asn.au

Claire Grills (MBBS, FACD)

Affiliation: Royal Children's Hospital, Parkville, Victoria, Australia

Email address: clairegrills@gmail.com

Mei Mui Tam (MBBS, FACD)

Affiliation: Skin Health Institute, Carlton, Victoria, Australia

Funding:

No funding required

Acknowledgments:

¹ Author's present address is Macquarie University, Sydney, New South Wales, Australia (Balaclava Road, Macquarie Park 2109).

This is the author manuscript accepted for publication and has undergone full peer review but has not been through the copyediting, typesetting, pagination and proofreading process, which may lead to differences between this version and the [Version of Record](#). Please cite this article as [doi: 10.1111/AJD.13675](https://doi.org/10.1111/AJD.13675)

This article is protected by copyright. All rights reserved

Dr Nishan Amerasinghe (MBBS, FACD) for providing photographs of glucose sensor

Dr Smriti Tandon (MBBS) for providing clinical details of patient 3.

No conflict of interest to declare

Patients consented to publication with de-identified data

Key words:

isobornyl acrylate, contact dermatitis, patch tests, glucose sensors, hydrocolloid, polyisobutylene/polyisobutene, pressure sensor adhesives

MISS KAY LIN NG (Orcid ID : 0000-0002-1338-0634)

Article type : Brief Report

ABSTRACT

Isobornyl acrylate (IBOA) has recently caused a number of cases of allergic contact dermatitis (ACD) from its use in medical devices. We would like to enhance awareness of this issue with the reporting of three Australian cases, involving two adults and a child. We also report a successful solution by using hydrocolloid wafer (Stomahesive®) as a barrier. As IBOA is not usually found on baseline patch test series and does not cross react with other acrylic monomers, ACD to IBOA may be missed by clinicians.

INTRODUCTION

Isobornyl acrylate (IBOA) is a monofunctional, photopolymerisable acrylic monomer providing a sturdy, yet flexible quality and is incorporated into a wide range of consumer goods such as adhesives and sealants, and in inks, plastic, rubber, paints, and coatings (8). Globally, there have been an increasing number of reports of occupational ACD to IBOA (1). IBOA is used in medical devices including glucose sensors for flash (FGM) or continuous glucose monitoring (CGM) (See Supplementary Figures). These devices remain in prolonged contact with a patient's skin for up to two weeks (3, 4). One European paper reported a 3.8% incidence of IBOA-related ACD from the Freestyle Libre® CGM sensor between 2016 and 2019 (11). In the past 2 years, multiple international reports have emerged, but there have been no Australian studies.

We present two adults and a child in Australian healthcare settings who developed IBOA-related ACD from glucose monitoring sensors. We discuss the use of hydrocolloid wafer with a polyisobutylene-based adhesive (Stomahesive®) as an effective barrier (Figure 1).

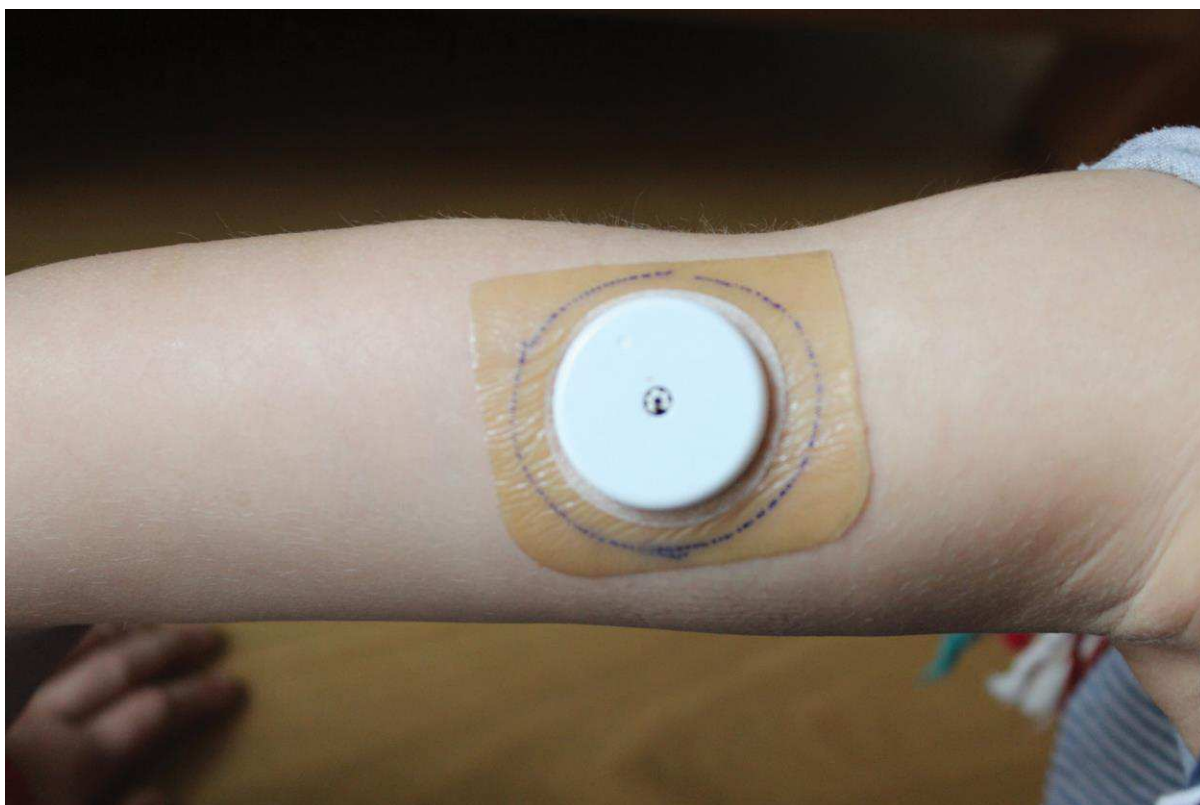


Figure 1 – An image (from <https://onlinelibrary.wiley.com/doi/abs/10.1111/cod.13248>) showing a hydrocolloid plaster applied between the white glucose sensor and the skin, acting as a barrier.

CASE SERIES

Patient One

Patient One was a 59-year-old female computer consultant with no previous known allergies nor atopy, who began using FreeStyle Libre® 1 FGM sensor in January 2018 to manage random hypoglycaemic attacks. She had developed type 1 diabetes mellitus secondary to pancreatitis. After 5 months, she developed localised pruritus under the sensor after 48 hours and then a vesicular eruption within a few hours. Use of Skin Prep® wipes, barrier cream and Tegaderm® slowed and reduced the reaction.

Patch testing was performed with the Australian Baseline Series, acrylate and tape series and her own products including the glucose sensor adhesive, Elocon® ointment, Liv Wipes®, Skin Prep® wipes, and isopropyl alcohol wipes. The glucose sensor adhesive reacted (+) on day 4. Nickel and formaldehyde reacted (+) on day 4. Nickel reaction was of old relevance due to previous piercings and formaldehyde was of unknown relevance. She was not exposed to formaldehyde nor formalin releasing preservatives. All other tests were negative. Nickel may be found in insulin pump needles, but not in glucose sensor needles.

We specifically then tested her to IBOA (0.1% petrolatum) and IBOA with Stomahesive® wafer acting as a barrier and Stomahesive® wafer itself (Figure 2). The results showed a (+) reaction on day 4 confirming the diagnosis of ACD to IBOA. The Stomahesive® wafer acted as a barrier to the IBOA centrally, but there was a peripheral reaction where the IBOA had migrated. Stomahesive® alone did not react (Figure 2). With the use of Stomahesive as a barrier, she was able to continue using the glucose sensor without the further development of ACD.

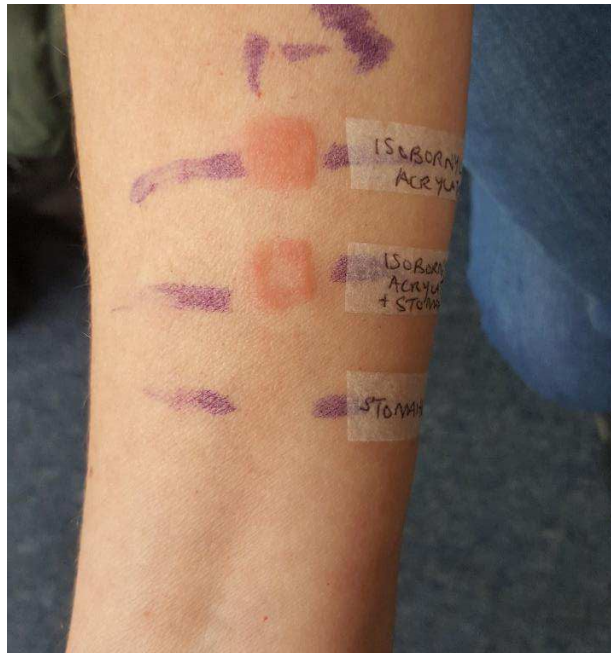


Figure 2 – Patch test showing a + reaction to IBOA, a peripheral reaction with Stomahesive® and IBOA applied on top, and lastly no reaction to the Stomahesive® wafer.

Patient Two

Patient Two was a 61-year-old male IT Systems Analyst with 37-year history of type 1 diabetes. Other past medical history included coeliac disease, gastro oesophageal reflux disease and osteopenia. In January 2017 he started using the FreeStyle Libre® FGM sensor for post-prandial glucose control and weight management. Twelve months later, he developed circular patches of erythematous, scaly itchy, irritated, vesicular eruptions where the sensor adhesive had been in contact (Figure 3). He had no known atopy nor previous allergies. Limited patch testing was performed to IBOA, IBOA with Stomahesive® and Stomahesive®. IBOA reacted with day 2 (+/-) reaction and day 4 (+) reaction. The other 2 patches were negative. With the use of Stomahesive® wafer as a barrier with additional Primapore® reinforcement over the sensor, he was able to continue using the glucose sensor without further ACD.

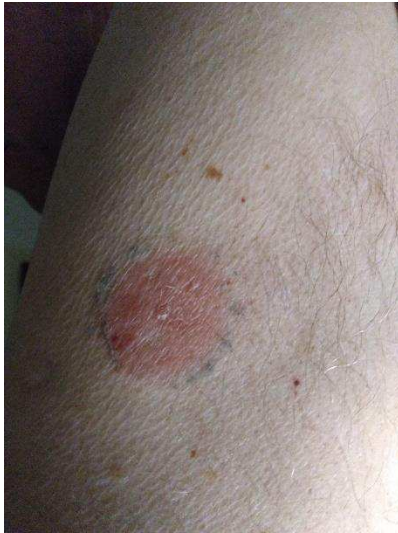

Figure 3 – Patient Two demonstrating a reaction to the FreeStyle Libre sensor with no barrier between the sensor and the skin.

Patient 3

Patient Three was a 12-year-old girl with Type 1 Diabetes Mellitus since age 9. She had a past and family history of atopic eczema, amoxicillin allergy and skin reactions to plastic Band-Aids and nickel. Three months after using the Medtronic® Glucose Monitor including IBOA and Enlite® OverTape (with polyurethane and colophony), she developed an erythematous itchy eruption at the adherence site. The eruption did not fully settle with topical Diprosone® treatment.

The patient was patch tested to the Australian Paediatric Baseline Series, acrylates, adhesives/glues and to IBOA and her own products. On day 4, the patient had + reactions to IBOA, colophonium, nickel, cobalt, fragrance mix I, *Myroxolon pereirae*, hydroperoxides of limonene and linalool, Amerchol L101 and propolis. She was diagnosed with ACD to IBOA in the glucose sensor and the other reactions were deemed not to be relevant. She applied Advantan® lotion and Stomahesive® wafer as a barrier with improvement.

DISCUSSION

IBOA was named the 2019 American Contact Dermatitis Society allergen of the year and is found in glucose monitoring sensors, insulin pumps and other medical devices (1). Initial reactions to these materials may be irritant but allergy to IBOA may supervene. Both Freestyle Libre® 1 and Medtronic Enlite® contain IBOA. The new adhesive in Freestyle Libre® 2 is unknown and is not yet available in Australia. It also contains butylated hydroxytoluene as a potential allergen. Dexcom G4® glucose sensor previously had ethyl cyanoacrylate as its adhesive, which has now been replaced with a new

unnamed adhesive in G6®. It is often difficult to obtain the exact nature of adhesives used from the companies.

Chemical analyses of the sensor device revealed that IBOA is used to join the two halves of the sensor together but is not used in the skin adhesive. Subsequently IBOA migrates and leaches on to the skin area causing ACD. (4, 5).

The Pharmaceutical Benefit Scheme (PBS) subsidises the cost of glucose sensors for type 1 diabetic young patients under 21, certain adult patients with concessional cover and those who are planning pregnancy (9). The monitors enable accurate control of insulin requirement hence reducing the incidence of hypoglycaemic attacks and reducing the amount of skin pricks daily. The Dexcom® sensors last 10 days whereas Freestyle Libre® sensors last 14 days before needing to be replaced (3, 4). The cost of continuous glucose monitoring (CGM) in Australia including consumables (sensors) is approximately \$5000 a year per patient (9). The paediatric population are the main demographic using these devices but sadly there is limited access to patch testing for paediatric patients which has been further hampered by the COVID-19 pandemic. Hence in Australia there have been few reports of ACD to IBOA, contributed to by low levels of use of the sensors, their cost and access to patch testing.

A previous German report of using 2 Hansaplast™ hydrocolloid blister plasters successfully decreased the ACD caused by IBOA from the CGM sensors (8). We then trialled a similar hydrocolloid plaster by Convatec, Stomahesive® wafers. One 10cm square wafer was cut to size to provide 4 barriers.

Stomahesive® wafers contain polyisobutylene (organic polymer adhesive), gelatine (collagen derivative), Sodium Carboxymethylcellulose (cellulose derivative) and Pectin (polysaccharide).

There have been no reports of ACD to PIB or cross-reactions between IBOA and PIB (6). In pressure sensor adhesive (PSA) manuals, IBOA and PIB are manufactured differently and classified as separate adhesives (2).

It is important for clinicians and patients using CGM to be aware of sensor reactions and that IBOA could be a potential cause of their ACD. Patch testing could ascertain the nature of the reaction and an effective short-term solution utilised using hydrocolloid plasters as barrier. PIB in the wafers does not cross-react with IBOA or cause ACD. Manufacturers need to be aware when making future products with prolonged skin contact that they do not include IBOA in them.

REFERENCES

1. Aerts O, Herman A, Mowitz M, Bruze M, Goossens A. Isobornyl Acrylate, *Dermatitis*: 1/2 2020; 31(1): p. 4-12 doi: 10.1097/DER.0000000000000549
2. Benedek I, Feldstein M. *Handbook of Pressure-Sensitive Adhesives and Products: - Three Volume Set*: CRC Press; 2019. 1100 p.
3. Dexcom Continuous Glucose Monitoring. 2021. <https://www.dexcom.com/en-AU>. Accessed Feb 4, 2021
4. Freestyle Libre. Freestyle Libre Sensor. 2021. <https://www.freestylelibre.com.au/freestyle-libre-au-sensor.html>. Accessed Feb 4, 2021
5. Herman A, Darrigade A-S, de Montjoye L, Baeck M. Contact dermatitis caused by glucose sensors in diabetic children. *Contact Dermatitis*. 2020;82: 105–111. <https://doi.org/10.1111/cod.13429>
6. Herman A, Mowitz M, Aerts O, et al. Unexpected positive patch test reactions to sesquiterpene lactones in patients sensitized to the glucose sensor FreeStyle Libre. *Contact Dermatitis*. 2019;1–14. <https://doi.org/10.1111/cod.13330>

Herman A, Darrigade A-S, de

Montjoye L, Baeck M. Contact dermatitis caused by glucose sensors in diabetic children. *Contact Dermatitis*. 2020;82: 105–111.

<https://doi-org.simsrad.net.ocs.mq.edu.au/10.1111/cod.13429>

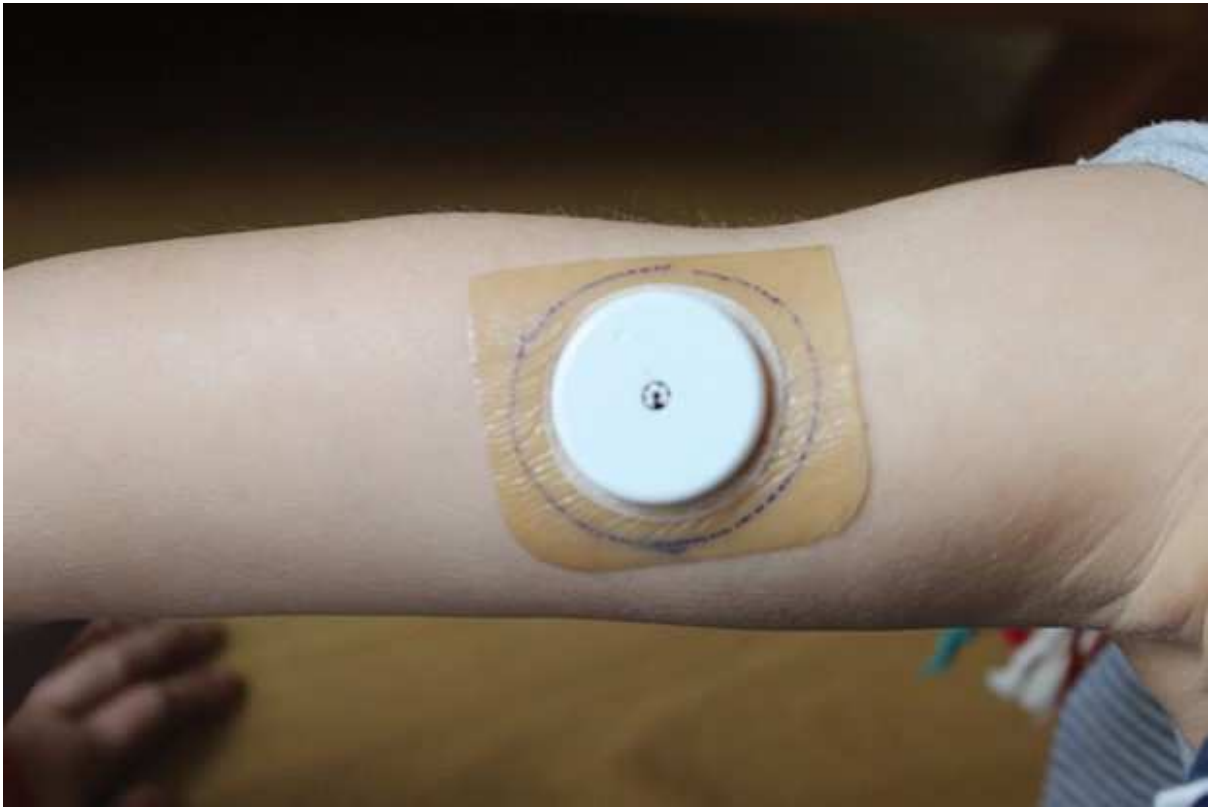
Herman A, Darrigade A-S, de

Montjoye L, Baeck M. Contact dermatitis caused by glucose sensors in diabetic children. *Contact Dermatitis*. 2020;82: 105–111.

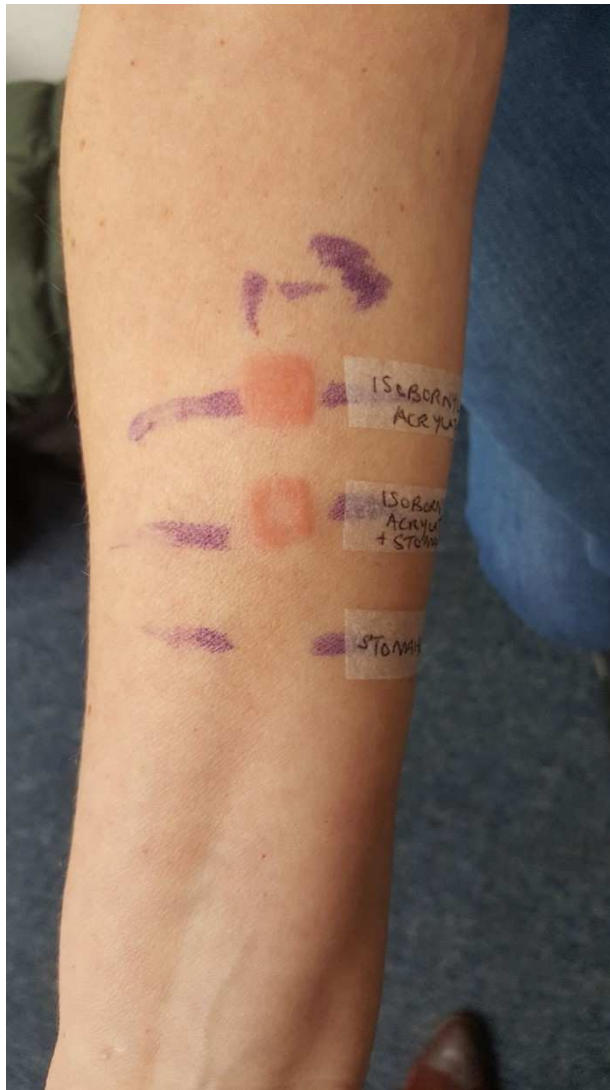
<https://doi-org.simsrad.net.ocs.mq.edu.au/10.1111/cod.13429>

7. Hyry HSI, Liippo JP, Virtanen HM. Allergic contact dermatitis caused by glucose sensors in type 1 diabetes patients. *Contact Dermatitis*. 2019;81:161–166. <https://doi.org/10.1111/cod.13337>
8. Kamann S, Oppel E. Hydrocolloid blister plaster decreases allergic contact dermatitis caused by Freestyle Libre and isobornyl acrylate. *Contact Dermatitis*. 2019;81:380 – 381. <https://doi.org/10/1111/cod.13329>

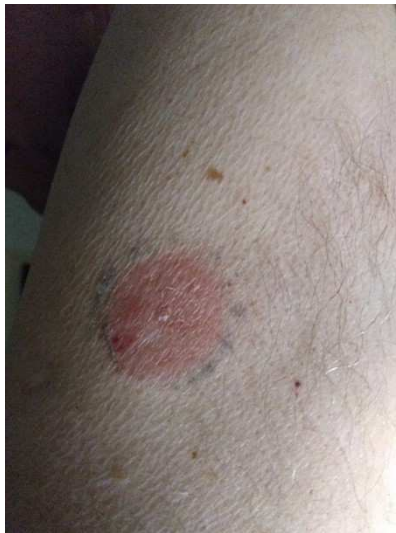9. National Diabetes Services Scheme. Continuous glucose monitoring fact sheet. 2021.
<https://www.ndss.com.au/about-diabetes/resources/find-a-resource/continuous-glucose-monitoring-fact-sheet/>. Accessed Feb 4, 2021.
10. Pyl J, Dendooven E, Van Eekelen I, den Brinker M, Dotremont H, France A, Foubert K, Pieters L, Lambert J, De Block C, Aerts O. Prevalence and Prevention of Contact Dermatitis Caused by FreeStyle Libre: A Monocentric Experience. *Diabetes Care* 2020, dc191354; **DOI:** 10.2337/dc19-1354



ajd_13675_f1.tiff



ajd_13675_f2.tiff



ajd_13675_f3.tiff