



Minerva Access is the Institutional Repository of The University of Melbourne

Author/s:

van Beek, EJR;Kuhl, C;Anzai, Y;Desmond, P;Ehman, RL;Gong, Q;Gold, G;Gulani, V;Hall-Craggs, M;Leiner, T;Lim, CCT;Pipe, JG;Reeder, S;Reinhold, C;Smits, M;Sodickson, DK;Tempany, C;Vargas, HA;Wang, M

Title:

Value of MRI in medicine: More than just another test?

Date:

2019-06-01

Citation:

van Beek, E. J. R., Kuhl, C., Anzai, Y., Desmond, P., Ehman, R. L., Gong, Q., Gold, G., Gulani, V., Hall-Craggs, M., Leiner, T., Lim, C. C. T., Pipe, J. G., Reeder, S., Reinhold, C., Smits, M., Sodickson, D. K., Tempany, C., Vargas, H. A. & Wang, M. (2019). Value of MRI in medicine: More than just another test?. *Journal of Magnetic Resonance Imaging*, 49 (7), pp.e14-e25. <https://doi.org/10.1002/jmri.26211>.

Persistent Link:

<https://hdl.handle.net/11343/284402>

The value of MRI in Medicine – more than just another test?

Abstract

There is increasing scrutiny from healthcare organisations towards the utility and associated costs of imaging. MR imaging has traditionally been used as a high-end modality, and although shown extremely important for many types of clinical scenarios, it has been suggested as too expensive by some.

This editorial will try and explain how value should be addressed and gives some insights and practical examples of how value of MR imaging can be increased. It requires a global effort to increase accessibility, value for money and impact on patient management. We hope this editorial sheds some light and give some indications of where the field may wish to address some of its research to proactively demonstrate the value of MRI.

Key words: MR imaging, costs, value, accessibility, patient-centred, management

Introduction

This work is the result of ongoing attempts to evaluate the utility of diagnostic imaging within the larger framework of healthcare, international economic drivers, costs containment and research.[1-3] Magnetic resonance imaging (MRI) is a pivotal, diverse modality, used to evaluate a range of morphological and functional targets. It is a highly versatile diagnostic tool and s an information-rich research tool for studying the mechanistic underpinning of body function and dysfunction.

There is little doubt that MR imaging is one of the most powerful diagnostic tools in contemporary clinical medicine, while offering highly advanced research opportunities and studies of (patho)physiological processes. Unfortunately, it is also – rightly or wrongly – perceived as a cost intensive method and an important driver of overall healthcare costs. Thus, there is a critical need to prove its effectiveness in terms of clinical outcomes, within the context of non-invasive diagnosis and minimally invasive therapy.

By definition, however, outcomes evaluate the end result of a given diagnostic-therapeutic pathway. Since diagnostic procedures take place at the very beginning, the further downstream the outcome variable is, the more confounders will occur between the diagnostic test and the end result for a patient. So although MRI – like other diagnostic tests – is performed to guide treatment, it can be very challenging to measure its clinical utility when established clinical outcome measures are used, i.e.

This is the author manuscript accepted for publication and has undergone full peer review but has not been through the copyediting, typesetting, pagination and proofreading process, which may lead to differences between this version and the Version of Record. Please cite this article as doi: [10.1002/jmri.26211](https://doi.org/10.1002/jmri.26211)

outcome measures that have been developed and refined to rate the utility of therapeutic interventions.

Value is widely defined as the ratio of benefit to cost. Accordingly, there are two different avenues to respond to the demand for value driven medicine: First, we need to improve methods that help us measure the true clinical benefit of diagnostic tests. Imaging societies must respond to the growing demand for “proof of outcome” by supporting trials that provide such evidence. This requires identification of innovative imaging-specific outcome measures that are useful to reflect the impact of improved diagnostic accuracy on patient outcome. Subsequently, the imaging community needs to be educated on the difference between diagnostic and therapeutic studies and the importance of using imaging specific outcome variables.

Second, we need new ways of thinking about how to reduce the cost of advanced imaging methods. Research in imaging must diversify to investigate the utility of “streamlined” advanced imaging methods (e.g. abbreviated MRI protocols that are focused to answer a specific clinical question), and also to develop minimally invasive MRI guided therapies, as well as other sources of new documentable value.

In this paper, we review a number of important topics related to the value of MRI, aiming for a broad scope and a global perspective. We encourage all readers with an interest in magnetic resonance and biomedical imaging to take note, and to rise to the challenges posed here.

The concept of value in relation to costs and economics

MRI plays an integral part in the management of many diseases. It provides multi-modal information on metabolism, function and molecular structure, and this has extended its use in many fields including completely new arenas, such as quantitative MRI in precision medicine, functional MRI and fibre tracking in neuroradiology, and psychoradiology.[4]

The Concept of Value

The concept of value is broad and may mean different things in different situations and societies. Usually, value is defined as outcome over cost. As the word “outcome” implies, in clinical medicine, the most relevant outcome variables relate to the late effects of treatment, e.g. morbidity, mortality, and quality of life. The usual way to demonstrate “value” is to demonstrate a (positive) impact on these (late) outcome variables. Diagnostic imaging in general, and so MRI, however, provides information – but not treatment. Therefore, the usual outcome metrics may fall short to rate the utility of diagnostic tests. An appropriate definition of value for an imaging method is that it provides accurate information that is useful to guide treatment: Information on presence or absence of a disease or a condition, on the local or systemic extent of disease, on the likelihood with which a disease will respond to treatment, or be

amenable to specific types of treatment, on the actual response of disease to treatment, or on patient prognosis. The current challenge for diagnostic imaging methods is to find metrics that capture the information provided by diagnostic imaging.

It is well recognized that non-invasive imaging tests, such as ultrasound, CT and MRI, have led to significant reduction of invasive testing, such as exploratory surgery.

Imaging can also be valuable merely by contributing information that is needed to guide patient management and optimising patient care. However, this “value” is difficult to measure.

Costs of delivering MR scans are easier to capture, but vary globally across different healthcare systems.[3] Costs are borne by different groups in different societies, varying from the government through employers to individuals, but this is largely irrelevant when discussing costs control. Costs may be fixed (such as the cost of MRI systems [initial capital, depreciation, and upgrades], service contracts, staff costs) or variable (e.g. contrast and consumables). Further, the ‘costs’ will also vary depending on perspective, e.g. reducing exam time may reduce the healthcare system cost, but the patient charge may remain unaltered.

Value in MR

Factors affecting MR value include efficacy, capacity and availability of scanners and human resources, availability of alternatives, economic considerations and expertise. The law of diminishing returns of marginal gains applies to MRI with regards to exam protocols. In most protocols, there will be 2-3 key sequences that yield the majority of information. Additional sequences will provide more nuanced and specialized information. Similarly, if there is limited MRI capacity, this is likely to be used where there are few suitable alternatives to MRI, and the diagnostic yield is high. Where scanners availability is plentiful, the diagnostic yield per patient may decrease. In general, methods that could accelerate the examination and increase the efficiency in the course of clinical intervention are most valuable. From the patient perspective, costs include opportunity cost and discomfort for longer scan time.

Even in the wealthiest of societies, healthcare costs are rapidly becoming unsustainable. Consequently, the costs of imaging have to be controlled and rationalized; demonstrating and increasing ‘MR Value’ is a global necessity. To establish what is high value MRI requires an evidence-based evaluation template for assessment of new MRI techniques. For healthcare payers, simplifying and streamlining the components of the examinations and developing a disease-based approach is potentially more efficient. From a government perspective, different geographical regions have different clinical needs, which in turn require different MRI approaches. Thus, optimized arrangements of MRI systems and new techniques are important to save resources, while improving effectiveness.

Considerations for Evaluation of MR Value

Some of the considerations that need to form part of the discussion of MR Value include:

- *Role of focussed, limited examination*

Where financial and capacity constraints are paramount, MRI protocols should provide the most important information for the majority of patients. Scanner efficiency can be improved by using faster or more effective sequences. Highly proscribed scan protocols can facilitate the use of less specialised technicians and extends hours of use of MRI systems.

- *Role of high-quality, highly detailed examination*

In the setting of a research study, or where constraints of economic resources are less problematic, this approach may be the most appropriate. There are also other situations where complex MRI might be the *only* diagnostic modality, such as surgical planning for epilepsy and psychoradiology.

Outside a research setting, on the other hand, performing a highly detailed MR scan without subsequent appropriate treatment may not be considered value for money.

- *Is MRI better than alternative imaging methods?*

Assessment of exam efficacy compared with other imaging methods is well established and forms part of evidence based medicine. This includes an assessment of how MRI compares in terms of clinical yield and cost effectiveness. An MR exam could be justified if it can replace other expensive alternative tests or lead to optimised treatments with costs reduction.

Economic and health value can be demonstrated by showing that MRI alters decision-making and improves patient outcome

- *MR-guided therapeutics.*

This expanding field may provide real value compared to invasive alternatives where there is proven therapeutic efficacy, similar to cost savings and value of minimally invasive surgery compared with open surgery. One of the most elegant example of this is the totally non-invasive MR guided focused ultrasound surgery for thermal ablation of the subthalamic nucleus to cure essential tremor.

- *Industrial collaborations*

All improvements designed to increase scan efficacy ultimately have to engage with industrial partners and vendors in order to be able to deliver affordable solutions into clinical and research environments.. New technologies will only make sense if the costs of upgrading are affordable.

- *Patient experience*

Shorter scans with less noise, in more comfortable scanners can improve patient experience and improve patient perception of value. It should be remembered here,

that reimbursement by Medicare in the USA is now intricately linked to patient satisfaction.[5]

- *Exam read time.*

Reporting times increase with increasing scan complexity. Optimizing protocols and reducing the number of scans required per patient can increase reporting throughput. Furthermore, the development of artificial intelligence/machine learning has the potential for additional costs savings.

Value across the world – there are differences

Many recent discussions on the topics ‘Value in Imaging’ and ‘Value in MRI’ have been generally US and Europe centric. However, in many parts of Asia, South America and Africa, there are diverse and variable conditions that surround healthcare, with different infrastructure, funding models and medical practice that will have an important impact on this topic. These may differ substantially from conditions in North America and (Western) Europe, and there may be additional challenges, including MRI scanner availability.. Some geographical areas are hampered by low socio-economic development (lack of electricity and clean water) and unstable security situations (failed states and war zones), further limiting valuable health provisions for these populations. This means that patient access to advanced MRI systems and its consequent valuable diagnostic decision-making maybe restricted, and they may be forced to depend on cross-border medical resources.

An additional important factor is that healthcare policies are highly nationalised and depend on economic status and priorities due to disease prevalence. In many resource-challenged nations, there also exists a diversity of disease mix of clinical cases, with more infectious diseases, affecting younger and growing population demographics, as well as disparate educational, economic and cultural factors. These conditions may affect population attitudes to health and health-seeking behaviour, not just among patient populations, but also amongst health-care providers, who might require education in the most appropriate and valuable investigations (and conversely, inappropriate and low-value tests) once MRI systems become available.

Education is a key factor in healthcare to allow introduction of MRI into clinical, evidence based practice in these underserved global populations. A steep learning curve is needed for radiologists and imaging specialists in some countries, when these acquire new MRI equipment and apply this to their patients for the first time. Hence, the ISMRM remains well-placed to provide basic and advanced educational activities through innovative outreach programs, such as “Teach the Teacher” programme, to develop a better skilled workforce in MR imaging. This would be of particular value to developing countries, and will help establish high value MRI for new populations that are currently under served.

The value of MRI – how do we prove it?

As discussed, there are many factors that influence the utilization of medical imaging technologies across the world. Regardless of geographic variations, the ultimate basis for the acceptance and use of imaging should be strong clinical evidence supporting its value. A few successful examples are the recent randomized controlled trial of >50,000 smokers that demonstrated a 20% reduction in lung cancer mortality in high-risk patients undergoing chest CT screening [7] or where coronary artery CT improved long-term outcome when compared to standard of care.[8] Although these examples are the exception rather than the rule, imaging plays a key role in almost all therapeutic clinical trials, from determining trial eligibility and obtaining tissue to guide management to defining clinical endpoints to assess pharmacologic effects.

Hierarchical models for appraising the value of diagnostic imaging, including MRI, have been proposed, and involve a step-wise progression to generate evidence that attests to the efficacy and value of an imaging exam (Table 1)[9]. Multiple levels of evidence are necessary before even attempting to prove impact on patient outcomes, including technical and diagnostic accuracy and efficacy.[10] Rapid equipment turnover and product modifications partly explain the focus on constant innovation and advancement in technologic development, with evidence for potential utility limited to assessing the diagnostic capability of an MRI technique to “detect” a ground truth. While progression through these steps is a pre-requisite, studies evaluating the value from the patient and societal perspectives are lacking. There are several potential reasons for this. The rapid technical advances may make it seem more attractive to “move on” to evaluating a newer MRI technique, before “closing the loop” on validating and assessing the true value of an older MRI technique. Thus, the value of an MRI technique is often implicitly assumed and incorporated into standard of care on the basis of evidence of its diagnostic accuracy only. This leads to a vicious circle, where studies for assessing the higher order value of MRI are hindered as their findings are not perceived as news worthy. Finally, there is a need for innovative study designs that maximize the assessment of the value as it relates to patient outcomes that can be directly attributed to MRI.

In therapeutic clinical trials, patients are often randomized to a standard versus a new treatment or intervention, and outcomes are compared. However, this study design does not lend itself to evaluating the contribution of MRI to the clinical outcomes of interest, even if MRI findings were central to guide management. Alternative study designs, specifically geared towards linking MRI-determined phenotypes to outcomes, are needed.

Some examples of potential alternatives to provide this higher order information for the value of MRI using dedicated study designs have been proposed.

- A randomised study design, introducing a new MRI technique into patients in one arm, who are managed accordingly, while the standard of care is used in the other arm with management accordingly. Follow-up for events will be performed to assess outcome differences; an example of this design was the SCOTHEART trial. [8]
- In the paired study design, both an investigational and a standard of care imaging exam are performed in all patients; if the findings from the 2 exams are concordant the patient is treated as per the standard procedures, but if the findings are discordant patients are randomized to one of two arms: treatment according to the results of the standard exam versus treatment according to the investigational exam (Figure 1).
- In the modified marker strategy design, all patients undergo an investigational MRI exam at baseline and are stratified based on risk determined from the MRI and standard prognostic variables. Patients for whom the treatment decision would be the same with or without the MRI findings go off study; all other patients are randomized to treatment based on MRI findings versus standard of care (Figure 2).

Nevertheless, in spite of these approaches, the fundamental problem remains that treatment can be variable and outcome measures may vary simple based in different treatment efficacy, surgical skills and patient population factors. For instance, the reexcision rate in breast cancer was shown to vary across surgeons, regions and hospitals.[11,12]

In addition to the novel approaches described above, it is also useful to consider the role of MRI in deriving prognostic information. Although MRI examinations are typically performed for diagnostic purposes, the image datasets often contain important prognostic information. For instance, El Aidi et al. assessed the prognostic value of several cardiac MRI derived indices to predict outcomes in patients with suspected coronary artery disease or recent myocardial infarction.[13] Recent developments in image analysis techniques based on machine learning and deep learning will help remove this constraint. Development of machine learning algorithms has great potential to enhance the value of imaging. Recently, Oakden-Rayner et al. described how these techniques can be used to predict longevity from routinely collected medical images.[14]

MR value and the regulations and reimbursement system.

High-tech medical imaging modalities such as MRI and CT have revolutionized healthcare so profoundly that most physicians would have trouble imagining how they could take proper care of patients without access to these essential diagnostic tools. The cost of MRI and CT accounts for less than 3% of Medicare spending in the United States and very often these modalities replace more invasive and expensive

tests.[15] Yet the use of these technologies is often cited as a major contributor to the escalating cost of healthcare. This provides strong motivation for the MRI community to focus on proving the value of MRI in patient care, and to identify ways to further increase value.

In this context, the value of an MRI exam can be defined as sum of measures of the actionable diagnostic information provided by the exam, safety, and service, all divided by costs. Improved diagnostic certainty, replacement of invasive procedures, standardized reporting and development of quantitative measures can all enhance the value of MRI. Furthermore, focused optimized MRI protocols will trim exam times, improving efficiency of scanner use.

One of the barriers to implementing focused, low cost, high value MRI protocols in the United States is related to the system of standardized codes for medical procedures (CPT codes), which are used in the traditional fee-for-service model of radiology practice. There are only a few CPT codes for MRI examinations for each part of the body, e.g. only three codes for MRI brain. The system has encouraged the use of broad, comprehensive protocols in MRI, suitable for many different indications. These comprehensive exams are well reimbursed under the fee-for-service system and MRI has therefore traditionally been a revenue generating (“profit”) center in many medical institutions. The down-side of this approach is that it has led to reduced economic motivation for developing lower cost, efficient MRI exam protocols, which also enhance patient throughput. Other obstacles to adopting high value MRI protocols include concerns about medicolegal issues and questions of eligibility for reimbursement when anything less than a full comprehensive MRI protocol is used.

While these challenges are real, the changing face of healthcare economics provides strong motivation for making progress in developing higher value MRI protocols. Healthcare payment systems are steadily shifting from the fee-for-service model to bundled payment systems for entire healthcare encounters or population based prospective payment models. Under these models, imaging becomes a “cost” centre rather than a profit centre, and creates new strong incentive to re-engineer MRI practice, with an emphasis on high value, low cost protocols.

The implementation of focused, high value, low cost protocols will benefit all users. Thus, although the USA serves as a healthcare system model that can drive these changes, the entire world stands to benefit from these adaptations and developments.

The value of MRI – some practical examples

In this section, we highlight some examples of highly focused MRI studies that have high, and in some cases, unique clinical impact.

Breast imaging:

It is well established that breast MRI is by far the most powerful method for breast cancer diagnosis as well as for screening.. [16] Overdiagnosis is evident by cancer epidemiology. [17] Underdiagnosis is evident through the high number of cancers that remain undetected by mammographic screening, and are diagnosed because they become clinically palpable after a normal screening mammogram: the so called “interval cancers”. [18] By way of contrast, detection of breast cancer in breast MRI relies on the depiction of pathophysiological changes that are prerequisites for fast growth and metastatic activity, i.e. angiogenesis and protease activity. Accordingly, breast MRI is associated with what one could call a “reverse length time bias” (Figure 3).

In 2014, Kuhl et al published a seminal study on the use of an abbreviated MRI protocol for breast cancer screening taking only 3 minutes of acquisition time. [19] This offered an equivalent cancer yield and diagnostic accuracy as did the full, multiparametric protocol used thus far for screening. Accordingly, with abbreviated protocols, the more widespread use of breast MRI for screening, even on a population-wide scale, is conceivable.

Breast MRI thus promises to correct for the major shortcomings of screening mammography, and will be a major milestone regarding the further reduction of breast cancer mortality.

Abdominal/Liver MRI:

MRI is routinely and increasingly used for screening patients with cirrhosis, who are at elevated risk of developing hepatocellular carcinoma (HCC). [20] It is key to assessing the increasingly prevalent nonalcoholic fatty liver disease (NAFLD) and viral associated cirrhosis. Marks and co-authors have demonstrated the feasibility of an innovative approach to screen for HCC using hepatobiliary gadolinium based contrast agents, Figure 4. [21] While patients with suspicious hepatic nodules may require additional imaging, given the very low (93 HCC in 1.6 million person years of follow-up; <7 per 100,000 person years) incidence of new HCC in cirrhotic patients undergoing screening [22], the majority of patients require no additional imaging until their next screening visits. [23] This confers substantial potential cost savings, and an improved patient experience. [23]

Pulmonary MRA:

Pulmonary embolism (PE) is a common and potentially life threatening clinical conundrum and imaging is key for diagnostic management. [24] Currently, CT angiography (CTA) is the reference standard for the diagnosis of PE. [25] Recently, Nagle et al have described the use of pulmonary MRA as an alternative to CTA in young patients presenting to the Emergency Department with clinical suspicion for PE. [26]. In this approach a rapid MRA protocol , which took less than 10 minutes, was demonstrated to be a safe and viable alternative to CTA for the diagnosis and exclusion of PE, without the need for ionizing radiation (Figure 5). .

Musculoskeletal:

Rapid protocols in musculoskeletal MRI have been used to rule out occult fractures of the hip and wrist in the emergency setting. [27-29]. When negative, MRI can exclude a fracture with rapidity and certainty, avoiding further testing. When positive, MR can lead to rapid treatment avoiding complications. While typical MSK MR protocols for joint are up to 30 minutes long, 3D methods with isotropic resolution can cut the exam time to as little as 5 minutes, Figure 6. [30-32]

Prostate:

Multi-parametric (mp) MRI has gained increasing relevance for the detection and characterization of intra-glandular prostate cancer, Figure 7. [33].

Currently prostate cancer remains the last cancer in the body to be diagnosed by random sampling of the gland. Multiple studies have shown the increased yield of clinically significant prostate cancer (usually defined as cancer with Gleason $\geq 3+4$) using the MRI guided targeted prostate biopsies. Shorter and less invasive high value protocols being investigated in pre-biopsy planning.

In the last 6 months alone there have been 2 prospective studies demonstrating the value of both mp and bp-MRI at either 1.5T or 3T, multi-parametric or bi-parametric with either typical protocol length or abbreviated (15 mins) can, in certain groups of men, reduce the need for prostate biopsy by 24-27%, Figure 8, or increased the yield of biopsy compared to TRUS guided biopsy. [34,35]

Brain:

Neurological imaging is one of the commonest MRI exams and there are multiple neurological applications of rapid MR protocols, and three representative examples are discussed here. These include a single-shot T2 weighted fast spin echo (FSE) sequence, which takes 3 minutes of exam time, for assessing hydrocephalus and shunt tip location in children.[36-39] Direct comparison to CT shows non-inferiority of the MR based protocols to CT scanning, allowing rapid adoption to the MRI approach. [40]

While CT is currently the main imaging modality in acute stroke in many countries, MRI has been widely utilized for rapid assessment of stroke. Exams can be completed in acute stroke patients in under 15 minutes, and affect the management of these patients. [41] Multiple groups adopted time shortening advances in acquisition such as parallel imaging. [42-45] Results from the DAWN trial indicate the importance of infarct volume for treatment decisions, and reiterate the value of MR in the setting of acute stroke. [46]

A final example concerns the use of arterial spin labelling (ASL) MRI in patients with suspected dementia as a potential replacement of the much more expensive FDG-PET (Figure 9). [47,48] Earlier and accurate diagnosis allows for the prompt start of supportive treatments that have their greatest effect when patients are not yet severely affected by the disease, allowing patients to remain independent for longer. Increasing patients' independence and thus delaying institutionalised care further increases the cost-effectiveness of ASL-MRI on a societal level.

New Challenges and Opportunities for the MRI community

The requirement to address the unsustainable rise in healthcare costs is both a tremendous challenge and a matter of critical importance, both for society in general, and for MRI in particular. Payers want evidence that an MRI study adds clinical value for the patient, or avoids unnecessary surgery or other costs. Hospitals want to know that their equipment is utilized efficiently, especially if the MRI examination is performed in the setting of an accountable care organization or cost-centre. The imperative to prove the value of MRI, moreover, goes beyond economics alone. Patients certainly want to know that any imaging test they undergo is necessary and helpful for their care.

In the rapidly-evolving global healthcare landscape, these challenges will continue to rise for traditional imaging enterprises. Along with these challenges, though, come enormous opportunities for the development of technology and practice in our field. Since MRI is utilized at the front end of patient management, during therapy, as well as in prognosis, it can be leveraged in numerous ways to better direct patients to the

optimal therapy for the best outcome, coupled with substantial benefits in economic value and patient satisfaction.

As has been noted earlier, one key direction of innovation involves the development of abbreviated MRI examinations that may not utilize the full range of contrast mechanisms available, but that contribute substantively to diagnosis and management in a rapid and cost-effective manner. New MRI methods need to be evaluated in terms of how much value they contribute to the patient and how long they take to perform. It is likely in this environment we will see more diverse clinical protocols that are shorter and more tailored, perhaps using AI or Machine Learning, to specific patients and situations.

At the same time, it is important that we continue to explore new contrast mechanisms, to generate new biophysical information in our MR scans, and to invent new ways of gathering and interpreting image data. Guided by the overarching metric of value, these new dimensions of imaging must be evaluated in the totality of patient management. We should investigate not only how to image less, but also how to image differently. We should also work together to figure out how to apply rigorous standards of value to such studies, early and often.

Better value in MRI, with improved patient outcomes at a lower cost to the health system, is good for everyone. It will benefit the entire imaging community to use the drive for increased value to build better bridges between clinical practitioners, comparative effectiveness and outcomes researchers, and clinical, scientific, and technical innovators. Academic innovators must work with industry partners to move advances into the marketplace. Industry and educators must help clinical practices, beyond the top academic sites, to put best practices into place. Also, we must create conduits to allow insights and data from clinical practice at all levels to come back to the innovators, partnered with health service researchers to foster comparative effectiveness research.

At a practical level, there are several baseline practical issues that can be addressed to move us forward, including

- establishing standards to reduce variability across sites and vendors,
- establishing standards for quantitative measures in in-vivo MRI,
- creating actionable diagnostic targets that allow meaningful assessment of imaging protocols without the confounding variability of treatment paradigms and practices,
- creating more sophisticated decision support for optimal, personalized diagnostic pathways,
- creating meaningful, automated metrics for image efficacy assessment beyond diagnostic accuracy,
- decreasing scan times through technical innovation and change in practice and protocols,
-

- identifying better management pathways for early identification of false positives and benign findings before inappropriate treatment is employed.

It is abundantly clear that the challenges of healthcare economics, coupled with the ongoing imperatives of patient care, create an enormous need and opportunity for innovation, cooperation, education, and improved practice for MRI in patient management. This is no small task, and it will not be accomplished quickly, but it can be addressed in meaningful ways. We must continue to align ourselves in this journey across disciplines, across the relevant societies, centers, and industries. We must continue to lay the groundwork, and build the processes, for long-term innovation that brings better care to our patients in an economically sustainable framework.

References

1. Lee VS. Annual Oration: driving value through imaging. *Radiology* 2017;285:3-11.
2. European Society of Radiology. ESR concept paper on value-based radiology. *Insights Imaging* 2017;8:447-454.
3. Rubin GD. Costing in radiology and health care: rationale, relativity, rudiments, and realities. *Radiology* 2017;282:333-347.
4. Lui S, Zhou XH, Sweeney JA, Gong QY. Psychoradiology: the frontier of neuroimaging in psychiatry. *Radiology* 2016;281:357-372.
5. <https://www.cms.gov/Medicare/Quality-Initiatives-Patient-Assessment-Instruments/HomeHealthQualityInits/HHQIQualityMeasures.html> (accessed 17 Dec 2017).
6. Wang M, Dai Y, Han Y, Haacke EM, Dai J, Shi D. Susceptibility weighted imaging in detecting hemorrhage in acute cervical spinal cord injury, *Magnetic Resonance Imaging*, 2011;29:365-373.
7. Aberle DR, DeMello S, Berg CD, et al. Results of the two incidence screenings in the National Lung Screening Trial. *New Engl J Med* 2013;369:920-931.
8. SCOT-HEART investigators. CT coronary angiography in patients with suspected angina due to coronary heart disease (SCOT-HEART): an open-label, parallel-group, multicentre trial. *Lancet* 2015;385:2383-2391.
9. Fryback DG, Thornbury JR. The efficacy of diagnostic imaging. *Med Decis Making* 1991;11:88-94.
10. Bossuyt PM, Reitsma JB, Bruns DE, et al. STARD 2015: an updated list of essential items for reporting diagnostic accuracy studies. *Radiology* 2015;277:826-832.
11. McCahill LE, Single RM, Aiello Bowles EJ, et al. Variability in reexcision following breast conservation surgery. *JAMA* 2012;307:467-475.
12. Wilke LG, Czechura T, Wang C, et al. Repeat surgery after breast conservation for the treatment of stage 0 to II breast carcinoma: a report from the National Cancer Data Base, 2004-2010. *JAMA Surg* 2014;149:1296-1305.
13. El Aidi H, Adams A, Moons KG, Den Ruijter HM, Mali WP, Doevendans PA, Nagel E, Schalla S, Bots ML, Leiner T. Cardiac magnetic resonance imaging findings and the risk of cardiovascular events in patients with recent myocardial infarction or suspected or known coronary artery disease: a systematic review of prognostic studies. *J Am Coll Cardiol*. 2014 Mar 25;63(11):1031-1045.
14. Oakden-Rayner L, Carneiro G, Bessen T, Nascimento JC, Bardley AP. Precision Radiology: predicting longevity using feature engineering and deep learning methods in a radiomics framework. *Sci Rep* 2017;7:1648.
15. Lee DW, Duszak R Jr, Hughes DR. Comparative analysis of Medicare spending for medical imaging: sustained dramatic slowdown compared with other services. *Am J Roentgenol* 2013;201:1277-1282.

16. Kuhl CK Current status of breast MR imaging. Clinical applications. *Radiology* 2007;244:672-691.
17. Alvarado M, Ozanne E, Esserman L. Overdiagnosis and overtreatment of breast cancer. *Am Soc Clin Oncol Educ Book* 2012:e40–e45.
18. Li J, Holm J, Bergh J, Eriksson M et al. Breast-cancer genetic risk profile is differentially associated with interval and screen-detected breast-cancers. *Ann Oncol*. 2015 26:517-522.
19. Kuhl CK, Schrading S, Strobel K, Schild HH, Hilgers RD, Bieling HB. Abbreviated breast magnetic resonance imaging (MRI): first postcontrast subtracted images and maximum-intensity projection-a novel approach to breast cancer screening with MRI. *J Clin Oncol*. 2014;32:2304-2310.
20. Díaz-González Á, Forner A. Surveillance for hepatocellular carcinoma. *Best Pract Res Clin Gastroenterol*. 2016;30:1001-1010.
21. Marks RM, Ryan A, Heba ER, et al. Diagnostic per-patient accuracy of an abbreviated hepatobiliary phase gadoteric acid-enhanced MRI for hepatocellular carcinoma surveillance. *Am J Roentgenol*. 201;204:527-535.
22. Yan JD, Ahmed Mohammed H, Harmsen WS, Enders F, Gores GJ, Roberts LR. Recent trends in the epidemiology of hepatocellular carcinoma in Olmsted County, Minnesota: a US population-based study. *J Clin Gastroenterol* 2017;51:742-748.
23. Yang JD, Mannalithara A, Piscitello AJ, et al. Impact of surveillance for hepatocellular carcinoma on survival in patients with compensated cirrhosis. *Hepatology* 2017 [Epub ahead of print]
24. Hendriksen JM, Geersing GJ, Lucassen WA, et al. Diagnostic prediction models for suspected pulmonary embolism: systematic review and independent external validation in primary care. *Br Med J* 2015;351:h4438.
25. Levin D, Seo JB, Kiely DG, et al. Triage for suspected acute pulmonary embolism: think before opening Pandora's Box. *Eur J Radiol* 2015;84:1202-1211.
26. Nagle SK, Schiebler ML, Replinger MD, et al. Contrast enhanced pulmonary magnetic resonance angiography for pulmonary embolism: building a successful program. *Eur J Radiol* 2016;85:563-563.
27. Lim KB, Eng AK, Chang SM, Tan AG, Thoo FL, Low CO. Limited magnetic resonance imaging (MRI) and the occult hip fracture. *Ann Acad Med Singapore*. 2002;31:607-610.
28. Kelson T, Davidson R, Baker T. Early MRI versus conventional management in the detection of occult scaphoid fractures: what does it really cost? A rural pilot study. *J Med Radiat Sci*. 2016;63:9-16.
29. Gold GE, Busse RF, Beehler C, Han E, Brau AC, Beatty PJ, Beaulieu CF. Isotropic MRI of the knee with 3D fast spin-echo extended echo-train acquisition (XETA): initial experience. *Am J Roentgenol*. 2007;188:1287-1293.
30. Kijowski R, Davis KW, Woods MA, Lindstrom MJ, De Smet AA, Gold GE, Busse RF. Knee joint: comprehensive assessment with 3D isotropic resolution fast spin-echo MR imaging--diagnostic performance compared with that of conventional MR imaging at 3.0 T. *Radiology*. 2009;252:486-495.

31. Chaudhari AS, Black MS, Eijgenraam S, et al. Five-minute knee MRI for simultaneous morphometry and T2 relaxometry of cartilage and meniscus and for semiquantitative radiological assessment using double-echo in steady-state at 3T. *J Magn Reson Imaging* 2017 [Epub ahead of print]
32. Siddiqui MM, Rais-Bahrami S, Turkbey B, et al. Comparison of MR/ultrasound fusion-guided biopsy with ultrasound-guided biopsy for the diagnosis of prostate cancer. *JAMA* 2015;313: 390-397.
33. Tempany CM, Zhou X, Zerhouni EA, et al. Staging of prostate cancer: results of Radiology Diagnostic Oncology Group project comparison of three MR imaging techniques. *Radiology*. 1994;192:47-54.
34. Faria R, Soares MO, Spackman E, et al. Optimising the Diagnosis of Prostate Cancer in the Era of Multiparametric Magnetic Resonance Imaging: A Cost-effectiveness Analysis Based on the Prostate MR Imaging Study (PROMIS). *Eur Urol* 2018;73:23-30.
35. Jambor I, Boström PJ, Taimen P, et al. Novel biparametric MRI and targeted biopsy improves risk stratification in men with a clinical suspicion of prostate cancer (IMPROD Trial). *J Magn Reson Imaging* 2017;46:1089-1095.
36. O'Neill BR, Pruthi S, Bains H, et al. Rapid sequence magnetic resonance imaging in the assessment of children with hydrocephalus. *World Neurosurg* 2013;80:e307-e312.
37. Iskandar BJ, Sansone JM, Medow J, Rowley HA. The use of quick-brain magnetic resonance imaging in the evaluation of shunt-treated hydrocephalus. *J Neurosurg* 2004;101(2 Suppl):147-151.
38. Rozovsky K, Ventureyra EC, Miller E. Fast-brain MRI in children is quick, without sedation, and radiation-free, but beware of limitations. *J Clin Neurosci* 2013;20:400-405.
39. Ashley WW Jr, McKinstry RC, Leonard JR, Smyth MD, Lee BC, Park TS. Use of rapid-sequence magnetic resonance imaging for evaluation of hydrocephalus in children. *J Neurosurg* 2005; 103 (2 Suppl):124–130.
40. Niederhauser BD, McDonald RJ, Eckel LJ, et al. Retrospective review of rapid pediatric brain MR imaging at an academic institution including practice trends and factors affecting scan times. *Am J Neuroradiol* 2013;34:1836-1840.
41. Sunshine JL, Tarr RW, Lanzieri CF, Landis DM, Selman WR, Lewin JS. Hyperacute stroke: ultrafast MR imaging to triage patients prior to therapy. *Radiology* 1999;212:325-332.
42. Willinek WA, Gieseke J, von Falkenhausen M, Neuen B, Schild HH, Kuhl CK. Sensitivity encoding for fast MR imaging of the brain in patients with stroke. *Radiology* 2003;228:669-675.
43. U-King-Im JM, Trivedi RA, Graves MJ, et al. Utility of an ultrafast magnetic resonance imaging protocol in recent and semi-recent strokes. *J Neurol Neurosurg Psychiatry* 2005;76:1002-1005.
44. Bai Q, Zhao Z, Li Y, et al. The application of fast multiparametric protocol MRI-based thrombolysis with rt-PA hyperacute cerebral infarction. *Neurol Res* 2008;30:344-347.

45. Nael K, Khan R, Choudhary G, et al. Six-minute magnetic resonance imaging protocol for evaluation of acute ischemic stroke: pushing the boundaries. *Stroke*. 2014;45:1985-1991.
46. Nogueira RG, Jadhav AP, Haussen DC et al. Thrombectomy 6 to 24 Hours after Stroke with a Mismatch between Deficit and Infarct. *N Engl J Med* 2018; 378:11-21.
47. Grade M, Hernandez Tamames JA, Pizzini FB, Achten E, Golay X, Smits M. A neuroradiologist's guide to arterial spin labeling MRI in clinical practice. *Neuroradiology* 2015;57:1181-1202.
48. Haller S, Zaharchuk G, Thomas DL, Lovblad KO, Barkhof F, Golay X. Arterial Spin Labeling Perfusion of the Brain: Emerging Clinical Applications. *Radiology* 2016;281:337-356.

Table 1. Hierarchical Model for Appraising Diagnostic Imaging (adapted from reference 15)

Level	Examples
1. Technical efficacy	Signal-to-noise, resolution
2. Diagnostic accuracy efficacy	Sensitivity, specificity
3. Diagnostic Thinking efficacy	Impact on diagnosis or differential dx
4. Therapeutic efficacy	Impact on treatment decisions
5. Patient outcome efficacy	Overall survival, QALYs
6. Societal efficacy	Cost effectiveness

Figure Legends

Figure 1: Paired study design

Figure 2: Modified marker strategy design

Figure 3: 54-year old woman, no family history. Digital mammography exhibits heterogeneously dense breast (ACR 3 or C) (a). Breast MRI reveals invasive breast cancer in the right breast, plus a DCIS (b). MR guided biopsy (c) revealed high grade, ER/PR negative, Her2-positive breast cancer plus high grade DCIS.

Figure 4: Screening of the liver for hepatocellular carcinoma (HCC) using dynamic contrast enhanced (DCE) MRI can be performed as part of a focused liver screening protocol. In this example from a 61 year old woman with NASH, a 4.9cm HCC in segment IV of the liver was identified and characterized as an OPTN 5b / LI-RADS 5 lesion using just four breath-holds requiring approximately 5 minutes of table time. All of the features needed to characterize this lesion can be ascertained from this exam, including arterial phase enhancement (late arterial T1w), washout (2 minute delayed T1w) and capsular rim enhancement (portal venous T1W).

Figure 5: Pulmonary MRA can be performed to evaluate patients for pulmonary embolus in 3-4 15-20 second breath-holds: pre-contrast, arterial phase, and 1-2 delayed phase T1 weighted MRA acquisitions), requiring approximately 5-10 minutes of table time. In this example, right lower lobe pulmonary emboli are shown in a 22 year old female presenting with acute chest pain and dyspnea (yellow arrows). Shown are the arterial phase images in coronal (acquired) orientation and axial and cropped double oblique multi-planar reformats (MPR).

Figure 6: A 5-minute knee MRI protocol demonstrating morphometric and semi-quantitative assessment of cartilage. [ref 37]

Figure 7: Images from a prospectively performed biparametric prostate MRI exam consisting of T2 weighted and diffusion imaging in a patient with prior negative biopsies. Imaging time was 11.9 minutes, table time 15 minutes. There is an anterior transition zone lesion that is Category 5 by PIRADs version 2, with low T2 weighted signal (left), persistent signal on $b=1400$ s/mm² image (middle), and low apparent diffusion coefficient (right).

Figure 8: 69-year-old patient, PSA 6,3 ng/ml, increasing. Underwent transrectal ultrasound-guided biopsy four times, always with benign results. Abbreviated (biparametric) prostate MRI shows suspicious lesion in anterior zone (PIRADS-5) Histology on MR-guided targeted biopsy: prostate cancer, Gleason 8 (4+4)

Figure 9: Comparison of ^{18}F FDG-PET and arterial spin labelling MRI, demonstrating decreased metabolism corresponding with decreased perfusion (arrows). With permission from: Pizzini F, Smits M, Wesolowski R, Chapell M, Jäger R, Mutsaerts HJ, Hernandez-Tamames J. Arterial Spin Labelled MRI perfusion imaging techniques. In: Perfusion Imaging in Clinical Practice: A multimodality diagnostic approach to tissue perfusion analysis. Saremi F (ed). Wolters Kluwer, Philadelphia 2015. ISBN 978-1-4511-9316-9

Figure 1: Paired study design

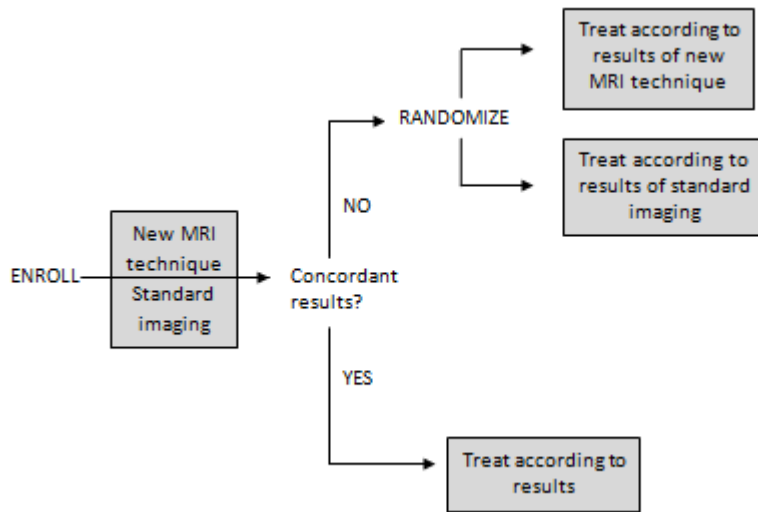


Figure 2: Modified marker strategy design

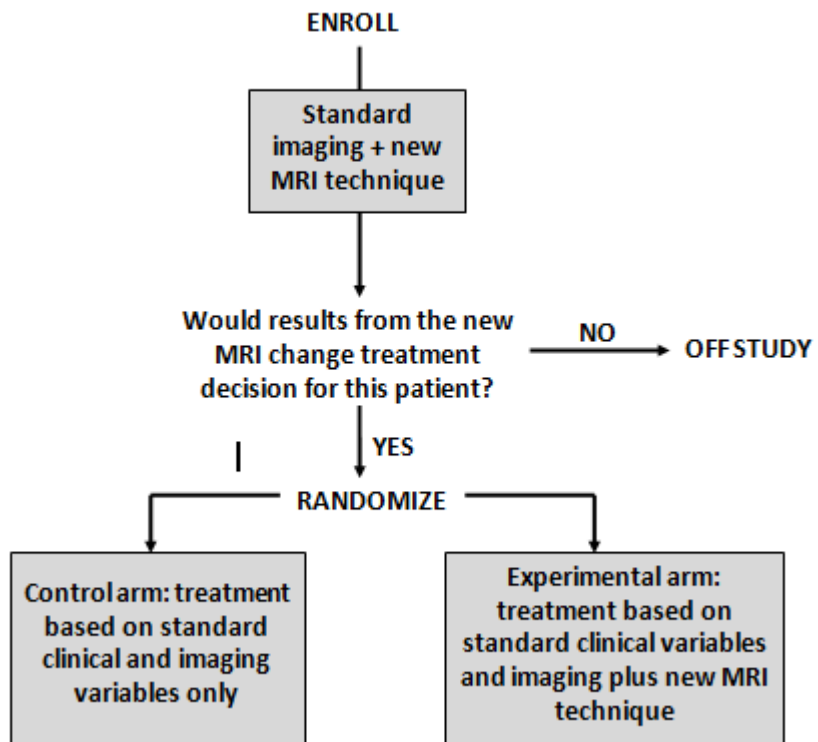
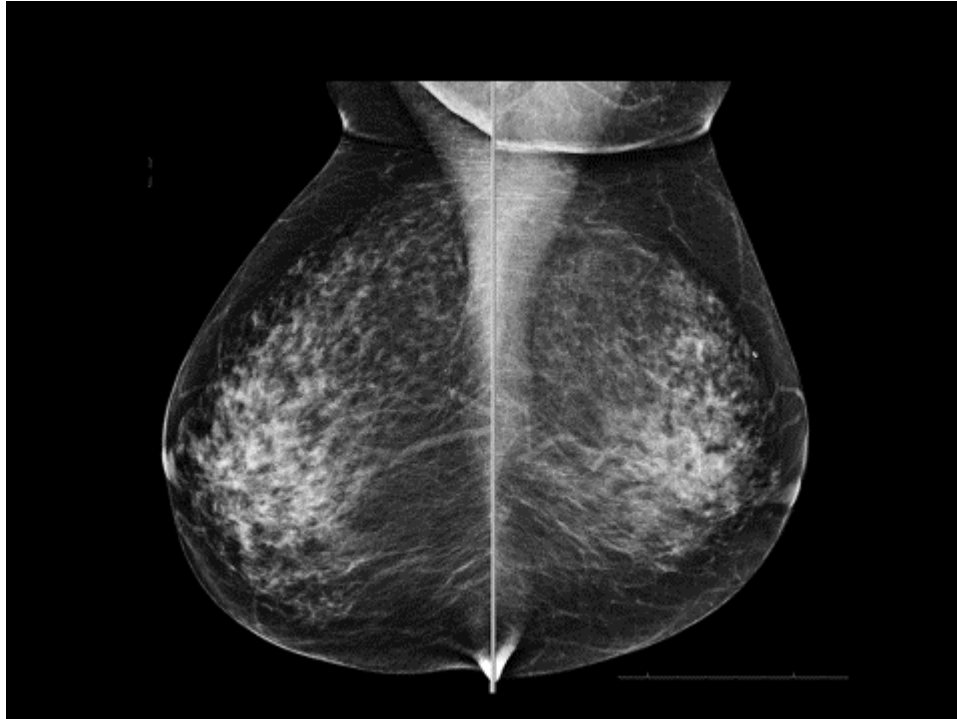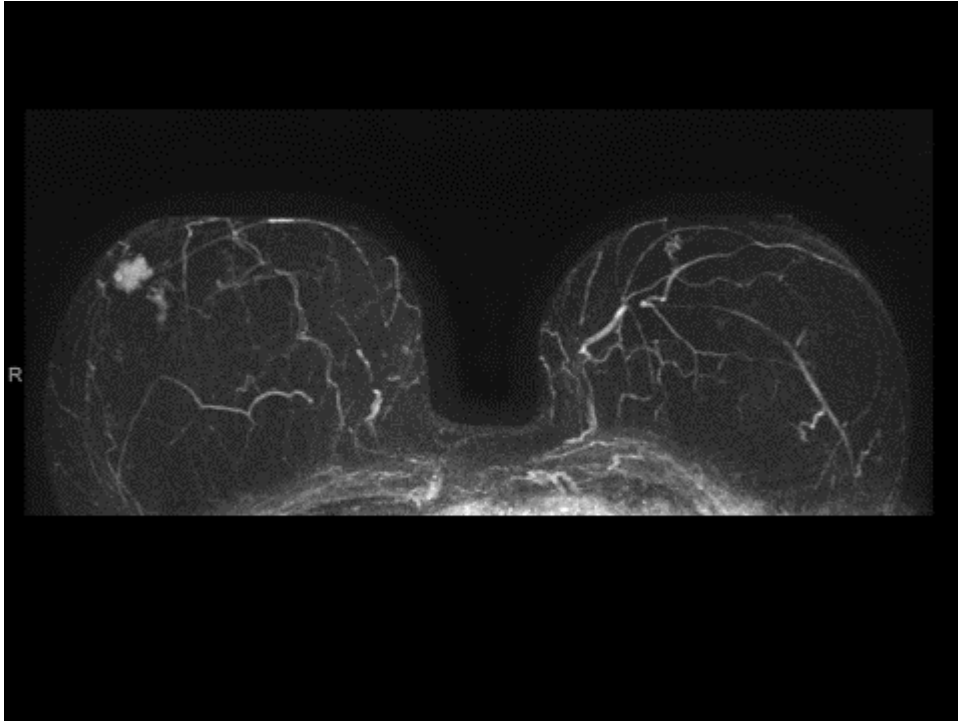


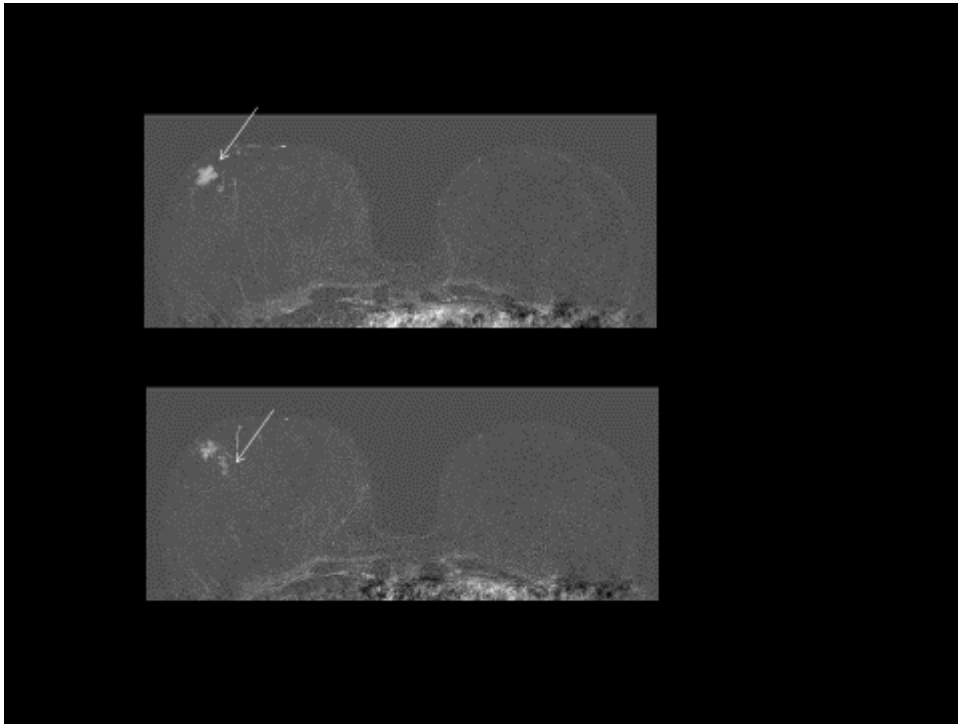
Figure 3: 54-year old woman, no family history. (a) Digital mammography exhibits heterogeneously dense breast (ACR 3 or C). Breast MRI reveals invasive breast cancer in the right breast, plus a DCIS (b). MR guided biopsy (c) revealed high grade, ER/PR negative, Her2-positive breast cancer plus high grade DCIS



(a)



(b)



(c)

Figure 4: Screening of the liver for hepatocellular carcinoma (HCC) using dynamic contrast enhanced (DCE) MRI can be performed as part of a focused liver screening protocol. In this example from a 61-year old woman with NASH, a 4.9cm HCC in segment IV of the liver was identified and characterized as an OPTN 5b / LI-RADS 5 lesion using just four breath-holds requiring approximately 5 minutes of table time. All of the features needed to characterize this lesion can be ascertained from this exam, including arterial phase enhancement (late arterial T1w), washout (2 minute delayed T1w) and capsular rim enhancement (portal venous T1w).

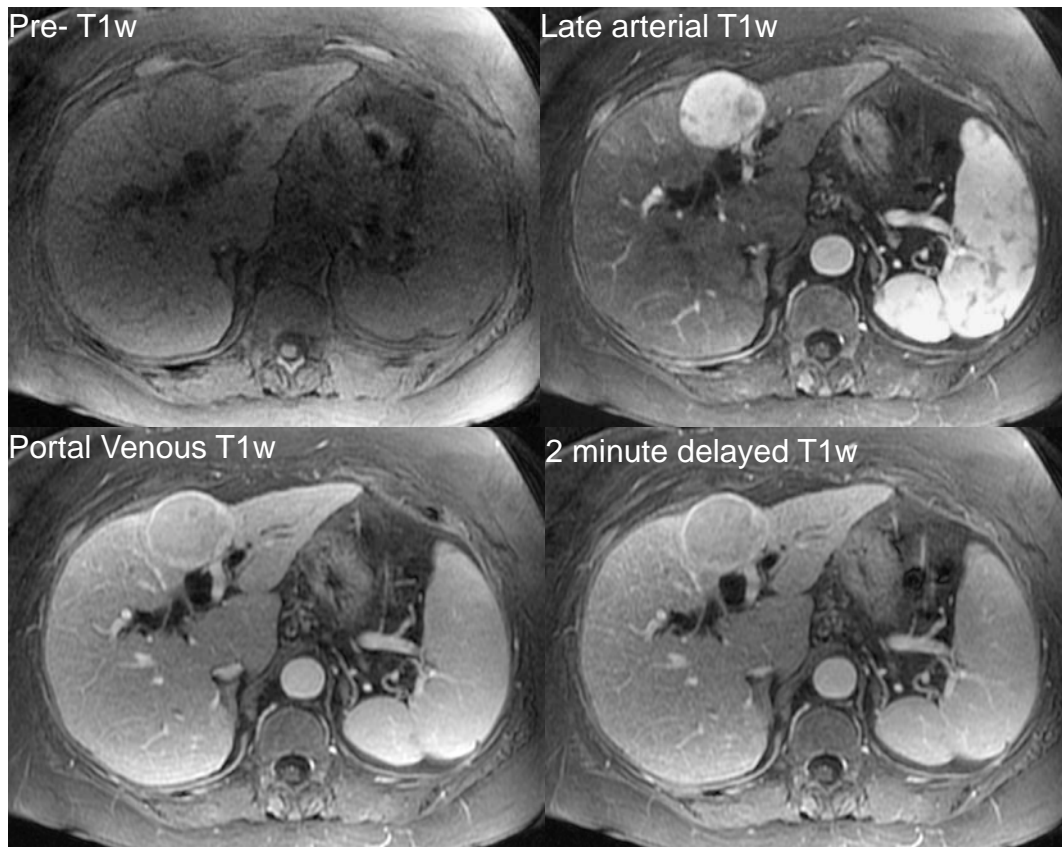


Figure 5: Pulmonary MRA can be performed to evaluate patients for pulmonary embolus in 3-4 15-20 second breath-holds: pre-contrast, arterial phase, and 1-2 delayed phase T1 weighted MRA acquisitions), requiring approximately 5-10 minutes of table time. In this example, right lower lobe pulmonary emboli are shown in a 22 year old female presenting with acute chest pain and dyspnea (yellow arrows). Shown are the arterial phase images in coronal (acquired) orientation and axial and cropped double oblique multi-planar reformats (MPR).

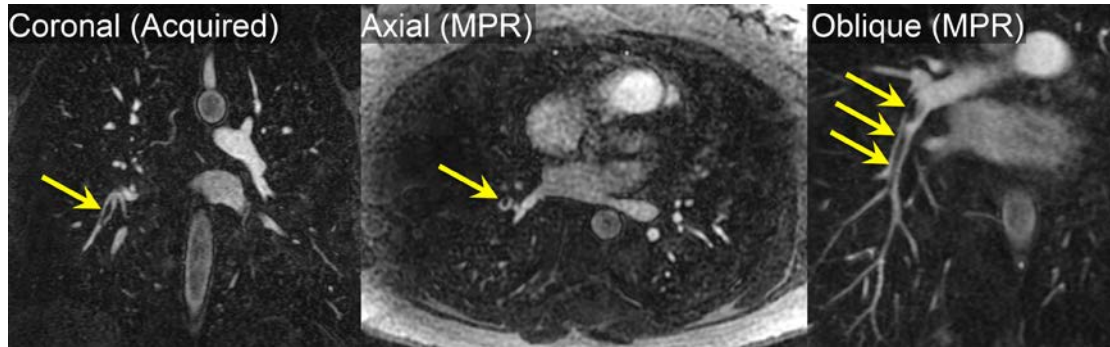


Figure 6: A 5-minute knee MRI protocol demonstrating morphometric and semi-quantitative assessment of cartilage. [ref 37]

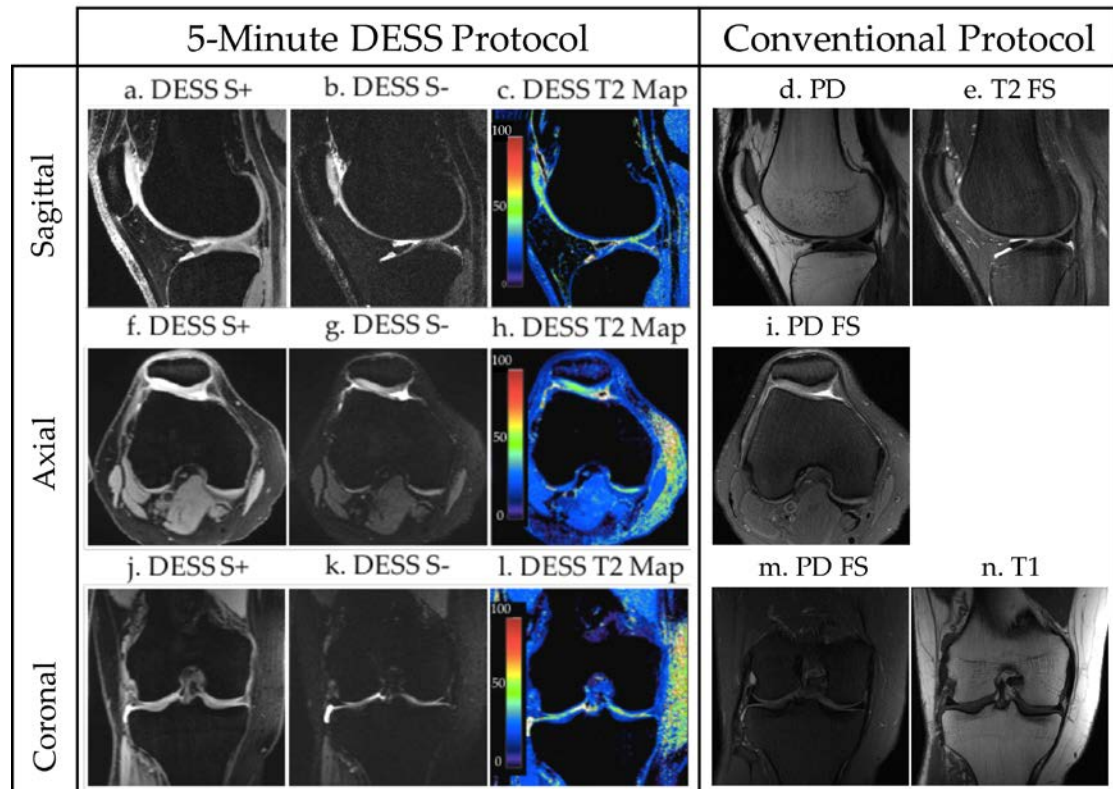


Figure 7: Images from a prospectively performed biparametric prostate MRI exam consisting of T2 weighted and diffusion imaging in a patient with prior negative biopsies. Imaging time was 11.9 minutes, table time 15 minutes. There is an anterior transition zone lesion that is Category 5 by PIRADs version 2, with low T2 weighted signal (left), persistent signal on b=1400 s/mm² image (middle), and low apparent diffusion coefficient (right).

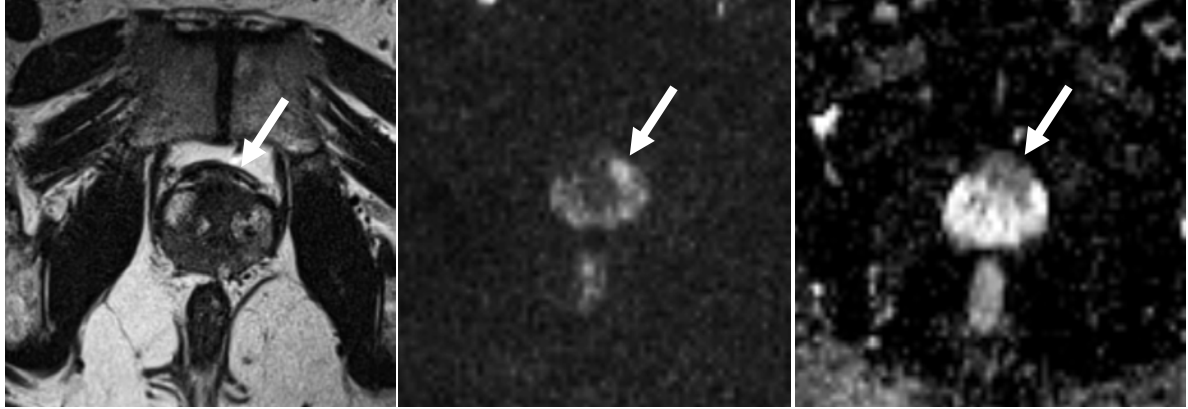

Figure 8: 69-year-old patient, PSA 6,3 ng/ml, increasing. Underwent transrectal ultrasound-guided biopsy four times, always with benign results. Abbreviated (biparametric) prostate MRI shows suspicious lesion in anterior zone (PIRADS-5) Histology on MR-guided targeted biopsy: prostate cancer, Gleason 8 (4+4)

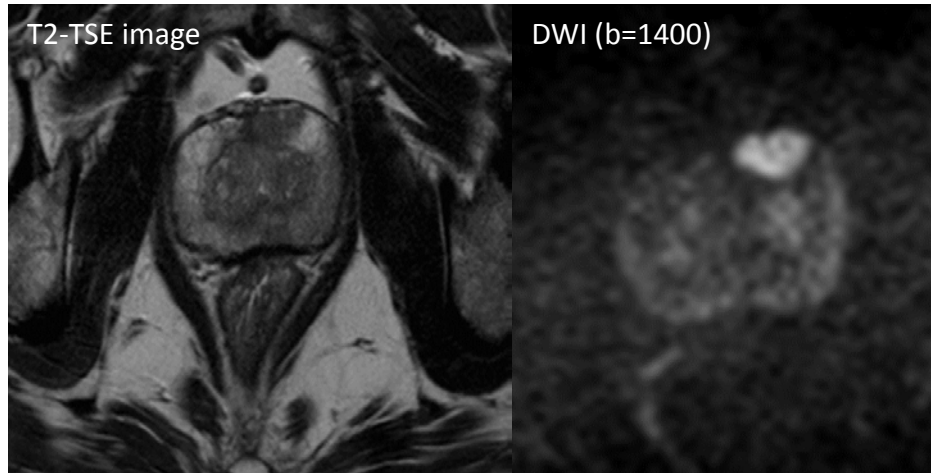


Figure 9: Comparison of ^{18}F FDG-PET and arterial spin labelling MRI, demonstrating decreased metabolism corresponding with decreased perfusion (arrows). With permission from: Pizzini F, Smits M, Wesolowski R, Chapell M, Jäger R, Mutsaerts HJ, Hernandez-Tamames J. Arterial Spin Labelled MRI perfusion imaging techniques. In: Perfusion Imaging in Clinical Practice: A multimodality diagnostic approach to tissue perfusion analysis. Saremi F (ed). Wolters Kluwer, Philadelphia 2015. ISBN 978-1-4511-9316-9

