



Minerva Access is the Institutional Repository of The University of Melbourne

Author/s:

Chowdhury, JMY;Wilks, DJ;Bhat, W;Vollans, S;Foster, N;Wiper, J;Harwood, PJ

Title:

Wrist fusion using an induced membrane technique for forearm salvage in a patient with an infected open injury with segmental bone loss: A case report

Date:

2021-12-01

Citation:

Chowdhury, J. M. Y., Wilks, D. J., Bhat, W., Vollans, S., Foster, N., Wiper, J. & Harwood, P. J. (2021). Wrist fusion using an induced membrane technique for forearm salvage in a patient with an infected open injury with segmental bone loss: A case report. *Trauma Case Reports*, 36, pp.100550-. <https://doi.org/10.1016/j.tcr.2021.100550>.

Persistent Link:

<https://hdl.handle.net/11343/296554>

License:


[CC BY-NC-ND](#)



ELSEVIER

Contents lists available at [ScienceDirect](https://www.sciencedirect.com)

Trauma Case Reports

journal homepage: www.elsevier.com/locate/tcr

Wrist fusion using an induced membrane technique for forearm salvage in a patient with an infected open injury with segmental bone loss: A case report

James M.Y. Chowdhury^{*}, Daniel J. Wilks, Waseem Bhat, Sam Vollans, Nicholas Foster, Jay Wiper, Paul J. Harwood

Department of Trauma & Orthopaedics, Leeds General Infirmary, Great George Street, Leeds LS1 3EX, United Kingdom

ARTICLE INFO

Keywords:

Masquelet
Induced membrane
Limb salvage
Forearm
Reconstruction
Fracture
Bone defect

ABSTRACT

This case report describes the management of a 27-year-old male who, after a quadbike accident, presented with an open, infected, segmental both bone forearm injury with significant bone and soft tissue loss including the radio-carpal joint. Limb salvage was accomplished in the form of a single bone forearm fusion utilising Masquelet's two-stage induced membrane technique to reconstruct the segmental bone defect. The patient proceeded to uneventful bony union by 6 months and returned to driving and riding a quadbike. Despite significant deep infection, successful salvage was achieved using the induced membrane technique. Critical to success was aggressive, repeated debridement alongside restoration of vascular supply and reconstruction of soft tissue defects. We highlight the multidisciplinary approach to management including relevant specialists with a particular interest in limb reconstruction.

Introduction

Significant bone loss from high energy trauma in the upper limb is rare but often occurs in combination with soft tissue loss and neuromuscular injury. Infection and devascularisation are common and mandate extensive debridement, often resulting in significant loss of bone stock. Resultant composite defects represent a complex decision-making and reconstructive challenge.

Several methods have been described to address segmental bone loss including shortening, distraction osteogenesis, vascularised or non-vascularised bone graft, amputation, and more recently Masquelet's induced membrane technique (IMT) [1–3]. Proposed in 1986, the IMT involves two stages [4]. A thorough debridement of bone and soft tissues with temporary stabilisation, conventionally with an external fixator, is performed. An antibiotic loaded polymethyl methacrylate (PMMA) cement spacer is shaped to fill the bony void and the soft tissues are reconstructed. Over subsequent weeks, a biologically active pseudosynovial membrane forms around the spacer. The second stage involves removing the spacer, preserving the membrane and filling the resultant biologically active chamber with autologous bone graft. It is proposed that the membrane's highly vascularised and osteoinductive nature reduces resorption of the bone graft and enhances union [5]. This paper reports an example of such a complex situation, demonstrating successful application of the Masquelet technique for upper limb salvage.

^{*} Corresponding author at: Flat 12, Block A, Victoria Riverside, Atkinson Street, Leeds LS10 1EJ, United Kingdom.

E-mail addresses: james.chowdhury@nhs.net (J.M.Y. Chowdhury), daniel.wilks@rch.org.au (D.J. Wilks), w.bhat@nhs.net (W. Bhat), sam.vollans@nhs.net (S. Vollans), nicholas.foster3@nhs.net (N. Foster), paulharwood@nhs.net (P.J. Harwood).

<https://doi.org/10.1016/j.tcr.2021.100550>

Received 15 August 2021; Accepted 23 October 2021

Available online 25 October 2021

2352-6440/© 2021 The Authors. Published by Elsevier Ltd. This is an open access article under the CC BY-NC-ND license

(<http://creativecommons.org/licenses/by-nc-nd/4.0/>).

Case report

A 27-year-old, previously healthy, right-handed man presented with a crush injury to the left forearm during a quadbike accident sustained overseas. Initial debridement, radial artery repair, and spanning external fixation were performed by the primary receiving unit.

Following repatriation, 2 weeks following injury, the patient presented to our unit. A complex, composite defect remained which was clinically infected, the patient having a white cell count of $12.5 \times 10^3/\mu\text{L}$ and CRP of $213 \mu\text{g/mL}$ (Fig. 1). Both radius and ulna had multi-fragmentary fractures with bone loss. The median nerve was divided with 15 cm loss. The radial artery vein graft had thrombosed leaving an approximately 15 cm deficit from the mid forearm. The ulnar artery was thrombosed at the same level. Hand perfusion was maintained via the posterior interosseous artery. Sensibility via the ulnar and superficial branch of the radial nerve was preserved. A $30 \times 11 \text{ cm}$ skin deficit overlay the open fractures and the superficial digital flexors had been debrided.

Initial treatment comprised debridement and revision external fixation. The distal third of the radius and ulna were infected and non-viable and were removed, including the whole proximal side of the radio-carpal joint (Fig. 2). Deep digital and wrist flexors were intact. The dorsal skin and extensor compartment was intact. The intrinsic musculature was necrotic and debrided. Intravenous teicoplanin and ciprofloxacin targeted *Enterobacter cloacae* and *Bacillus cereus* grown from deep biopsy. Serial debridement followed by negative pressure wound therapy was performed repeatedly until the site was clean.

Following an MDT assessment involving upper limb, trauma and limb reconstruction orthopaedic and plastic surgeons along with microbiologists, treatment options including amputation were discussed with the patient. Despite the challenges involved and projected functional loss, the patient wished an attempt at limb salvage. Wrist fusion, creation of a single bone forearm using an IMT with internal fixation, and a flow-through free anterolateral thigh (ALT) flap for soft tissue cover and hand revascularisation were planned. The first stage of the IMT was performed concurrently with ulnar artery interposition vein graft and a flow-through free ALT using the radial artery as recipient. The hand was centralised to the ulna remnant and a long dorsal fusion plate applied from the radial border of the ulna to the third metacarpal with approximately 5 cm of shortening in mid-prone rotation. To prepare for fusion, the lunate was excised and the triquetrum, capitate and scaphoid decorticated. A PMMA cement spacer with gentamicin and vancomycin was inserted into the resultant defect (Fig. 3). A split skin graft was used over a small remaining tissue defect on the radial border. Six weeks of systemic antimicrobial therapy based upon deep culture results was given.

Four months after the first stage, the second-stage was performed. This was delayed somewhat for logistics. Large volume autologous cancellous bone graft was harvested from the contralateral femur using a RIA system (DePuy Synthes). This was augmented with tri-calcium phosphate graft expander (Vitoss, Stryker Biologics) and bone morphogenetic protein-2 (Osigraft, Stryker Biologics). The cement spacer was removed and replaced with bone graft, preserving the Masquelet membrane, which was closed. Sural nerve grafts reconstructed the median nerve defect.

Uneventful radiographic union occurred at around 6 months, providing a stable platform for rehabilitation without the encumbrance of an external fixator. Intrinsic release and flap debulking were undertaken to improve hand function and aesthetics (Fig. 4). No secondary operations were required for infection or to achieve union. At latest follow up (16 months) the patient remains infection free with a secure soft tissue envelope. He can pick up items with minimal difficulty and drive his car and quadbike unaided.

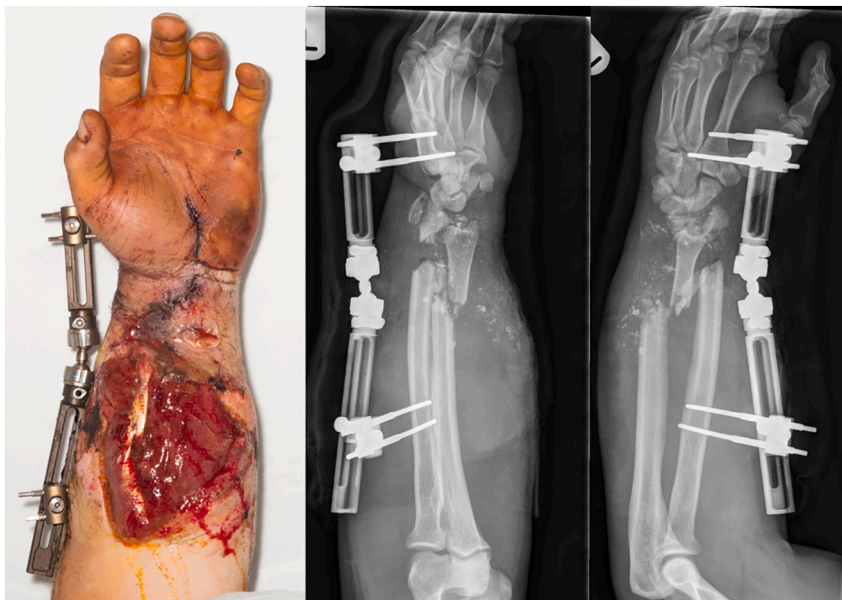


Fig. 1. Clinical photographs and x-rays on presentation to our unit.

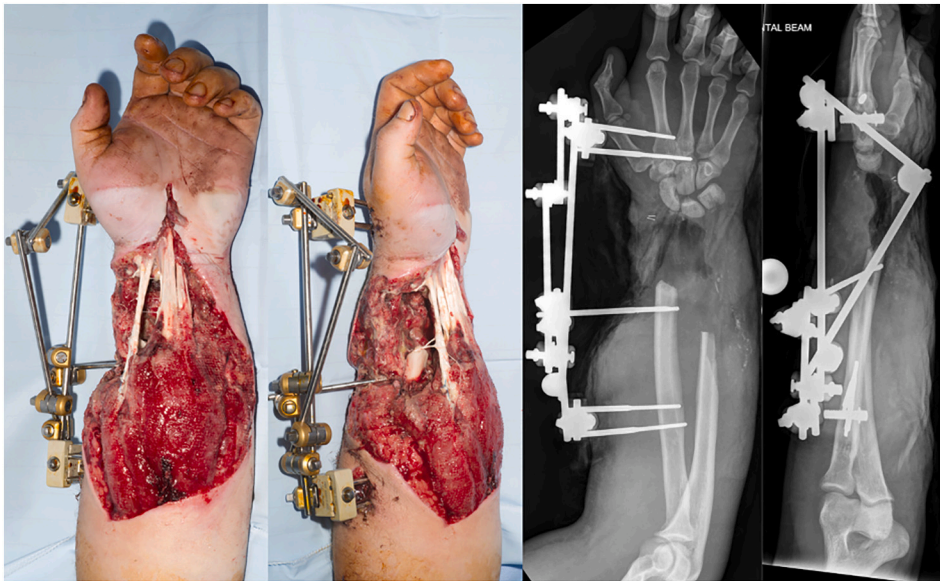


Fig. 2. Clinical photographs and x-rays post debridement.

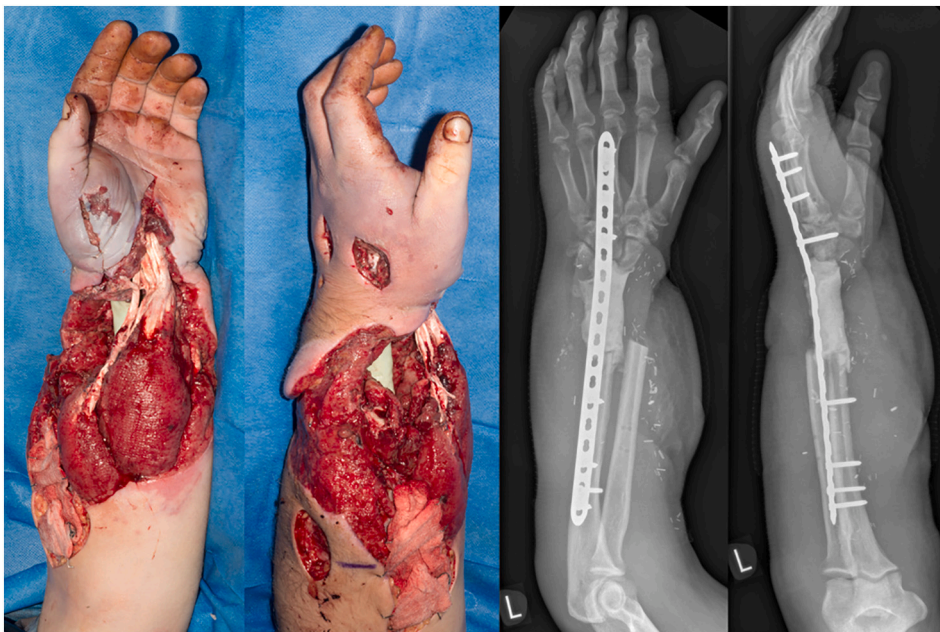


Fig. 3. Clinical photographs and x-rays after cement spacer insertion.

Discussion

Complex forearm injuries with bone, soft tissue, and neurovascular compromise pose a considerable reconstructive challenge. Limb salvage and restoration of hand function are the primary aims, but amputation is a consideration as the burden of reconstruction can be too demanding for some patients and so patients must be counselled thoroughly regarding the options available. Some upper limb prosthesis are poor functionally and psychosocial outcomes can be worse than in the lower limb [6]. Despite concerns about the complexity and limited expectations regarding return of hand function, this patient elected to undergo reconstruction. The aim of treatment was to achieve an infection-free arm with sufficient sensibility to allow bimanual grasp and single hand large object grasp.

Selecting the most appropriate technique for bone reconstruction was challenging. Acute shortening and fusion can be achieved provided the bone defect is <2-3 cm [7]. Greater shortening increases the risk of vascular compromise due to vessel kinking [8] and

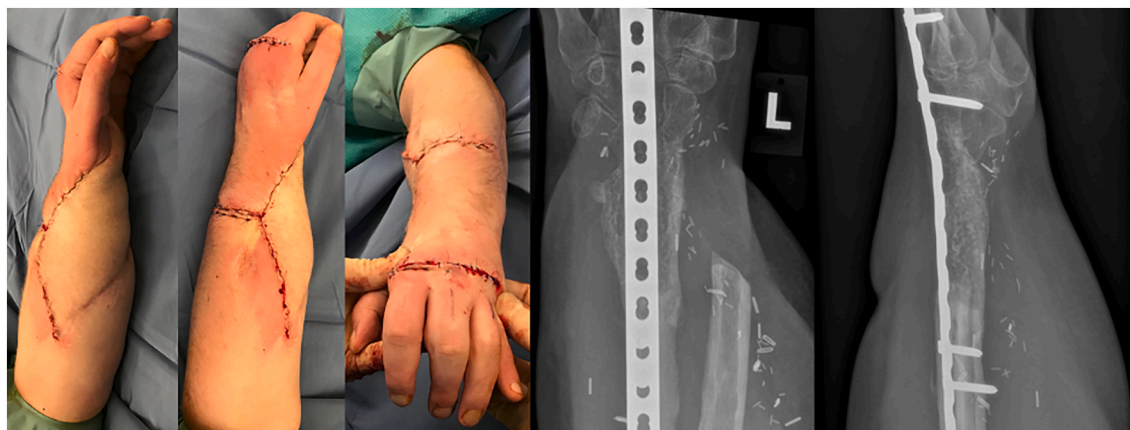

Fig. 4. Clinical photographs post debulking, and x-rays demonstrating union.

alters tendon excursion leading to flexor/extensor imbalance and reduced active range of motion. In this case, as vascular reconstruction was required, vessel kinking was less of a concern. Distraction osteogenesis is a well-established method for managing long bone defects, however this case required fusion between the ulna and the carpus. Docking at the wrist would have proven difficult, along with the risks of transporting bone through a free flap and nerve reconstruction. Furthermore, circular external fixation is less well tolerated in the upper limb and the patient wished to avoid this. Vascularised bone flaps are likely superior to non-vascularised bone in the presence of infection. However, composite flap reconstruction using a free osteocutaneous fibula flap was considered inadequate to address the soft tissue defect. A fibula bone flap would have required a second free flap to reconstruct the skin defect with limited axial vascular supply to the upper limb. It was therefore proposed that bone reconstruction be achieved by wrist fusion using IMT.

Multiple debridements are often required in cases with an extensive zone of injury and a crush mechanism. The full extent of damage often evolves over time, even when previous debridement was deemed adequate, with further areas becoming necrotic and infected. A staged procedure with an antibiotic cement spacer was also therefore preferred to single stage reconstruction given the severity of infection at presentation and multiple procedures that had already been required. The IMT allowed a large segmental defect to be reconstructed without significant donor site morbidity.

Conclusion

Planning is critical in such cases; a multidisciplinary approach and consideration of all available options is required. It is important that potential for functional restoration is considered and the patient aware of projected outcomes. Despite significant infection and devascularisation, thorough debridement followed by internal fixation to achieve bony stability in combination with an induced membrane technique and restoration of robust vascularised soft tissue, union can be achieved. Often, repeated debridement is required to achieve eradication of infection resulting in an optimal environment for graft consolidation. This complex forearm injury, complicated by infection, demonstrates the favourable outcomes that can be achieved using the IMT, with a realistic goal of limb salvage.

Funding

The authors declare no funding to report.

Declaration of competing interest

The authors declare no conflict of interest.

References

- [1] A. Lerner, L. Fodor, M. Soudry, I.J. Peled, D. Herer, Y. Ullmann, Acute shortening: modular treatment modality for severe combined bone and soft tissue loss of the extremities, *J. Trauma* 57 (2004) 603–608.
- [2] K. Millonig, B. Hutchinson, Management of osseous defects in the tibia: utilization of external fixation, distraction osteogenesis, and bone transport, *Clin. Podiatr. Med. Surg.* 38 (2021) 111–116.
- [3] S. Semaya Ael, E. Badawy, M. Hasan, R.M. El-Nakeeb, Management of post-traumatic bone defects of the tibia using vascularised fibular graft combined with Ilizarov external fixator, *Injury* 47 (2016) 969–975.
- [4] C. Karger, T. Kishi, L. Schneider, F. Fitoussi, A.C. Masquelet, French Society of Orthopaedic S, Treatment of posttraumatic bone defects by the induced membrane technique, *Orthop. Traumatol. Surg. Res* 98 (2012) 97–102.

- [5] P. Pelissier, A.C. Masquelet, R. Bareille, S.M. Pelissier, J. Amedee, Induced membranes secrete growth factors including vascular and osteoinductive factors and could stimulate bone regeneration, *J. Orthop. Res.* 22 (2004) 73–79.
- [6] E.E. Desteli, Y. Imren, M. Erdogan, G. Sarisoy, S. Cosgun, Comparison of upper limb amputees and lower limb amputees: a psychosocial perspective, *Eur. J. Trauma Emerg. Surg.* 40 (2014) 735–739.
- [7] H.K. Sharma, G. Colleary, D.M. Marsh, Acute forearm shortening, *Injury* 35 (2004) 531–533.
- [8] N. Kusnezov, J.C. Dunn, J. Stewart, J.S. Mitchell, M. Pirela-Cruz, Acute limb shortening for major near and complete upper extremity amputations with associated neurovascular injury: a review of the literature, *Orthop. Surg.* 7 (2015) 306–316.