

Title Page – Original Research

A retrospective audit of patients referred for further treatment following Mohs Surgery for non-melanoma skin cancer

Authors:

- Edmund Wee¹
- Michelle S Goh¹
- Vanessa Estall²
- Albert Tiong²
- Angela Webb¹
- Catherine Mitchell³
- William Murray³
- Phillip Tran²
- Christopher J McCormack¹
- Michael Henderson¹
- Emma L Hiscutt¹

Declaration:

This paper has not been published or submitted for publication elsewhere.

This research was presented as an oral presentation at the Australasian College of Dermatologists Annual Scientific Meeting in May 2016.

All authors have contributed significantly, and all authors are in agreement with the content of the manuscript.

There was no financial support or relationships that may pose a conflict of interest.

Institution:

This is the author manuscript accepted for publication and has undergone full peer review but has not been through the copyediting, typesetting, pagination and proofreading process, which may lead to differences between this version and the [Version of Record](#). Please cite this article as [doi: 10.1111/ajd.12779](https://doi.org/10.1111/ajd.12779)

This article is protected by copyright. All rights reserved

- ¹Department of Surgical Oncology, The Peter MacCallum Cancer Centre, Parkville, Melbourne.
- ²Department of Radiation Oncology, The Peter MacCallum Cancer Centre, Parkville, Melbourne.
- ³Department of Pathology, The Peter MacCallum Cancer Centre, Parkville, Melbourne.

Contact details for corresponding author:

- Dr Edmund Wee
- Edmundwee1@gmail.com
- Postal Address:
Department of Surgical Oncology
The Peter MacCallum Cancer Centre
305 Grattan St, Melbourne VIC 3000
- Mobile: 0419907818

Word Count:

Abstract: 250 Words

Main text (not including references, tables, figures): 2632 Words

Figures: 3

Tables: 3

Article type : Original Research

Abstract

Background/Objectives

This study describes the characteristics, subsequent management and outcomes of patients referred for further management following Mohs micrographic surgery (MMS) for basal cell carcinoma (BCC) and squamous cell carcinoma (SCC).

Methods

Retrospective analysis of patients referred to a quaternary cancer center from 2000 to 2015.

Results

In total, 83 lesions in 82 patients were referred for further management; 52 (62%) were SCC and 80 (96%) were located in the head and neck. Reasons for referral included high-risk disease for consideration of adjuvant radiotherapy (37/83, 45%), inadequate resection (28/83, 34%) or recurrence following previous MMS (15/83, 17%). Less than 40% of the 69 referrals received from MMS surgeons included photos or an operative report and diagram.

There was discordance in pathology opinion in 11 (13%) of our cases. Histology from MMS was reviewed in eight cases and there was discordance with the in-hospital pathology opinion in six of these. In-hospital re-excision was performed in 19 cases and in five of these the pathology report on the paraffin-sectioned re-excised tissue was discordant with prior MMS assessment. Significantly, 2 cases

were associated with misinterpretation of lymphocytic infiltrate as residual disease in patients with chronic lymphocytic leukemia (CLL).

Conclusion

This study highlights some of the challenges and limitations of MMS. Early referral for multidisciplinary management is recommended when MMS resection margins are inadequate or uncertain, especially for high-risk SCC. We recommend that referrals be accompanied by histological material, as well as a detailed report with operative photos and diagrams. CLL can pose an intraoperative diagnostic challenge. Discrepancies relating to MMS slide interpretation present an opportunity for improvement, and our findings support the role of ongoing quality assurance programs.

Key words

Mohs micrographic Surgery, SCC, BCC, non-melanoma skin cancers, laboratory discrepancy

Learning Points

- CLL can pose an intraoperative diagnostic challenge during MMS.
- Discrepancies relating to MMS slide interpretation support ongoing quality assurance programs and consideration of pathology reviews in cases of uncertainty.
- Early referral for multidisciplinary management is recommended in high-risk disease, or when MMS resection margins are inadequate.

- Detailed MMS reports are essential for further multidisciplinary management, in particular for planning adjuvant radiotherapy.

Introduction

Mohs micrographic surgery (MMS) is well established in the management of basal cell carcinoma (BCC) and squamous cell carcinoma (SCC).¹ Indications for MMS include the management of patients at high risk of local recurrence or the need for tissue sparing in key head and neck sites.¹ While MMS is usually a safe and well-tolerated outpatient procedure,² it is not without complications and recurrences may occur.

For patients with compromised margins following MMS, further excision is recommended.³ When repeat excision is not technically possible or is declined due to associated morbidity such as cosmetic disfigurement; radiotherapy may be considered.³ Adjuvant radiotherapy is also indicated for patients with clear margins but a high risk of local recurrence, such as when extensive perineural invasion is present.⁴

The aim of this study was to review our experience, at a quaternary cancer centre, with patients referred for further management following MMS. The indications for referral, management and outcomes of these high-risk patients were examined to identify potential management issues.

Materials and Methods

Patient selection.

All patients were treated at a quaternary cancer center in Victoria, Australia between January 1, 2000 and June 1, 2015. Patients were identified through the Health Information Service Master Patient Index and the Department of Pathology database. The search term 'Mohs' was used and all patient records were retrospectively reviewed to determine eligibility. Only BCC or SCC cases previously treated with MMS, performed by an Australasian College of

Dermatologists' accredited Mohs surgeon and subsequently referred for further management were included. Patients were managed by a multidisciplinary team including dermatologists, plastic surgeons, head and neck surgeons as well as radiation oncologists. Pathology reviews were conducted by trained fellows of the Royal College of Pathologists of Australasia, all with extensive experience in interpreting cutaneous pathology. Recurrent tumours were defined as those that recurred within ten years of prior excision. The study was approved by the Human Research Ethics committee at our institution.

Data Collection

Data collected included primary reason for referral, patient age, sex, comorbidities as well as tumour characteristics including histological subtype, size, site, depth, previous recurrence and the presence of perineural or perivascular invasion.

Details of the prior MMS procedure were obtained from referral letters and operative reports, where available. When pathology reviews of MMS slides or lesion re-excision had been performed, the pathologist's opinion was compared with that of the Mohs Surgeon to evaluate any discordance in pathology assessment. The subsequent timing and mode of treatment undertaken, as well as the development of recurrence during follow up, was also collected.

Statistical Analysis

Summary statistics only are presented (median and range), as the small numbers precluded further meaningful statistical analysis.

Results

Patient characteristics

The patient demographics are summarised in Table 1. There were a total of 83 SCC and BCC lesions, in 82 patients, that were referred following previous MMS. The majority of lesions were SCC (63%) and most were located on the head and neck (96%). The patients were predominantly male (72%), with a median age of

72 years (range, 28 – 97 years). Fourteen patients were immunosuppressed due to underlying haematological malignancy or immunosuppressive medications. Four patients had received previous radiotherapy in the proximity of the current lesion. One patient was pregnant at the time of presentation. The median follow up period at our institution, calculated from first attendance to last appointment or death, was 11 months (range, 0.5 – 84 months).

Risk factors for recurrence are shown in Table 2 and 3. The majority of SCC (67%) and BCC (81%) cases had two or more risk factors for local and/or distant recurrence.

Primary reason for referral

The primary reasons for referral after MMS are summarised in Figure 1. Referrals came from 14 MMS surgeons. The majority of patients were referred for urgent management, following recent MMS (69/83, 82%), whilst the remainder (14/83, 17%) were referred for management of recurrence that had arisen following previous MMS. Three patients in the former group (n=69) had just undergone a second MMS procedure for disease recurrence. Nearly half (46%) of the patients referred for uncertain or incomplete MMS margin clearance had tumour involving or adjacent to periosteum.

Referral data

Less than 40% of the 69 referrals received from Mohs surgeons included photos or an operative report and diagram. Only 18 (26%) accurately reported the pre-operative size of the primary lesion, while just 13 (19%) included photographs. An operative report or diagram was included in 25 (36%) and defect size was described in 27 (39%) of referrals.

Recurrence after previous MMS

In the study, there were 17 cases (10 SCC, 7 BCC) that were managed for recurrence following MMS. Fifteen were local recurrences, while 3 were metastatic recurrences in regional lymph nodes.

For SCC, the median time from MMS to recurrence and referral to our institution was 4.5 months (range, 1 – 36 months). For BCC, the median time from MMS to recurrence and referral to our institution was 45 months (range, 1 – 108). Furthermore, of the 10 recurrent SCCs, 4 recurred within one month of MMS (2 locally recurrent and 2 with lymph node metastases).

Pathology Assessment

There were 8 lesions (3 BCC, 5 SCC) that underwent a pathology review of MMS slides prior to further treatment at our institution. In this group, 5 had been referred with uncertain margin clearance and 3 with high-risk disease for consideration of adjuvant therapy. The pathologist disagreed with the intraoperative MMS assessment in 6 (75%) of these cases. Four were false negatives where the pathologist identified residual tumour in areas reported by the Mohs surgeon as clear. Two cases involved previously unrecognised perineural invasion (PNI) that was identified by the pathologist. In one case this went on to influence management, as this PNI was assessed to be an indication for adjuvant radiotherapy. The pathologists concurred with the MMS assessment in the remaining 2 cases, however, in one of these the pathologist determined that margin clearance could not be confirmed due to the presence of scar tissue.

Of the 69 lesions referred by Mohs surgeons after recent MMS treatment, 19 underwent local re-excision. Of the 18 lesions that had available pathology reports on paraffin sections of the reexcision specimen, discordance with prior MMS assessment was noted in 5 cases (28%; 2 BCC, 3 SCC). Two were false negatives where residual disease was found on re-excision pathology, though the Mohs surgeon had reported this as clear; these lesions were re-excised due to the presence of high-risk features. Three were false positives where the Mohs surgeon had reported involved margins, though subsequent re-excision was negative; these lesions had been referred for further management of incomplete margin clearance. Of note, 2 of the false positives involved misinterpretation of lymphocytic infiltrate as residual disease in patients with known chronic lymphocytic leukemia (CLL). This had led to a large resection field (60x55mm) during MMS in one of these cases.

Management and outcomes

The management undertaken at our institution following appropriate restaging investigations and multidisciplinary discussion is summarised in Figure 2. The majority of cases (86%) underwent further treatment. The remainder were managed conservatively, with close observation (5%) or palliative radiotherapy (1%). Seven patients (8%) declined treatment or were lost to follow up.

For lesions that underwent adjuvant radiotherapy alone, the median interval from MMS to commencement of radiation treatment was 55 days (range, 27 – 204 days). For lesions that underwent re-excision and adjuvant radiotherapy, the median interval from surgery to commencement of radiation treatment was 47 days (range, 22 – 134 days).

Whilst no recurrences occurred in patients managed with observation alone, there were 9 cases (13%) of recurrence after further treatment at our institution. In this group, 3 were locally recurrent BCCs, 2 were locally recurrent SCCs, 2 were SCCs with local recurrence in addition to regional metastases and 2 were SCCs with distant metastases. Three of the locally recurrent tumors had narrow or unclear surgical margins, where attempted re-excision had been difficult due to a deeply invasive tumor. For SCC, the median time from completion of further treatment to recurrence was 10.5 months (range, 0 – 24 months). For BCC, the median time from completion of further treatment to recurrence was 38 months (range, 3 – 56 months)

Discussion

In this retrospective study, we describe the characteristics and outcomes of 83 BCC and SCC lesions that were referred to a quaternary cancer centre after MMS treatment. MMS is typically used to manage non-melanoma skin cancers (NMSC) that have features such as a mid-facial location, size exceeding 2 cm, high-risk histologic features including PNI, or that are recurrent or incompletely excised.¹ Given these indications for MMS, it was not surprising that a large proportion of

lesions in the study were located in the head and neck and had multiple adverse features. However, it was noteworthy that while the vast majority (greater than 90%) of MMS is used to treat BCC,⁵ most of the lesions in our cohort were SCC (62%).

Complete surgical excision remains the gold standard treatment for NMSC,⁴ with current expert consensus that adjuvant radiotherapy be considered in cases with a high risk of recurrence.⁴ In particular, these are lesions with PNI of large nerves (greater than 0.1mm), repeated recurrence or multiple high-risk features.⁴ Consistent with this, the most common reason for referral of NMSC after MMS in our study was for consideration of adjuvant radiotherapy in the setting of high-risk disease.

Similar to other treatment modalities, MMS has limitations and complete excision is not always attainable. For instance, tumours may invade major anatomical structures as well as bone, which is less amenable to frozen section examination.^{1,6} Uncertainty with margin clearance may arise with deeper tumours, due to increased difficulty with maintaining the orientation of specimens during mapping.⁶ Nevertheless, unintended incomplete MMS is rare, with one large study demonstrating an incidence of 0.15%.⁶ In our study, uncertain or incomplete margin clearance was the second most common reason for referral for further management after MMS. Nearly half of these cases had tumour adjacent to or involving periosteum.

Although MMS has the highest reported cure rates for NMSC¹, recurrences can still occur. A systematic review assessing outcomes of SCC treated with MMS demonstrated a pooled average local recurrence rate of 3%.⁷ Other studies have shown that primary and recurrent BCC had a five-year recurrence rate of 1% and 4% respectively after MMS.⁸ The findings of this study are consistent with the known potential aggressive nature of SCC;⁹ it had a much shorter time to recurrence following MMS compared to BCC and there were 4 recurrences of SCC that developed within 1 month of MMS. Australian guidelines recommend clinical and histological excision margins of 4mm and 1mm respectively for

SCC.¹⁰ The best approach to management of high-risk SCC is not definitely known.^{11,12} However, consensus UK guidelines recommend a wider ≥ 6 mm clinical margin to ensure completeness of tumour clearance in such cases.¹¹ Furthermore, early (and ideally, preoperative) multidisciplinary discussion is recommended should there be concerns or difficulties with margin clearance.¹¹

The high rate of clear histological margins associated with MMS is critically dependent on the ability of the surgeon to accurately evaluate frozen histopathological specimens, thus allowing residual tumour to be precisely mapped and sequentially removed.¹ It is not routine to send specimens for formal reporting by an anatomical pathologist and so the assessment of margin control is usually wholly dependent on the Mohs surgeon. However, while previous studies have demonstrated good concordance rates (95 – 99%) between Mohs surgeons and dermatopathologists,¹³⁻¹⁶ others have shown that at least 30% of recurrences after MMS are due to errors in slide interpretation leading to unexcised tumour.¹⁷⁻¹⁹ Poor slide quality with tissue drop out may contribute to misinterpretation and has also been recognized as a risk factor for recurrence after MMS.^{18,19} In this study, there was a relatively high rate of MMS histopathology discordance, although this is reflective of the cohort being a sample of complex cases referred to our institution. Nevertheless, our findings support the role of continuing quality improvement measures, such as additional pathology reviews²⁰ and the mandatory quality assurance program recently implemented by the Australasian College of Dermatologists.²¹

CLL presents a unique intraoperative diagnostic challenge for the Mohs surgeon. The complete excision of SCC is of particular importance in patients with CLL given that they are at risk of aggressive SCCs with a high rate of recurrence and metastasis.²² However, dense lymphocytic infiltrate in the skin is often seen in CLL and this may obscure or be mistaken for tumour.^{23,24} In our study, 2 cases had a leukaemic infiltrate that was misinterpreted as tumour during MMS. Other previous similar reports²⁴⁻²⁶ also highlight the importance of recognizing CLL

leukaemic infiltration as a differential diagnosis, particularly in elderly patients.²⁷ In cases of diagnostic uncertainty, useful options include pathologist review of MMS slides or submission of excised tissue for paraffin sections with immunohistochemistry and delayed reconstruction.^{11,28}

Most of the NMSC in our cohort were managed with a combination of re-excision and/or radiotherapy. When adjuvant radiotherapy is used to minimise the risk of recurrence after NMSC excision, treatment should ideally be started with minimal delay. Previous studies in mucosal head and neck SCC have indicated that an interval between surgery and postoperative radiotherapy of more than 6 weeks may impair outcome.²⁹ In our study, adjuvant radiotherapy was delayed by greater than 6 weeks on average, though the reasons for this were multifactorial. Contributing factors included delayed referral for multidisciplinary management, waitlist times, poor patient performance status, time needed for further investigations and slow wound healing due to skin graft failure or planned secondary intention healing. Secondary intention healing should ideally be avoided if the patient requires adjuvant radiotherapy.

Another issue that was highlighted by this study was the frequent lack of detail in referrals received from Mohs surgeons, with fewer than 40% providing photos or operative diagrams and details. In our experience, this lack of information caused difficulties with radiotherapy planning, resulting in the need for a larger radiation field. A proforma for Mohs surgeons referring to our centre has since been created to improve communication during the referral process (see Figure 3).

This study had several limitations, particularly since it was limited to cross-sectional retrospective data at a single site. Data on comparable referrals following conventional surgery was not available, precluding comparisons with MMS. Our cohort is unlikely to be representative of all MMS procedures in general, due to selection bias for high-risk and complex cases. The absolute number of MMS procedures, from which our cohort arose, could not be accurately estimated. Based on department of health statistics, approximately

27000 MMS procedures were undertaken in our catchment area during the study period, but a number of these may have been referred to other tertiary centers or private practitioners. Nevertheless, our data reflects our experience as a major multidisciplinary referral centre for complex skin cancers. The duration of follow up in the study was also variable, with some patients returning to their primary referring specialist after treatment. Although patients would likely have been re-referred if major complications were to occur, our limited follow up duration in some patients could have led to an underestimation of the observed rate of recurrence following treatment at our center.

In summary, this study highlights some of the challenges and limitations associated with MMS for high-risk NMSC. Complete margin clearance is not always possible, particularly when there is invasion to deep underlying structures such as bone. MMS slide interpretation can be difficult in patients with CLL and pathologist review should be sought in cases of uncertainty.

Discrepancies relating to MMS slide interpretation present an opportunity for improvement and our findings support the role of ongoing quality assurance programs. Early referral for multidisciplinary management is recommended in high-risk disease, especially for SCC, or when MMS resection margins are inadequate. We recommend that referrals be accompanied by histological material as well as a detailed report with operative photos and diagrams, particularly in cases with high-risk disease, incomplete margin clearance or diagnostic uncertainty.

References

1. Shriner DL, McCoy DK, Goldberg DJ, et al. Mohs micrographic surgery. *J Am Acad Dermatol* 1998; 39: 79-97.
2. Alam M, Ibrahim O, Nodzenski M, et al. Adverse events associated with mohs micrographic surgery: multicenter prospective cohort study of 20,821 cases at 23 centers. *JAMA Dermatol* 2013; 149: 1378-85.

3. Nguyen BM, Schmults CD. Update on Evaluation and Management of High-Risk Squamous Cell Carcinomas. *Curr Derm Rep* 2014; 79-85.
4. Gupta A, Veness M, De'Ambrosio B, et al. Management of squamous cell and basal cell carcinomas of the head and neck with perineural invasion. *Australas J Dermatol* 2016; 57: 3-13.
5. Lim P, Paver R, Penas PF. Mohs micrographic surgery at the Skin and Cancer Foundation Australia, 10 years later (1997 vs 2007). *J Am Acad Dermatol* 2010; 63: 832-5.
6. Madani S, Huilgol SC, Carruthers A. Unplanned incomplete Mohs micrographic surgery. *J Am Acad Dermatol* 2000; 42: 814-9.
7. Lansbury L, Bath-Hextall F, Perkins W, et al. Interventions for non-metastatic squamous cell carcinoma of the skin: systematic review and pooled analysis of observational studies. *BMJ* 2013; 347: f6153.
8. Leibovitch I, Huilgol SC, Selva D, et al. Basal cell carcinoma treated with Mohs surgery in Australia II. Outcome at 5-year follow-up. *J Am Acad Dermatol* 2005; 53: 452-7.
9. Nerad JA. All skin cancers are not created equal. *Br J Ophthalmol* 2007; 91: 276-7.
10. Basal Cell Carcinoma, squamous cell carcinoma (and related lesions) - a guide to clinical management in Australia. Cancer Council Australia 2008.
11. Newlands C, Currie R, Memon A, et al. Non-melanoma skin cancer: United Kingdom National Multidisciplinary Guidelines. *J Laryngol Otol* 2016; 130: S125-S32.
12. Squamous Cell Skin Cancer. *NCCN Clinical Practice Guidelines in Oncology* 2017.
13. Semkova K, Mallipeddi R, Robson A, et al. Mohs micrographic surgery concordance between Mohs surgeons and dermatopathologists. *Dermatol Surg* 2013; 39: 1648-52.
14. Tan E, Elliott T, Yu L, et al. Mohs surgery histopathology concordance in Australia. *Australas J Dermatol* 2011; 52: 245-7.
15. Lane JE, Chiller KG, Baucom MF, et al. Mohs micrographic surgery histopathology concordance in fellowship-trained surgeons. *J Am Acad Dermatol* 2010; 62: 148.

16. Mariwalla K, Aasi SZ, Glusac EJ, et al. Mohs micrographic surgery histopathology concordance. *J Am Acad Dermatol* 2009; 60: 94-8.
17. Lee KC, Higgins HW, 2nd, Dufresne RG, Jr. Tumor recurrence after Mohs micrographic surgery. *J Am Acad Dermatol* 2014; 70: 385-6.
18. Hruza GJ. Mohs micrographic surgery local recurrences. *J Dermatol Surg Oncol* 1994; 20: 573-7.
19. Campbell T, Armstrong AW, Schupp CW, et al. Surgeon error and slide quality during Mohs micrographic surgery: is there a relationship with tumor recurrence? *J Am Acad Dermatol* 2013; 69: 105-11.
20. van Lee CB, Graafland B, Koljenovic S, et al. Additional review of Mohs slides to optimize Mohs micrographic surgery. *Br J Dermatol* 2015; 173: 123-7.
21. Mohs Diagnostic Module. Australasian College of Dermatologists. (Accessed 25 September, 2017, at <https://www.rcpaqap.com.au/mohs-diagnostic-module>.)
22. Perez-Reyes N, Farhi DC. Squamous cell carcinoma of head and neck in patients with well-differentiated lymphocytic lymphoma. *Cancer* 1987; 59: 540-4.
23. Mehrany K, Byrd DR, Roenigk RK, et al. Lymphocytic infiltrates and subclinical epithelial tumor extension in patients with chronic leukemia and solid-organ transplantation. *Dermatol Surg* 2003; 29: 129-34.
24. Albregts T, Orengo I, Salasche S, et al. Squamous cell carcinoma in a patient with chronic lymphocytic leukemia. An intraoperative diagnostic challenge for the Mohs surgeon. *Dermatol Surg* 1998; 24: 269-72.
25. Padgett JK, Parlette HL, 3rd, English JC, 3rd. A diagnosis of chronic lymphocytic leukemia prompted by cutaneous lymphocytic infiltrates present in mohs micrographic surgery frozen sections. *Dermatol Surg* 2003; 29: 769-71.
26. Walther BS, Gibbons G, Chan EF, et al. Leukemia cutis (involving chronic lymphocytic leukemia) within excisional specimens: a series of 6 cases. *Am J Dermatopathol* 2009; 31: 162-5.
27. Kipps TJ. Chronic lymphocytic leukemia. *Curr Opin Hematol* 2000; 7: 223-34.
28. Behan FC, Rozen WM, Kwee MM, et al. Oncologic clearance with preservation of reconstructive options: literature review and the 'delayed

reconstruction after pathology evaluation (DRAPE)' technique. *ANZ J Surg* 2012; 82: 780-5.

29. Marshak G, Popovtzer A. Is there any significant reduction of patients' outcome following delay in commencing postoperative radiotherapy? *Curr Opin Otolaryngol Head Neck Surg* 2006; 14: 82-4.

Figure legends

Figure 1. Summary of the study cohort, based on primary reason for referral after Mohs Micrographic Surgery, for non-melanoma skin cancer.

Figure 2. Summary of management undertaken at our quaternary cancer center, for cases where further management was required after Mohs Micrographic Surgery for non-melanoma skin cancer.

Figure 3. Proforma for Mohs surgeons referring patients for further multidisciplinary management

Table 1. Characteristics of study population

Characteristic	Number of lesions (n=83; 82 patients)
Median (range) of age at presentation, years	72 (28 – 97)
Sex	
- Male	60 (72.2%)
- Female	23 (27.7%)
Tumour Type	
- SCC	52 (62.7%)
- BCC	31 (37.3%)
Location	
- Head and Neck	80 (96.3%)
- Back	1 (1.2%)
- Chest	1 (1.2%)
- Upper Limb	1 (1.2%)
Immunosuppression, total	13 (15.7%)
- Haematological Malignancy	
○ Chronic Lymphocytic Leukaemia	2 (2.4%)
○ Myelofibrosis	1 (1.2%)
○ Waldenstrom's Macroglobulinaemia	1 (1.2%)
- Solid Organ Transplant	

<ul style="list-style-type: none"> ○ Renal ○ Lung - Other indication for immunosuppressive medication <ul style="list-style-type: none"> ○ Rheumatoid arthritis ○ Bullous Pemphigoid 	2 (2.4%) 1 (1.2%) 5 (6.0%) 1 (1.2%)
Median (range) follow up period, months	11 (0.5 – 84)

SCC, squamous cell carcinoma; BCC, basal cell carcinoma

Table 2. Adverse features of squamous cell carcinomas, referred following MMS

Risk Factor for SCC recurrence	Number of lesions (N= 52)
Primary site (Ear, non-glabrous lip)	15 (29%)
Poorly differentiated on histology	16 (29%)

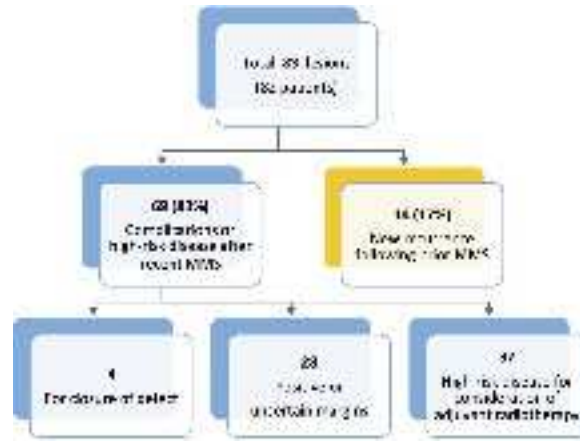
Perineural invasion	23 (44%)
Recurrent Disease	23 (44%)
Clark level \geq IV (Invasion into cartilage, skeletal muscle, periosteum)	19 (37%)
2 or more Risk factors	29 (67%)

SCC, squamous cell carcinoma; MMS, Mohs Micrographic Surgery

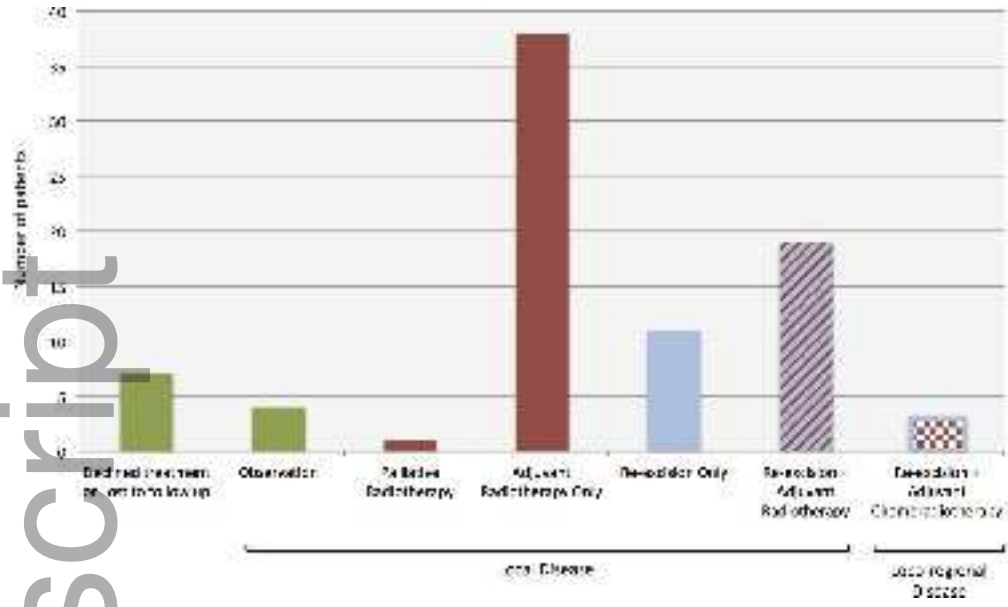
Table 3. Adverse features of basal cell carcinomas referred following MMS

Risk Factor for BCC recurrence	Number of lesions (N=31)
Primary site (Eyes, nose, lips, ears)	22 (71%)
Histological subtype (Morphoeic, infiltrative or micronodular)	14 (44%)
Perineural invasion and/or perivascular involvement	12 (38%)
Recurrent Disease	10 (32%)
2 or more Risk Factors	25 (81%)

BCC, basal cell carcinoma; MMS, Mohs Micrographic Surgery



ajd_12779_f1.jpg



ajd_12779_f2.jpg

Mohs Surgery Referral Checklist

1. Details of referring surgeon

Name of referrer	
Contact Number Tels Email	
Practice Address	
Provider Number	

2. Details of patient

Name of patient	
Sex	
Date of birth / Age	
Patient Address	
Contact number	

3. Reason for referral (Tick all that apply)

<input type="checkbox"/> Closure of Defect <input type="checkbox"/> In-situ / Thin or healed margins <input type="checkbox"/> High Risk Disease (i.e. consideration of adjuvant therapy) <input type="checkbox"/> Concern re regional / distant metastases <input type="checkbox"/> Other:	
--	--

4. Checklist (Documents / Details to be sent with referral):

Initial histology / biopsy
Mohs report and diagram (including details of location, defect size, presence of perineural invasion, margin clearance, depth of invasion, type of closure)
Photographs (before / during / after, if available)
Mohs Slides (To be sent if using standard / high risk disease / unusual histology)
Patient Medical History (including details of immunosuppression, previous radiotherapy)

ajd_12779_f3.jpg