



Minerva Access is the Institutional Repository of The University of Melbourne

Author/s:

Kuik, KTH;Trubiano, J;Worth, LJ;Harun, NS;Steinfort, D;Johnson, D

Title:

Pneumocystis jirovecii pneumonia following everolimus treatment of metastatic breast cancer

Date:

2014-01-01

Citation:

Kuik, K. T. H., Trubiano, J., Worth, L. J., Harun, N. S., Steinfort, D. & Johnson, D. (2014). Pneumocystis jirovecii pneumonia following everolimus treatment of metastatic breast cancer. Medical Mycology Case Reports, 6, pp.34-36. <https://doi.org/10.1016/j.mmcr.2014.08.007>.

Persistent Link:

<https://hdl.handle.net/11343/261351>

License:


[CC BY-NC-ND](#)



ELSEVIER

Contents lists available at ScienceDirect

Medical Mycology Case Reports

journal homepage: www.elsevier.com/locate/mmcr

Pneumocystis jirovecii pneumonia following everolimus treatment of metastatic breast cancer



Kelvin Teck-Hong Kuik^{a,*}, Jason Trubiano^b, Leon J. Worth^{b,c}, Nur-shirin Harun^a, Daniel Steinfort^a, Douglas Johnson^a

^a Department of General Medicine, Peter MacCallum Cancer Centre, East Melbourne, Australia

^b Department of Infectious Diseases, Peter MacCallum Cancer Centre, East Melbourne, Australia

^c Department of Medicine, University of Melbourne, Parkville, Australia

ARTICLE INFO

Article history:

Received 26 May 2014

Received in revised form

25 August 2014

Accepted 29 August 2014

Keywords:

PJP

Pneumocystis

Pneumonitis

Everolimus

Cancer

ABSTRACT

Everolimus is an inhibitor of mammalian target of rapamycin with anti-tumour activity. While everolimus is known to cause drug-induced pneumonitis, it is rarely associated with *Pneumocystis jirovecii* pneumonia (PJP). We report a patient on everolimus therapy for metastatic breast cancer that developed PJP. Diagnosis was based on clinical features and a quantitative polymerase chain reaction for *P. jirovecii* DNA. Clinicians should consider PJP as a potential cause of pulmonary infiltrates in patients treated with everolimus.

Crown Copyright © 2014 Published by Elsevier B.V. on behalf of International Society for Human and Animal Mycology This is an open access article under the CC BY-NC-ND license (<http://creativecommons.org/licenses/by-nc-nd/3.0/>).

1. Introduction

Pneumocystis jirovecii pneumonia (PJP) continues to emerge outside of the historical setting of HIV infection, especially with the development of new immunomodulating therapies [1,2]. Everolimus is a mammalian target of rapamycin inhibitor, and has an important role as an immunosuppressive agent in organ transplantation [3,4]. It also has anti-tumour effects and has been employed for treatment of a range of malignancies, including neuroendocrine, renal cell and breast carcinomas [5–7].

We present a case of PJP following everolimus treatment for metastatic breast cancer. Although drug-induced pneumonitis is a recognised complication of everolimus therapy [8], there are few reports of PJP associated with this agent [9,10] outside of solid organ transplantation.

2. Case

A 75-year-old female with metastatic breast cancer presented to a tertiary referral cancer centre with a two week history of fever, cough and progressive dyspnoea, one month after commencing everolimus. Eight years prior, she had an in-situ recurrence of her

breast cancer, with subsequent metastatic recurrences in the right groin and left axilla, each treated with radiotherapy. Disease had progressed through multiple hormonal treatments (anastrozole, tamoxifen, exemestane and medroxyprogesterone) before starting everolimus and exemestane combination therapy. She was a non-smoker with no previous history of chronic obstructive airways disease, and her regular medications included ramipril and simvastatin. Prior to presentation, she was not taking corticosteroid therapy or any agent for PJP prophylaxis.

On admission, she was febrile (39 °C), hypoxic (SpO₂ 84% on room air) and tachypnoeic. Initial chest X-ray demonstrated reticular shadowing of the left lung, and computed tomography (CT) revealed ground glass infiltration throughout the left lung (Fig. 1). She had an elevated CRP of 150 mg/L (reference range 0–10 mg/L), and a normal leucocyte count of 5.0 × 10⁹/L (reference range 4.0–11.0), with reduction in the lymphocyte subset (0.84 × 10⁹/L, reference range 1.00–4.00).

With a history of immunosuppression, fever and elevated CRP, an infectious cause of pneumonia was considered probable. Everolimus was ceased, and the patient was commenced on ceftriaxone (1 g daily) and azithromycin (500 mg daily) as empiric treatment for community acquired pneumonia. Trimethoprim-sulfamethoxazole was also commenced (1600 mg/320 mg orally four times a day) for the possibility of PJP. Prednisolone was administered concurrently (60 mg daily).

A bronchoalveolar lavage (BAL) was performed on the following day. Real-time polymerase chain reaction (PCR) of the BAL fluid

* Corresponding author. Tel.: +61 421 286 668.

E-mail address: kyoichisan@hotmail.com (K.-H. Kuik).

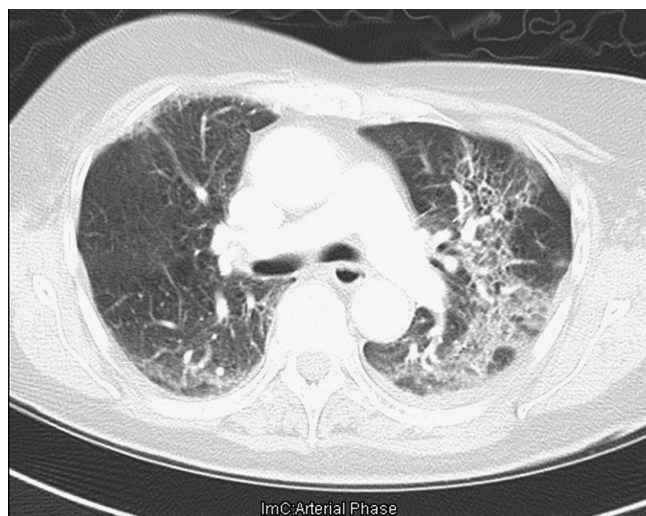


Fig. 1. CT of chest demonstrating extensive interstitial changes in the left lung.

was positive for *Pneumocystis* DNA, with a significant cycle-threshold (Ct) value of 32 (Ct value < 33 is significant for active infection). The diagnostic sample was tested with the Light Cycler (version 2.0; Roche Diagnostics, Mannheim, Germany), using a real-time touch-down PCR assay to target the *P. jirovecii* major surface glycoprotein (MSG) genes, performed as described by Larsen et al. [13]. No fungal elements were identified on toluidine blue staining. No bacterial pathogen was cultured, and PCR for respiratory viruses (influenza A virus, influenza B virus, parainfluenza viruses, respiratory syncytial virus, adenovirus, rhinoviruses and enteroviruses), and herpes viruses (herpes simplex virus types 1 and 2, cytomegalovirus, and varicella-zoster virus) was negative. No malignant cells were identified in the BAL.

Clinical and laboratory markers of illness severity (fever, dyspnoea and CRP) improved during the first week. Repeat chest X-ray demonstrated reduction in the reticular changes in the left lung. Trimethoprim-sulfamethoxazole was given for 21 days, and prednisolone was reduced in a step-wise manner over a month. A repeat chest CT at two months showed complete resolution of the interstitial infiltrate. Following the episode, the patient was not re-challenged with everolimus therapy, though exemestane was continued.

3. Discussion

This is the first report of PJP in a patient receiving everolimus therapy for metastatic breast cancer, where the diagnosis of PJP was confirmed by molecular investigation. The case highlights the difficulties in diagnosis of PJP in the setting of possible drug-induced pneumonitis.

A meta-analysis of five trials involving breast, neuroendocrine and renal cell carcinoma reported everolimus-induced pneumonitis in 10.4% of patients [8]. It is not clear if sensitive molecular tests for PJP were employed in all instances where pneumonitis has been identified. PJP complicating everolimus therapy in solid malignancies appears to be rare. To date, there have been two reported cases of PJP in these patient populations [9,10]. Both patients had metastatic renal cell carcinoma, and demonstrated clinical and radiological features of pneumonitis. In both instances, elevated serum β -D-glucan (a cell wall component of most fungi) was interpreted as evidence for *Pneumocystis* infection [11], although the diagnostic approach is less specific than molecular diagnostic techniques [12]. There have been no reports of PJP in everolimus therapy in the setting of organ transplantation. We

postulate that in such cases, everolimus is often combined with other immunosuppressants more conventionally associated with PJP, where it would be difficult and clinically irrelevant to attribute a PJP specifically to everolimus.

In our case, the clinical features and positive PCR for *P. jirovecii* were suggestive of an infective process. *Pneumocystis* PCR sensitivity is in the range of 80–100% using real-time PCR assays, with higher specificity than standard PCR [2]. The cycle threshold (Ct) value from real-time PCR, as performed in our centre, allows for further differentiation of active infection from colonisation [2,13,14]. Expressed as the number of DNA amplification cycles needed to achieve the required fluorescence, the Ct value is an inverse representation of alveolar fungal burden [15]. Recent evidence suggests that the clinical dilemma of *Pneumocystis* colonisation versus infection can be clarified by knowledge of quantitative PCR results, but there is currently no consensus cut-off value for the Ct value for the purposes of confirming infection [2,11,14,16]. Nonetheless, we report a value of less than 33 cycles as a significant positive result for active infection (the threshold where cysts can still be seen under direct microscopy in a positive reference case).

The association between everolimus and PJP in this case is further strengthened by the absence of other contributing risks for PJP, such as longstanding or high-dose corticosteroid therapy, or clustering of cases within our healthcare facility. Furthermore, we believe that the unilateral distribution of the interstitial changes and the presence of high grade fever were more suggestive of an infective process than a drug-induced pneumonitis.

Host immune response to PJP relies on the range of cells that include CD4+ T cells, CD8+ T cells, alveolar macrophages, dendritic cells and neutrophils, with CD4+ T cells playing a critical role in recruitment and activation of effector B cells to eliminate the organism [17]. Everolimus inhibits proliferation of both B- and T-cells [18], and this may be a mechanism by which predisposition to PJP is incurred. The effect of cumulative dosing over time and subsequent risks for developing PJP require further evaluation.

Our patient continued with exemestane hormone therapy for her metastatic breast cancer. To date, there are no case reports that describe a link between exemestane and pneumonitis or PJP.

The incidence of PJP in patients treated with everolimus is not known, therefore the need for PJP prophylaxis in patients on everolimus outside of solid organ transplantation has not been determined. What is clear is that unrecognised PJP can lead to deterioration in a patient's condition [10], especially if the patient is further immunocompromised with other agents that increase vulnerability to PJP (e.g. corticosteroid therapy when drug-induced pneumonitis is suspected). Clinicians should consider the possibility of PJP in patients with an undifferentiated pulmonary infiltrate who are receiving everolimus therapy. Early recognition of PJP (through BAL and quantitative PJP PCR) or empiric PJP therapy while awaiting diagnostic evaluation is justified in these populations.

Conflict of interest statement

There are none.

Acknowledgements

There are none.

References

- [1] Sepkowitz KA, Brown AE, Armstrong D. *Pneumocystis carinii* pneumonia without acquired immunodeficiency syndrome. More patients, same risk. Arch Intern Med 1995;155:1125–8.

- [2] Reid AB, Chen SC, Worth LJ. *Pneumocystis jirovecii* pneumonia in non-HIV-infected patients: new risks and diagnostic tools. *Curr Opin Infect Dis* 2011;24:534–44.
- [3] Hirt SW, Bara C, Barten MJ, Deuse T, Doesch AO, Kaczmarek I, et al. Everolimus in heart transplantation: an update. *J Transplant* 2013;2013:683964.
- [4] Ponticelli C. The pros and the cons of mTOR inhibitors in kidney transplantation. *Expert Rev Clin Immunol* 2014;10:295–305.
- [5] Kunz PL, Reidy-Lagunes D, Anthony LB, Bertino EM, Brendtro K, Chan JA, et al. Consensus guidelines for the management and treatment of neuroendocrine tumors. North American Neuroendocrine Tumor Society. *Pancreas* 2013;42:557–77.
- [6] Amato R, Stepankiw M. Evaluation of everolimus in renal cell cancer. *Expert Opin Pharmacother* 2013;14:1229–40.
- [7] Martin LA, André F, Campone M, Bachelot T, Jerusalem G. mTOR inhibitors in advanced breast cancer: ready for prime time? *Cancer Treat Rev* 2013;39:742–52.
- [8] Iacovelli R, Palazzo A, Mezi S, Morano F, Naso G, Cortesi E. Incidence and risk of pulmonary toxicity in patients treated with mTOR inhibitors for malignancy. A meta-analysis of published trials. *Acta Oncol* 2012;51:873–9.
- [9] Saito Y, Nagayama M, Miura Y, Ogushi S, Suzuki Y, Noro R, et al. A case of *Pneumocystis* pneumonia associated with everolimus therapy for renal cell carcinoma. *Jpn J Clin Oncol* 2013;43:559–62.
- [10] Toshio Suzuki, Yuji Tada, Tsushima Kenji, Terada Jiro, Sakurai Takayuki, Akira Watanabe et al. *Pneumocystis* pneumonia in everolimus therapy: an indistinguishable case from drug induced interstitial lung disease. *Respir Med Case Rep* 2013;10:27–30.
- [11] Damiani C, Le Gal S, Da Costa C, Virmaux M, Nevez G, Totet A. Combined quantification of pulmonary *Pneumocystis jirovecii* DNA and serum (1- \rightarrow 3)- β -D-glucan for differential diagnosis of *Pneumocystis* pneumonia and *Pneumocystis* colonization. *J Clin Microbiol* 2013;51:3380–8.
- [12] Carmona EM, Limper AH. Update on the diagnosis and treatment of *Pneumocystis* pneumonia. *Ther Adv Respir Dis* 2011;5:41–59.
- [13] Larsen HH, Masur H, Kovacs JA, Gill VJ, Silcott VA, Kogulan P, et al. Development and evaluation of a quantitative, touch-down, real-time PCR assay for diagnosing *Pneumocystis carinii* pneumonia. *J Clin Microbiol* 2002;40:490–4.
- [14] Teh BW, Azzato FA, Lingaratnam SM, Thursky KA, Slavin MA, Worth LJ. Molecular diagnosis of *Pneumocystis jirovecii* in patients with malignancy: Clinical significance of quantitative polymerase chain reaction. *Med Mycol* 2014;52:427–32.
- [15] Fillaux J, Malvy S, Alvarez M, Fabre R, Cassaing S, Marchou B, et al. Accuracy of a routine real-time PCR assay for the diagnosis of *Pneumocystis jirovecii* pneumonia. *J Microbiol Methods* 2008;75:258–61.
- [16] Maillet M, Maubon D, Brion JP, François P, Molina L, Stahl JP, et al. *Pneumocystis jirovecii* (Pj) quantitative PCR to differentiate Pj pneumonia from Pj colonization in immunocompromised patients. *Eur J Clin Microbiol Infect Dis* 2014;33:331–6.
- [17] Kelly MN, Shellito JE. Current understanding of *Pneumocystis* immunology. *Future Microbiol* 2010;5:43–65.
- [18] Thomson AW, Turnquist HR, Raimondi G. Immunoregulatory functions of mTOR inhibition. *Nat Rev Immunol* 2009;9:324–37.