



Minerva Access is the Institutional Repository of The University of Melbourne

Author/s:

Nevgi, A;Klein, O;Cheung, AS

Title:

Sustained remission of Lynch syndrome-associated metastatic adrenocortical carcinoma following checkpoint inhibitor therapy-associated multiorgan autoimmunity

Date:

2020-08-01

Citation:

Nevgi, A., Klein, O. & Cheung, A. S. (2020). Sustained remission of Lynch syndrome-associated metastatic adrenocortical carcinoma following checkpoint inhibitor therapy-associated multiorgan autoimmunity. *Clinical Endocrinology*, 93 (2), pp.214-216. <https://doi.org/10.1111/cen.14258>.

Persistent Link:

<https://hdl.handle.net/11343/275884>

DR ADA S CHEUNG (Orcid ID : 0000-0001-5257-5525)

Article type : Case Report

Corresponding author mail id:- [adac@unimelb.edu.au](mailto:adac@unimelb.edu.au)

**Sustained remission of Lynch syndrome-associated metastatic adrenocortical carcinoma following checkpoint inhibitor therapy-associated multiorgan autoimmunity.**

Aditi Nevgi<sup>1,2</sup>, Oliver Klein<sup>3,4</sup>, and Ada S. Cheung<sup>1,5</sup>

<sup>1</sup> Department of Endocrinology, Austin Health, Heidelberg, Australia

<sup>2</sup> Endocrinology Unit, Monash Health, Clayton, Australia

<sup>3</sup> Olivia Newton – John Cancer Centre, Austin Health, Heidelberg, Australia

<sup>4</sup> Olivia Newton-John Cancer Research Institute, Heidelberg, Australia

<sup>5</sup> Department of Medicine (Austin Health), The University of Melbourne, Heidelberg, Australia

Words 993

Adrenocortical carcinoma (ACC) is a rare and aggressive tumour with limited treatment options for metastatic disease<sup>1</sup>. Immunotherapy with checkpoint inhibition, in particular anti-programmed death receptor 1 (PD-1)/programmed death-ligand-1 (PD-L1) blockade has transformed the management of several malignancies. We describe prolonged remission of an ectopic-ACTH secreting refractory stage-IV ACC treated with anti-PD-1 antibody nivolumab

**This is the author manuscript accepted for publication and has undergone full peer review but has not been through the copyediting, typesetting, pagination and proofreading process, which may lead to differences between this version and the [Version of Record](#). Please cite this article as [doi: 10.1111/CEN.14258](https://doi.org/10.1111/CEN.14258)**

This article is protected by copyright. All rights reserved

combined with anti-cytotoxic T-lymphocyte-associated protein 4 (CTLA-4) antibody ipilimumab.

A 38-year-old presented in January 2017 with acute chest pain and dyspnoea on a background of 2 months of worsening left-sided flank and epigastric pain. He was previously well with stable depression and a known microprolactinoma controlled on low-dose cabergoline. Abdominal CT scan revealed a 17cm heterogenous left-sided adrenal mass with renal vein and inferior vena cava (IVC) thrombus extending to the right atrium and large bilateral pulmonary emboli. Urine cortisol excretion (24 hours) was elevated at 793 nmol/day (reference range 100–379), and 2 separate 1mg dexamethasone suppression tests did not completely suppress (cortisol 68 nmol/L and 91 nmol/L). ACTH was 5.0 ng/L (7.2–63.3) consistent with ACTH-independent Cushing's syndrome. Plasma metanephrines and aldosterone:renin ratio were normal. Despite the biochemical cortisol excess, the patient had no symptoms or signs of Cushing's syndrome.

A 2.1kg adrenal tumour was excised in a radical left-sided adrenalectomy, nephrectomy and IVC thrombectomy. Histology confirmed an ACC with an extremely high mitotic rate of >50/50hpf. Post-operatively, early-morning cortisol concentration was 25 nmol/L, with ACTH 5.2 ng/L (7.2–63.3) and he was commenced on hydrocortisone and anticoagulation.

Imaging one month later revealed lung and liver metastases. Chemotherapy with cisplatin and etoposide was tolerated poorly with febrile neutropenia, severe nausea, fatigue, and peripheral neuropathy. Subsequent treatment with mitotane was commenced. Monitoring over eight months on mitotane found a slow rise in early-morning cortisol concentrations (performed withholding morning hydrocortisone dose) from 25 to 468 nmol/L with associated rising ACTH to 214 ng/L (7.2 – 63.3). Hydrocortisone was ceased. Restaging scans demonstrated new metastases in his right adrenal gland and increase in liver and lung metastases. Pituitary hormones performed to investigate severe fatigue were normal including prolactin, thyroid function and total testosterone (25.4 nmol/L (12.0 – 30.0)).

The patient was enrolled ten months after his initial presentation into a clinical trial using combination immunotherapy with nivolumab and ipilimumab. After two treatment doses, he was hospitalised with severe fatigue, hypotension and generalised pain. Investigations revealed a highly elevated serum ALT and AST in keeping with immunotherapy-associated

hepatitis, immune-mediated adrenalitis with low serum cortisol leading to hyponatremia and hyperkalemia, and hyperthyroidism due to thyroiditis. ACTH was 6.0 ng/L. In view of the high-grade immune related adverse events (irAEs), immunotherapy was ceased. After a four-week course of prednisolone, hepatitis resolved, and he became euthyroid. Adrenal insufficiency was managed adequately on hydrocortisone and fludrocortisone. However, the patient had persistent fatigue, low libido and severe generalised pain (predominantly abdominal) requiring large doses of oxycodone up to 100mg daily as analgesia. Fasting total testosterone was 2.3 nmol/L (12.0 – 30.0) and elevated FSH 58.3 IU/L (1.5-9.7) and LH 70.1 IU/L (1.8 – 9.2) were consistent with new primary hypogonadism presumed to be immunotherapy-related orchitis. He had no testicular pain or swelling, though his generalised abdominal pain and high-dose opioids may have masked his symptoms. Treatment with intramuscular testosterone undecanoate led to good improvements in his energy levels and libido.

Family history revealed that his father had bowel and bladder cancer, and his paternal grandfather had died from an unknown cancer. Genetic studies confirmed a MSH2 germline mutation, consistent with Lynch Syndrome. Immunohistochemistry revealed loss of expression of MSH2 and MSH6 in his tumour.

Despite cessation of immunotherapy, ongoing regression of the patient's metastatic disease has been observed, persisting two years after his last treatment dose (Figure). He has excellent performance status having returned to work, and continues on therapeutic replacement doses of hydrocortisone, fludrocortisone and testosterone undecanoate.

ACC is a rare cancer with an annual incidence of 1 per million<sup>1</sup>. Ectopic-ACTH production from metastatic ACC has not been previously reported in the English literature with only one Spanish report<sup>2</sup>. Our patient's ACC developed on the background of Lynch Syndrome, typically characterised by an increased risk for colorectal and endometrial cancer. Fewer than 20 cases of ACC have been reported as part of Lynch Syndrome—generally associated with germline pathogenic variants in DNA mismatch repair genes MSH2 or MSH6<sup>1</sup>. MSH2 mutations occur in ~40% of all cases of Lynch syndrome and in our patient, was likely paternal in origin. Detection has subsequently informed screening needs for his immediate family. Notably, ACC can be associated with other familial cancer syndromes such as Li-Fraumeni syndrome and multiple endocrine neoplasia.

Our patient was enrolled into a clinical trial using ipilimumab and nivolumab combination treatment in patients with rare cancers. His dramatic and prolonged tumour response to immunotherapy is best explained by the mismatch repair protein (MMRP) deficient state of his tumour causing an increase of mutation-associated neoantigens, triggering more immune cells to infiltrate into the tumour and a greater anti-tumour response to checkpoint blockade therapy<sup>3</sup>. A high response rate of MMRP deficient tumours to PD-1 inhibition is well documented<sup>3</sup>. Our patient developed severe multiorgan autoimmunity in keeping with a break of immune tolerance that likely facilitated an effective anti-tumour immune response. There is currently conflicting evidence whether the development of irAEs under checkpoint inhibitor therapy is associated with treatment response<sup>4</sup>.

Whilst common endocrinopathies such as autoimmune thyroid disease, diabetes and hypophysitis are well documented, orchitis is rare and only reported in 2 previous cases who both experienced scrotal pain after checkpoint inhibition for melanoma<sup>5</sup>. The acute onset of primary hypogonadism in our patient with previously normal testosterone concentrations was consistent with immunotherapy-related autoimmune orchitis.

Overall this case illustrates that patients with ACC should be considered for genetic testing, in particular patients with a strong family history. In addition, our case adds to the evidence that immunotherapy with checkpoint inhibitors can lead to durable response in patients with metastatic ACC, a patient population that is in urgent need of therapies that can provide prolonged clinical benefits.

#### DATA AVAILABILITY STATEMENT

Data sharing is not applicable to this article as no new data were created or analyzed in this study.

#### FUNDING STATEMENT

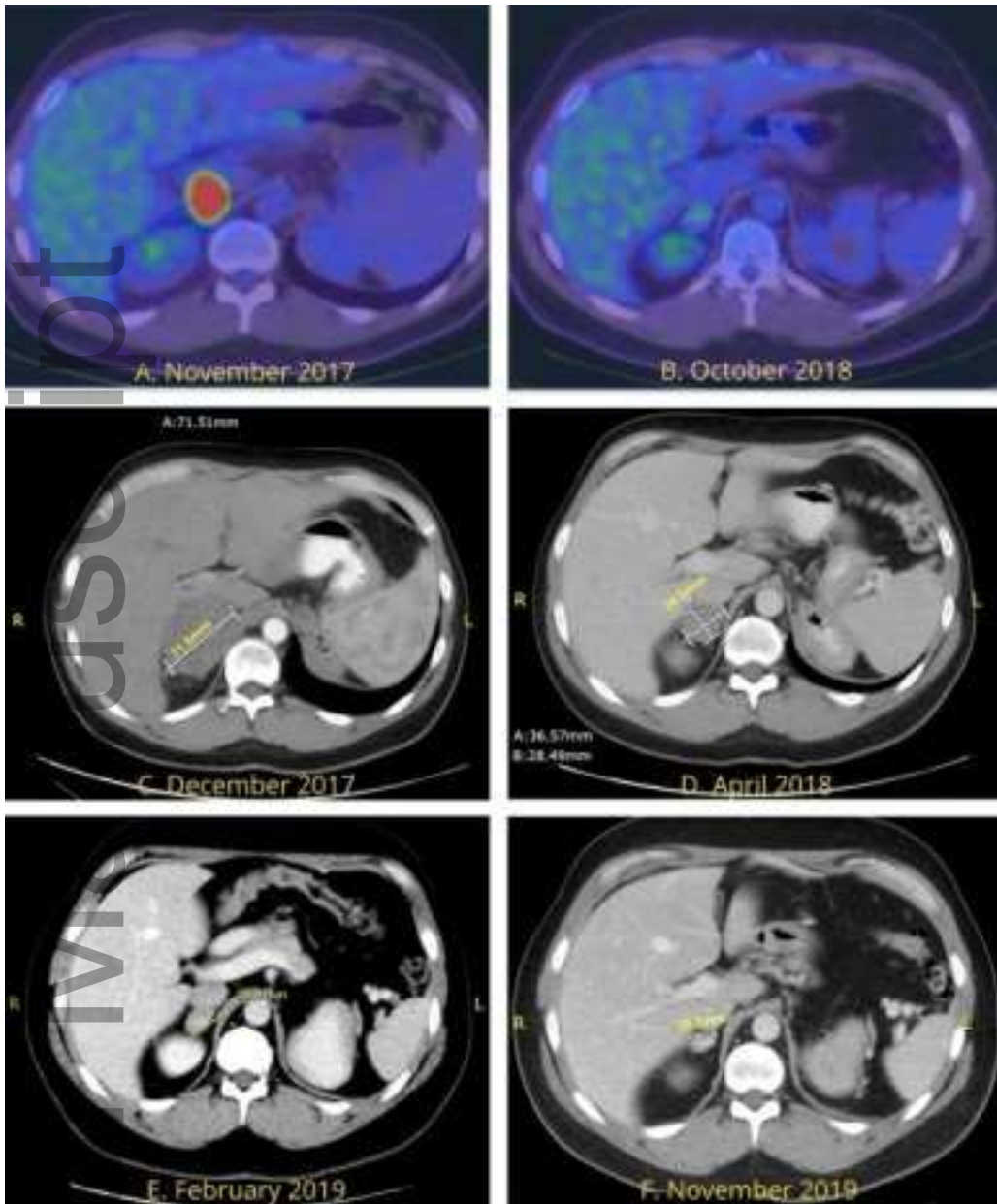
ASC is supported by a National Health and Medical Research Council of Australia Early Career Fellowship #1143333

## DECLARATION OF INTERESTS

We declare no conflicts of interest.

## REFERENCES

1. Kaur RJ, Pichurin PN, Hines JM, Singh RJ, Grebe SK, Bancos I. Adrenal Cortical Carcinoma Associated With Lynch Syndrome: A Case Report and Review of Literature. *J Endocr Soc* 2019; **3**(4): 784-90.
2. Pallardo LF, Sanchez Franco F, Fernandez Marino A, et al. [Adrenal carcinoma producing ectopic ACTH]. *Revista Clínica Española* 1981; **162**(5): 189-92.
3. Raj N, Zheng Y, Kelly V, et al. PD-1 Blockade in Advanced Adrenocortical Carcinoma. *J Clin Oncol* 2020; **38**(1): 71-80.
4. Ellithi M, Elnair R, Chang GV, Abdallah MA. Toxicities of Immune Checkpoint Inhibitors: Itis-Ending Adverse Reactions and More. *Cureus* 2020; **12**(2): e6935.
5. Quach HT, Robbins CJ, Balko JM, et al. Severe Epididymo-Orchitis and Encephalitis Complicating Anti-PD-1 Therapy. *Oncologist* 2019; **24**(7): 872-6.



cen\_14258\_f1.jpg