



Minerva Access is the Institutional Repository of The University of Melbourne

Author/s:

Ye, Z;Lin, S;Zhao, X;Bennett, MF;Brown, NJ;Wallis, M;Gao, X;Sun, L;Wu, J;Vedururu, R;Witkowski, T;Gardiner, F;Stutterd, C;Duan, J;Mullen, SA;McGillivray, G;Bodek, S;Valente, G;Reagan, M;Yao, Y;Li, L;Chen, L;Boys, A;Adikari, TN;Cao, D;Hu, Z;Beshay, V;Zhang, VW;Berkovic, SF;Scheffer, IE;Liao, J;Hildebrand, MS

Title:

Mosaicism in tuberous sclerosis complex: Lowering the threshold for clinical reporting

Date:

2022-12-01

Citation:

Ye, Z., Lin, S., Zhao, X., Bennett, M. F., Brown, N. J., Wallis, M., Gao, X., Sun, L., Wu, J., Vedururu, R., Witkowski, T., Gardiner, F., Stutterd, C., Duan, J., Mullen, S. A., McGillivray, G., Bodek, S., Valente, G., Reagan, M. ,... Hildebrand, M. S. (2022). Mosaicism in tuberous sclerosis complex: Lowering the threshold for clinical reporting. *Human Mutation*, 43 (12), pp.1956-1969. <https://doi.org/10.1002/humu.24454>.

Persistent Link:

<https://hdl.handle.net/11343/316384>

License:

CC BY-NC-ND

# Mosaicism in tuberous sclerosis complex: Lowering the threshold for clinical reporting

Zimeng Ye<sup>1</sup>  | Sufang Lin<sup>2</sup> | Xia Zhao<sup>2</sup> | Mark F. Bennett<sup>1,3,4</sup> |  
Natasha J. Brown<sup>5,6,7</sup> | Mathew Wallis<sup>8,9,10,11</sup> | Xinyi Gao<sup>12</sup> | Li Sun<sup>12</sup> |  
Jiarui Wu<sup>12</sup> | Ravikiran Vedururu<sup>13</sup> | Tom Witkowski<sup>1</sup> | Fiona Gardiner<sup>1</sup> |  
Chloe Stutterd<sup>7,8</sup> | Jing Duan<sup>2</sup> | Saul A. Mullen<sup>1,8</sup> | George McGillivray<sup>7</sup> |  
Simon Bodek<sup>8</sup> | Giulia Valente<sup>8</sup> | Matthew Reagan<sup>14</sup> | Yi Yao<sup>2</sup> | Lin Li<sup>2</sup> |  
Li Chen<sup>2</sup> | Amber Boys<sup>5</sup> | Thiuni N. Adikari<sup>1,10</sup> | Dezhi Cao<sup>2</sup> | Zhanqi Hu<sup>2</sup> |  
Victoria Beshay<sup>13</sup> | Victor W. Zhang<sup>12</sup> | Samuel F. Berkovic<sup>1,8</sup> |  
Ingrid E. Scheffer<sup>1,5,6,8,15</sup> | Jianxiang Liao<sup>2</sup> | Michael S. Hildebrand<sup>1,5,8</sup>

<sup>1</sup>Epilepsy Research Centre, Department of Medicine, The University of Melbourne, Heidelberg, Victoria, Australia

<sup>2</sup>Department of Neurology, Epilepsy Centre, Shenzhen Children's Hospital, Shenzhen, Guangdong Province, China

<sup>3</sup>Population Health and Immunity Division, The Walter and Eliza Hall Institute of Medical Research, Parkville, Victoria, Australia

<sup>4</sup>Department of Medical Biology, The University of Melbourne, Parkville, Victoria, Australia

<sup>5</sup>Murdoch Children's Research Institute, Royal Children's Hospital, Parkville, Victoria, Australia

<sup>6</sup>Department of Paediatrics, Royal Children's Hospital, The University of Melbourne, Parkville, Victoria, Australia

<sup>7</sup>Victorian Clinical Genetics Services, Royal Children's Hospital, Parkville, Victoria, Australia

<sup>8</sup>Austin Health, Heidelberg, Victoria, Australia

<sup>9</sup>Tasmania Clinical Genetics Service, Royal Hobart Hospital, Tasmania, Australia

<sup>10</sup>School of Medicine, University of Tasmania, Tasmania, Australia

<sup>11</sup>Menzies Institute for Medical Research, University of Tasmania, Tasmania, Australia

<sup>12</sup>AmCare Genomics Laboratory, Guangzhou, Guangdong Province, China

<sup>13</sup>Molecular Diagnostic Pathology, Peter MacCallum Cancer Centre, Melbourne, Victoria, Australia

<sup>14</sup>Department of Medicine, Peninsula Health, Monash University, Frankston, Victoria, Australia

<sup>15</sup>The Florey Institute, Parkville, Victoria, Australia

## Correspondence

Michael S. Hildebrand and Ingrid E. Scheffer,  
Epilepsy Research Centre, Department of  
Medicine, University of Melbourne, 245  
Burgundy St. Heidelberg, Victoria 3084,  
Australia.  
Email: [michael.hildebrand@unimelb.edu.au](mailto:michael.hildebrand@unimelb.edu.au) and  
[i.scheffer@unimelb.edu.au](mailto:i.scheffer@unimelb.edu.au)

## Abstract

Tuberous sclerosis complex (TSC) is a multi-system genetic disorder. Most patients have germline mutations in *TSC1* or *TSC2* but, 10%–15% patients do not have *TSC1/TSC2* mutations detected on routine clinical genetic testing. We investigated the contribution of low-level mosaic *TSC1/TSC2* mutations in unsolved sporadic patients and families with TSC. Thirty-one sporadic TSC patients negative on

Zimeng Ye, Sufang Lin, and Xia Zhao contributed equally to this study.

This is an open access article under the terms of the Creative Commons Attribution-NonCommercial-NoDerivs License, which permits use and distribution in any medium, provided the original work is properly cited, the use is non-commercial and no modifications or adaptations are made.

© 2022 The Authors. *Human Mutation* published by Wiley Periodicals LLC.

Jianxiang Liao, Epilepsy Centre, Department of Neurology, Shenzhen Children's Hospital, 7019 Yitian Rd., Futian District, Shenzhen, Guangdong Province 518038, China.  
Email: [liaojianxiang@vip.sina.com](mailto:liaojianxiang@vip.sina.com)

#### Funding information

CURE Epilepsy; Australia National Health and Medical Research Council; Victorian State Government Operational Infrastructure Support; Epilepsy Foundation of Victoria; Sanming Project of Medicine in Shenzhen

routine testing and eight families with suspected parental mosaicism were sequenced using deep panel sequencing followed by droplet digital polymerase chain reaction. Pathogenic variants were found in 22/31 (71%) unsolved sporadic patients, 16 were mosaic (median variant allele fraction [VAF] 6.8% in blood) and 6 had missed germline mutations. Parental mosaicism was detected in 5/8 families (median VAF 1% in blood). Clinical testing laboratories typically only report pathogenic variants with allele fractions above 10%. Our findings highlight the critical need to change laboratory practice by implementing higher sensitivity assays to improve diagnostic yield, inform patient management and guide reproductive counseling.

#### KEYWORDS

high-depth sequencing, mosaic mutations, parental mosaicism, tuberous sclerosis complex

## 1 | INTRODUCTION

Tuberous Sclerosis Complex (TSC) is a multisystem genetic disorder characterized by benign hamartomas in multiple organs including brain, skin, kidney, heart, eye, and lung. The estimated prevalence is 1 in 6,000 to 1 in 10,000 live births (Northrup et al., 2013). Frequent neuropsychiatric features of TSC include epilepsy, intellectual disability, and autism spectrum disorder (Curatolo, Moavero, de Vries, 2015). Clinical manifestations and severity vary widely among individuals, and within families (Caban et al., 2017; Northrup et al., 2013). Overall, 85%–90% of patients have identified heterozygous germline pathogenic variants in *TSC1* or *TSC2* (Tyburczy et al., 2015). *TSC1* and *TSC2* encode negative regulators of the mammalian target of rapamycin (mTOR) pathway. Loss-of-function variants in *TSC1* and *TSC2* lead to mTOR pathway hyperactivation and abnormal cell growth, neuronal connectivity, and excitability (Baybis et al., 2004; Curatolo et al., 2018; Hodges et al., 2001; Tavazoie et al., 2005).

TSC is an autosomal dominant disorder with high penetrance (Frost & Hulbert, 2015; Mayer et al., 2014). In about one-third of patients, TSC is familial, following autosomal dominant inheritance, with the remaining patients being sporadic due to de novo pathogenic variants (Rose et al., 1999; Sampson et al., 1989). In sporadic patients, germline *TSC2* variants are much more common than germline *TSC1* variants (Au et al., 2007; Kingswood et al., 2017; Martin et al., 2017), while for familial cases, the proportion of *TSC1* and *TSC2* germline variants is almost equal (Au et al., 2004; Au et al., 2007; Jones et al., 1999). Patients with *TSC2* germline variants tend to have more severe phenotypes compared to those with germline *TSC1* variants, characterized by higher number of tubers, earlier age at seizure onset, and higher prevalence of intellectual disability, affecting their reproductive fitness (Au et al., 2007; Curatolo, Moavero, Roberto, et al., 2015; Dabora et al., 2001; Giannikou et al., 2019; Ogórek et al., 2020).

While most patients have germline pathogenic variants detected, 10%–15% patients have “no mutation identified” (NMI) on clinical genetic testing (Giannikou et al., 2019; Qin et al., 2010; Tyburczy et al., 2015). Some NMI patients have germline pathogenic variants missed on initial testing due to technical issues whereas, in others, mosaic pathogenic variants may be present at allele fractions below the level of detection of standard depth sequencing (Tyburczy et al., 2015). Mosaic variants are DNA changes that occur postzygotically (after fertilization). These variants may arise at any time a cell divides during development, and are therefore found in only a fraction of the cells of an individual (Ye et al., 2019). Variant allele fraction (VAF) of mosaic variants often varies significantly in different organs of an individual, depending on the timing of the mutational event and the embryonic lineage in which it occurs (Giannikou et al., 2019; Treichel et al., 2019; Tyburczy et al., 2015; Vadlamudi et al., 2010). Patients with TSC due to a mosaic pathogenic variant usually have milder phenotypes compared to patients with germline variants (Giannikou et al., 2019; Ogórek et al., 2020; Treichel et al., 2019; Tyburczy et al., 2015; Verhoef et al., 1999).

Mosaicism in parents is a critical issue with serious reproductive counseling consequences. Patients thought to have “de novo” pathogenic variants based on routine genetic testing of parental blood-derived DNA, may have a mosaic parent who has no or subtle clinical features of TSC. Once a family with a mildly affected or unaffected parent has more than one affected child, parental mosaicism is highly likely. Conventional testing often misses low-level mosaicism due to technological limitations.

Here, we performed a detailed study of mosaicism in TSC with the following aims: (1) To study 31 mutation-negative sporadic patients to identify missed pathogenic variants. (2) To test the VAF in different tissues from mosaic patients and compare the clinical features between mosaic patients and 213 patients with germline pathogenic variants. (3) To study eight families with likely *TSC1*/*TSC2* parental mosaicism and compare the phenotypes in mosaic parents with their affected children.

## 2 | METHODS

### 2.1 | Editorial policies and ethical considerations

The Human Research Ethics Committee of Austin Health (Project No. H2007/02961) and the Research Ethics Committee of Shenzhen Children's Hospital approved this study. This study adhered to the Declaration of Helsinki. Written informed consent was obtained from all participants or their parents or legal guardians in the case of minors or those with intellectual disability. All patients' clinical and genetic data were deidentified.

### 2.2 | Participants and phenotyping

#### 2.2.1 | Sporadic TSC patients

Thirty-one sporadic patients with a definite clinical diagnosis of TSC who had NMI on clinical genetic testing were recruited, including 8 adults and 23 children. TSC was diagnosed according to the updated international TSC diagnostic criteria (Northrup et al., 2021).

The adult patients were recruited between July 30, 2018 and February 20, 2020 through the Undiagnosed Diseases Program of Austin Health, Melbourne, Australia. The pediatric patients were recruited from a large TSC study of 425 patients between July 18, 2013 and January 17, 2020, at the Shenzhen Children's Hospital, Shenzhen, China. In this cohort, 216/242 (89%) patients had a known germline *TSC1* or *TSC2* pathogenic variant, and 26/242 (11%) had NMI on clinical testing; 23 of these NMI patients were available to be included in this study. Detailed clinical examination findings and investigation results for all TSC features of these patients are summarized in Table 1. Different tissues including blood, saliva, buccal cells, urine, brain and skin were collected, where possible. The clinical features of the pediatric mosaic sporadic patients were compared with the Chinese pediatric patients with germline pathogenic variants.

#### 2.2.2 | Families with suspected parental mosaicism

To explore parental mosaicism, 35 members from 8 families were recruited from Shenzhen Children's Hospital based on meeting one of two criteria for suspected mosaicism: (i) multiple siblings with TSC sharing the same germline variant; or (ii) only one affected child with one parent negative on gene testing having clinical features of TSC. The eight probands were drawn from the 216 patients with known germline *TSC1* or *TSC2* pathogenic variants, and all of their parents had tested negative for the relevant pathogenic variant on Sanger sequencing. Five families were selected because there were multiple siblings with TSC sharing the same germline variants. None of the parents were diagnosed with TSC before molecular testing. The remaining three families were selected, because, although there was only one affected child, one parent in each family had clinical features

of TSC but was negative for the testing of their child's pathogenic variant. Two parents from these three families had been diagnosed with mild TSC before this study, whereas, one was diagnosed clinically through this study. Because germline mutations were not detected in the parents within these eight families via Sanger sequencing, it was possible they carried low-level mosaic variants below the limit of detection. Different tissues, including blood, saliva, buccal cells, and urine, were collected from all parents recruited, and semen samples were collected from three fathers.

### 2.3 | DNA and RNA extraction

For Melbourne participants, genomic DNA was extracted using the Qiagen QIAamp DNA Maxi Kit for blood, DNA GenotekPrepIT-L2P Kit for saliva, Isohelix BuccalPrep Plus DNA Isolation Kit for buccal cells, Qiagen DNA Micro Kit for urine, and Qiagen AllPrep DNA/RNA Kit for skin biopsy samples. RNA was extracted from whole blood collected in the BD PAXgene® Blood RNA Tube using Qiagen PAXgene Blood RNA Kit.

For Shenzhen participants, genomic DNA was extracted using the Magen MagPure Tissue&Blood DNA LQ Kit for blood, GENFINE FineQuick Saliva DNA Kit for saliva, GENFINE FineMag Swab DNA Kit for buccal cells, Qiagen DNA Micro Kit for urine, Magen SolPure Tissue DNA Kit for brain, Qiagen AllPrep DNA/RNA Kit for skin biopsy samples, and Magen HiPure Universal DNA Kit for semen. RNA was extracted from whole blood collected in the BD PAXgene® Blood RNA Tube using Magen HiPure Total RNA Plus Mini Kit.

### 2.4 | Deep massively parallel sequencing

The Melbourne sporadic patients were tested with a gene panel at Peter MacCallum Cancer Center, Melbourne. Sequencing was performed on DNA extracted from blood ( $n = 7$ ) or facial angiofibroma biopsy ( $n = 1$ ). Libraries were prepared and enriched using SureSelect XT target enrichment (Agilent Design ID 0825941). The hybrid capture bait set covered all coding regions, splice sites, and 20bp up- and downstream of all exons of *TSC1* and *TSC2*. Indexed libraries were pooled and sequenced to a targeted coverage of ~1000 reads/base (Illumina NextSeq. 500,  $\times 2$  75 bp), achieving a mean coverage of 687-fold across the coding regions of *TSC1* and *TSC2*. Reads were aligned to the hg19 reference genome with BWA-MEM v0.7.17-r1188, then duplicate marking and base quality score recalibration were performed with the Genome Analysis Toolkit (GATK) version 3.7.0 (McKenna et al., 2010). Germline variant calling was performed with GATK HaplotypeCaller, and mosaic variant calling with GATK Mutect2. Variants were filtered using the following criteria: mutant reads  $\geq 10$ , and variant frequency  $\geq 2\%$ . Variants were annotated using vcfanno (Pedersen et al., 2016) and ANNOTATE VARIATION (Wang et al., 2010).

The sporadic patients from Shenzhen were tested using a Tuberous Sclerosis 2-gene (*TSC1/TSC2*) gene panel using

TABLE 1 Phenotype of the 31 sporadic patients

Patient	Age (year)	Sex	Major features											Neuropsychiatric features						
			Skin			Ungual		Eye		Brain		Heart		Lungs		Kidney and liver				
			AF ( $\geq 3$ ) or forehead plaque	Hypomelanotic macules ( $\geq 3$ )	Hypomelanotic macules ( $\geq 3$ )	Fibromas ( $\geq 2$ )	Shagreen patch	Multiple Retinal Hamartomas	Cortical dysplasia (no.) <sup>a</sup>	SEN	SEGA	Cardiac rhabdomyoma	LAM	AML ( $\geq 2$ )	Minor features	Seizures	ASD	ID		
CHN-1	10	F	-	+	-	-	-	-	+	(2)	-	-	-	-	-	-	-	+	-	Moderate
CHN-2	11	F	-	+	-	-	-	-	+	(8)	+	-	+	-	-	-	-	+	-	Moderate
CHN-3	6	M	-	+	-	-	-	-	+	(16)	+	+	+	-	-	-	-	+	-	-
CHN-4	21	F	+	+	-	-	-	-	+	(2)	+	-	+	+	-	-	-	-	-	-
CHN-5	5	M	+	+	-	-	-	-	+	(3)	+	-	-	-	-	-	-	+	-	-
CHN-6	13	M	+	-	-	-	-	-	+	(8)	+	-	-	+	-	-	-	-	-	-
CHN-7	10	M	-	+	-	-	-	+	+	(16)	+	-	-	-	-	-	-	+	-	Borderline
CHN-8	13	F	+	+	-	-	-	+	+	(7)	+	-	+	+	-	-	-	-	-	-
CHN-9	16	M	-	-	-	-	-	+	+	(4)	-	-	+	+	-	-	-	+	+	Severe
CHN-10	7	F	+	+	-	-	-	-	+	(5)	+	-	+	+	-	-	-	+	-	-
CHN-11	8	F	-	+	-	-	-	-	-	(15)	+	-	+	+	-	-	-	+	+	Mild
																				Renal cysts
CHN-12	5	M	+	+	-	-	-	-	-	(17)	+	-	-	-	-	-	-	+	+	Moderate
CHN-13	3	M	-	+	-	-	-	+	+	(1)	+	-	+	+	-	-	-	+	-	Moderate
CHN-14	13	M	-	+	-	-	-	+	+	(4)	-	-	+	+	-	-	-	+	-	Moderate
CHN-15	7	F	+	+	-	-	-	-	NA	(28)	+	-	+	+	-	-	-	+	-	Mild
CHN-16	18	M	-	+	-	-	-	-	-	(21)	+	+	-	-	-	-	-	+	-	-
CHN-17	11	F	-	+	-	-	-	-	-	(4)	+	-	-	-	-	-	-	+	-	Moderate
CHN-18	14	F	+	-	-	-	-	-	-	(7)	+	-	-	-	+	-	-	+	-	Mild
CHN-19	3	F	-	+	-	-	-	-	NA	(11)	+	-	+	+	-	-	-	+	-	-
CHN-20	6	M	-	-	-	-	-	-	-	(5)	+	-	+	+	-	-	-	-	-	-
CHN-21	2	M	-	-	-	-	-	-	+	-	+	-	-	-	-	-	-	+	+	Moderate
CHN-22	7	F	+	+	-	-	-	-	-	(1)	-	-	-	-	-	-	-	+	+	Mild
																				Renal cysts
CHN-23	7	F	+	+	-	-	-	+	+	(17)	+	-	+	+	-	-	-	+	-	Mild

TABLE 1 (Continued)

Patient	Age (year)	Sex	Major features											Neuropsychiatric features						
			Skin			Eye			Brain		Heart		Lungs		Kidney and liver		Seizures	ASD	ID	
			AF (≥3) or forehead plaque	Hypomelanotic macules (≥3)	Ungual Fibromas (≥2)	Shagreen patch	Multiple Retinal Hamartomas	Cortical dysplasia (no.) <sup>a</sup>	SEN	SEGA	Cardiac rhabdomyoma	LAM	AML (≥2)	Minor features						
AUS-1	35	F	-	-	-	-	-	-	-	-	-	-	-	-	-	-	-	-		
AUS-2	18	F	+	-	-	-	-	-	-	-	-	-	-	-	+	+	-	-		
AUS-3	29	F	-	+	-	-	-	-	-	-	+	(3)	-	-	NA	-	-	+	NA	-
AUS-4	51	F	+	-	-	-	-	NA	NA	+	(6)	+	-	-	NA	-	-	+	NA	-
AUS-5	43	M	+	-	-	-	-	NA	NA	+	(4)	+	-	-	Suspected	-	-	+	-	-
AUS-6	19	F	-	-	-	-	-	-	-	-	+	(1)	-	-	-	-	-	-	-	-
AUS-7	42	M	-	-	-	-	-	NA	NA	+	(3)	+	-	-	NA	+	-	+	NA	-
AUS-8	32	F	-	-	-	-	-	-	-	-	+	(7)	-	-	+	+	-	-	-	-

Abbreviations: AF, angiofibroma; AML, angiomyolipoma; ASD, autism spectrum disorder; ID, intellectual disability; LAM, lymphangioleiomyomatosis; MRI, magnetic resonance imaging; NA, not available; SEN, subependymal nodules; SEGA, Subependymal giant cell astrocytoma.

<sup>a</sup>Denotes number of tubers on MRI brain.

blood-derived DNA. The panel covers all the coding regions, splice sites, and introns of *TSC1* and *TSC2* (except six large introns: *TSC1* NM\_000368.5 introns 1, 2, 8, and 23, and *TSC2* NM\_000548.5 introns 9 and 16). *TSC1* and *TSC2* were amplified with long-segment polymerase chain reaction (PCR) (mean size ~8.5 kb). DNA libraries were prepared using a KAPA LTP Library Preparation Kit Illumina® platforms (KRO453) (KAPA BIO) according to the manufacturer's protocol, followed by paired-end sequencing to a targeted coverage of ~4000 reads/base on the NextSeq. 500 platform. Reads were aligned to the hg19 reference genome with NextGENe software v2.4.1.2 (SoftGenetics), then duplicate marking and base quality score recalibration were performed with the NextGENe software v2.4.1.2. The mean coverage achieved was 4019-fold. Germline variant calling and mosaic variant calling were also performed with NextGENe software v2.4.1.2. Variants were filtered using the following criteria: mutant reads  $\geq 10$ , and variant frequency  $\geq 2\%$ . Variants were annotated using population and literature databases including 1000 Genomes, the single nucleotide polymorphism database, the genome aggregation database, the ClinVar database, the human gene mutation database, the online mendelian inheritance in man database and an internal database of 100,000 Han Chinese individuals from the AmCare Genomics Laboratory.

## 2.5 | Copy number variation (CNV) analysis

For Melbourne patients, clinical chromosomal microarrays from the Illumina Global Diversity array platform (GDav1.0) were used to screen for genome-wide germline and mosaic ( $\geq 10\%$  VAF) CNV and loss of heterozygosity for *TSC1* and *TSC2* at a reportable resolution of 200 kb or greater on blood-derived DNA. Gene specific microarray analysis for *TSC1* and *TSC2* excluded single or multi exon CNVs in these genes except for exon 1 of *TSC2* as there was a 1.4 kb probe gap over this region. The data was analyzed using NxClinicalv6.0 (BioDiscovery) using genome reference sequence NCBI37/hg19. For Shenzhen patients, panel sequencing data was used to assess copy number of *TSC1* and *TSC2*. The normalized coverage depth of each exon of a test sample was compared with the mean coverage of the same exon in the reference file to detect potential CNVs with a VAF  $\geq 10\%$ . The data was analyzed using Amcarelab.ModelAnalysis-Tool software using genome reference sequence NCBI37/hg19 as previously reported (Feng et al., 2015). Breakpoints were verified by long-range PCR.

## 2.6 | Validation of candidate variants

Standard Sanger sequencing was performed to validate germline variants. Droplet digital PCR (ddPCR) was used to validate mosaic variants and determine their VAF in different tissues. Custom oligonucleotides and probes used for ddPCR assays are detailed in Supporting Information: Tables S1 and S2. For validation of mosaic

single nucleotide variants, ddPCR was performed as previously reported (Damiano et al., 2017). Positive results were defined as at least 3 positive droplets being detected using the BioRad QuantaSoft software (Uchiyama et al., 2016). For validation of mosaic copy number variants, a 22  $\mu$ l mixture was constructed for each reaction, containing 10  $\mu$ l of  $\times 2$  ddPCR EvaGreen Supermix (Bio-Rad), 0.4  $\mu$ l of each primer (5  $\mu$ M) and 20 ng of DNA. Twenty microliter of the mixture was subjected to droplet generation using 70  $\mu$ l of droplet generation oil for Evageen (Bio-Rad). Samples were manually transferred to a 96-well PCR plate, heat-sealed and amplified on a C1000 Touch thermal cycler using: 95°C for 5 min for one cycle, followed by 40 cycles at 94°C for 30 s and 60°C for 60 s, then one cycle at 4°C for 5 min and 90°C for 5 min, and finally infinite hold at 4°C. Post-PCR products were read on the QX200 droplet reader (Bio-Rad) and analyzed using QuantaSoft software.

## 2.7 | Complementary DNA (cDNA) synthesis and reverse-transcriptase PCR (RT-PCR)

To confirm aberrant splicing, reverse-transcriptase PCR was performed. cDNA was synthesized from 1  $\mu$ g of RNA extracted from whole blood using the Invitrogen™ SuperScript™ III First-Strand Synthesis System Kit with the random hexamer protocol. RT-PCR was performed with 2  $\mu$ l of cDNA using a standard protocol (Hildebrand et al., 2015).

## 2.8 | Statistical analysis

All statistical analyses were performed using IBM SPSS Statistics version 27. Correlation analyses were performed using the Pearson correlation test. Comparison of the frequency of different TSC clinical features in mosaic and germline patients was analyzed using Fisher's exact test. Bonferroni correction was performed to adjust for multiple comparisons. A *p* value of less than 0.05 was considered statistically significant.

# 3 | RESULTS

## 3.1 | Pathogenic variants in sporadic TSC patients

We identified a pathogenic variant in 22/31 (71%) patients in either *TSC1* or *TSC2*, including 16 with mosaic pathogenic variants and 6 with germline pathogenic variants that had been missed on clinical testing (Table 2 and Table 3). Overall, the VAF detected by ddPCR was consistent with that determined by gene panel sequencing in the same tissue. The only exception was patient (CHN-13) whose *TSC1* c.1888\_1891del (p.Lys630Glnfs\*22) variant was initially considered to be mosaic (VAF 29% in blood) on the basis of gene panel sequencing, but we determined it was germline by ddPCR (VAF ~50% in all tissues). This gene panel sequencing error was attributable to

**TABLE 2** Variant Allele Fraction (VAF) in different tissues from sporadic patients with mosaic pathogenic variants

Patient	Variant	ACMG Pathogenicity	Panel sequencing		ddPCR		Urine VAF	Brain VAF	Skin VAF	Number of major clinical features	Number of minor clinical features	
			Tissue tested	VAF	Blood VAF	Buccal VAF						
CHN-8	TSC2 c.598C > T (p.Gln200*)	Pathogenic	Blood	3.6%	3.7%	12%	12.8%	27.4% <sup>a</sup>	-	7	0	
CHN-4	TSC2 c.4198delG (p.Asp1400Thrfs*11)	Pathogenic	Blood	5.8%	6.4%	5.3%	11.5%	12.5%	-	6	0	
CHN-10	TSC2 c.4905C > A (p.Cys1635*)	Pathogenic	Blood	3.9%	3.0%	3.0%	9.2%	ND	-	6	0	
CHN-11	TSC2 exon37-38 del	Pathogenic	Blood	30%	37% <sup>a</sup>	51.1% <sup>a</sup>	50.6% <sup>a</sup>	ND	-	5	1	
CHN-3	TSC2 c.4881delC (p.Lys1628Argfs*44)	Pathogenic	Blood	11.3%	11.8%	18.7%	22.2%	19.2%	-	5	0	
CHN-2	TSC2 c.4850-1G > C	Pathogenic	Blood	19.6%	19.8%	14.5%	11.5%	13.5%	18%	4	0	
CHN-7	TSC2 c.729_730del (p.Cys244Serfs*93)	Pathogenic	Blood	7.2%	7.8%	8.6%	10.6%	19% <sup>a</sup>	-	4	0	
CHN-6	TSC2 c.2015dupC (p.Ala673Glyfs*30)	Pathogenic	Blood	7.5%	7.3%	4%	2.5%	24.2% <sup>a</sup>	-	4	0	
CHN-12	TSC2 c.838_839del (p.Met280Glyfs*57)	Pathogenic	Blood	6.0%	7.1%	10.2%	7.3%	12%	-	4	0	
CHN-9	TSC2 c.5240T > A (p.Ile1747Asn)	Likely pathogenic	Blood	4.7%	4.6%	5.5%	2.7%	ND	-	4	0	
CHN-5	TSC2 c.3685C > T (p.Gln1229*)	Pathogenic	Blood	8.9%	8.3%	9.7%	11%	12%	-	4	0	
AUS-8	TSC2 c.4235dupC (p.Glu1413*)	Pathogenic	Blood	4.3%	4.8%	2.5%	-	9.1%	-	3	0	
AUS-2	TSC2 c.1714_1716 + 4dup	Pathogenic	Angiofibroma	1.9%	0.5%	0.2%	0.07%	ND	Normal skin: 0.06% Lesion <sup>b</sup> : 2.5%	2	1	
AUS-3	TSC1 c.1770_1777del (p.Pro591Serfs*12)	Pathogenic	Blood	21%	27%	-	-	-	-	2	0	
CHN-1	TSC2 c.1912delG (p.Val638Cysfs*60)	Pathogenic	Blood	8.9%	5.2%	4.5%	1.4%	5.2%	1.6%	Lesion <sup>c</sup> : 1.1%	2	0
AUS-1	TSC2 c.4537G > T (p.Glu1513*)	Pathogenic	Blood	2%	1.8%	2.2%	1.6%	1.3%	-	2	0	

Abbreviations: ACMG, American College of Medical Genetics guideline; ddPCR, droplet digital polymerase chain reaction; ND, not detectable due to low DNA yield from urine samples; -, no sample.

<sup>a</sup>Mean VAF from 2 different samples of each tissue;

<sup>b</sup>Same angiofibroma DNA used for panel sequencing;

<sup>c</sup>Hypomelanotic macule skin lesion DNA.

**TABLE 3** Sporadic patients with missed germline mutations

Patient	Variant	ACMG pathogenicity	Function	Number of major clinical features	Number of minor clinical features
CHN-13	TSC1 c.1888_1891del (p.Lys630Glnfs*22)	Pathogenic	Known pathogenic variant <sup>a</sup>	5	0
CHN-15	TSC2 c.976-15G > A	Pathogenic	Known pathogenic variant <sup>b</sup>	5	0
CHN-14	TSC2 c.3598C > T (p.Pro1200Trp)	Pathogenic	Known pathogenic variant <sup>c</sup>	4	0
CHN-16	TSC2 c.1443G > A (p.Glu481=)	Pathogenic	Exon 14 skipping	4	0
CHN-17	TSC2 c.2639 + 4A > T	Likely pathogenic	Exon 23 skipping	3	0
AUS-4	TSC1 c.362A > G (p.Lys121Arg)	Pathogenic	Exon 5 skipping	3	0

Abbreviation: ACMG, American College of Medical Genetics guideline.

<sup>a</sup>National Center for Biotechnology Information. ClinVar; [VCV000005097.6], <https://www.ncbi.nlm.nih.gov/clinvar/variation/VCV000005097.6>

<sup>b</sup>Tyburczy et al., 2015

<sup>c</sup>National Center for Biotechnology Information. ClinVar; [VCV000049770.12], <https://www.ncbi.nlm.nih.gov/clinvar/variation/VCV000049770.12>

strong strand bias, low coverage, and/or reduced alignment of reads containing the deletion.

Mosaic pathogenic variants were identified in *TSC2* in 15/16 patients, including 7 small insertions or deletions, 5 nonsense, 1 missense, 1 splicing and 1 CNV; whereas, only 1 mosaic pathogenic variant was in *TSC1*, an 8 base pair deletion (Table 2). Overall, VAF ranged from 0.5% to 37% in blood by ddPCR (median 6.8%), 0.2–51.1% in saliva (median 5.5%), and 0.07–50.6% in buccal cells (median 9.2%). Patient CHN-11 had a mosaic CNV with a VAF in blood of 30% on panel sequencing and 37% on ddPCR compared with 51.1% in saliva and 50.6% in buccal DNA. In view of the 50% VAF in saliva and buccal samples, we recollected all three tissues again and confirmed that this variant was indeed mosaic (Table 2).

Urine-derived DNA was less reliable for testing and generally of lower concentration than DNA from other tissues, resulting in variants detectable in the urine of only 11 patients, with VAF ranging from 1.3% to 27.4% (median 12.5%). In patients CHN-6, CHN-7, and CHN-8, their urine VAF was much higher than the VAF in their other tissues. We therefore collected a second urine sample from each child which confirmed the high urine VAF of 24.2%, 19% and 27.4%, respectively (Table 2). It is noteworthy that patients CHN-6 and CHN-8 both have multiple renal angiomyolipomata (AML) (Table 1), which may explain the higher VAF in urine compared to other tissues. The lower VAF of 19% was found in CHN-7 who did not have renal AML on ultrasound.

Three patients had lesion-derived DNA tested in addition to DNA from blood, saliva, buccal cells, and urine (Table 2). For patient AUS-2, VAF was highest in the facial angiofibroma biopsy (2.5%) compared to normal skin (0.06%) and other tissues (0.07–0.5%). For patient CHN-2, the VAF in cortical tuber (18%) was similar to that in blood (19.8%) and slightly higher than in other tissues (11.5%–14.5%). Conversely, for patient CHN-1, the VAF in cortical tuber (1.6%) and a hypomelanotic skin macule (1.1%) was much lower than in blood, saliva, and urine (4.5%–5.2%). Overall, we found that VAF across different tissues was relatively similar in some patients, but varied widely in others (Table 2).

Of the 6 germline pathogenic variants, 4/6 were in *TSC2* and 2/6 in *TSC1*. There were 4 splicing defects, including splice-site pathogenic variants in *TSC2* in CHN-15 and CHN-17, 1 synonymous variant in the last base pair of exon 14 of *TSC2* in CHN-16, and 1 missense variant in the second last base pair of exon 5 of *TSC1* in AUS-4 (Table 3). The recurrent heterozygous *TSC2* c.976-15G > A pathogenic variant found in CHN-15 has been shown to cause aberrant splicing (Tyburczy et al., 2015). Using RT-PCR and Sanger sequencing of patient RNA samples, we confirmed that the *TSC1* c.362A > G (p.Lys121Arg and AUS-4) variant leads to exon 5 skipping, *TSC2* c.1443G > A (p.Glu481= and CHN-16) variant causes exon 14 skipping, and *TSC2* c.2639 + 4A > T (CHN-17) variant induces exon 23 skipping (Table 3 and Supporting Information: Figure S1). The remaining two germline pathogenic variants were a missense variant in *TSC2* (CHN-14) and a four base pair deletion in *TSC1* (CHN-13), both recurrent pathogenic variants reported in ClinVar (VCV000005097.6 and VCV000049770.12) (Table 3).

### 3.2 | Genotype-phenotype correlation in mosaic patients

Overall, for patients with mosaic pathogenic variants, the number of major clinical features (Table 2) did not correlate with blood VAF ( $R = 0.022$ ,  $n = 16$ ,  $p = 0.94$ ), saliva VAF ( $R = 0.33$ ,  $n = 15$ ,  $p = 0.23$ ) or buccal VAF ( $R = 0.44$ ,  $n = 14$ ,  $p = 0.11$ ). In contrast, the brain tuber load did correlate with saliva VAF ( $R = 0.57$ ,  $n = 15$ ,  $p = 0.026$ ) and buccal VAF ( $R = 0.56$ ,  $n = 14$ ,  $p = 0.037$ ), but not with blood VAF ( $R = 0.37$ ,  $n = 16$ ,  $p = 0.16$ ).

Clinical data was available for 213 of the 216 Chinese patients from the Shenzhen cohort who had germline *TSC1* and *TSC2* pathogenic variants. We compared the frequency of each TSC feature in the 12 pediatric mosaic patients and the 213 pediatric germline patients. We found a trend that hypomelanotic macules, subependymal nodules (SEN), seizures and retinal hamartomas were

**TABLE 4** Comparison of frequency of clinical features between pediatric mosaic and germline patients

Features	Mosaic patients (n = 12)			Germline patients (n = 213)			Adjusted <i>p</i> value mosaic versus germline (Bonferroni test)
	Positive	Negative	Prevalence	Positive	Negative	Prevalence	
<b>Cutaneous features</b>							
Angiofibromas (≥3)	6	6	50%	97	101	49%	1
Forehead plaque	3	9	25%	51	146	26%	1
Hypomelanotic macules (≥3)	10	2	83%	203	2	99%	0.192
Ungual fibromas (≥2)	0	12	0%	9	200	4%	1
Shagreen patch	3	9	25%	106	102	51%	0.864
<b>Neurological features</b>							
Cortical dysplasias	12	0	100%	202	5	98%	1
Subependymal nodule	10	2	83%	197	9	96%	1
Subependymal giant cell astrocytoma	1	11	8%	83	124	40%	0.276
Seizure	9	3	75%	201	12	94%	0.444
<b>Other organs</b>							
Cardiac rhabdomyoma	7	5	58%	118	84	58%	1
Renal angiomyolipomata	6	6	50%	71	130	35%	1
Multiple retinal hamartomas	0	12	0	37	77	32%	0.144

less frequent in mosaic patients, however, none of them were statistically significant (Bonferroni adjusted  $p > 0.05$ , Table 4).

### 3.3 | Low-level parental mosaicism in families with TSC

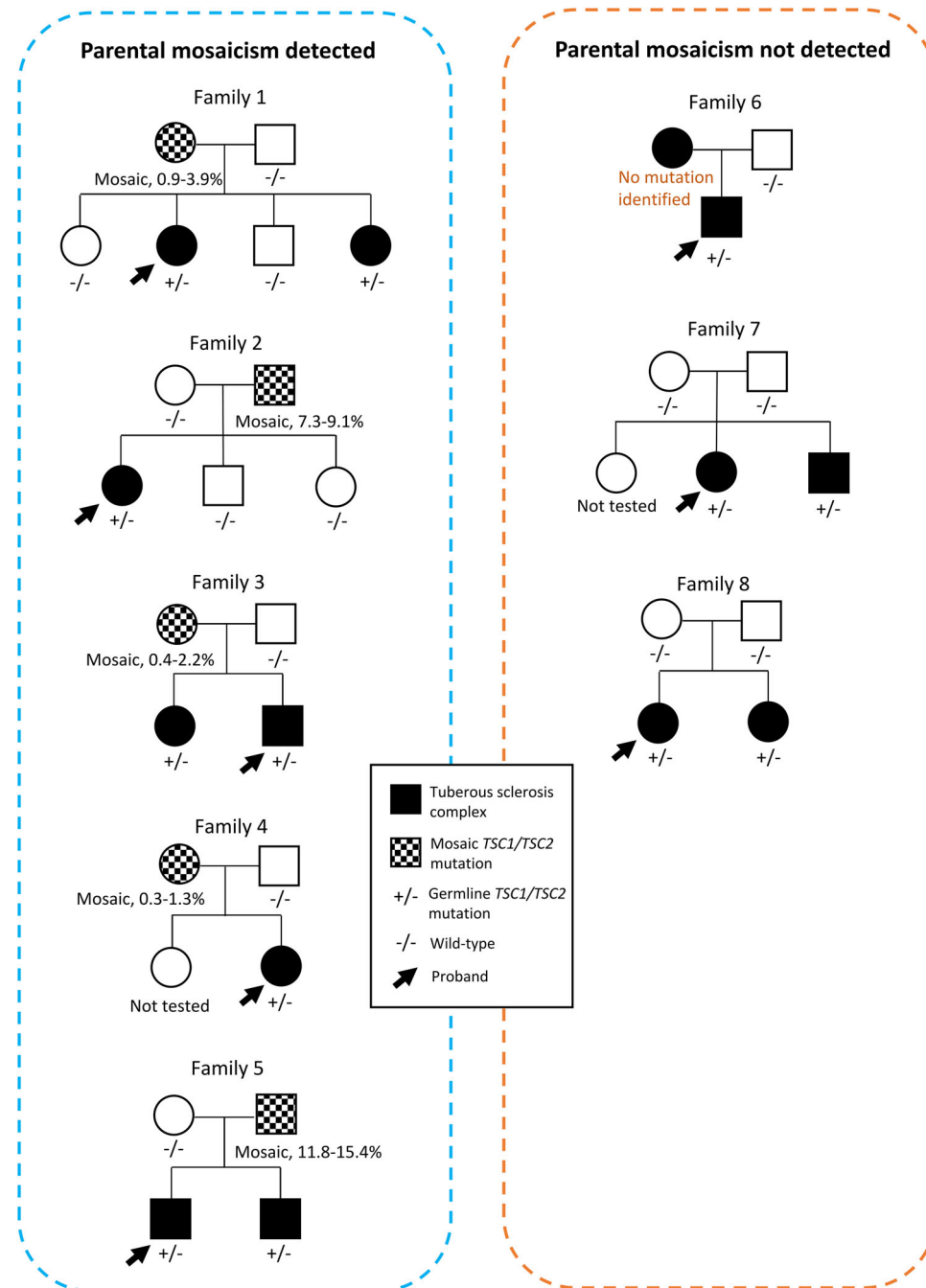
Parental mosaicism for *TSC2* variants was detected in 5/8 families studied (Figure 1, Table 5). VAF in the mosaic parents ranged from 0.3% to 9.1%. Mosaic parents had milder phenotypes with fewer clinical features (range: 0–2) compared to their children with heterozygous pathogenic variants (range: 5–8) (Table 5). Although the parents in these families had low-level mosaicism, it is noteworthy that 6/11 of their children had TSC, while 5 did not and were negative for the familial pathogenic variant (Figure 1).

In Family 1, mosaicism was detected in the mother, with a VAF ranging from 2% to 3.9% in the tissues tested. After genetic testing was received, examination revealed multiple facial angiofibromas and multiple renal AML resulting in a clinical diagnosis of definite TSC. In Family 2, the father had multiple facial angiofibromas and multiple renal AML and was diagnosed with definite TSC before genetic testing, but he had been negative for his child's variant on routine clinical testing. Mosaicism was detected, with a VAF ranging from 7.3%–9.1%. In Family 3, mosaicism was detected in the mother (VAF 0.4%–2.2%). Following the molecular diagnosis, the mother had comprehensive physical examination and imaging and was found to only have an unguinal fibroma without any other clinical features. In

Family 4, mosaicism was detected in the mother (VAF 0.3%–1.3%); subsequently she was diagnosed with multiple renal AML and possible TSC following the molecular testing, based on clinical criteria. In Family 5, both parents did not have any TSC features identified with comprehensive physical examination and imaging. Mosaicism was identified in the father's semen (VAF: 15.4%) and urine samples (VAF: 11.8%), but was not detectable in the other tissues tested.

## 4 | DISCUSSION

We sought to identify low-level mosaic pathogenic variants in *TSC1* or *TSC2* in individuals with unsolved TSC, and in families where an undetected low-level mosaic pathogenic variant could explain the observed TSC inheritance pattern. We solved 22/31 (71%) sporadic NMI patients with 16/31 having mosaic and 6/31 missed germline pathogenic variants in *TSC1* or *TSC2*, providing molecular diagnosis for most unsolved patients, consistent with an earlier report (Tyburczy et al., 2015). In the 16 patients with mosaic pathogenic variants, VAFs ranged from 0.5% to 37% in blood (median = 6.8%). Clinical genetic laboratories typically only report variants with an allele fraction greater than 10% (Batalini et al., 2019) and focus on blood or saliva-derived DNA. Therefore, it was not surprising that VAFs for 12/16 mosaic pathogenic variants in our cohort were below 10% in blood. Overall, our findings highlight the importance of applying sensitive assays in clinical laboratories to enable



**FIGURE 1** Family pedigrees of the eight families with potential parental mosaicism.

Phenotypes were classified according to the 2012 TSC diagnostic criteria guideline (Northrup et al., 2013). Black symbols represent patients with tuberous sclerosis complex; mosaic symbols represent individuals with parental mosaicism; arrows represent probands. Genotypes are provided for tested individuals as  $-/-$  for wild-type and  $+/-$  for heterozygous *TSC1/TSC2* pathogenic variants. For parents with mosaic pathogenic variants, variant allele frequency is provided. TSC, Tuberous sclerosis complex.

identification and reporting of disease-causing mosaic pathogenic variants down to at least 2% VAF. These findings have both clinical management implications for the mosaic individual, together with critical reproductive counseling implications.

Mosaicism explained half of the 11% of patients who were negative on prior clinical molecular testing in our large pediatric cohort from Shenzhen. Thus, we estimate that mosaic pathogenic

variants explain 5.5% of all TSC patients. This is a large number of patients considering the prevalence of TSC, however, this estimate is based on a relatively small number of studies (Giannikou et al., 2019; Treichel et al., 2019; Tyburczy et al., 2015) with limited data on genotype-phenotype correlation. We found that specific cutaneous features (hypomelanotic macules), neurological features (SEN and seizures) and ophthalmological feature (multiple retinal hamartomas)

**TABLE 5** Clinical and genetic diagnosis of parents and affected children in families with TSC

Family number	Family member	Clinical features for TSC	Variant	VAF				
				Blood	Saliva	Buccal	Urine	Semen
1	Mother	Definite TSC, 2 major features (multiple AF, multiple renal AML)	Mosaic <i>TSC2</i> c.439A > G	2%	3.1%	0.9%	3.9%	-
	Second child	Definite TSC, 7 major features	Germline <i>TSC2</i> c.439° > G	50%				
	Fourth child	Definite TSC, 6 major features		50%				
2	Father	Definite TSC, 2 major features (multiple AF, multiple renal AML)	Mosaic <i>TSC2</i> c.1832G > C	8.8%	9.1%	8.3%	7.3%	-
	First child	Definite TSC, 8 major features	Germline <i>TSC2</i> c.1832G > C	50%				
3	Mother	Does not meet TSC diagnosis criteria (only 1 ungual fibroma)	Mosaic <i>TSC2</i> c.668_676del	1%	1.6%	2.2%	0.4%	-
	First child	Definite TSC, 8 major features	Germline <i>TSC2</i> c.668_676del	50%				
	Second child	Definite TSC, 5 major features and 1 minor feature		50%				
4	Mother	Possible TSC, 1 major feature (multiple renal AML)	Mosaic <i>TSC2</i> c.3581G > A	0.3%	1.3%	0.7%	ND	-
	Second child	Definite TSC, 6 major features	Germline <i>TSC2</i> c.3581G > A	50%				
5	Mother	No TSC feature	ND	ND	ND	ND	ND	-
	Father	No TSC feature	ND	ND	ND	11.8%	15.4%	
	First child	Definite TSC, 5 major features	Germline <i>TSC2</i> c.4738_4741dup	50%				
	Second child	Definite TSC, 6 major features		50%				
6	Mother	Definite TSC, 2 major features (shagreen patch; multiple renal AML)	ND	ND	ND	ND	ND	-
	Only child	Definite TSC, 5 major features	Germline <i>TSC2</i> c.2015_2016insTT	50%				
7	Mother	No TSC feature	ND	ND	ND	ND	ND	-
	Father	No TSC feature	ND	ND	ND	ND	ND	ND
	Second child	Definite TSC, 6 major features	Germline <i>TSC2</i> c.1939dup	50%				
	Third child	Definite TSC, 7 major features		50%				
8	Mother	Does not meet TSC diagnosis criteria (1 suspected liver AML)	ND	ND	ND	ND	ND	-
	Father	No TSC feature	ND	ND	ND	ND	ND	ND
	First child	Definite TSC, 5 major features	Germline <i>TSC2</i> c.976-15G > A	50%				
	Second child	Definite TSC, 7 major features		50%				

Abbreviations: AF, facial angiofibroma; AML, angiomyolipoma; ND: not detected; -, not applicable.

were less common in pediatric mosaic patients compared to pediatric patients with germline pathogenic variants, but they did not achieve a statistical significance, most likely due to the small sample size, as we only have 12 pediatric mosaic patients for comparison. We were not able to compare the frequency of lymphangioleiomyomatosis, autism spectrum disorders and intellectual disability in the pediatric groups, and not able to compare adult mosaic patients with adult germline patients due to lack of available data.

Germline pathogenic variants were missed in six sporadic patients on prior testing, likely due to technical issues. These may

arise due to poor coverage of certain genomic regions or because variants impacting splicing, such as synonymous changes, may be filtered out by standard analytic pipelines or may not have been considered potentially significant. RT-PCR should be considered to confirm the impact of putative splicing variants if tissue RNA is available. It is also worth mentioning that Patient CHN-17 was initially ascertained as sporadic because the patient was clinically diagnosed as definite TSC, while the parents did not have any clinical features of TSC on physical examination and declined further clinical investigation at that time. Following discovery of the germline splice

site mutation in Patient CHN-17, we Sanger sequenced both parents and found the mother also carried this variant. The mother subsequently received comprehensive clinical investigation and was found to have renal angiomyolipoma.

Nine sporadic patients remain unsolved, possibly due to the following limitations of our study: (1) deep intronic pathogenic variants not covered by gene testing panels; (2) mosaic pathogenic single nucleotide variants with a VAF < 2% and genomic deletions/rearrangements with a VAF < 10%, which were below the limit of detection using our methods with lower sequencing depth or microarray resolution than reported in some other studies (Giannikou et al., 2019; Tyburczy et al., 2015); or (3) mosaic somatic pathogenic variants confined to affected organs (brain, kidney) and not detectable in peripheral tissues available for testing. Novel technologies, including genome sequencing, may identify the remaining pathogenic variants, be they deep intronic or novel variation types. There has long been speculation as to whether there is a third TSC gene (Qin et al., 2010). Our findings reinforce that a third TSC gene is unlikely, consistent with previous reports of NMI patients (Giannikou et al., 2019; Tyburczy et al., 2015).

Parental mosaicism was found in 5 families with VAFs ranging from 0.3% to 9.1%. The affected offspring with germline pathogenic variants had more severe phenotypic manifestations and a greater number of clinical features on average. In the remaining three families, parental mosaicism was not detected. Family 6 has one affected child with the germline *TSC2* c.2105\_2016insTT pathogenic variant. The mother has multiple bilateral renal AML and shagreen patch. However, mosaicism was not detected in any of her tissues, including urine. Her variant might be confined to certain organs which were not studied. Families 7 and 8 both have two affected children with the same germline pathogenic variant detected in both affected children. Both parents underwent comprehensive physical examinations, but no TSC features were identified, except for the mother in Family 8 who had a suspected liver AML. Different tissues from both parents were tested, including semen samples from the two fathers. Interestingly, mosaicism was not detected in any tissue, leaving a possible explanation of maternal gonadal mosaicism.

Renal AML was the most common major feature in parents with mosaicism, suggesting that renal ultrasounds should be routinely performed in parents of children with TSC. The mother in Family 4 had renal AML on re-examination following our detection of ultra-low *TSC2* mosaicism, with 0.3% in blood. Currently there is no consensus regarding variant threshold for diagnosis in the setting of mosaic pathogenic variants even in the updated diagnostic guidelines published in 2021 (Northrup et al., 2021).

Low-level *TSC1/TSC2* mosaicism may be under-recognized as such individuals may have no clinical TSC features or only subtle manifestations (Giannikou et al., 2019; Ogórek et al., 2020; Tyburczy et al., 2015). We observed this phenomenon; the sole feature in the mother in Family 3 was one unguil fibroma reflecting her ultra-low level of mosaic pathogenic variant (1% VAF in blood). This single subtle clinical feature would be insufficient for a TSC diagnosis based on clinical criteria alone; however, there is likely to be an increased

recurrence risk, acknowledging we could not determine the percentage mosaicism in gonadal tissue.

In conclusion, we found mosaic pathogenic variants in 52% of patients with TSC negative on conventional genetic testing. Most mosaic pathogenic variants had a VAF of less than 10%, highlighting the importance of using high-depth sequencing and ddPCR assays to increase sensitivity to detect and confirm low-level mosaic pathogenic variants. Mosaic patients have fewer cutaneous and neurological features compared to patients with germline variants. Higher VAFs in saliva and buccal cells positively correlated with tuber load in mosaic patients. Parents with low-level mosaic pathogenic variants and few or no clinical features of TSC can transmit their pathogenic variant to their offspring; careful clinical examination of parents is recommended. Genetic investigations, incorporating testing for low-level mosaicism, critically inform clinical management and reproductive counseling for patients and families with TSC.

## ACKNOWLEDGMENTS

We thank the patients and their families for participating in our research program. This study was supported by a Sanming Project of Medicine in Shenzhen (SZSM201812005); an Australia National Health and Medical Research Council (NHMRC) Program Grant (1091593) to I.E.S. and S.F.B., a Project Grant (1129054) to S.F.B., a Project Grant (1079058) to M.S.H., a Practitioner Fellowship (1006110) and Senior Investigator grant (1172897) to I.E.S., a Senior Research Fellowship (1102971) to M.F.B., and a R.D Wright Career Development Fellowship (1063799) to M.S.H. This study was also supported by a Taking Flight Award from CURE Epilepsy to M.F.B. and an Australian Epilepsy Research Fund Scheme Grant from the Epilepsy Foundation to M.S.H. and Victorian State Government Operational Infrastructure Support and Australian Government NHMRC IRIISS. Open access publishing facilitated by The University of Melbourne, as part of the Wiley-The University of Melbourne agreement via the Council of Australian University Librarians.

## CONFLICT OF INTEREST

I. E. S has served on scientific advisory boards for UCB, Eisai, GlaxoSmithKline, BioMarin, Nutricia, Rogcon, Chiesi, Encoded Therapeutics, Knopp Biosciences and Xenon Pharmaceuticals; has received speaker honoraria from GlaxoSmithKline, UCB, BioMarin, Biocodex, Chiesi, Liva Nova and Eisai; has received funding for travel from UCB, Biocodex, GlaxoSmithKline, Biomarin and Eisai; has served as an investigator for Zogenix, Zynerba, Ultragenyx, GW Pharma, UCB, Eisai, Xenon Pharmaceuticals, Anavex Life Sciences, Ovid Therapeutics, Epigenyx, Encoded Therapeutics and Marinus; and has consulted for Zynerba Pharmaceuticals, Atheneum Partners, Ovid Therapeutics, Care Beyond Diagnosis, Epilepsy Consortium and UCB; and is a Nonexecutive Director of Bellberry Ltd. She may accrue future revenue on pending patent WO61/010176 (filed: 2008): Therapeutic Compound; has a patent for SCN1A testing held by Bionomics Inc and licensed to various diagnostic companies; has a patent molecular diagnostic/theranostic target for benign familial infantile epilepsy (BFIE) [PRRT2] 2011904493 and 2012900190 and

PCT/AU2012/001321 (TECH ID:2012-009). The remaining authors declare no competing interests or conflicts of interest.

## DATA AVAILABILITY STATEMENT

Data available on reasonable request due to privacy/ethical restrictions. Variants identified in this study were submitted to the Leiden Open Variation Database (LOVD database): ([https://databases.lovd.nl/whole\\_genome/variants/TSC1](https://databases.lovd.nl/whole_genome/variants/TSC1) and [https://databases.lovd.nl/whole\\_genome/variants/TSC2](https://databases.lovd.nl/whole_genome/variants/TSC2)).

## ORCID

Zimeng Ye  <https://orcid.org/0000-0002-5578-9374>

## REFERENCES

- Au, K. S., Williams, A. T., Gambello, M. J., & Northrup, H. (2004). Molecular genetic basis of tuberous sclerosis complex: From bench to bedside. *Journal of Child Neurology (St. Louis, MO)*, *19*(9), 699–709. <https://doi.org/10.1177/08830738040190091101>
- Au, K. S., Williams, A. T., Roach, E. S., Batchelor, L., Sparagana, S. P., Delgado, M. R., Wheless, J. W., Baumgartner, J. E., Roa, B. B., Wilson, C. M., Smith-Knuppel, T. K., Cheung, M. Y., Whittemore, V. H., King, T. M., & Northrup, H. (2007). Genotype/phenotype correlation in 325 individuals referred for a diagnosis of tuberous sclerosis complex in the United States. *Genetics in Medicine*, *9*(2), 88–100. <https://doi.org/10.1097/gim.0b013e31803068c7>
- Batalini, F., Peacock, E. G., Stobie, L., Robertson, A., Garber, J., Weitzel, J. N., & Tung, N. M. (2019). Li-Fraumeni syndrome: Not a straightforward diagnosis anymore—the interpretation of pathogenic variants of low allele frequency and the differences between germline PVs, mosaicism, and clonal hematopoiesis. *Breast Cancer Research*, *21*(1), 107. <https://doi.org/10.1186/s13058-019-1193-1>
- Baybis, M., Yu, J., Lee, A., Golden, J. A., Weiner, H., McKhann, G., 2nd, Aronica, E., & Crino, P. B. (2004). mTOR cascade activation distinguishes tubers from focal cortical dysplasia. *Annals of Neurology*, *56*(4), 478–487. <https://doi.org/10.1002/ana.20211>
- Caban, C., Khan, N., Hasbani, D. M., & Crino, P. B. (2017). Genetics of tuberous sclerosis complex: Implications for clinical practice. *The Application of Clinical Genetics*, *10*, 1–8. <https://doi.org/10.2147/TACG.S90262>
- Curatolo, P., Moavero, R., Roberto, D., & Graziola, F. (2015). Genotype/Phenotype correlations in tuberous sclerosis complex. *Seminars in Pediatric Neurology*, *22*(4), 259–273. <https://doi.org/10.1016/j.spen.2015.10.002>
- Curatolo, P., Moavero, R., van Scheppingen, J., & Aronica, E. (2018). mTOR dysregulation and tuberous sclerosis-related epilepsy. *Expert Review of Neurotherapeutics*, *18*(3), 185–201. <https://doi.org/10.1080/14737175.2018.1428562>
- Curatolo, P., Moavero, R., & de Vries, P. J. (2015). Neurological and neuropsychiatric aspects of tuberous sclerosis complex. *Lancet Neurology*, *14*(7), 733–745. [https://doi.org/10.1016/S1474-4422\(15\)00069-1](https://doi.org/10.1016/S1474-4422(15)00069-1)
- Dabora, S. L., Jozwiak, S., Franz, D. N., Roberts, P. S., Nieto, A., Chung, J., Choy, Y. S., Reeve, M. P., Thiele, E., Egelhoff, J. C., Kasprzyk-Obara, J., Domanska-Pakiela, D., & Kwiatkowski, D. J. (2001). Mutational analysis in a cohort of 224 tuberous sclerosis patients indicates increased severity of TSC2, compared with TSC1, disease in multiple organs. *American Journal of Human Genetics*, *68*(1), 64–80. <https://doi.org/10.1086/316951>
- Damiano, J. A., Do, H., Ozturk, E., Burgess, R., Kalnins, R., Jones, N. C., Dobrovic, A., Berkovic, S. F., & Hildebrand, M. S. (2017). Sensitive quantitative detection of somatic mosaic mutation in “double cortex” syndrome. *Epileptic Disorders*, *19*(4), 450–455. <https://doi.org/10.1684/epd.2017.0944>
- Feng, Y., Chen, D., Wang, G. L., Zhang, V. W., & Wong, L. J. (2015). Improved molecular diagnosis by the detection of exonic deletions with target gene capture and deep sequencing. *Genetics in Medicine*, *17*(2), 99–107. <https://doi.org/10.1038/gim.2014.80>
- Frost, M., & Hulbert, J. (2015). Clinical management of tuberous sclerosis complex over the lifetime of a patient. *Pediatric Health Med Ther*, *6*, 139–146. <https://doi.org/10.2147/PHMT.S67342>
- Giannikou, K., Lasseter, K. D., Grevelink, J. M., Tyburczy, M. E., Dies, K. A., Zhu, Z., Hamieh, L., Wollison, B. M., Thorner, A. R., Ruoss, S. J., Thiele, E. A., Sahin, M., & Kwiatkowski, D. J. (2019). Low-level mosaicism in tuberous sclerosis complex: Prevalence, clinical features, and risk of disease transmission. *Genetics in Medicine*, *21*(11), 2639–2643. <https://doi.org/10.1038/s41436-019-0562-6>
- Hildebrand, M. S., Tankard, R., Gazina, E. V., Damiano, J. A., Lawrence, K. M., Dahl, H. H., Regan, B. M., Shearer, A. E., Smith, R. J., Marini, C., Guerrini, R., Labate, A., Gambardella, A., Tinuper, P., Lichetta, L., Baldassari, S., Bisulli, F., Pippucci, T., Scheffer, I. E.,... Berkovic, S. F. (2015). PRIMA1 mutation: a new cause of nocturnal frontal lobe epilepsy. *Annals of Clinical and Translational Neurology*, *2*(8), 821–830. <https://doi.org/10.1002/acn3.224>
- Hodges, A. K., Li, S., Maynard, J., Parry, L., Braverman, R., Cheadle, J. P., Declue, J. E., & Sampson, J. R. (2001). Pathological mutations in TSC1 and TSC2 disrupt the interaction between hamartin and tuberin. *Human Molecular Genetics*, *10*(25), 2899–2905. <https://doi.org/10.1093/hmg/10.25.2899>
- Jones, A. C., Shyamsundar, M. M., Thomas, M. W., Maynard, J., Idziaszczyk, S., Tomkins, S., Sampson, J. R., & Cheadle, J. P. (1999). Comprehensive mutation analysis of TSC1 and TSC2-and phenotypic correlations in 150 families with tuberous sclerosis. *American Journal of Human Genetics*, *64*(5), 1305–1315. <https://doi.org/10.1086/302381>
- Kingswood, J. C., D'augères, G. B., Belousova, E., Ferreira, J. C., Carter, T., Castellana, R., Cottin, V., Curatolo, P., Dahlin, M., de Vries, P. J., Feucht, M., Fladrowski, C., Gislimberti, G., Hertzberg, C., Jozwiak, S., Lawson, J. A., Macaya, A., Nabbout, R., O'Callaghan, F., ... TOSCA consortium and TOSCA, i (2017). Tuberous Sclerosis registry to increase disease awareness (TOSCA) - baseline data on 2093 patients. *Orphanet Journal of Rare Diseases*, *12*(1), 2. <https://doi.org/10.1186/s13023-016-0553-5>
- Martin, K. R., Zhou, W., Bowman, M. J., Shih, J., Au, K. S., Dittenhafer-Reed, K. E., Sisson, K. A., Koeman, J., Weisenberger, D. J., Cottingham, S. L., DeRoos, S. T., Devinsky, O., Winn, M. E., Cherniack, A. D., Shen, H., Northrup, H., Krueger, D. A., & MacKeigan, J. P. (2017). The genomic landscape of tuberous sclerosis complex. *Nature Communications*, *8*, 15816. <https://doi.org/10.1038/ncomms15816>
- Mayer, K., Fonatsch, C., Wimmer, K., van den Ouweland, A. M., & Maat-Kievit, A. J. (2014). Clinical utility gene card for: Tuberous sclerosis complex (TSC1, TSC2). *European Journal of Human Genetics*, *22*(2). <https://doi.org/10.1038/ejhg.2013.129>
- McKenna, A., Hanna, M., Banks, E., Sivachenko, A., Cibulskis, K., Kernytsky, A., Garimella, K., Altshuler, D., Gabriel, S., Daly, M., & DePristo, M. A. (2010). The genome analysis toolkit: A MapReduce framework for analyzing next-generation DNA sequencing data. *Genome Research*, *20*(9), 1297–1303. <https://doi.org/10.1101/gr.107524.110>
- Northrup, H., Aronow, M. E., Bebin, E. M., Bissler, J., Darling, T. N., de Vries, P. J., Frost, M. D., Fuchs, Z., Gosnell, E. S., Gupta, N., Jansen, A. C., Józwiak, S., Kingswood, J. C., Knilans, T. K., McCormack, F. X., Pounders, A., Roberds, S. L., Rodriguez-Buritica, D. F., Roth, J.,... International Tuberous Sclerosis Complex Consensus, G. (2021). Updated international tuberous sclerosis complex diagnostic

- criteria and surveillance and management recommendations. *Pediatric Neurology*, 123, 50–66. <https://doi.org/10.1016/j.pediatrneurol.2021.07.011>
- Northrup, H., Krueger, D. A., & International Tuberous Sclerosis Complex Consensus, G. (2013). Tuberous sclerosis complex diagnostic criteria update: recommendations of the 2012 international tuberous sclerosis complex consensus conference. *Pediatric Neurology*, 49(4), 243–254. <https://doi.org/10.1016/j.pediatrneurol.2013.08.001>
- Ogórek, B., Hamieh, L., Hulshof, H. M., Lassetter, K., Klonowska, K., Kuijff, H., Moavero, R., Hertzberg, C., Weschke, B., Riney, K., Feucht, M., Scholl, T., Krsek, P., Nabbout, R., Jansen, A. C., Benova, B., Aronica, E., Lagae, L., Curatolo, P., ... Kwiatkowski, D. J. (2020). TSC2 pathogenic variants are predictive of severe clinical manifestations in TSC infants: Results of the EPISTOP study. *Genetics in Medicine*, 22(9), 1489–1497. <https://doi.org/10.1038/s41436-020-0823-4>
- Pedersen, B. S., Layer, R. M., & Quinlan, A. R. (2016). Vcfanno: Fast, flexible annotation of genetic variants. *Genome Biology*, 17(1), 118. <https://doi.org/10.1186/s13059-016-0973-5>
- Qin, W., Kozłowski, P., Taillon, B. E., Bouffard, P., Holmes, A. J., Janne, P., Camposano, S., Thiele, E., Franz, D., & Kwiatkowski, D. J. (2010). Ultra deep sequencing detects a low rate of mosaic mutations in tuberous sclerosis complex. *Human Genetics*, 127(5), 573–582. <https://doi.org/10.1007/s00439-010-0801-z>
- Rose, V. M., Au, K. S., Pollom, G., Roach, E. S., Prashner, H. R., & Northrup, H. (1999). Germ-line mosaicism in tuberous sclerosis: How common. *American Journal of Human Genetics*, 64(4), 986–992. <https://doi.org/10.1086/302322>
- Sampson, J. R., Scahill, S. J., Stephenson, J. B., Mann, L., & Connor, J. M. (1989). Genetic aspects of tuberous sclerosis in the west of Scotland. *Journal of Medical Genetics*, 26(1), 28–31. <https://doi.org/10.1136/jmg.26.1.28>
- Tavazoie, S. F., Alvarez, V. A., Ridenour, D. A., Kwiatkowski, D. J., & Sabatini, B. L. (2005). Regulation of neuronal morphology and function by the tumor suppressors Tsc1 and Tsc2. *Nature Neuroscience*, 8(12), 1727–1734. <https://doi.org/10.1038/nn1566>
- Treichel, A. M., Hamieh, L., Nathan, N. R., Tyburczy, M. E., Wang, J. A., Oyerinde, O., Raiciulescu, S., Julien-Williams, P., Jones, A. M., Gopalakrishnan, V., Moss, J., Kwiatkowski, D. J., & Darling, T. N. (2019). Phenotypic distinctions between mosaic forms of tuberous sclerosis complex. *Genetics in Medicine*, 21(11), 2594–2604. <https://doi.org/10.1038/s41436-019-0520-3>
- Tyburczy, M. E., Dies, K. A., Glass, J., Camposano, S., Chekaluk, Y., Thorner, A. R., Lin, L., Krueger, D., Franz, D. N., Thiele, E. A., Sahin, M., & Kwiatkowski, D. J. (2015). Mosaic and intronic mutations in TSC1/TSC2 explain the majority of TSC patients with no mutation identified by conventional testing. *PLoS Genetics*, 11(11), e1005637. <https://doi.org/10.1371/journal.pgen.1005637>
- Uchiyama, Y., Nakashima, M., Watanabe, S., Miyajima, M., Taguri, M., Miyatake, S., Miyake, N., Saitsu, H., Mishima, H., Kinoshita, A., Arai, H., Yoshiura, K., & Matsumoto, N. (2016). Ultra-sensitive droplet digital PCR for detecting a low-prevalence somatic GNAQ mutation in Sturge-Weber syndrome. *Scientific Reports*, 6, 22985. <https://doi.org/10.1038/srep22985>
- Vadlamudi, L., Dibbens, L. M., Lawrence, K. M., Iona, X., McMahon, J. M., Murrell, W., Mackay-Sim, A., Scheffer, I. E., & Berkovic, S. F. (2010). Timing of de novo mutagenesis—A twin study of sodium-channel mutations. *New England Journal of Medicine*, 363(14), 1335–1340. <https://doi.org/10.1056/NEJMoa0910752>
- Verhoef, S., Bakker, L., Tempelaars, A. M., Hesseling-Janssen, A. L., Mazurczak, T., Jozwiak, S., Fois, A., Bartalini, G., Zonnenberg, B. A., van Essen, A. J., Lindhout, D., Halley, D. J., & van den Ouweland, A. M. (1999). High rate of mosaicism in tuberous sclerosis complex. *American Journal of Human Genetics*, 64(6), 1632–1637. <https://doi.org/10.1086/302412>
- Wang, K., Li, M., & Hakonarson, H. (2010). ANNOVAR: Functional annotation of genetic variants from high-throughput sequencing data. *Nucleic Acids Research*, 38(16), e164. <https://doi.org/10.1093/nar/gkq603>
- Ye, Z., McQuillan, L., Poduri, A., Green, T. E., Matsumoto, N., Mefford, H. C., Scheffer, I. E., Berkovic, S. F., & Hildebrand, M. S. (2019). Somatic mutation: The hidden genetics of brain malformations and focal epilepsies. *Epilepsy Research*, 155, 106161. <https://doi.org/10.1016/j.eplepsyres.2019.106161>

## SUPPORTING INFORMATION

Additional supporting information can be found online in the Supporting Information section at the end of this article.

**How to cite this article:** Ye, Z., Lin, S., Zhao, X., Bennett, M. F., Brown, N. J., Wallis, M., Gao, X., Sun, L., Wu, J., Vedururu, R., Witkowski, T., Gardiner, F., Stutterd, C., Duan, J., Mullen, S. A., McGillivray, G., Bodek, S., Valente, G., Reagan, M., ... Hildebrand, M. S. (2022). Mosaicism in tuberous sclerosis complex: Lowering the threshold for clinical reporting. *Human Mutation*, 1–14. <https://doi.org/10.1002/humu.24454>