

**THE USE OF COMPUTED TOMOGRAPHY IN DETERMINING DEVELOPMENTAL CHANGES,
ANOMALIES AND TRAUMA OF THE THYROID CARTILAGE**

Phillip Naimo³, Chris O'Donnell^{1,2}, Richard Bassed^{1,2}, Christopher Briggs^{1,2,3}

¹Victorian Institute of Forensic Medicine, 57-83 Kavanagh Street, Southbank, Victoria 3006

²Department of Forensic Medicine, Monash University, Clayton, Victoria 3168

³Department of Anatomy and Neuroscience, University of Melbourne, Parkville Victoria 3010

Corresponding author:

Associate Professor Christopher Briggs

Department of Anatomy and Neuroscience

University of Melbourne

Parkville, 3010

Email: c.briggs@unimelb.edu.au

Phone: +613 83445776

Abstract

Recognition of injury to the hyoid bone and thyroid and cricoid cartilages is intrinsic to post-mortem examination. Due to its increasing brittleness with age the thyroid cartilage is particularly susceptible to injury following neck trauma, although there is inconsistency in the patterns of injury reported. In this study Computed Tomography (CT) scans of the head and neck of 431 deceased persons (235 males and 196 females) between the ages of 1 day and 100 years (mean age 35.93±24.15), and including 25 victims of hangings, were examined to reveal the pattern of age-related change and the types of injury that occurred. Thyroid cartilage anomalies likely to cause confusion and be misinterpreted as trauma-related are documented. Angulation of the thyroid cartilage horns was found to change with age, and it is suggested this may be a significant factor in traumatic neck injury. Unlike in previous reports, the average age of hanging victims with fractures to the thyroid cartilage was 34 years. The base of the superior horn was the most common fracture site and in 50% of hanging cases was associated with a ligature positioned on the thyrohyoid membrane or thyroid

lamina. Although an age-related relationship exists it was not possible to establish narrow age-prediction ranges from calcification of the thyroid cartilage.

Keywords: thyroid cartilage; calcification; anomalies; thyroid fracture

INTRODUCTION

The thyroid cartilage is the largest of the laryngeal cartilages. It consists of two quadrilateral plates, or laminae, anteriorly, which fuse in the midline to form the distinctive laryngeal prominence. Posteriorly, the laminae fan out and their posterior borders project up and down as superior and inferior horns or cornu [1].

The thyroid cartilage is comprised primarily of hyaline cartilage, which may calcify to a variable degree over several decades, generally commencing from late in the second to early in the third decade [2, 3] but often into old age. Calcification converts a soft pliable structure in the young to a more rigid protective framework in the adult. It generally progresses across the laminae leaving two radiolucent windows (anterior and posterior) which may remain un-calcified [3-6] although calcification commonly proceeds to engulf these areas later in life [3, 4]. Two small anomalous nodules, the triticeous cartilages (*cartilages triticea*) may be found in the free edge of the thyrohyoid membrane, about halfway between the superior horn of the thyroid cartilage and tip of the greater cornu of the hyoid bone. The incidence and significance of these is uncertain.

Cerny [5] reported step-wise calcification of the thyroid cartilage and indicated this may be a useful age indicator in deceased unidentified persons. Garvin [7], however, concluded that although an age-relationship exists it was not possible to establish narrow age-prediction ranges. To date, only one other study has used Computed Tomography (CT) imaging to assess calcification of the thyroid cartilage and it comprised a volume analysis of 312 cartilages using three dimensional reconstructions. The authors reported they could find no relationship between calcification and age [8].

Assessment of laryngeal cartilages including the thyroid is intrinsic to post-mortem forensic examination. Due to increasing brittleness with age they are increasingly susceptible to injury, including fracture, in traffic accidents, falls, in assaults involving blunt force trauma to the head and neck, and during hanging and manual strangulation [9-11].

In the present study age-related calcification of the thyroid cartilage was determined from CT images of deceased individuals admitted for autopsy to the Victorian Institute of Forensic Medicine (VIFM), Melbourne, Australia. In addition, geometric features including angulation of its horns and common variants were assessed. Access to such a database enabled the inclusion of a relatively large sample of children and adolescents to assess the minimum age of commencement of calcification and patterns of development. In addition, thyroid cartilages from 25 victims of hanging were analyzed to determine sites typical of traumatic injury. Ethical approval to conduct this study was provided by the Victorian Institute of Forensic Medicine.

METHODS

CT scans of 431 deceased persons (235 males and 196 females, including 25 victims of hangings) between the ages of 1 day and 100 years (mean age 35.93 ± 24.15) who were admitted for autopsy to the VIFM between 01/01/2006 and 01/09/2010 were examined. All deceased had whole body CT scans performed as a routine part of the initial forensic examination. Images were obtained using a 16 channel MDCT scanner (Aquilion16[®], Toshiba Medical Systems, Minato-ku, Tokyo, Japan) based at the VIFM. Raw data acquisition consisted of helical 0.5mm slices using 120kVp and 300mA exposure factors which were reconstructed into 1.0mm slices with 0.2mm overlap. Two convolutional kernels (reconstruction algorithms) were applied to the overlapping data set. The first was specifically designed to show soft tissues but also allows for maximum clarity in volume rendered three dimensional reconstructed images. The second was an edge enhancement (bone) algorithm that allows for maximum resolution in two dimensional multi-planar reformation, producing views of the thyroid in axial, coronal and sagittal planes.

To aid detailed assessment of calcification patterns the thyroid cartilage was subdivided into sub-sections according to Garvin [7] (Fig. 1). The laryngeal prominence is referred to as the medial branch, cartilage above and below the laminae as cranial and caudal branches; the superior and inferior horns are connected by the posterior branch, the root of which is termed the posterior triangle. A midline 'tongue' separates the two laminae. Degree of calcification was determined from the three dimensional reconstruction images and a scoring system of 0 (no calcification) and 1 (calcification present) was applied to each sub-section.

Measurements recorded as to side (Table 1) were obtained using a "bone" algorithm two-dimensional image that was manipulated with oblique multi-planar reformation (MPR) and a Ray Sum algorithm of 4 x slice (i.e. 3.2mm) to reduce image noise. The axes of the nominal axial, coronal

and sagittal images were adjusted until the thyroid cartilage was viewed in the anatomical plane prior to measurements being taken (Fig. 2). Images were then viewed and measurements obtained using an AquariusNet (AqNet) (TeraRecon Inc, San Mateo, California, USA) thin client workstation. A number of proprietary template algorithms present on AqNet enabled specific structures to be viewed in the three dimensional reconstructions. In addition, any anomalies were documented.

The angle subtended by the laminae was obtained from the axial CT image using the “angle” measurement tool on AqNet. The angles of the superior and inferior horns were measured relative to the posterior branch. To view the image correctly, the axes of the nominal axial image were aligned so that the vertical axis ran through the thyroid laminae (Fig. 2a). The axes were then rotated so that the horizontal axis transected the superior and inferior horns (Fig. 2b). The axes were then rotated so that the vertical axis ran through both the inferior and superior horns and angle measurements subsequently taken (Fig. 3a & b).

Data was compiled according to sex into pre-determined age groups: infants (0–2 years), n=32; children (3–12 years), n=42; adolescents (13–18 years), n=31; young adults (19–24 years), n=39; adults (25–65 years), n=206; elderly (66+ years), n=56, and analysed using ANOVA and unpaired Student’s t-test as appropriate (Minitab 16.1.1, Minitab Inc., State College, PA, USA). ANOVA were followed by Tukey’s post-hoc range test. Significance was set at $p < 0.05$.

RESULTS

Calcification

Of 431 cartilages examined 335 had commenced calcification. In males, the process started postero-inferiorly in the posterior triangle or adjacent inferior horn at the beginning of the 3rd decade, spreading to the superior horn, caudal branch, and medial branch (laryngeal prominence) before terminating in the cranial branch early in the 6th decade (Table 2). Anterior and posterior windows were observed in the laminae of only 37 individuals (30 males and 7 females, average ages 51 and 55 years respectively).

Calcification in the laminae commenced towards the end of the 2nd decade and was completed, including in both anterior and posterior windows, by the middle of the 6th decade (Table 3). There were significant age-related differences. In females onset of calcification was not apparent in some parts of the laminae until the end of the fifth or beginning of the sixth decade and tended to occur at the same time except in the antero-superior and antero-inferior parts.

Angulation of thyroid horns

Angulation between the superior horn and posterior branch decreased with age, although this was significant only on the right side.

Projection of the superior horn medially was determined from the coronal view (Fig. 4). Analogous to the previous measurement, there were no significant sex differences; however there was an age group difference between children, young adults and adults compared to the elderly on the left side, as well as between young adults and adults compared to the elderly on the right (Fig. 5).

Angulation between inferior horn and posterior branch was significantly different between male and female adults however there were no age group differences within each sex. Sex differences were observed in both left and right inferior horns in adult males and females ($p=0.005$, $p=0.004$ respectively) and the left inferior horns of elderly males and females ($p=0.002$). The mean angulation of the left inferior horn was $179.44\pm 10.58^\circ$ and $174.88\pm 10.86^\circ$ while the right inferior horn was $176.40\pm 12.16^\circ$ and $181.49\pm 11.10^\circ$ for female and male adults respectively (Fig. 6).

Anomalies

A number of anomalous thyroid cartilages were observed (Table 4 and Figs. 7-9). Triticeous cartilages were present in 102 of 431 thyroid cartilages (23.6%). Other anomalies included absent superior horns, superior horns in two or more parts, connections of superior horn to the greater cornu of the hyoid bone, joint spaces between lamina and superior horn as well as accessory horns. Of these anomalies, 61 were bilateral, 14 were only on the left and 27 only on the right. Many of the unilateral cartilages had the opposing superior horn much longer than the triticeous horn.

Cases of hanging

Twenty five of the deceased were reported to the Coroner as hanging victims. Eight of these had sustained trauma to the superior horn, five being bilateral (Fig. 10), and one to the inferior horn. Two individuals also presented with combined fracture of the hyoid bone and thyroid cartilage, the latter approximately 3cm inferior to the lamina; which, along with the trachea, was detached from the remainder of the larynx (Fig. 11).

The site of a ligature, if visible, was also recorded, with four being below the thyroid cartilage, two on the thyroid lamina, eight on the thyrohyoid membrane and one on the body of the hyoid. In 11 individuals the ligature site was either not visible or not recorded. In the combined hyoid and thyroid cartilage fracture the ligature was also on the thyrohyoid membrane. Of the eight superior horn fractures, four had ligatures either on the thyrohyoid membrane or the thyroid laminae while in the remaining four the ligature sites were not visible. The single inferior horn fracture had the ligature located below the thyroid laminae, directly on the inferior horns.

Metric traits were also assessed for victims of hanging. All thyroid angle measurements were significantly different among hanging victims compared to those that had not sustained trauma ($p < 0.05$). The mean angle of the left superior horn to the posterior branch was 180.85 ± 23.34 degrees in trauma victims compared to 160.47 ± 13.25 degrees in the normal CT sample. The right superior horn had a mean angle of 171.02 ± 22.11 degrees in trauma victims compared to 160.05 ± 13.25 degrees in the CT sample. The inferior horns showed similar variation with a mean angle of 183.93 ± 9.88 degrees and 183.03 ± 9.23 degrees in hanging victims and 176.75 ± 10.34 degrees and 178.15 ± 10.95 degrees for left and right inferior horns respectively. The medial deviation of the superior horns was greater for non-trauma individuals compared to trauma ($p < 0.05$). The left superior horn had a mean medial deviation angle of 25.44 ± 8.76 degrees and 19.51 ± 11.33 degrees for non-trauma and trauma respectively, while the right superior horn had mean deviation angles of 24.92 ± 8.27 degrees and 19.51 ± 14.79 degrees, respectively.

DISCUSSION

Previous data on age- and sex-related development of the thyroid cartilage is limited due to insufficient sample sizes and variability of imaging techniques. The present study is unique in that assessment of calcification patterns, angulations of superior and inferior horns as well as common variants has been assessed from infancy to old age.

Calcification

The posterior triangle was the first part of the thyroid cartilage to calcify, the process then continuing upwards along the posterior branch. Garvin [7] indicated that the posterior branch and inferior horns had completely calcified by 37 years of age, a finding not supported in the present study in which several individuals over 40 years (and some above 75 years) lacked calcification of the entire posterior branch. The developmental pattern of the remainder of the thyroid cartilage was quite variable. While the posterior triangle, inferior horns and part of the posterior branch generally

calcified before other sections, and the superior horns and caudal branch were calcified prior to the laminae, calcification of subsequent sections was variable and did not follow a step-wise pattern. In females each section of cartilage had a mean minimum commencement age and completion that was significantly later than in males ($p < 0.05$).

Geometry

No previous study has taken into account angulation of the superior horns of the thyroid cartilage and their relationship to fracture and it is believed this may be a relevant factor in neck trauma. Angulation of the superior horn to the posterior branch decreased with age while the inferior horn in males protruded significantly more anteriorly than in females. Trauma resulting in fracture to the superior horn generally caused its angle to the posterior branch to become exaggerated. In contrast, the medial deviation angle of the superior horn to the posterior branch became smaller; possibly due to the proximal end of the superior horn being forced medially by pressure from, for example, a ligature, while the distal segment remained fixed in the thyrohyoid membrane.

Triticeous cartilage

Early in development the body of the hyoid bone and superior horns of the thyroid cartilage are linked by an expansion from the thyrohyoid membrane [12, 13]. This connection usually disappears during development as the hyoid and thyroid cartilage move apart, but may remain as a complete connection or an island of cartilage embedded in the thyrohyoid membrane, and is referred to as the *triticeous cartilage* [6, 12]. Presence of the triticeous cartilage may have forensic significance. Owing to its close proximity to the upper margin of the superior horn of the thyroid cartilage there is a likelihood it may be confused with a fracture. Triticeous cartilages were noted in 102 CT scans (23.2%), 61 were bilateral, a finding similar to previous studies [6, 13, 14]. Interestingly, when a triticeous cartilage presented unilaterally, the contralateral superior horn was elongated, suggesting that the developing triticeous cartilage on the elongated superior horn had not detached [12].

Sex and age determination

There were clear differences in calcification patterns between males and females. The mean minimum age at which calcification commenced as well as when each section was completed was later in females than in males. In some females calcification did not occur at all in several areas, in particular the anterior sections of the laminae as well as in the caudal and cranial branches. This variability has also been reported in previous studies [2, 6-8, 15, 18, 19].

Variability in the pattern of calcification shown in this study poses a problem in determining the age of individuals based on the thyroid cartilage alone. Although previous studies [5, 15-17] suggested a direct relationship between age and calcification of specific sections, more recent work [7, 8] disputes this finding. In the present study there was statistical significance between the minimum ages when each section commenced calcification; however inter-individual variability was too large to support a direct correlation with age.

Neck trauma and injury to related structures.

Thyroid cartilage fracture is a relatively common feature among victims of neck trauma [9-11, 20-25]. In a recent report of 1930 adult post-mortem examinations over a five year period, Dunsby and Davison [25] found 78 fractures of the larynx, with the thyroid cartilage alone being involved in 38 cases. Of the 25 cases of hanging reviewed in this study, there was injury to the thyroid cartilage in 32% (8/25). Pollanen [26] suggested the most common fracture site was at the base of the superior horn. In this study fracture at the base of the superior horn was observed in five of eight cases while in the remainder it was found approximately one third to one half the distance along its length and commonly resulted in discontinuity between it and the posterior branch. In one case there was fracture of the inferior horn. While it has been reported that fracture of the thyroid cartilage is more likely in older victims due to advanced calcification [10, 26] the average age of all hanging victims in this study was 27.12 ± 10.08 years and the average age of those with fractures was 34.11 ± 8.64 years.

KEY POINTS

1. This study utilized CT images which provide a more accurate measurement tool than has been used in previous studies, which, in the majority of cases was plane film radiography.
2. The geometry of superior and inferior horns of the thyroid cartilage may be a significant diagnostic factor in traumatic neck injury.
3. The prevalence of thyroid cartilage anomalies may cause confusion and be misinterpreted as trauma-related. The triticeous cartilage, often referred to as an anomaly, is commonly incorporated into the superior horn and when present may be mistaken for fracture of the superior horn.
4. The average age of hanging victims with fractures to the thyroid cartilage was 34 years, in contrast to previous reports indicating fracture occurs primarily in older individuals.
5. The base of the superior horn was the most common fracture site, and in 50% of these cases was associated with a ligature positioned on the thyrohyoid membrane or thyroid laminae.

REFERENCES

1. Standring S. *Gray's Anatomy: The Anatomical Basis of Clinical Practice*. 40th ed. London: Churchill Livingstone Elsevier; 2008.
2. Mupparapu M, Vuppalapati A. Ossification of laryngeal cartilages on lateral cephalometric radiographs. *Acta Orthod*. 2005;75:196–201.
3. Jurik AG. Ossification and calcification of the laryngeal skeleton. *Acta Radiol Diag*. 1984;25(1):17–22.
4. Paulsen F, Kimpel M, Lockemann U, Tillmann B. Effects of ageing on the insertion zones of the human vocal fold. *J Anat*. 2000;196:41–54.
5. Cerny M. Our experience with estimation of an individual's age from skeletal remains of the degree of thyroid cartilage ossification. *Acta Univ Palacki Olomuc*. 1983;3:121–44.
6. Hatley W, Evison G, Samuel E. The pattern of ossification in the laryngeal cartilages: a radiological study. *Brit J Radiol*. 1965;38:585–91.
7. Garvin HM. Ossification of laryngeal structures as indicators of age. *J Forensic Sci*. 2008;53(5):1023–27.
8. Dang-Tran KD, Dedouit F, Joffre F, Rouge D, Rousseau H, Telmon N. Thyroid cartilage ossification and multi-slice computed tomography examination: a useful tool for age assessment? *J Forensic Sci*. 2010;55(3):677–83.
9. Naik SK, Patil DY. Fracture of hyoid bone in cases of asphyxial deaths resulting from constricting force round the neck. *J Indian Academy Forensic Med*. 2005;27(3):149–53.
10. Nikolic S, Micic J, Atanasijevic T, Djokic V, Djonic D, Analysis of neck injuries in hanging. *Am J Forensic Med Pathol*. 2003;24(2):179–82.
11. Khokhlov VD. Injuries to the hyoid bone and laryngeal cartilages: effectiveness of different methods of medico-legal investigation. *Forensic Sci Int*. 1997;88:173-83.
12. Grossman JW. The triticeous cartilages. *Am J Roent Radium Ther*. 1945;53(2):166–70.
13. Ahmad M, Madden R, Perez L. Triticeous cartilage: prevalence on panoramic radiographs and diagnostic criteria. *Oral Surg Oral Pathol Oral Radiol Endod*. 2005;99:225–30.
14. Di Nunno N, Lombardo S, Castantinides F, Di Nunno C. Anomalies and alterations of the hyoid-larynx complex in forensic radiographic studies. *Am J For Med Pathol*. 2004;25:14-19.
15. Turk LM, Hogg DA. Age changes in the human laryngeal cartilages. *Clin Anat*. 1993;6(3):54–62.

16. Sugiyama S, Tatsumi S, Noda H, Yamaguchi M, Furutani A, Yoshimura M. Estimation of age from image processing of soft X-ray findings in Japanese male thyroid cartilages. *Nihon Hoigaku Zasshi*. 1995;49(4):231–35.
17. De la Grandmaison GL, Banasr A, Durigon M. Age estimation using radiographic analysis of laryngeal cartilage. *Am J For Med Pathol*. 2003;24(1):96–99.
18. Mupparapu M, Vuppalapati A. Detection of an early ossification of thyroid cartilage in an adolescent on a lateral cephalometric radiograph. *Acta Orthod*. 2002;72:576–78.
19. Yeager VL, Lawson C, Archer CR. Ossification of the laryngeal cartilages as it relates to computed tomography. *Invest Radiol*. 1982;17(1):11–19.
20. Di Maio VJ. Homicidal asphyxia. *Am J For Med Pathol*. 2000;21(1):1–4.
21. Green H, James RA, Gilbert JD, Byard RW. Fractures of the hyoid bone and laryngeal cartilages in suicidal hangings. *J Clin For Med*. 2000;7:123–26.
22. Ubelaker DH. Hyoid fracture and strangulation. *J For Sci*. 1992;37(5):1216–22.
23. Luke JL. Asphyxial deaths by hanging in New York City. *J For Sci*. 1967;3:359–69.
24. Simonsen J. Patho-anatomic findings in neck structures in asphyxiation due to hanging: a survey of 80 cases. *For Sci Int*. 1988;38:83–91.
25. Dunsby AM, Davision AM. Causes of laryngeal cartilage and hyoid bone fractures found at post-mortem. *Med Sci Law*. 2011;51(2):109-13.
26. Pollanen MS. Subtle fatal manual neck compression. *Med Sci Law*. 2001;41(2):135–40.

Table 1 Measurements of thyroid cartilage

Height and width of 'anterior window'
Height and width of 'posterior window'
Angle of superior horn to posterior branch measured in sagittal plane
Angle of inferior horn to posterior branch measured in sagittal plane
Angle of superior horn to posterior branch measured in coronal plane through their centres

Table 2 Minimum mean ages of calcification of specific sections of the thyroid cartilage

Section of	MALE	FEMALE

thyroid cartilage	Total number that presented with calcification	Mean minimum age of calcification	Standard deviation of mean age	Total number that presented with calcification	Mean minimum age of calcification	Standard deviation of mean age
Posterior Triangle	11	21.18	3.80	6	19.5	3.28
Inferior horn	21	20.19 [#]	2.86	23	22.57 [#]	4.44
Caudal branch	89	25.44 ^{*#}	6.71	178	44.31 ^{*#}	17.43
Superior horn	31	31.03 ^{*#}	14.11	67	37.60 ^{*#}	13.80
Medial branch	57	46.12 ^{*#}	18.32	62	60.56 ^{*#}	18.79
Cranial branch	138	52.41 ^{*#}	19.48	110	61.99 ^{*#}	20.83

*Significantly different from preceding section within the same sex. P<0.05, unpaired Student's t-test.

Significantly different from the same section of the opposite sex. P<0.05, unpaired Student's t-test.

Table 3 Mean age of calcification sections of left and right lamina of males and females

Variable		MALE				FEMALE			
		Total number that presented with calcification	Minimum age of calcification	Mean age of calcification	Standard deviation of mean age	Total number that presented with calcification	Minimum age of calcification	Mean age of calcification	Standard deviation of mean age
Left	PI	76	16	51.64	20.43	66	28	61.80	17.36
	PS	28	24	54.11	21.63	43	28	62.79	17.92
	MI	81	19	54.14	19.96	47	28	66.60	17.78
	MS	55	19	50.84	18.59	31	28	67.10	19.83
	AI	54	19	56.24	19.53	15	48	66.73	17.04
	AS	51	19	54.61	19.09	11	48	61.82	13.28
Right	PI	77	16	52.49	20.57	66	28	61.80	17.36
	PS	28	24	54.75	21.49	45	28	62.20	17.73
	MI	82	19	53.21	19.30	45	28	66.64	18.01

	MS	53	19	51.74	19.06	30	28	66.17	19.47
	AI	55	19	55.53	19.98	15	48	67.47	18.04
	AS	51	19	55.25	17.69	12	48	62.92	13.22

Sections of laminae are as follows, PI = posterior inferior; PS = posterior superior; MI = middle inferior; MS = middle superior; AI = anterior inferior; AS = anterior superior.

Table 4 Anomalies of thyroid cartilage

Anomaly	Left	Right	Bilateral	Total
Triticeous cartilage	14	27	61	102 (29.5%)
Triticeous cartilage with elongated superior horn	11	18	-	29 (8.4%)
Absent superior horn	3	5	1	9 (2.6%)
Superior horn in more than 2 parts	19	10	4	33 (9.5%)
Superior horn connected to greater cornua	-	-	2	2 (0.6%)
Joint between superior horn and lamina	1	3		4 (1.2%)
Accessory horn	-	-	1	1 (0.3%)

Fig. 1 Individual sections of thyroid cartilage scored for calcification. A = anterior I = inferior; Lat = lateral; M = Middle; Med = medial; P = posterior; S = superior (image authors own).

Fig. 2a Showing adjustment of nominal axial image prior to measurement. **Fig 2b** Angle subtended by thyroid laminae.

Fig. 3a Sagittal image showing the angle between the superior horn and posterior branch. **Fig. 3b** Sagittal image showing the angle between the inferior horn and posterior branch.

Fig. 4 Angulation of the left (black) and right (red) superior horn to the posterior branch (viewed laterally). Age groups: 2=children; 3=adolescents; 4=young adults; 5=adults; 6=elderly. *Significant difference from all other age groups within the same sex. $P < 0.05$, unpaired Student's t-test. $N = 17, 29; 39; 181; \text{ and } 53$ for each group respectively.

Fig. 5 Age groups vs. angle of medial deviation made by the left (black) and right (red) superior horn with the posterior branch (coronal view). Age groups as per Fig. 2. *Significantly different from all other age groups within the same sex. $P < 0.05$, unpaired Student's t-test. $N = 17, 29; 39; 181; \text{ and } 53$ for each group respectively.

Fig. 6 - Triticeous cartilage (arrow)

Fig. 7 - Connection of greater cornu of hyoid to superior horn of thyroid.

Fig. 8 - Accessory horns

Fig. 9 - Bilateral fracture of the superior horn

Fig. 10 - Fracture of the inferior horn and laryngo-tracheal separation following hanging: the inferior horn, cricoid cartilage and part of the trachea have detached from the thyroid.

Fig. 11 – Fracture of inferior horn (arrow), repositioned below the remainder of the thyroid cartilage.

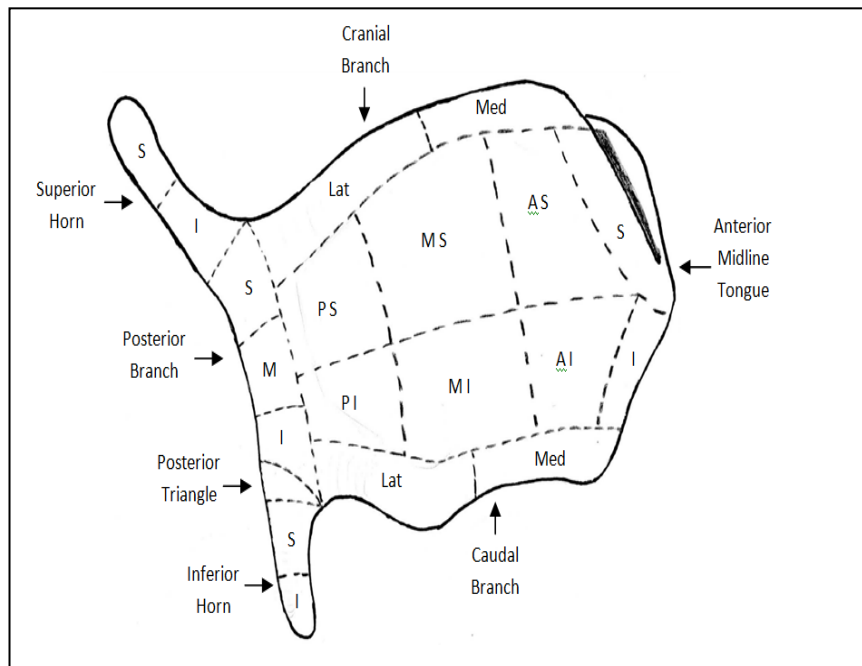


Fig 1 - Individual sections of thyroid cartilage scored for calcification. A = anterior I = inferior; Lat = lateral; M = Middle; Med = medial; P = posterior; S = superior (image author own).

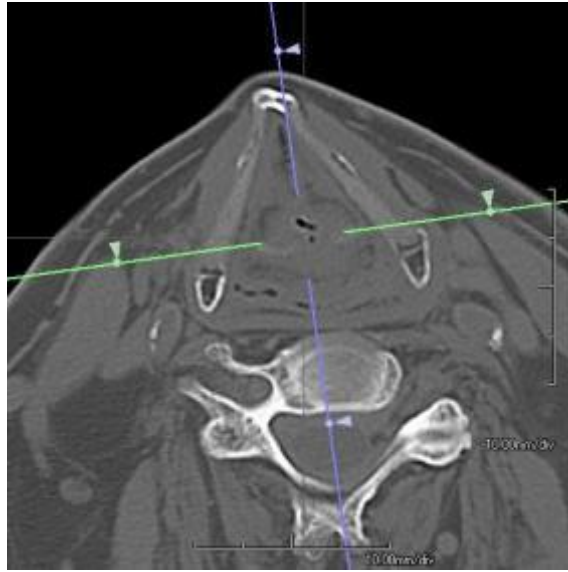

Fig 2A - Showing adjustment of nominal axial image prior to measurement

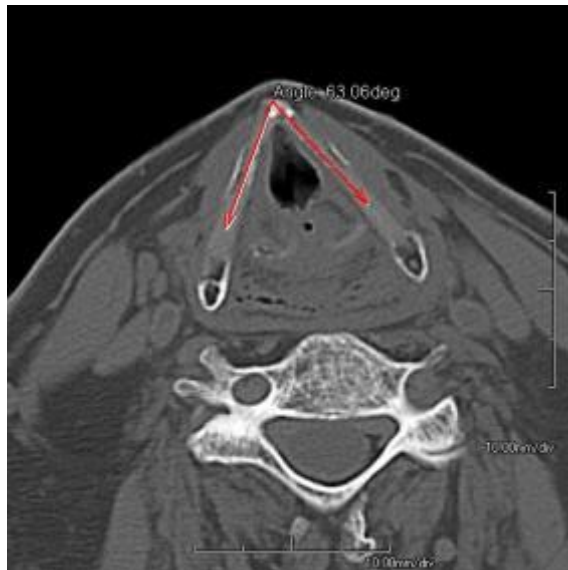

Fig 2B – Angle subtended by thyroid laminae

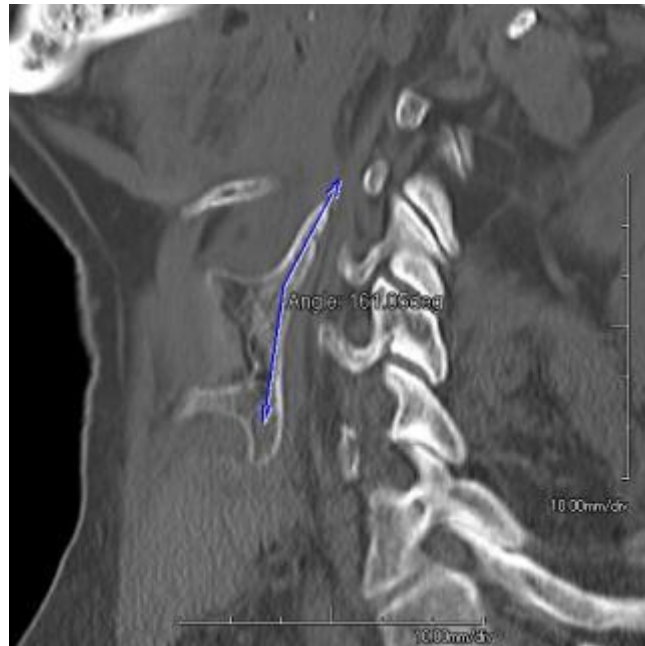

Fig 3A – Sagittal image showing angle between superior horn and posterior branch.

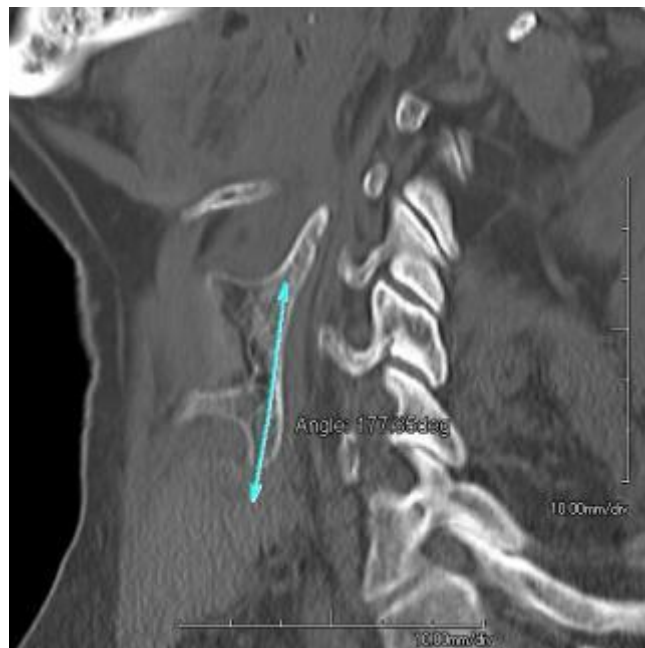

Fig 3B – Sagittal image showing angle between inferior horn and posterior branch.

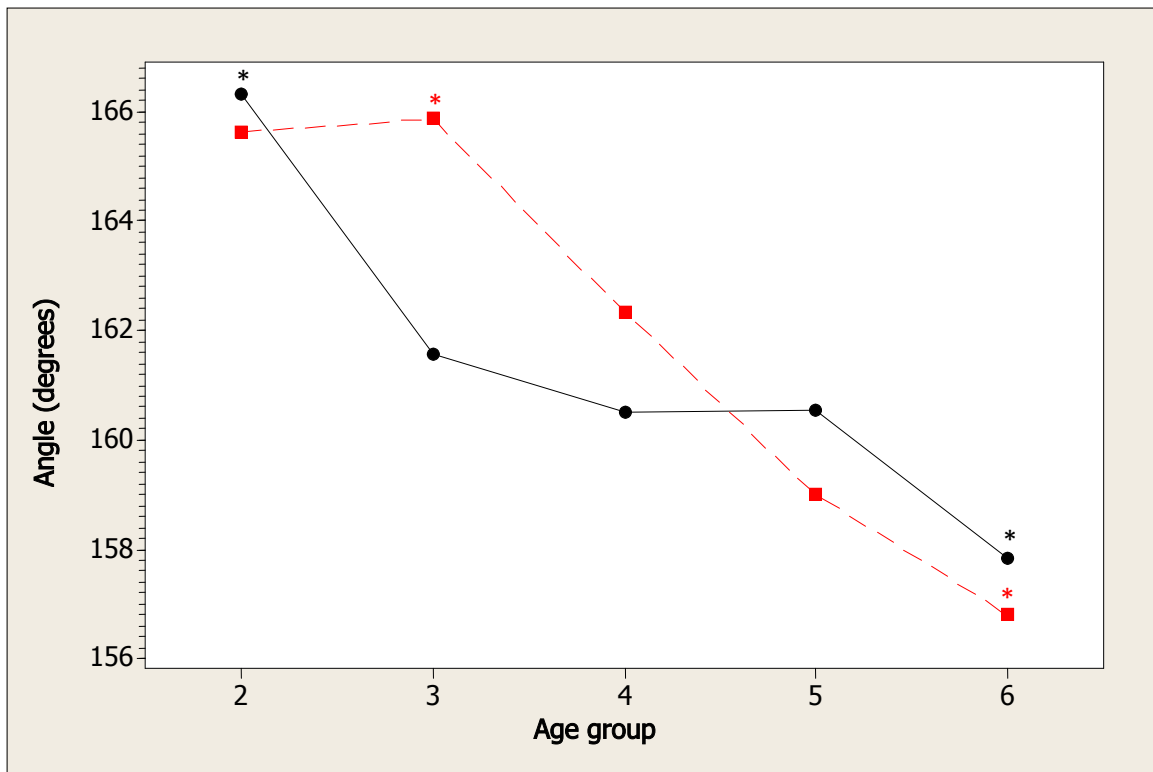


Fig 4 - Angulation of the left (black) and right (red) superior horn to the posterior branch (viewed from laterally)

Age groups: 2 = children; 3 = adolescents; 4 = young adults; 5 = adults; 6 = elderly.

*Significant difference from all other age groups within the same sex. $P < 0.05$, unpaired Student's t-test. N = 17, 29; 39; 181; and 53 for each group respectively.

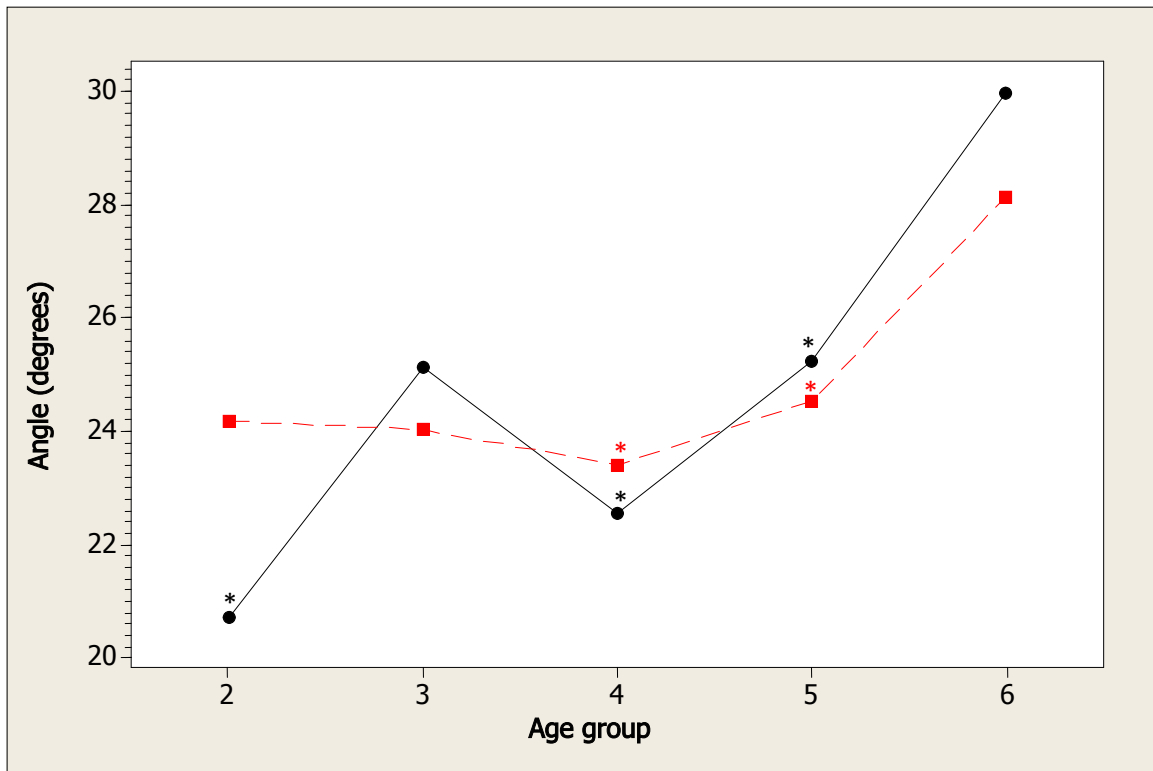


Fig 5 - Age groups vs. angle of medial deviation made by the left (black) and right (red) superior horn with the posterior branch (coronal view). Age groups as per Figure 2

* Significantly different from all other age groups within the same sex. $P < 0.05$, unpaired Student's t-test. $N = 17, 29; 39; 181; \text{ and } 53$ for each group respectively.

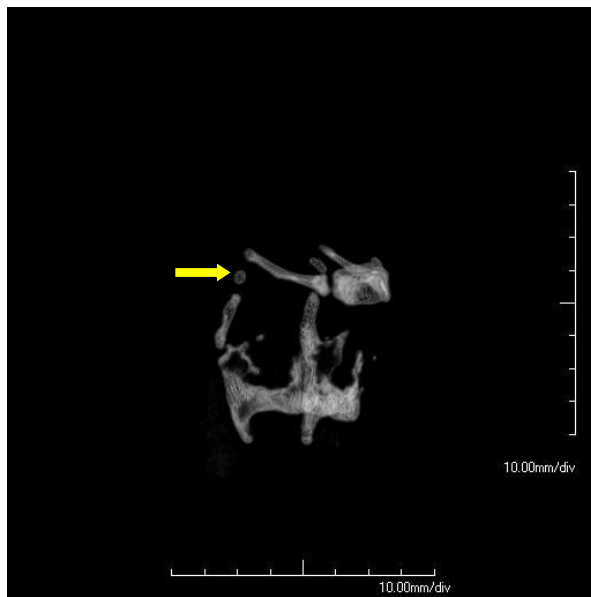


Fig 6 - Triticeous cartilage (arrow)

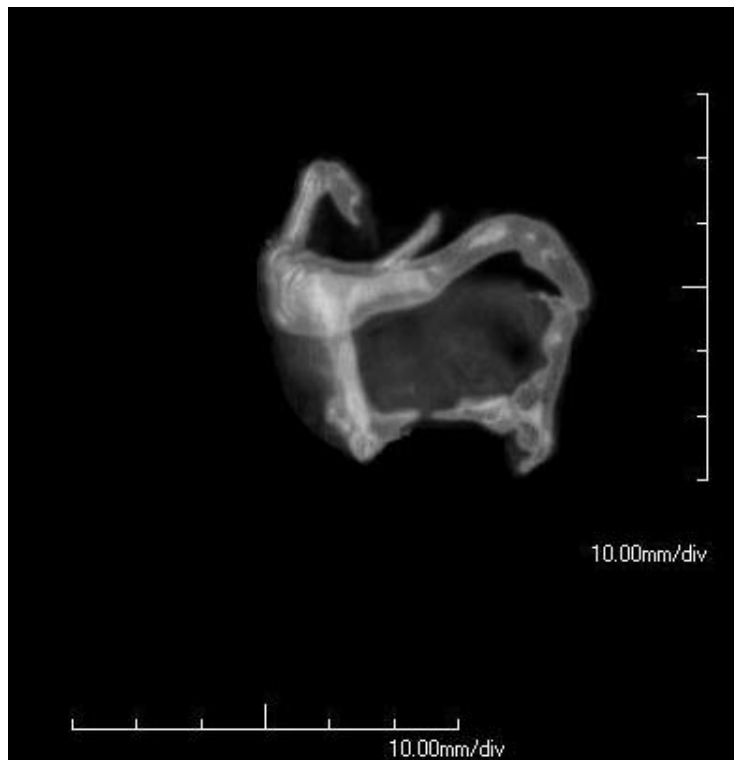

Fig 7 - Connection of greater cornu of hyoid to superior horn of thyroid.

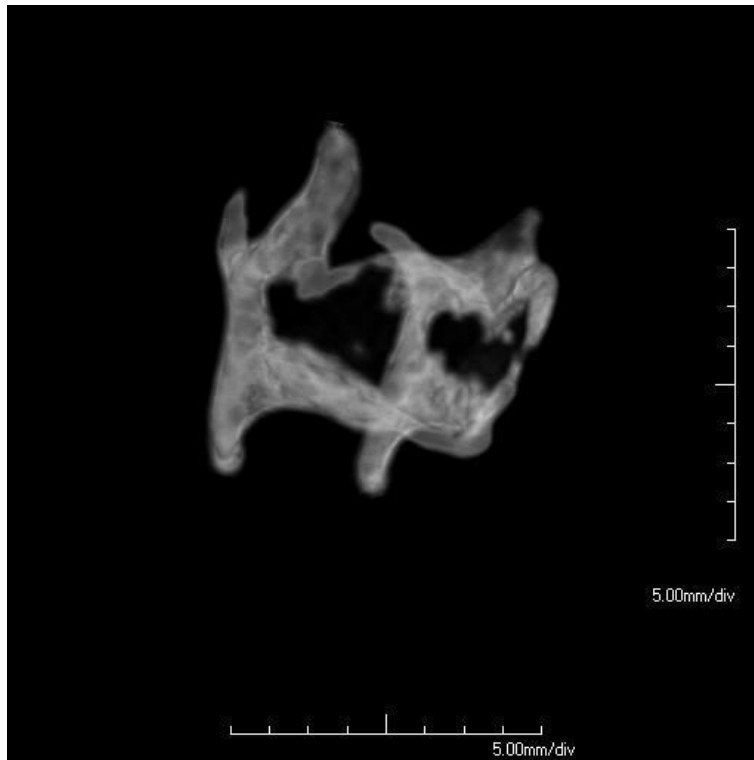


Fig 8 - Accessory horns

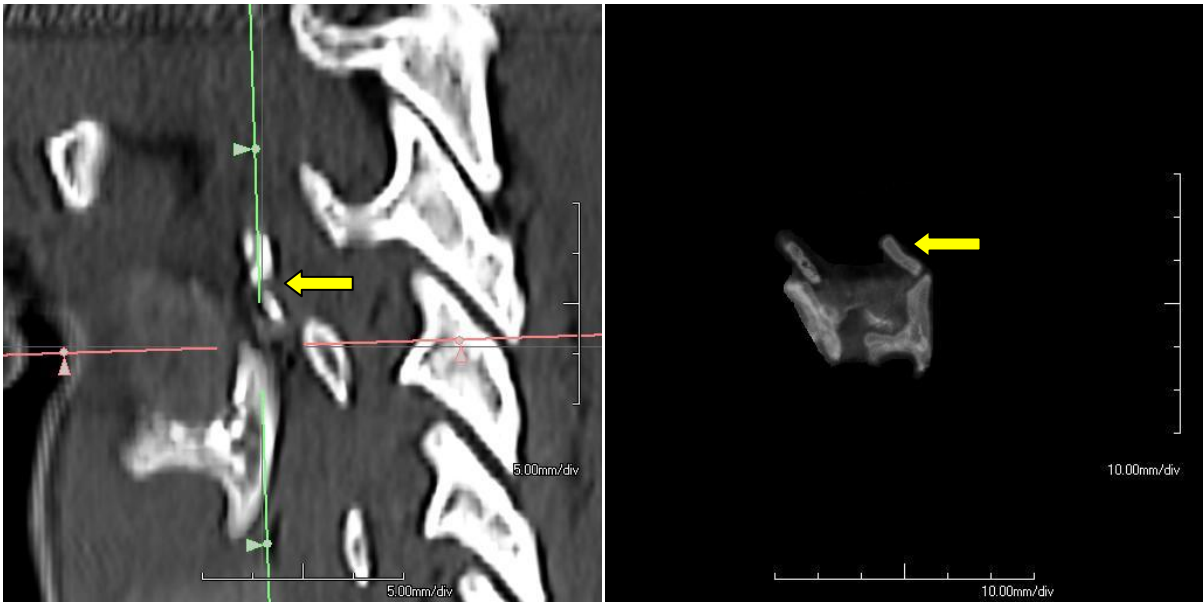

Fig 9 - Bilateral fracture of superior horn

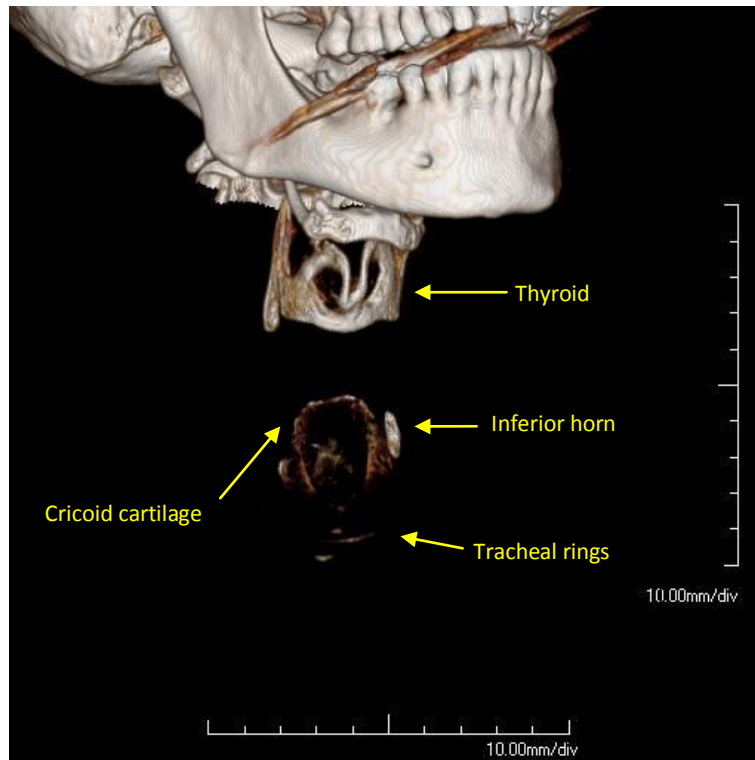


Fig 10 - Fracture of the inferior horn and laryngo-tracheal separation following hanging: inferior horn, cricoid cartilage and part of the trachea have detached from the thyroid.

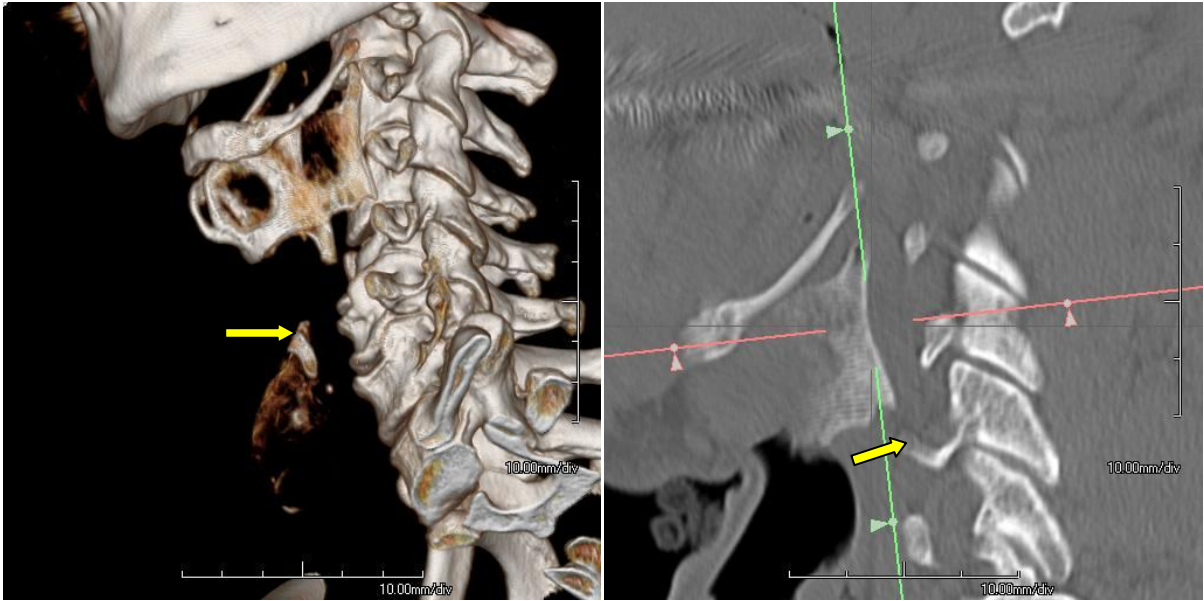


Fig 11 – Fracture of inferior horn (arrow), repositioned below the remainder of the thyroid cartilage