



Minerva Access is the Institutional Repository of The University of Melbourne

Author/s:

Kowalczyk, MA;Omidvarnia, A;Abbott, DF;Tailby, C;Vaughan, DN;Jackson, GD

Title:

Clinical benefit of presurgical EEG-fMRI in difficult-to-localize focal epilepsy: A single-institution retrospective review

Date:

2020-01-01

Citation:

Kowalczyk, M. A., Omidvarnia, A., Abbott, D. F., Tailby, C., Vaughan, D. N. & Jackson, G. D. (2020). Clinical benefit of presurgical EEG-fMRI in difficult-to-localize focal epilepsy: A single-institution retrospective review. *Epilepsia*, 61 (1), pp.49-60. <https://doi.org/10.1111/epi.16399>.

Persistent Link:

<https://hdl.handle.net/11343/286705>

MS. MAGDALENA KOWALCZYK (Orcid ID : 0000-0002-5410-0299)

DR. DAVID F ABBOTT (Orcid ID : 0000-0002-7259-8238)

Article type : Full length original research paper

Clinical benefit of presurgical EEG-fMRI in difficult-to-localize focal epilepsy: a single institution retrospective review

Magdalena A. Kowalczyk^{1,2}, Amir Omidvarnia^{1,2}, David F. Abbott^{1,2}, Chris Tailby¹,
David N. Vaughan^{1,3}, Graeme D. Jackson^{1,2,3#}

Affiliations:

1. The Florey Institute of Neuroscience and Mental Health, Austin Campus, Heidelberg, VIC, Australia
2. The Florey Department of Neuroscience and Mental Health, Faculty of Medicine, Dentistry and Health Sciences, University of Melbourne, Parkville, VIC, Australia.
3. Department of Neurology, Austin Health, Heidelberg, VIC, Australia

Corresponding author: Address: The Florey Institute of Neuroscience and Mental Health, Austin Campus, 245 Burgundy Street, Heidelberg 3084, VIC, Australia. Telephone number: +61 3 90357000, Fax number: +61 3 90355459. E-mail address: graeme.jackson@florey.edu.au.

This is the author manuscript accepted for publication and has undergone full peer review but has not been through the copyediting, typesetting, pagination and proofreading process, which may lead to differences between this version and the [Version of Record](#). Please cite this article as [doi: 10.1111/EPL.16399](https://doi.org/10.1111/EPL.16399)

This article is protected by copyright. All rights reserved

E-mail addresses: magdalena.kowalczyk@florey.edu.au (M.A. Kowalczyk), amir.omidvarnia@florey.edu.au (A. Omidvarnia), david.abbott@florey.edu.au (D.F. Abbott), chris.tailby@florey.edu.au (C. Tailby), david.vaughan@florey.edu.au (D.N. Vaughan), graeme.jackson@florey.edu.au (G.D. Jackson)

Keywords: EEG, fMRI, focal epilepsy, epilepsy surgery

Number of pages: 23

Number of words body of manuscript (limit 4000 words): 4000

Number of words in Summary (limit 300 words): 299

Number of words in Introduction (limit 600 words): 343

Number of words in Discussion (limit 1200 words): 1075

Number of references (limit 50): 48

Number of figures: 2

Number of tables: 4

Number of supplementary figures/tables: 3

Summary

Objective: The aim of this report is to present our clinical experience of EEG-fMRI in localising the epileptogenic focus, and to evaluate the clinical impact and challenges associated with the use of EEG-fMRI in pharmacoresistant focal epilepsy.

Methods: We identified EEG-fMRI studies (n=118) in people with focal epilepsy performed at our centre from 2003 to 2018. Participants were referred from our Comprehensive Epilepsy Program in an exploratory research effort to address often difficult clinical questions, due to complex and difficult-to-localise epilepsy. We assessed the success of each study, the clinical utility of the result, and when surgery was performed the postoperative outcome.

Results: Overall, 50% of EEG-fMRI studies were successful, meaning that data was of good quality and interictal epileptiform discharges were recorded. With an altered recruitment strategy since 2012 with increased inclusion of patients who were inpatients for video-EEG monitoring, we found that this selected inpatient group were more likely to have epileptic discharges detected during EEG-fMRI (96% of inpatients vs 29% of outpatients, $p < 0.0001$). To date, 48% (57 of 118) of patients have undergone epilepsy surgery. In 10 cases (17% of the 59 successful studies) the EEG-fMRI result had a 'critical impact' on the surgical

decision. These patients were difficult-to-localize because of subtle abnormalities, apparently normal MRI, or extensive structural abnormalities. All ten had a good seizure outcome at one year after surgery (mean follow-up 6.5 years).

Significance: EEG-fMRI results can assist identification of the epileptogenic focus in otherwise difficult-to-localise cases of pharmacoresistant focal epilepsy. Surgery determined largely by localisation from the EEG-fMRI result can lead to good seizure outcomes. A limitation of this study is its retrospective design with non-consecutive recruitment. Prospective clinical trials with well-defined inclusion criteria are needed to determine the overall benefit of EEG-fMRI for preoperative localisation and postoperative outcome in focal epilepsy.

Keywords: EEG, fMRI, focal epilepsy, epilepsy surgery

Key Points:

- 50% of our EEG-fMRI studies were successful, meaning that data was of good quality and interictal epileptiform discharges were detected.
- Interictal epileptiform discharges were more often seen during EEG-fMRI when performed as a hospital inpatient than outpatient ($p < 0.0001$).
- EEG-fMRI result critically influenced the decision to offer surgery in patients with subtle abnormalities, normal MRI or extensive multi-lobar abnormalities.
- EEG-fMRI is feasible in a tertiary hospital clinical environment and can aid surgical planning in complex epilepsy cases.
- Prospective, well-controlled clinical trials are needed to determine the benefit of EEG-fMRI in the pre-surgical assessment of epilepsy.

1 Introduction

The best hope for improvement in pharmacoresistant focal epilepsy is surgical removal of the brain region responsible for the epileptogenic onset. Seizure freedom is achieved for between 34% and 74% of patients selected for surgical procedures.¹ However, even with current best clinical practice, a majority (72%) of patients referred for pre-surgical evaluation are not able to proceed to surgery.² One of the main reasons for the failure to offer surgical treatment is because the epileptogenic zone cannot be adequately localised.³

Simultaneous EEG-fMRI is a highly specialised technique, where EEG recording is used to detect the times at which interictal epileptiform discharges (IEDs) occur and functional MRI

(fMRI) is used to map the spatial distribution of activity associated with the IEDs.⁴ This promising technique thus has the potential to contribute to localisation of the epileptogenic focus. Multiple previous reviews have provided details of EEG-fMRI technical basics, artefact correction, data acquisition, concurrent analysis techniques, limitations, as well as presented key findings from various research centres.⁵⁻⁹ We have also published numerous technical advancements, applications and comments regarding EEG-fMRI in epilepsy (for example¹⁰⁻²⁶), some of which include subsets of patients that are included in this review.

However, other reviews and our previous reports leave a number of key questions unanswered, including:

- 1) Can EEG-fMRI be practically employed in a working clinical environment?
- 2) How often are EEG-fMRI studies successful in a typical clinical population with epilepsy (i.e. can good quality data be obtained, and interictal EEG discharges IEDs detected)?
- 3) Does performing EEG-fMRI ultimately benefit individual patients? Specifically, does EEG-fMRI improve localisation of the epileptogenic focus, influence decision-making in epilepsy surgery, and are outcomes after surgery altered?

Therefore, in this retrospective review we provide an overview of the practical use of EEG-fMRI in the clinical environment at a single tertiary-referral epilepsy centre. We present our institution's experience with EEG-fMRI acquired from patients with focal epilepsy, over a 16-year period, and address some of the issues related to performing EEG-fMRI studies in this setting. Finally, we consider the factors influencing success of the study and the clinical utility of the result.

2 Methods

2.1 Patient recruitment

We reviewed our experience of simultaneous EEG-fMRI in patients with pharmacoresistant focal epilepsy scanned at 3 tesla at The Florey Institute of Neuroscience and Mental Health, Austin Campus, Melbourne, Australia (including at the now-amalgamated Brain Research Institute) between 2003 and 2018.

At our institution, EEG-fMRI has been a research-based procedure and is not otherwise available as a routine part of standard clinical care. Patients were referred for EEG-fMRI mainly from the Comprehensive Epilepsy Program at Austin Health, which is a tertiary centre for epilepsy management including a well-established track record of epilepsy surgery.²⁷

In earlier years of the review period, all EEG-fMRI studies were research-funded, participants were selected based on active EEG findings during inpatient video-EEG-monitoring, and participants were subsequently imaged as outpatients at another hospital site remote from the monitoring unit. The availability to perform EEG-fMRI during video-EEG monitoring has been facilitated by the co-location of The Florey at the Austin Health campus since 2012, and the attendance of hospital medical staff while these studies are performed. EEG-fMRI studies were then performed while patients were either outpatients, or during inpatient video-EEG monitoring at Austin Health. During inpatient monitoring, anti-epilepsy medications are often reduced or withdrawn entirely, and patients have a degree of sleep deprivation (either incidentally or due to intentional reversal of the sleep-wake cycle). For inpatient cases, EEG-fMRI studies were organized on the last day of the video-EEG monitoring. In rare cases, when EEG-fMRI could not be performed at the end of inpatient stay, EEG electrodes from video-EEG monitoring were removed for the EEG-fMRI and reapplied after the study.

Since 2012, many EEG-fMRI studies were clinically referred (hospital-funded) while others were recruited purely as part of research projects, especially related to the validation and development of EEG-fMRI methods (research-funded). Reasons for clinical referral were variable, but frequently included very complex cases where referral was made after other investigations provided conflicting or uninformative results. Our usual practice has been to discourage referrals where the frequency of interictal epileptiform discharges (IEDs) recorded on inpatient or outpatient EEG is less than 10 per hour. For example, this has been the case for a few hospital inpatients, where administration of anti-seizure medications (particularly benzodiazepines) have abolished IEDs prior to a scheduled study. Only patients who eventually completed an EEG-fMRI study are reported here; those who were deemed unsafe to undergo MRI are not included.

Several research-only studies of specific epilepsies have also been undertaken at our centre with targeted recruitment – these do not form any part of this cohort and are described in detail elsewhere (childhood absence epilepsy^{14,15}; Lennox–Gastaut syndrome^{12,24,25}; benign epilepsy with centrotemporal spikes¹⁹).

2.2 Data acquisition and analysis

We allocate 90 minutes of scanner time for fMRI acquisition, which includes 60 minutes of simultaneous EEG and fMRI recording. Participants are instructed to stay still and keep their

eyes closed. We encourage participants to drowse and/or sleep during the study as this often increases the frequency of IEDs. No sedating medication is used.

Between 2003 and 2011, fMRI data were acquired using a 3T General Electric (GE) Signa LX scanner. Between 2012 and mid-2013 fMRI data were acquired using a 3T Siemens Trio. From mid-2013 to 2018, data were acquired using a 3T Siemens Skyra-scanner.

Full details of the EEG-fMRI protocol have been described previously (GE Signa^{15,17,18} Siemens Trio^{24,25}; Siemens Skyra^{21,23}). In brief, fMRI data were obtained using a gradient-recalled echo planar imaging with blood oxygenation-level dependent (BOLD) weighting and whole-brain slice coverage (GE Signa protocol #1: repetition time = 3.0s, echo time = 40ms, flip angle = 60°, 25 slices, 4.0mm thick + 1.0mm gap, field of view = 240mm; acquisition matrix size = 128 x 128 yielding in-plane resolution 1.875mm x 1.87 mm; GE Signa protocol #2: repetition time = 3.2s, echo time = 40ms, flip angle = 80°, 40 slices, 3.2mm thick + 0.2mm gap, field of view = 220mm; acquisition matrix size = 64 x 64 yielding in-plane resolution 3.4mm x 3.4mm; Siemens Trio: repetition time = 3s, echo time = 30ms, flip angle = 85°, 44 slices, 3mm thick + 0.2mm gap, field of view = 216mm; acquisition matrix size = 72 x 72 yielding in-plane resolution 3mm x 3mm; Siemens Skyra: repetition time = 3s, echo time = 30ms, flip angle = 85°, 44 slices, 3mm thick + 0.2mm gap, field of view = 216mm; acquisition matrix size = 72 x 72 yielding in-plane resolution 3mm x 3mm).

Simultaneous EEG data were acquired according to the 10-20 standard system of electrode placement. Prior to the fMRI acquisition, a short period of EEG data is recorded outside the scanner to ensure good technical quality and to assist later identification of IEDs. Between 2003 and 2011 we employed an in-house custom-developed EEG acquisition system, with 18 non-metallic scalp electrodes. From 2012 to 2018, a 32-channel MR-compatible EEG cap (BrainCap MR, EasyCap GmbH, Germany) and a BrainAmps EEG recorder was used (Brain Products GmbH, Germany) in conjunction with both the Siemens Trio and Skyra MRI. Since 2005, additional signals from three carbon-fibre loops electrically isolated from the scalp have been acquired along with the EEG, for detection of head motion artefacts.^{10,18} Acquired EEG recordings were preprocessed and then reviewed by epileptologists experienced in EEG interpretation, for manual mark-up of all epileptic activity. For each patient, long-term and out-of-scanner EEG was first used to define the expected categories of morphologically distinct IEDs epileptiform discharges (for example spikes or polyspike-waves discharges in singletons or trains, paroxysmal fast activity or focal slowing). These specified IED types were then identified on the inside-scanner EEG record, and the onset and end of each discharge marked.

This article is protected by copyright. All rights reserved

FMRI data were preprocessed in MATLAB (MathWorks Inc., USA) using SPM (Wellcome Department of Imaging Neuroscience) with the aid of iBrain²⁸ and the iBrain Analysis Toolbox for SPM.²⁹ Standard preprocessing included: slice timing correction, re-alignment to reduce the effects of head motion, and coregistration to a standardised EPI template. For the Siemens data, the template was the EPI template provided with the SPM package (which approximates the space of the 152-brain MNI T1-weighted template); for the GE Signa, due to signal distortions and dropout in this early-generation 3T scanner, a custom average template (in approximately the same space as the MNI template) was used to provide a target that more closely matched images acquired on this scanner.²²

~~In our analysis,~~ We used standard General Linear Modelling to extract statistical parametric maps of brain activity from EEG and fMRI with each IED type modelled using its own regressor. This was obtained as a boxcar function convolved with the SPM canonical haemodynamic response function (HRF). Temporal and dispersion derivatives were included as additional columns in the design matrix. Nuisance covariates were also entered as regressors of no interest, specifically a cosine basis set to perform high-pass filtering (1/128Hz), scrubbing regressors to ignore high-motion time points, and motion regressors derived from the motion estimates of the realignment pre-processing. Resultant statistical maps were thresholded at $p < 0.05$ corrected for multiple comparisons (family-wise error). Unthresholded statistical maps were retained to aid interpretation.

Both significant BOLD increases and decreases related to IEDs were considered equally, since it has been demonstrated that both can be observed in the epileptogenic zone.^{30,31}

2.3 Definitions

In this retrospective analysis we assessed collected EEG-fMRI data in terms of (1) success of the study and (2) the clinical utility of the study result.

~~For the purposes of this review,~~ A 'successful' study was defined as a study with good quality fMRI and EEG data (i.e., free from serious artefacts) and with active EEG recording showing frequent IEDs or the presence of typical ictal events. Studies of the patients who did not have any epileptic activity recorded inside the scanner or who had unsatisfactory technical quality of either EEG or MRI data were classified as unsuccessful. For clinical purposes at our institution, no GLM-based analysis is reported to the epilepsy team in cases where no IEDs are detected during the study.

Clinical utility was assessed by the consequences of providing EEG-fMRI results to the clinical team. Our routine clinical practice is to record the working case formulation and
This article is protected by copyright. All rights reserved

management plan during each multidisciplinary team meeting, and the conclusion is dictated by a senior epileptologist with the plan clearly described. From retrospective review of these records, we evaluated whether the treatment plan had been altered following presentation of the EEG-fMRI results, i.e. whether surgery was proposed or surgical plans were re-defined (such change were mainly based on the localisation revealed in the IED-related BOLD maps). Specifically, we defined that the EEG-fMRI results had a ‘critical impact’, when it was considered to have influenced the final decision for surgery, i.e. surgery decision was based on the EEG-fMRI localisation. We defined the EEG-fMRI results as only ‘supportive’ when the results were in-line with presumed epileptogenic focus based on other modalities, but did not influence the surgery decision, i.e. data sufficient to proceed to surgery was available without the EEG-fMRI result. The EEG-fMRI results ‘did not support’ the surgical localisation in cases where the EEG-fMRI localisation was discordant with presumed epileptogenic focus, i.e. BOLD clusters were remote from the presumed epileptogenic focus. We assessed the ‘critical impact’ and supportive/unsupportive character of the result only for cases where surgery was performed.

3 Results

3.1 Patient recruitment

In total, 118 patients with an electroclinical diagnosis of focal epilepsy had EEG-fMRI performed over the 16-year review period, which is 6% of all patients admitted for inpatient video-EEG over this time. Of these, 79 studies were performed prior to 2012 with a mean scan duration of 53 ± 7 minutes (range 20-60 minutes) on the GE Signa. Subsequently, 12 studies were recorded with a mean scan duration of 58 ± 5.8 minutes (range 40-60 minutes) on the Trio and 27 studies were performed with a mean scan duration of 57 ± 9.7 minutes (range 16-60 minutes) on the Skyra. Since 2012, 5 of 39 scans (13%) were stopped early because of the patient’s general discomfort (n=3) or a convulsive seizure (n=2).

3.2 Technical evaluation of data acquisition

Overall, 59 out of 118 (50%) EEG-fMRI studies were successful (Table 1). Prior to 2012, 33 of 79 studies (42%) were successful, with the remainder either having no IEDs epileptic discharges during the study (41 of 79, 52%) or failure of data acquisition due to buffer overflow of the EEG recording system (5 of 79, 6%). Since 2012, 26 of 39 studies (67%)

were successful, while 13 (33%) did not have any IEDs. ~~epileptic discharges during the study.~~

Table 1 near here

With regard to seizures, 10 out of 59 (17%) patients with successful EEG-fMRI experienced at least one ictal event during the study. These included nine ictal events in six patients scanned at the GE Signa, and 13 ictal events in four patients scanned at the Skyra scanner. All patients who had seizures during the study had frequent IEDs, meaning that these studies would remain 'successful' by our definition even if ictal events were ignored.

3.3 Effect of inpatient versus outpatient referral

Since 2012, 22 of 39 studies (56%) were performed as ~~hospital~~ inpatients. Of the inpatient group, typically on reduced medications, 96% (21 of 22) had IEDs recorded during the EEG-fMRI study. In contrast, in patients studied in the outpatient setting, only 29% (5 of 17) had IEDs recorded during the EEG-fMRI study (Table 2 and Suppl.Figure 1). The difference in detection of IEDs between the inpatient and outpatient groups was statistically significant (chi-squared test; $p < 0.0001$).

Table 2 near here

3.4 Detection of a significant BOLD response with IEDs

A statistically significant (thresholded at $p < 0.05$, family-wise error-corrected) BOLD response in association with one or more IED types was detected in 51 of 59 successful EEG-fMRI studies (86%) (Table 3). We have not observed susceptibility artefacts in cases with no significant BOLD changes.

Table 3 near here

We considered whether the number of IEDs could explain the presence or lack of a significant BOLD finding. In the 51 cases with significant BOLD changes, the median number of recorded IEDs per IED-type-per study was 93 (range 10-1132) and the median
This article is protected by copyright. All rights reserved

aggregate duration of marked IEDs per IED-type-per-study was 60 seconds (range 0.94-809.7seconds).

In the remaining eight cases with no significant BOLD response, we recorded median 32 IEDs (range 10-412), with a median aggregate duration of marked IEDs of 6.1 seconds (range 0.8-98.5seconds). There was a statistically significant difference in number of IEDs (Mann-Whitney U-test; $U=404$, $Z=2.63043$, $p=0.009$) and their aggregate duration (Mann-Whitney U-test; $U=221.5$, $Z=4.40512$, $p<0.001$) between two groups. The anatomical location and nature of the underlying pathology may also be a relevant factor to whether a significant BOLD response is detected. In surgical cases with no significant BOLD changes from standard-GLM analysis ($n=7$), 57% patients underwent anterior temporal lobe resection, mostly performed because of mesial temporal tumours or hippocampal sclerosis.

In the GE Signa cohort, we recorded a total of 51 IEDs types in 33 patients, with 12 patients having more than one type of IED. Twenty-seven of 33 patients (82%) had statistically significant BOLD response associated with their 39 IED types. Statistical analysis of 12 IED types in six patients did not reveal any significant change in BOLD changes signal.

In the Siemens cohort, 26 patients had 38 IEDs types, with 12 patients having more than one type of IED. Of those, 24 (92%) had statistically significant BOLD changes associated with their 36 IEDs types. Two IEDs types in two patients did not demonstrate any significant change in BOLD signal.

3.5 Clinical impact of EEG-fMRI findings

Despite the time-consuming nature of EEG-fMRI analysis, the usual analysis turnaround in our institution is on the order of weeks. The EEG-fMRI result was ready prior to the final surgical discussion for each patient in this study.

Overall, 57 of the total 118 patients have proceeded to epilepsy surgery. A further six cases with significant BOLD response have been offered epilepsy surgery and are currently on a surgical waitlist. Surgeries performed and postoperative outcomes for the full cohort are shown in Figure 1. Overall, 43 (75%) had good outcome at 2 years after surgery (ILAE class 1 or 2).

Figure 1 near here

In operated patients, the EEG-fMRI result had a ‘critical impact’ on the surgical decision in 10 cases (see ~~Table 4 for clinical details~~). Within this group, four were clinically reported as ‘MRI-negative’, three had very subtle MRI abnormalities (~~small dysplastic lesions~~), and three had obvious and extensive multi-lobar MRI abnormalities (~~multiple tubers, post-meningitis gliosis, extensive bilateral periventricular nodular heterotopia~~). Three patients had previous unsuccessful epilepsy resections, including two of the ‘MRI-negative’ cases and one patient with extensive post-meningitis lesions. The majority of these patients (80%) had good post-surgical outcomes.

In four of those 10 patients (patients #2, 4, 7, 9) EEG-fMRI results informed the decision to proceed to intracranial video-EEG before surgery to explore the regions of interests and validate the EEG-fMRI findings. The EEG-fMRI result influenced the invasive electrode placement in each case, i.e. electrode placement was re-defined to cover the areas of BOLD change. This sub-group includes cases with previous surgeries or discordant data, where intracranial EEG aimed to clarify the localisation of a single focus.

Table 4 near here

In operated patients with significant BOLD, the EEG-fMRI result was supportive, but not ‘critical’, for surgical localisation in 11 cases (Suppl. Table 1). Most of these patients (73%) had good post-surgical outcomes.

In the subgroup, where no IEDs were detected during EEG-fMRI (n=29), 55% patients underwent standard anterior temporal lobectomy, with a higher proportion of mesial temporal lobe pathologies (e.g. hippocampal sclerosis, developmental tumours or temporal pole encephaloceles), where sufficient data to proceed to surgery was available even without the EEG-fMRI result. Figure 2 shows examples of cases where the EEG-fMRI result had ‘critical impact’ or was ‘supportive’ for surgical localisation. ~~See Suppl. Table 1 for details on all surgical cases with no EEG-fMRI result or supportive but not ‘critical’ EEG-fMRI result.~~

Figure 2 near here

Twenty-four patients (47%) of the total 51 with significant BOLD response have not had, and are not scheduled for, epilepsy surgery. The main reasons are lack of a convincing single epileptic focus (n=12 including MRI-negative status or extensive brain malformations) or a significant risk of cognitive deficits with resection of the presumed epileptogenic zone (n=8). In all patients with significant BOLD and defined presumed epileptogenic focus, and who have not proceeded to/are not scheduled for surgery, EEG-fMRI results were concordant with other clinical information (Suppl. Table 2). This was assessed by epileptologists via visual comparison of the EEG-fMRI result and localisation of the presumed epileptic focus.

4 Discussion

This single-centre uncontrolled retrospective review, examining the research application of EEG-fMRI in difficult-to-localize focal epilepsy, confirms that this technique is feasible in a clinical environment and can aid surgical planning in this very complex patient cohort. Over the last 16 years in our centre, 50% of EEG-fMRI studies were successful. ~~Recently a much higher proportion of successful cases has been achieved by selecting patients to be studied who have frequent epileptiform discharges IEDs during inpatient video-EEG monitoring, while on reduced or withdrawn medications.~~ EEG-fMRI results critically influenced the decision to offer surgery in 10 patients, corresponding to 17% of the 59 successful EEG-fMRI studies.

Similarly, previous studies have reported that EEG-fMRI led to resection in one patient and opened new prospects of surgery in three others³² and allowed a more specific localisation of epileptic focus when compared with EEG alone, in half of patients.³³ Significant BOLD response can help delineate the epileptogenic region and concordance between BOLD response and resection is indicative of seizure freedom.³⁴⁻³⁷ Collectively, these findings support EEG-fMRI as a useful tool to define the epileptic focus.

Generally, good quality EEG recording and MR images, together with frequently occurring IEDs, are essential for a successful EEG-fMRI study.⁶ In practice, performing EEG-fMRI in epilepsy patients carries many additional challenges that need to be overcome to obtain good results. At present, simultaneous EEG-fMRI is used in just 14% of European epilepsy surgery centres to aid the localisation of the epileptogenic focus.³⁸ Barriers to wider adoption include substantial initial setup cost for MRI and compatible EEG equipment, the challenges of integrating these technologies and the required expertise across electrophysiology and

imaging domains. ~~Additionally, the current limited evidence of eventual benefit to patients may hamper institutional or government commitment to funding.~~

Medications and IED frequency

One of the biggest barriers for a successful EEG-fMRI study in our institution was an inactive EEG. Overall, 46% of patients did not have any epileptic activity seen on scalp EEG during the recording. The majority of these patients underwent EEG-fMRI as an outpatient while they were taking multiple medications. However, a change in our approach in 2012 has led to a dramatic improvement, as 96% of patients recorded whilst an inpatient for video-EEG monitoring have shown IEDs during the EEG-fMRI recording. This improved success rate may be largely due to better participant selection. For inpatient studies, we could recruit participants with frequent IEDs ~~epileptic discharges~~ seen on long-term EEG from the ward, whereas in outpatient cases we could only rely on previous EEG recordings and could not predict how active the EEG would be on the day of the EEG-fMRI study.

Reduction of medication may increase the rate of IEDs and improve the sensitivity of EEG-fMRI studies. Withdrawing antiepileptic medications during inpatient EEG-video monitoring enables this step to be taken safely in a medically supervised environment (considering the risk of provoking frequent or prolonged seizures) and allows these medication-reduced EEG-fMRI studies to be performed without ethical concerns.³⁹ Organizing such studies at short notice can be a logistical challenge, due to MR scanner unavailability and timely MRI safety clearance. This can be overcome by the weekly scheduled timeslot for inpatient EEG-fMRI studies. ~~Reduction of antiepileptic medications in the outpatient setting could be contemplated for selected patients under the guidance of their treating physician, but for many patients this would be contraindicated due to safety concerns.~~

Resources and costs

EEG-fMRI studies require MR-compatible EEG equipment due to safety and performance issues.⁴⁰ Currently, many commercial EEG systems are available for safe use in the MR scanner and EEG-fMRI recordings are well-established in selected clinical research environments worldwide. The operational cost of a standard EEG-fMRI study is considerably higher than for a conventional MRI study due to the numerous additional resources required, including pre-scan preparation and post-scan data analysis. For example, EEG-fMRI setup with standard 10-20 system and 35 electrodes takes 30-50 minutes ~~(including a short period of recording prior to moving into the MRI scanner)~~, while data filtering, marking up of IEDs and data analysis takes additional 5-15 hours depending upon the complexity of the recorded

EEG. It is worth noting that manual markup of the EEG is considerably more onerous than typical clinical assessment of EEG, because in EEG-fMRI *all* the epileptiform events need to be marked to provide the optimum model for subsequent analysis of the associated BOLD signal. ~~The multiple resources involved in EEG-fMRI together with the relatively high logistical setup cost and expertise required for EEG-fMRI can be a barrier to performing more frequent, routine studies.~~ To help translate EEG-fMRI ~~research~~ into a faster, more affordable and easier-to-use tool in clinical settings, we recently developed and implemented an IED detection algorithm for scalp ~~interictal~~ EEG recordings. Our recent study shows that automatic spike detection can provide comparable and, in some cases, even superior results compared to manual EEG markup in EEG-fMRI analysis.²¹ Similarly, another recent study shows that deep-learning-based semi-automatic spike detector can produce comparable EEG-fMRI results compared to traditional markup methods.⁴¹

Lack of significant BOLD response

The standard GLM analysis did not demonstrate any significant BOLD response in eight out of the 59 successful studies in this series (14%). Our data suggests that the number of IEDs and their aggregate duration might influence the detection of significant BOLD changes. Lack of significant BOLD response may reflect ~~also~~ limitations in the standard fMRI signal modelling, or be associated with the quality of detected IEDs.¹⁶ The phenomenon of lack of BOLD ~~signal~~ changes associated with IEDs has been reported by other researchers.⁴²⁻⁴⁴ In some cases, continuous local epileptic activity (which is not necessarily seen on scalp EEG recordings) might have resulted in too little contrast between the spiking and an implicit baseline in the GLM. We have also observed that BOLD activity associated with some spikes may not follow the conventionally assumed response function, and can even begin before the onset of the scalp discharge.¹⁹

In this review we have focussed on the ~~conventional~~ GLM analysis of fMRI data as the primary measure that was reported to our Comprehensive Epilepsy Program. Although a GLM approach is by far the most commonly used for the integration of EEG and fMRI, it is ineffective when IEDs are not seen in the EEG. Other methods, involving independent component analysis (ICA),⁴⁵ an EEG-derived scalp topography-based method⁴⁶ or local connectivity analysis⁴⁷ may ~~also~~ be useful when IEDs are not detected ~~during EEG-fMRI~~.

Impact on clinical care

We examined the MRI features of 10 patients where EEG-fMRI had a critical impact. In these cases, the other clinical investigations provided conflicting or uninformative results,

particularly when there was no apparent structural epileptogenic lesion (~~'MRI-negative'~~) or when an extensive multi-lobar structural malformation was present. The majority of these patients had an excellent ~~seizure~~ post-operative outcome ~~after epilepsy surgery~~. ~~All these focal resections were guided by the results of the EEG-fMRI study.~~

Interestingly, within the surgical group with no IEDs detected during EEG-fMRI, we found a high proportion of cases with mesial temporal lobe epilepsy, which often generates relatively infrequent scalp-detectable epileptic discharges. As the most common form of adult epilepsy, with a strong evidence base for surgical treatment,⁴⁸ EEG-fMRI will often not be needed to determine the management for these patients. Within the surgical group where EEG-fMRI result was congruent and supportive but not 'critical' for the surgical decision, we found mainly lesional cases, indicating that EEG-fMRI may be less influential when a clear structural lesion has already been established.

5 Conclusions

This retrospective review has presented our experience with EEG-fMRI studies in patients with pharmacoresistant focal epilepsy over a 16-year period. EEG-fMRI is now a well-established tool for mapping the location of epileptic activity and can feasibly be applied in a tertiary hospital environment. The findings from EEG-fMRI can have a critical impact on patient management, including influencing the decision for targeted surgical resection, with good subsequent seizure outcomes.

We therefore consider it is time for a systematic, well-controlled and suitably powered clinical trial, to evaluate whether EEG-fMRI can improve outcomes for patients. Only with this evidence will it be possible to accurately estimate the potential cost vs benefit of routine clinical EEG-fMRI for pre-surgical planning in epilepsy, and to argue for the additional resourcing of radiology (MRI) and neurophysiology (EEG) that will be needed to enable provision of this technology across epilepsy centres more widely.

Acknowledgements

This work was supported by the National Health and Medical Research Council (NHMRC) of Australia (program grant 1091593; project grant 1081151). G.D.J. was supported by an NHMRC practitioner fellowship (1060312). M.A.K. was supported by Melbourne Research Scholarship from the University of Melbourne. D.F.A. was supported by fellowship funding from the National Imaging Facility. The Florey Institute of Neuroscience and Mental Health acknowledges the strong support from the Victorian Government and in particular the

funding from the Operational Infrastructure Support Grant. The authors acknowledge the facilities and scientific and technical assistance of the National Imaging Facility, a National Collaborative Research Infrastructure Strategy (NCRIS) capability, at The Florey Institute of Neuroscience and Mental Health.

Our EEG-fMRI journey would not have been possible without the advice, dedicated work and support of many people. We thank the patients, their families, as well as neurologists, neurosurgeons, radiologists, nuclear medicine specialists, psychiatrists, nurses and epilepsy registrars of the Austin Hospital Comprehensive Epilepsy Program. We acknowledge Mr. Steven Fleming for MRI technical support; Dr Danny Flanagan, Dr John Archer, Dr Patrick Carney and Dr Moksh Sethi for assistance with EEG recording, review, markup and analysis; Dr Richard Masterton for contributions to methods development; EEG Technicians at Austin Hospital for EEG markup; Ms. Selma Music, Ms. Mira Semmelroch, Ms. Donna Parker and Ms. Cassandra Marotta for assistance with patient recruitment and data acquisition; Florey MRI Department for MRI scanning; Dr Marie O'Shea and Mr. Alex Wynd for assessing the long-term patient outcomes after neurosurgery.

Disclosure of Conflicts of interest

None of the authors has any conflict of interest to disclose.

Ethical Publication Statement

We confirm that we have read the Journal's position on issues involved in ethical publication and affirm that this report is consistent with those guidelines.

References

1. Jobst BC, Cascino GD. Resective epilepsy surgery for drug-resistant focal epilepsy: a review. *JAMA* 2015;313(3):285–93.
2. Dugan P, Carlson C, Jetté N, et al. Derivation and initial validation of a surgical grading scale for the preliminary evaluation of adult patients with drug-resistant focal epilepsy. *Epilepsia*. 2017;58(5):792–800.
3. Selwa LM, Schmidt SL, Malow BA, et al. Long-term outcome of nonsurgical candidates with medically refractory localization-related epilepsy. *Epilepsia* 2003;44(12):1568–72.
4. Ives JR, Warach S, Schmitt F, et al. Monitoring the patient's EEG during echo planar MRI. *Electroencephalogr Clin Neurophysiol*. 1993;87(6):417–20.

5. Hamandi K, Salek-Haddadi A, Fish DR, et al. EEG/functional MRI in epilepsy: The Queen Square Experience. *J Clin Neurophysiol.* 2004;21(4):241–8.
6. Gotman J. Epileptic networks studied with EEG-fMRI. *Epilepsia* 2008;49(Suppl 3):42–51.
7. Laufs H. Functional imaging of seizures and epilepsy: evolution from zones to networks. *Curr Opin Neurol.* 2012;25(2):194–200.
8. van Graan LA, Lemieux L, Chaudhary UJ. Methods and utility of EEG-fMRI in epilepsy. *Quant Imaging Med Surg.* 2015;5(2):300–12.
9. Maloney TC, Tenney JR, Szaflarski JP, et al. Simultaneous Electroencephalography and Functional Magnetic Resonance Imaging and the Identification of Epileptic Networks in Children. *J Pediatr Epilepsy* 2015;4(4):174–83.
10. Abbott DF, Masterton RAJ, Archer JS, et al. Constructing Carbon Fiber Motion-Detection Loops for Simultaneous EEG-fMRI. *Front Neurol.* 2014;5:260.
11. Archer JS, Briellmann RS, Syngeniotis A, et al. Spike-triggered fMRI in reading epilepsy: involvement of left frontal cortex working memory area. *Neurology.* 2003;60(3):415–21.
12. Archer JS, Warren AEL, Stagnitti MR, et al. Lennox-Gastaut syndrome and phenotype: secondary network epilepsies. *Epilepsia* 2014;55(8):1245–54.
13. Bhaganagarapu K, Jackson GD, Abbott DF. De-noising with a SOCK can improve the performance of event-related ICA. *Front Neurosci.* 2014;8:285.
14. Carney PW, Masterton R a. J, Harvey AS, et al. The core network in absence epilepsy. Differences in cortical and thalamic BOLD response. *Neurology* 2010;75(40):904–11.
15. Carney PW, Masterton R a. J, Flanagan D, et al. The frontal lobe in absence epilepsy: EEG-fMRI findings. *Neurology* 2012;78(45):1157–65.
16. Flanagan D, Abbott DF, Jackson GD. How wrong can we be? The effect of inaccurate mark-up of EEG/fMRI studies in epilepsy. *Clin Neurophysiol.* 2009;120(9):1637–47.
17. Flanagan D, Badawy R a. B, Jackson GD. EEG-fMRI in focal epilepsy: local activation and regional networks. *Clin Neurophysiol.* 2014;125(1):21–31.
18. Masterton RAJ, Abbott DF, Fleming SW, et al. Measurement and reduction of motion and ballistocardiogram artefacts from simultaneous EEG and fMRI recordings. *Neuroimage* 2007;37(1):202–11.
19. Masterton RAJ, Harvey AS, Archer JS, et al. Focal epileptiform spikes do not show a canonical BOLD response in patients with benign rolandic epilepsy (BECTS). *Neuroimage* 2010;51(1):252–60.
20. Masterton RAJ, Carney PW, Abbott DF, et al. Absence epilepsy subnetworks revealed by event-related independent components analysis of functional magnetic resonance imaging. *Epilepsia* 2013;54(5):801–8.
21. Omidvarnia A, Kowalczyk MA, Pedersen M, et al. Towards fast and reliable simultaneous EEG-fMRI analysis of epilepsy with automatic spike detection. *Clin Neurophysiol.* 2019;130(3):368–78.

22. Waites AB, Shaw ME, Briellmann RS, et al. How reliable are fMRI-EEG studies of epilepsy? A nonparametric approach to analysis validation and optimization. *Neuroimage* 2005;24(4):192–9.
23. Walz JM, Pedersen M, Omidvarnia A, et al. Spatiotemporal mapping of epileptic spikes using simultaneous EEG-functional MRI. *Brain* 2017;140(4):998–1010.
24. Warren AEL, Harvey AS, Abbott DF, et al. Cognitive network reorganization following surgical control of seizures in Lennox-Gastaut syndrome. *Epilepsia* 2017;58(5):e75–81.
25. Warren AEL, Abbott DF, Jackson GD, et al. Thalamocortical functional connectivity in Lennox-Gastaut syndrome is abnormally enhanced in executive-control and default-mode networks. *Epilepsia* 2017;58(12):2085–97.
26. Federico P, Archer JS, Abbott DF, et al. Cortical/subcortical BOLD changes associated with epileptic discharges: an EEG-fMRI study at 3 T. *Neurology* 2005;64(7):1125–30.
27. McIntosh AM, Kalnins RM, Mitchell LA, et al. Temporal lobectomy: long-term seizure outcome, late recurrence and risks for seizure recurrence. *Brain* 2004;127(Pt 9):2018–30.
28. Abbott, D. F., Jackson G.D. (2001). IBrain — Software for Analysis and Visualisation of Functional MR Images. *NeuroImage* 13(6):59.
29. Abbott, D. F., Masterton, R.A.J, Waites, A., et al. The iBrain™ analysis toolbox for SPM, in Proceedings of the 17th Annual Meeting of the Organisation for Human Brain Mapping 2011, Quebec, QC.
30. Jacobs J, Kobayashi E, Boor R, et al. Hemodynamic responses to interictal epileptiform discharges in children with symptomatic epilepsy. *Epilepsia*. 2007;48(11):2068–78.
31. Kobayashi E, Bagshaw AP, Grova C et al. Negative BOLD Responses to Epileptic Spikes. *Human Brain Mapping* 2006;27:488–497.
32. Zijlmans M, Huiskamp G, Hersevoort M, et al. EEG-fMRI in the preoperative work-up for epilepsy surgery. *Brain*. 2007;130(9):2343-53.
33. Pittau F, Dubeau F, Gotman J. Contribution of EEG/fMRI to the definition of the epileptic focus. *Neurology* 2012;78(19):1479-87.
34. An D, Fahoum D, Hall J, et al. Electroencephalography/functional magnetic resonance imaging responses help predict surgical outcome in focal epilepsy. *Epilepsia*. 2013;54(12):2184–2194.
35. Coan AC, Chaudhary UJ, Grouiller F, et al. EEG-fMRI in the presurgical evaluation of temporal lobe epilepsy. *J Neurol Neurosurg Psychiatry*. 2016;87(6):642-9.
36. Moeller F, Tyvaert L, Nguyen DK, et al. EEG-fMRI. Adding to standard evaluations of patients with nonlesional frontal lobe epilepsy. *Neurology*. 2009;73(23):2023-30.
37. Thornton R, Laufs H, Rodionov R, et al. EEG correlated functional MRI and postoperative outcome in focal epilepsy. *J Neurol Neurosurg Psychiatry*. 2010;81(8):922-7.

38. Mouthaan BE, Rados M, Barsi P, et al. Current use of imaging and electromagnetic source localization procedures in epilepsy surgery centers across Europe. *Epilepsia* 2016;57(5):770–6.
39. Hermans K, Ossenblok P, van Houdt P, et al. Network analysis of EEG related functional MRI changes due to medication withdrawal in focal epilepsy. *Neuroimage Clin.* 2015;8:560–71.
40. Duyn JH. EEG-fMRI Methods for the Study of Brain Networks during Sleep. *Front Neurol.* 2012;3.
41. Hao Y, Khoo HM, von Ellenrieder N, et al. DeepIED: An epileptic discharge detector for EEG-fMRI based on deep learning. *NeuroImage: Clinical* 2018;17:962–75.
42. Al-Asmi A, Bénar C-G, Gross DW, et al. fMRI activation in continuous and spike-triggered EEG-fMRI studies of epileptic spikes. *Epilepsia* 2003;44(10):1328–39.
43. Salek-Haddadi A, Diehl B, Hamandi K, et al. Hemodynamic correlates of epileptiform discharges: an EEG-fMRI study of 63 patients with focal epilepsy. *Brain Res.* 2006;1088(1):148–66.
44. Jacobs J, Kobayashi E, Boor R, et al. Hemodynamic responses to interictal epileptiform discharges in children with symptomatic epilepsy. *Epilepsia.* 2007;48(11):2068–78.
45. Rodionov R, De Martino F, Laufs H, et al. Independent component analysis of interictal fMRI in focal epilepsy: comparison with general linear model-based EEG-correlated fMRI. *Neuroimage* 2007;38(3):488–500.
46. Grouiller F, Thornton RC, Groening K, et al. With or without spikes: localization of focal epileptic activity by simultaneous electroencephalography and functional magnetic resonance imaging. *Brain* 2011;134(10):2867–86.
47. Jackson GD, Pedersen M, Harvey AS. How small can the epileptogenic region be? A case in point. *Neurology* 2017;88(24):2017–9.
48. Wiebe S, Blume WT, Girvin JP, et al. Effectiveness and Efficiency of Surgery for Temporal Lobe Epilepsy Study Group. A randomized, controlled trial of surgery for temporal-lobe epilepsy. *N Engl J Med.* 2001;345(5):311–8.

Figure legends

Figure 1. EEG-fMRI in pre-surgical assessment and surgery outcomes – an overview.

Abbreviations: BOLD = Blood-Oxygen-Level-Dependent, CEP = Comprehensive Epilepsy Program, EEG = electroencephalography, fMRI = functional magnetic resonance imaging, ILAE 1 = completely seizure-free, no aura, ILAE 2 = only auras, no other seizures.

Figure 2. *Case A: 'critical impact'*: MRI negative patient with discordant EEG and ictal SPECT data. Decision prior to EEG-fMRI was to do not perform surgery due to lack of a convincing single epileptic focus. After EEG-fMRI, decision was to perform intracranial EEG guided by the EEG-fMRI result and subsequently a resection guided by the EEG-fMRI result. *Case B, 'supportive'*: The EEG-fMRI result was supportive of surgical localisation in a left superior frontal region but did not have a 'critical impact' on surgical planning. The epileptic focus was well-defined based on other concordant modalities prior to EEG-fMRI study, and the EEG-fMRI result was in agreement with this localisation. *Abbreviations: EEG = electroencephalography, fMRI = functional magnetic resonance imaging, ILAE I = completely seizure-free, no aura, PET = Positron Emission Tomography, SPECT = Single Photon Emission Computed Tomography, y =year.*

Suppl. Figure 1. IEDs are more often seen during EEG-fMRI when performed as a hospital inpatient during video-EEG monitoring (data 2012-2018), $p < 0.0001$. *Abbreviations: EEG = electroencephalography, fMRI = functional magnetic resonance imaging, IEDs = interictal epileptiform discharges.*

Table 1. Success of EEG-fMRI studies performed in our research institute.

Obtained EEG-fMRI study	Number of studies		
	3T GE Signa	3T Siemens Trio/Skyra	Total
	(2003-2011) n=79	(2012-2018) n=39	
Successful study (epileptic activity present on EEG, good quality data)	33/79 (42%)	26/39 (67%)	59/118 (50%)
No epileptic activity evident on EEG during the study	41/79 (52%)	13/39 (33%)	54 /118 (46%)
Bad quality data (serious artefact, data unusable)	5 (6%)	0	5 /118 (4%)
Total	79	39	118

Abbreviations: EEG = electroencephalography, fMRI = functional magnetic resonance imaging.

Table 2. IEDs presence during EEG-fMRI in inpatient/outpatient setting (data 2012-2018), p <0.0001.

3T Siemens Trio/ Skyra	Number of studies		
	IEDs during EEG-fMRI	No IEDs during EEG-fMRI	Total
Inpatient	21	1	22
Outpatient	5	12	17
Total	26	13	39

Abbreviations: EEG = electroencephalography, fMRI = functional magnetic resonance imaging, IEDs = interictal epileptiform discharges.

Table 3. BOLD response in EEG-fMRI studies.

EEG-fMRI findings	Number of studies		
	3T GE Signa (2003-2011)	3T Siemens Trio/ Skyra (2012-2018)	Total
Significant BOLD response present	27/33 (82%)	24/26 (92%)	51/59 (86%)
No significant BOLD response despite IEDs detected	6/33 (18%)	2/26 (8%)	8/59 (14%)

Abbreviations: BOLD = Blood-Oxygen-Level-Dependent, EEG = electroencephalography, fMRI = functional magnetic resonance imaging, IEDs = interictal epileptiform discharges.

Table 4. Clinical details on cases where the EEG-fMRI result had a ‘critical impact’ on the surgical decision.

Patient	Age [years]	Sex	Seizure onset age	Epilepsy semiology	Scalp EEG report	Formal MRI report	PET report	Ictal SPECT report	Previous surgery	EEG-fMRI findings	iEEG	Epilepsy surgery	Reported pathology	Outcome (follow-up)	Individual ‘critical impact’ of EEG-fMRI results
1	38	M	4y	R TLE	R temp and R central	MRI-negative	R inferolateral temp	R temp	-	R temp	-	R anterolateral temp corticectomy	Old cortical loss and gliosis, features consistent with old infarction	ILAE 1 (11y)	EEG-fMRI changed decision from ‘no surgery’ to ‘surgery’
2	33	F	3mo	R posterior	R post quadrant, R temporal	R frontal and R occipito-parietal lesions (post infantile salmonella meningitis)	R parieto-occipital	R parieto-occipital	R parietal corticectomy at the age of 27y, sz ongoing (pathology: atrophic tissues, gliosis)	R parieto-occipital	R frontal and R parietal implantation revealed R parieto-occipital focus	R parieto-occipital lesionectomy	Astrocytosis, with increased numbers of corpora amylacea	ILAE 1 (8y)	iEEG decided based on EEG-fMRI; EEG-fMRI changed decision from ‘no surgery’ to ‘surgery’
3	21	M	11mo	R TLE	R posterior temp	MRI-negative	Diffuse R temp	R frontal and R posterior temporal	Partial R temp lesion removed at the age of 11mo (pathology: ganglioglioma),sz return at the age of 12y	R posterior temp	-	R anterior temporal lobectomy	Evidence of partial HS, gliosis	ILAE 1 (9y)	EEG-fMRI changed decision from ‘no surgery’ to ‘surgery’
4	16	M	12y	L parietal	L posterior temporal	Suspected very subtle L parietal dysplastic lesion	L temp, L parietal	L temporoparietal	-	L parietal	L postcentral implantation revealed L parietal focus	L parietal lesionectomy	FCD IIb	ILAE 3 (8y)	iEEG decided based on EEG-fMRI; EEG-fMRI changed decision from ‘no surgery’ to ‘surgery’
5	10	M	2.5y	R TLE	R anterior-temp	MRI-negative	R temp	R mesial and posterolateral temp	-	R amygdala	-	R anterior temporal lobectomy with partial removal of the amygdala but sparing of the hippocampus	Gliosis	ILAE 1 (15y)	EEG-fMRI changed decision from ‘no surgery’ to ‘surgery’
6	38	F	26y	L TLE	L temp	Bilat PVNH, more on the L than R, involving L anterior temp and L posterior	Bitemporal, worse on the L	L temporal, L inferior frontal	-	L temp	-	L post inferior temp corticectomy	Heterotopic grey matter (dysplasia)	ILAE 1 (13mo)*	EEG-fMRI changed decision from ‘no surgery’ to ‘surgery’

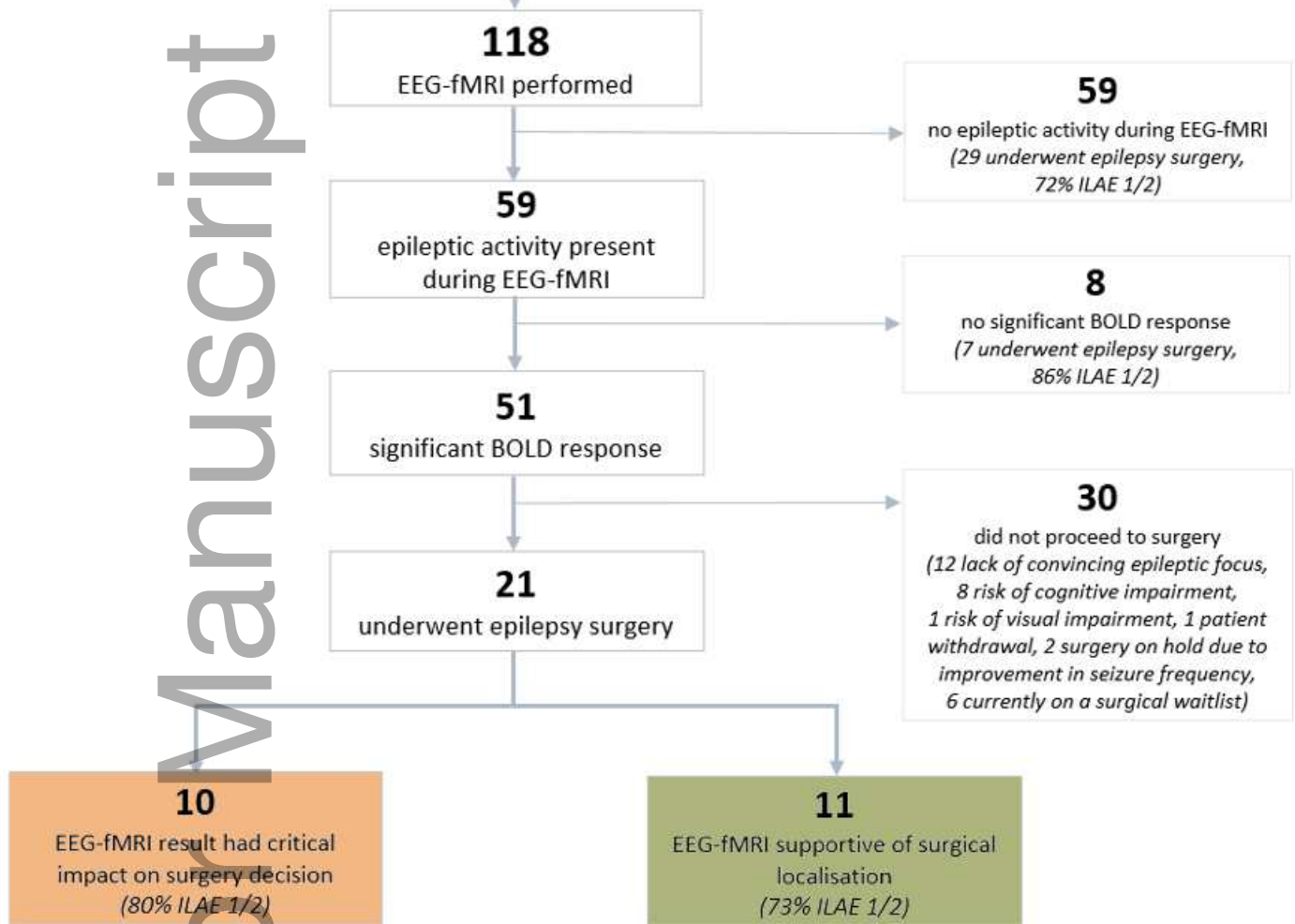
7	49	M	18y	R FLE	R frontal, bilateral temp	Very subtle R frontal dysplastic lesion	L temp, R temp, R orbitofrontal	R frontal	-	R mesial temp, R caudate, R frontal	R fronto-temp implantation revealed R frontal focus	R inferior frontal lesionectomy	FCD IIb	ILAE 1 (5y)	iEEG decided based on EEG-fMRI; EEG-fMRI changed decision from 'no surgery' to 'surgery'
8	41	M	10y	L TLE	L temp, rare R temp	L HS, multiple tubers (L temp lobe, L parietal region and L anterior cingulate)	L temp, L parietal	L temp, L orbitofrontal	-	L anterior temp	-	L anterior temp lobectomy	Dysplasia, multiple tubers	ILAE 1 (4y)	EEG-fMRI resulted in modified surgical plan (smaller resection volume)
9	27	F	8y	R TLE	R posterior quadrant, bilateral temp	MRI-negative	R temp	R temp	R posterior inferior temp corticectomy at the age of 25y, sz ongoing (pathology: negative)	R posterior inferior temp	R posterior temp implantation revealed R posterior temp focus	R posterior inferior temp corticectomy	FCD IIb	ILAE 1 (2.5y)	EEG-fMRI changed decision from 'no surgery' to 'surgery'
10	24	M	23y	R parietal	R frontal, parietal	Subtle R mesial parietal lesion	R frontal	NA	-	R medial parietal, frontal	-	R parietal lesionectomy	Cavernoma	ILAE 3 (1y)	EEG-fMRI changed decision from 'no surgery' to 'surgery'

Abbreviations: EEG = electroencephalography, F = female, FCD IIb = Focal cortical dysplasia type IIb, FLE = frontal lobe epilepsy, HS = hippocampal sclerosis, iEEG = intracranial electroencephalography, ILAE 1 = completely seizure-free, no aura, ILAE 3 = 1 to 3 seizure days per year; ± auras, L = left, M = male, mo = month, MRI = magnetic resonance imaging, NA = not available, PET = Positron Emission Tomography, PVNH = periventricular nodular heterotopia, R = right, sz = seizure, temp = temporal, SPECT = Single Photon Emission Computed Tomography, TLE = temporal lobe epilepsy, y = year. *Patient died 13 months after epilepsy surgery from an unrelated cause.

Author Manuscript

Refractory focal epilepsy patients in pre-surgical assessment

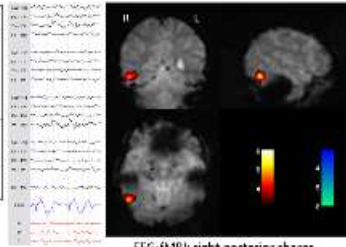
Clinical referral from CEP or research interest
recruitment of patients with recent active EEG



epi_16399_f1.tif

Case A. 'Critical impact' on the surgical decision

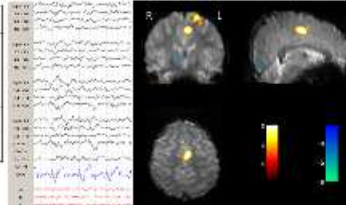
27 y, Right temporal lobe epilepsy (onset: 8 y)	
1 st Interictal EEG	Right temporal and left temporal
ictal EEG	Right temporal, left temporal and bilateral
PET	Right temporal and right occipital
ictal SPECT	Right temporal and left temporal
MRI	Negative
2 nd EEG-fMRI	Right temporal
3 rd Intracranial VEM	Right temporal
4 th Surgery	Right posterior temporal (TAE 1)



EEG-fMRI: right posterior sharp
(n = 83, total duration: 30 sec)

Case B. 'Supportive' of surgical localisation, but not 'critical impact'

14 y, Left frontal lobe epilepsy (onset: 2 y)	
1 st Interictal EEG	Left precentral focus, close to midline
ictal EEG	Left central
PET	Left superior frontal
MRI	Negative
2 nd EEG-fMRI	Left superior frontal
3 rd Surgery	Left frontal (TAE 1)



EEG-fMRI: central fast activity
(n = 15, total duration: 31 sec)

epi_16399_f2.tif