



Minerva Access is the Institutional Repository of The University of Melbourne

Author/s:

Riddiough, GE;Hornby, ST;Asadi, K;Aly, A

Title:

Gastric adenocarcinoma of the upper oesophagus: A literature review and case report

Date:

2017-01-01

Citation:

Riddiough, G. E., Hornby, S. T., Asadi, K. & Aly, A. (2017). Gastric adenocarcinoma of the upper oesophagus: A literature review and case report. *International Journal of Surgery Case Reports*, 30 (C), pp.205-214. <https://doi.org/10.1016/j.ijscr.2016.11.014>.

Persistent Link:

<https://hdl.handle.net/11343/270501>

License:

[CC BY-NC-ND](#)



Contents lists available at ScienceDirect

International Journal of Surgery Case Reports

journal homepage: www.casereports.comGastric adenocarcinoma of the upper oesophagus: A literature review and case report[☆]Georgina E. Riddiough^{a,*}, Steve T. Hornby^a, Khashayar Asadi^b, Ahmed Aly^c^a Austin Health, Department of Upper GI Surgery, 145 Studley Road, Heidelberg 3084, Australia^b Austin Health, Department of Pathology, 145 Studley Road, Heidelberg 3084, Australia^c Head of Department of Upper GI Surgery, Austin Health, 145 Studley Road, Heidelberg 3084, Australia

ARTICLE INFO

Article history:

Received 21 September 2016

Received in revised form 8 November 2016

Accepted 10 November 2016

Available online 1 December 2016

Keywords:

Adenocarcinoma
Ectopic gastric mucosa
Gastric inlet patch
Oesophageal cancer

ABSTRACT

BACKGROUND: Ectopic gastric mucosa (EGM) otherwise termed gastric heterotopia or gastric inlet patch occurs in approximately 2.5% of the population. Adenocarcinoma uncommonly involves the upper oesophagus, rarely arising from gastric heterotopia or submucosal glands. Currently, there are 58 cases in the literature of oesophageal adenocarcinoma arising within areas of EGM. To date no paper has differentiated between gastric or intestinal type adenocarcinoma. This case, which describes adenocarcinoma arising within EGM, exhibited a different immunophenotype reminiscent of gastric type glands, in the absence of intestinal metaplasia. This case should be regarded as a different type of carcinoma, consistent with a non-Barrett's oesophagus-associated adenocarcinoma.

CLINICAL PRESENTATION: A 63 year old female presented with a three month history of progressive cervical dysphagia with no associated weight loss or general malaise. Gastroscopy revealed a suspicious lesion at the cricopharyngeus. Positron emission tomography demonstrated a metabolically active primary lesion without evidence of distant disease. The patient received neo-adjuvant chemotherapy followed by a three stage total oesophagectomy. Histology demonstrated a moderately differentiated adenocarcinoma with gastric immunophenotype and background changes of gastric heterotopia.

CONCLUSION: EGM is common but scarcely biopsied for evidence of dysplasia or adenocarcinoma. Whilst malignant progression is rare it is important that endoscopists are aware of the potential. Determining the exact type of adenocarcinoma may have implications for therapeutic approaches.

Recognition of EGM at endoscopy may identify patients at greater risk of developing adenocarcinomas of the proximal oesophagus, however, this relationship and the necessity for screening requires more study.

© 2016 The Author(s). Published by Elsevier Ltd on behalf of IJS Publishing Group Ltd. This is an open access article under the CC BY-NC-ND license (<http://creativecommons.org/licenses/by-nc-nd/4.0/>).

1. Introduction

The incidence of oesophageal cancer is increasing and currently affects in excess of 450,000 people each year worldwide [1]. Most commonly squamous cell carcinoma arises within the proximal third of the oesophagus and less often adenocarcinoma occurs within the distal third of the oesophagus in association reflux and Barrett's metaplasia. Adenocarcinoma within the proximal oesophagus and unrelated to Barrett's metaplasia are extremely rare and arise either from foci of EGM or submucosal glands. At least 58

cases of oesophageal carcinoma arising in an area of ectopic gastric mucosa (EGM), also referred to as gastric inlet patch or gastric heterotopia, have been reported in the literature. However this is the first to describe an adenocarcinoma arising within the proximal oesophagus within an area of EGM that has exhibited gastric immunophenotype.

1.1. Pathogenesis of ectopic gastric mucosa

The aetiology of EGM is poorly understood. Currently, two main theories exist to explain the pathogenesis. The most widely accepted of these is that EGM is an embryological remnant. Incomplete embryological replacement of columnar mucosa by squamous epithelium leads to the development of remnant patches of columnar epithelium which differentiate into gastric mucosa [2,3].

The alternative theory proposes that EGM, in a similar way to Barrett's oesophagus, is an acquired condition as a result of gastro-oesophageal reflux disease [4]. One study found that the immunohistochemical staining of an adenocarcinoma arising

Abbreviations: EGM, ectopic gastric mucosa; CK, cytokeratin; PET, positron emission tomography; FDG, fludeoxyglucose; CT, computed tomography; EC, Epirubicin, cisplatin, fluorouracil 5FU; MUC, mucins.

[☆] No grants or other assistance to declare.

* Corresponding author at: Austin Health, Department of Upper GI Surgery, 145 Studley Road, Heidelberg 3084, Australia.

E-mail address: griddiough@doctors.org.uk (G.E. Riddiough).

<http://dx.doi.org/10.1016/j.ijscr.2016.11.014>

2210-2612/© 2016 The Author(s). Published by Elsevier Ltd on behalf of IJS Publishing Group Ltd. This is an open access article under the CC BY-NC-ND license (<http://creativecommons.org/licenses/by-nc-nd/4.0/>).

within a patch of EGM, shared the same pattern of staining as that of Barrett's metaplasia, that is CK7 positive and CK20 negative staining. They concluded from this that EGM and Barrett's must have a common pathogenesis. However, whilst EGM itself may be a congenital condition, exposure to acid, either secreted from parietal cells within the EGM or refluxing caudally from the stomach, may lead to the acquired changes known to cause Barrett's and hence explain the immunohistochemical staining.

1.2. Development of invasive carcinoma within areas of ectopic gastric mucosa

It is widely accepted that Barrett's oesophagus can lead to the development of adenocarcinoma as a result of successive dysplastic changes culminating in invasive carcinoma [5]. This metaplasia-dysplasia sequence could also be the cause of adenocarcinomas arising in EGM, especially considering that EGM likely contains parietal cells that secrete hydrochloric acid locally, and thus induce the metaplasia-dysplasia pathway. However, in this case, no intestinal metaplasia was found histologically and the presence of EGM raised the possibility of a different pathway of carcinogenesis in this tumour.

2. Presentation of case

A 63 year old female initially presented with a 4 month history of progressive cervical dysphagia with no associated weight loss or malaise. Risk factors for cancer included being an ex-smoker and daily alcohol consumption. Her other medical history included hypertension and hypercholesterolaemia.

2.1. Investigations

- Barium swallow – demonstrated a smooth lesion at the level of the cricopharyngeus extending from the inferior border of C6 to inferior border of T2. The remaining oesophagus appeared normal.
- Gastroscopy – confirmed the presence of a suspicious lesion within the upper oesophagus situated immediately below the cricopharyngeus as well as mild oesophagitis, prepyloric gastritis and duodenitis. *H. pylori* and standard biopsies were obtained.
- Histopathology – a moderately differentiated adenocarcinoma of gastric type with variable glandular, villiform and papillary architecture with marked cytological and nuclear atypia, as well as marked inflammation was found in the biopsies taken from the proximal oesophageal lesion.
- Staging CT – invasion into the adjacent mediastinal fat but no definite invasion of the great vessels or trachea and no definite lymphadenopathy could be identified.
- PET scan – revealed an FDG-avid right sided para-oesophageal lymph node and confirmed the absence of any distant FDG-avid disease.
- Bronchoscopy and endobronchial ultrasound were also performed and demonstrated no invasion of the airway structures.
- Clinical staging was cT3 N0.

The patient was discussed at a multidisciplinary meeting and the decision was made to proceed with neoadjuvant chemotherapy. The patient received ECF neoadjuvant chemotherapy.

2.2. Operative findings and technique

After completion of induction chemotherapy the patient underwent a three stage total oesophagectomy.

A 2 cm tumour within the upper oesophagus was found 19 cm distal to the oral cavity and 5 cm distal to the pharynx. There was no

evidence of macroscopic metastatic disease in the abdomen, neck or chest. Enlarged, but soft, para-oesophageal nodes were noted in the upper mediastinum.

Thoracoscopic mobilisation of the oesophagus was performed with clearance of the upper para-oesophageal nodes. A left neck incision was made along the anterior border of sternocleidomastoid through which the oesophagus was completely mobilised up to the larynx. At this point, it was felt that the tumour could be completely resected without performing laryngectomy. A prophylactic tracheostomy was performed.

The cervical oesophagus was divided 2 cm proximal to the tumour. A single layered end to side, oesophago-gastric anastomosis was fashioned with 3.0 PDS. A nasogastric tube was placed across the anastomosis.

A pyloromyotomy was performed and a feeding jejunostomy placed.

2.3. Histology

Histological examination of the specimen revealed a non-Barrett's associated gastric type adenocarcinoma arising within an area of ectopic gastric mucosa in the upper oesophagus (Fig. 1), in the absence of any intestinal metaplasia. Adjacent areas of high grade dysplasia of gastric/foveolar type were noted.

Immunohistochemical staining revealed the tumour was CK7 strongly and diffusely positive (Fig. 2), with only patchy-weak CK20 expression. Also, there was strong diffuse expression of MUC-1 (Fig. 3), as well as MUC-5AC (Fig. 4) but only sparse MUC-2 staining and no CDX-2 labeling. This immunoprofile and lack of Barrett's oesophagus is consistent with non-intestinal phenotype adenocarcinoma of the upper gastro-intestinal tract. The tumour was limited to the deep submucosa with no invasion into the muscularis propria or lymph node involvement. Pathological stage was ypT1b N0.

3. Follow up

The patient is currently disease free 20 months post surgery. The patient had gastroscopies 2–5 months post operatively for management of dysphagia secondary to anastomotic stricture. These procedures demonstrated no evidence of macroscopic tumour recurrence. Notably, no were biopsies obtained. The last surveillance CT scan demonstrated no evidence of disease recurrence. 11 months post surgery the patient presented with nausea and vomiting secondary to small bowel obstruction. An emergency laparotomy and adhesiolysis was performed which also confirmed the absence of any intra-abdominal metastasis.

4. Literature review

We searched Ovid and Embase databases using the search terms 'ectopic gastric mucosa', 'heterotopic gastric mucosa', gastric inlet patch' and 'adenocarcinoma'. We also yielded results from the reference lists of papers identified in this search.

5. Results

In total 58 cases of adenocarcinoma arising within EGM in the proximal oesophagus were identified in 52 papers (Table 1). Two papers could not be obtained in English full text, Frezza et al. and Armstrong et al. In the majority of papers the finding of intestinal metaplasia was not reported on (n = 42). Only 3 cases reported finding intestinal metaplasia and 7 cases reported on the absence of intestinal metaplasia. Cases of adenocarcinoma arising EGM have been reported worldwide (Table 2), interestingly the majority of cases have been reported in Japan. Median age 64 (43–88) years

Table 1
Table of all papers reporting cases of adenocarcinoma arising within ectopic gastric mucosa.

No.	Paper	Country	Year	Age	Gender	TNM	LVI	Histology	Intestinal Metaplasia	Treatment	Follow Up
1	A Carrie{CARRIE:1950vk}	UK	1950	64	M	pT2NXM0		Adenocarcinoma	?	Subtotal oesophagectomy	1 year, no recurrence, alive
2	BC Morson{MORSON:1952ci}	UK	1952	56	M	cT3N1M1		Adenocarcinoma (high grade)	N	Subtotal oesophagectomy	2 months, alive
3	Frezza LG	Italy	1956								
4	Armstrong		1959								
5	H A Raphael{Raphael:1966ci}	USA	1966	75	M			Adenocarcinoma (grade 3)		Radiotherapy and dilatation	34 months, died
6				76	F			Adenocarcinoma (grade 1)		Patient refused treatment	18 months, died
7				69	M			Adenoma of mucous gland		Radiotherapy and dilatation	4 months, committed suicide
8	W M Davis{Davis:1969ts}		1969	68	M	pT1NXM0		Adenocarcinoma, mucinous		Radiotherapy and oesophagectomy	7 months, alive, no recurrence
9	G Sakamoto{Sakamoto:1970uo}	Japan	1970	64	M	pT2N0M0		Adenocarcinoma		Oesophagectomy	10 months, died
10	P Jernstrom{Jernstrom:1970vs}	USA	1970	73	M	pT3N0M0		Poorly differentiated adenocarcinoma		Radiotherapy and oesophagectomy	4 months, died
11	C Clemente {Clemente:1974up}	Italy	1974	53	M	pT3		Adenocarcinoma		Oesophagectomy	10 months, recurrence
12	B Danoff{Danoff:1978vk}	USA	1978	43	M	cT4N0M0		Poorly differentiated adenocarcinoma		Radiotherapy	9 months, died
13	H Schmidt {Schmidt:1985tq}	Germany	1985	54	M						
14				37	M	pT3NXMX		Adenocarcinoma		Oesophagectomy	4 months, died
15	O Goeau-Brissoniere {GoeauBrissoniere:1985wi}	France	1985	38	M	pT3		Adenocarcinoma		Oesophagectomy	
16	W N Christensen{Christensen:1987wi}	USA	1987	52	M	pT2N1M0		Poorly differentiated adenocarcinoma		Oesophagectomy	25 months, recurrence
17				50	M	pT3N1M0		Moderately differentiated adenocarcinoma		Oesophagectomy	unknown
18	S X Bai{Bai:1989wa}	China	1989								
19	K Ishii{Ishii:1991tn}	Japan	1991	66	M	cT3N?		Well differentiated tubular adenocarcinoma	N	Oesophagectomy	20 months, alive no recurrence
20	Takagi Y{TAKAGI:1994gc}	Japan	1994	85	M	A2NXM0Plx		Poorly differentiated adenocarcinoma			Unknown
21	Kubota S{S:1993tc}		1993	58	M						
22	R M Sperling{Sperling:1995uf}	USA	1995	79	M	cT4N0M0		Poorly differentiated adenocarcinoma		Radiotherapy	Unknown

Table 1 (Continued)

No.	Paper	Country	Year	Age	Gender	TNM	LVI	Histology	Intestinal Metaplasia	Treatment	Follow Up
23	A Takagi{Takagi:1995tw}	Japan	1995	70	M	pT1N0M0	N	Well differentiated tubular adenocarcinoma	?	Oesophagectomy	Unknown
24	Mion F{Mion:1996et}	France	1996	45	M	uT1N0MX	N	Tubulovillous adenoma with high grade dysplasia	N	Subtotal oesophagectomy	Unknown
25	Kammori M	Japan	1996	74	F	pT1N0M0		Well differentiated adenocarcinoma		Subtotal oesophagectomy	Unknown
26	S Pai{Pai:1997wc}	India	1997	60	M	pT2N0M0		Poorly differentiated adenocarcinoma		Oesophagectomy and chemoradiotherapy	24 months, recurrence
27	C Berkelhammer{Berkelhammer:1997tk}	USA	1997	71	M	pT1bN1M0		Moderately differentiated adenocarcinoma	N	Oesophagectomy	24 months, alive, no recurrence
28	G Y Lauwers{Lauwers:1998us}	USA	1998	57	M	cT4or3, N0,M0	N	Moderately differentiated adenocarcinoma, mucinous and papillary	Y	Oesophagectomy, total laryngectomy and partial pharyngectomy, adjuvant radiotherapy	8 months, alive, no recurrence
29	O Pech{Pech:2001wo}	Germany	2001	77	M	pT1bN0M0	N	Well differentiated adenocarcinoma	?	EMR	12 months, alive, no recurrence
30	J M Klaase{Klaase:2001ki}	Netherlands	2001	66	M	pT4N1M0		High grade dysplasia within EGM		Endoscopic mucosal ablation	16 months, alive
31				43		pT4N1M0		Poorly differentiated adenocarcinoma		Subtotal oesophagectomy	4 months, died
32	T Noguchi{Noguchi:2001wv}	Japan	2001	73	M	pT1NXMX	?	Well differentiated adenocarcinoma		Subtotal oesophagectomy, laryngectomy and pharyngectomy	5 years, no recurrence
33	Denis Chatelain{Chatelain:2002wp}	France	2002	61	M	cT4N0M0	?	Poorly differentiated adenocarcinoma	Y	Subtotal oesophagectomy	15 months, died, recurrence
34	Jean-Michel Balon{Balon:2003wn}	France	2003	61	M	pT3NXM0		Adenocarcinoma		Oesophagectomy	21 months, died
35	Nobuo Hirayama{Hirayama:2003hy}	Japan	2003	77		pT1N0M0	N	Well differentiated papillotubular adenocarcinoma	?	EMR	31 months, alive
36	Tatsuya Abe{Abe:2004ue}	Japan	2004	50	M	pT1bN0M0	N	Well differentiated adenocarcinoma	?	Oesophagectomy	18 months, alive, no recurrence
37	Kagawa N{N:2004un}	Japan	2004	51	M	?	?	Moderately differentiated adenocarcinoma	?	Subtotal oesophagectomy	11 months, died, recurrence
38	S J Alrawi{Alrawi:2005vz}	USA	2005	60	M	pT1N0M0		Moderately differentiated adenocarcinoma		Subtotal oesophagectomy, adjuvant chemo9radiation	6 years, alive
39	von Rahden{vonRahden:2005cw}	Germany	2005	52	M	cT3N1M0		Moderately differentiated tubulo-papillary adenocarcinoma		Neoadjuvant chemo-rad Oesophagectomy	3 years, alive
40	Hayashi T{T:2005tt}	Japan	2005	72	F	cT1N0M0		Low grade dysplasia in an adenoma, arising in EGM		EMR	3 years, alive
41	Hakan Alagozlu{Alagozlu:2007ku}	Turkey	2007	57	M	cT4N1M0		Poorly differentiated adenocarcinoma		Oesophageal stent	Lost to FU
42	Hoshino A{Hoshino:2007ef}	Japan	2007	74	M	pT3N0M0		Adenocarcinoma, papillary		Oesophagectomy	5 months, recurrence

43	Shuji Komori{Komori:2010kl}	Japan	2010	75	M	pT2N0M0	N	Moderately differentiated tubular adenocarcinoma	?	Subtotal oesophagectomy	3.5 years alive, no recurrence
44	Yoshida T{Yoshida:2010ck}	Japan	2010	79	M	cT1N0M0,	N	Moderately differentiated adenocarcinoma	?	EMR	2 years, alive, no recurrence
45	Hirano A{A:2010uy}	Japan	2010	57	M	?		Adenocarcinoma	Y	Subtotal oesophagectomy	
46	Ando T{T:2010tf}	Japan	2010	64	M	pT1aN0M0		Well differentiated adenocarcinoma	?	Subtotal oesophagectomy	
47	Bard A{A:2011uh}	France	2011	87	M	cT3N1M0		Moderately differentiated adenocarcinoma			17 months, died
48	Iitaka D{Iitaka:2011il}	Japan	2011	64	M	uT1N0M0, pT1aN0M0	N	Well differentiated adenocarcinoma	?	Subtotal oesophagectomy	
49	Toshihiro Kitajima{Kitajima:2013ho}	Japan	2013	64	M	pT1bN0M0	N	Well differentiated tubular adenocarcinoma, mixed neuroendocrine tumour	?	Radical oesophagectomy	16 months, alive
50	K Nonaka{Nonaka:2013jw}	Japan	2013	74	M	pT1aN0M0		Atypical glandular structures arising in EGM		EMR	Unknown
51	Yash P Verma{Verma:2013hi}	India	2013	50	F	?		Poorly differentiated adenocarcinoma	?	Radiotherapy	3 months, alive
52	Naoki Akanuma{Akanuma:2013kk}	Japan	2013	57	M	pT2N0M0	N	Well – moderately differentiated adenocarcinoma, positive margins	N	Neoadjuvant chemo-rad Oesophagectomy Adjuvant chemo-rad	4 years, alive, no recurrence
53	Oliver Moschler{Moschler:2014km}	Germany	2014	83	M	pT1aN1M0	Y	Well differentiated adenocarcinoma	?	EMR	Unknown
54	Mariko Tanaka{Tanaka:2014ci}	Japan	2014	76	M	pT1N0M0	N	Well differentiated tubular adenocarcinoma	N	Subtotal oesophagectomy	19 months, alive
55	Bulent Yasar{Yasar:2014bw}	Turkey	2014	52	F	pT1N0M0	N	Well differentiated adenocarcinoma	?	EMR	3 months, alive
56	V R Hudspeth{Hudspeth:2014gu}	USA	2014	77	M	cT1N0M0		Moderately differentiated adenocarcinoma	N	EMR and argon plasma coagulation to margins RFA	12 months, alive, no recurrence
57	Payne J{J:0qm1NLVz}	USA	2015	88	M	cT?N2M1		Moderately differentiated adenocarcinoma	N	Palliative Chemo-rad	10 months, alive
58	Amjal S{Ajmal:2015ei}		2015	57	M	pT1bN0M0	?	Well – moderately differentiated adenocarcinoma	?	Oesophagectomy	Unknown

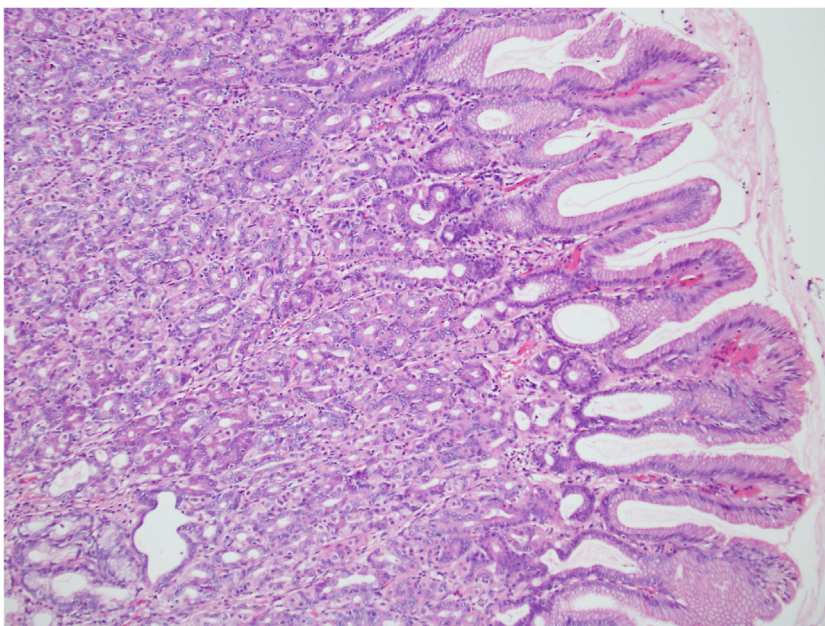


Fig. 1. Medium power image of ectopic gastric mucosa within the proximal oesophagus.

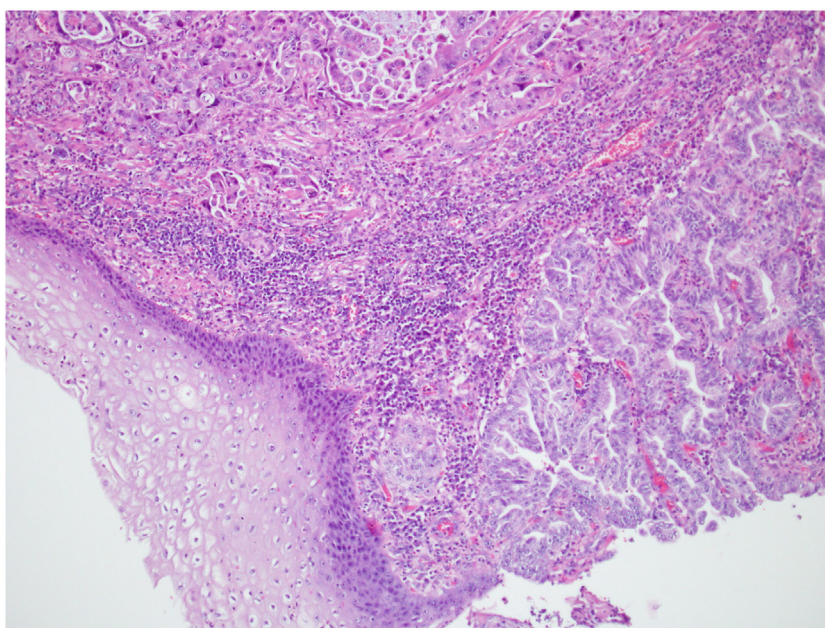


Fig. 2. Adenocarcinoma of the upper oesophagus with variable morphology including papillary and micropapillary patterns adjacent to normal squamous mucosa.

(Table 2). The vast majority of patients were male. Median follow up time 16 months. The majority (57%) of patients underwent surgical management without adjuvant or neoadjuvant chemoradiotherapy. 7 patients (12%) underwent endomucosal resection. O’Pech et. al reported the first case to be successfully treated with endomucosal resection in 2001 [6].

6. Discussion

Ectopic gastric mucosa is a well-recognised phenomenon, however, adenocarcinoma of the proximal oesophagus remains uncommon and many specialist upper gastrointestinal surgeons will never come across a case. The cases summarised here serve as an important reminder to endoscopists to be aware of gastric

inlet patches, whose prevalence has been estimated between 0.21% and 10% of the general population [7–9]. The prevalence of cancers arising within EGM does not warrant routine surveillance but attention should be paid to any visualised mucosal abnormality and in selected cases the use of narrowband imaging and specialized chromoendographic stains may be useful. Adenocarcinomas arising within EGM in the cervical oesophagus can often be missed by swiftly passing the scope through the upper oesophagus. Published literature demonstrates that, when found early, it is possible to successfully manage these cancers with endomucosal resection. In particular situations, for example where patients require prophylactic gastrectomy for genetic predisposition to gastric cancer (e.g. CDH-1), knowledge of EGM may prove important.

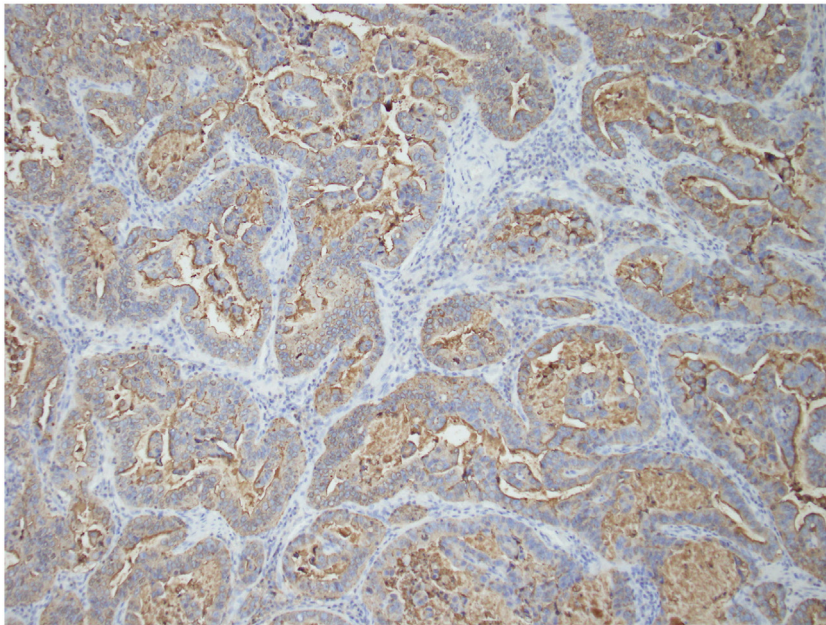


Fig. 3. Immunohistochemical staining with MUC-1 demonstrating strong positive apical expression.

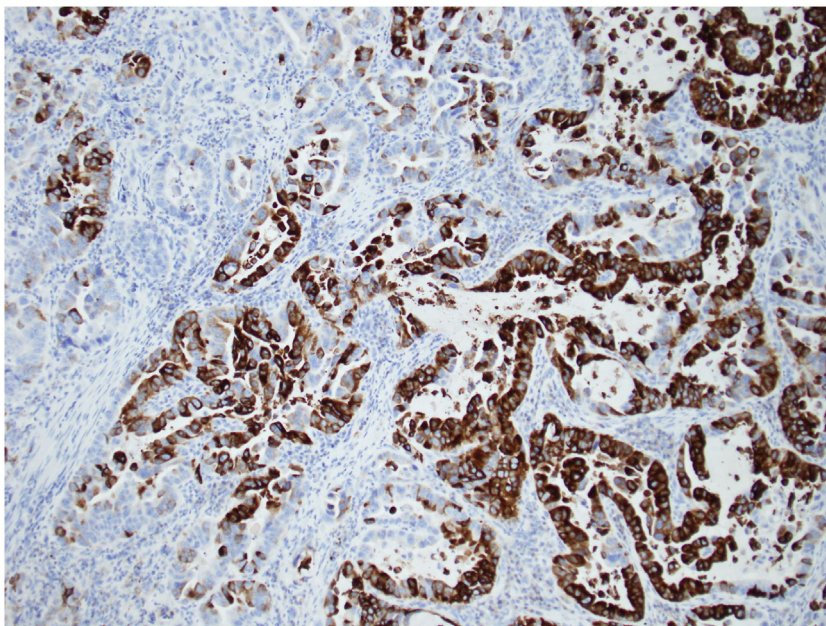


Fig. 4. Immunohistochemical staining demonstrating expression of MUC-5AC strongly suggestive of gastric type adenocarcinoma.

Immunohistochemical staining in this case demonstrated the tumour had a gastric immunophenotype. This tumour showed similar morphology to usual adenocarcinoma of the distal oesophagus including a papillary growth pattern. However, specialist immunohistochemical staining demonstrated the presence of adjacent gastric oxyntic type mucosa in the absence of Barrett's epithelium, which represents a gastric variant of adenocarcinoma currently regarded as non-Barrett's associated adenocarcinoma. Recent studies suggest that most Barrett-related carcinomas can be either gastric or intestinal type, with phenotypic stability during progression to cancer, supporting separate gastric and intestinal pathways of carcinogenesis [10]. In summary, the pathway of carcinogenesis in this case is clearly different to those adenocarcinomas associated with Barrett's, this is also supported by the absence of intestinal

metaplasia. The reporting of intestinal metaplasia amongst other case reports is highly variable, and in the majority of cases was not commented upon. Subsequently, it is difficult to draw any precise conclusions to the usual development of proximal oesophageal adenocarcinomas within EGM.

Where cases of adenocarcinomas arise in unusual locations we would recommend the use of immunohistochemical stains such as MUC-1, MUC-2, MUC-5AC, MUC-6 and CDX2, in addition to the more commonly used stains CK7 and CK20, as well as careful sampling of background mucosa to help differentiate between intestinal type and non-intestinal type adenocarcinomas. Most surgeons and endoscopists consider EGM to be a rare and benign phenomenon but this case reminds us that malignant transformation can occur within these areas.

Table 2
Summarised data of gastric adenocarcinomas of the upper oesophagus.

Age (median (range))	64 (43–88)
Male:Female	43:5
Follow up (months) (median (range))	16 (3–72)
Pathology	
Well	13, 22%
Moderate	11, 19%
Poorly	10, 17%
Other	19, 33%
Unknown	5, 9%
Management	
Surgical only	27, 47%
Neoadjuvant chemo and surgery	4, 10%
Surgery and adjuvant chemo/rad	3, 5%
Radiotherapy only	6, 10%
EMR	7, 12%
Palliative	1, 2%
Other	3, 5%
Unknown	5, 9%

7. Conclusion

This literature review of adenocarcinomas arising from EGM within the proximal oesophagus is the most complete to date. We discovered 55 papers reporting 58 cases of adenocarcinoma arising within EGM dating back to 1950. The management of these cases has evolved over time, but overwhelmingly the most common strategy has been oesophagectomy. More recently, small carcinomas confined to the submucosal surface have been successfully managed with endomucosal resection [11–13]. Ours is the first case to describe true gastric type adenocarcinoma arising within ectopic gastric mucosa in the proximal oesophagus. In summary, we can propose two different pathways for the pathogenesis of adenocarcinoma within EGM:

1. Induction of metaplasia-dysplasia pathway via locally secreted acid or refluxed acid leading to intestinal metaplasia and an intestinal type adenocarcinoma
2. Intrinsic development of adenocarcinoma within gastric/foveolar cells in EGM leading to gastric type adenocarcinoma

EGM although common is scarcely biopsied, whilst malignant progression is very rare, endoscopists and surgeons should be weary of the potential. The relationship between EGM and the risk for developing proximal adenocarcinomas requires much larger, population studies.

Conflicts of interest

Nil.

Funding

Nil.

Ethical approval

Not applicable.

Consent

Yes written consent obtained.

Author contribution

Ahmed Aly – conceptualisation of case report.

G Riddiough – data collection, writing of paper.

S Hornby – writing of paper.

K Asadi – interpretation of histology and immunohistochemistry results for paper.

Guarantor

Ahmed Aly.

References

- [1] World Cancer Research Fund International. Available at <http://www.wcrf.org/int/cancer-facts-figures/data-specific-cancers/oesophageal-cancer-statistics>.
- [2] M. Tanaka, T. Ushiku, M. Ikemura, J. Shibahara, Y. Seto, M. Fukayama. Esophageal adenocarcinoma arising in cervical inlet patch with synchronous Barrett's esophagus-related dysplasia, *Pathol. Int.* 64 (August (8)) (2014) 397–401.
- [3] B.H.A. von Rahden, H.J. Stein, K. Becker, D. Liebermann-Meffert, J.R. Siewert, Heterotopic gastric mucosa of the esophagus: literature-review and proposal of a clinicopathologic classification. *Am. J. Gastroenterol.* Nature Publishing Group (2004) 99 (March (3)) 543–551.
- [4] B. Avidan, A. Sonnenberg, G. Chejfec, T.G. Schnell, S.J. Sontag, Is there a link between cervical inlet patch and Barrett's esophagus?, *Gastrointest. Endosc.*, Elsevier, (2001) 53 (June (7)) 717–721.
- [5] R. Milind, S.E. Attwood, Natural history of Barrett's esophagus, *World J. Gastroenterol.* 18 (July (27)) (2012) 3483–3491.
- [6] O. Pech, A. May, L. Gossner, M. Vieth, F. Trump, M. Stolte, et al., Early stage adenocarcinoma of the esophagus arising in circular heterotopic gastric mucosa treated by endoscopic mucosal resection, *Gastrointest. Endosc.* 54 (November (5)) (2001) 656–658.
- [7] Y.-R. Chen, M.-M. Wu, Q. Nan, L.-P. Duan, Y.-L. Miao, X.-Y. Li, Heterotopic gastric mucosa in the upper and middle esophagus: 126 cases of gastroscopically and clinical characteristics, *Hepatogastroenterology* 59 (June (116)) (2012) 1123–1125.
- [8] V.H. Chong, Clinical significance of heterotopic gastric mucosal patch of the proximal esophagus, *World J. Gastroenterol.* 19 (January (3)) (2013) 331–338.
- [9] A. Rodríguez-Martínez, J.C. Salazar-Quero, C. Tutau-Gómez, B. Espín-Jaime, M. Rubio-Murillo, A. Pizarro-Martín, Heterotopic gastric mucosa of the proximal esophagus (inlet patch): endoscopic prevalence, histological and clinical characteristics in paediatric patients, *Eur. J. Gastroenterol. Hepatol.* 26 (October (10)) (2014) 1139–1145.
- [10] T.S. Khor, E.E. Alfaro, E.M.M. Ooi, Y. Li, A. Srivastava, H. Fujita, et al., Divergent expression of MUC5AC, MUC6, MUC2, CD10, and CDX-2 in dysplasia and intramucosal adenocarcinomas with intestinal and foveolar morphology: is this evidence of distinct gastric and intestinal pathways to carcinogenesis in Barrett Esophagus? *Am. J. Surg. Pathol.* 36 (March (3)) (2012) 331–342.
- [11] K. Nonaka, M. Watanabe, H. Yuruki, A. Okuda, K. Sakurai, K. Iyama, et al., Narrow band imaging of adenocarcinoma arising from ectopic gastric mucosa in the upper esophagus, *Endoscopy*. © Georg Thieme Verlag KG (2013) 45 (Suppl. 2) UCTN(S 0 2) E112–E113.
- [12] N. Hirayama, M. Arima, S.-I. Miyazaki, H. Shimada, S.-I. Okazumi, H. Matsubara, et al., Endoscopic mucosal resection of adenocarcinoma arising in ectopic gastric mucosa in the cervical esophagus: case report, *Gastrointest. Endosc.* 57 (February (2)) (2003) 263–266.
- [13] O. Möschler, M. Vieth, M.K. Müller, Endoscopic resection of an adenocarcinoma occurring in ectopic gastric mucosa within the proximal esophagus, *Endoscopy*. © Georg Thieme Verlag KG (2014) 46 (Suppl. 1) UCTN(S 01) E24–E25.

Further reading

[14] A. Carrie. Adenocarcinoma of the upper end of the oesophagus arising from ectopic gastric epithelium *Br. J. Surg.* 1950, 37 (April (148)) 474.

[15] B.C. Morson, J.R. Belcher Adenocarcinoma of the oesophagus and ectopic gastric mucosa, *Br. J. Cancer.* Nature Publishing Group (1952) 6 (June (2)) 127–130.

[16] L.G. Frezza. Primary adenocarcinoma of the superior third of esophagus on islands of heterotopic gastric mucosa *Ann. Ital. Chir.* 1956, 33 (4) 361–370.

[17] R.A. Armstrong, G.M. Carrera, J.B. Blalock. Adenocarcinoma of the middle third of the esophagus arising from ectopic gastric mucosa *J. Thorac. Surg.* 1959, 37 (March (3)) 398–403.

[18] H.A. Raphael, F.H. Ellis, M.B. Dockerty, Primary adenocarcinoma of the esophagus: 18-year review and review of literature, *Ann. Surg. Lippincott, Williams, and Wilkins* (1966) 164 (November (5)) 785–796.

- [19] W.M. Davis, M.N. Goodwin, H.C. Black, J.C. Hawk. Polypoid adenocarcinoma of the cervical esophagus Arch. Pathol. 1969, 88 (October (4)) 367-370.
- [20] G. Sakamoto, K. Nakamura, K. Saito, M. Sato, T. Sugahara. Primary adenocarcinoma of the esophagus arising from heterotopic gastric glands Gan No Rinsho. 1970, 16(November (11)) 1105-1110.
- [21] P. Jernstrom, L.A. Brewer. Primary adenocarcinoma of the mid-esophagus arising in ectopic gastric mucosa with associated hiatal hernia and reflux esophagitis (Dawson's syndrome) Cancer 1970, 26 (December (6)) 1343-1348.
- [22] C. Clemente. A case of adenocarcinoma of the upper third of the esophagus arising on ectopic gastric tissue (author's transl) Tumori 1974, 60 (January (1)) 17-24.
- [23] B. Danoff, J. Cooper, M. Klein. Primary adenocarcinoma of the upper oesophagus Clin. Radiol. 1978, 29 (September (5)) 519-522.
- [24] H. Schmidt, R.H. Riddell, B. Walther, D.B. Skinner, J.F. Riemann, H. Grottl. Adenocarcinoma of heterotopic gastric mucosa in the proximal esophagus Leber. Magen. Darm. 1985, 15 (July (4)) 144-147.
- [25] O. Goëau-Brissonnière, L. Hannoun, C. Huguët. Adenocarcinoma of the cervical esophagus. Association with a gastric heterotopia J. Chir. (Paris) 1985, 122 (February (2)) 101-103.
- [26] W.N. Christensen, S.S. Sternberg. Adenocarcinoma of the upper esophagus arising in ectopic gastric mucosa. Two case reports and review of the literature Am. J. Surg. Pathol. 1987, 11 (May (5)) 397-402.
- [27] S.X. Bai. Primary esophageal adenocarcinoma—report of 19 cases Zhonghua Zhong Liu Za Zhi. 1989, 11 (September (5)) 383-385.
- [28] K. Ishii, H. Ota, J. Nakayama, T. Katsuyama, K. Matsuzawa, T. Honda, et al. Adenocarcinoma of the cervical oesophagus arising from ectopic gastric mucosa: The histochemical determination of its origin Virchows Arch. A Pathol. Anat. Histopathol. 1991, 419 (2) 159-164.
- [29] Y. Takagi, S. Sato, O. Koganezawa, M. Moritani, N. Kuroda, Y. Osaka, et al. A case of primary upper intra-thoracic esophageal adenocarcinoma in ectopic gastric mucosa in an elderly patient J. Jpn. Pract. Surg. Soc. 1994, 55 (2) 390-394.
- [30] S. Kubota, et al. A case of adenocarcinoma of the cervical esophagus arising from heterotopic gastric mucosa Endosc. Dig. 1993, 5 1255-1260.
- [31] R.M. Sperling, J.H. Grendell. Adenocarcinoma arising in an inlet patch of the esophagus Am. J. Gastroenterol. 1995, 90 (January (1)) 150-152.
- [32] A. Takagi, Y. Ema, S. Horii, M. Morishita, O. Miyaishi, I. Kino. Early adenocarcinoma arising from ectopic gastric mucosa in the cervical esophagus Gastrointest. Endosc. 1995, 41 (February (2)) 167-170.
- [33] F. Mion, R. Lambert, C. Partensky, M. Cherkaoui, F. Berger. High-grade dysplasia in an adenoma of the upper esophagus developing on heterotopic gastric mucosa Endoscopy 1996, 28 (September (7)) 633-635.
- [34] S. Pai, R. Deshpande, K.N. Naresh. Adenocarcinoma of cervical esophagus arising in aberrant gastric mucosa Indian J. Gastroenterol. 1997; 16: (October (4)) 157-158.
- [35] C. Berkelhammer, M. Bhagavan, A. Templeton, R. Raines, J. Walloch. Gastric inlet patch containing submucosally infiltrating adenocarcinoma J. Clin. Gastroenterol. 1997, 25 (December (4)) 678-681.
- [36] G.Y. Lauwers, G.V. Scott, J.N. Vauthey. Adenocarcinoma of the upper esophagus arising in cervical ectopic gastric mucosa: rare evidence of malignant potential of so-called inlet patch Dig. Dis. Sci. 1998, 43 (April (4)) 901-907.
- [37] J.M. Klaase, L.C. Lemaire, E.A. Rauws, G.J. Offerhaus, J.J. van Lanschot. Heterotopic gastric mucosa of the cervical esophagus: a case of high-grade dysplasia treated with argon plasma coagulation and a case of adenocarcinoma Gastrointest. Endosc. 2001, 53 (January (1)) 101-104.
- [38] T. Noguchi, S. Takeno, Y. Takahashi, T. Sato, Y. Uchida, S. Yokoyama. Primary adenocarcinoma of the cervical esophagus arising from heterotopic gastric mucosa J. Gastroenterol. 2001, 36 (October (10)) 704-709.
- [39] D. Chatelain, A.-S. de Lajarte-Thirouard, E. Tiret, J.-F. Flejou. Adenocarcinoma of the upper esophagus arising in heterotopic gastric mucosa: common pathogenesis with Barrett's adenocarcinoma? Virchows Arch. 2002, 441 (October (4)) 406-411.
- [40] J.-M. Balon, C. Mariette, S. Fabre, E. Tiret, J.-P. Triboulet. Primary adenocarcinoma of the cervical esophagus arising from heterotopic gastric mucosa Gastroenterol. Clin. Biol. 2003, 27 (August (8-9)) 836-838.
- [41] T. Abe, M. Hosokawa, T. Kusumi, M. Kusano, K. Hokari, H. Kagaya, et al. Adenocarcinoma arising from ectopic gastric mucosa in the cervical esophagus Am. J. Clin. Oncol. 2004, 27 (December (6)) 644-645.
- [42] N. Kagawa, et al. A case of esophageal adenocarcinoma arising from ectopic gastric mucosa in the cervicothoracic esophagus J. Jpn. Surg. Assoc. 2004, 65 2637-2641.
- [43] S.J. Alrawi, J. Winston, D. Tan, J. Gibbs, T.R. Loree, W. Hicks, et al. Primary adenocarcinoma of cervical esophagus J. Exp. Clin. Cancer Res. 2005, 24 (June (2)) 325-330.
- [44] B.H.A. von Rahden, H.J. Stein, K. Becker, R.J. uuml diger Siewert. Esophageal adenocarcinomas in heterotopic gastric mucosa: review and report of a case with complete response to neoadjuvant radiochemotherapy Dig. Surg. 2005, 22 (1-2) 107-112.
- [45] T. Hayashi, K. Takizawa, K. Kobayashi, N. Watanabe, T. Ikarashi. Low-grade dysplasia in an adenomatous polyp of the esophagus developing on pyloric-type heterotopic gastric mucosa treated with endomucosal resection: a case report Esophagus 2005, 2 (December (4)) 205-208.
- [46] H. Alagozlu, M. Ergun, M. Cindoruk, S. Unal, S. Dumlu, A. Poyraz, et al. The rare presentations of a large polyp and an esophageal carcinoma in heterotopic gastric mucosa: a case series J. Med. Case Rep. BioMed Central Ltd. 2007, 1 (1) 127.
- [47] A. Hoshino, Y. Otuka, S. Nara, Y. Harihara, T. Konishi, A case of primary adenocarcinoma of the cervical esophagus arising from the ectopic gastric mucosa, Esophagus. Springer-Verlag (2007) 29, 4 (June (2)) 83-86.
- [48] S. Komori, S. Osada, Y. Tanaka, T. Takahashi, N. Nagao, K. Yamaguchi et al. A case of esophageal adenocarcinoma arising from the ectopic gastric mucosa in the thoracic esophagus Rare Tumors 2010, 2 (1) e5.
- [49] T. Yoshida, Y. Shimizu, M. Kato. Image of the month. Use of magnifying endoscopy to identify early esophageal adenocarcinoma in ectopic gastric mucosa of the cervical esophagus Clin. Gastroenterol. Hepatol. 2010, 8 (September (9)) e91-e93.
- [50] A. Hirano, et al. A case of early adenocarcinoma of the cervical esophagus arising from the heterotopic gastric mucosa Gastroenterol. Endosc. 2010, 52 (June (6)) 1533-1540
- [51] T. Ando. Double Cancer of Adenocarcinoma of the Cervical Esophagus Arising from Heterotopic Gastric Mucosa and Squamous Cell Carcinoma of the Lower Esophagus 2010.
- [52] A. Bard, T. Coton, C. De Biasi, M. Guisset. Adenocarcinoma of the upper esophagus Clin. Res. Hepatol. Gastroenterol. 2011, 35, 418-419
- [53] D. Iitaka, H. Fujiwara, A. Shiozaki, T. Kubota, T. Ando, Y. Murayama, et al., Double primary cancer of the esophagus consisting of ectopic gastric mucosa-derived adenocarcinoma and squamous cell carcinoma: a first case report, Esophagus. 8 ed. Springer Japan (2011) 8 (November (4)) 303-309.
- [54] T. Kitajima, S. Kaida, S. Lee, S. Haruta, H. Shinohara, M. Ueno, et al. Mixed adeno(neuro)endocrine carcinoma arising from the

ectopic gastric mucosa of the upper thoracic esophagus World J. Surg. Oncol. BioMed Central Ltd. 2013, 11 (1) 218.

[55] Y.P. Verma, A.K. Chauhan, R. Sen. Primary adenocarcinoma of the upper oesophagus *Ecancermedicalsecience* 2013, 7, 314

[56] N. Akanuma, I. Hoshino, Y. Akutsu, K. Shuto, T. Shiratori, T. Kono, et al., Primary esophageal adenocarcinoma arising from heterotopic gastric mucosa: report of a case, *Surg. Today*. Springer Japan (2013) 43 (April (4)) 446–451.

[57] B. Yasar, O. Tarcin, D. Benek, S. Goksel, Intramucosal adenocarcinoma arising from ectopic gastric mucosa in the upper esophagus treated successfully with endoscopic mucosal resection, *J. Gastrointest. Cancer*. Springer US (2014) 45 (Suppl. 1) (December (S1)) 201–204.

[58] V.R. Hudspeth, D.S. Smith, T. Pacicco, J.J. Lewis. Successful endoscopic resection of adenocarcinoma arising in an esophageal inlet patch *Dis. Esophagus* 2014 (June).

[59] J. Payne, J. Mobley, S. Radhi. Adenocarcinoma of the cervical esophagus in an 88-year-old male: a case report and review of the literature *J. Invest. Med.* 2015 (February)

[60] S. Ajmal, J.S. Young, T. Ng. Adenocarcinoma arising from cervical esophageal gastric inlet patch *J. Thorac. Cardiovasc. Surg.* 2015, 149 (June (6)) 1664–1665.

Open Access

This article is published Open Access at scimedirect.com. It is distributed under the [IJSCR Supplemental terms and conditions](#), which permits unrestricted non commercial use, distribution, and reproduction in any medium, provided the original authors and source are credited.