



Minerva Access is the Institutional Repository of The University of Melbourne

Author/s:

Koehler, A;Scheelings, TF;Gasser, RB

Title:

Cryptosporidium cf. avium in an inland-bearded dragon (*Pogona vitticeps*) - A case report and review of the literature

Date:

2020-12-01

Citation:


Koehler, A., Scheelings, T. F. & Gasser, R. B. (2020). *Cryptosporidium cf. avium* in an inland-bearded dragon (*Pogona vitticeps*) - A case report and review of the literature. *International Journal for Parasitology: Parasites and Wildlife*, 13, pp.150-159. <https://doi.org/10.1016/j.ijppaw.2020.09.004>.

Persistent Link:

<https://hdl.handle.net/11343/251656>

License:

[CC BY-NC-ND](#)



Invited article

Cryptosporidium cf. *avium* in an inland-bearded dragon (*Pogona vitticeps*) – A case report and review of the literature

Anson V. Koehler^{a,*}, T. Franciscus Scheelings^{a,b}, Robin B. Gasser^a

^a Faculty of Veterinary and Agricultural Sciences, The University of Melbourne, Parkville, Victoria 3010, Australia

^b Australian Wildlife Health Centre, Healesville Sanctuary, Zoos Victoria, Healesville, Victoria 3777, Australia



ARTICLE INFO

Keywords:

Actin gene

Cryptosporidium cf. *avium*

Inland bearded dragon

PCR-coupled sequencing

Pogona vitticeps

reptile

Small subunit of nuclear RNA (SSU)

ABSTRACT

Here, we report the first case of *Cryptosporidium* cf. *avium* from an inland bearded dragon (*Pogona vitticeps*) from a wildlife sanctuary in Victoria, Australia. Molecular characterisation was conducted by PCR-coupled sequencing of regions in the small subunit of nuclear RNA (SSU), *actin* and large subunit of nuclear RNA (LSU) genes. The sequences obtained grouped with those of *C. ornithophilus* and other *C. avium* genotypes/variants originating from reptiles or birds. We discuss this case in relation to the current state of knowledge of *C. avium* of birds and reptiles, considering provenance and environment (agricultural, pet industry, wildlife, zoo or wildlife park) as well as clinical context, and pathological changes associated with cryptosporidiosis in these host animals.

1. Introduction

Cryptosporidium sp. are apicomplexan gregarine parasites (Ryan et al., 2016) that typically infect epithelial cells of the gastrointestinal tracts of vertebrates (Chalmers and Davies, 2010). Currently, 41 species and ≥70 genotypes (Holubová et al., 2019) have been recorded in a wide range of host species (Zahedi et al., 2016). The commonest agents causing cryptosporidiosis in reptiles are *C. serpentis* (type A in snakes, type B in lizards), *C. varanii* (syn. *C. saurophilum*) in lizards as well as *C. ducismarci* and *C. testudines* in tortoises and alligators (Xiao et al., 2004; Pavlasek and Ryan, 2008; Jež;ková et al., 2016; Bogan, 2019; Huang et al., 2020).

Lizards can also harbour *C. avium*-related *Cryptosporidium* taxa (Latney and Wellehan, 2020) of the “*C. avium* clade” (Kubota et al., 2020), comprising *C. avium*, *C. cf. avium* and *C. ornithophilus* (formerly *C. avium* genotype II; Holubová et al., 2020). To date, there have been three reported cases of cryptosporidiosis in lizards caused by *C. avium* genotype V – now known as *C. avium* (see Holubová et al., 2016) – recorded in green iguanas (*Iguana*) with colitis and cystitis (Kik et al., 2011); *C. cf. avium* from spiny-tailed lizards (*Uromastyx* sp.) with catarrhal enteritis (Kubota et al., 2020); or *C. avium* from an inland bearded dragon (*Pogona vitticeps*) in Scotland, presenting with refractory conjunctivitis (Lewis et al., 2020).

Molecular detection or identification of *Cryptosporidium* using PCR-coupled tools is the most effective means of diagnosis, as microscopy

is often insufficiently sensitive, and cannot identify or delineate species (Jex et al., 2008; Ryan et al., 2014). Genetic markers in the small subunit of nuclear RNA (SSU), *actin*, 70 kDa heat shock protein (*hsp70*) and, recently, in the large subunit of nuclear RNA (LSU) genes have been used in these tools to identify and characterise *Cryptosporidium* taxa (Morgan et al., 2001; Ryan et al., 2003; Ng et al., 2006; Koehler et al., 2017).

In the present study, we employed a molecular approach to discover and characterise a member of the *C. avium* clade in an inland bearded dragon, native to central Australia (cf. Cogger, 2014), using PCR-coupled sequencing approach. This is the fourth record of a taxon of the *C. avium* clade from a reptile. The present case is discussed in relation to current state of knowledge of *C. avium* in birds and reptiles as well as clinical and pathological aspects.

2. Materials and methods

2.1. Case report

In August 2015, some reptiles in an mixed-species exhibit of centralian blue-tongues (*Tiliqua multifasciata*), spiny-tailed monitors (*Varanus acanthurus*) and inland-bearded dragons (*Pogona vitticeps*), at the Healesville Sanctuary (Victoria, Australia), had non-specific clinical signs, including lethargy and inappetence, and some animals died with no prominent signs of illness. A *post mortem* examination of a deceased centralian blue tongue revealed histological evidence of *Cryptosporidium*

* Corresponding author.

E-mail addresses: anson.koehler@unimelb.edu.au (A.V. Koehler), fscheelings@hotmail.com (T.F. Scheelings), robinbg@unimelb.edu.au (R.B. Gasser).

<https://doi.org/10.1016/j.ijppaw.2020.09.004>

Received 9 September 2020; Received in revised form 28 September 2020; Accepted 28 September 2020

Available online 2 October 2020

2213-2244/© 2020 The Authors. Published by Elsevier Ltd on behalf of Australian Society for Parasitology. This is an open access article under the CC BY-NC-ND

license (<http://creativecommons.org/licenses/by-nc-nd/4.0/>).

infection in the gastrointestinal tract, but the necrotic tissues taken were formalin-fixed and proved unsuitable for DNA-based testing. Faeces from the live spiny-tailed monitor and the inland-bearded dragon were collected for DNA analysis. Subsequently, the bearded dragon was euthanised due to a diagnosis of adenovirus infection and continued deterioration of this animal.

2.2. DNA extraction, PCR and sequencing

Genomic DNA was extracted from 0.25 g of faeces from the inland bearded dragon, the spiny-tailed monitor and a portion of the centralian blue-tongue's formalin-fixed gastrointestinal tract using the PowerSoil DNA Isolation Kit (MoBio, USA), according to the manufacturer's protocol. This DNA was subjected to PCR, targeting (individually) four distinct loci of nuclear DNA: *SSU*, *actin*, *hsp70* and *LSU*. Each PCR was conducted in a volume of 50 µl containing GoTaq Flexi buffer (Promega, USA), 3.0 mM of MgCl₂, 200 µM of each dNTP, 50 pmol of each primer, 1 U of GoTaq DNA polymerase (Promega, USA) and 2 µl of the genomic DNA sample. Known test-positive, test-negative and no-template controls were included in each step of each PCR run.

An *SSU* gene region (800 bp) was amplified by nested PCR, first using primers 18SiCF2 (forward: 5'-GAC ATA TCA TTC AAG TTT CTG ACC-3') and 18SiCR2 (reverse: 5'-CTG AAG GAG TAA GGA ACA ACC-3'), and then employing primers 18SiCF1 (forward: 5'-CCT ATC AGC TTT AGA CGG TAG G-3') and 18SiCR1 (reverse: 5'-TCT AAG AAT TTC ACC TCT GAC TG-3') (Ryan et al., 2003); for both PCR steps, cycling conditions were: 94 °C for 5 min (initial denaturation), followed by 45 cycles of 94 °C for 30 s (denaturation), 58 °C for 30 s (annealing) and 72 °C for 30 s (extension), and a final extension of 72 °C for 10 min.

An *actin* gene region (830 bp) was amplified by nested PCR, first using primers AII F1 (forward: 5'-ATG CCV GGW RTW ATG GTD GGT ATG-3') and Act6R (reverse: 5'-GGD GCA ACR ACY TTR ATC TTC-3'), and using primers AII F2 (forward: 5'-GAY GAR GCH CAR TCV AAR AGR GGT AT-3') and AII R1 (reverse: 5'-TTD ATY TTC ATD GTH GAH GGW GC-3') (Ng et al., 2006); for both PCR steps, the cycling conditions were: one cycle of 94 °C for 120 s (denaturation), 60 °C for 60 s (annealing) and 72 °C for 120 s (extension), followed by 50 cycles of 94 °C for 30 s (denaturation), 58 °C for 20 s (annealing) and 72 °C for 40 s (extension), and a final extension of 72 °C for 7 min.

Amplification of the *hsp70* gene region (450 bp) was attempted using primers HSPF4 (forward: 5'-GGT GGT GGT ACT TTT GAT GTA TC-3') and HSPR4 (reverse: 5'-GCC TGA ACC TTT GGA ATA CG-3') (Morgan et al., 2001). The cycling conditions were: cycling conditions were: 94 °C for 5 min (initial denaturation), followed by 35 cycles of 94 °C for 30 s (denaturation), 55 °C for 30 s (annealing) and 72 °C for 30 s (extension), and a final extension of 72 °C for 5 min. In addition, a portion of the *LSU* gene (~500 bp) was amplified previously (Koehler et al., 2017) using primer pairs LSU2040F/LSU3020R and LSU2065F/LSU2557R.

The intensity and size of amplicons were assessed by electrophoresis (7 V/cm) in 1.5% agarose gels. Following electrophoresis, gels were stained with ethidium bromide and their size estimated by comparison to ΦX174-*Hae*III (Promega, USA) markers. Aliquots (5 µl) of individual amplicons were treated with ExoSAP-IT (Affymetrix, USA), according to the manufacturer's instructions, and then subjected to direct, automated sequencing (BigDye Terminator v.3.1 chemistry, Applied Biosystems, USA) in both directions using the same primers as employed for the second PCR step. Sequences were deposited in GenBank under accession nos. KY882314 (*SSU*), MT746065 (*actin*) and KY882339 (*LSU*).

2.3. Sequences alignments

Sequences of the *SSU* and *actin* gene regions were trimmed and aligned (over consensus lengths of 661 bp and 804 bp, respectively) with those of representative *Cryptosporidium* taxa and outgroups using the program Muscle (Edgar, 2004), and alignments adjusted manually using the program Mesquite v.3.6.1 (Maddison and Maddison, 2015). The

percentages of pairwise differences in the *SSU* and *actin* sequences between selected *Cryptosporidium* taxa were calculated using Geneious Prime 2020.0.5 (www.geneious.com) (Table 1).

A shorter alignment (Fig. 1) of partial *SSU* (400 bp) was also performed, in order to compare the 124 bp sequence (GenBank accession no. HM069184) from the green iguana (Kik et al., 2011) with other sequences in the *C. avium* group. Originally, this sequence from the iguana represented *C. sp. avian* genotype V, but given its length, it could not be included in the larger phylogenetic analysis of *SSU* data. This alignment (over 400 bp) was also used to illustrate the minor differences between the *C. avium*-like genotype and others in the *C. avium* group (Fig. 1). A comparison of the *LSU* sequence obtained (accession no. KY882339) with the very limited number of *LSU* sequences available in the GenBank database was not informative.

2.4. Phylogenetic analyses

Separate phylogenetic analyses of the aligned *SSU* (661 bp), *actin* (804 bp) or the concatenated *SSU* + *actin* (1465 bp) sequence data sets were conducted using the neighbour-joining (NJ) distance method (Saitou and Nei, 1987) in the program MEGA X v.10.1.8 (Stecher et al., 2020). Evolutionary distances were computed using the 'number of differences' method (Nei and Kumar, 2000), including 'transitions and transversions' for the nucleotide data. Rates of evolution among sites were considered uniform, and gaps were treated using pairwise deletion. A total of 10,000 bootstrap replicates were performed and were recorded as bootstrap support percentages (bs). The outgroup used in the analyses was *C. andersoni*.

2.5. Literature survey of the *C. avium* clade

To adequately compare our findings with the current state of knowledge in the area, we reviewed the literature to provide up-to-date information on *C. cf. avium*. We reviewed all reports of *C. avium*, *C. cf. avium*, *C. avian* genotype V and *C. ornithophilus*; nucleic acid sequence data in the key public repository (GenBank) and salient information, including molecular markers used, host origin, clinical and environmental context (agricultural, pet industry, wildlife, zoo or wildlife park) and country (Table 2).

3. Results

3.1. Sequence comparisons

While cryptosporial *SSU* could not be PCR-amplified from faecal DNA from either the spiny-tailed monitor or the centralian blue-tongue, amplicons were produced from genomic DNA from faeces from the inland bearded dragon, and sequences obtained were compared with data in the NCBI database using BLASTn. The *SSU* sequence obtained (747 bp) was identical to that representing *C. avium* (GenBank accession no. LC310795; over 735 bp) from a brown wood owl (*Strix leptogrammica*) in Japan (Makino et al., 2018), to that of *C. avium* (GenBank accession no. MT074295; over 724 bp) from an inland bearded dragon from Scotland (Lewis et al., 2020) and to *C. cf. avium* (GenBank acc. no. LC416466; over 401 bp) from an Arabian blue mastigure (*Uromastix ornata philbyi*) from Japan (Kubota et al., 2020). The *SSU* sequence also matched (99% identity over 725 bp) several other *C. avium* sequences, with an insertion of a thymine in relation to the *C. avium* reference sequence KU058875. The *actin* gene sequence obtained (804 bp) was 99% identical to that representing *C. cf. avium* (GenBank accession no. LC416468; 2 bp differences over 804 bp) from the mastigure (Kubota et al., 2020) and to *C. cf. avium* (GenBank accession no. LC310796; 4 bp differences over 804 bp) from the brown wood owl (Makino et al., 2018).

Pairwise identities, based on the 401 bp (*SSU*) and 770 bp (*actin*) alignments, were calculated (Table 1). For this *SSU* region, all *C. cf.*

avium sequences were identical, while the pairwise nucleotide sequence identities between the novel *C. cf. avium* and *C. avium* and *C. ornithophilus* were 99.75% and 99.50%, respectively (Table 1). For the *actin* gene region, the pairwise nucleotide sequence identities between the novel *C. cf. avium* and the sequence from the mastigure, brown wood owl, *C. ornithophilus* and *C. avium* were 99.75%, 99.50%, 98.38% and 98.13%, respectively (Table 1).

We compared the short *SSU* sequence (124 bp) publicly available for *C. cf. avium* of the green iguana (GenBank accession no. HM069184; Kik et al., 2011) with those available for select members of the *C. avium* clade and *C. baileyi*, to identify genetic differences. The alignment (Fig. 1) shows that the thymine deletion for this *SSU* region can be used to differentiate *C. cf. avium* from *C. avium*. Further differences that distinguish *C. cf. avium* from *C. avium*, *C. ornithophilus*, *C. avian* genotype I as well as *C. baileyi* (comparator) are also indicated.

3.2. Phylogenetic analyses of *SSU* and *actin* gene data sets

When the *SSU* sequence of *C. avium* from the present inland bearded dragon (GenBank accession no. KT882314) was placed in a phylogenetic context with closely related reference sequences from GenBank, using *C. andersoni* as the outgroup (Fig. 2), there was a moderately supported (bs: 86%) *C. avium* clade consisting of four distinct groups: (1) a moderately-supported (bs: 84%) *C. avium*; (2) a well-supported (bs: 94%) grouping of *C. ornithophilus*; (3) a well-supported (bs: 94%) group of the *C. cf. avium* sequences including the one from this study (accession no. KT882314); and (4) a sole distinct sequence (GenBank accession no. MH553330) from a Brazilian flat-faced fruit-eating bat (*Artibeus planirostris*). The sister group to *C. avium* was comprised of two well-supported groups representing *C. avian* genotype I and *C. baileyi*, respectively.

The topology of the *actin* gene tree was similar to the *SSU* tree, yet with stronger nodal support values (Fig. 3). There was a strongly supported clade consisting of *C. sp. avian* genotype I and *C. baileyi* on one branch, and the collective *C. avium* group on the other. The *C. avium* clade was represented by three strongly supported groups (bs: 99/100/97%): (1) the *C. avium* group; (2) the *C. ornithophilus* group; and (3) the *C. cf. avium* group (with some variation within the clade). The concatenated tree (Fig. 4) had the same topology as the *actin* gene tree. The name *C. cf. avium* will hereby be used to refer to all four samples within the *C. cf. avium* clade.

3.3. Literature survey of the *C. avium* clade

In total, 24 studies recorded species/genotypes of *Cryptosporidium* belonging to the *C. avium* clade – three from reptiles, one from a bat and all others from birds (Table 2). Most studies involved animals from the pet trade (61%), followed by animals from farms (26%), wildlife (17%)

and zoos (9%). Studies were from eight countries, including Brazil (n = 7), China (n = 4), Japan (4), Czechia (n = 3). The commonest genetic marker used was *SSU*, followed by the *actin* and *hsp70* genes. In cases associated with *C. avium* or *C. cf. avium* infection, clinical signs ranged from gastrointestinal symptoms, such as diarrhoea (Makino et al., 2018), renal cryptosporidiosis (Curtiss et al., 2015), conjunctivitis (Lewis et al., 2020) and cloacal prolapse (Santos et al., 2005; Curtiss et al., 2015). For 12 of 24 of the cases, no pathological changes were detected; for 4 of 24 cases, no pathological investigation was mentioned.

4. Discussion

4.1. First characterisation of *C. cf. avium* from an inland bearded dragon from Australia

This is the fourth report of *C. cf. avium*. As “*C. cf. avium*” was coined only recently (Kubota et al., 2020), we suggest that this name be used to classify *Cryptosporidium* found in mastigures (Makino et al., 2018), owls (Kubota et al., 2020) and the other inland bearded dragon from Scotland (Lewis et al., 2020), which all grouped together in phylogenetic analyses, with strong statistical/nodal support (Fig. 1).

In the commonly-sequenced *SSU* region, the difference between *C. cf. avium* and *C. avium* is a thymine insertion for *C. cf. avium* (Fig. 1). The sequence difference between *C. cf. avium* and *C. avium* in the partial *actin* gene sequence is much more pronounced (i.e. 1.87%) (Fig. 3; Table 1). As for other *Cryptosporidium* species, small differences in the *SSU* sequence can suggest large differences in other loci, such as the *actin* and 60 kDa glycoprotein (*gp60*) gene regions (Koehler et al., 2016, 2018). Makino et al. (2018) concluded that the owl, from which they molecularly-characterised *Cryptosporidium*, had mixed infections of *C. avium* (they did not detect the thymine indel) and a novel *Cryptosporidium* genotype, because of nucleotide differences in the *actin* and *hsp70* loci with respect to *C. avium*. We propose that the *SSU*, *actin* and *hsp70* sequences obtained by Makino et al. (2018) were derived from the same taxon of *C. cf. avium*, and were not the result of sequences originating from distinct *Cryptosporidium* taxa within a mixed infection.

The *C. avium* clade – first coined by Kubota et al. (2020) – comprises *C. avium*, *C. cf. avium* and *C. ornithophilus* (Figs. 2–4). The first molecularly-characterised member of this clade was *C. avian* genotype II (now *C. ornithophilus*) from a study of birds from wildlife parks and zoos in Western Australia (Ng et al., 2006). *C. avian* genotype V was first recorded in cockatiels from the Japanese pet trade (Abe and Makino, 2010) and was subsequently described as *C. avium* (see Holubová et al., 2016). The first record of a *C. avium* clade-member from reptiles was *C. sp. avian* genotype V from two green iguanas (Kik et al., 2011); however, due to the short length of the sequence 124 bp and the emergence of *C. cf. avium*, it was necessary to definitively determine to which group this sequence belongs. Here, the alignment (Fig. 1) which includes the

Table 1

Pairwise differences (%) between select species/genotypes of *Cryptosporidium* compared to *C. cf. avium* from the Inland bearded lizard. Alignment of 401 bp region of small subunit of nuclear RNA gene (*SSU*) on lower diagonal and 770 bp region of *actin* gene on the upper diagonal.

	<i>C. cf. avium</i> Inland bearded lizard Australia	<i>C. cf. avium</i> Inland bearded lizard Scotland	<i>C. cf. avium</i> Spiny-tailed lizard	<i>C. cf. avium</i> Brown wood owl	<i>C. ornithophilus</i> Ostrich	<i>C. avium</i> Chicken	<i>C. baileyi</i> Zebra finch
<i>C. cf. avium</i> Inland bearded lizard, Australia	-	NA	99.75	99.50	98.38	98.13	88.31
<i>C. cf. avium</i> Inland bearded lizard, Scotland	100	-	NA	NA	NA	NA	NA
<i>C. cf. avium</i> Spiny-tailed lizard	100	100	-	99.75	98.63	98.38	88.56
<i>C. cf. avium</i> Brown wood owl	100	100	100	-	98.63	98.38	88.68
<i>C. ornithophilus</i> Ostrich	99.50	99.50	99.50	99.50	-	98.51	89.18
<i>C. avium</i> Chicken	99.75	99.75	99.75	99.75	99.75	-	89.43
<i>C. baileyi</i> Zebra finch	97.51	97.51	97.51	97.51	97.01	97.26	-

NA = Not applicable

Table 2

Summary of known case reports from members of the *Cryptosporidium avium* clade including: *C. cf. avium*, *C. avium*, and *C. ornithophilus*.

Species/genotype	Host species	Scientific name(s)	Country	GenBank Accession nos.			Pathology/symptoms	References
				SSU	actin	hsp70		
<i>C. cf. avium</i>	Inland-bearded dragon ^Z	<i>Pogona vitticeps</i>	Australia	KY882314†	MT746065	none	none	present study
<i>C. cf. avium</i>	Inland-bearded dragon ^P	<i>Pogona vitticeps</i>	Scotland	MT074295	none	none	refractory conjunctivitis	Lewis et al. (2020)
<i>C. cf. avium</i>	Brown wood owl, Spotted wood owl ^P	<i>Strix leptogrammica</i> , <i>Strix seloputo</i>	Japan	LC310795	LC310796	LC310797	vomiting, diarrhoea	Makino et al. (2018)
<i>C. cf. avium</i>	Arabian blue mastigure, Sudan mastigure (Spiny-tailed lizards) ^P	<i>Uromastix ornata philbyi</i> , <i>Uromastix dispar flavifasciata</i>	Japan	LC416466	LC416467	LC416468	catarrhal enteritis, villous atrophy, constipation, diarrhoea, vomiting	Kubota et al. (2020)
<i>C. avium</i>	Cockatiel ^P	<i>Nymphicus hollandicus</i>	Japan	AB471646-7	AB471660-1	AB471665 AB538401	none	Abe and Makino (2010)
<i>C. avium</i>	White-eyed parakeet ^W	<i>Aratinga leucophthalma</i>	Brazil	HM126669	none	none	none	Seva et al. (2011)
<i>C. avium</i>	Cockatiel ^P	<i>Nymphicus hollandicus</i>	China	AB471647	none	none	unknown	Qi et al. (2011)
<i>C. avium</i>	Green iguana ^P	<i>Iguana iguana</i>	Netherlands	HM069184	none	none	colitis cystitis cloacal prolapse	Kik et al. (2011)
<i>C. avium</i>	Blue-fronted parrot ^{W, P}	<i>Amazona aestiva</i>	Brazil	KJ487974	none	none	none	Nakamura et al. (2014)
<i>C. avium</i>	Major Mitchell Cockatoo ^P	<i>Lophochora leadbeateri</i>	USA	KP342400	none	none	cloacal prolapse, lethargy, anorexia, death, renal cryptosporidiosis	Curtiss et al. (2015)
<i>C. avium</i>	Cockatiel ^P	<i>Nymphicus hollandicus</i>	Japan	none	none	none	found in lungs trachea and cloaca. No pathology.	Abe and Matsubara, 2015
<i>C. avium</i>	Buderigar, Cockatiel ^P	<i>Melopsittacus undulates</i> <i>Nymphicus hollandicus</i>	China	KM267556	none	none	unknown	Zhang et al. (2015)
<i>C. avium*</i>	Red-crowned parakeet, Chicken, Budgerigar ^P	<i>Cyanoramphus novaezealandiae</i> , <i>Gallus gallus</i> , <i>Melopsittacus undulates</i>	Czechia	KU058875-78	KU058879-82	KU058883-86	none	Holubova et al. (2016)
<i>C. avium</i>	Canary ^P	<i>Serinus canaria</i>	Brazil	MG832882	none	none	none	Camargo et al. (2018)
<i>C. avium*</i>	Cockatiel ^P , Chicken [*]	<i>Nymphicus hollandicus</i> , <i>Gallus gallus</i>	China	JQ246415	JQ320301	JQ798893	none	Cui et al. (2018)
<i>C. avium*</i>	Mallard, Chicken, Pheasant ^{W, A}	<i>Anas platyrhynchos</i> , <i>Gallus gallus</i> , <i>Phasianus colchicus</i>	Czechia	none	none	none	none	Holubova et al. (2018)
<i>C. avium</i>	Red-crowned parakeet, Budgerigar ^P	<i>Cyanoramphus novaezealandiae</i> , <i>Melopsittacus undulates</i>	Czechia	MK311139-40	MK311156-57	MK311173-74	none	Holubova et al. (2019)
<i>C. ornithophilus</i>	Ostrich ^A	<i>Struthio camelus</i>	Brazil	none	none	none	cloacal prolapse	Santos et al. (2005)
<i>C. ornithophilus*</i>	Chicken ^A (infected from Ostrich, Santos et al., 2005)	<i>Gallus gallus</i>	Brazil	DQ002931	DQ002930	DQ002929	none	Meireles et al. (2006)
<i>C. ornithophilus</i>	Major Mitchell cockatoo, Eclectus, Cockatiel, Sun conure, Princess parrot, Galah, Alexandrine ^{Z, P}	<i>Lophochora leadbeateri</i> , <i>Eclectus roratus</i> , <i>Nymphicus hollandicus</i> , <i>Aratinga solstitialis</i> , <i>Polytelis alexandrae</i> , <i>Eolophus roseicapilla</i> , <i>Psittacula eupatria</i>	Australia	DQ650340	DQ650347, DQ650348	none	none	Ng et al. (2006)
<i>C. ornithophilus</i>	Ostrich ^A	<i>Struthio camelus</i>	Brazil	none**	none	none	none	Nakamura et al. (2009)
<i>C. ornithophilus</i>	Ostrich ^A	<i>Struthio camelus</i>	Vietnam	AB696811, AB696812	AB696813, AB696815	AB696814, AB696816	none	Nguyen et al. (2013)
<i>C. ornithophilus</i>	Chicken ^A	<i>Gallus gallus</i>	China	JX548291-292 and 299***	none	none	unknown	Wang et al. (2014)
<i>C. ornithophilus*</i>	Ostrich ^A , Chicken [*] , Cockatiel [*] , Goose [*]	<i>Struthio camelus</i> , <i>Gallus gallus</i> , <i>Nymphicus hollandicus</i> , <i>Anser anser</i>	Czechia	MN969957-963	MN969947-953	MN969934-943	none	Holubova et al. (2020)
<i>C. avium</i> -like	Flat-faced fruit-eating bat ^W	<i>Artibeus planirostris</i>	Brazil	MH553330	none	none	unknown	Batista et al. (2019)

A (Agriculture); P (Pet industry); W (Wildlife); Z (Zoo/Wildlife Park); †Also large subunit of ribosomal RNA (*LSU*) sequence KY882339 from Koehler et al. (2017); *Experimental infection; **Authors claimed there were GenBank sequences but none can be found; ***Listed as *C. avium* type V on GenBank.




Fig. 1. Sequence alignment of a partial region (124 bp) of SSU for selected *Cryptosporidium* sp. to verify the identity of the green iguana sequence from the Netherlands HM069184 (Kik et al., 2011) and the sequence from *Cryptosporidium* from an inland bearded dragon from Scotland MT074295 (Lewis et al., 2020). (For interpretation of the references to colour in this figure legend, the reader is referred to the Web version of this article.)

sequence from *C. sp. avian genotype V* from the green iguana provides support that the indel seen in the short sequence most closely resembles the indels seen in other *C. avium* sequences. The *C. avium* clade has been restricted to avian and reptilian hosts, apart from one case from a flat-faced fruit-eating bat, *Artibeus planirostris* (see Batista et al., 2019), which might have been linked mechanical transmission via avian hosts, or pseudoparasitism.

4.2. Clinical aspects of avian and reptilian cryptosporidiosis caused by members of the *Cryptosporidium avium* clade

In birds, cryptosporidial infections can be in the respiratory tract (*C. baileyi*), proventriculus (*C. galli*), intestines (*C. meleagridis*) and/or the bursa of Fabricius (*C. avian genotype II*) (Nakamura and Meireles, 2015). In reptiles, infection is typically gastric (*C. serpentis*) or intestinal (*C. varanii*) (Bogan, 2019; Latney and Wellehan, 2020). There have been relatively few case reports of members of the *C. avium* clade, with most studies reporting no clinical signs ($n = 14$) or no signs recorded ($n = 4$) (Table 2). The first clinical manifestation of cryptosporidiosis in an ostrich linked to *C. ornithophilus* in Brazil was a cloacal prolapse (Santos et al., 2005). Previously, a *Cryptosporidium* sp. had been implicated in cloacal prolapse of ostriches, but had not been molecularly characterised (Penrith et al., 1994). In two green iguanas, recurrent cloacal prolapse and cystitis were indicated in an infection of what turned out to be *C. avium* (see Kik et al., 2011). *C. avium* was confirmed by PCR from a Major Mitchell's cockatoo in the USA, which, like the iguanas and ostriches, presented with cloacal prolapse, but also renal cryptosporidiosis (Curtiss et al., 2015). Cui et al. (2018) suggested that the bursa of Fabricius was the main site of infection for *C. avium*, which was established via experimental infection of chickens – which showed no clinical signs during infection.

The highest incidence of symptomatic cases has been associated with *C. cf. avium* group within the *C. avium* clade (Table 2). The case report of the brown wood owl described ‘vomiting’ and severe diarrhoea; however, another owl from the same pet merchant was PCR test-positive for *C. cf. avium*, yet asymptomatic (Makino et al., 2018). The case report of the spiny-tailed lizards (mastigures) involved two individual animals: The first, an Arabian blue mastigure, had symptoms of diarrhoea and ‘vomiting’ and then died, with the necropsy revealing catarrhal enteritis; the second, a Sudan mastigure, presented with constipation (Kubota et al., 2020). Finally, conjunctivitis caused by *C. cf. avium* was reported from an inland bearded dragon which was euthanised; a *post mortem* examination revealed hepatic fibrosis and biliary hyperplasia, but there was no evidence of *Cryptosporidium* in the intestines (Lewis et al., 2020).

Multiple case reports have noted the high degree of contagiousness of *Cryptosporidium* (Kik et al., 2011; Lewis et al., 2020), yet some animals appear to remain asymptomatic; it was reported that the mastigures infected each other (Kubota et al., 2020); at least two owls from the same wholesaler were infected (Makino et al., 2018); and one iguana infected

another from the Netherlands case (Kik et al., 2011). Host age and/or immune status could be the reason why some animals display symptoms and others remain asymptomatic, as was thought to be the case for the owls (the one-month-old owlet was sick and the older 3-month-old was asymptomatic) (Makino et al., 2018). In the present case, the inland bearded dragon appeared to be asymptomatic; however, the centralian blue tongue in the same exhibit possibly died from cryptosporidiosis, as it had histological evidence of *Cryptosporidium* sp. infection in the gastrointestinal tract.

4.3. *Cryptosporidium* of reptiles

Numerous studies have used PCR to molecularly characterise *Cryptosporidium* in reptiles (e.g., Xiao et al., 2004; Kuroki et al., 2008; Pedraza-Díaz et al., 2009; Richter et al., 2011; Díaz et al., 2013) and, typically, *C. serpentis* Type A is the dominant *Cryptosporidium* taxon in snakes, followed by *C. varanii*, and *C. varanii* is dominant in lizards (reviewed in Bogan et al., 2019; Latney and Wellehan, 2020). *C. serpentis* causes a gastric form of *Cryptosporidium*, and the major symptoms and pathology are gastritis, regurgitation and midbody oedema, while *C. varanii* causes an intestinal form of disease, with symptoms of proliferative enteritis and chronic wasting (Bogan et al., 2019; Latney and Wellehan, 2020).

The following cases of *Cryptosporidium* sp. in reptiles were reported prior to the routine diagnostic use of PCR and, therefore, some of these uncharacterised species might have belonged to the *C. avium* clade: Gastric cryptosporidiosis from a wild frilled lizard (*Chlamydosaurus kingi*) from Australia (Orós et al., 1998); oocysts found in the gut epithelium of the starred lizard (*Agama stellio*) in Israel (Ostrovskaya and Paperna, 1990); oocysts in the cloacas of two Madagascar giant day geckos (*Phelsuma madagascariensis grandis*) from the USA (Upton and Barnard, 1987); proliferative enteritis in leopard geckos (*Eublepharis macularius*), USA (Terrell, 2003); renal cryptosporidiosis in both an iguana and a Parson's chameleon (*Calumma parsonii*), USA (Frye et al., 1999); tympanic cavity of a green iguana, USA (Fitzgerald et al., 1998); and aural-pharyngeal polyps in three green iguanas, USA (Uhl et al., 2001). A survey of 150 pet lizards and snakes in Italy detected *Cryptosporidium* but the taxa could not be characterised due to a low quality of sequence data obtained using a PCR-based approach (Rinaldi et al., 2012). Some recent studies did not use PCR, such as in the case of eight captive green iguanas in Poland, which were submitted for treatment for cryptosporidiosis after showing signs of diarrhoea (Gałęcki and Sokół, 2018). In our opinion, future studies should use PCR-coupled sequencing of SSU, *actin* and *hsp70* gene regions to allow comparisons with available data sets.

Inland bearded dragons are very popular animals in the pet trade (Doneley, 2006) and are also frequently kept in zoological parks. The first molecularly-characterised case of *Cryptosporidium* from *Pogona vitticeps* was *C. varanii* (syn. *C. saurophilum*) from the St. Louis Zoo in the

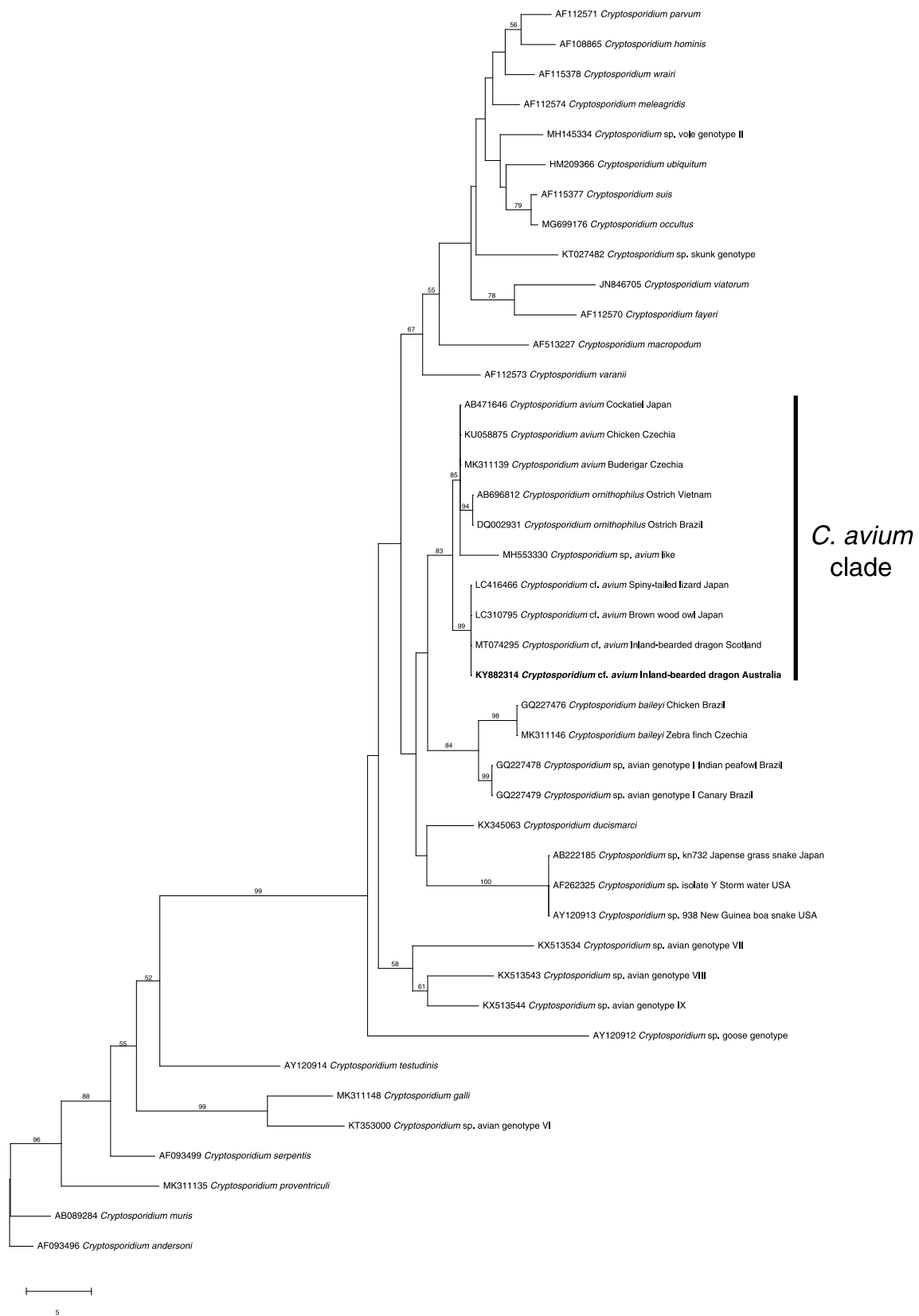


Fig. 2. Relationship of the novel *Cryptosporidium* cf. *avium* taxa (in bold) from the faeces of the inland-bearded dragon with representative *Cryptosporidium* sequences, established based on a phylogenetic analysis of sequence data from a portion of the small subunit of nuclear ribosomal RNA gene (*SSU*) employing the neighbour-joining distance method. Branch supports are represented by neighbour-joining bootstrap percentages. *C. andersoni* was used as an outgroup.

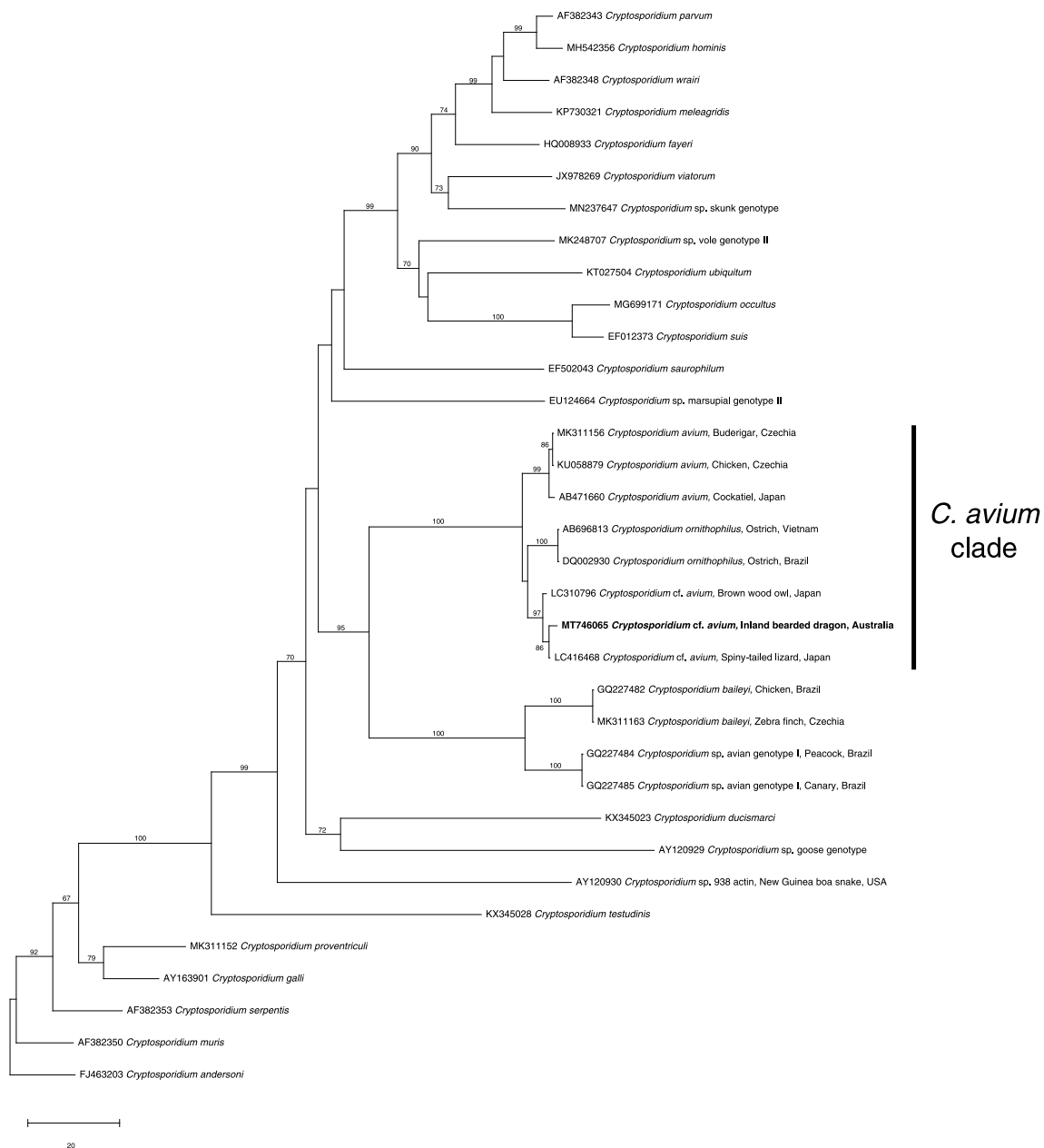


Fig. 3. Relationship of the novel *Cryptosporidium cf. avium* taxa (in bold) from the faeces of the inland-bearded dragon with representative *Cryptosporidium* sequences, established based on a phylogenetic analysis of sequence data from a portion of the *actin* gene employing the neighbour-joining distance method. Branch supports are represented by neighbour-joining bootstrap percentages. *C. andersoni* was used as an outgroup.

USA (Xiao et al., 2004). As bearded dragons are common pets, Grosset et al. (2011) attempted to test the effect of paromomycin – an aminoglycoside antimicrobial – on *Cryptosporidium*. These authors characterised experimental infections of an unknown species of *Cryptosporidium* (sourced from an adult *P. vitticeps*) in 10 *P. vitticeps* individuals (4 months of age), which remained asymptomatic throughout the trial; they noted that the infection was highly contagious (infecting separated, uninfected control animals), and emphasised the point that asymptomatic carriers can quickly spread infection to other species housed nearby, as might be the case in zoos and pet stores Grosset et al. (2011). Other than these aforementioned cases, the present case from a wildlife sanctuary in Australia and a previous case from Scotland (Lewis et al., 2020) are the only records of *Cryptosporidium* from inland bearded dragons.

4.4. Current state of knowledge about *C. cf. avium* and associated cryptosporidiosis

In order to adequately discuss our findings in relation to the current state of knowledge in the area, we elected to review the literature to provide up-to-date information on *C. cf. avium*. Table 2 reveals some biases in the studies of members of the *C. avium* clade. Two thirds of the studies related to animals associated with the pet trade and/or zoos (66%; 16/24) (Table 2). Clearly, domestic pets are more likely to be treated and subsequently reported by clinicians as cases *vis-à-vis* wildlife cases. The species diversity in Table 2 is likely limited, because the types of pets examined would typically include exotic animals, such as Psittaciformes, and commonly-kept reptiles, such as iguanas and bearded dragons. Ostriches were also well-sampled (66.6%; four of six *C. ornithophilus* reports) due to ostrich farming being relatively common (Santos et al., 2005; Meireles et al., 2006; Nakamura et al., 2009;

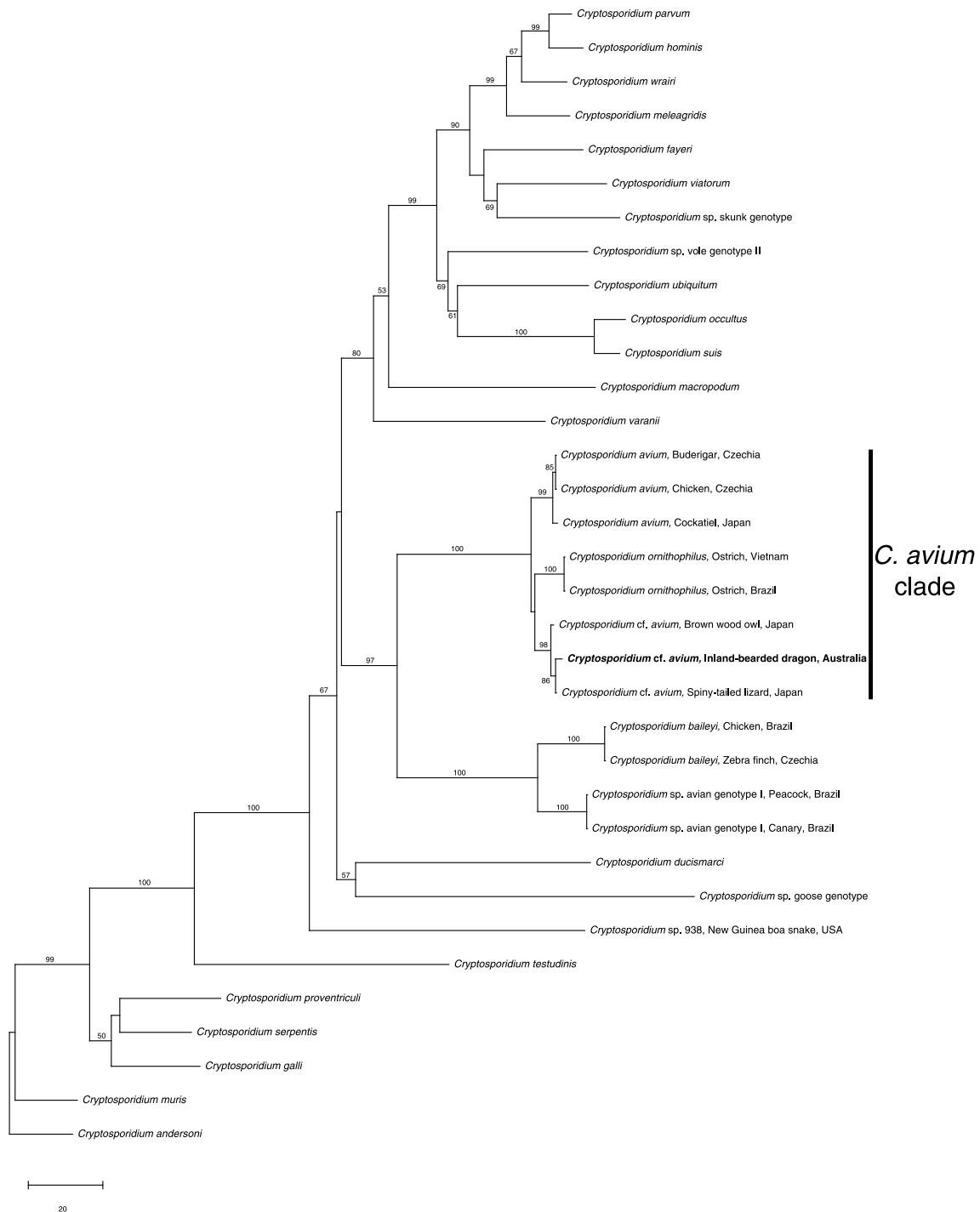


Fig. 4. Relationship of the novel *Cryptosporidium cf. avium* taxa (in bold) from the faeces of the inland-bearded dragon with representative *Cryptosporidium* sequences, established based on a phylogenetic analysis of sequence data from concatenated *SSU* and *actin* genes employing the neighbour-joining distance method. Branch supports are represented by neighbour-joining bootstrap percentages. *C. andersoni* was used as an outgroup.

Nguyen et al., 2013; Holubová et al., 2020). There is also a bias in the countries (including Australia, Brazil, China, Czech Republic and Japan), from which studies were published, as these are countries in which there is an active research focus on *Cryptosporidium*. There were limited samples directly from wild-caught animals ($n = 4$) (Sevá et al., 2011; Nakamura et al., 2014; Holubová et al., 2018; Batista et al., 2019). We believe that investigating such animals is critical when attempting to discover a possible endemic origin for *C. avium* cases, vis-à-vis those from pet shops, zoos and agriculture.

4.5. Possible sources of infection

We wanted to establish why there is a distinct subtype of *C. avium* in lizards. Examining some of the commonalities of the four *C. cf. avium* cases might help bring us closer to addressing this question. There is sufficient genetic distance (*actin* gene) to suggest that *C. cf. avium* is not a recent divergence. Further examination of the *gp60* gene would probably support this hypothesis if primers could be developed for the region. All of the animals involved were captive, either from the pet industry or housed in an exhibit as in the present case, which does not

allow for reliable source-tracking. Two of the cases originated from wild-caught animals (present case and mastigures – Kubota et al., 2020), and the others were either reared in captivity (owls; Makino et al., 2018) or of unknown origin (the Scottish inland bearded dragon was abandoned at a pet shop; Lewis et al., 2020).

Food sources were mentioned in some case reports: owls were fed defrosted quail, and mastigures were fed commercial tortoise pellets, commercial bird seed and vegetable matter (Makino et al., 2018; Kubota et al., 2020). Both the mastigure and owl cases originated from or near Tokyo, although the pet stores were not located in the same suburbs. As *C. cf. avium* has now been seen in Australia, Japan and Scotland, it is probably circulating throughout the pet trade. Sampling more wildlife and identifying *Cryptosporidium* species/genotypes should assist in identifying sources of infection and reservoir hosts. Processes such as ecological fitting, where chance contact (increased globalisation of pet trade) between novel hosts and novel pathogens result in an adequate environment for the pathogen to persist (Araujo et al., 2015), could be the answer. Or, *C. cf. avium* could potentially be a host-switching relict, from when birds split from reptiles prior to the Cretaceous-Tertiary extinction event (Cracraft, 2001). Other protistan parasites share a close relationship between their closely-related bird and lizard hosts (e.g., malaria; cf. Perkins and Schall, 2002; Hayakawa et al., 2008; Martinsen et al., 2008).

4.6. Conclusions

Clearly, members of the *C. cf. avium* clade are capable of infecting avian and reptilian hosts, causing morbidity and mortality. Precautions involving biosecurity and quarantine procedures should be implemented in pet stores, zoological enclosures harbouring both birds and reptiles. When infections are discovered, it is important that PCR-coupled sequencing analysis be performed, ideally with *SSU*, *actin* and *hsp70* gene markers wherever possible. As evidenced here, *Cryptosporidium* is not limited to the gastrointestinal tracts of reptiles; multiple organs should be examined for disease when performing a necropsy. Future work should include defining a panel of single-copy gene markers in the nuclear genome, including *gp60*, which would aid in the refining the genetic characterisation of members of this genus. Continued wildlife surveys will assist in filling knowledge gaps surrounding the systematics, epidemiology and population genetics of *Cryptosporidium*, including members of the *C. cf. avium* clade, and associated cryptosporidiosis.

Declaration of competing interest

The authors declare that they have no known competing financial interests or personal relationships that could have appeared to influence the work reported in this paper.

Acknowledgements

This study was partially supported through a grant from the Australian Research Council (LP160101299 to RBG and AVK).

References

Abe, N., Makino, I., 2010. Multilocus genotypic analysis of *Cryptosporidium* isolates from cockatiels. *Japan. Parasitol. Res.* 106, 1491–1497.

Abe, N., Matsubara, K., 2015. Molecular identification of *Cryptosporidium* isolates from exotic pet animals in Japan. *Vet. Parasitol.* 209, 254–257.

Araujo, S.B., Braga, M.P., Brooks, D.R., Agosta, S.J., Hoberg, E.P., von Hartenthal, F.W., Boeger, W.A., 2015. Understanding host-switching by ecological fitting. *PLoS One* 10, e0139225.

Batista, J.M.N., de Carvalho, C., Pedro, W.A., Santana, B.N., Camargo, V.S., Ferrari, E.D., Nascimento, I.G., Meireles, M.V., 2019. Identification of *Cryptosporidium* bat genotypes XVI–XVIII in bats from Brazil. *Parasitol. Res.* 118, 2183–2191.

Bogan, J.E., 2019. Gastric cryptosporidiosis in snakes, a review. *J. Herpetol. Med. Surg.* 29, 71–86.

Camargo, V.d.S., Santana, B.N., Ferrari, E.D., Nakamura, A.A., Nagata, W.B., Nardi, A.R.M., Meireles, M.V., 2018. Detection and molecular characterization of *Cryptosporidium* spp. in captive canaries (*Serinus canaria*) using different diagnostic methods. *Rev. Bras. Parasitol. Vet.* 27, 60–65.

Chalmers, R.M., Davies, A.P., 2010. Minireview: clinical cryptosporidiosis. *Exp. Parasitol.* 124, 138–146.

Cogger, H., 2014. *Reptiles and Amphibians of Australia*. CSIRO Publishing, Collingwood, p. 1064.

Cracraft, J., 2001. Avian evolution, Gondwana biogeography and the Cretaceous-Tertiary mass extinction event. *Proc. Biol. Sci.* 268, 459–469.

Cui, Z., Song, D., Qi, M., Zhang, S., Wang, R., Jian, F., Ning, C., Zhang, L., 2018. Revisiting the infectivity and pathogenicity of *Cryptosporidium avium* provides new information on parasitic sites within the host. *Parasites Vectors* 11, 514.

Curtiss, J.B., Leone, A.M., Wellehan Jr., J.F., Emerson, J.A., Howerth, E.W., Farina, L.L., 2015. Renal and cloacal cryptosporidiosis (*Cryptosporidium avium* genotype V) in a major Mitchell's cockatoo (*Lophochroa leadbeateri*). *J. Zoo Wildl. Med.* 46, 934–937.

Díaz, P., Rota, S., Marchesi, B., López, C., Panadero, R., Fernández, G., Díez-Baños, P., Morrono, P., Poglajen, G., 2013. *Cryptosporidium* in pet snakes from Italy: molecular characterization and zoonotic implications. *Vet. Parasitol.* 197, 68–73.

Doneley, B., 2006. Caring for the bearded dragon. *Proceedings of the North American Veterinary Conference*, Orlando, FL, pp. 1607–1611.

Edgar, R.C., 2004. MUSCLE: multiple sequence alignment with high accuracy and high throughput. *Nucleic Acids Res.* 32, 1792–1797.

Fitzgerald, S.D., Moisan, P.G., Bennett, R., 1998. Aural polyp associated with cryptosporidiosis in an iguana (*Iguana iguana*). *J. Vet. Diagn. Invest.* 10, 179–180.

Frye, F., Garman, R., Graczyk, T., Boyer, T., Miller, H., 1999. Atypical non-alimentary cryptosporidiosis in three lizards. *Proc. Assoc. Reptil. Amphib. Vet.* 2, 43.

Gałęcki, R., Sokół, R., 2018. Treatment of cryptosporidiosis in captive green iguanas (*Iguana iguana*). *Vet. Parasitol.* 252, 17–21.

Grosset, C., Villeneuve, A., Brieger, A., Lair, S., 2011. Cryptosporidiosis in juvenile bearded dragons (*Pogona vitticeps*): effects of treatment with paromomycin. *J. Herpetol. Med. Surg.* 21, 10–15.

Hayakawa, T., Culleton, R., Otani, H., Horii, T., Tanabe, K., 2008. Big bang in the evolution of extant malaria parasites. *Mol. Biol. Evol.* 25, 2233–2239.

Holubová, N., Sak, B., Hlášková, L., Květoňová, D., Hanzal, V., Rajský, D., Rost, M., McEvoy, J., Kváč, M., 2018. Host specificity and age-dependent resistance to *Cryptosporidium avium* infection in chickens, ducks and pheasants. *Exp. Parasitol.* 191, 62–65.

Holubová, N., Sak, B., Horčíčková, M., Hlášková, L., Květoňová, D., Menchaca, S., McEvoy, J., Kváč, M., 2016. *Cryptosporidium avium* n. sp. (Apicomplexa: cryptosporidiidae) in birds. *Parasitol. Res.* 115, 2243–2251.

Holubová, N., Tůmová, L., Sak, B., Hejzlarová, A., Konečný, R., McEvoy, J., Kváč, M., 2020. Description of *Cryptosporidium ornithophilus* n. sp. (Apicomplexa: cryptosporidiidae) in farmed ostriches. *Parasites Vectors* 13, 1–17.

Holubová, N., Zikmundová, V., Limpouchová, Z., Sak, B., Konečný, R., Hlášková, L., Rajský, D., Kopacz, Z., McEvoy, J., Kváč, M., 2019. *Cryptosporidium proventriculi* sp. n. (apicomplexa: cryptosporidiidae) in Psittaciformes birds. *Eur. J. Protistol.* 69, 70–87.

Huang, J.M., Chen, H.L., Zhou, Y.K., Wang, S., Ren, Q., Fang, Z., Li, H.H., Zheng, K.L., Liu, X.C., Gu, Y.F., Li, W.C., 2020. The first report of *Cryptosporidium testudinis* in Chinese alligators (*Alligator sinensis*) in China. *Parasitol. Res.* 119, 2359–2362.

Jex, A.R., Smith, H.V., Monis, P.T., Campbell, B.E., Gasser, R.B., 2008. *Cryptosporidium* - biotechnological advances in the detection, diagnosis and analysis of genetic variation. *Biotechnol. Adv.* 26, 304–317.

Ježková, J., Horčíčková, M., Hlášková, L., Sak, B., Květoňová, D., Novák, J., Hofmannová, L., McEvoy, J., Kváč, M., 2016. *Cryptosporidium testudinis* sp. n., *Cryptosporidium ducismarci* Traversa, 2010 and *Cryptosporidium* tortoise genotype III (Apicomplexa: cryptosporidiidae) in tortoises. *Folia Parasitol. (Praha)* 63 (10), 14411.

Kik, M.J., van Asten, A.J., Lenstra, J.A., Kirpensteijn, J., 2011. Cloaca prolapse and cystitis in green iguana (*Iguana iguana*) caused by a novel *Cryptosporidium* species. *Vet. Parasitol.* 175, 165–167.

Koehler, A.V., Haydon, S.R., Jex, A.R., Gasser, R.B., 2016. Is *Cryptosporidium* from the common wombat (*Vombatus ursinus*) a new species and distinct from *Cryptosporidium ubiquitum*? *Infect. Genet. Evol.* 44, 28–33.

Koehler, A.V., Korhonen, P.K., Hall, R.S., Young, N.D., Wang, T., Haydon, S.R., Gasser, R.B., 2017. Use of a bioinformatic-assisted primer design strategy to establish a new nested PCR-based method for *Cryptosporidium*. *Parasites Vectors* 10, 509.

Koehler, A.V., Wang, T., Haydon, S.R., Gasser, R.B., 2018. *Cryptosporidium viatorum* from the native Australian swamp rat *Rattus lutreolus* - an emerging zoonotic pathogen? *Int. J. Parasitol. Parasites Wildl.* 7, 18–26.

Kubota, R., Tokiwa, T., Matsubara, K., Okamoto, M., Ike, K., 2020. Detection and molecular characterization of *Cryptosporidium* species in wild-caught pet spiny-tailed lizards. *Int. J. Parasitol. Parasites Wildl.* 11, 83–87.

Kuroki, T., Izumiya, S., Yagita, K., Une, Y., Hayashidani, H., Kuro-o, M., Mori, A., Moriguchi, H., Toriba, M., Ishibashi, T., 2008. Occurrence of *Cryptosporidium* sp. in snakes in Japan. *Parasitol. Res.* 103, 801–805.

Latney, L.T.V., Wellehan, J.F., 2020. Selected emerging infectious diseases of Squamata: an update. *Vet. Clin.: Exotic Animal Practice* 23, 353–371.

Lewis, M., Bartley, P., Katzer, F., Morrison, L., Philbey, A., Eatwell, K., Walker, D., 2020. Conjunctival *Cryptosporidium avium* infection in a captive inland bearded dragon (*Pogona vitticeps*). *J. Exot. Pet Med.* 35, 23–26. <https://doi.org/10.1053/j.jepm.2020.05.014>.

Maddison, W.P., Maddison, D.R., 2015. Mesquite: a Modular System for Evolutionary Analysis, 3.04.

- Makino, I., Inumaru, M., Abe, N., Sato, Y., 2018. A new avian *Cryptosporidium* genotype in a 1-month-old caged brown wood owl (*Strix leptogrammica*) with severe dehydration and diarrhea. *Parasitol. Res.* 117, 3003–3008.
- Martinsen, E.S., Perkins, S.L., Schall, J.J., 2008. A three-genome phylogeny of malaria parasites (*Plasmodium* and closely related genera): evolution of life-history traits and host switches. *Mol. Phylogenet. Evol.* 47, 261–273.
- Meireles, M.V., Soares, R.M., Márcia Mercês Aparecida Bianchi dos, S., Gennari, S.M., 2006. Biological studies and molecular characterization of a *Cryptosporidium* isolate from ostriches (*Struthio camelus*). *J. Parasitol.* 92, 623–626.
- Morgan, U.M., Monis, P.T., Xiao, L., Limor, J., Sulaiman, I., Raidal, S., O'Donoghue, P., Gasser, R., Murray, A., Fayer, R., Blagburn, B.L., Lal, A.A., Thompson, R.C.A., 2001. Molecular and phylogenetic characterisation of *Cryptosporidium* from birds. *Int. J. Parasitol.* 31, 289–296.
- Nakamura, A.A., Homem, C.G., da Silva, A.M., Meireles, M.V., 2014. Diagnosis of gastric cryptosporidiosis in birds using a duplex real-time PCR assay. *Vet. Parasitol.* 205, 7–13.
- Nakamura, A.A., Meireles, M.V., 2015. *Cryptosporidium* infections in birds - a review. *Rev. Bras. Parasitol. Vet.* 24, 253–267.
- Nakamura, A.A., Simões, D.C., Antunes, R.G., da Silva, D.C., Meireles, M.V., 2009. Molecular characterization of *Cryptosporidium* spp. from fecal samples of birds kept in captivity in Brazil. *Vet. Parasitol.* 166, 47–51.
- Nei, M., Kumar, S., 2000. *Molecular Evolution and Phylogenetics*. Oxford University Press.
- Ng, J., Pavlasek, I., Ryan, U.M., 2006. Identification of novel *Cryptosporidium* genotypes from avian hosts. *Appl. Environ. Microbiol.* 72, 7548–7553.
- Nguyen, S.T., Fukuda, Y., Tada, C., Huynh, V.V., Nguyen, D.T., Nakai, Y., 2013. Prevalence and molecular characterization of *Cryptosporidium* in ostriches (*Struthio camelus*) on a farm in central Vietnam. *Exp. Parasitol.* 133, 8–11.
- Orós, J., Rodríguez, J.L., Patterson-Kane, J., 1998. Gastric cryptosporidiosis in a wild frilled lizard from Australia. *J. Wildl. Dis.* 34, 807–810.
- Ostrowska, K., Paperna, I.K., 1990. *Cryptosporidium* sp. of the starred lizard *Agama stellio*: ultrastructure and life cycle. *Z. Parasitenkd.* 76, 712–720.
- Pavlasek, I., Ryan, U.M., 2008. *Cryptosporidium varanii* takes precedence over *C. saurophilum*. *Exp. Parasitol.* 118, 434–437.
- Pedraza-Díaz, S., Ortega-Mora, L.M., Carrión, B.A., Navarro, V., Gómez-Bautista, M., 2009. Molecular characterisation of *Cryptosporidium* isolates from pet reptiles. *Vet. Parasitol.* 160, 204–210.
- Penrith, M.L., Bezuidenhout, A.J., Burger, W.P., Putterill, J.F., 1994. Evidence for cryptosporidial infection as a cause of prolapse of the phallus and cloaca in ostrich chicks (*Struthio camelus*). *Onderstepoort J. Vet. Res.* 61, 283–289.
- Perkins, S.L., Schall, J., 2002. A molecular phylogeny of malarial parasites recovered from cytochrome b gene sequences. *J. Parasitol.* 88, 972–978.
- Qi, M., Wang, R., Ning, C., Li, X., Zhang, L., Jian, F., Sun, Y., Xiao, L., 2011. *Cryptosporidium* spp. in pet birds: genetic diversity and potential public health significance. *Exp. Parasitol.* 128, 336–340.
- Richter, B., Nedorost, N., Maderner, A., Weissenböck, H., 2011. Detection of *Cryptosporidium* species in feces or gastric contents from snakes and lizards as determined by polymerase chain reaction analysis and partial sequencing of the 18S ribosomal RNA gene. *J. Vet. Diagn. Invest.* 23, 430–435.
- Rinaldi, L., Capasso, M., Mihalca, A., Cirillo, R., Cringoli, G., Caccio, S., 2012. Prevalence and molecular identification of *Cryptosporidium* isolates from pet lizards and snakes in Italy. *Parasit* 19, 437.
- Ryan, U., Fayer, R., Xiao, L., 2014. *Cryptosporidium* species in humans and animals: current understanding and research needs. *Parasitology* 141, 1667–1685.
- Ryan, U., Papparini, A., Monis, P., Hijjaw, N., 2016. It's official—*Cryptosporidium* is a gregarine: what are the implications for the water industry? *Water Res.* 105, 305–313.
- Ryan, U.M., Xiao, L., Read, C., Zhou, L., Lal, A.A., Pavlasek, I., 2003. Identification of novel *Cryptosporidium* genotypes from the Czech republic. *Appl. Environ. Microbiol.* 69, 4302–4307.
- Saitou, N., Nei, M., 1987. The neighbor-joining method: a new method for reconstructing phylogenetic trees. *Mol. Biol. Evol.* 4, 406–425.
- Santos, M., Peiró, J., Meireles, M., 2005. *Cryptosporidium* infection in ostriches (*Struthio camelus*) in Brazil: clinical, morphological and molecular studies. *Braz. J. Poultry Sci.* 7, 113–117.
- Sevá, A.d.P., Funada, M.R., Richtzenhain, L., Guimarães, M.B., de Oliveira Souza, S., Allegratti, L., Sinhorini, J.A., Duarte, V.V., Soares, R.M., 2011. Genotyping of *Cryptosporidium* spp. from free-living wild birds from Brazil. *Vet. Parasitol.* 175, 27–32.
- Stecher, G., Tamura, K., Kumar, S., 2020. Molecular evolutionary genetics analysis (MEGA) for macOS. *Mol. Biol. Evol.* 37, 1237–1239.
- Terrell, S.P., 2003. Proliferative enteritis in leopard geckos (*Cryptosporidium* sp.) infection. *J. Zoo Wildl. Med.* 34, 69–75.
- Upton, S., Barnard, S., 1987. Two new species of coccidia (Apicomplexa: eimeriidae) from Madagascar gekkonids. *J. Protozool.* 34, 452–454.
- Uhl, E., Jacobson, E., Bartick, T., Micinilio, J., Schimdt, R., 2001. Aural-pharyngeal polyps associated with *Cryptosporidium* infection in three iguanas (*Iguana iguana*). *Vet. Pathol.* 38, 239–242.
- Wang, L., Xue, X., Li, J., Zhou, Q., Yu, Y., Du, A., 2014. Cryptosporidiosis in broiler chickens in Zhejiang Province, China: molecular characterization of oocysts detected in fecal samples. *Parasit* 21, 36.
- Xiao, L., Ryan, U.M., Graczyk, T.K., Limor, J., Li, L., Kombert, M., Junge, R., Sulaiman, I. M., Zhou, L., Arrowood, M.J., 2004. Genetic diversity of *Cryptosporidium* spp. in captive reptiles. *Appl. Environ. Microbiol.* 70, 891–899.
- Zahedi, A., Papparini, A., Jian, F., Robertson, I., Ryan, U., 2016. Public health significance of zoonotic *Cryptosporidium* species in wildlife: critical insights into better drinking water management. *Int. J. Parasitol. Parasites Wildl.* 5, 88–109.
- Zhang, X.-X., Zhang, N.-Z., Zhao, G.-H., Zhao, Q., Zhu, X.-Q., 2015. Prevalence and genotyping of *Cryptosporidium* infection in pet parrots in North China. *BioMed Res. Int.* 2015, 1–6.