



Minerva Access is the Institutional Repository of The University of Melbourne

Author/s:

Hughes, TM;Williams, GJ;Gyorki, DE;Kelly, JW;Stretch, JR;Varey, AHR;Hong, AM;Scolyer, RA;Thompson, JF

Title:

Desmoplastic melanoma: a review of its pathology and clinical behaviour, and of management recommendations in published guidelines

Date:

2021-06-01

Citation:

Hughes, T. M., Williams, G. J., Gyorki, D. E., Kelly, J. W., Stretch, J. R., Varey, A. H. R., Hong, A. M., Scolyer, R. A. & Thompson, J. F. (2021). Desmoplastic melanoma: a review of its pathology and clinical behaviour, and of management recommendations in published guidelines. *Journal of the European Academy of Dermatology and Venereology*, 35 (6), pp.1290-1298. <https://doi.org/10.1111/jdv.17154>.

Persistent Link:

<https://hdl.handle.net/11343/298300>

PROF. RICHARD A. SCOLYER (Orcid ID : 0000-0002-8991-0013)

PROF. JOHN THOMPSON (Orcid ID : 0000-0002-2816-2496)

Article type : Review Article

Desmoplastic Melanoma: A review of its pathology and clinical
behaviour, and of management recommendations in published
guidelines

Keywords: melanoma, desmoplasia, pathology, management guidelines

Authors

T.M. Hughes^{1, 2, 3, 4}

G.J. Williams^{2,3}

D.E. Gyorki^{1, 5}

J.W. Kelly^{1,6}

J.R. Stretch^{1, 2, 3, 8}

A.H.R. Varey^{2,3,7}

A.M. Hong^{1,2,3, 8}

R.A. Scolyer^{1, 2,3, 8, 9}

J.F. Thompson^{1,2, 3, 8}

This is the author manuscript accepted for publication and has undergone full peer review but has not been through the copyediting, typesetting, pagination and proofreading process, which may lead to differences between this version and the [Version of Record](#). Please cite this article as [doi: 10.1111/JDV.17154](https://doi.org/10.1111/JDV.17154)

This article is protected by copyright. All rights reserved

Affiliations

¹Cancer Council Australia Melanoma Guidelines Working Party

²Melanoma Institute Australia, The University of Sydney, Sydney, NSW, Australia

³Faculty of Medicine and Health, The University of Sydney, Sydney, NSW, Australia

⁴Sydney Adventist Hospital, Sydney, NSW, Australia

⁵Peter MacCallum Cancer Centre, Melbourne, VIC, Australia

⁶Victorian Melanoma Service, Alfred Hospital, Melbourne, VIC, Australia

⁷Westmead Hospital, Sydney, NSW, Australia

⁸Royal Prince Alfred Hospital, Sydney, NSW, Australia

⁹NSW Health Pathology, Sydney, NSW, Australia

Corresponding author:

John F Thompson

Melanoma Institute Australia, the University of Sydney

40 Rocklands Road, NORTH SYDNEY NSW 2060

AUSTRALIA

E: john.thompson@melanoma.org.au

Funding: National Health and Research Council of Australia Program grant (APP1093017)

(RAS and JFT), the Melanoma Foundation of the University of Sydney and Melanoma Institute Australia. RAS is supported by an NHMRC Practitioner Fellowship

Contributor Statement; All authors substantially contributed to the manuscript

Conflict of Interest/Financial disclosures; RAS has received fees for professional services from Novartis Pharma AG, MSD Australia, NeraCare, Amgen Inc., BMS Australia, Novartis Pharmaceuticals Australia, Myriad Genetics GmbH, GSK Australia, QBiotics. JFT has received

honoraria for advisory board participation from BMS Australia, MSD Australia, GSK and Provectus Inc, and travel support from GSK and Provectus Inc. AHRV has received honoraria from Medtronic, travel and meeting expenses from Acelity and meeting expenses from Synthes. The other authors have no conflict of interest or financial disclosures.

Abstract

Desmoplastic melanomas are uncommon. Their behaviour differs from that of other melanoma subtypes, therefore management guidelines for non-desmoplastic melanomas may not be applicable. This review sought to examine all available evidence relating to the behaviour and management of desmoplastic melanomas, based on review of all relevant English-language publications, and to critically assess the recommendations for their management in current published melanoma management guidelines.

Compared with other melanoma subtypes, patients with “pure” desmoplastic melanomas (where $\geq 90\%$ of the invasive melanoma is of desmoplastic melanoma subtype) have much lower rates of sentinel node positivity and distant metastasis. Local recurrence rates are higher for desmoplastic melanomas, but resection margins wider than those recommended for non-desmoplastic melanomas have not been shown to be of benefit. Adjuvant radiotherapy reduces the risk of local recurrence when a satisfactory histological clearance ($\geq 8\text{mm}$) cannot be achieved. Of 29 published melanoma management guidelines identified, only 11 specified management for desmoplastic melanomas, while seven simply stated that the feature should be reported.

Desmoplastic melanoma is a unique melanoma subtype with biology that differs from that of other melanoma subtypes. It requires specific management strategies but few current guidelines address these.

Desmoplastic melanoma (DM) is an uncommon melanoma subtype, comprising only 1–4% of all primary cutaneous melanomas. DM may be difficult to recognise, both clinically and pathologically, and its behaviour differs from that of non-desmoplastic melanoma (non-DM)¹⁻⁵. In this article, the special features of DM and the results of reported management strategies are reviewed. In addition, the evidence supporting the current recommendations in published melanoma management guidelines that specifically mention the management of DM is critically assessed.

Identification of all English-language publications related to desmoplastic and neurotropic melanomas and guideline recommendations for their management was achieved by searching Medline, Embase and Cochrane Library databases using the terms melanoma, desmoplastic, neurotropic. From the assembled collection of 254 unique articles, 36 articles containing clinically-relevant material and 29 published melanoma management guidelines were then examined in detail.

. Clinical and Pathological Characteristics of Desmoplastic Melanomas

DM is characterized histologically by variably pleomorphic, spindle-shaped cells separated by collagen fibers, with a fibrotic stromal reaction termed desmoplasia (Figure 1) ⁶. In contrast, the spindle cells in non-desmoplastic spindle cell melanomas are in direct contact with one another. The cells resemble fibroblasts, as found in scar tissue, but usually display a degree of cytological atypia.² The amount of collagen present is highly variable. In many DMs, there is also a non-DM component. Immunohistochemically, DM differs from non-DM in its expression of melanoma-associated antigens. Whilst DM usually expresses S100 protein and SOX10, DM is almost always negative for MelanA/Mart1 and HMB45/GP100. At times, S100 immunostaining can be useful in defining the extent of DM.

In 2005, it was proposed that DM should be sub-classified into “pure” DM and “mixed” DM, on the basis that the subclasses exhibit differing clinical behaviour.⁷⁻⁹ Those with a $\geq 90\%$ DM component were defined as “pure” DMs, while “mixed” DMs were those comprising $>10\%$ and $<90\%$ DM. Close to 50% of all DMs are pure DMs.^{3-5,10-13} In a review of 252 DMs, Murali *et al* showed that pure DMs differ significantly from mixed DMs in location, Clark level of invasion, Breslow thickness, mitotic rate, perineural invasion and locoregional recurrence rate.¹¹ A lower rate of distant metastasis with pure DM and better survival have been demonstrated in some series^{5,7,8,10} but not in others.^{11,14} One study compared survival in 117 patients with pure DM with 2273 cases of superficial spreading melanoma and found significantly improved melanoma-specific survival for pure DM after adjusting for other variables (HR 0.49, P = 0.01)¹⁵.

Clinically, melanomas that are predominantly desmoplastic usually present as firm plaques, nodules or areas of thickening and are often not pigmented unless there is a lentigo maligna in the overlying epidermis (present in approximately 50% of cases).¹⁶ The frequently unremarkable clinical appearance often leads to delayed diagnosis, consequently DMs tend to present at a more advanced clinical stage of disease than other melanoma subtypes.^{17,18} The mean and median thickness of DMs is substantial - around 4.0mm (2.0 mm- 6.5mm) in reported series,^{2-5,10-14,17,19,20} and the majority of DMs have invasion to Clark level IV or V.

DMs are strongly associated with sun-exposure and most frequently arise in the head and neck region.^{2,4,10,13,14,20,21} In one large study of scalp melanomas, 29% were desmoplastic.²² DMs are more common in males (M:F 2:1) and in older patients (median age 60-70 years) compared with patients with non-DMs (median age 50 years).^{2-5,10,12-14,20,23-25}

Cutaneous melanoma is known to have a much higher number of mutations than most other cancers, attributed to the role of sunlight exposure in its aetiology.²⁶ Of all melanoma subtypes, DM is the most likely to arise on severely sun-damaged skin and, consistent with this, recent evidence indicates that DM has the highest mutation burden of any melanoma subtype.²⁷ The high mutation burden is probably why metastatic DM responds particularly well to immunotherapy²⁸. Similarly, the driver mutations associated with DM differ from those more commonly seen in other types of cutaneous melanoma. Frequently mutated genes in DM include: *NF1*, *ERBB2*, *MAP2K1*, *MAP3K1*, *EGFR*, *MET*, *TERT*, *NFKBIE*, *PIK3CA* and *PTPN11*²⁷. *BRAF* and *NRAS* mutations are less frequent than in other melanoma subtypes.

Neurotropism in desmoplastic melanomas

DM has a propensity for neurotropism. Neurotropism usually involves tumor invasion into and along nerves perineurally or endoneurally. Rarely the tumor cells themselves may form structures resembling nerves and some regard this as a form of neurotropism. In the great majority of cases, however, neurotropism takes the first of these forms (perineural or endoneural tumor invasion, with perineural invasion more common). DMs with neurotropism are designated desmoplastic neurotropic melanomas (DNMs)^{2,29,30}. Neurotropism is seen in 30–60% of DMs^{3,4,7,11-14,21,31} and is found most frequently in pure DMs. Occasionally, large named nerves can be involved, an issue that can be particularly difficult to manage clinically when there is tumor extension along cranial nerves and their branches from a cutaneous primary site on the head or neck towards the base of the skull.¹⁴ It is important to note that neurotropism is not exclusive to DMs. Up to 30% of neurotropic melanomas are not DMs.³⁰ Valey *et al* reported a series of neurotropic melanomas in which 191 of 671 cases (28%) were not DMs.³⁰ Some evidence suggests that there may also be a higher incidence of neurotropism in acral melanomas, where it is reported in up to 8% of cases.^{32,33}

Surgical Management of Desmoplastic Melanoma: Margins of Excision

Early reports of DM highlighted a very high risk of local recurrence, ranging from 25% to 60%^{17,34-36} and suggested the need for more aggressive local treatment than for non-DMs, with wider margins and the use of adjuvant

radiotherapy (RT) to reduce the risk of local recurrence.¹⁹ More contemporary studies do not show such an alarmingly high rate of local recurrence.^{2,4,12-14,21} Nevertheless, the local recurrence rate for DM in these later studies (6–15%) is still higher than for non-DM (<5%).⁴ The high rate of local recurrence reported in early studies related to incomplete or close resection margins in most of the patients who recurred locally.^{12,14,30} Neurotropism has not been demonstrated to be a significant independent risk factor for local recurrence in most studies of DM,^{11,12,14,17,19,30,35,37} nor in studies of non-DM.^{30,33} The reported relationship between subtype of DM (pure vs mixed) and the risk of local recurrence is variable, with some studies showing a higher risk of local recurrence for pure DM compared with mixed DM^{10,11}, but others showing no difference in risk.^{5,14}

To date, no prospective randomized clinical trials have specifically examined the appropriate clinical or histological margins required to minimize the risk of local recurrence in patients with DM.

Local recurrence associated with DM as the initial site of recurrence is associated with a high rate of development of distant metastases, as it is with melanomas in general. Guadagnolo *et al* reported that 19 of 130 patients (15%) with DM developed local recurrence, and 15 of the 19 developed the local recurrence as the first site of recurrence¹⁴. Of these, 9 (60%) went on to develop distant metastases. Similarly, Maurichi *et al* reported subsequent distant metastasis in 22 of 37 patients (59%) with local recurrence¹⁰.

Varey *et al* reported no effect on local recurrence rates for neurotropic melanomas irrespective of whether the neurotropism occurred in association with DM or non-DM.^{30,38} There was however, a significant relationship between inadequate histological margins (<2mm vs ≥8mm) and local

recurrence for all neurotropic melanomas. Multiple studies have shown that local recurrence is strongly related to involved definitive resection margins.^{2,12,14,30}

In summary, if adequate histological margins are achieved, there is no evidence that DM is associated with a higher rate of local recurrence compared with non-DM. Further, there is no evidence supporting the suggestion that excision margins for DM or neurotropic DM should differ from those recommended for other melanoma subtypes.

Adjuvant treatment of the primary site: radiotherapy

No randomized controlled trials addressing the potential benefit of adjuvant radiotherapy (RT) for DM or neurotropic melanoma have been published. However, Varey *et al* found in their retrospective study of neurotropic melanomas that RT (given to 82 patients) halved the risk of local recurrence if histological margins were $<8\text{mm}$ ³⁰, with no difference between DM and non-DM.

Guadagnolo *et al* found a significant reduction in the local recurrence rate in 130 DM patients treated with adjuvant RT. On subset analysis in this study, no benefit was observed with RT for DMs with no evidence of neurotropism, or mixed DMs.¹⁴

Oliver *et al* also reported better local control in a small subset of DM patients who received adjuvant RT. There was no local recurrence in 10 patients treated with surgery and RT, but recurrence occurred in 10 of 85 patients (12%) who were initially treated with surgery alone ($P=0.59$)⁴. Strom *et al* reported results for 277 DM patients with a median follow-up of 43 months¹².

The overall local recurrence rate was 13%. There was a very substantial benefit for adjuvant RT if resection margins were reported to be histologically involved (5-year actuarial local control 89% vs 18%, $p=0.003$) and a reduced local recurrence rate with adjuvant RT for head and neck primaries with negative margins (local control 95% vs 76%, $p=0.03$). It was concluded that two subsets of patients with DM and clear resection margins could safely have adjuvant RT omitted: 1) those with non-head and neck site and ≤ 4 mm thick; 2) those with no neurotropism and ≤ 4 mm thick.

Chen *et al* reviewed 128 patients with DNM². Twenty-seven of the patients received adjuvant RT, 26 with primaries in the head and neck region, often with an excision margin < 5 mm. Local control rates in the adjuvant RT group were similar to the surgery-only group. It was concluded that adjuvant RT can produce local control rates similar to those produced by adequate surgical excision, when the latter cannot be achieved.

Sentinel node biopsy for desmoplastic melanoma

Regional lymph node involvement rates have been reported to be lower in DMs than in non-DMs and, as a result, standard recommendations pertaining to sentinel node biopsy (SNB) for the staging of primary cutaneous melanoma may not be applicable.

Dunne *et al* published a systematic review of 16 case series that reported the SN status of 1519 patients with DM³⁹. The SN-positivity rate was 6.5%, compared with an expected rate of 15–20% for non-DMs, and was significantly lower for pure DMs (5.4%) compared with mixed DMs (13.8%).

The authors proposed that SNB should be considered for patients with mixed DM, as it would be for non-DM, but not for those with pure DM. However,

the NCCN guidelines⁴⁰ advise that a SN-positivity rate of >5% warrants consideration of SNB. Furthermore, an initial partial biopsy may indicate pure DM with the final resection showing mixed DM, leading to the erroneous omission of a SNB at the time of complete resection if a policy of not performing SNB for pure DM is adopted. In a recently-published, evidence-based online tool for estimating the likelihood of SN-positivity, the risk is considerably lower for pure DMs, but the presence of other predictive clinico-pathological risk factors⁴¹ often results in an estimated risk of SN-positivity exceeding 5% by a considerable margin.

Systemic therapy for advanced stage metastatic desmoplastic melanoma

DM has one of the highest mutation burdens of any tumor.²⁷ The high mutation burden is probably why metastatic DM responds particularly well to immunotherapy²⁸. Driver mutations in *BRAF* and *NRAS* are uncommon in DM, hence targeted therapy with a MAPK-inhibitor is rarely indicated.

Current national and international treatment guidelines for desmoplastic and desmoplastic neurotropic melanomas

Twenty-nine published guidelines were identified that appeared to be the most recent originating from specific guideline groups.

The clinical management information detailed earlier is reflected in most melanoma guidelines from around the world, but some contain recommendations that do not appear to be evidence-based. Eleven guidelines provide specific advice for the management of DM and DNM^{40,42-51}, seven simply suggest reporting the subtype in the pathology report⁵²⁻⁵⁸ and

11 do not address the management of DM as a separate entity^{42,59-68}. The guidelines that do provide advice base their recommendations on low-level evidence (case series) or low-level evidence in combination with expert consensus.

The recommendations made in published guidelines in relation to the management of DM and DNM, where they exist, are documented in Table 1, together with the levels of evidence on which they are based. Where the management of DM and DNM is specifically mentioned and the supporting levels of evidence are satisfactory, there is generally little disagreement in the guideline recommendations. These are summarized as follows:

1. Pathological reporting

Nine guidelines recommend that if a melanoma is of the desmoplastic subtype, this should be noted in the pathology report^{40,43,49,51,53-55,57,69}.

Two guidelines state that it is important for the reporting pathologist to distinguish between pure and mixed DM.^{40,53} Seven guidelines advise that the presence of neurotropism should be reported.^{43,49,52,54-56,58}

2. Excision margins

Only three guidelines make specific recommendations about excision margins for DM^{45,48,50}. The Norwegian guidelines recommend excision margins of 2-3cm, even for DMs only 1-2mm in Breslow thickness⁴⁸, but there is no evidence supporting this recommendation. The evidence-based South African and Australian guidelines specifically recommend using the same margins for DM as for non-DM, based on Breslow thickness^{45,50}.

3. Adjuvant radiotherapy

Six guidelines state that if excision margins are considered to be inadequate, adjuvant radiotherapy to the primary site is recommended for DMs and neurotropic melanomas, to improve local tumor control^{140,44,45,51,69,70}. However, what constitutes an inadequate margin is specified only in the Australian guidelines (< 8 mm pathological margin)⁴⁵ and the German guidelines (< 1 cm)⁵¹. Adjuvant post-excision radiotherapy for DMs and neurotropic melanomas, not limited only to those with narrow or inadequate margins, is recommended in three guidelines^{43,71,72}. American Academy of Dermatology guidelines recommend radiotherapy for patients with DM treated with narrow margins or high risk features such as Breslow thickness > 4mm⁷⁰ and South African guidelines suggest that adjuvant radiotherapy be used for recurrent desmoplastic or neurotropic melanomas⁵⁰.

4. Sentinel node biopsy

Guidelines differ in their recommendations for SN biopsy in patients with DM. Since the SN-positivity rate is substantially lower for pure DM (5.4% in a systematic review)³⁹, some guidelines (e.g. NCCN⁴⁰) suggest that forgoing SN biopsy for confirmed pure DM may be considered, regardless of tumor thickness and ulceration status. Based on assessment of the available evidence, the Australian guidelines suggest that it should be considered using the same criteria as would be applied for non-DM⁴⁵. However, uncertainty is reflected by the suggestion in both the NCCN and Australian guidelines that there should be discussion about the value of SNB for patients with DM on a case-by-case basis by a multidisciplinary team^{40,45}. A recommendation for SNB for an individual patient will be based not only on the estimated SN-positivity rate (which can be obtained

from a validated nomogram)⁴¹, but also on the patient's comorbidities, and whether knowledge of SN status will change their management.

Acknowledgments:

This article was written by members of the Cancer Council Australia Melanoma Guidelines Working Party. Development of the guidelines was supported by Cancer Council Australia, Melanoma Institute Australia, Skin Cancer College Australasia and the Australian College of Dermatology. .

Figure legends

Figure 1 – Legend: Desmoplastic melanoma on the ear of a 70 year old female. A: the dermis is expanded by a cellular infiltrate of pleomorphic spindle shaped melanoma cells associated with fibrotic stroma (desmoplasia). There is marked solar elastosis in the dermis superficial to the tumour. B: The melanoma cells are highlighted by strong positive staining for S100 (nuclear and cytoplasmic).

Table. 1. International clinical guidelines relating to diagnosis and treatment of desmoplastic melanoma, including neurotropic melanoma.

Guideline group	Country	Year	Recommendation related to desmoplastic or neurotropic melanoma	Level of evidence	Grade of recommendation
European Dermatology Forum (EDF), the European Association of Dermato-Oncology (EADO) and the European Organization for Research and Treatment of Cancer (EORTC) ^{56,73}	Europe	2020	1. For the pathology report.... additional information can be provided, including; Vascular or perineural involvement	Not stated	Not stated
Japanese Dermatological Association ⁷⁴	Japan	2020	None	-	-
American Academy of Dermatology ⁴⁹	USA	2019	1. Optional features for inclusion in the pathology report; a. Histological subtype (including desmoplastic) b. Neurotropism/perineural invasion	II (Limited quality patient-oriented evidence) III (Other evidence, including consensus	B (based on inconsistent or limited quality patient-oriented evidence) C (Recommendation based on consensus,

			2. Adjuvant radiotherapy after wide excision may be used for desmoplastic cutaneous melanoma with high risk features (eg Breslow thickness > 4mm, Clark level V, extensive neurotropism/perineural invasion, head and neck location and/or narrow deep margin resection).	guideline, opinion, case studies) II/III	opinion, case studies, or disease-oriented evidence) B
Cancer Council Australia ⁴⁵	Australia	2019	1. Desmoplastic melanomas and neurotropic melanomas should be excised with the same margins as non-desmoplastic/neurotropic melanomas of the same Breslow thickness. 2. Adjuvant radiotherapy to the primary excision site should be considered for patients with desmoplastic or neurotropic melanomas for whom adequate (≥8mm) pathological resection margins are not achieved. 3. Sentinel lymph node biopsy (SLNB) should be considered for patients with desmoplastic melanoma, as it would be for non-desmoplastic melanoma.	IV(case series) IV(case series) III-1 (systematic review of case series)	Not stated Not stated Not stated
Cancer Care Ontario ⁷⁵	Canada	2019	None	-	-
European Society of Medical Oncologists ⁶⁸	Europe	2019	None	-	-
Deutsche Krebsgesellschaft,	Germany	2019	1. Histopathological peculiarities...(e.g. desmoplastic melanoma parts) and vascular intrusions should, if available, be optionally included	0 (Expert consensus)	0 (open recommendation)

Deutsche Krebshilfe, AWMF ⁵¹			2. In the case of desmoplastic melanomas that have not been resected with a sufficient safety margin (<1 cm or R1 / R2), postoperative radiotherapy should be carried out to ensure local tumor control.	2b (Individual cohort study)	B (Should recommend)
International Collaboration on Cancer Reporting (ICCR) ^{38,57}	USA, Canada, Australia, UK, Europe	2019	Non-core (recommended) elements for pathology reporting include melanoma subtype (including desmoplastic melanoma)	Not stated	Not stated
National Comprehensive Cancer Network ⁴⁰	USA	2019	<ol style="list-style-type: none"> 1. Adjuvant radiation may be considered for selected cases of high-risk desmoplastic melanoma with close margins when re-resection is not feasible and/or with extensive neurotropism 2. Encourage consistent reporting of; pure desmoplastic, if present, or specify pure vs. mixed desmoplastic with spindle cell and/or epithelioid cells 3. When pure desmoplastic melanoma is suspected, multidisciplinary consultation including an experienced dermatopathologist is recommended for determining staging and treatment options. 4. The role of SLNB in patients with pure desmoplastic melanoma is controversial. Clinicians may consider 	<p>2B (low-level evidence, non-uniform consensus)</p> <p>2A (Lower level evidence, uniform consensus)</p> <p>2A</p>	<p>Not stated</p> <p>Not stated</p> <p>Not stated</p> <p>Not stated</p>

			forgoing SLNB in patients with confirmed pure desmoplastic melanoma	2A	
National Health Commission of the People's Republic of China ⁵⁸	China	2018	A histopathological report of primary skin melanoma should contain.... neurotropism	Not stated	Not stated
Association of Italian Medical Oncologists ⁵²	Italy	2018	Presence of neurotropism should be part of a standard pathology report.	Not stated	Not stated
Norwegian Health Directorate ⁴⁸	Norway	2018	For Breslow thickness > 4mm and desmoplastic lesions; excision with 2-3 cm excision width (in vivo) margins	2b (knowledge based on at least one other well-designed quasi-experimental study without randomization)	Not stated
Finnish Melanoma Group ⁴⁶	Finland	2018	Indications for adjuvant therapy; large desmoplastic melanoma	Not stated	Not stated
Croatian Society for Medical Oncology ⁶⁵	Croatia	2017	None	-	-

French Dermatology Society and French National Federation of Comprehensive Cancer Centres, French National Cancer Institute ⁶⁴	France	2017	None	-	-
Scottish Intercollegiate Guidelines network (SIGN) ⁵³	Scotland	2017	It is important to distinguish between pure and mixed subtypes of desmoplastic melanoma. Pure DM is thought to be associated with a more favourable outcome and lower incidence of a positive SLNB Histogenic type should be included in the pathology report	Not stated	Not stated
Clinicians at University hospitals in Spain ⁴⁴	Spain	2017	Adjuvant radiotherapy is rarely necessary for excised local melanoma and can be considered for inadequate resection margins in lentigo maligna, and desmoplastic neurotropic melanoma	2b(Time series comparisons or dramatic results from uncontrolled studies)	B (not explained)
University Hospital clinicians (Zurich, Bern, Lausanne, Basel) ⁶¹	Switzerland	2016	None	-	-
Dutch Societies of Radiology, Dermatology and Venereology,	Netherlands	2016	None	-	-

Pathology, Surgery, Internal Medicine and Radiology ⁶²					
Central Oncology Institute, Warsaw ⁶⁹	Poland	2016	1. Features conditionally specified in the histopathological report: histological subtype ... other types, e.g. desmoplastic 2. Indication for complementary radiotherapy after primary tumor resection the following factors may be: desmoplastic melanoma cut with narrow margins, positive surgical margins (especially after excision local recurrence)... Increased neurotropism	Not stated Not stated	Not stated Not stated
UK National Disciplinary guidelines for head and neck cancers ⁵⁹	United Kingdom	2016	None	-	-
Brazilian Dermatological Society ⁶⁰	Brazil	2015	None	-	-
National Collaborating Centre for Cancer ⁶⁶	United Kingdom	2015	None	-	-
Danish Melanoma Group ⁵⁴	Denmark	2014	Neurotropism should be stated in the histopathology report Tumour type should include desmoplastic	Not stated	Not stated
State expert Centre of Ministry of Health of Ukraine,	Ukraine	2015	1. Histopathology report should state desmoplastic with or without neurotropism	Not stated	Not stated Not stated

National Cancer Institute of the Ministry of Health of Ukraine ⁴³			2. Adjuvant radiotherapy after surgery can be considered to improve local control	Non-randomized comparison	
Melanoma Cancer Site Team ⁶³	Canada	2013	None	Not stated	Not stated
Provincial Melanoma Treatment Guidelines ⁴²	Canada	2012	Adjuvant radiotherapy to the primary site can be considered to reduce local recurrence in the following conditions: Melanomas with desmoplastic or neurotropic features.	Not stated	Not stated
British Association of Dermatologists ⁵⁵	United Kingdom	2010	Desmoplastic melanoma with or without neurotropism should be recorded because of its different biological behaviour and clinical outcome	Case series	Not stated
Melanoma Advisory Board (consisting of dermatologists, oncologists, plastic surgeons and pathologists) ⁵⁰	South Africa	2004	1. Wider excision than is normal for other histological types of melanoma is recommended for desmoplastic melanoma 2. Postoperative radiotherapy in consultation with a specialist should be considered after surgical excision of recurrent desmoplastic or neurotropic melanoma	Two Case series	Not stated

REFERENCES

- 1 Broer PN, Walker ME, Goldberg C *et al.* Desmoplastic melanoma: a 12-year experience with sentinel lymph node biopsy. *Eur J Surg Oncol* 2013; **39**: 681-5.
- 2 Chen JY, Hruby G, Scolyer RA *et al.* Desmoplastic neurotropic melanoma: a clinicopathologic analysis of 128 cases. *Cancer* 2008; **113**: 2770-8.
- 3 Mohebbati A, Ganly I, Busam K *et al.* The role of sentinel lymph node biopsy in the management of head and neck desmoplastic melanoma. *Annals of surgical oncology* 2012; **19**: 4307-13.
- 4 Oliver DE, Patel KR, Switchenko J *et al.* Roles of adjuvant and salvage radiotherapy for desmoplastic melanoma. *Melanoma research* 2016; **26**: 35.
- 5 Pawlik TM, Ross MI, Prieto VG *et al.* Assessment of the role of sentinel lymph node biopsy for primary cutaneous desmoplastic melanoma. *Cancer* 2006; **106**: 900-6.
- 6 Conley J, Lattes R, Orr W. Desmoplastic malignant melanoma (a rare variant of spindle cell melanoma). *Cancer* 1971; **28**: 914-36.
- 7 Busam KJ, Mujumdar U, Hummer AJ *et al.* Cutaneous desmoplastic melanoma: reappraisal of morphologic heterogeneity and prognostic factors. *Am J Surg Pathol* 2004; **28**: 1518-25.
- 8 Hawkins WG, Busam KJ, Ben-Porat L *et al.* Desmoplastic melanoma: a pathologically and clinically distinct form of cutaneous melanoma. *Ann Surg Oncol* 2005; **12**: 207-13.

- 9 Scolyer RA, Thompson JF. Desmoplastic melanoma: a heterogeneous entity in which subclassification as "pure" or "mixed" may have important prognostic significance. *Ann Surg Oncol* 2005; **12**: 197-9.
- 10 Maurichi A, Miceli R, Camerini T *et al.* Pure desmoplastic melanoma: a melanoma with distinctive clinical behavior. *Ann Surg* 2010; **252**: 1052-7.
- 11 Murali R, Shaw HM, Lai K *et al.* Prognostic factors in cutaneous desmoplastic melanoma: a study of 252 patients. *Cancer* 2010; **116**: 4130-8.
- 12 Strom T, Caudell JJ, Han D *et al.* Radiotherapy influences local control in patients with desmoplastic melanoma. *Cancer* 2014; **120**: 1369-78.
- 13 Han D, Han G, Zhao X *et al.* Clinicopathologic predictors of survival in patients with desmoplastic melanoma. *PLoS One* 2015; **10**: e0119716.
- 14 Guadagnolo BA, Prieto V, Weber R *et al.* The role of adjuvant radiotherapy in the local management of desmoplastic melanoma. *Cancer* 2014; **120**: 1361-8.
- 15 Howard MD WE, Wolfe R, McLean CA, Kelly JW, Pan Y. Differences between pure desmoplastic melanoma and superficial spreading melanoma in terms of survival, distribution and other clinicopathologic features. *J Eur Acad Dermatol Venereol* 2019; **33**: 1899-906.
- 16 Jaimes N, Chen L, Dusza SW *et al.* Clinical and dermoscopic characteristics of desmoplastic melanomas. *JAMA Dermatol* 2013; **149**: 413-21.
- 17 Lens MB, Newton-Bishop JA, Boon AP. Desmoplastic malignant melanoma: a systematic review. *Br J Dermatol* 2005; **152**: 673-8.
- 18 McCarthy SW, Scolyer RA, Palmer AA. Desmoplastic melanoma: a diagnostic trap for the unwary. *Pathology* 2004; **36**: 445-51.

- 19 Foote MC, Burmeister B, Burmeister E *et al.* Desmoplastic melanoma: the role of radiotherapy in improving local control. *ANZ J Surg* 2008; **78**: 273-6.
- 20 Wasif N, Gray RJ, Pockaj BA. Desmoplastic melanoma - the step-child in the melanoma family? *J Surg Oncol* 2011; **103**: 158-62.
- 21 Posther KE, Selim MA, Mosca PJ *et al.* Histopathologic characteristics, recurrence patterns, and survival of 129 patients with desmoplastic melanoma. *Ann Surg Oncol* 2006; **13**: 728-39.
- 22 Xie C, Pan Y, McLean C *et al.* Scalp melanoma: Distinctive high risk clinical and histological features. *Australas J Dermatol* 2017; **58**: 181-8.
- 23 Carlson JA, Dickersin GR, Sober AJ *et al.* Desmoplastic neurotropic melanoma. A clinicopathologic analysis of 28 cases. *Cancer* 1995; **75**: 478-94.
- 24 Sims JR, Wieland CN, Kasperbauer JL *et al.* Head and neck desmoplastic melanoma: Utility of sentinel node biopsy. *Am J Otolaryngol* 2017; **38**: 537-41.
- 25 Murali R, Shaw HM, Lai K *et al.* Prognostic factors in cutaneous desmoplastic melanoma: a study of 252 patients. *Cancer* 2010; **116**: 4130-8.
- 26 Alexandrov LB, Nik-Zainal S, Wedge DC *et al.* Signatures of mutational processes in human cancer. *Nature* 2013; **500**: 415-21.
- 27 Shain AH, Garrido M, Botton T *et al.* Exome sequencing of desmoplastic melanoma identifies recurrent NFKBIE promoter mutations and diverse activating mutations in the MAPK pathway. *Nature genetics* 2015; **47**: 1194-9.
- 28 Eroglu Z, Zaretsky JM, Hu-Lieskovan S *et al.* High response rate to PD-1 blockade in desmoplastic melanomas. *Nature* 2018; **553**: 347-50.

- 29 Reed RJ, Leonard DD. Neurotropic melanoma. A variant of desmoplastic melanoma. *Am J Surg Pathol* 1979; **3**: 301-11.
- 30 Varey AHR, Goumas C, Hong AM *et al.* Neurotropic melanoma: an analysis of the clinicopathological features, management strategies and survival outcomes for 671 patients treated at a tertiary referral center. *Mod Pathol* 2017; **30**: 1538-50.
- 31 Quinn MJ, Crotty KA, Thompson JF *et al.* Desmoplastic and desmoplastic neurotropic melanoma: experience with 280 patients. *Cancer* 1998; **83**: 1128-35.
- 32 Nagore E, Pereda C, Botella-Estrada R *et al.* Acral lentiginous melanoma presents distinct clinical profile with high cancer susceptibility. *Cancer Causes Control* 2009; **20**: 115-9.
- 33 Scanlon P, Tian J, Zhong J *et al.* Enhanced immunohistochemical detection of neural infiltration in primary melanoma: is there a clinical value? *Hum Pathol* 2014; **45**: 1656-63.
- 34 Jaroszewski DE, Pockaj BA, DiCaudo DJ *et al.* The clinical behavior of desmoplastic melanoma. *Am J Surg* 2001; **182**: 590-5.
- 35 Vongtama R, Safa A, Gallardo D *et al.* Efficacy of radiation therapy in the local control of desmoplastic malignant melanoma. *Head Neck* 2003; **25**: 423-8.
- 36 Smithers B, McLeod G, Little J. Desmoplastic, neural transforming and neurotropic melanoma: a review of 45 cases. *Australian and New Zealand Journal of Surgery* 1990; **60**: 967-72.
- 37 Livestro DP, Muzikansky A, Kaine EM *et al.* Biology of desmoplastic melanoma: a case-control comparison with other melanomas. *J Clin Oncol* 2005; **23**: 6739-46.

- 38 Scolyer R.A., Balamurgan T., Busam K *et al.* Invasive Melanoma, Histopathology Reporting Guide, 2nd Edition. In: *International Collaboration on Cancer Reporting*. 2019.
- 39 Dunne JA, Wormald JC, Steele J *et al.* Is sentinel lymph node biopsy warranted for desmoplastic melanoma? A systematic review. *J Plast Reconstr Aesthet Surg* 2017; **70**: 274-80.
- 40 Coit DG, Thompson JA, Albertini MR *et al.* Cutaneous Melanoma, Version 2.2019, NCCN Clinical Practice Guidelines in Oncology. *J Natl Compr Canc Netw* 2019; **17**: e1.
- 41 Lo SN, Ma J, Scolyer RA *et al.* Improved risk prediction calculator for sentinel node positivity in patients with melanoma: The Melanoma Institute Australia nomogram. *J Clin Oncol* 2020: JCO. 19.02362.
- 42 Abbas T, Brunet B, Dubey A *et al.* Provincial Melanoma Treatment Guidelines. In: *Clinical Practice Guidelines*, Vol. 2019. Regina, Saskatchewan, Canada: Saskatchewan Cancer Agency. 2012.
- 43 Alexandrovich GA, Igorovich KS, A. IL *et al.* Melanoma. Adapted, evidence based clinical setting guidelines. In: (National Cancer Institute of the Ministry of Health of Ukraine, ed), Vol. 2019. Ukraine: National Cancer Institute of the Ministry of Health of Ukraine,. 2015.
- 44 Berrocal A, Arance A, Castellon V *et al.* SEOM clinical guideline for the management of malignant melanoma (2017). *Clin Trans Oncol* 2018; **20**: 69-74.
- 45 Hughes TM, Gyorki D, Kelly J *et al.* Primary desmoplastic and neurotropic melanomas. In: *Clinical Guidelines Network - Melanoma*. Australia: Cancer Council Australia. 2018.

- 46 Koskivuo I, Hernberg M, Ilmonen S *et al.* [Oncological treatment of skin melanoma 2018, Primary melanoma surgical treatment 2018]. In, Vol. 2019. Turku, Finland: Finnish Oncology Association. 2018.
- 47 Pflugfelder A, Kochs C, Blum A *et al.* Malignant melanoma S3-guideline “diagnosis, therapy and follow-up of melanoma”. *J Dtsch Dermatol Ges* 2013; **11**: 1-116.
- 48 Straume O, Akslen L, Bachmann IM *et al.* Nasjonalt handlingsprogram med retningslinjer for diagnostikk, behandling og oppfølging av maligne melanomer. In, Vol. 2019. Oslo, Norway: Helsedirektoratet. 2018.
- 49 Swetter SM, Tsao H, Bichakjian CK *et al.* Guidelines of care for the management of primary cutaneous melanoma. *J Am Acad Dermatol* 2019; **80**: 208-50.
- 50 Whitaker D, Sinclair W. Melanoma Advisory Board - Guideline on the management of melanoma. *J S Afr Med* 2004; **94**: 699-707.
- 51 Arbeitsgemeinschaft der Wissenschaftlichen Medizinischen Fachgesellschaften e.V. (AWMF). S3-Leitlinie zur Diagnostik, Therapie und Nachsorge des Melanoms. In: *Leitlinienprogramm Onkologie der Arbeitsgemeinschaft der Wissenschaftlichen Medizinischen Fachgesellschaften e.V. (AWMF), Deutschen Krebsgesellschaft e.V. (DKG) und Deutschen Krebshilfe (DKH)*. Vol. 2020: Arbeitsgemeinschaft der Wissenschaftlichen Medizinischen Fachgesellschaften e.V. (AWMF),. 2019.
- 52 Ascierto PA, Minisini AM, Botti G *et al.* Linee Guida - Melanoma. In: (Medica AldO, ed), Vol. 2019. Milan, Italy: Associazione Italiani di Oncologia Medica. 2018.
- 53 Brown E, Ballantyne S, Brown J *et al.* Cutaneous melanoma: A national clinical guideline In: (Scottish Intercollegiate Guidelines Network (SIGN)).

- ed), Vol. 2019. Edinburgh, Scotland: Scottish Intercollegiate Guidelines Network (SIGN). 2017.
- 54 Drzewiecki KT, Gjorup C. [Treatment of primary tumour]. In, Vol. 2019. Copenhagen, Denmark: Danish Melanoma Group,. 2014.
- 55 Marsden J, Newton-Bishop J, Burrows L *et al*. Revised UK guidelines for the management of cutaneous melanoma 2010. *Br J Dermatol* 2010; **163**: 238-56.
- 56 Garbe C, Amaral T, Peris K *et al*. European consensus-based interdisciplinary guideline for melanoma. Part 1: Diagnostics - Update 2019. *Eur J Cancer* 2020; **126**: 141-58.
- 57 Williams MD, Franchi A, Helliwell T *et al*. Data Set for the Reporting of Mucosal Melanomas of the Head and Neck: Explanations and Recommendations of the Guidelines From the International Collaboration on Cancer Reporting. *Arch Pathol Lab Med* 2019; **143**: 603-9.
- 58 National Health Commission of the People's Republic of China. Chinese guidelines for the diagnosis and treatment of melanoma 2018 (English version). *Chin J Cancer Res* 2019; **31**: 578-85.
- 59 Ahmed OA, Kelly C. Head and neck melanoma (excluding ocular melanoma): United Kingdom National Multidisciplinary Guidelines. *J Laryngol Otol* 2016; **130**: S133-S41.
- 60 Castro LGM, Messina MC, Loureiro W *et al*. Guidelines of the Brazilian Dermatology Society for diagnosis, treatment and follow up of primary cutaneous melanoma-Part I. *An Bras Dermatol* 2015; **90**: 851-61.
- 61 Dummer R, Siano M, Hunger RE *et al*. The updated Swiss guidelines 2016 for the treatment and follow-up of cutaneous melanoma. *Swiss Med Wkly* 2016; **146**.

- 62 Dutch Melanoma Working Group. [Melanoma National Directive 2.1]. In, Vol. 2019. 2016.
- 63 Giacomantonio C, Morris S, Langley R *et al.* Guidelines for the Management of Malignant Melanoma. Cancer Care Nova Scotia. In, Vol. 2019. Halifax, Nova Scotia, Canada: Nova Scotia Health Authority. 2013.
- 64 Guillot B, Dalac S, Denis MG *et al.* French updated recommendations in Stage I to III melanoma treatment and management. *J Eur Acad Dermatol Venereol* 2017; **31**: 594-602.
- 65 Herceg D, Jakopovic M, Dedic Plavetic N *et al.* Cancer patients follow-up- Croatian Society for medical Oncology Clinical Guidelines Part V: melanoma, sarcomas, central nerve system tumors, lung cancer. *Lijec Vjesn* 2017; **139**: 17-23.
- 66 National Institute for Health and Care Excellence (NICE). Melanoma: assessment and management (NICE Guideline [NG14]). In: *NICE Guidance* (National Institute for Health and Care Excellence, ed), Vol. 2019. London, UK: National Institute for Health and Care Excellence (NICE),. 2015.
- 67 Wright F, Souter LH, Kellett S *et al.* Primary Excision Margins and Sentinel Lymph Node Biopsy in Cutaneous Melanoma. In: *Guidelines and Advice*, Vol. 2019. Toronto, Canada: Cancer Care Ontario. 2017.
- 68 Michielin O, van Akkooi ACJ, Ascierto PA *et al.* Cutaneous melanoma: ESMO Clinical Practice Guidelines for diagnosis, treatment and follow-updagger. *Ann Oncol* 2019; **30**: 1884-901.
- 69 Rutkowski P, Wysocki PJ, Nasierowska-Guttmejer A *et al.* Cutaneous melanoma — diagnostic and therapeutic guidelines in 2016. *Oncol Clin Pract* 2015; **11**: 216-331.

- 70 Swetter SM, Tsao H, Bichakjian CK *et al.* Guidelines of care for the management of primary cutaneous melanoma. *Journal of the American Academy of Dermatology* 2019; **80**: 208-50.
- 71 Koskivuo I, Hernberg M, Ilmonen S *et al.* [Oncological treatment of skin melanoma 2018, Primary melanoma surgical treatment 2018]. In, Vol. 2019. 2018.
- 72 Abbas T, Brunet B, Dubey A *et al.* Provincial Melanoma Treatment Guidelines. In, Vol. 2019. 2012.
- 73 Garbe C, Amaral T, Peris K *et al.* European consensus-based interdisciplinary guideline for melanoma. Part 2: Treatment - Update 2019. *Eur J Cancer* 2020; **126**: 159-77.
- 74 Nakamura Y, Asai J, Igaki H *et al.* Japanese Dermatological Association Guidelines: Outlines of guidelines for cutaneous melanoma 2019. *J Dermatol* 2020; **47**: 89-103.
- 75 Wright FC, Souter LH, Kellett S *et al.* Primary excision margins, sentinel lymph node biopsy, and completion lymph node dissection in cutaneous melanoma: a clinical practice guideline. *Curr Oncol* 2019; **26**: e541-e50.

Guideline group	Country	Year	Recommendation related to desmoplastic or neurotropic melanoma	Level of evidence	Grade of recommendation
European Dermatology Forum (EDF), the European Association of Dermato-Oncology (EADO) and the European Organization for Research and Treatment of Cancer (EORTC) ^{56,73}	Europe	2020	1. For the pathology report.... additional information can be provided, including; Vascular or perineural involvement	Not stated	Not stated
Japanese Dermatological Association ⁷⁴	Japan	2020	None	-	-
American Academy of Dermatology ⁴⁹	USA	2019	1. Optional features for inclusion in the pathology report; <ol style="list-style-type: none"> Histological subtype (including desmoplastic) Neurotropism/perineural invasion 2. Adjuvant radiotherapy after wide excision may be used for desmoplastic cutaneous melanoma with high risk features (eg Breslow thickness > 4mm, Clark level V, extensive neurotropism/ perineural invasion, head and neck location and/or narrow deep margin resection).	II (Limited quality patient-oriented evidence) III (Other evidence, including consensus guideline, opinion, case studies) II/III	B (based on inconsistent or limited quality patient-oriented evidence) C (Recommendation based on consensus, opinion, case studies, or disease-oriented evidence) B
Cancer Council Australia ⁴⁵	Australia	2019	1. Desmoplastic melanomas and neurotropic melanomas should be excised with the same margins as non-desmoplastic/neurotropic melanomas of the same Breslow thickness. 2. Adjuvant radiotherapy to the primary excision site should be considered for patients with desmoplastic or neurotropic melanomas for whom adequate (≥8mm) pathological resection margins are not achieved. 3. Sentinel lymph node biopsy (SLNB) should be considered for patients with desmoplastic melanoma, as it would be for non-desmoplastic melanoma.	IV(case series) IV(case series) III-1 (systematic review of case series)	Not stated Not stated Not stated
Cancer Care Ontario ⁷⁵	Canada	2019	None	-	-
European Society of Medical Oncologists ⁶⁸	Europe	2019	None	-	-
Deutsche Krebsgesellschaft, Deutsche Krebshilfe, AWMF ⁵¹	Germany	2019	1. Histopathological peculiarities...(e.g. desmoplastic melanoma parts) and vascular intrusions should, if available, be optionally included 2. In the case of desmoplastic melanomas that have not been resected completely, postoperative radiotherapy should be carried out to ensure local tumor control.	0 (Expert consensus) 2b (Individual cohort study)	0 (open recommendation) B (Should recommend)
International Collaboration on Cancer Reporting (ICCR) ^{38,57}	USA, Canada, Australia, UK, Europe	2019	Non-core (recommended) elements for pathology reporting include melanoma subtype (including desmoplastic melanoma)	Not stated	Not stated

Author Manuscript

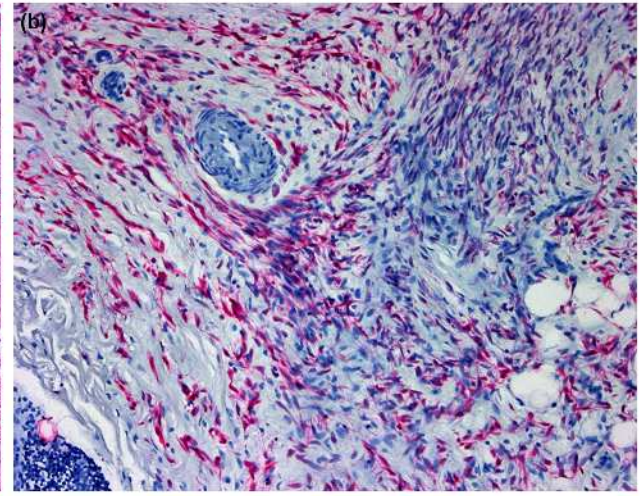
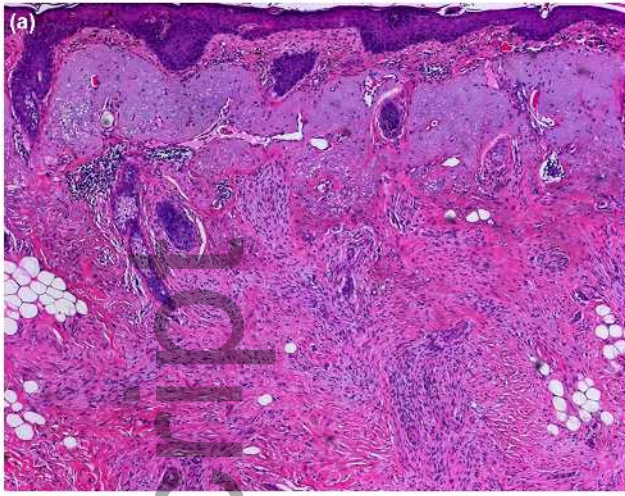
This article is protected by copyright. All rights reserved.

Guideline group	Country	Year	Recommendation related to desmoplastic or neurotropic melanoma	Level of evidence	Grade of recommendation
National Comprehensive Cancer Network ⁴⁰	USA	2019	1. Adjuvant radiation may be considered for selected cases of high-risk desmoplastic melanoma with close margins when re-resection is not feasible and/or with extensive neurotropism	2B (low-level evidence, non-uniform consensus)	Not stated
			2. Encourage consistent reporting of; pure desmoplastic, if present, or specify pure vs. mixed desmoplastic with spindle cell and/or epithelioid cells	2A (Lower level evidence, uniform consensus)	Not stated
			3. When pure desmoplastic melanoma is suspected, multidisciplinary consultation including an experienced dermatopathologist is recommended for determining staging and treatment options.	2A	Not stated
			4. The role of SLNB in patients with pure desmoplastic melanoma is controversial. Clinicians may consider forgoing SLNB in patients with confirmed pure desmoplastic melanoma	2A	Not stated
National Health Commission of the People's Republic of China ⁵⁸	China	2018	A histopathological report of primary skin melanoma should contain.... neurotropism	Not stated	Not stated
Association of Italian Medical Oncologists ⁵²	Italy	2018	Presence of neurotropism should be part of a standard pathology report.	Not stated	Not stated
Norwegian Health Directorate ⁴⁸	Norway	2018	For Breslow thickness > 4mm and desmoplastic lesions; excision with 2-3 cm excision width (in vivo) margins	2b (knowledge based on at least one other well-designed quasi-experimental study without randomization)	Not stated
Finnish Melanoma Group ⁴⁶	Finland	2018	Indications for adjuvant therapy; large desmoplastic melanoma	Not stated	Not stated
Croatian Society for Medical Oncology ⁶⁵	Croatia	2017	None	-	-
French Dermatology Society and French National Federation of Comprehensive Cancer Centres, French National Cancer Institute ⁶⁴	France	2017	None	-	-
Scottish Intercollegiate Guidelines network (SIGN) ⁵³	Scotland	2017	It is important to distinguish between pure and mixed subtypes of desmoplastic melanoma. Pure DM is thought to be associated with a more favourable outcome and lower incidence of a positive SLNB Histogenic type should be included in the pathology report	Not stated	Not stated
Clinicians at University hospitals in Spain ⁴⁴	Spain	2017	Adjuvant radiotherapy is rarely necessary for excised local melanoma and can be considered for inadequate resection margins in lentigo maligna, and desmoplastic neurotropic melanoma	2b (Time series comparisons or dramatic results from uncontrolled studies)	B (not explained)
University Hospital clinicians (Zurich, Bern, Lausanne, Basel) ⁶¹	Switzerland	2016	None	-	-
Dutch Societies of Radiology, Dermatology and Venereology, Pathology, Surgery, Internal Medicine and Radiology ⁶²	Netherlands	2016	None	-	-
Central Oncology Institute, Warsaw ⁶⁹	Poland	2016	1. Features conditionally specified in the histopathological report, including subtypes, other types of desmoplastic	Not stated	Not stated
			2. Indication for complementary radiotherapy after primary tumor resection the following factors may be: desmoplastic melanoma cut with narrow margins, positive surgical margins (especially after excision local recurrence).... Increased neurotropism	Not stated	Not stated

Author Manuscript

This article is protected by copyright. All rights reserved.

Guideline group	Country	Year	Recommendation related to desmoplastic or neurotropic melanoma	Level of evidence	Grade of recommendation
UK National Disciplinary guidelines for head and neck cancers ⁵⁹	United Kingdom	2016	None	-	-
Brazilian Dermatological Society ⁶⁰	Brazil	2015	None	-	-
National Collaborating Centre for Cancer ⁶⁶	United Kingdom	2015	None	-	-
Danish Melanoma Group ⁵⁴	Denmark	2014	Neurotropism should be stated in the histopathology report Tumour type should include desmoplastic	Not stated	Not stated
State expert Centre of Ministry of Health of Ukraine, National Cancer Institute of the Ministry of Health of Ukraine ⁴³	Ukraine	2015	1. Histopathology report should state desmoplastic with or without neurotropism 2. Adjuvant radiotherapy after surgery can be considered to improve local control	Not stated Non-randomized comparison	Not stated Not stated
Melanoma Cancer Site Team ⁶³	Canada	2013	None	Not stated	Not stated
Provincial Melanoma Treatment Guidelines ⁴²	Canada	2012	Adjuvant radiotherapy to the primary site can be considered to reduce local recurrence in the following conditions: Melanomas with desmoplastic or neurotropic features.	Not stated	Not stated
British Association of Dermatologists ⁵⁵	United Kingdom	2010	Desmoplastic melanoma with or without neurotropism should be recorded because of its different biological behaviour and clinical outcome	Case series	Not stated
Melanoma Advisory Board (consisting of dermatologists, oncologists, plastic surgeons and pathologists) ⁵⁰	United States of America	2004	1. Preoperative radiotherapy is recommended for desmoplastic melanoma 2. Postoperative radiotherapy in consultation with a specialist should be considered after surgical excision of recurrent desmoplastic or neurotropic melanoma	Two Case series	Not stated



jdv_17154_f1.tif

Author Manuscript