

1
2
3
4
5
6
7
8
9
10
11
12
13
14
15
16
17
18
19
20
21
22
23
24
25
26
27
28
29
30
31

DR. KRISTEN LLOYD (Orcid ID : 0000-0002-4834-5222)
DR. MATTHEW RONALD WILLIAM SMITH (Orcid ID : 0000-0002-8051-1534)
DR. CHRIS WHITTON (Orcid ID : 0000-0003-0012-4065)
DR. CATHERINE STEEL (Orcid ID : 0000-0001-7106-7884)

Article type : Case Report

Osteochondral fragmentation of the palmarolateral/plantarolateral aspect of the distal phalanx in four horses: a novel location

K. A. Lloyd^{*a}, M. R. W. Smith^b, R. C. Whitton^a, A. W. Stent^a and C. M. Steel^a
^aFaculty of Veterinary and Agricultural Sciences, The University of Melbourne, Werribee, Victoria, Australia and ^bNewmarket Equine Hospital, Newmarket, UK.

*Corresponding author email: kristenlloyd.vet@gmail.com

Keywords: horse; articular; distal interphalangeal joint; fragment

Running Head: Osteochondral fragmentation of the distal phalanx

Summary

Four horses presenting for lameness were diagnosed with unilateral osteochondral fragmentation (OCF) of the palmarolateral/plantarolateral aspect of the distal phalanx within the distal interphalangeal joint (DIPJ). Histologic evaluation of one case supported a diagnosis of osteochondritis dissecans (OCD), with patient age and history from two cases suggesting a traumatic origin. Lesion appearance on conventional radiography, computed tomography (CT), nuclear scintigraphy and magnetic resonance imaging (MRI) are described. Fragmentation was best identified on dorsal 65° proximal-palmaro/plantarodistal oblique (D65°PrPDiO/D65°PrPIDiO) and dorsal 65° proximal-palmaro/plantarodistal lateral

This is the author manuscript accepted for publication and has undergone full peer review but has not been through the copyediting, typesetting, pagination and proofreading process, which may lead to differences between this version and the [Version of Record](#). Please cite this article as [doi: 10.1111/EVE.13456](https://doi.org/10.1111/EVE.13456)

This article is protected by copyright. All rights reserved

32 oblique (D65°Pr45°L-PDiMO/D65°Pr45°L-PiDiMO) radiographic projections of the foot,
33 but articular pathology appeared more severe on cross-sectional imaging modalities. In all
34 cases lameness was refractory to conservative management. Arthroscopic evaluation of the
35 DIPJ was performed in three horses, although the lesion was inaccessible in two. In one horse
36 access to the lesion was possible due to increased joint laxity, presumably due to concurrent
37 soft tissue injury. One horse was euthanased after failed conservative management, one was
38 pasture sound following palmar digital neurectomy 12 months after initial presentation, one
39 returned to racing and one was lost to follow up. Osteochondral fragmentation at this location
40 has not previously been described, treatment options are limited and the prognosis appears to
41 be poor.

42

43 **Introduction**

44 Osteochondral fragmentation (OCF) in horses can result from acute traumatic injury,
45 as a failure of the subchondral bone secondary to chronic loading and bone material fatigue
46 (Tidswell *et al.* 2008), or in the case of osteochondrosis dissecans (OCD) due to failure of
47 endochondral ossification (Stock *et al.* 2005; van Weeren 2012). The subsequent loss of
48 congruity at the joint surface, intra-articular debris and resulting synovitis can cause lameness
49 and lead to osteoarthritis, providing a rationale for attempting surgical removal soon after
50 diagnosis (Mellwraith *et al.* 2012; Graham *et al.* 2020).

51 Diagnosis of OCF is commonly made from radiographic findings, although
52 limitations exist, with Vanderperren *et al.* (2009) demonstrating that the number and location
53 of OCF identified on radiographs was in agreement with arthroscopic findings in only 44% of
54 cases. Kannegieter and Burbidge (1990) found better agreement between OCF identification
55 in the equine carpus, but additional lesions were still identified in 18% of cases on
56 arthroscopy that were not observed on pre-operative radiographs. Additional radiographic
57 projections or the use of complementary imaging using ultrasonography, CT or MRI with
58 superior bone and soft tissue contrast may therefore be required for accurate diagnosis prior
59 to surgical assessment.

60 The purpose of this report is to describe the clinical findings, diagnosis, attempted
61 treatment and outcome in four horses presenting with unilateral fore- or hindlimb lameness
62 diagnosed with OCF in a previously unreported location at the lateral, palmaro- or plantaro-
63 proximal aspect of the articular surface of the distal phalanx. Suspected aetiopathogeneses are

64 discussed, together with the histopathologic appearance of one horse's lesion on post-mortem
65 examination.

66 **Case History and Presentation**

67 Cases varied in age (range 2 to 20-years-old) and duration of lameness from acute in onset to
68 approximately 6 months duration. All cases presented with DIPJ effusion and were positive
69 to distal limb flexion. Diagnostic analgesia localised the lameness to the distal limb, and in
70 some cases more specifically to the DIPJ. Patient signalment, use, history and clinical
71 findings are provided in Table 1.

72 **Diagnostic Imaging**

73 A summary of pertinent diagnostic imaging findings on radiographic examination, CT, MRI
74 and nuclear scintigraphy are provided in Table 2, with the region of interest for each being
75 the distal limb below the level of the proximal interphalangeal joint. The OCF was best
76 observed on D65°PrPDiO or D65°Pr45°L-PDiMO (forelimb) and D65°PrPIDiO or
77 D65°Pr45°L-PIDiMO (hindlimb) radiographic projections (Figure 1). Additional information
78 regarding imaging techniques including machine details and images obtained are provided in
79 Supplementary Item 1.

80 **Surgical Treatment and Outcome**

81 Attempts at surgical removal of the OCF via arthroscopy of the DIPJ in three cases, in
82 addition to adjunct treatment and case outcomes are summarised in Table 3. The OCF in two
83 cases were deemed surgically inaccessible and their outcome was poor. In case three, lesion
84 access was possible given an increase in joint laxity suspected to be due to concurrent soft
85 tissue injury such as joint capsular disruption, although this was not definitively diagnosed.
86 The OCF was left in situ despite arthroscopic access given its extensive attachment to the
87 distal sesamoidean impar ligament (Figure 4). This horse subsequently had a successfully
88 racing career. The owners of one case declined surgical treatment and elected humane
89 euthanasia.

90 **Post Mortem and Histopathology**

91 Post-mortem examination was performed in one horse (case two). The distal phalanx
92 was decalcified and representative cross-sections of the lesion were obtained for
93 histopathology. Cartilage clefts dissected between the articular cartilage and subchondral
94 bone in the affected region, with an occasional fissure extending to the articular surface
95 (Figure 5). The surrounding cartilage was fragmented and degenerate with hypertrophy and
96 nesting of the remaining chondrocytes. The surface cartilage displayed mild fibrillation but

97 was otherwise unremarkable. Based on the characteristic histological features, a diagnosis of
98 OCD of the palmar aspect of the distal phalanx was made.

99

100 **Discussion**

101 This report describes four cases of OCF of the palmaro- or plantaro-lateral aspect of the distal
102 phalanx causing lameness in the horse. The OCF was visualised radiographically, albeit not
103 on routine projections indicating such lesions have the potential to be overlooked.
104 Furthermore, it was difficult to differentiate the source of the fragmentation given the
105 superimposition of the distal and middle phalanges, and the distal sesamoid bone. CT was
106 performed in all cases and revealed a greater extent of bone pathology. For example, in case
107 one a second OCF was identified on the adjacent distal sesamoid bone that had not been
108 appreciated by conventional radiography. In the case that had subsequent MRI, additional
109 soft tissue injury in the form of distal sesamoidean impar and lateral collateral ligament
110 desmitis was also observed. Evaluation of horses presenting with lameness localised to the
111 foot, or more specifically the DIPJ using diagnostic local anaesthesia should include both
112 D65°PrPDiO or D65°PrPIDiO and D65°Pr45°L-PDiMO or D65°Pr45°L-PIDiMO
113 radiographic projections, and when fragmentation of the palmar articular margin is suspected,
114 include complimentary CT and/or MRI if available with an understanding that concurrent soft
115 tissue injury may be present.

116 Histologic examination of one case was consistent with an underlying pathogenesis
117 involving OCD, yet the signalment and imaging findings from two other cases suggested a
118 traumatic aetiopathogenesis. Whether these lesions are primarily traumatic in origin or related
119 to OCD, with or without a concurrent traumatic component, is unknown. The signalment of
120 these cases does not favour either aetiology. It would be unlikely a lesion of developmental
121 origin in this location would remain clinically quiescent for twenty years (case four), yet the
122 younger age of cases one and two with lameness noted at the onset of training coupled with
123 supporting histopathology suggest OCD. Also, the acute onset of lameness in case three with
124 the extensive nature of the fragmentation (plantar articular margin of the distal phalanx, entire
125 lateral margin of the distal sesamoid bone) suggest a traumatic aetiology. Traumatic OCF
126 could be secondary to avulsion or compressive load, as would theoretically occur when a
127 horse kicks out a wall or solid structure. This could potentially result in impact of the plantar
128 rim of the distal phalanx against the distal articular surface of the middle phalanx. There is
129 insufficient evidence in the existing literature coupled with the cases presented here to

130 support a singular aetiology, and further investigation with additional histopathology is
131 required.

132 Of the three horses for which surgical treatment was attempted, lesions were not
133 accessible arthroscopically in two. Arthroscopic evaluation of the palmar pouch of the DIPJ
134 is recognised to be restricted to the proximal rim of the distal sesamoid bone and condyles of
135 the middle phalanx, and the adjacent soft tissue structures (McIlwraith *et al.* 2015). Although
136 not reported in the literature, OCF of the palmar/plantar aspect of the distal phalanx has been
137 recognised previously (A. Nixon, personal communication 2017) and removal via a palmar
138 arthroscopic approach has similarly been attempted with little success. It is suspected that the
139 successful placement of the arthroscopic canula in a two-year-old Thoroughbred was due to
140 concurrent unidentified soft tissue damage such as capsular disruption allowing for greater
141 distraction of the distal sesamoid bone and middle phalanx (Figure 4), although MRI was not
142 performed to confirm soft tissue involvement. In a different case, a collateral sesamoidean
143 ligament desmotomy facilitated placing the arthroscope and instrument between the middle
144 phalanx and distal sesamoid bone, but debridement of the lesion remained impossible. One
145 author (M.R.W.S.) has additionally used a solar approach with a trephine to successfully
146 access a lesion on the distal phalanx adjacent to the abaxial margin of the deep digital flexor
147 tendon, but the open navicular bursa and DIPJ deterred the author from using this approach
148 again. Case one underwent a biaxial palmar digital neurectomy of the affected limb, and
149 while this surgical option may provide a paddock sound animal it would preclude the horse
150 from competition and may result in complications including recurrence of lameness, neuroma
151 formation, and rarely rupture of the deep digital flexor tendon and laminitis (Jackman *et al.*
152 1993; Matthews *et al.* 2003).

153 Although apparently uncommon, OCF of the palmaro- or plantaro-proximal aspect of
154 the distal phalanx should be considered in horses with lameness localised to the foot or DIPJ.
155 In the cases presented here, lesions were best identified on dorsal 65° proximal
156 palmaro/plantarodistal lateral or medial oblique radiographic projections. CT was superior to
157 conventional radiography in providing details of lesion location and extent of fragmentation,
158 and MRI provided information about concurrent soft tissue injury. A definitive cause could
159 not be determined as signalment, patient presentation and histopathological findings
160 suggested both a primary traumatic aetiology and OCD may be possible. Although one horse
161 had a successful racing career following arthroscopic debridement, given the surgical
162 inaccessibility in most cases and osteoarthritic change within the DIPJ identified on imaging,
163 we conclude the prognosis for future soundness in these cases is poor.

164

165 **Authors' declarations of interest**

166 No conflicts of interest have been declared.

167 **Ethical animal research**

168 Owner consent was obtained for all aspects of case management; institutional animal ethics
169 approval was not required.

170 **Source of funding**

171 No funding was received.

172 **Antimicrobial Stewardship Policy**

173 Authors declare no off label antimicrobial use.

174 **Acknowledgements**

175 The authors would like to thank Kane Wilson for his assistance with image acquisition and
176 processing.

177 **Authorship**

178 All authors contributed to case diagnosis, treatment and management. The report was drafted
179 by K. Lloyd and revised by the other authors. The final document was approved by all
180 authors prior to submission.

181

182 **Manufacturer' addresses**

183 ¹Aspen Australia, St Leonards, New South Wales, Australia.

184 ²Randlab Australia Pty. Ltd, Chipping Norton, New South Wales, Australia.

185

186 **Tables**

187

Case	Signalment	Use	History	Clinical Findings
1	5-year-old Warmblood gelding	Show-jumping	RF lameness of 6 months duration resolved with intra-articular local anaesthesia of the DIPJ by referring veterinarian; medicating DIPJ with TA ([Kenacort ¹] 10mg i.a) improved but did not resolve lameness prior to referral.	Moderate RF lameness (AAEP grade 3/5), moderate DIPJ effusion, positive distal limb flexion. Palmar digital nerve combined with dorsal branch perineural anaesthesia eliminated lameness.
2	3-year-old Warmblood gelding	Unbroken	LF lameness of several months duration observed while being broken to saddle	Moderate LF lameness (AAEP grade 2/5), moderate DIPJ effusion, positive distal limb flexion. Palmar digital nerve combined with dorsal branch perineural anaesthesia eliminated lameness.
3	2-year-old Thoroughbred colt	Racing	Acute onset of LH lameness during training, referred for nuclear scintigraphy	Moderate LH lameness (AAEP grade 3/5), moderate effusion of DIPJ. Horse was referred for nuclear scintigraphy.
4	20-year-old Arab X Welsh mare	Pleasure	Chronic RH lameness of more than 6 months duration	Moderate RH lameness (AAEP grade 3/5). Negative response to plantar digital analgesia, yet intra-articular DIPJ analgesia provided good improvement.

188

189 **Table 1:** Signalment and details of four horses presenting for unilateral limb lameness of various durations with clinical findings [RF = right
190 forelimb; DIPJ = distal interphalangeal joint; TA = triamcinolone acetate; AAEP = American Association of Equine Practitioners, [Stashak
191 2002]; LF = left forelimb; LH = left hindlimb, RH = right hindlimb]

Case	Radiography	Computed Tomography	Further Diagnostics	Interpretation and Diagnosis
1	OCF identified at the palmarolateral aspect of the articular surface of the distal phalanx, adjacent to the axial border of the lateral palmar process (Figure 1).	OCF identified with surrounding hyperattenuation in the distal phalanx (w: 6 mm, l: 5 mm, h: 10 mm). A second OCF with mild displacement associated with the lateral angle of the distal sesamoid bone was also observed (w: 7 mm, l: 3 mm, h: 4 mm). Mild periarticular osteophyte formation at the dorsoproximolateral margin and enthesophyte formation at the lateral extremity of the distal sesamoid bone.	Nil.	Moderate OCF of the palmarolateral distal phalanx with associated OA of the DIPJ.
2	OCF palmarolateral aspect of the articular surface of the distal phalanx, axial to the lateral palmar process. Subchondral	Large, irregularly margined, shallow bone defect (w: 13 mm, l: 6 mm) at the palmarolateral aspect of the distal phalanx, with a	MRI: OCF palmarolateral aspect of the articular surface of the distal phalanx axial to the lateral palmar process, with a hyperintense line	Moderate-marked OCF of the palmarolateral distal phalanx, with associated OA of the DIPJ.

	<p>ovoid lucency with increased radiopacity distal to the fragment.</p>	<p>surrounding area of moderate hyperattenuation (Figure 2). Within the defect extending palmarly, there were multiple areas of OCF. Fragments had smooth margins and were minimally displaced.</p>	<p>extending distally towards the solar surface on T1W (Figure 3). The adjacent distal phalanx T2W and T1W hypointense, with ill-defined STIR hyperintensities. Lateral collateral and distal sesamoidean impar ligament T2W and STIR hyperintensities, with marked insertional enthesiophytes at dorsal border of middle phalanx. Moderate DIPJ distension with proliferative synovium.</p>	<p>Concurrent lateral collateral sesamoidean desmopathy and insertional enthesophyte formation presumed to be secondary to chronic altered weight bearing through the podotrochlear apparatus.</p>
3	<p>OCF plantarolateral aspect of the articular surface of the distal phalanx, with adjacent fragmentation lateral margin of the distal sesamoid bone. Irregular new bone formation on the dorsal surface of the middle phalanx in the region of the capsular reflection of the DIPJ.</p>	<p>OCF plantarolateral aspect of the articular surface of the distal phalanx and fragmentation entire lateral margin of the distal sesamoid bone (w: 14 mm, h: 6 mm, l: 4 mm) with displaced fragments within the proximal plantar pouch of the DIPJ.</p>	<p>Nuclear Scintigraphy [performed as initial diagnostic]: IRU DIPJ, centred on the lateral body of the distal phalanx and adjacent distal sesamoid bone, with IRU on the dorsal surface of the middle phalanx.</p>	<p>Moderate OCF of the plantarolateral aspect of the distal phalanx and lateral margin of the distal sesamoid bone, with associated OA of the DIPJ.</p>

4	No OCF identified radiographically. Moderate insertional enthesophytes present at the dorsal aspect of the middle phalanx in the region of the capsular reflection of the DIPJ.	OCF of the plantarolateral aspect of the articular surface of the distal phalanx (w: 15 mm, h: 7 mm, l: 4 mm), with moderate enthesophytes at the capsular insertion as seen on radiographs. Distension of the DIPJ and concurrent capsular thickening.	Nil	Moderate OCF of the plantarolateral aspect of the distal phalanx, with associated OA of the DIPJ.
---	---	---	-----	---

192

193 **Table 2:** Diagnostic imaging findings, interpretation and working diagnosis for four horses presenting with unilateral limb lameness localised to

Case	Surgical (Arthroscopic) and Adjunct Treatment	Outcome
1	Routine palmar arthroscopic approach to DIPJ under GA. Moderate amount of proliferative synovium observed, articular surface of the distal sesamoid bone and middle phalanx had no abnormalities. Only the most lateral palmar border of the distal phalanx visualised with joint manipulation (including use of intra-articular elevator), which did not allow access to the fragmentation. Lesion deemed surgically inaccessible via this approach. Remedial farriery with an aluminium shoe with 12 degrees of heel elevation was fitted in attempt to shift the break-over cranially. A partial improvement in lameness occurred over the following weeks and the DIPJ was medicated with sodium hyaluronate ([Equinate ²] 20mg i.a).	Biaxial palmar digital neurectomy performed following ongoing lameness and client dissatisfaction. Reported to be pasture sound approximately 12 months later.
2	No attempt at treatment performed.	Humanely euthanised.

194 the foot with perineural analgesia [OCF = osteochondral fragmentation; OA = Osteoarthritis; DIPJ = distal interphalangeal joint; MRI =

195 magnetic resonance imaging; IRU = increased radiopharmaceutical uptake; w = width; l = length; h = height; mm = millimetres]

3	<p>Routine palmar arthroscopic approach to DIPJ under GA. Fragmentation of the plantarolateral distal sesamoid bone involving the adjacent collateral sesamoidean ligament successfully removed, osseous and ligamentous lesions debrided. Loose fragmentation within the proximal plantar pouch removed. Arthroscope able to be inserted between the distal sesamoid bone and plantar middle phalanx to view the plantar articular margin of the distal phalanx. Principal fragment substantially attached to the distal sesamoidean impar ligament, left <i>in situ</i>, with only detached adjacent cartilage removed. Horse recovered in a distal limb cast uneventfully.</p>	<p>The horse successfully returned to racing, completed 23 races for two wins and nine places post-operatively.</p>
4	<p>Routine palmar arthroscopic approach to DIPJ under GA. Haemosiderin staining of the synovium and tearing of the joint capsule observed, debrided. Increased mobility between the distal sesamoid bone and middle phalanx, but insufficient to pass the arthroscope cannula between the two surfaces to allow access to the plantar articular margin of distal phalanx and area of fragmentation. Desmotomy of the collateral sesamoidean ligament of the distal sesamoid bone performed arthroscopically, also failed to create sufficient manouverability to grant access. Lesion deemed surgically inaccessible via this approach and the horse was recovered in a distal limb cast uneventfully.</p>	<p>Four months following surgery the horse had improved to AAEP grade 1/5 RH lame, attempted to return to work. Severity of lameness increased and the horse developed progressive OA of the DIPJ, resulting in euthanasia 12 months post-operatively.</p>

196

197 **Table 3:** Surgical descriptions, adjunctive treatment and case outcome for four horses presenting with unilateral limb lameness localised to the
 198 distal limb and diagnosed with osteochondral fragmentation of the palmar/plantarolateral aspect of the distal phalanx [DIPJ = distal
 199 interphalangeal joint; GA = general anaesthesia; AAEP = American Association Equine Practitioners, [Stashak 2002]; RH = right hindlimb; OA
 200 = osteoarthritis]

201 **Figures**

202 **Figure 1:** Dorsal 65° proximal-palmarodistal oblique (LEFT) and dorsal 65° proximal 45°
203 lateral-palmarodistal medial oblique (RIGHT) radiographic projections of a 5-year-old
204 Warmblood gelding (case one) with right forelimb lameness localised to the foot. An
205 osteochondral fragment at the palmarolateral aspect of the articular surface of the distal
206 phalanx, axial to the lateral palmar process of the distal phalanx is present (arrows).

207 **Figure 2:** 3-D volume reconstructions of the distal phalanx (and distal sesamoid bone) of
208 LEFT: a 5-year-old Warmblood gelding (case one) with a discrete osteochondral fragment at
209 the palmarolateral aspect of the articular surface of the distal phalanx, axial to the lateral
210 palmar process of the right forelimb and RIGHT: a 3-year-old Warmblood gelding (case two)
211 with a large area of osteochondral fragmentation at the palmarolateral aspect of the articular
212 surface of the distal phalanx, axial to the lateral palmar process of the left forelimb. Lateral is
213 to the left.

214 **Figure 3:** Transverse (LEFT), dorsal (MIDDLE) and sagittal (RIGHT) T1W MRI images
215 from a 3-year-old Warmblood gelding (case two) with osteochondral fragmentation at the
216 palmarolateral aspect of the articular surface of the distal phalanx. Note the hypointense bone
217 surrounding the defect (LEFT) and hyperintense line extending from the defect distally
218 towards the solar margin (RIGHT, arrow). Lateral (or dorsal) is to the left.

219 **Figure 4:** Arthroscopic image from a standard portal in the plantar pouch of the distal
220 interphalangeal joint, advanced distally between the distal sesamoid bone and middle phalanx
221 from a 2-year-old Thoroughbred colt (case three) that presented with an acute onset of left
222 hindlimb lameness subsequently diagnosed with osteochondral fragmentation of the
223 plantarolateral aspect of the distal phalanx [P2, middle phalanx; N, distal sesamoid bone].

224 **Figure 5:** Articular surface of the distal phalanx from a 3-year-old Warmblood gelding (case
225 two) with osteochondral fragmentation at the palmarolateral aspect of the distal phalanx
226 displaying a vertical cleft through the articular cartilage with degeneration and fragmentation
227 in the deep zone cartilage (arrows) undermining the more superficial tissue. HE, Bar =
228 300µm.

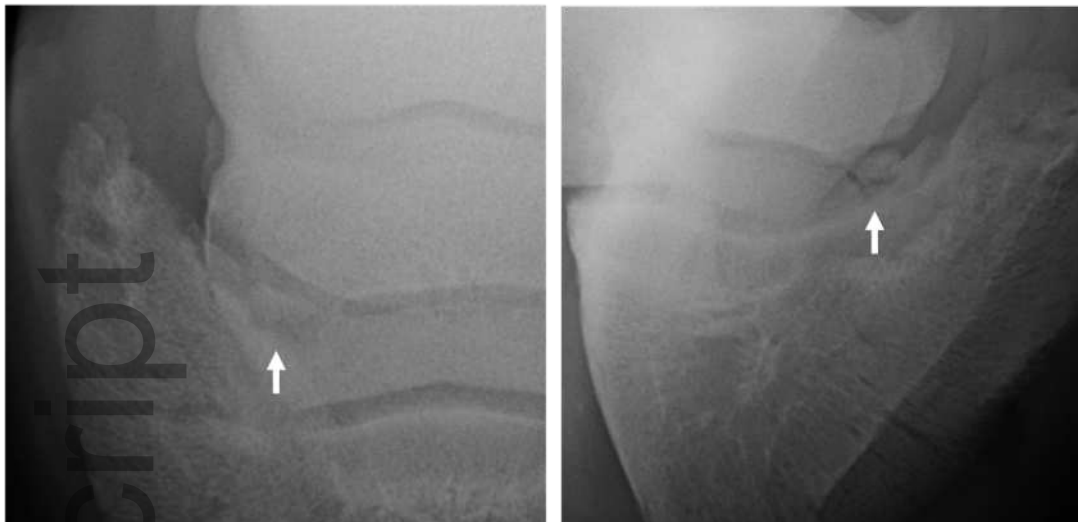
229
230 **Supplementary Items**

231 **Supplementary Item 1:** Imaging modalities, regions of interest, techniques and machine
232 details used in the assessment of four horses presenting with unilateral limb lameness [RF =
233 right fore; LF = left fore; LH = left hind; RH = right hind; 3D = three-dimensional; HL =
234 hindlimb].

235

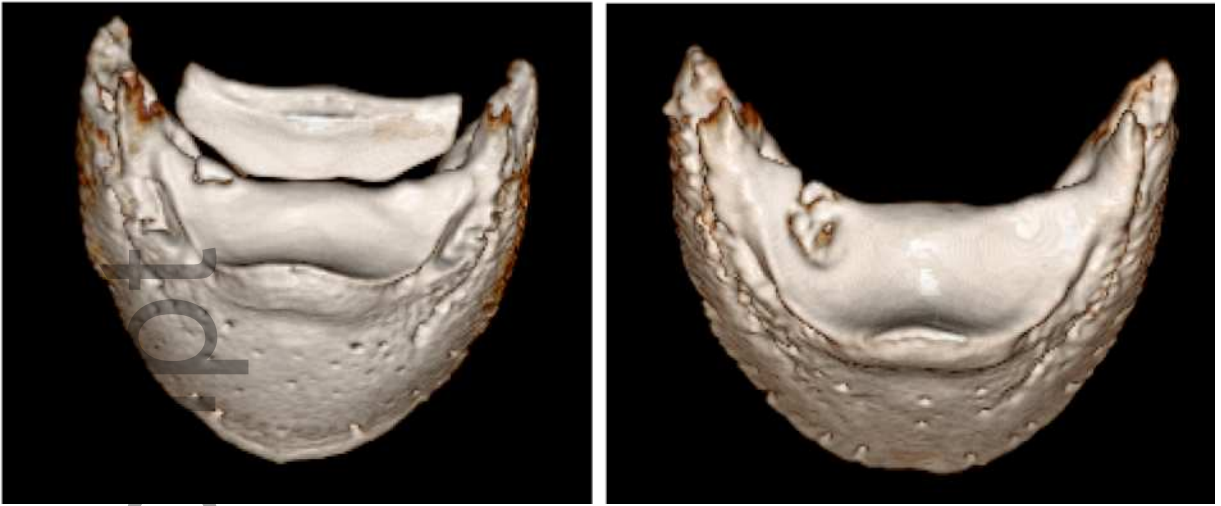
236 **References**

- 237 Graham, R.J.T.Y., Rosanowski, S.M. and McIlwraith, C.W. (2020) A 10-year study of
238 arthroscopic surgery in racing Thoroughbreds and Quarterhorses with osteochondral
239 fragmentation of the carpus. *Equine Vet. J.* **52**, 225-231.
- 240 Jackman, B.R., Baxter, G.M., Doran, R.E., Allen, D. and Parks, A.H. (1993) Palmar digital
241 neurectomy in horses 57 cases (1984–1990). *Vet. Surg.* **22**, 285-288.
- 242 Kannegieter, N. J. and Burbidge, H. M. (1990) Correlation between radiographic and
243 arthroscopic findings in the equine carpus. *Aust. Vet. J.* **4**, 132-133.
- 244 Matthews, S., Dart, A.J. and Dowling, B.A. (2003) Palmar digital neurectomy in 24 horses
245 using the guillotine technique. *Aust. Vet. J.* **81**, 402-405.
- 246 McIlwraith, C.W., Frisbie, D.D. and Kawcak, C.E. (2012) The horse as a model of naturally
247 occurring osteoarthritis. *Bone & Joint Research* **1**, 297-309.
- 248 McIlwraith, C.W., Nixon, A.J. and Wright, I.M. (2015) Arthroscopic surgery of the distal and
249 proximal interphalangeal joints. In *Diagnostic and Surgical Arthroscopy in the Horse*,
250 4th edn. Eds: C.W. McIlwraith, A.J. Nixon and I.M. Wright. Elsevier Limited, China.
251 pp 316-329.
- 252 Stashak, T.S. (2002) Diagnosis of lameness. In: *Adams' Lameness in Horses*. Ed: T.S.
253 Stashak. Lea & Febiger, Philadelphia. p122.
- 254 Stock, K.E, Hamann, H. and Distl, O. (2005) Prevalence of osseous fragments in distal and
255 proximal interphalangeal, metacarpo- and metatarsophalangeal, and tarsocrural joints of
256 Hanoverian Warmblood horses. *J. Vet. Med. Assoc. Phys. Path. Clin. Med.* **52**, 388-
257 394.
- 258 Tidswell, H.K., Innes, J.F., Avery, N.C., Clegg, P.D., Barr, A.R.S., Vaughan-Thomas, A.,
259 Wakley, G. and Tarlton, J.F. (2008) High-intensity exercise induces structural,
260 compositional and metabolic changes in cuboidal bones—findings from an equine
261 athlete model. *Bone.* **43**, 724-733
- 262 Vanderperren, K., Martens, A.M., Declercq, J., Duchateau, L. and Saunders, J.H. (2009)
263 Comparison of ultrasonography versus radiography for the diagnosis of dorsal
264 fragmentation of the metacarpophalangeal or metatarsophalangeal joint in horses. *J.*
265 *Am. Vet. Med. Assoc.* **1**, 70-75
- 266 Van Weeren, P.R. (2012) Osteochondrosis. In: *Equine Surgery*, 4th edn. Eds: J.A. Auer and
267 J.A. Stick. Saunders Elsevier, St. Louis, Missouri. pp 1239-1255.



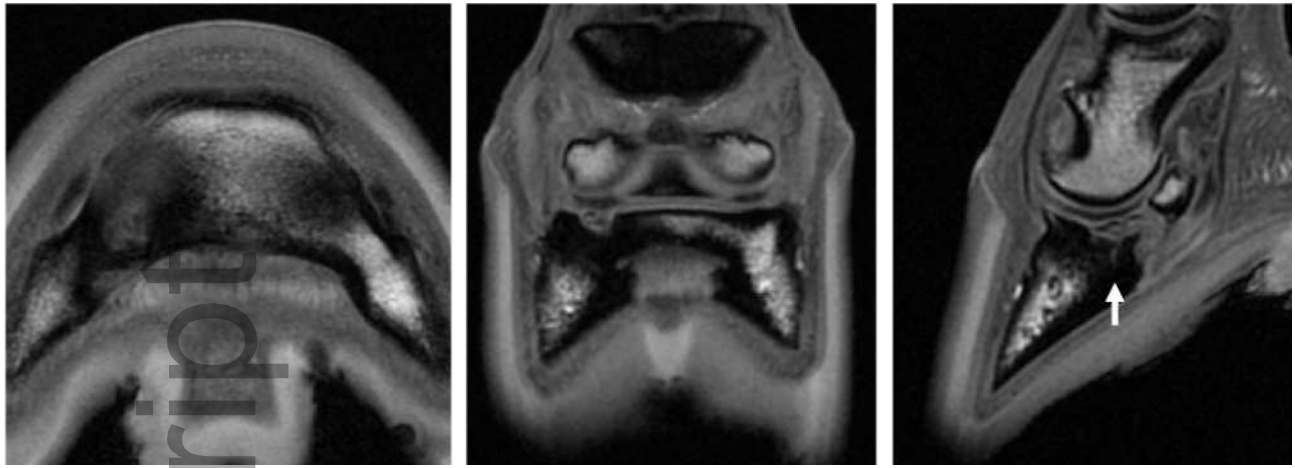
eve_13456_f1.tiff

Author Manuscript



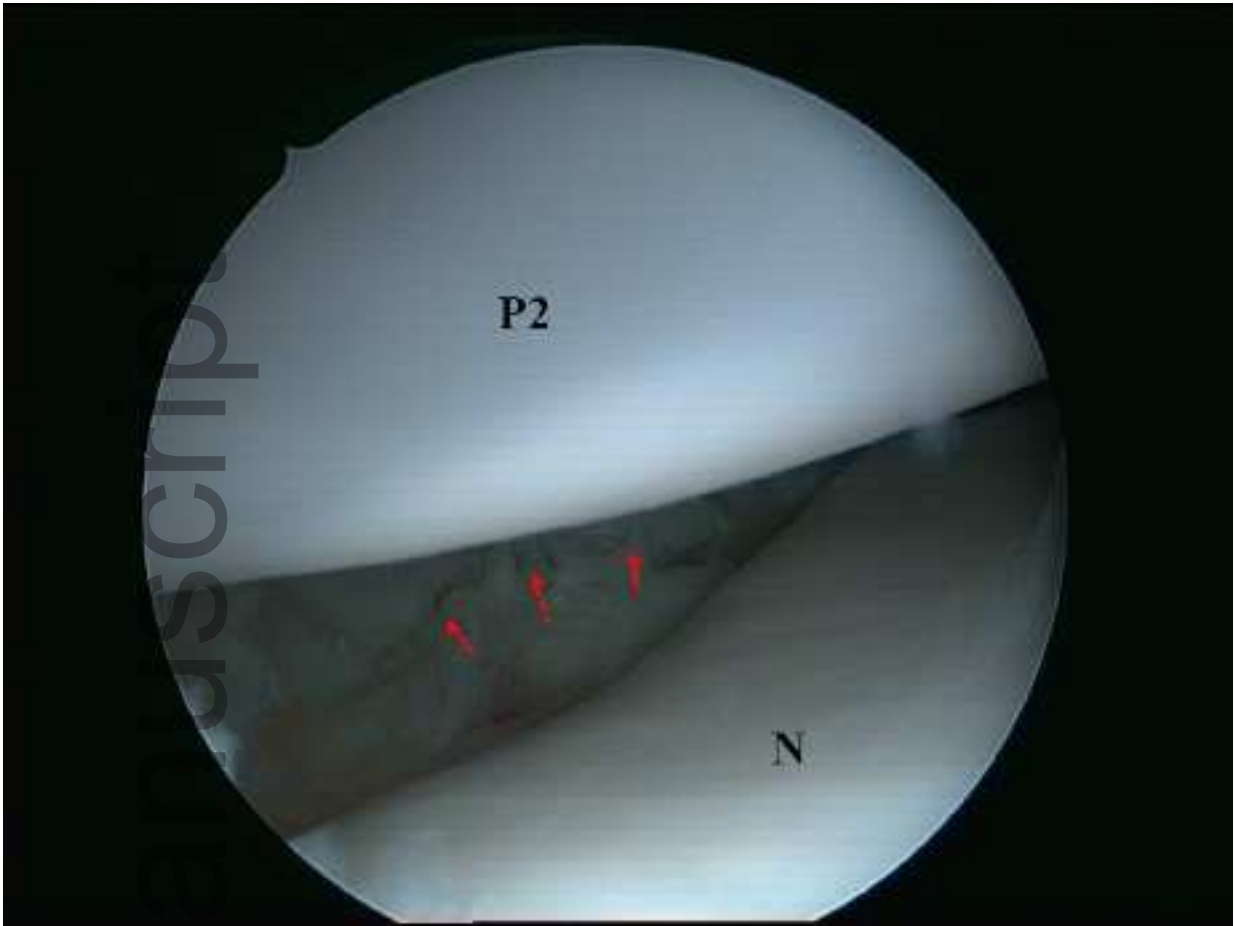
eve_13456_f2.tiff

Author Manuscript



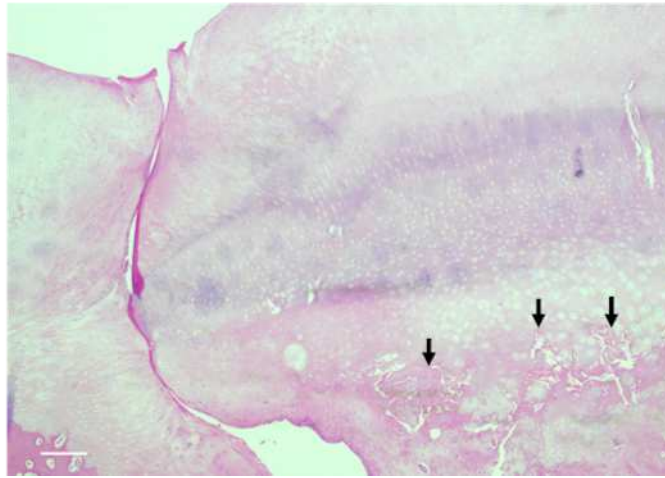
eve_13456_f3.tiff

Author Manuscript



eve_13456_f4.tiff

Author Manuscript



eve_13456_f5.tiff