



Minerva Access is the Institutional Repository of The University of Melbourne

Author/s:

Hayes, JA; Temple-Smith, MJ

Title:

What is the anatomical basis of labiaplasty? A review of normative datasets for female genital anatomy

Date:

2021-06-01

Citation:

Hayes, J. A. & Temple-Smith, M. J. (2021). What is the anatomical basis of labiaplasty? A review of normative datasets for female genital anatomy. *Australian and New Zealand Journal of Obstetrics and Gynaecology*, 61 (3), pp.331-338. <https://doi.org/10.1111/ajo.13298>.

Persistent Link:

<https://hdl.handle.net/11343/276797>

What is the anatomical basis of labiaplasty? A review of normative datasets for female genital anatomy

Jennifer A. HAYES

Email: j.hayes@unimelb.edu.au

ORCID: 0000-0003-4281-9607

PhD Candidate, Department of General Practice, University of Melbourne, Melbourne, Australia

Associate Professor of Topographic Anatomy, Department of Anatomy and Neuroscience, University of Melbourne, Melbourne, Australia

Meredith J. TEMPLE-SMITH

Email: m.temple-smith@unimelb.edu.au

ORCID: 0000-0003-1296-9591

Professor of General Practice, Department of General Practice, University of Melbourne, Melbourne, Australia

Corresponding author: Jennifer A. Hayes

Running title: Anatomical basis of labiaplasty

Acknowledgements: Jennifer Hayes is the recipient of an Australian Government Research Training Program Stipend Scholarship.

Conflict of interest statement: The authors have no conflicts of interest to declare.

This is the author manuscript accepted for publication and has undergone full peer review but has not been through the copyediting, typesetting, pagination and proofreading process, which may lead to differences between this version and the [Version of Record](#). Please cite this article as [doi: 10.1111/AJO.13298](https://doi.org/10.1111/AJO.13298)

This article is protected by copyright. All rights reserved

A/PROF. JENNIFER ANNE HAYES (Orcid ID : 0000-0003-4281-9607)

Article type : Systematic Review

What is the anatomical basis of labiaplasty? A review of normative datasets for female genital anatomy

Running title: Anatomical basis of labiaplasty

Key words: anatomy; genitalia, female; reference values; surgery, plastic; review

Manuscript word count: 3250

Abstract word count: 199

Figure count: 1

Table count: 1

Abstract

Background: Despite increasing numbers of labiaplasties being performed, there is little quantitative information on normal labial diversity to guide medical education, patient education and surgical treatment.

This article is protected by copyright. All rights reserved

Aim: This scoping review will determine what is known in the published literature about the anatomical basis of normal for labia and female genital cosmetic surgery (FGCS).

Materials and methods: The scoping review identified 10 population-based studies that recorded labial dimensions by searching 3 electronic databases utilising a PRISMA search strategy. Strict inclusion and exclusion criteria were applied and then reference lists were scrutinised until no further articles that met the criteria were located.

Results: These studies showed significant variation in labial length (range 5–100 mm) and width (range 1–60 mm). Labia minora were wider in pre-menopausal women than in post-menopausal women, protruding labia minora were more common than not, and asymmetry between right and left labia was common. Variation in recruitment, inclusion and exclusion criteria, and measurement did not allow for summation of the data sets.

Conclusion: This information could usefully be added to medical textbooks and teaching to ensure that medical graduates are sufficiently informed about normal variation in female genital anatomy to assess and advise women seeking FGCS.

Introduction

Female genital cosmetic surgery (FGCS) is an umbrella term encompassing a diverse range of surgical procedures that change the structure and appearance of female genitals in the absence of pathology. These surgeries are performed on women and girls with a normal range of genital variation including post-childbearing and age-related changes.¹ Professional medical organisations^{1,2,3} are united in their concerns about FGCS and the lack of an evidence base for the long-term outcomes of these surgeries, including the oft-promised additional benefit of sexual function enhancement and partner satisfaction. This is, of course, the opposite of female genital mutilation, which is performed to diminish sexual function. In neither case is there a robust dataset to validate the claim.⁴

The business practices surrounding FGCS have raised concerns about conflict of interest and lack of professionalism in direct-to-patient marketing on the internet.⁵ Together with censored vulvar images in print and online pornography, these have contributed to the skewing of social perception of what constitutes normal towards a “slit like genital hiatus with the labia minora and labia majora coming together in the midline”.^{6(p.1083)} Skewing the perception of normal coincides with the increasing trend among women for Brazilian waxing and other forms of pubic hair depilation. This provides unobstructed views of variable normal

genitalia, creating an ever-increasing subpopulation of women wanting to change their genital anatomy in the belief that it will enhance their attractiveness, sexual desire and sexual function.⁷ As Moynihan noted, it is “the ever-narrowing definitions of normal which help turn the complaints of the healthy into the conditions of the sick”.^{8(p.47)}

The most popular of the female genital cosmetic surgeries is labiaplasty, which involves cutting back the labia minora so that they sit flush with, or are entirely hidden by, the labia majora.⁹ The labia minora are cutaneous folds without hair or fat that lie internal to the labia majora and form the boundaries of the vestibule of the vagina. The anterior ends of the labia minora split to form the (dorsal) prepuce and (ventral) frenulum of the clitoris, while posteriorly they are united by a small transverse skin fold, the frenulum of the labia. Labia minora are rich in elastic fibres and small blood vessels that are arranged to form erectile tissue similar to that in the penis. Arterial supply is abundant via the internal pudendal artery. Venous return is into the vaginal venous plexus and internal pudendal vein. Innervation is via the internal pudendal nerve (S2–4) posteriorly and the ilio-inguinal (T12, L1) and genito-femoral (L1–2) nerves anteriorly. The labia minora can be short or long, smooth or wrinkled, light or dark, and one side may be longer or wider, which is similar to the asymmetry of many body parts. The labia minora take many years to develop fully and change significantly over a woman’s lifetime.¹⁰ The main functions of the labia minora are to protect the vaginal and urethral openings, direct the flow of urine, and contribute sensory and erectile tissue for sexual arousal and intercourse, functions that require the labia minora to be 1 cm or more in size.¹¹

Descriptions of female genital anatomy are sparse in medical textbooks,¹² and detailed morphological study of the vulva, including normal variation, is not included in medical training.¹³ The resulting knowledge gap in medical graduates may underlie the lack of confidence reported in a survey of 433 Australian general practitioners that found that more than half had been consulted by women and girls seeking FGCS and that 75% thought they had inadequate relevant knowledge.¹⁴ A small qualitative study of 21 Australian university students found that young women had little knowledge of normal genital anatomy and might be reassured and dissuaded from undergoing unnecessary surgery by a confident and knowledgeable general practitioner.¹⁵ However, an audit of 48 referral letters in a National Health Service gynaecology clinic in the United Kingdom showed that only 77% of the referrers reported examining the patient, a third of the referrers described the labia as normal but still requested surgery for the patient and 25% of referrals contained pejorative language such as “leathery” or “pendulous”.^{13(p.99)} In each case the general practitioner, if

inexperienced in dealing with such intimate concerns, might have been relying on the specialist to persuade the patient that she was normal, but the lack of immediate reassurance combined with specialist referral could be interpreted by the patient as proof of the need for surgery.¹⁶

In summary, there appears to be a pervasive lack of general knowledge about the normal anatomy and function of female genitalia that may contribute to the notion that any variation from an idealised appearance is abnormal and requires surgical repair to achieve perfection and enhance function. To explore this in more detail, this study aimed to determine what is known in the published literature about the anatomical basis of normal for labia and FGCS.

Methods (Figure 1)

A search of existing literature with no date limit was conducted on 13 June 2020. Medical Subject Headings (MeSH) and the key terms (labiaplasty OR labioplasty) AND (anatom*) AND (normal* OR variation) were used to search Scopus, PubMed and PsychInfo databases. A total of 137 papers were identified, after which papers were excluded if they were:

- duplicated in databases (n=11)
- non-English language (n=6)
- referring to labial structures other than vulva (n=17)
- relating to development, pathology or genital function without structure (n=21)
- reporting non-surgical therapies or surgery related to gender re-assignment or genital cutting (n=7).

Of the remaining 75 papers, only seven defined normal labial dimensions by measurement. To these were added three more papers identified from hand-searching reference lists.

Results

In contrast to public discourse, there had, until fairly recently, been only limited discussion in the medical literature about what constitutes normal anatomy for female genitalia. Much of the attention had instead been devoted to the underlying social and psychological reasons for women contemplating and undergoing labiaplasty, and to the surgical planning and technique (most of the papers dealing with female genital anatomy are cosmetic surgery orientated and start with the notion of *abnormal*).¹⁷ Although the first description of labiaplasty in the literature was in 1984,¹⁸ it was not until 2005 that the first study regarding genital dimensions

in healthy women was published. A search of the literature identified 10 papers (see Table 1) measuring normal genitalia in pre-pubertal and adolescent girls, and pre- and post-menopausal women from eight different countries and varied ethnicities, all published from 2005 to 2020.

In the first observational cross-sectional study, which was published in 2005, Lloyd et al. recruited 50 pre-menopausal women from gynaecology operating lists at a central London teaching hospital.¹⁹ All were having routine procedures such as hysteroscopy or diagnostic laparoscopy and had not expressed concern about their vulval appearance. The researchers measured a variety of parameters, including labial length, labial width and rugosity (ridging or wrinkling) of labial skin. They found a wide range for each measurement (up to 5 cm for labial width) and found no statistically significant association with age, parity, ethnicity, hormone use or sexual history.

Lloyd et al.'s¹⁹ study is widely regarded as the seminal reference and seven papers have replicated this range of variation in Thai,²⁰ Austrian,²¹ American,²² Swiss,²³ Danish,²⁴ Israeli,²⁵ and Turkish²⁶ samples of adolescent girls and pre- and post-menopausal women. Kreklau et al. published the largest of these studies, measuring the vulval dimensions of a group of 657 pre- and post-menopausal women covering seven decades of ages.²³

Very little is known about the development of female external genitalia during puberty.⁷ The classification system of physical development in children and adolescents, Tanner stages 1 to 5, comes from a large epidemiological study by Marshall and Tanner²⁷ that recorded pubic hair and testicular development in boys, and pubic hair and breast development in girls, so no studies exist for female genitalia. Two of the 10 papers identified in this review sought to establish genital standards in girls through external genital measurements in pre-pubertal samples. Akbiyik et al. examined 205 girls aged 1 month to 10 years old and developed equations to estimate the expected external genital dimensions according to age, weight and height.²⁸ Chalmers et al. examined and measured the genitalia of 56 Tanner stage 1 girls in several age groups and generated regression models to show significant linear growth with age.²⁹

The findings of the papers in this review are striking and highlight the variety in normal vulval appearance. All studies found a wide disparity in labial length (range 5–100 mm) and labial width (range 1–60 mm). Kreklau et al. created seven subgroups within their sample, one for each decade between 25 and 84 years, and found at least a five-fold variation in labia minora width within any of the groups.²³ Labia minora were wider in pre-menopausal women compared with post-menopausal women.²⁶ It was more common to have protruding

labia minora than not,^{20,21,24} and asymmetry between right and left labia was common.^{22,24} Although these data demonstrate the wide variability of female genital anatomy, they bring us no closer to an established international normal range because there are significant variations in inclusion and exclusion criteria and methodologies that preclude direct comparison between the measurements in each study.

All of the studies recruited patients attending public gynaecology clinics, either for annual examination or for unrelated surgery. Within the cohorts there were different approaches to racial and ethnic diversity. In Lloyd et al's original sample of 50, "the majority of women were white (n=37) with five Asian women, six black women, one Latin American woman and one woman who was mixed race".^{19(p.644)} Brodie et al. also measured a racially and ethnically diverse cohort where "most were non-Hispanic ethnicity (n=32/44) and were Caucasian race (n=38/44)".^{22(p.27)} Three of the reviewed studies^{20,23,24} consciously avoided racial and ethnic diversity to create a normative dataset specific to that cohort: "we chose to include white women only, to create a homogeneous group of just one ethnicity".^{23(p.1657)} In the other five studies^{21,25,26,28,29} cohort composition was not recorded.

In terms of defining a sample of women with normal labia to measure, only one study²⁰ used the validated Genital Appearance Satisfaction scale to include only women who were rated most satisfied. The Genital Appearance Satisfaction scale was originally developed to measure the attitudes towards genital appearance of normal women in general society, but it has subsequently been validated for labiaplasty patient samples as well.³⁰ The remaining studies simply presumed participants were satisfied with their vulvae because they were not actively seeking FGCS; "none of the women in our study had expressed any personal difficulty or sought cosmetic surgical alternation".^{19(p.645)}

Two of the studies excluded women using hormone replacement therapy,^{23,26} one study excluded women using oral contraceptives and medicated intrauterine devices²⁵ and one study excluded pregnant women²³. Two of the studies that did not apply these exclusion criteria instead analysed the potential effects of use of systemic hormone therapy on genital dimension and found that women taking oestrogen-containing medications did not show any variation compared with the rest of the pre-menopausal women.^{19,22} Another study²⁶ compared pre- and post-menopausal women and found that the mean width of labia minora was significantly higher in the pre-menopausal group (mean \pm standard deviation: 17.9 \pm 4.1 mm vs 15.4 \pm 4.7 mm), which is consistent with reduction in collagen levels and skin thickness associated with ageing and oestrogen withdrawal.³¹

In the original 2005 paper, Lloyd et al.¹⁹ used a disposable paper tape for all measurements other than vaginal length, for which a vaginal swab was used. There is no reference to traction being applied (or not) before measurement. All measurements were taken by one of two gynaecology registrars to minimise inter-observer variability and both registrars were present during examinations. There is significant variation in measurement technique between Lloyd et al. and the subsequent studies. Four of the 10 studies specified that no traction was applied when measuring the flexible tissue (labia folded to the side without stretching),^{21,23,24,25} two studies specified minimal traction,^{20,29} one study measured with and without stretching (on a pre-pubertal sample)²² and three studies made no reference to applying traction.^{19,26,28} It is reasonable to assume that traction was only applied under general anaesthetic. Measuring tools were measuring tape or ruler (eight studies) and digital callipers (two studies). Two distinct ways of measuring labia minora width were used: from lateral edge to vaginal introitus (internal surface) or from lateral edge to interlabial sulcus (external surface). The number of measurers varied between one and 12, although three studies did not specify, and there was wide variation in measures taken to reduce observer variability from stringent to none described.

All of the patients were measured supine, mostly lithotomy or frog-leg position. Those attending outpatient clinics were not anaesthetised for measurement, unlike those undergoing unrelated surgery. This potentially makes a difference to the recorded measurements because of the vascularity of the labia minora. It is reasonable to assume that general anaesthetic agents would produce vasodilation and engorgement of the vascular structures while the anxiety provoked by measuring an unanaesthetised patient in a clinical setting might induce sympathetic-mediated vasoconstriction.

Discussion

The international FGCS market is booming due to the promotion of a specific notion of normal, the flat Barbie doll vulva with no protuberances beyond the labia majora.³² This appearance is not consistent with the wide range of labial morphology and measurements in the studies analysed. Despite variation in recruitment, inclusion and exclusion criteria, and measurement, these studies showed significant variation in labial length and labial width. Labia minora were wider in pre-menopausal women compared with post-menopausal women,²⁶ it was more common to have protruding labia minora than not^{20,21,24} and asymmetry between right and left labia was common.^{22,24}

These findings coincide with a proliferation of resources on female genital diversity that reflect the depth of societal concerns^{33,34,35,36} but are not represented in anatomy texts.¹² A study comparing 253 visual images from online pornography, feminist publications (online and print) and anatomy textbooks found that labia minora were significantly less protuberant in anatomy textbooks and online pornography compared with the feminist publications.³⁷ The anatomy textbooks used in medical education should include images of non-protruding and visible, and symmetrical and asymmetrical, labia minora so that non-specialist medical professionals are fully conversant with normal genital diversity when consulted by women who are concerned about their genital appearance.

Cosmetic surgeons describe visible labia minora as hypertrophy, which means excessive growth.⁹ Hypertrophy of the labia has been variably defined, without proper scientific methodology, as maximal labial width exceeding 5 cm,³⁸ 4 cm³⁹ or 3 cm,⁴⁰ and more recently cosmetic surgeon Stefan Gress suggested that 2 cm constituted a useful baseline definition of hypertrophy because it is at this point that “the inner vaginal lips generally start to be visible outside the shelter of the labia majora”.^{41(p.6)} A variety of classification schemes for labial protrusion have been proposed to guide different treatment paradigms but, again, with no consensus regarding definition or use.⁴²

The implication here is that abnormal is the key ethical criterion for labiaplasty⁴³ and that a cut-off or threshold exists for normal beyond which surgery is indicated. Only one study has proposed an evidence-based cut-off point for normal labia minora. The United Kingdom group who reported the first study on normal genitalia subsequently published a prospective study of 33 women seeking labiaplasty.⁴⁴ They found that the labial widths of all 33 women seeking surgery (right labia mean 26.9 mm [standard deviation 12.8 mm], left labia mean 24.8 mm [standard deviation 13.1 mm]) were within the defined normal limits of their previous study,¹⁹ although three patients had significant labial asymmetry with a difference of 30 mm in width. Unilateral labiaplasty was offered to the three women with asymmetry but the other 30 women were refused surgery: 11 accepted a psychologist referral, 12 opted for a second opinion and one was referred for urgent mental health assessment. The authors concluded that “there is an urgent need for data based on a large general population sample stratified according to age, ethnicity and parity”.^{44(p.1509)} All of the studies analysed shared this common objective of establishing a normative numeric data resource for pre-operative counselling, especially when labiaplasty is desired for aesthetic reasons (with the exception of the two studies with pre-pubertal subjects). “These women need to have access

to adequate education and knowledge of the diversity in the normal genital appearance. This could be conducted by presenting the normative data”.^{24(p.202)}

The focus on normative datasets and normal has been labelled a preoccupation of the literature⁴³ and a distraction⁴⁵ because it implies that women who seek surgery to alter the appearance of their vulvae have “an underlying desire for normalcy”.^{43(p.538)} In a recent qualitative study, the authors interviewed 11 clinicians who had received requests for labiaplasty from adolescent girls and concluded that education and reassurance do not always work. The researchers identified two categories of patients: the desisters who were reassured with explanations about normality and subsequently lost their desire for labiaplasty, and the persistors who, despite education and reassurance, remained concerned and desirous of surgery. In doing so the authors identified a clear gap in the recommendations of professional position statements, with their emphasis on education and reassurance, because they do not address how to deal with *persistors*.⁴³

Normative datasets are useful when planning reconstructive or transgender surgery but their role in patient education has been questioned by the identification of the persistor subgroup in adolescent labiaplasty referrals. Further research could usefully be directed towards whether and to what degree the persistor patient profile exists in pre- and post-menopausal cohorts of women seeking FGCS and what it might take to dissuade them from submitting to costly labiaplasty surgery. Many researchers have stressed the need for preoperative counselling and education to go beyond what is normal and include the use of validated tools that measure psychological, physical and sexual function.⁴⁶

This review is the first analysis of normative datasets from an anatomical viewpoint. There was no combination of search terms and databases that located all of these papers in one search. The 10 studies analysed were published in nine different journals and had a total of 33 key words, with the words female, anatomy and measurements listed in three studies each, and the words labiaplasty, genitalia and vulva listed in two studies each. The remaining 27 key words were used in one article each. This diffusion through the literature reflects the breadth of academic interest in FGCS, which has captured the attention of many other specialties (gynaecologists, sexual therapists and psychologists) in addition to cosmetic surgeons. A weakness of this study is the limitation to English-language publications, given that the successful mainstreaming of FGCS in higher income countries is now reflected in middle- and low-income countries with the potential for publications in many languages other than English.

Data on vulval measurements has historically been sparse. This paper has reviewed 10 published studies that show a wide range of normal variation in the anatomy of the labia minora. This information does not appear to be common knowledge amongst the general public, or even the medical profession, as evidenced by the fact that labia are described as hypertrophic when still within the normal range demonstrated.

Summation of the data sets did not allow for population-based and observer-based bias and methodological variation, and evidence was presented that the focus on defining normality may be overemphasised, but the general findings can still be helpful in counselling women seeking labiaplasty. This information could usefully be added to medical textbooks and teaching to ensure that medical graduates are sufficiently informed about normal variation in female genital anatomy to assess and advise women seeking FGCS.

Author Manuscript

Table

Table 1. Aim, selection criteria, methodology and results for each study

Author (year)	Aim	Participants (country)	Patient selection	Method	Measurements
Chinkangsadan et al. (2020) ²⁰	Normative data and difference between pre- and post-menopausal groups	155 pre- and post- aged 20–70 years (Thailand)	Attending outpatient clinic for annual pelvic exam and satisfied with external genitalia (Genital Appearance Satisfaction Questionnaire) Excluded previous genital surgery or episiotomy	<ul style="list-style-type: none">• Lithotomy position• Not anaesthetised• Minimal traction• Digital callipers• First author did all measuring	<ul style="list-style-type: none">• Labia minora median width: right 9.69 mm (range 6.61–27.30 mm), left 10.46 mm (range 6.75–32.91 mm)• Labia minora median length: right 30.91 mm (range 8.85–85.73 mm), left 30.93 mm (range 7.71–87.33 mm)• Protrusion of labia minora median 0 mm (range 0–15.81 mm)• 38.1% had protruding labia minora

Author (year)	Aim	Participants (country)	Patient selection	Method	Measurements
Widschwendter et al. (2020) ²¹	To correlate objective measurements of labia minora with perception or complaints	200 pre-menopausal women aged 18–50 years; median 33.5 years (Austria)	Attending outpatient clinic for check-up or other gynaecological issue Excluded previous genital surgery or vulval disease	<ul style="list-style-type: none"> • Dorsosacral position • Not anaesthetised • No traction applied • Tape measure • Measurers not identified • Participants also completed questionnaire about subjective perception of labial size and complaints 	<ul style="list-style-type: none"> • Labia minora median width 19.0 mm (interquartile range 12.6–27.5 mm) • Labia minora median length 35.5 mm (interquartile range 27.8–48.9 mm) • Median difference in length between sides 4 mm • 56.5% had visible labia minora

Author Manuscript

Author (year)	Aim	Participants (country)	Patient selection	Method	Measurements
Brodie et al. (2019)²²	Sample of normal female adolescents with focus on size and morphology of labia minora	44 adolescents aged 10–19 years; mean 14.4 years (United States)	Presenting for routine surgical procedures Excluded pre-pubertal (Tanner stage 1, 2), genital abnormality or previous genital surgery	<ul style="list-style-type: none"> • Frog-leg position or stirrups • Anaesthetised • Stretched and unstretched measurements taken • Flexible paper ruler • Four measurers 	<ul style="list-style-type: none"> • Labia minora median width 10 mm (range 3–70 mm) • Labia minora median length 31 mm (range 10–90 mm) • Right and left labial width (unstretched) different in 55%
Kreklau et al. (2018)²³	Cross-sectional study of normal vulva in white women aged 15–84 years (conscious avoidance of ethnic diversity)	657 pre- and post-menopausal women aged 15–84 years; mean 47.27 years (Switzerland)	Attending outpatient clinic Excluded previous genital surgery, vulval pathology, pregnancy or hormone therapy other than oral contraceptive pill	<ul style="list-style-type: none"> • Lithotomy position • Not anaesthetised • No traction applied • Paper measuring tape • 12 measurers 	<ul style="list-style-type: none"> • Labia minora mean width: right 13.4 mm (range 2–61 mm), left 14.15 mm (range 1–42 mm) • Labia minora mean length: right 42.1 mm (range 6–100 mm), left 42.97 mm (range 5–100 mm) • Asymmetry not statistically significant

Author (year)	Aim	Participants (country)	Patient selection	Method	Measurements
Lykkebo et al. (2017) ²⁴	To correlate size and perception of labia minora in normal women	244 pre-menopausal women aged 18–50 years (Denmark)	Attending outpatient clinic Excluded previous genital surgery or vulval skin disease	<ul style="list-style-type: none"> • Lithotomy position • Not anaesthetised • No traction applied, • Tape measure • Four measurers 	<ul style="list-style-type: none"> • Mean width: right 15.9 mm (range 1–45 mm), left 15.5 mm (range 1–40 mm) • Median length 35.5 mm • 54% had visible labia minora • 87.5% perceived their vulva as normal, including 2/3 women with labia >26.5 mm
Krissi et al. (2016) ²⁵	Correlate anatomical dimensions of adult female genitalia with sexual function (orgasm frequency)	32 pre-menopausal women aged 20–51 years; mean 33.38 years (Israel)	Undergoing surgery unrelated to vulvar morphology Excluded previous genital surgery, oral contraceptive pill or post-menopausal	<ul style="list-style-type: none"> • Lithotomy position • Anaesthetised • No traction applied • Paper tape • One measurer 	<ul style="list-style-type: none"> • Mean width: right 14.9 mm (range 10–30 mm), left 14.5 mm (range 10–40 mm) • Mean length: right 34.7 mm (10–60 mm), left 38.2 mm (range 20–60 mm)

Author (year)	Aim	Participants (country)	Patient selection	Method	Measurements
Chalmers et al. (2014) ²⁹	Baseline genital standards in pre-pubescent females for genital reconstruction in congenital abnormalities	56 pre-pubertal girls divided into age groups: <2, 2–5, 5–11 and >11 years (United States)	Undergoing unrelated surgery Excluded previous genital surgery, genital anomalies or developmental delay	<ul style="list-style-type: none"> • Supine position • Anaesthetised • Gentle traction • Metric ruler • Resident or surgeon measuring 	<ul style="list-style-type: none"> • Labia minora size showed a linear correlation with advance of age, height and body weight
Akbiyik et al. (2010) ²⁸	Baseline genital standards in pre-adolescent females for feminising genitoplasty	205 pre-pubertal girls divided into age groups: 1–12, 13–24, 25–60 months and 61–120 months (Turkey)	Undergoing unrelated surgery Excluded previous genital surgery, genital anomalies or developmental delay	<ul style="list-style-type: none"> • Supine with hips flexed • Anaesthetised • Digital calliper • Measurers not identified 	<ul style="list-style-type: none"> • Labia minora size showed a linear correlation with advance of age, height and body weight • Asymmetry in 25%

Author (year)	Aim	Participants (country)	Patient selection	Method	Measurements	
Basaran (2008) ²⁶	Compare genital measurements between pre- and post-menopausal women	50 pre-menopausal women aged 22–39 years; mean 30.2 years 50 post-menopausal women aged 47–60 years; mean 55.1 years (Turkey)	Attending gynaecology and menopause clinics Excluded history of pelvic surgery or congenital anomaly, episiotomy or hormone replacement therapy	outpatient and Identified	<ul style="list-style-type: none"> • Lithotomy • Not anaesthetised • Tape measure • Measurers not identified 	<p>Pre-menopausal</p> <ul style="list-style-type: none"> • Mean width: right 17.7 mm (range 9–29 mm), left 18.1 mm (range 12–33 mm) • Mean length: right 55.6 mm (range 33–75 mm), left 55.8 mm (range 35–75 mm) <p>Post-menopausal</p> <ul style="list-style-type: none"> • Mean width: right 15.5 mm (range 7–29 mm), left 15.3 mm (range 6–26 mm) • Mean length: right 34.7mm (range 10–60 mm), left 38.2 mm (range 20–60 mm) • The labia minora were wider in pre-menopausal women than post-menopausal women (mean ± standard deviation: 17.9 ± 4.1 mm vs 15.4 ± 4.7 mm)

Author (year)	Aim	Participants (country)	Patient selection	Method	Measurements
Lloyd (2005) ¹⁹	Observational cross-sectional study of genital dimensions in normal women	50 pre-menopausal women aged 18–50 years; mean 35.6 years (United Kingdom)	Undergoing gynaecological surgery not involving genitalia Excluded previous genital surgery or female genital mutilation	<ul style="list-style-type: none"> • Lithotomy • Anaesthetised • Tape measure • Two registrars measured 	<ul style="list-style-type: none"> • Mean length 60.6 mm (range 20–100 mm) • Mean width 21.8 mm (range 7–50 mm)

Author Manuscript

Figure legend

Figure 1. Literature search process and results in PRISMA 2009 flow diagram

References

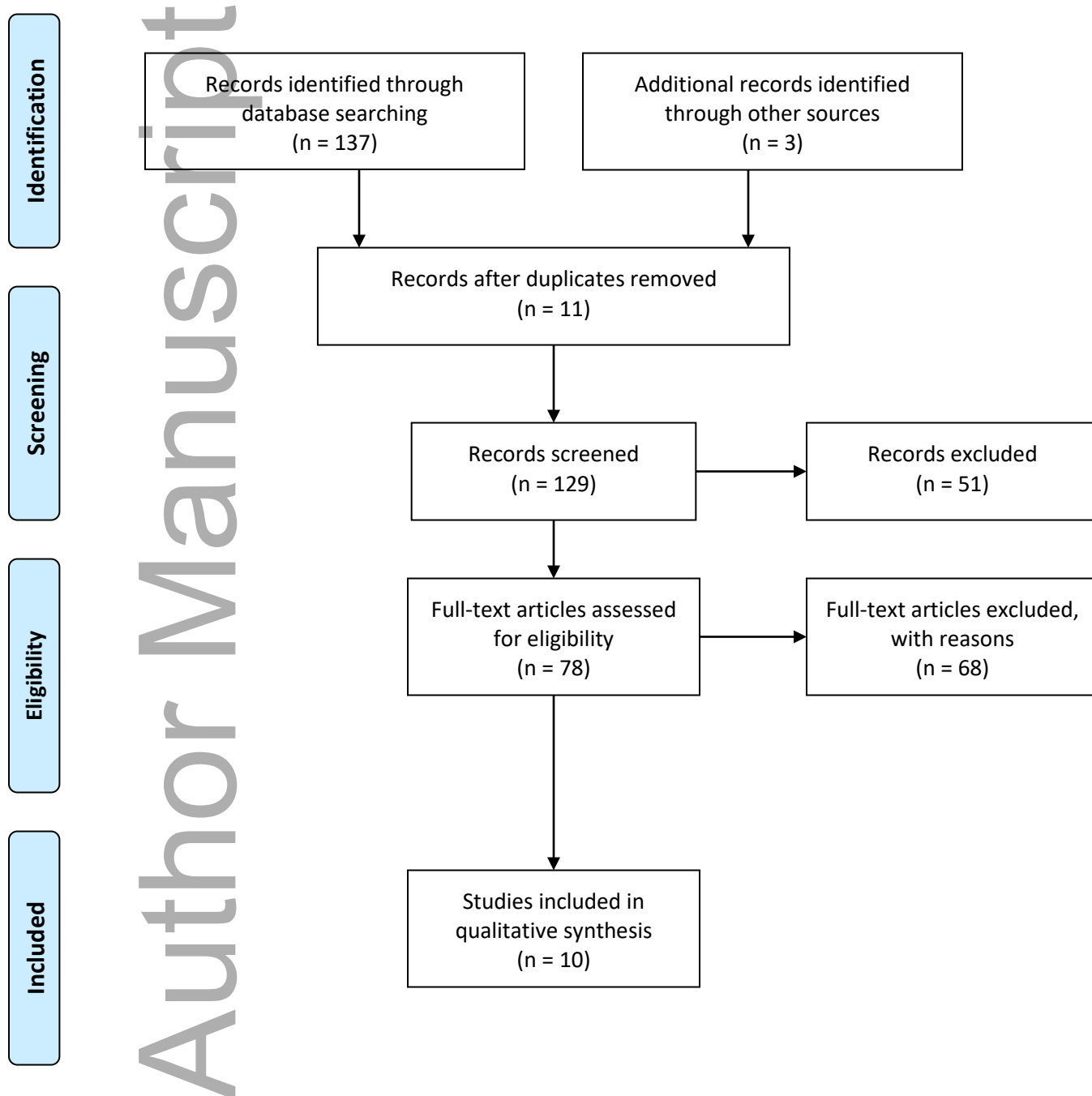
- 1 Committee on Gynecologic Practice. Elective female genital cosmetic surgery: ACOG committee opinion, Number 795. *Obstet Gynecol.* 2020; 135(1): e36–e42. doi: 10.1097/AOG.0000000000003616.
- 2 Royal College of Obstetricians and Gynaecologists Ethics Committee. Ethical opinion paper: ethical considerations in relation to female genital cosmetic surgery (FGCS) [Internet]. London: Royal College of Obstetricians and Gynaecologists; 2013. Available from: <https://www.rcog.org.uk/globalassets/documents/guidelines/ethics-issues-and-resources/rcog-fgcs-ethical-opinion-paper.pdf>. Accessed 21 July 2020.
- 3 RANZCOG Women’s Health Committee. Vaginal “rejuvenation” and cosmetic vaginal procedures. *Aust N Z J Obstet Gynaecol.* 2019. doi: 10.1111/ajo.12999. Online ahead of print.
- 4 Cain JM, Iglesia CB, Dickens B, Montgomery O. Body enhancement through female genital cosmetic surgery creates ethical and rights dilemmas. *Int J Gynaecol Obstet.* 2013; 122(2): 169–172. doi: 10.1016/j.ijgo.2013.03.020.
- 5 Chibnall K, McDonald K, Kirkman M. Pathologising diversity: medical websites offering female genital cosmetic surgery in Australia. *Cult Health Sex.* 2020; 22(1): 64–80. doi: 10.1080/13691058.2019.1574029.
- 6 Iglesia CB. Cosmetic gynecology and the elusive quest for the “perfect” vagina. *Obstet Gynecol.* 2012; 119(6): 1083–1084. doi: 10.1097/AOG.0b013e31825833f5.
- 7 Michala L, Koliantzaki S, Antsaklis A. Protruding labia minora: abnormal or just uncool? *J Psychosom Obstet Gynaecol.* 2011; 32(3): 154–156. doi: 10.3109/0167482X.2011.585726.
- 8 Moynihan R. The making of a disease: female sexual dysfunction. *BMJ.* 2003; 326(7379): 45–47. doi: 10.1136/bmj.326.7379.45.
- 9 Nurka C. Female genital cosmetic surgery: deviance, desire and the pursuit of perfection. Switzerland: Palgrave MacMillan; 2019.
- 10 Sacher BC. The normal vulva and vagina. In: Bornstein J, editor. *Vulvar disease*. Cham: Springer; 2019. p. 7–19.

- 11 Clerico C, Lari A, Mojallal A, Boucher F. Anatomy and aesthetics of the labia minora: the ideal vulva? *Aesthetic Plast Surg*. 2017; 41(3): 714–719. doi: 10.1007/s00266-017-0831-1.
- 12 Andrikopoulou M, Michala L, Creighton SM, Liao LM. The normal vulva in medical textbooks. *J Obstet Gynaecol*. 2013; 33(7): 648–650. doi: 10.3109/01443615.2013.807782.
- 13 Deans R, Liao LM, Crouch NS, Creighton SM. Why are women referred for female genital cosmetic surgery? [letter] *Med J Aust*. 2011; 195(2): 99. doi: 10.5694/j.1326-5377.2011.tb03223.x
- 14 Simonis M, Manocha R, Ong JJ. Female genital cosmetic surgery: a cross-sectional survey exploring knowledge, attitude and practice of general practitioners. *BMJ Open*. 2016; 6(9): e013010. doi: 10.1136/bmjopen-2016-013010.
- 15 Howarth C, Hayes J, Simonis M, Temple-Smith M. “Everything’s neatly tucked away”: young women’s views on desirable vulval anatomy. *Cult Heal Sex*. 2016; 18(12): 1363–1378. doi: 10.1080/13691058.2016.1184315.
- 16 Liao LM, Creighton SM. Requests for cosmetic genitoplasty: how should healthcare providers respond? *BMJ*. 2007; 334(7603): 1090–1092. doi: 10.1136/bmj.39206.422269.BE.
- 17 Braun V. Selling the “perfect” vulva? In: Heyes CJ, Jones M, editors. *Cosmetic surgery: a feminist primer*. Abingdon: Routledge. 2016. p. 133–154.
- 18 Hodgkinson DJ, Hait G. Aesthetic vaginal labioplasty. *Plast Reconstr Surg*. 1984; 74(3): 414–416. doi: 10.1097/00006534-198409000-00015.
- 19 Lloyd J, Crouch NS, Minto CL, Liao LM, Creighton SM. Female genital appearance: “normality” unfolds. *BJOG*. 2005; 112(5): 643–646. doi: 10.1111/j.1471-0528.2004.00517.x.
- 20 Chinkangsadan T, Ruanphoo P, Bunyavejchevin S. Variation of genital appearance in Thai women. *Thai Journal of Obstetrics and Gynaecology*. 2020; 28(2): 112–119. doi: 10.14456/tjog.2020.15.
- 21 Widschwendter A, Riedl D, Freidhager K, Azim SA, Jerabek-Klestil S, D’Costa E. et al. Perception of labial size and objective measurements – is there a correlation? A cross-sectional study in a cohort not seeking labiaplasty. *J Sex Med*. 2020; 17(3): 461–469. doi: 10.1016/j.jsxm.2019.11.272.

- 22 Brodie K, Alaniz V, Buyers E, Caldwell B, Grantham E, Sheeder J. et al. A study of adolescent female genitalia: what is normal? *J Pediatr Adolesc Gynecol.* 2019; 32(1): 27–31. doi: 10.1016/j.jpag.2018.09.007.
- 23 Kreklau A, Vâz I, Oehme F, Strub F, Brechbühl R, Christmann C, et al. Measurements of a “normal vulva” in women aged 15–84: a cross-sectional prospective single-centre study. *BJOG.* 2018; 125(13): 1656–1661. doi: 10.1111/1471-0528.15387.
- 24 Lykkebo AW, Drue HC, Lam JUH, Guldborg R. The size of labia minora and perception of genital appearance: a cross-sectional study. *J Low Genit Tract Dis.* 2017; 21(3): 198–203. doi: 10.1097/LGT.0000000000000308.
- 25 Krissi H, Ben-Shitrit G, Aviram A, Weintraub AY, From A, Wiznitzer A. et al. Anatomical diversity of the female external genitalia and its association to sexual function. *Eur J Obstet Gynecol Reprod Biol.* 2016; 196: 44–47. doi: 10.1016/j.ejogrb.2015.11.016.
- 26 Basaran M, Kosif R, Bayar U, Civelek B. Characteristics of external genitalia in pre- and postmenopausal women. *Climacteric.* 2008; 11(5): 416–421. doi: 10.1080/13697130802366670.
- 27 Marshall WA, Tanner JM. Variations in pattern of pubertal changes in girls. *Arch Dis Child.* 1969; 44(235): 291–303. doi: 10.1136/adc.44.235.291.
- 28 Akbiyik F, Kutlu AO. External genital proportions in prepubertal girls: a morphometric reference for female genitoplasty. *J Urol.* 2010; 184(4): 1476–1481. doi: 10.1016/j.juro.2010.06.023.
- 29 Chalmers DJ, O’Donnell CI, Casperson KJ, Bergard SC, Hou AH, Nuss GR. et al. Normal anatomic relationships in prepubescent female external genitalia. *J Pediatr Urol.* 2014; 10(6): 1117–1121. doi: 10.1016/j.jpuro.2014.04.011.
- 30 Sharp G, Maynard P, Hamori CA, Oates J, Sarwer DB, Kulkarni J. Measuring quality of life in female genital cosmetic procedure patients: a systematic review of patient-reported outcome measures. *Aesthet Surg J.* 2020; 40(3): 311–318. doi: 10.1093/asj/sjz325.
- 31 Brincat M, Kabalan S, Studd JW, Moniz CF, Montgomery J. A study of the decrease of skin collagen content, skin thickness, and bone mass in the postmenopausal woman. *Obstet Gynecol.* 1987; 70(6): 840–845.
- 32 Iglesia CB, Yurteri-Kaplan L, Alinsod R. Female genital cosmetic surgery: a review of techniques and outcomes. *Int Urogynecol J.* 2013; 24(12): 1997–2009. doi: 10.1007/s00192-013-2117-8.

- 33 The Labia Library [Internet]. Melbourne: Women's Health Victoria; 2011. Available from: www.labialibrary.org.au/. Accessed 21 Jul 2020.
- 34 The Vulva Gallery [Internet]. Melbourne: Women's Health Victoria; 2017. Available from: www.thevulgagallery.com/. Accessed 21 Jul 2020.
- 35 Karras N. *Petals*. San Diego: Crystal River Publishing; 2003.
- 36 McCartney J. *Great wall of vagina*. London: Fine Art Studios. Available from: www.greatwallofvagina.co.uk/home. Accessed 21 Jul 2020.
- 37 Howarth H, Sommer V, Jordan FM. Visual depictions of female genitalia differ depending on source. *Med Humanit*. 2010; 36(2): 75–79. doi: 10.1136/jmh.2009.003707.
- 38 Friedrich EG. *Vulvar disease*. 2nd ed. Philadelphia: WB Saunders; 1983.
- 39 Rouzier R, Louis-Sylvestre C, Paniel BJ, Haddad B. Hypertrophy of labia minora: experience with 163 reductions. *Am J Obstet Gynecol*. 2000; 182(1 Pt 1): 35–40. doi: 10.1016/s0002-9378(00)70488-1.
- 40 Munhoz AM, Filassi JR, Ricci MD, Aldrighi C, Correia LD, Aldrighi JM, et al. Aesthetic labia minora reduction with inferior wedge resection and superior pedicle flap reconstruction. *Plas Reconstr Surg*. 2006; 118(5): 1237–1247. doi: 10.1097/01.prs.0000237003.24294.04.
- 41 Gress S. *Aesthetic and functional labiaplasty*. Cham: Springer; 2017.
- 42 Motakef S, Rodriguez-Feliz J, Chung MT, Ingargiola MJ, Wong VW, Patel A. Vaginal labiaplasty: current practices and a simplified classification system for labial protrusion. *Plast Reconstr Surg*. 2015; 135(3): 774–788. doi: 10.1097/PRS.0000000000001000.
- 43 Spriggs M, Gillam L. “I don't see that as a medical problem”: clinicians' attitudes and responses to requests for cosmetic genital surgery by adolescents. *J Bioeth Inq*. 2018; 15(4): 535–548. doi: 10.1007/s11673-018-9878-1.
- 44 Crouch NS, Deans R, Michala L, Liao LM, Creighton SM. Clinical characteristics of well women seeking labial reduction surgery: a prospective study. *BJOG*. 2011; 118(12): 1507–1510. doi: 10.1111/j.1471-0528.2011.03088.x.
- 45 Spriggs M, Gillam L. Cosmetic labiaplasty: defining “normality” is not the issue. *J Pediatr Adolesc Gynecol*. 2017; 30(3) :438. doi: 10.1016/j.jpag.2016.12.007.
- 46 Brotto LA, Bryce M, Todd N. Female genital cosmetic surgery: psychological aspects and approaches. In: Creighton SM, Liao L-M, editors. *Female genital cosmetic surgery: solution to what problem?* Cambridge: Cambridge University Press; 2019. p. 118–128.

Figure 1. Literature search process and results in PRISMA 2009 flow diagram



From: Moher D, Liberati A, Tetzlaff J, Altman DG, The PRISMA Group (2009). Preferred Reporting Items for Systematic Reviews and Meta-Analyses: The PRISMA Statement. PLoS Med 6(7): e1000097. doi:10.1371/journal.pmed1000097