



Minerva Access is the Institutional Repository of The University of Melbourne

Author/s:

Hobbs, EC;Loukopoulos, P;Stinear, TP;Porter, JL;Lee, JYH;Whiteley, P;Skerratt, LF;Gibney, KB;Meredith, A

Title:

Severe cases of Buruli ulcer (infection with *Mycobacterium ulcerans*) in common ringtail possums in Victoria adversely affect animal welfare

Date:

2024-10-01

Citation:

Hobbs, E. C., Loukopoulos, P., Stinear, T. P., Porter, J. L., Lee, J. Y. H., Whiteley, P., Skerratt, L. F., Gibney, K. B. & Meredith, A. (2024). Severe cases of Buruli ulcer (infection with *Mycobacterium ulcerans*) in common ringtail possums in Victoria adversely affect animal welfare. *Australian Veterinary Journal*, 102 (10), pp.517-523. <https://doi.org/10.1111/avj.13360>.

Persistent Link:

<https://hdl.handle.net/11343/351291>

License:

[CC BY](#)



## CASE REPORT

# Severe cases of Buruli ulcer (infection with *Mycobacterium ulcerans*) in common ringtail possums in Victoria adversely affect animal welfare

EC Hobbs,<sup>a,b,\*</sup> P Loukopoulos,<sup>a</sup> TP Stinear,<sup>c</sup> JL Porter,<sup>c</sup> JYH Lee,<sup>c</sup> P Whiteley,<sup>a</sup> LF Skerratt,<sup>a</sup> KB Gibney<sup>b</sup> and A Meredith<sup>a,d</sup>

Buruli ulcer is a chronic ulcerative disease of the skin and subcutaneous tissues caused by infection with *Mycobacterium ulcerans*. Although Australian possums are known to be susceptible to Buruli ulcer, many aspects of the disease in possums, including welfare impacts, remain largely unreported. Severe clinical Buruli ulcer was identified in four common ringtail possums (*Pseudocheirus peregrinus*) from Melbourne, Victoria. All four possums were euthanased due to the presence of deep ulcerative lesions on paws, with extensive tissue necrosis that exposed bones and tendons in three cases. Histologically, there was severe ulcerative necrotising pyogranulomatous dermatitis, panniculitis and myositis, with intralesional acid-fast bacteria. *M. ulcerans* was detected by real-time PCR in all swabs, tissues and faeces collected from all four cases. Buruli ulcer may be an important and under-recognised cause of poor possum welfare in endemic areas. The physical impacts of the severe cutaneous lesions, especially those extending to underlying bones and joints, would have directly impaired the mobility of these possums, affecting navigation of their natural environments and expression of natural behaviours including foraging and socialising. Systemic distribution of *M. ulcerans* throughout all major internal organs, as observed here, may further impact the health and fitness of infected possums. Faecal shedding of *M. ulcerans* in all four cases supports the role of possums as zoonotic reservoirs. Further research is needed to investigate the epidemiology, pathogenesis and welfare impacts of Buruli ulcer in possums and to inform the design of interventions that may protect their health and welfare.

**Keywords** animal welfare; Buruli ulcer; *Mycobacterium ulcerans*; possums; wild animals

**Abbreviations** BU, Buruli/Bairnsdale ulcer; BCG, bacille Calmette–Guérin (vaccine against *Mycobacterium tuberculosis*); BCS, body condition score; CRT, common ringtail possum

(*Pseudocheirus peregrinus*); MU, *Mycobacterium ulcerans*; ZN, Ziehl–Neelsen

*Aust Vet J* 2024;102:517–523

doi: 10.1111/avj.13360

**B**uruli, or Bairnsdale, ulcer (BU) is a chronic, necrotising and debilitating disease of skin and subcutaneous tissues caused by *Mycobacterium ulcerans* (MU). BU is predominantly described and reported as a human disease, but cases are occasionally reported in domestic and wild animals.<sup>1–3</sup> Most human cases are reported in sub-Saharan Africa, however, the incidence of BU appears to be declining in this region.<sup>4</sup> Australia is the only high-income country reporting significant endemic human BU.<sup>4</sup> The most significant disease focus is in Victoria, where cases have been increasing in number and geographical distribution over the past decade,<sup>5,6</sup> with suburban cases now frequently reported in the state's two largest cities, Melbourne and Geelong.

BU is both vector-borne and zoonotic in Victoria, with certain species of mosquito and native possum acting as MU vectors and reservoirs, respectively.<sup>7–9</sup> Common ringtail (CRT, *Pseudocheirus peregrinus*) and common brushtail (*Trichosurus vulpecula*) possums, both of which are endemic and abundant throughout Victoria, can excrete significant amounts of MU into the environment via their faeces.<sup>7</sup> Possums are also susceptible to clinical disease: a 2014 paper described clinical BU in 27 possums, most of which had cutaneous ulcers on the face (exposing bone in one case), limbs and/or tail.<sup>10</sup> Pathology and/or the presence of MU was confirmed by PCR in some internal tissues including lung and liver<sup>10</sup>, however, the welfare impacts of BU on the affected possums were not evaluated or discussed.

To further investigate BU in possums, we conducted a necropsy-based study through opportunistic collection of deceased animals, and active trap-and-release events, as part of the National Health and Medical Research Council (NHMRC)-funded 'Beating Buruli in Victoria' project led by the University of Melbourne's Doherty Institute and the Melbourne Veterinary School (UniMelb AEC 22910; DELWP permits 10009447 and 10010257). Possums that died or were euthanased for any reason at two veterinary clinics in Werribee and North Melbourne, Victoria, between May 2021 and December 2022, were collected and stored at  $-20^{\circ}\text{C}$ . Two trap-and-release events were conducted, and one possum that was euthanased due to presence of severe ulcerative lesions was included in the necropsy study. Thawed possums were necropsied at the Melbourne

\*Corresponding author.

<sup>a</sup>Melbourne Veterinary School, Faculty of Science, The University of Melbourne, Werribee, Victoria, Australia; [ehobbs@unimelb.edu.au](mailto:ehobbs@unimelb.edu.au)

<sup>b</sup>Department of Infectious Diseases, Doherty Institute, The University of Melbourne, Parkville, Victoria, Australia

<sup>c</sup>Department of Microbiology and Immunology, Doherty Institute, The University of Melbourne, Parkville, Victoria, Australia

<sup>d</sup>Faculty of Natural Sciences, The University of Keele, Keele, UK  
KB Gibney and A Meredith Joint senior authors.

Veterinary School by one veterinarian (ECH). Species, sex, weight, age categorisation (adult, sub-adult or juvenile, based on body weight<sup>11</sup>), five-point body condition score (BCS)<sup>11</sup> and pouch status where applicable were recorded on customised necropsy sheets (see Supplementary document 1). Cutaneous lesions were first photographed, measured and described on the mapping silhouette on the necropsy record sheet, and a semi-subjective estimate of the severity of the lesions and inferred welfare impacts was recorded as mild, moderate or severe, based on the World Health Organization's BU disease classification for assessment of human cases.<sup>12</sup> Plain microbiological swabs were taken from each possum's oral cavity, cloaca, pouch and skin lesions, and duplicate sets of a variety of tissues and organs (full list in Supplementary document 1) plus any skin lesions were collected into formalin for histopathology, and cryovials stored at  $-80^{\circ}$  for PCR, culture and genomic analysis where indicated.

These studies concluded in 2023, and the results will be presented in due course. However, the identification of four cases of severe BU in CRTs that necessitated euthanasia was deemed to be of sufficient interest to the veterinary community to justify early publication. This case series describes the clinical and laboratory findings from four cases of severe BU in CRTs from this larger study that were euthanased due to the severity of the disease.

## Case reports

### Case 1

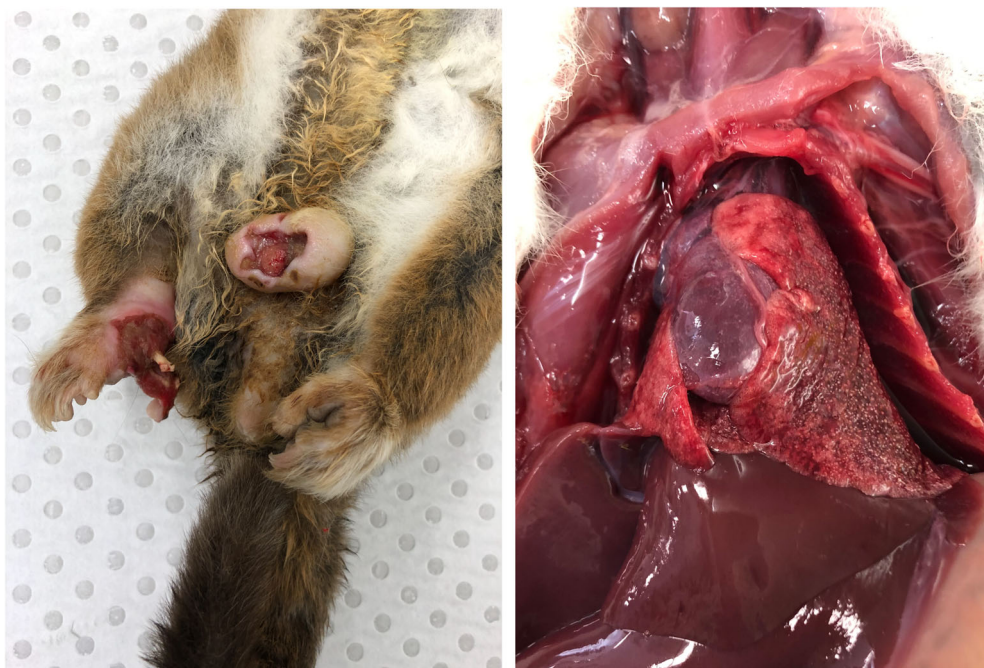**History.** An adult male CRT that regularly visited a residential property in Essendon, Victoria, was observed in April 2021 to have cutaneous ulcerations. Several CRTs frequented this property, including a female CRT with severe cutaneous lesions captured at this address in 2019, which was euthanased and later diagnosed with BU.<sup>13</sup> The male possum was captured and taken to a veterinary

clinic, where it was euthanased due to the severity of its ulcerative lesions and high clinical suspicion of BU given the property's history.

**Postmortem examination.** The body condition was thin (body condition score (BCS) 2/5). There were two deep cutaneous ulcers on the right hind paw and scrotum, which would likely have been aligned and in contact when the possum was crouched (Figure 1). The ulcer on the first digit of the right hind paw continued to the bone at the proximal aspect of the first metacarpal, with the entire distal portion of the bone exposed. The ulcer on the ventral scrotum measured approximately 3 cm  $\times$  2 cm, extended to the testicular fascia and appeared granulated and proliferative, with undermined edges. Multifocally, nodules of approximately 1 mm diameter, presumably grossly interpreted as microgranulomas, were observed throughout the lungs.

**Laboratory investigations.** MU was detected by PCR testing on all swabs (skin, oral cavity and cloaca) and tissues collected during necropsy (ulcers, ear, nose, front footpad, hind footpad, submandibular lymph node, lung, liver, spleen, kidney, adrenal gland, body cavity fluid, gut contents, stomach, small intestine, caecum, large intestine and faeces). MU was cultured from a sample of the testicular ulcer, and genome sequencing confirmed that the genotype matched the MU isolate obtained from the female CRT confirmed with BU from the same location in 2019.

Histological examination of the skin lesions revealed severe ulcerative necrotising pyogranulomatous dermatitis, cellulitis and myositis, with abundant intralesional Gram-positive and acid-fast bacilli on Ziehl–Neelsen (ZN) staining. Severe autolysis and freeze–thaw artefact prevented meaningful histological interpretation of the organ sections, including the lungs.



**Figure 1.** Severe cutaneous and systemic *M. ulcerans* infection in a male common ringtail possum from Essendon, Victoria (Case 1). **Left:** Extensive, deep ulcers are visible on the right hind paw, exposing the distal portion of the metacarpal bone of digit 1, and the scrotum. These lesions would likely have been aligned and in contact when the animal was sitting crouched. (Photo credit: JYHL) **Right:** Lesions presumably interpreted as multifocal pulmonary microgranulomas were observed grossly.

**Case 2**

**History.** An adult male CRT with multiple skin lesions was captured in Bentleigh, Victoria, in December 2021, and taken to a veterinary clinic. The severity of its cutaneous ulcerations necessitated euthanasia.

**Postmortem examination.** Eight ulcerative lesions were identified as follows (Figure 2):

- Single dry erythematous ulcers approximately 1 cm in diameter with white margins on the palmar surfaces of each fore paw; two lateral carpal bones of the left paw were exposed.
- Two shallow dry, scabbed lesions approximately 1–1.5 cm<sup>2</sup> on the plantar surfaces of each hind paw.
- One shallow erythematous ulcer encircled by white margins surrounding the cloacal opening.
- One approximately 3 mm<sup>2</sup> blackened oedematous ulcer with necrotic focus encompassing the distal tail tip.

The body condition was thin (BCS 2/5). No other abnormalities were detected at necropsy.

**Laboratory investigations.** MU was detected by PCR in all swabs (ulcers, oral cavity and cloaca) and tissue samples collected during necropsy (ulcers, ear, nose, front footpad, hind footpad, submandibular lymph node, heart, lung, liver, spleen, kidney, adrenal gland, body cavity fluid, gut contents, stomach, small intestine, caecum, large intestine and faeces).

Histopathology of the skin lesions confirmed severe ulcerative necrotising pyogranulomatous dermatitis and panniculitis, with intralosomal acid-fast bacilli observed in ZN-stained sections, in four ulcers (tail, left hind and right hind limb ulcers). The tail and one right forelimb ulcer were the deepest, expanding to the underlying

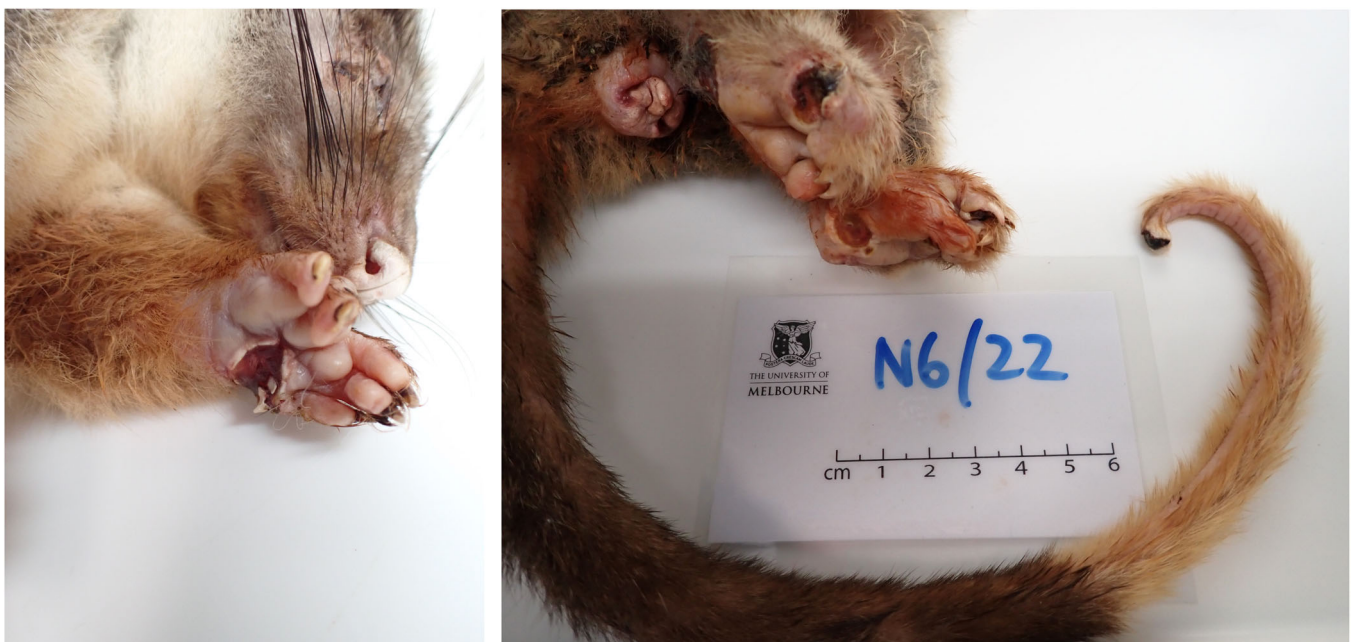bone. The left forelimb lesion showed pyogranulomatous dermatitis, with epidermal hyperplasia and other changes consistent with ongoing cutaneous healing in the overlying epidermis. All examined lesion sections were ZN negative. The liver showed minimal multifocal lymphoplasmacytic aggregation, interpreted as incidental. The pancreas showed possible mild acinar atrophy, consistent with poor nutritional condition. The heart, brain, meninges, kidneys and stomach showed no noteworthy changes. The freeze–thaw artefact and autolysis in the intestines and other examined organs prevented meaningful evaluation.

**Case 3**

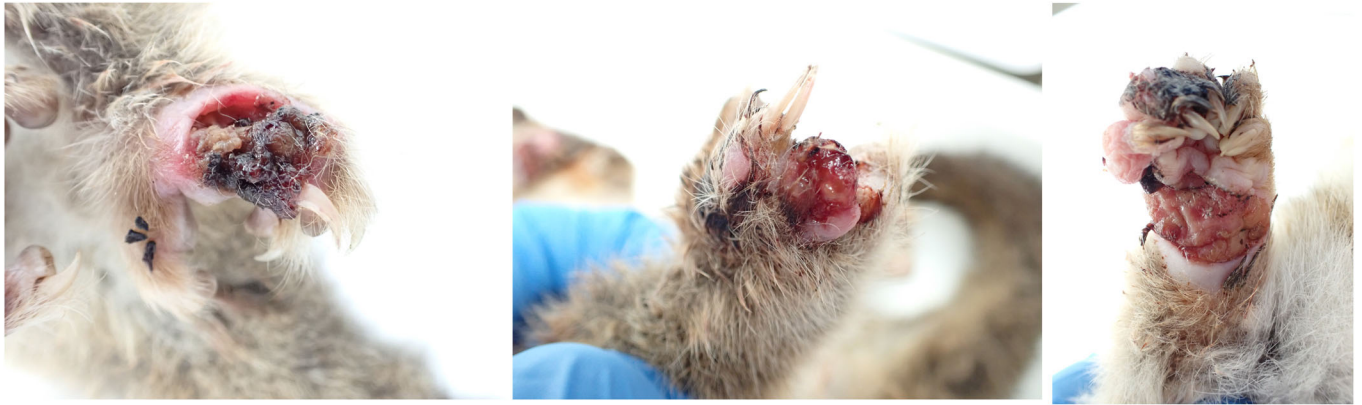**History.** A moribund adult female CRT was found on the ground during daytime hours in Essendon, Victoria, in October 2022. It was taken to a veterinary clinic, where it was euthanased due to severe swelling and ulceration of three of its paws.

**Postmortem examination.** Body condition was emaciated (BCS 1/5). Severe ulcerative lesions were observed on three paws (see Figure 3) and the tail as follows:

- The right forepaw was markedly oedematous and bore an approximately 2.5 cm x 1 cm almost circumferential proliferative ulcerative lesion covering most of its palmar aspect and extending partially to the dorsal aspect of digit 1.
- The dorsal surface of the left hind paw was swollen and bore an approximately 2 cm x 1.5 cm ulcer between digits 1 and 2, with deeply undermined caudal wound edges. The ulcer was covered by a plug of necrotic material and extended deep into the underlying muscle and tendon.



**Figure 2.** Severe ulcerative BU lesions in a common ringtail possum from Richmond, Victoria (Case 2). *Left:* Palmar surface of left forepaw, with lateral carpal bones exposed. *Right:* View of hindquarters showing desiccated ulcers on both hind paws, the cloaca and the distal tip of the tail.



**Figure 3.** Three of the ulcerative BU lesions observed in a female common ringtail possum from Essendon (Case 3). *Left:* Dorsal surface of left hind paw with deeply undermined wound edges and tendons and bone visible under the central necrotic plug. *Centre:* Craniodorsal aspect of right hind paw, showing the exudative ulcerated surface of digit 4 and missing nail. *Right:* Palmar view of the extensive proliferative ulcerative lesion partially encircling the right fore paw.

- The craniodorsal aspect of digit 4 of the right hind paw was swollen, ulcerated to the level of the underlying subcutis and contained thick purulent exudate; the claw was absent.
- Two shallow dry circular ulcers were present on the hairless ventral surface of the tail, approximately halfway down the white-furred section, and 1.5 cm apart. The proximal ulcer was 3 mm<sup>2</sup>, and the distal ulcer was 6 mm<sup>2</sup>.

**Laboratory investigations.** All swabs (ulcers, oral cavity, cloaca and pouch) and tissues collected during necropsy (ulcers, ear, nose, front footpad, hind footpad, submandibular lymph node, heart, lung, liver, spleen, kidney, adrenal gland, body cavity fluid, gut contents, stomach, small intestine, caecum, large intestine and faeces) were PCR positive for MU.

The cutaneous ulcers from the paws showed exceedingly severe ulcerative necrotising pyogranulomatous dermatitis and cellulitis, with myriad bacteria both on the surface (gram positive) and deep within the dermis and underlying tissues (ZN positive). The right hindlimb ulcer was covered by thick serocellular crust. The right forelimb ulcer showed more extensive necrosis.

There was marked pulmonary oedema, with thrombosis of several medium calibre vessels and several mild lymphohistiocytic aggregates, however, granulomas were not definitively detected. Diffuse moderate periportal, random and intra-sinusoidal aggregation of neutrophils and lymphocytes and fewer histiocytes were observed in liver sections (moderate neutrophilic, lymphohistiocytic hepatitis). No bacteria were observed on histochemical staining of lung, liver or kidney sections. The brain, heart, kidneys, spleen and stomach showed no noteworthy changes.

#### Case 4

**History.** Trapping was conducted in December 2022 on the Essendon property where Case 1 and the previous BU-positive female CRT from 2019 were identified, in response to reports from the resident of additional possums with lesions.

A young adult male CRT was trapped and examined under general anaesthesia (isoflurane in oxygen administered via face mask). Body condition was thin (BCS 2/5), and the coat appeared dull. The left hind paw was grossly swollen to approximately twice the normal size, with a suppurative linear opening on the dorsal aspect. Examination and palpation of the paw indicated structural deformities and likely function loss. Three partially contracted ulcerative lesions were also observed on the tail. The possum was euthanased due to the severity of the hind paw lesion.

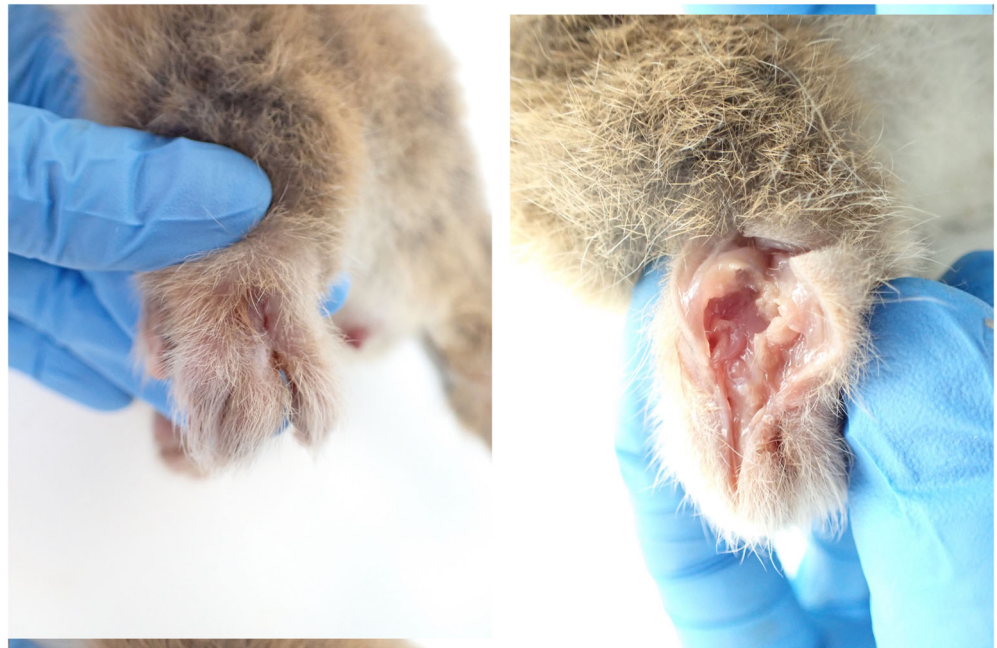
#### Postmortem examination

- There was an approximately 4 mm x 2 mm linear epidermal ulcer exuding suppurative material on the dorsal aspect of the markedly oedematous left dorsal hind paw, dissection through which revealed a tunnelling wound that extended through the subcutaneous tissues to a central cavity involving striated muscle, ligaments and tendons (see Figure 4).
- There were two discrete, scabbed, dry, 3–5 mm<sup>2</sup> ulcerative lesions on the ventral surface of the proximal portion of the tail and a third in the proximal portion of the distal white section.

No noteworthy macroscopic changes were detected in the remaining body systems.

**Laboratory investigations.** PCR testing confirmed the presence of MU DNA in all swabs (ulcers, oral cavity and cloaca) and tissues (ulcers, ear, nose, front footpad, hind footpad, submandibular lymph node, heart, lung, liver, spleen, kidney, adrenal gland, body cavity fluid, gut contents, stomach, small intestine, caecum, large intestine, faeces and bone marrow) collected during necropsy.

Histologic examination of the lesions revealed widespread dermal and subcutaneous necrosis and discrete deep ulcers extending to the underlying subcutaneous connective tissue and striated muscle. The ulcer beds were filled with debris, fibrin, oedema and degenerate leukocytes. There was mild epidermal hyperplasia of the tail ulcer margins, and lymphoid aggregates multifocally in the subcutis. ZN staining revealed moderate to large numbers of acid-fast bacteria in all lesions, concentrated in areas of tissue necrosis. Multifocal, mild



**Figure 4.** Oedematous lesion with tunnelling wound on the right hind paw of a male common ringtail possum from Essendon (Case 4). *Left:* Oedematous dorsal surface of left hind paw with linear sinus. *Right:* Dorsal view of left hind paw after incision through the sinus revealed a central cavity exposing striated muscle, ligaments and tendons.

to moderate portal hepatitis was observed, however, the presence of freeze–thaw artefact and autolysis effects prevented further detection and interpretation of other changes that may have been present in the liver and other tissues.

### Discussion

This case series describes severe BU in four CRTs, euthanased due to the severity of the disease, from Melbourne's inner suburbs where BU is now endemic. The physical impacts of the extensive swelling, ulceration and tissue necrosis that exposed bones and tendons would have directly impaired the possums' welfare. Additionally, all five domains (nutrition, environment, health, behaviour and mental state)<sup>14</sup> of animal welfare would have likely been affected. The severe paw ulcerations would have reduced the possums' mobility, essential for climbing, foraging and expressing other natural behaviours. The below-average body condition of all four possums and the possible pancreatic atrophy observed in Case 2 indicate their reduced ability to obtain sufficient nutrition. The moribund state of Case 3, found on the ground during daylight hours, is particularly suggestive of substantial impairment in this nocturnal, arboreal species.<sup>15</sup> Despite the lack of confirmed histopathological changes in other organ samples from these possums, the systemic internal distribution of MU bacteria as confirmed by PCR may be associated with impaired function of cardiovascular, respiratory, digestive, reproductive and/or immune systems, which would further reduce animal fitness and welfare. While ulcerative lesions in people are typically painless due to the local analgesic effects of the mycolactones produced by MU,<sup>16</sup> oedematous lesions, as observed in Cases 3 and 4, are often associated with pain.<sup>17</sup> Acute and chronic pain can further reduce the mental domain of severely affected animals and cause additional disturbances to normal behaviours including feeding, sleeping, exploring and socialising.<sup>18</sup> Our findings suggest that severe BU may be an

important cause of impaired possum health and welfare. While few confirmed BU cases in possums have been reported to date, this is likely a reflection of the small proportion of sick or injured wildlife that are presented to veterinary clinics. Structured surveys of possum excreta have reported up to 43% of CRT faecal samples collected from a high endemicity area (Point Lonsdale, Victoria) were positive for MU<sup>7</sup>, suggesting that far more possums are infected with MU than confirmed clinical case numbers would indicate.

Interestingly, the presence of epidermal hyperplasia and multifocal lymphoid aggregates observed in the subcutis of Case 2's left fore-limb lesion and at least one of Case 4's tail ulcers indicates that some level of lesion healing is possible in CRTs. This is a novel finding in this species; to date, spontaneous resolution of BU lesions has only been reported in one common and one mountain brushtail possum<sup>10</sup>, however, the long-term outcomes of those lesions are unknown as both individuals were lost to follow up. Complete resolution of small untreated BU lesions can occur in people,<sup>19</sup> while large lesions that heal by secondary intention can cause chronic disability due to scarring, limb contracture, joint subluxation, muscle atrophy and distal lymphoedema.<sup>12</sup> Lesion progression and long-term outcomes of BU in possums have not been documented to date.

The anatomical BU lesion distribution reported here may suggest routes of MU infection in possums. The predominance of lesions on distal limbs and tails aligns with previously published findings,<sup>7,10</sup> which also reported ulcers on possums' noses, lips and ears. These relatively less furred regions may be more susceptible to bites from MU-harboring mosquitoes. Paws and tails used for climbing may more frequently incur micro-traumas that are susceptible to bacterial invasion; similarly, faces and ears may receive more injuries during fights with other possums. Direct transmission of MU from a possum was recently confirmed in a Victorian man who developed BU

on his finger several months after being bitten while rescuing a sick CRT.<sup>20</sup> While ingestion of MU via contaminated food or water might explain transient MU faecal positivity observed in some clinically unaffected possums,<sup>7,10</sup> it is less likely to cause severe cutaneous ulcerations as observed in these four cases. More research is needed to understand the infection and transmission dynamics of BU in possums.

In Victoria, BU is a notifiable disease in humans but not in animals, and a low awareness of the disease among veterinarians (personal observations, ECH, PW) means animal BU cases are likely to be substantially under-recognised – particularly in free-ranging wildlife that are not regularly presented to veterinary clinics. A not-for-profit wildlife rescue organisation – Wildlife Victoria – reported 75 cases of ulcerative conditions in possums rescued between 2013 and 2022, with an upward trend observed since 2018 (excluding 2020/2021, potentially due to decreased reporting during the COVID-19 pandemic).<sup>21</sup> Inclusion of BU as a differential diagnosis for cutaneous ulcerations in possums in the recently updated Victorian Wildlife Disease Rehabilitation Guidelines<sup>22</sup> was an important step for BU awareness, however, more targeted educational outreach to veterinarians, wildlife carers and pet owners about BU in animals is needed.

Validated management strategies are also needed for prevention of MU infection and/or reduction of disease severity in possums. At present, possums with severe cutaneous lesions presenting to veterinary clinics in Victoria are typically euthanased without attempting diagnosis or treatment. While human cases of BU are successfully treated with several weeks of combination antibiotic therapy, frequent dressing changes and/or surgery,<sup>12,23</sup> these interventions are neither established nor likely to be suitable for free-living wildlife including possums. In particular, CRTs appear highly sensitive to adverse effects of antibiotics: iatrogenic disturbance of normal gut flora can cause potentially fatal caecal stasis and dysbiosis,<sup>15</sup> meaning antibiotics should be used with caution in this species and duration of therapy kept to a minimum.<sup>24</sup> Stress caused by long-term captivity of wild possums may have additional welfare impacts,<sup>22,25</sup> and successful reintegration of possums into wild populations may be compromised after long absences. Aside from ethical considerations, culling wildlife to control infectious diseases has shown equivocal results and may counterintuitively increase both transmission and geographical distribution of pathogens.<sup>26,27</sup> Oral bait vaccination may be a feasible strategy for control of BU in possums. The *Mycobacterium tuberculosis* bacilli Calmette–Guérin (BCG) vaccine has been successfully used in New Zealand for control of bovine tuberculosis (*Mycobacterium bovis*) in brushtail possums,<sup>28</sup> and early results indicate that BCG vaccination protects against BU in mice.<sup>29</sup> A recent article<sup>30</sup> proposed a series of laboratory and field-based studies to trial BCG vaccination against MU infection in possums and to optimise palatability, delivery and efficacy of oral bait vaccine formulations targeted to ringtail and brushtail possums. Successful BU disease control in possums could have manifold benefits including reduced morbidity, mortality and disease transmission. Our findings, which show that all four cases had MU-positive faeces, further support evidence implicating possums as zoonotic reservoirs of MU in Victoria<sup>9</sup>, and suggest that successful control of BU in possums may also benefit public health. Until long-term impacts and outcomes of

BU in possums have been established, and in the absence of validated interventions for control or prevention of BU at present, it is likely that severely clinically affected possums will continue to be euthanased. This case study and the semi-subjective lesion scoring system described here may provide a useful interim tool for veterinarians to recognise BU and assess disease severity in ulcerated possums, which may inform their clinical management of these animals.

Our study has certain inherent limitations. As a predominantly necropsy-based study of wildlife, it was not possible to comment on the ante-mortem condition of three of these possums, nor could we observe or measure the effects of BU on the possums over time. The absence of definitive histopathological changes and acid-fast bacteria in some PCR-positive organs could indicate that the presence of MU was not associated with pathological changes, or may reflect inadvertent sampling bias or the effects of freeze–thaw artefacts and autolysis that were present to varying degrees in all four possums. These effects also prevented our ability to confirm or refute the presumptive pulmonary microgranulomas observed grossly in Case 1. In future, conducting necropsies on fresh rather than frozen possums, and performing in-situ PCR or immunohistochemistry with an MU antibody on tissue blocks, may allow more accurate evaluation of the systemic distribution and pathogenesis of MU in possums.

This case series provides an important first step for integrating animal welfare considerations into BU research and management, however, more research, development and educational outreach are needed. Longitudinal studies involving repeated sampling of individual possums and assessment of a range of behavioural, immunological and other factors would provide a deeper understanding of the disease progression and welfare impacts of BU over time. Other knowledge gaps include the source(s) of MU infection; incubation periods and fatality rates in naturally infected animals; risk and protective factors for MU infection and clinical disease; and disease transmission dynamics both within and between possum populations, and the mechanisms and extent to which zoonotic and/or vector-borne transmission to humans occurs.

## Conclusion

This case series highlights the severity of cutaneous BU lesions that can occur in Australian possums and discusses the additional health and welfare impacts of severe disease that may be experienced by these animals. Our findings underscore the need for research into the broader health and welfare impacts of BU on possum individuals and populations as well as other wildlife species, and for validated interventions that can safeguard individual wellbeing and collective protection against this important zoonotic disease in endemic areas of Australia.

## Acknowledgments

Funding for this study was provided by the Australian National Health and Medical Research Council (NHMRC) grant GNT1196396. We would like to thank Dr Tristan Rich, Samantha Lovett and the staff of Lort Smith Animal Hospital; the veterinary staff of the former U-Vet Werribee Animal Hospital (The University of Melbourne); and Jessica Haining and other Anatomic Pathology

lab staff at the Melbourne Veterinary School who were involved in the collection, transport and storage of possum cadavers for our study. We also thank Faye Docherty and Mirjana Bogeski for histology and histochemistry. We would like to acknowledge the tireless advocacy of Natalie J. Russell on behalf of the Essendon possums, and are grateful to Dr Sarah Frith, Katherine Whittaker, Dr Liz Dobson, Dr Richard Ploeg and Dr Smitha Georgy for their assistance with various aspects of these cases.

### Conflicts of interest and sources of funding

The authors declare that the research was conducted in the absence of any commercial or financial relationships that could be construed as a potential conflict of interest.

### References

- Mitchell PJ, Jerrett IV, Slee KJ. Skin ulcers caused by *Mycobacterium ulcerans* in koalas near Bairnsdale, Australia. *Pathology* 1984;16:256–260. <https://pubmed.ncbi.nlm.nih.gov/6514393/>.
- Van Zyl A, Daniel J, Wayne J et al. *Mycobacterium ulcerans* infections in two horses in south-eastern Australia. *Aust Vet J* 2010;88:101–106. <https://doi.org/10.1111/j.1751-0813.2009.00544.x>.
- O'Brien CR, McMillan E, Harris O et al. Localised *Mycobacterium ulcerans* infection in four dogs. *Aust Vet J* 2011;89:506–510. <https://doi.org/10.1111/j.1751-0813.2011.00850.x>.
- WHO. WHO Meeting on Buruli ulcer and other skin NTDs- Final report, 25–27 March 2019. World Health Organization (WHO), Geneva, Switzerland. 2019: 212. Available at: <https://apps.who.int/iris/rest/bitstreams/1257101/retrieve>.
- DH. Victoria, local public health areas and local government areas surveillance summary report. Available at: <https://www.health.vic.gov.au/infectious-diseases/local-government-areas-surveillance-report> 2023. Retrieved 7/12/2023.
- Tai AYC, Athan E, Friedman ND et al. Increased severity and spread of *Mycobacterium ulcerans*, southeastern Australia. *Emerg Infect Dis* 2018;24:58–64. <https://doi.org/10.3201/eid2401.171070>.
- Fyfe JAM, Lavender CJ, Handasyde KA et al. A major role for mammals in the ecology of *Mycobacterium ulcerans*. *PLoS Negl Trop Dis* 2010;4:e791. <https://doi.org/10.1371/journal.pntd.0000791>.
- Johnson PDR, Azuolas J, Lavender CJ et al. *Mycobacterium ulcerans* in mosquitoes captured during outbreak of Buruli ulcer, southeastern Australia. *Emerg Infect Dis* 2007;13:1653–1660. <https://doi.org/10.3201/eid1311.061369>.
- Mee PT, Buultjens AH, Oliver J et al. Mosquitoes provide a transmission route between possums and humans for Buruli ulcer in southeastern Australia. *Nat Microbiol* 2023;9:377–389. <https://doi.org/10.1101/2023.05.07.539718>.
- O'Brien CR, Handasyde KA, Hibble J et al. Clinical, microbiological and pathological findings of *Mycobacterium ulcerans* infection in three Australian possum species. *PLoS Negl Trop Dis* 2014;8:e2666. <https://doi.org/10.1371/journal.pntd.0002666>.
- Jackson S. *Australian mammals: biology and captive management*. Melbourne, Australia, CSIRO Publishing, 2003;96. [https://www.publish.csiro.au/ebook/chapter/9780643090705\\_13](https://www.publish.csiro.au/ebook/chapter/9780643090705_13).
- WHO. *Treatment of Mycobacterium ulcerans disease (Buruli ulcer)- guidance for health workers*. Geneva, Switzerland, World Health Organization, 2012;76. <https://www.who.int/publications/i/item/9789241503402>.
- Ban S, Cox-Whitton K, Grillo T. *Mycobacterium ulcerans* in a ringtail possum in a new location. *Anim Health Surveill Q* 2020;25(3):13–17. <http://www.sciquest.org.nz/elibrary/edition/8052>.
- Mellor DJ, Beausoleil NJ, Littlewood KE et al. The 2020 five domains model: including human–animal interactions in assessments of animal welfare. *Animals* 2020;10:1870. <https://doi.org/10.3390/ani10101870>.
- Vogelnest L. Marsupialia (Marsupials). In: Miller RE, Fowler ME, editors. *Fowler's Zoo and Wild Animal Medicine*. Elsevier, St Louis, Missouri, 2015; 255–274.
- Marion E, Song OR, Christophe T et al. Mycobacterial toxin induces analgesia in Buruli ulcer by targeting the angiotensin pathways. *Cell* 2014;157:1565–1576. <https://pubmed.ncbi.nlm.nih.gov/24949969/>.
- O'Brien DP, Friedman ND, McDonald A et al. Clinical features and risk factors of oedematous *Mycobacterium ulcerans* lesions in an Australian population: beware cellulitis in an endemic area. *PLoS Negl Trop Dis* 2014;8:e2612. <https://doi.org/10.1371/journal.pntd.0002612>.
- Rutherford KMD. Assessing pain in animals. *Anim Welf* 2002;11:31–53. <https://doi.org/10.1017/s0962728600024301>.
- O'Brien DP, Murrie A, Meggyesy P et al. Spontaneous healing of *Mycobacterium ulcerans* disease in Australian patients. *PLoS Negl Trop Dis* 2019;13: e0007178. <https://doi.org/10.1371/journal.pntd.0007178>.
- Xu RW, Stinear TP, Johnson PDR et al. Possum bites man: case of Buruli ulcer following possum bite. *Med J Aust* 2022;216:452–453. <https://doi.org/10.5694/mja2.51505>.
- Wildlife Victoria. Ulcerative lesions in Victorian possums, 2013–2022 [unpublished data]. 2023. Available at: [www.wildlifevictoria.org.au/](http://www.wildlifevictoria.org.au/).
- DEECA. Victorian Wildlife Rehabilitation Guidelines. Available at: <https://www.wildlife.vic.gov.au/victorian-wildlife-rehabilitation-guidelines/victorian-wildlife-rehabilitation-guidelines> 2023. Retrieved 10/9/2023.
- Yotsu RR, Richardson M, Ishii N. Drugs for treating Buruli ulcer (*Mycobacterium ulcerans* disease) (Review). *Cochrane Database Syst Rev*. 2018;8:CD012118. <https://doi.org/10.1002/14651858.cd012118.pub2>.
- Johnson R, Hemsley S. Gliders and possums. In: Vogelnest L, Woods R, editors. *Medicine of Australian mammals*. CSIRO, Clayton South, Australia, 2009. [www.publish.csiro.au](http://www.publish.csiro.au).
- Agriculture Victoria. Code of practice for the welfare of wildlife during rehabilitation. In: Victoria AW, editor. *Agriculture Victoria*, Canberra, Australia, 2020. <https://agriculture.vic.gov.au/livestock-and-animals/animal-welfare-victoria/poact-1986/victorian-codes-of-practice-for-animal-welfare/code-of-practice-for-the-welfare-of-wildlife-during-rehabilitation>
- Miguel E, Grosbois V, Caron A et al. A systemic approach to assess the potential and risks of wildlife culling for infectious disease control. *Commun Biol* 2020;3:3. <https://doi.org/10.1038/s42003-020-1032-z>.
- Mysterud A, Rauset GR, Van Moorter B et al. The last moves: the effect of hunting and culling on the risk of disease spread from a population of reindeer. *J Appl Ecol* 2020;57:2509–2518. <https://doi.org/10.1111/1365-2664.13761>.
- Tompkins DM, Ramsey DSL, Cross ML et al. Oral vaccination reduces the incidence of tuberculosis in free-living brushtail possums. *Proc Royal Soc B* 2009;276:2987–2995. <https://doi.org/10.1098/rspb.2009.0414>.
- Muhi S, Stinear TP. Systematic review of *M. bovis* BCG and other candidate vaccines for Buruli ulcer prophylaxis. *Vaccine* 2021;39:7238–7252. <https://www.sciencedirect.com/science/article/pii/S0264410X21007003>.
- O'Brien DP, Blasdel K, Muhi S et al. Is BCG vaccination of possums the solution to the Buruli ulcer epidemic in south-eastern Australia? *Med J Aust* 2023; 219:520–522. <https://doi.org/10.5694/mja2.52096>.

### Supporting information

Additional Supporting Information may be found in the online version of this article at the publisher's web-site: <http://onlinelibrary.wiley.com/doi/10.1111/avj.13360/supinfo>.

**Data S1. Supplementary document 1.** The customised possum necropsy record sheet devised for use in the Buruli ulcer surveillance studies.

(Accepted for publication 3 July 2024)