



Minerva Access is the Institutional Repository of The University of Melbourne

Author/s:

Galea, M;Messina, A;Hill, B;Cooper, C;Hahn, J;van Zyl, N

Title:

Reanimating hand function after spinal cord injury using nerve transfer surgery

Date:

2020-03

Citation:

Galea, M., Messina, A., Hill, B., Cooper, C., Hahn, J. & van Zyl, N. (2020). Reanimating hand function after spinal cord injury using nerve transfer surgery. *Advances in Clinical Neuroscience & Rehabilitation*, 20 (2), pp.17-19. <https://doi.org/10.47795/cqzf2655>.

Persistent Link:

<https://hdl.handle.net/11343/325388>

License:

[CC BY](#)

Mary Galea, AM FAHMS, B App Sc (Physio), BA, PhD

is a Professorial Fellow at the Department of Medicine, University of Melbourne. She is a Physiotherapist and Neuroscientist whose research programme includes both laboratory-based and clinical projects with the overall theme of understanding the control of voluntary movement by the brain, and factors that promote recovery following nervous system injury.



Aurora Messina, BSc (Hons), PhD

is a Senior Research Fellow at the Department of Medicine and the Peter Doherty Institute, University of Melbourne, Australia. She is a morphologist with an interest in the fields of nerve injury and regeneration, and tissue engineering.



Bridget Hill, MCSP, Postgrad Dip (Musc), PhD

is a Physiotherapist and Early Career Researcher having been awarded her PhD in 2017. She has wide research interests including the development, evaluation and use of outcome measures particularly for the upper limb, and the management of brachial plexus and spinal cord injury.



Catherine Cooper, B App Sc (OT)

is an experienced Occupational Therapist in the field of rehabilitation and spinal cord injury. She works with a team of plastic and reconstructive surgeons and co-ordinates the Upper Limb Programme embedded within the Victorian Spinal Cord Service, which has a focus on reconstructive hand surgery in tetraplegia.



Jodie Hahn, B Occ Ther (Hons), B Ergonomics

is an Occupational Therapist who specialises in upper limb rehabilitation post-cervical spinal cord injury. She has been involved in a number of projects and publications related to understanding and maximising patient outcomes and experience of nerve transfers for upper limb re-animation for people with tetraplegia.



Natasha van Zyl, MB ChB, FRACS

is a Plastic and Reconstructive Surgeon based at Austin Health in Melbourne, Australia and is a Surgeon for the Victorian Spinal Cord Service, which offers tendon and nerve transfer surgery to improve upper limb function in tetraplegia.



Reanimating hand function after spinal cord injury using nerve transfer surgery

Key Take Home Messages

- Loss of hand and arm function is a devastating consequence of cervical spinal cord injury
- Surgical approaches to reconstruct arm and hand function in people with tetraplegia include tendon transfer and nerve transfer surgery
- Nerve transfer surgery can be used in combination with tendon transfer surgery to increase the options for upper limb reconstruction and the number of functions that can be restored
- Nerve transfer surgery results in a softer more pliable hand, which facilitates use of electronic devices
- Further investigations of longer-term outcomes, patient selection, and optimal timing of surgery are needed

Abstract

Loss of arm and hand function is a devastating consequence of cervical spinal cord injury. Tendon transfer surgery has traditionally been used to restore key functions including elbow extension, wrist extension and grasp and pinch. The more recent development of nerve transfer surgery enables direct restoration of voluntary control of these functions. While both types of surgery are safe and effective, nerve transfer surgery results in a more open, flexible and natural hand, with more subtle control for a range of activities of daily living.

Spinal cord injury (SCI) leads to severe lifelong impairment of sensorimotor function. The annual crude incidence rates of traumatic SCI vary from 12.1 per million to 57.8 per million, with leading causes being motor vehicle accidents, falls, violence and sports activities.¹ There is a bimodal distribution, with one peak in the age group 15 to 29 years, and the second in the age group above 40 years of age.

Age at injury, and injuries caused by falls have increased over time.² Over half of the injuries affect the cervical spinal cord,¹ leading to tetraplegia, that is, some degree of paralysis in all four limbs as well as the trunk. In tetraplegia, the degree of impairment of the upper limb, including the hand, will vary depending on the level and completeness of injury.

Loss of function is greater the higher the level of injury. For example, individuals with C6 level of injury are able to move their arms and extend their wrists, but have little or no voluntary use of their hands. Injuries above C6 result in the inability to actively extend the elbow to reach for objects. Loss of hand and arm function is one of the most devastating consequences of spinal cord injury because of the severe impact on activities of daily living (ADL) and subsequent dependence on others, loss of privacy and loss of vocational opportunities. Loss of the use of one's hand results in the inability to grasp and manipulate objects of different sizes, heaviness and textures, inability to point and gesture, and inability to use common everyday implements (e.g. toothbrush, cutlery, pens). Therefore, people with tetraplegia report that limited hand and arm function is often more profoundly disabling and of greater importance than their inability to walk.^{3,4}

The key movements for improving independence in tetraplegia are elbow extension for reach and pushing a manual wheelchair, wrist extension, and hand opening and closing for grasp, pinch and release. Different treatment strategies have been directed to improving or restoring these movements, as even modest improvements in arm and hand function can have a substantial impact on potential for employment, independence and quality of life.

Rehabilitation has traditionally involved strengthening muscles above the level of injury and, in recovering muscle groups, maintaining range of movement in the upper limb joints, providing assistive technology, adaptive

Table 1: Nerve transfers commonly used by the authors for upper limb re-animation in mid-cervical spinal cord injury (C5, 6, 7)

Function restored	Donor nerve(s)	Recipient nerve(s)
Elbow extension	Teres minor	Triceps
	Teres minor and motor portion of posterior division of axillary nerve	Triceps
	Motor portion of posterior division of axillary nerve	Triceps
Wrist extension	Supinator	ECRB
	Supinator	PIN
	Fascicle of anterior division of axillary nerve	Triceps
Finger/thumb extension and thumb abduction	Supinator	AIN
	ECRB	AIN
	Supinator	AIN
	Fascicle to pronator teres	FDS

ECRB: Extensor carpi radialis brevis; PIN: Posterior interosseous nerve; AIN: anterior interosseous nerve; FDS: Flexor digitorum superficialis.

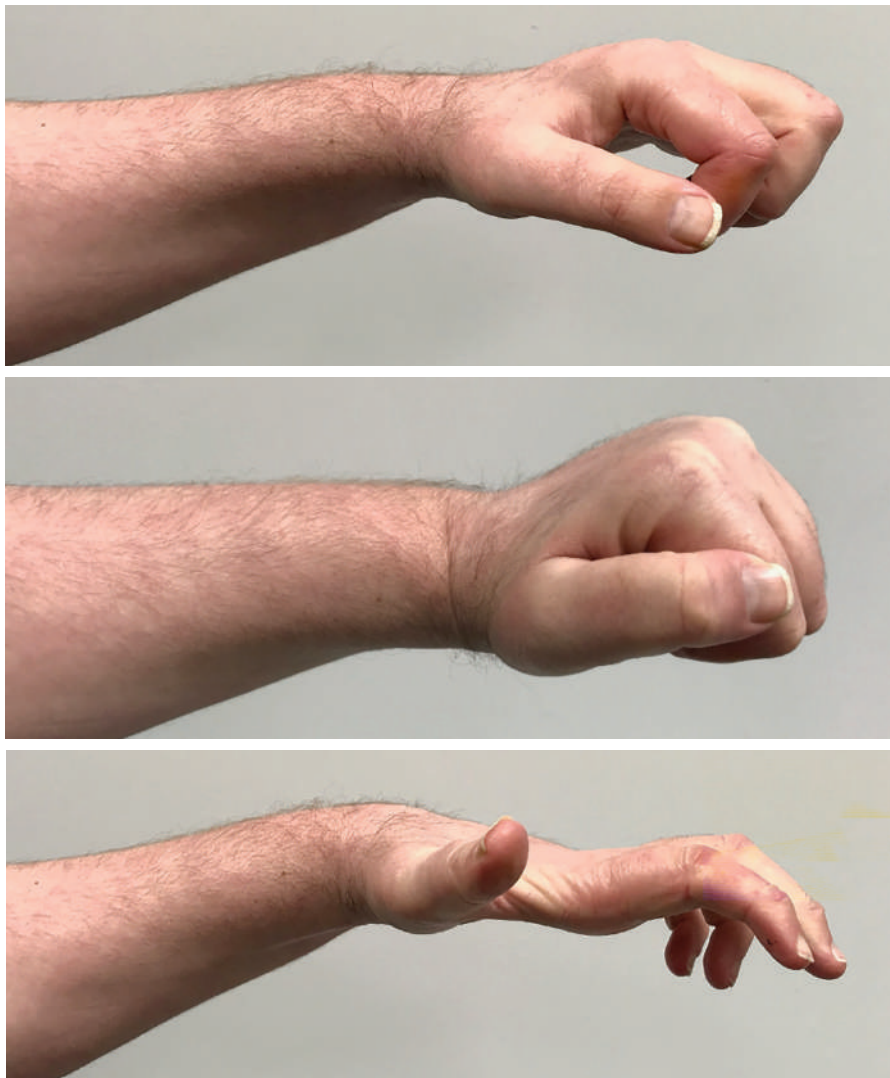


Figure 1. Hand function in a 35 y.o. male, spinal cord injury level C6, AIS B, 22 months after ECRB to AIN transfer and supinator to PIN transfer. (A) Hand at rest. (B) Hand closed in active grasp and key pinch. (C) hand open in active thumb and finger extension and thumb abduction

AIS: American Spinal Injury Association (ASIA) Impairment Scale

equipment and tools where appropriate, and training a repertoire of compensatory strategies to accomplish tasks. Among the compensatory strategies is the tenodesis grasp, which, in individuals who have voluntary wrist extension, provides a means of hand opening and closing through passive forces developed in the long finger and thumb flexors during wrist flexion and extension. Encouraging a tenodesis grasp involves improving or supporting active wrist extension, and reducing the resting length of the long flexors of the fingers and thumb, so that the fingers passively flex and the thumb approximates the fingers when the wrist is extended. An effective tenodesis grasp only enables the picking up of light objects as no power is generated.

Tendon transfer surgery to reconstruct arm and hand function in people with tetraplegia has a long and successful history. This type of surgery involves the transfer of the tendon from a functioning muscle to a new site, with the goal of reproducing lost movement at a specific joint, and reducing reliance on adaptive equipment.⁵ Tendon transfers redistribute expendable, non-paralysed muscle function to that of paralysed muscles to restore a number of key functions including elbow extension, wrist extension and grasp and pinch.⁶

More recent surgical developments include nerve transfer surgery.^{7,8} First developed as a surgical technique to reconstruct the brachial plexus or peripheral nerves after injury, nerve transfer surgery is now being applied to reanimate hand function in people with tetraplegia. Where a single tendon transfer can only be used to restore one function and is essentially a compensatory strategy, nerve transfers can allow for direct reanimation (restoration of voluntary control) of more than one muscle. The process involves taking working “donor” nerves from expendable muscles not affected by the spinal injury and coapting them to the “recipient” nerves of paralysed muscles. For example, to restore finger and thumb extension, the nerve(s) to the supinator muscle can be transferred to the posterior interosseous nerve. Supination of the forearm is still possible as it is one of the functions of the biceps muscle. Nerve transfer surgery can be used in combination with tendon transfer surgery to increase the options for upper limb reconstruction and the number of functions that can be restored. However, there are nerve transfer options for people with higher levels of SCI where tendon transfers are not possible.

Identifying the most appropriate candidates for such procedures requires a thorough knowledge of the functional anatomy of the upper limb and a detailed pre-operative assessment preferably by an interdisciplinary team. Evaluation of the range of movement, muscle strength and presence of spasticity are important components in determining the surgical procedure most appropriate for a specific patient, along with hand

dominance and tailored functional goals. The pattern of recovery post-injury and time since injury also influence decision making. Potential candidates for surgery should be re-assessed at appropriate intervals up to the day of surgery to track recovery, and potential surgical procedures should be delayed or reconsidered if significant natural recovery is apparent.

As there may be direct damage to the motor neurons within the injury zone resulting in a lower motor neuron injury, characterising the pattern of upper and lower motor neuron injury has implications for nerve transfer surgery. Lower motor neuron injury in the donor nerve may compromise its utility and, in the recipient nerve, it has implications for the timing of nerve transfer surgery, with surgery preferable before 12 months post-SCI to maximise outcomes. Assessing the relative proportions of upper and lower motor neuron injury in recipient nerves is not straightforward and the degree of lower motor neuron injury may vary considerably. In general, a muscle's response to surface electrical stimulation provides a good indication of the health of the peripheral nerve. Traditional motor and sensory nerve conduction studies combined with electromyography can demonstrate characteristics of impaired motor neuron function such as slowed motor conduction, reduced amplitude of compound action potentials, and fibrillations.⁹ Intraoperative stimulation can more directly examine the conduction along the nerve. However, neurophysiological techniques do not provide a complete picture of peripheral nerve health.

Direct assessment of peripheral nerves after SCI, through biopsies taken intraoperatively, has shown that the majority of both donor and recipient nerves sampled had morphological abnormalities. The most common abnormalities were myelin thickening and folding, demyelination, inflammation and a reduction in density of large myelinated axons. Other changes noted were a thickened perineurium, oedematous endoneurium and Renshaw bodies.¹⁰

Numerous single case reports describing new surgical procedures or small retrospective case series have shown that nerve transfer surgery is feasible, safe, and effective. However, the reporting quality of these studies is not high, with lack of clarity regarding inclusion and exclusion criteria and consecutive recruitment. The Medical Research Council strength grading,¹¹ with videotapes included as supplementary material, has been the major approach used for measurement of outcomes rather than standardised functional outcome measures of hand function (e.g. the Grasp-Release Test¹²) or of independence. Rigorous prospective studies of nerve transfer surgery using standardised outcome measures in this population are lacking, as are reports of outcomes for combinations of multiple nerve and tendon transfer surgeries.

Our research group recently published the largest prospective, consecutive case series of nerve transfers (total of 59 procedures in 27 limbs) undertaken at a single centre in the tetraplegic population to date.¹³ In ten of the participants, nerve transfers were performed

in one hand to restore grasp and pinch while tendon transfers were performed on the other. Assessments of muscle power, grasp and pinch strength, upper limb function, independence in activities of daily living, and hand opening ability, were undertaken before surgery, and at 12 and 24 months post-surgery. Where prior to surgery none of the participants were able to register forces in grasp and pinch dynamometry tests, at the 24 month time-point there were significant improvements in their grasp and pinch strength, ability to pick up and release objects of different sizes in tests of hand function, and in their independence.

The outcomes in hands where grasp and pinch had been reconstructed with nerve transfers were similar to those reconstructed with tendon transfers, however the appearance of the hands was different. Using nerve transfers to re-animate grasp and pinch results in a more open, flexible and natural hand, with more subtle control for finer tasks and social interactions.

While nerve transfer surgery has been shown to be safe and effective and to have results comparable to those of tendon transfers, further research is needed. Areas requiring further investigation include: the longer-term outcomes of surgery, both functionally and from the individual's perspective; how to maximise an individual's use of the improved function in daily activities; and how an understanding of the health of donor and recipient nerves can be used in patient selection, predicting outcomes and determining the optimal timing of surgery.

REFERENCES

1. Van den Berg MEL, Castellote JM, Mahillo-Fernandez I, de Pedro-Cuesta J. *Incidence of spinal cord injury worldwide: a systematic review*. *Neuroepidemiol* 2010;234:184-192. <https://doi.org/10.1159/000279335>
2. Chen Y, He Y, DeVivo MJ. *Changing demographics and injury profile of new traumatic spinal cord injuries in the United States 1972-2014*. *Arch Phys Med Rehabil* 2016;97:1610-1619. <https://doi.org/10.1016/j.apmr.2016.03.017>
3. Snoek GJ, Iljerman MJ, Hermens HJ, Maxwell D, Biering-Sorensen F. *Choice-based evaluation of the improvement of upper-extremity function compared with other impairments in tetraplegia*. *Arch Phys Med Rehabil* 2005;86:1623-1630. <https://doi.org/10.1016/j.apmr.2004.12.043>
4. Anderson KD. *Targeting recovery- priorities of the SCI population*. *J Neurotrauma* 2004;21:1371-1383. <https://doi.org/10.1089/neu.2004.21.1371>
5. Hentz VR, Leclercq C. *Surgical Rehabilitation of the Upper Limb in Tetraplegia*. WB Saunders. 2002
6. Hamou C, Shah NR, DiPonio L, Curtin CM. *Pinch and elbow extension restoration in people with tetraplegia: a systematic review of the literature*. *J Hand Surg Am* 2009;34:692-699. <https://doi.org/10.1016/j.jhnsa.2008.12.002>
7. Cain SA, Gohritz A, Fridén J, van Zyl N. *Review of upper extremity nerve transfer in cervical spinal cord injury*. *J Brachial Plex Peripher Nerve Inj* 2015;10:e34-e42. <https://doi.org/10.1055/s-0035-1558427>
8. Ledgard JP, Geschwind CR. *Evidence for efficacy of new developments in reconstructive upper limb surgery for tetraplegia*. *J Hand Surgery* 2020; 45:43-50. <https://doi.org/10.1177/1753193419886443>
9. Riley DA, Burns AS, Carrion-Jones M, Dillingham TR. *Electrophysiological dysfunction in the peripheral nervous system following spinal cord injury*. *PM R* 2011;3:419-425. <https://doi.org/10.1016/j.pmrj.2010.12.021>
10. Messina A, Van Zyl N, Weymouth M, Flood S, Nunn A, Cooper C, Hahn J, Galea MP. *Morphology of donor and recipient nerves utilized in nerve transfer surgery to restore upper limb function after cervical spinal cord injury*. *Brain Sci* 2016;6:42. <https://doi.org/10.3390/brainsci6040042>
11. Seddon HJ. *Peripheral nerve injuries. Medical Research Council special report series no 282*. London: Her Majesty's Stationery Office. 1954
12. Wuolle KS, Van Doren CL, Thrope GB, Keith MW, Peckham PH. *Development of a quantitative hand grasp and release test for patients with tetraplegia using a hand neuroprosthesis*. *J Hand Surg* 1994;19A:209-218. [https://doi.org/10.1016/0363-5023\(94\)90008-6](https://doi.org/10.1016/0363-5023(94)90008-6)
13. Van Zyl N, Hill B, Cooper C, Hahn J, Galea MP. *Expanding traditional tendon-based techniques with nerve transfers for the restoration of upper limb function in tetraplegia: a prospective case series*. *Lancet* 2019; 394:565-575. [https://doi.org/10.1016/S0140-6736\(19\)31143-2](https://doi.org/10.1016/S0140-6736(19)31143-2)

Correspondence to:

Professor Mary Galea,
Department of Medicine (Royal Melbourne Hospital),
The University of Melbourne, 4th Floor,
Clinical Sciences Building, Royal Melbourne Hospital, Parkville, Victoria 3010, Australia.
E. m.galea@unimelb.edu.au

Conflict of interest statement:

Our study on evaluation of nerve transfer surgery was funded by the Institute for Safety, Compensation, and Recovery Research Australia

Provenance and peer review:

Submitted and externally reviewed.

Date first submitted: 10/6/20

Date submitted after peer review: 27/1/21

Acceptance date: 28/1/21

To cite: Galea M, Messina A, Hill B, Cooper C, Hahn J, van Zyl N. *Adv Clin Neurosci Rehabil* 2021;20(2):17-19

This is an open access article distributed under the terms & conditions of the Creative Commons Attribution license <http://creativecommons.org/licenses/by/4.0/>

<https://doi.org/10.47795/CQZF2655>