



Minerva Access is the Institutional Repository of The University of Melbourne

Author/s:

Niu, X;Di Carlo, G;Cornelis, MA;Cattaneo, PM

Title:

Three-dimensional analyses of short- and long-term effects of rapid maxillary expansion on nasal cavity and upper airway: A systematic review and meta-analysis

Date:

2020-08-01

Citation:

Niu, X., Di Carlo, G., Cornelis, M. A. & Cattaneo, P. M. (2020). Three-dimensional analyses of short- and long-term effects of rapid maxillary expansion on nasal cavity and upper airway: A systematic review and meta-analysis. *Orthodontics and Craniofacial Research*, 23 (3), pp.250-276. <https://doi.org/10.1111/ocr.12378>.

Persistent Link:

<https://hdl.handle.net/11343/286969>

Three-dimensional analyses of short- and long-term effects of rapid maxillary expansion on nasal cavity and upper airway: a systematic review and meta-analysis

Running Title: REVIEW OF UPPER AIRWAY CHANGES AFTER RME

Xiaowen Niu^a, Gabriele Di Carlo^b, Marie A Cornelis^c, Paolo Maria Cattaneo^c

^aPhD student, Section of Orthodontics, Department of Dentistry and Oral Health, Health, Aarhus University, Aarhus, Denmark

^bPostdoctoral Fellow, Department of Oral and Maxillofacial Sciences, Unit of Pediatric Dentistry, Sapienza University of Rome, Rome, Italy; Section of Orthodontics, Department of Dentistry and Oral Health, Health, Aarhus University, Aarhus, Denmark

^cAssociate professor, Section of Orthodontics, Department of Dentistry and Oral Health, Health, Aarhus University, Aarhus, Denmark

Address correspondence to:

Paolo M. Cattaneo, Section of Orthodontics, Department of Dentistry and Oral Health, Health, Aarhus University, Vennelyst Boulevard 9, DK-8000 Aarhus C, Denmark

E-mail: paolo.cattaneo@dent.au.dk

Telephone +45 87167459

Acknowledgements:

This is the author manuscript accepted for publication and has undergone full peer review but has not been through the copyediting, typesetting, pagination and proofreading process, which may lead to differences between this version and the [Version of Record](#). Please cite this article as [doi: 10.1111/OCR.12378](https://doi.org/10.1111/OCR.12378)

This article is protected by copyright. All rights reserved

We thank Janne Lytoft Simonsen, research librarian of Aarhus University, for help during the computerized searches of the databases; Rosamaria Fastuca, who was contacted for clarifications, for answering our questions; and State Scholarship Fund from China Scholar Council (201609110098).

Author Manuscript

Abstract

Introduction: The purpose of this systematic review was to evaluate the three-dimensional (3D) changes occurring at short- and long-term follow-up after rapid maxillary expansion (RME) in nasal cavity (NC) and upper airway (UA) in growing patients.

Methods: A literature search up to July 1st, 2019 was performed. Randomized and non-randomized clinical trials and cohort studies comparing the effects of RME in a pediatric population using 3D analyses based on computed tomography (CT), cone-beam CT, and MRI were included. The risks of bias of the included studies were assessed using the Cochrane Collaboration's risk of bias tool, the GRADE approach, and a customized tool. The random-effects meta-analyses of the mean differences and 95% confidence intervals of NC and UA volume changes were carried out, followed by subgroup analyses.

Results: Twenty-seven studies were included, with 18 selected for quantitative synthesis. Immediately after expansion, the nasopharynx and oropharynx increased significantly. After three months retention, only the NC and nasopharynx showed a significant volume increase. Two studies mentioned the use of a sleep disordered breathing questionnaire and one study reported the difference before and after RME. None of the 27 articles included assessed the correlation between the skeletal widening and NC or UA volume changes after RME.

Conclusions: The existing evidence confirmed only the short-term positive effect of RME on expanding the volume of the NC and the upper part of the UA. However, long-term stability could not be sustained.

Article type : Review Article

Three-dimensional analyses of short- and long-term effects of rapid maxillary expansion on nasal cavity and upper airway: a systematic review and meta-analysis

Abstract

Introduction: The purpose of this systematic review was to evaluate the three-dimensional (3D) changes occurring at short- and long-term follow-up after rapid maxillary expansion (RME) in nasal cavity (NC) and upper airway (UA) in growing patients.

Methods: A literature search up to July 1st, 2019 was performed. Randomized and non-randomized clinical trials and cohort studies comparing the effects of RME in a pediatric population using 3D analyses based on computed tomography (CT), cone-beam CT, and MRI were included. The risks of bias of the included studies were assessed using the Cochrane Collaboration's risk of bias tool, the GRADE approach, and a customized tool. The random-effects meta-analyses of the mean differences and 95% confidence intervals of NC and UA volume changes were carried out, followed by subgroup analyses.

Results: Twenty-seven studies were included, with 18 selected for quantitative synthesis. Immediately after expansion, the nasopharynx and oropharynx increased significantly. After three months retention, only the NC and nasopharynx showed a significant volume increase. Two studies mentioned the use of a sleep disordered breathing questionnaire and one study reported the difference before and after RME. None of the 27 articles included assessed the correlation between the skeletal widening and NC or UA volume changes after RME.

Conclusions: The existing evidence confirmed only the short-term positive effect of RME on expanding the volume of the NC and the upper part of the UA. However, long-term stability could not be sustained.

Keywords: Three-dimensional analyses; Nasal cavity; Upper airway; Meta-analysis

1. Introduction

Maxillary transverse deficiency,¹ one of the most common skeletal alterations in the craniofacial region, is associated with several problems including esthetic issues (i.e. black corridors), crossbite, dental crowding, and functional disharmony (i.e. functional shift). Moreover, maxillary deficiency has been considered a possible anatomic etiological factor for the development of obstructive sleep apnea in children.^{2,3} Rapid maxillary expansion (RME) has been proven to be an effective technique to produce transverse skeletal effects on the maxilla by opening the mid-palatal suture, regardless of the type of palatal expander used.⁴

The next logical initiative would be to explore the effect of this treatment modality on the nasal cavity (NC) size, airway dimensions, and airway resistance. RME has been subjectively observed to improve nasal breathing and decrease NC resistance.^{5,6} The effects of RME on reducing nasal airway resistance were already established more than 40 years ago by Linder-Aronson and Aschan,⁷ as well as by Hershey et al.⁸ These findings were later on supported by Warren et al.,⁹ who reviewed the nasal airway after expansion and reported 45% (RME group) and 55% (surgically assisted RME group) increases in nasal cross-sectional areas (CSA). Although many studies have assessed the linear transverse dental and skeletal changes produced by maxillary expansion, the alterations do not necessarily reflect three-dimensional (3D) airway changes.^{10,11}

Changes in the nasal and pharyngeal airway spaces secondary to RME have been also extensively investigated using two-dimensional (2D) cephalometric radiographs, rhinomanometry,¹² and acoustic rhinometry (AR).¹³ Although cephalometric data were recorded based on a standardized technique, the various structural superimpositions and image magnifications did not consistently allow for accurate quantification of the changes.¹⁴ Moreover, UA morphology cannot be accurately expressed by single linear measurement on 2D cephalograms, while information regarding areas (cross-section) and volumes, as well as 2D measurements performed on various planes can only be determined based on 3D imaging modalities.^{14,15} The investigations on the effects of RME treatment conducted using 2D radiographic examinations are characterized by analytical limitations, preventing an accurate assessment of the structures. More recently, some studies have used 3D imaging modalities to report the effects of RME on nasal and UA volumes.

According to an overview to report the evidence provided by systematic reviews on UA performed by Bucci et al.,¹⁶ there are five systematic reviews on this topic,¹⁷⁻²¹ with only one including a meta-analysis.¹⁷ However, in two of the five reviews, papers dealing with rhinomanometry, AR, 2D, and 3D imaging data, were included,^{17,21} while one review only included papers dealing with AR.²⁰ Ortu et al reviewed the paper that evaluated the oropharynx changing measured by CBCT, while no quantitative data were provided.²² Di Carlo et al. reported the role of CBCT in RME and UA morphology, but no meta-analysis was performed.¹⁸ In the review by Buck et al, the treatment effects after retention are reported, though without specifying the duration of the retention period. The long-term effects were assessed only by Baratieri et al., yet a meta-analysis was not performed. Therefore, a new, more thorough systematic review with meta-analysis seems necessary.

2. Objectives

The objective of this systematic review and meta-analysis is to review and evaluate the evidence of area and volumetric changes that occur at short-, medium-, and long-term follow-up after RME treatment on NC and UA in growing patients. The review aims to answer the following questions: What are the effects of RME treatment on the airway volume of NC and UA in growing patients? Are these volumetric changes stable in the long-term?

3. Material and methods

3.1 Protocol and registration

This review follows the guidelines of the Cochrane Handbook for Systematic Reviews of interventions (<http://ohg.cochrane.org>). The Preferred Reporting Items for Systematic Reviews and Meta-Analyses (PRISMA) statement checklist was used as a template.²³ The protocol for this review was prepared a priori based on the PRISMA-P statement²⁴ and registered in the PROSPERO (CRD42017073106).

3.2 Eligibility criteria

The PICOS (population, intervention, comparison, outcome, study design) format was used to formulate the clinical question with defined inclusion and exclusion criteria (Supplementary Table 1). Randomized, non-randomized clinical trials and cohort studies that include growing patients comparing the short- and long-term effects of RME on NC and UA using 3D analyses based on CT, CBCT, and MRI were included. Case reports, patients with cleft lip and palate, animal studies, studies where RME was combined with other treatment modalities were excluded. In case the baseline scan (the scan before treatment start) was not available, the record was excluded. Moreover, studies where

the second scan was obtained more than 1 year after expansion, as well as studies where a 3D evaluation was not performed were also excluded.

3.3 Information sources, search strategy and study selection

Three bibliographic databases, MEDLINE (1946-), EMBASE (1947-), and Cochrane Central Register of Controlled Trials (CENTRAL), were initially searched on June 20th, 2017 and subsequently updated on July 1st, 2019. The search consisted of a combination of the following three keywords: 1) 3D evaluation; 2) rapid maxillary expansion; 3) nasal cavity and/or upper airway. Additionally, a manual search of the reference lists of relevant articles, unpublished literature in ClinicalTrials.gov or ISRCTN registry, and grey literature in OpenGrey (<http://www.opengrey.eu>) was also conducted. Studies were retrieved with no restriction regarding date, language, or publication status. Exact search strategies are reported in Supplementary Table 2. The search keywords and strategy were developed with the help of a senior research librarian at XXXXXX.

3.4 Data items and collection

Titles, abstracts, and articles were reviewed independently by two authors (X.N. and G.D.C.) using pre-determined forms. Disagreements were settled by consensus or by consulting a third reviewer (P.M.C) for adjudication. A translation was arranged for three articles in Chinese.²⁵⁻²⁷ The data extraction form was developed in Excel (Microsoft Corp., WA) in order to extract all the relevant information. The presence of a sleep disordered breathing (SDB) questionnaire before, after, and at retention was checked. The amount of expansion of the mid-palatal suture, and the relationship with airway changes were assessed. Other measured outcomes were volumetric and CSA changes in NC and in each part of the UA. Anatomically, the UA was divided into three parts defined on the sagittal images (Figure 1): nasopharynx, oropharynx, and hypopharynx.²⁸ The soft palate is then used to further subdivide the oropharynx into two sections: the retropalatal and the retroglottal regions. Missing or unclear information, as well as raw data, were requested from the corresponding authors of the included trials to eliminate baseline confounding factors and perform explorative analyses.

3.5 Risk of bias in individual studies and across the studies

The risk of bias of the included randomized trial was assessed using the Cochrane Collaboration's risk of bias tool.²⁹ The methodological adequacy of the included non-randomized trials was assessed with a customized tool that was developed specifically for this systematic review based on various appraisal tools (including the Newcastle-Ottawa scale) and empirical evidence of bias in orthodontic clinical research (Supplementary Table 3).³⁰⁻³² The mean quality of studies was rated as 'High risk' (total score <60%); 'Moderate risk' (60%–70%); or 'Low risk' (>70%).^{33,34} The methodological quality scores were calculated as percentages of the maximum achievable score (16 points) for each study.

To evaluate the quality of evidence for meta-evidences (i.e. the strength of clinical recommendations), the Grading of Recommendations Assessment, Development, and Evaluation (GRADE) was applied. The GRADEpro software (GRADEpro Guideline Development Tool, available online at grade.pro.org.) was used to summarize the quality of evidence. The assessment was based on the following considerations: risk of bias, inconsistency, indirectness, imprecision and publication bias. The evidence could be graded in four levels: very low, low, moderate, and high, which are used to grade the strength of recommendations in clinical practice.³⁵

3.6 Summary measures and approach to synthesis

According to the included studies reported, time-points were defined as: T0 = baseline, before expansion; T1 = immediately after expansion; T2 = three months after expansion; T3 = six months after expansion; and T4 = 12 months after expansion. The pooled outcomes for this systematic review were the overall evaluation of NC and UA volumes, as they represent the most clinically relevant outcomes for the patient. The result of volume change obtained at T1 and at T2, T3, or T4, were calculated as final minus initial NC or UA volume. Given the importance of the time elapsed from the expansion, the main results of the present meta-analyses were presented as subgroup analyses according to the specific time-points (T2, T3, and T4) when the measurements of the UA volume were performed.

3.7 Statistical analysis

We combined results from articles reporting mean differences with their corresponding 95% confidence intervals in all meta-analyses. We calculated pooled estimates of weighted mean differences (WMD) in outcomes and weight between intervention groups by using a random-effects model (DerSimonian-Laird method) to adequately account for the different treatment protocols, RME appliances, patient characteristics, NC and UA regions, and measurements techniques.

The Cochran Q test was used to assess heterogeneity between studies and the I^2 test was used to measure the proportion of inconsistency in the combined estimates due to between-study heterogeneity. I^2 values lower than 30% was regarded as representing low heterogeneity, values of 30% to 60% as representing moderate heterogeneity, and values of over 60% as substantial heterogeneity.³⁶

Publication bias (including small-study effects) was assessed with Egger's linear regression test. Sensitivity analyses were conducted to assess their robustness according to the study design (prospective vs. retrospective), imaging modalities, and the initial mean age.

All analyses were performed using Stata 15 CI (StataCorp, College Station, Texas, USA). A 2-tailed P value of 0.05 was considered significant for hypothesis testing, except for the test of heterogeneity and publication bias, where a P value of 0.01 was applied due to low power.

4. Results

4.1 Study selection

Three hundred and twenty-five titles were identified from the three bibliographic databases and 72 additional records were identified through other sources. After removal of duplicates, 229 titles were reviewed; 163 records were excluded based on the title and abstract. Out of the remaining 66 articles, 36 did not meet the eligibility criteria, leaving a final number of 30 published papers. The authors of three of the 30 eligible studies³⁷⁻³⁹ were contacted by email, and confirmed that the three studies used the same sample of patients and follow-up periods: therefore, they were treated as one single study, using the data of the publication that had the largest sample size for the meta-analyses.⁴⁰ The study characteristics of other two studies indicated that the same sample of patients was used (the authors were contacted by e-mail, but no replies were received): the two studies were treated as one single study, following the same procedure as above.^{41,42} One study was excluded from the quantitative synthesis because only the mean values of the difference between before and after treatment was provided.⁴³ After these processes, 27^{25-27,39,40,42-63} and 18 studies^{25-27,40,44,47,48,50,52,53,55,56,58-63} were included in the qualitative and quantitative synthesis, respectively (Figure 2).

4.2 Study characteristics

Descriptive data for the studies included are summarized in Tables 1a, 1b, and 1c. Regarding study design, one study was a randomized controlled clinical trial,²⁵ six were case-controlled studies (two of them were prospective trials,^{46,47} four were retrospective^{43,45,50,55}), and the other 20 articles were cohort studies.^{26,27,39,40,42,44,48,49,51-54,56-63}

A total of 666 patients (mean age range 7.1-14.7 years) were included (Table 1a), with 300 males (45%) and 340 females (51%), while one study didn't supply the gender information.⁴³ Six studies had a control group for a total of 127 subjects (age range 8.8-14.1 years).^{43,45-47,50,55} Four studies had comparison groups; two compared different types of appliances,^{58,62} while two compared different expansion protocols.^{25,63} Ethical approval was not mentioned in two studies.^{27,49} Two items were consistently reported in most of the studies: constricted maxilla and skeletal maturation. Fifteen studies included patients with a constricted maxilla.^{26,27,39,42,44,47,51-53,56-61} In addition, posterior crossbite was a requirement for 11 studies,^{26,27,39,40,42,44,48,51,53,56,59} while it was optional in three studies.^{52,58,61} Five studies reported skeletal maturity of the patients, according to the cervical vertebral maturation method,^{39,40,42,46,51} while one study used hand-wrist radiographs.⁴⁹

Regarding the treatment protocol, the expansion appliances included Hyrax-type expanders,^{25-27,43,45,47,48,50,53,60-63} Haas-type expanders,^{39,40,46,49} bonded Hyrax with occlusal coverage,^{52,59} a cast cap splint expander,⁴⁴ a butterfly-shaped expander,⁴² and a modified Biederman,⁵⁶ while two studies did

not specify the type of maxillary expander used.^{54,55} Additionally, three studies used more than one type of expander.^{51,57,58} Two studies used the same expander but followed a different activation protocol in 2 different groups of patients.^{25,63} The expansion protocol was well defined in all but five studies (Table 1b).^{54,55,57-59}

All studies recorded baseline measurements. With regard to the second time-point recorded, five studies evaluated the changes at T1,^{44,49,56-58} seven studies at T2,^{45,48,53,60-63} one study four months after expansion,⁵⁹ two studies at T3,^{51,52} and three studies at T4 (Table 1b).^{39,40,46} Seven studies did not mention a clear study endpoint.^{25,27,43,47,50,54,55} Only two studies evaluated changes immediately after expansion at another time point: at T2²⁶ or at T3.⁴² Among the five studies evaluating the changes at T1 only two evaluated the change in width of the midpalatal suture,^{37,44} two studies assessed the width of the NC and the palate, yet without reporting the association between these variables (Table 1b). No study reported the relationship between the increase in width of the midpalatal suture and the palate with the changes in UA.

The 3D images used in the studies were generated using medical CT, low-dose medical CT, and CBCT images. Nineteen studies supplied the scanning setting, including kVp, mA, field of view (FOV), voxel size, and scanning time.^{25,26,39,40,42,43,45,46,48,50-56,60,62,63} The software packages used for 3D reconstruction included Dolphin in 14 studies,^{25,27,43,46-50,56,58-60,62,63} Mimics in six studies,^{39,40,51-53,57} while the following software was used in only one study: OnDemand3D and ITK-SNAP,⁴⁴ OsiriX MD,⁴⁵ Dentascan,⁴² INTAGE,^{54,55} EzImplant,²⁶ and Ez3D2009 (Table 1c).⁶¹

One study mentioned the use of an unspecified SDB questionnaire before RME but no results were presented.⁴⁵ Another study reported using an ENT questionnaire, but no quantitative results were reported.⁴⁷ One study reported the use of a questionnaire originally developed to measure the impact of adenotonsillectomy: the score after RME was statistically lower than before the intervention.⁵⁶

The NC morphology was assessed using linear and volume measurements: Six studies evaluated the volume of NC, of which four evaluated the volume with clear boundary reference points,^{25,44,56,60} one without clear boundary reference points,⁵² and one used a formula to calculate the volume of NC.⁶¹ One measured the anterior NC (Table 1c).⁵³

4.3 Risk of bias in individual studies and across the studies

The RCT study had the lowest risk of bias (Table 2a). Among the non-randomized studies, one study showed low risk, nine showed moderate risk, and 16 studies demonstrated a high risk of bias (Table 2b). The domain associated with challenges were blinding of participants and investigators, as the use of RME appliance was obvious. In all, only one study reported that blinding was implemented, but how this was applied was not clear.⁴⁶ Other domains of concern with a high risk of bias were:

randomization, control group, follow-up, and dropouts description. Besides that, segmentation details were also at high risk of bias, with most of the studies none reporting the parameters used.

The GRADE scores (calculated with the GRADEpro software) are presented in Table 3c: Six outcomes were assessed and all the included studies are observational studies. NC and oropharynx volume changes after retention scored very low, oropharynx volume changes after expansion scored low, while the other three outcome scored Moderate. The main reasons for lowering the quality of the evidence were serious methodological limitations.

4.4 Results of individual studies, meta-analyses, and subgroup analyses

4.4.1 NC volume (Figures 3a and Supplementary Table 4)

The test for heterogeneity confirmed that meta-analyses of the outcomes at all time-points were reasonable. The NC volume does not show a significant change immediately post-expansion (increment of 1224 mm³, 95% CI: -278, 2725 mm³, P = 0.110), however, a significant increase was seen at post-retention (increment of 1604 mm³, 95% CI: 891, 2318 mm³, P =0.000). With regards to the subgroup analysis for post-retention data, patients treated with RME showed significant increases in volume at T2 (increment of 1596 mm³, 95% CI: 726-2466 mm³, P =0.000). Beyond 6 months after expansion, no significant changes were observed (T2-T0: P=0.050; T4-T0: P=0.084).

4.4.2 Nasopharyngeal volume (Figures 3b and Supplementary Table 4)

Pooled analysis of the five studies that assessed the volume change in nasopharynx showed a significant increase post-expansion (increased by 829 mm³, 95% CI: 441-1217 mm³, P = 0.000), with no significant heterogeneity (I², 27.6%; P=0.238). The data showed significant difference from T0 to T2 (increased by 492 mm³, 95% CI: 70-913 mm³, P = 0.022), with no heterogeneity (I², 28%; P = 0.224).

4.4.3 Oropharyngeal volume (Figures 3c and Supplementary Table 4)

There were 11 studies looking at the oropharyngeal volume. When the results of the post-expansion studies were pooled, a significant increase after expansion (increment of 1424 mm³, 95% CI: 197-2651 mm³, P=0.023) was observed. However, the difference between T2 and T0 failed to reach statistical significance (P=0.198). Statistically, heterogeneity was measured to be moderate (T0-T1: I², 56.5%; P=0.042; T0-T2: I², 36.2%; P=0.139).

4.4.4 Retropalatal volume (Supplementary Figures 1 and Supplementary Table 4)

When post-expansion changes in retropalatal volume were analyzed, no significant increase was found (P=0.393), with a significant heterogeneity (I², 72.8%; P=0.012). There was only one study reporting the retropalatal volume at T2, with no significant different changes.⁴⁸

4.4.5 Retroglossal volume (Supplementary Figures 2 and Supplementary Table 4)

Regarding the retroglossal volume, no significant changes were seen after expansion ($P=0.087$) and heterogeneity was substantial (I^2 , 68%; $P=0.077$).

Three studies assessed post-retention changes: in the two studies looking at T2 no statistical changes were found compared to T0 ($P=0.373$), with low heterogeneity (I^2 , 0.0%; $P=0.775$). The results of the T3 study was reported in a forest plot for consistency (mean volume increment of 1915 mm³).

4.4.6 Hypopharyngeal volume (Figures 3d and Supplementary Table 4)

For hypopharyngeal volume, only one study was included after expansion, yet, the outcomes are presented as forest plots for consistency. Two studies reported the volume change at T2, with low heterogeneity (I^2 , 0.0%; $P=0.652$). No significant changes were observed in hypopharyngeal volume after expansion ($P=0.657$) and after retention (T2, $P=0.842$).

4.4.7 Cross-section for UA (Supplementary Table 5)

Five studies observed the CSA for UA in ten outcome items.^{25-27,46,59} A meta-analysis was not performed, as only one outcome was observed in two studies. A significant increase for the CSA at the hard palatal level was reported in one study after expansion²⁷ ($P=0.007$) and one after retention⁴⁸ (T2, $P=0.000$), whilst Li et al. reported a significant increase at the nasopharynx level after expansion ($P=0.007$).²⁶ One study reported the minimal CSA for the UA, but no details were provided.⁴⁸

4.5 Additional analyses

Regarding the assessment of publication biases, seven outcomes regarding NC and UA volumes were analyzed, whilst five other outcomes were not analyzed as they were included only one study in each. According to Egger's test, no considerable indications of reporting biases could be found (Supplementary Table 6).

The only sensitivity analysis that could be performed was the assessment of the difference in the effects for study design (prospective study and retrospective study), 3D imaging method (CT and CBCT), and patient's initial age. Sensitivity analyses indicated that the results were relatively robust, as no P-value was lower than 0.05 (Supplementary Table 7). The other planned sensitivity analyses were not performed due to the small number and characteristics of the included studies.

5. Discussion

5.1 Summary of evidence

5.1.1 General information

This systematic review was performed in order to provide data on the influence of RME on NC and UA of patients during their growth and development period. In order to avoid omitting any data,

wide-ranging inclusion criteria were defined. There were no limitations with respect to the year of publication and language.

The synthesized outcome included the volume of NC and every part of the UA. This systematic review included papers with analyses based on 3D datasets, yet, some of the studies reported the CSA and 2D measurements, thus not taking full advantage of the 3D material. The outcome of the CSA of the UA was not included as sufficient data were not available (Supplementary Table 5). In the included studies, various CSA were measured and most of them increased after RME, while three outcomes measured at the nasopharynx level displayed a statistically significant increase.^{26,27,48} Only Zeng et al. reported that CSA in the nasopharynx and oropharynx decreased after RME.⁶¹ This decrease could be possibly explained as the outcomes represent the average of five measures in the nasopharynx and 10 parts in the oropharynx.

Only three studies reported the use of SDB questionnaire: two did not reported the changes in the scores that happened before, after and at retention; one reported quantitative data, but the questionnaire used was originally developed to measure the impact of adenotonsillectomy on life quality, thus some limitations might be present when measuring the effect of RME on SDB.

The skeletal effect of RME has been investigated.^{4,64-66} The relationship between the amount of skeletal expansion and the increase in volume of the NC and UA should be investigated, as it might be useful for treatment planning. However, in the 27 articles included in this review, the change in mid-palatal suture width was only assessed by two studies,^{42,49} yet the correlation between the skeletal widening and NC and UA volume changes after RME has not been reported.

The segmentation of the NC is very complicated, as there are four pairs of paranasal air sinuses connected to NC. Two studies were rejected for meta-analyses because in one study the volume of the NC was assessed including the paranasal sinuses,⁵⁵ whilst in the other, only the volume of the anterior NC was measured.⁵³ Three studies used references plane to separate the paranasal sinuses from the NC, yet no explanation for choosing them was provided; moreover, with this approach most parts of the ethmoid sinus were still included.^{25,44,60}

Regarding UA, different reference planes were used: palatal plane,^{50,55,56,59} Frankfort plane,^{27,40} or any plane constructed horizontal to the floor through a specific point.⁴⁴ To be able to compare the results, we aimed to standardize the way the results were presented, also by merging the different parts of the UA. Consequently, the UA was divided into three sections (i.e. nasopharynx, oropharynx, and hypopharynx) following the method first described by Schwab²⁸ and then confirmed by Guijarro-Martínez,⁶⁷ using the hard palate, soft palate, and epiglottis. Only volumetric measurements evaluated by 3D imaging technology were included: Two studies were excluded as the airway volume was

evaluated by AR, and not by assessing the volume on the available the CBCT-scans.^{11,68} When synthesizing the outcomes, we discovered that some conclusions of the article of Chang and co-workers²⁵ were not totally supported by their original data. For example, the 95% CI for the difference in the volume of the NC post-expansion (T2-T1) contains zero, meaning that the change after expansion is not statistically significant; yet, the authors reported that the NC volume increased significantly.

5.1.2 Outcome of the review, agreements, and disagreements with other studies or reviews

Several reviews evaluated NC and UA after RME treatment. Immediate changes in the NC width after RME were reported in a meta-analysis.⁶⁹ This was corroborated by the literature review by Ramires et al., reporting an enlarged NC width following maxillary expansion assessed on anteroposterior cephalometries.⁷⁰ In contrast to these findings, Gordon et al., who evaluated changes in NC by means of AR on minimal NC cross-sectional area and volume, stated that though “NC changes are expected, however, their clinical significance is questionable”.²⁰ The cephalometric-based systematic review of Lagravere et al.⁷¹ reported that a long-term increase in the NC transversal width was reported only in one study.⁷²

In the present review, an increase in NC volume was found to be associated with RME, although this effect seems to diminish with time. This seems to be confirmed by several authors investigating the advantages of RME with respect to improved nasal airflow in patients with nasal stenosis.^{8,54,73} It is important to notice that inconsistency in NC volume measurements were present across the studies, mostly due to the various definitions of NC boundary.

Baratieri et al. in their systematic review reported a long-term increase in the posterior nasal airway and total nasal flow after RME in growing children,²¹ with the increase in volume expected to be stable for at least 11 months. Recently, Buck et al. investigated the effects of RME on UA volume based on three diagnostic modalities and performed a meta-analysis for total airway volume: They concluded that RME is associated with a total volume increase of UA that is present up to 8 months of retention.⁷⁴

On the contrary, the chief finding of the present review was that the volume for both the NC and nasopharynx, increased significantly from T0 to T1, whilst no significant increase was observed for the lower part of the UA. At T2 and T3, due to the limited number of studies, we found no convincing evidence confirming that the observed volume increase could be attributed to RME. Further studies are thus required to confirm the long-term effects of RME. McNamara et al. speculated that the reduced effects of RME on airway below the NC could be attributed to soft-tissue adaptation.⁷⁵

5.1.3 Quality of the evidence

In the present review, 27 studies were included, among which only one was an RCT with an active control group,²⁵ presenting a low-to-moderate risk of bias. The quality assessment of the non-randomized studies revealed moderate to high risk of bias (9 and 16, studies respectively). In both randomized and non-randomized studies, blinding of participants and personnel was not possible as the use of RME appliances was obvious. According to GRADE, the quality of the outcomes were considered to be moderate to low.

The importance of a control group has been emphasized to decrease the influence of growth, especially when assessing long-term changes. Out of the 27 included studies, six included inactive control groups and four have active control groups. The chief reason of not including a matched control group could be related to the ethical issue of exposing subjects to radiation without treatment. Some studies were associated with small sample size, therefore, the findings should be interpreted with caution with respect to the clinical recommendation. The demographic and clinical heterogeneity among the studies (age, sex, appliance type, expansion protocol) could not be avoided. Yet, Pangrazio-Kulbersh et al. found no changes in posterior airway volume between banded and bonded expander groups,⁵⁸ while Chang et al. reported an increase in volume of nasal airway by comparing two expansion protocols.²⁵ Previous research has indicated that gender of the patient is not associated with differences in changes in airway volume.⁷⁶ Mislik et al., based on a sample composed of 880 healthy untreated children aged 6 to 17 years, also confirmed that no significant differences exist between the genders. The nasal airway size increases by $0.032 \text{ cm}^2 / \text{year}$ from age 6 to 15,⁷⁷ and a continuous increase of the shortest distance between the soft palate and the posterior pharyngeal wall was reported.⁷⁸

Although all the included studies evaluated growing subjects, the mean initial chronologic age showed heterogeneity, with the mean initial age range being 8.8-14.7 years. Consequently, the participants enrolled in the different studies could have been at different stages of pubertal growth spurt, and it is known that skeletal maturity at the start of treatment critically affects the effectiveness of RME. The level of skeletal maturation of patients prior to expansion treatment was determined by using the cervical vertebral maturation index in five studies,^{39,40,42,46,51} while one used hand-wrist radiographs.⁴⁹

The scanning setting parameters (KVP, X-ray tube current, FOV, and slice thickness) are important factors affecting the results. Ten studies provided FOV, while four studies did not use a large FOV scan (a height equal to or more than 16cm). Though the voxel size influences the quality of the scans, only 12 studies provided this information, with two studies reporting a voxel size above 1mm.^{42,52} In medical imaging, segmentation is defined as the construction of 3D virtual surface models to match volumetric data,⁷⁹ with segmentation performed either manual or semimanual. As shown in the

quality assessment form, seven studies gave the details about the segmentation method, with only four of the studies described the thresholding procedure used to perform the semimanual segmentation.^{39,40,43,52}

5.2 Strengths and Limitations

5.2.1 Strength

The strengths of our systematic review include a comprehensive, extensive and unrestricted search strategy, thus reducing the risk of an incomplete yield and possible publication bias. Each article was reviewed by two reviewers to cross-check the extracted data. To the best of our knowledge, this review is the first to summarize the technical information on application of 3D analysis of the NC and UA after RME, including 3D scanning protocol and segmentation method, which is important for further research work. This review also looked at the differences in NC and UA between the short, medium, and long term follow-up after RME treatment using a precise period definition and the outcome were compared among them, as the short term results seems to be different from medium and long term effect, which was not done in the previous systematic reviews. The reason to assess the NC and UA enlargement is to evaluate whether RME could improve breathing, so at least a sleep questionnaire is necessary to screen the effect of expansion on breathing. This review is the first one to check in a systematic way whether there was any SDB questionnaire administered to the patients before and after RME. Moreover, this review was registered a priori, and provided quantitative data for all included studies; the robustness of the results to the risk of bias was verified through sensitivity analyses, subgroup analyses, small-study effects, no reporting biases. As the definitions of the NC and UA were different in the included studies, to avoid “comparing apples with pears,” we implemented a landmark boundary definition for each part to ensure accurate comparison.

5.2.2 Limitation

The present study is also associated with certain limitations. First, the methodological quality of the included studies was not satisfactory, as most studies were non-randomized studies, except one. This drawback might potentially influence the magnitude and direction of the observed effects. Second, despite our attempt to manage cross-study heterogeneity with appropriate meta-analytic techniques (eg, random-effect models), studies varied in their ascertainment of intervention protocol, study population, length of follow-up, and adjustment for confounding variables. With regard to inclusion of a control group, few studies had one and in most cases the controls were not untreated individuals or appropriately age-matched.

6. Conclusions

Based on the existing evidence, a short-term increase in nasopharynx and oropharynx volume could be observed. RME seems to enlarge the nasal airway in a three-month retention period as well, including the NC and nasopharynx, but the results could not be demonstrated to be stable in the long time. However, the conclusion of this systematic review and meta-analyses should be considered with some caution due to the low quality of evidence reported. For future studies, a matched control group is necessary if the study has a long-term follow-up period, as the effect of growth would be eliminated. Moreover, a SDB questionnaire administered the patients to assess the effect of expansion on breathing should be taken into consideration.

7 Clinical relevance

This systematic review suggests that RME seems to enlarge the NC, and the immediate expansion seems to be clinically significant, despite the lack of available evidence for the long-term effects. These changes can potentially influence the pattern of facial growth and improve nasal breathing, which might have a potential positive short term effect in patients with Pediatric Sleep disordered breathing.

8. References

1. McNamara JA. Maxillary transverse deficiency. *American journal of orthodontics and dentofacial orthopedics*. 2000;117(5):567-570.
2. Johal A, Conaghan C. Maxillary morphology in obstructive sleep apnea: a cephalometric and model study. *The Angle orthodontist*. 2004;74(5):648-656.
3. Schmidt-Nowara W, Lowe A, Wiegand L, Cartwright R, Perez-Guerra F, Menn S. Oral appliances for the treatment of snoring and obstructive sleep apnea: a review. *Sleep*. 1995;18(6):501-510.
4. Liu S, Xu T, Zou W. Effects of rapid maxillary expansion on the midpalatal suture: a systematic review. *European journal of orthodontics*. 2015;37(6):651-655.
5. Basciftci FA, Mutlu N, Karaman AI, Malkoc S, Kucukkolbasi H. Does the timing and method of rapid maxillary expansion have an effect on the changes in nasal dimensions? *The Angle orthodontist*. 2002;72(2):118-123.
6. Oliveira De Felipe NL, Da Silveira AC, Viana G, Kusnoto B, Smith B, Evans CA. Relationship between rapid maxillary expansion and nasal cavity size and airway resistance: short- and long-term effects. *American journal of orthodontics and dentofacial orthopedics*. 2008;134(3):370-382.

7. Linder-Aronson S, Aschan G. Nasal resistance to breathing and palatal height before and after expansion of the median palatine suture. *Odontol Revy.* 1963;14(3):254-270.
8. Hershey HG, Stewart BL, Warren DW. Changes in nasal airway resistance associated with rapid maxillary expansion. *American journal of orthodontics.* 1976;69(3):274-284.
9. Warren DW, Hershey HG, Turvey TA, Hinton VA, Hairfield WM. The nasal airway following maxillary expansion. *American journal of orthodontics and dentofacial orthopedics.* 1987;91(2):111-116.
10. Babacan H, Sokucu O, Doruk C, Ay S. Rapid maxillary expansion and surgically assisted rapid maxillary expansion effects on nasal volume. *The Angle orthodontist.* 2006;76(1):66-71.
11. Doruk C, Sokucu O, Bicakci AA, Yilmaz U, Tas F. Comparison of nasal volume changes during rapid maxillary expansion using acoustic rhinometry and computed tomography. *European journal of orthodontics.* 2007;29(3):251-255.
12. Chiari S, Romsdorfer P, Swoboda H, Bantleon HP, Freudenthaler J. Effects of rapid maxillary expansion on the airways and ears—a pilot study. *European journal of orthodontics.* 2009;31(2):135-141.
13. Hilberg O, Pedersen OF. Acoustic rhinometry: recommendations for technical specifications and standard operating procedures. *Rhinology Supplement.* 2000;16:3-17.
14. Lenza MG, Lenza MM, Dalstra M, Melsen B, Cattaneo PM. An analysis of different approaches to the assessment of upper airway morphology: a CBCT study. *Orthodontics & craniofacial research.* 2010;13(2):96-105.
15. White SM, Huang CJ, Huang SC, Sun Z, Eldredge JD, Mallya SM. Evaluation of the Upper Airway Morphology: The Role of Cone Beam Computed Tomography. *Journal of the California Dental Association.* 2015;43(9):531-539.
16. Bucci R, Montanaro D, Rongo R, Valletta R, Michelotti A, D'Anto V. Effects of maxillary expansion on the upper airways: Evidence from systematic reviews and meta-analyses. *Journal of oral rehabilitation.* 2019;46(4):377-387.
17. Buck LM, Dalci O, Darendeliler MA, Papageorgiou SN, Papadopoulou AK. Volumetric upper airway changes after rapid maxillary expansion: a systematic review and meta-analysis. *European journal of orthodontics.* 2016.
18. Di Carlo G, Saccucci M, Ierardo G, et al. Rapid Maxillary Expansion and Upper Airway Morphology: A Systematic Review on the Role of Cone Beam Computed Tomography. *BioMed research international.* 2017;2017:5460429.

19. Ortu E, Giannoni M, Ortu M, Gatto R, Monaco A. Oropharyngeal airway changes after rapid maxillary expansion: The state of the art. *International journal of clinical and experimental medicine*. 2014;7(7):1632-1638.
20. Gordon JM, Rosenblatt M, Witmans M, et al. Rapid palatal expansion effects on nasal airway dimensions as measured by acoustic rhinometry. A systematic review. *The Angle orthodontist*. 2009;79(5):1000-1007.
21. Baratieri C, Alves M, Jr., de Souza MM, de Souza Araujo MT, Maia LC. Does rapid maxillary expansion have long-term effects on airway dimensions and breathing? *American journal of orthodontics and dentofacial orthopedics*. 2011;140(2):146-156.
22. Ortu E, Giannoni M, Ortu M, Gatto R, Monaco A. Oropharyngeal airway changes after rapid maxillary expansion: the state of the art. *International journal of clinical and experimental medicine*. 2014;7(7):1632-1638.
23. Moher D, Liberati A, Tetzlaff J, Altman DG. Preferred reporting items for systematic reviews and meta-analyses: the PRISMA statement. *Journal of clinical epidemiology*. 2009;62(10):1006-1012.
24. Shamseer L, Moher D, Clarke M, et al. Preferred reporting items for systematic review and meta-analysis protocols (PRISMA-P) 2015: elaboration and explanation. *BMJ (Clinical research ed)*. 2015;350:g7647.
25. Chang DT, Zhou YH, Liu WT. [Evaluation of cone-beam computed tomography on upper airway changes after alternating rapid palatal expansion and constriction]. *Beijing da xue xue bao Yi xue ban = Journal of Peking University Health sciences*. 2017;49(4):685-690.
26. Li L, Qi S, Wang H, Ren S, Ban J. [Cone-beam CT evaluation of nasomaxillary complex and upper airway following rapid maxillary expansion]. *Zhonghua kou qiang yi xue za zhi = Zhonghua kouqiang yixue zazhi = Chinese journal of stomatology*. 2015;50(7):403-407.
27. Luo CH, Zheng ZJ, Xu WH, Wang QY. Three-dimensional reconstruction of the nasomaxillary complex and upper airway following rapid maxillary expansion by cone-beam CT. *Chinese Journal of Tissue Engineering Research*. 2017;21(36):5781-5786.
28. Schwab RJ. Upper airway imaging. *Clinics in chest medicine*. 1998;19(1):33-54.
29. Higgins JP, Altman DG, Gotzsche PC, et al. The Cochrane Collaboration's tool for assessing risk of bias in randomised trials. *BMJ (Clinical research ed)*. 2011;343:d5928.
30. Stroup DF, Berlin JA, Morton SC, et al. Meta-analysis of observational studies in epidemiology: a proposal for reporting. Meta-analysis Of Observational Studies in Epidemiology (MOOSE) group. *Jama*. 2000;283(15):2008-2012.

31. Papageorgiou SN, Kloukos D, Petridis H, Pandis N. Publication of statistically significant research findings in prosthodontics & implant dentistry in the context of other dental specialties. *Journal of dentistry*. 2015;43(10):1195-1202.
32. Papageorgiou SN, Xavier GM, Cobourne MT. Basic study design influences the results of orthodontic clinical investigations. *Journal of clinical epidemiology*. 2015;68(12):1512-1522.
33. Roscoe MG, Meira JB, Cattaneo PM. Association of orthodontic force system and root resorption: A systematic review. *American journal of orthodontics and dentofacial orthopedics*. 2015;147(5):610-626.
34. van Vlijmen OJ, Kuijpers MA, Berge SJ, et al. Evidence supporting the use of cone-beam computed tomography in orthodontics. *Journal of the American Dental Association (1939)*. 2012;143(3):241-252.
35. Guyatt GH, Oxman AD, Schunemann HJ, Tugwell P, Knottnerus A. GRADE guidelines: a new series of articles in the Journal of Clinical Epidemiology. *Journal of clinical epidemiology*. 2011;64(4):380-382.
36. White DP. Sleep-related breathing disorder.2. Pathophysiology of obstructive sleep apnoea. *Thorax*. 1995;50(7):797-804.
37. Caprioglio A, Meneghel M, Fastuca R, Zecca PA, Nucera R, Nosetti L. Rapid maxillary expansion in growing patients: correspondence between 3-dimensional airway changes and polysomnography. *International journal of pediatric otorhinolaryngology*. 2014;78(1):23-27.
38. Fastuca R, Zecca PA, Caprioglio A. Role of mandibular displacement and airway size in improving breathing after rapid maxillary expansion. *Progress in orthodontics*. 2014;15(1):40.
39. Fastuca R, Meneghel M, Zecca PA, et al. Multimodal airway evaluation in growing patients after rapid maxillary expansion. *European journal of paediatric dentistry : official journal of European Academy of Paediatric Dentistry*. 2015;16(2):129-134.
40. Fastuca R, Perinetti G, Zecca PA, Nucera R, Caprioglio A. Airway compartments volume and oxygen saturation changes after rapid maxillary expansion: a longitudinal correlation study. *The Angle orthodontist*. 2015;85(6):955-961.
41. Ballanti F, Lione R, Viarani S, Fanucci E, Cozza P. Post-retention effects of rapid maxillary expansion on nasal cavity and on periodontal structures. *ORAL & implantology*. 2008;1(3-4):95-103.
42. Ballanti F, Lione R, Baccetti T, Franchi L, Cozza P. Treatment and posttreatment skeletal effects of rapid maxillary expansion investigated with low-dose computed tomography in growing subjects. *American journal of orthodontics and dentofacial orthopedics*. 2010;138(3):311-317.

43. Abdalla Y, Brown L, Sonnesen L. Effects of rapid maxillary expansion on upper airway volume: A three-dimensional cone-beam computed tomography study. *The Angle orthodontist*. 2019.
44. Almuzian M, Ju X, Almukhtar A, Ayoub A, Al-Muzian L, McDonald JP. Does rapid maxillary expansion affect nasopharyngeal airway? A prospective Cone Beam Computerised Tomography (CBCT) based study. *The surgeon : journal of the Royal Colleges of Surgeons of Edinburgh and Ireland*. 2016.
45. Badreddine FR, Fujita RR, Alves FEMM, Cappellette Jr M. Rapid maxillary expansion in mouth breathers: A short-term skeletal and soft-tissue effect on the nose. *Brazilian journal of otorhinolaryngology*. 2017.
46. Baratieri CL, Alves M, Mattos C, Lau G, Nojima L, Souza M. Transverse effects on the nasomaxillary complex one year after rapid maxillary expansion as the only intervention: a controlled study. *Dental press journal of orthodontics*. 2014;19(5):79-87. <http://onlinelibrary.wiley.com/o/cochrane/clcentral/articles/815/CN-01255815/frame.html>.
47. Cappellette M, Jr., Alves F, Nagai LHY, Fujita RR, Pignatari SSN. Impact of rapid maxillary expansion on nasomaxillary complex volume in mouth-breathers. *Dental press journal of orthodontics*. 2017;22(3):79-88.
48. Chang Y, Koenig LJ, Pruszyński JE, Bradley TG, Bosio JA, Liu D. Dimensional changes of upper airway after rapid maxillary expansion: a prospective cone-beam computed tomography study. *American journal of orthodontics and dentofacial orthopedics*. 2013;143(4):462-470.
49. Christie KF, Boucher N, Chung CH. Effects of bonded rapid palatal expansion on the transverse dimensions of the maxilla: a cone-beam computed tomography study. *American journal of orthodontics and dentofacial orthopedics*. 2010;137(4 Suppl):S79-85.
50. El H, Palomo JM. Three-dimensional evaluation of upper airway following rapid maxillary expansion: a CBCT study. *The Angle orthodontist*. 2014;84(2):265-273.
51. Fastuca R, Lorusso P, Lagravere MO, et al. Digital evaluation of nasal changes induced by rapid maxillary expansion with different anchorage and appliance design. *BMC oral health*. 2017;17(1):113.
52. Gorgulu S, Gokce SM, Olmez H, Sagdic D, Ors F. Nasal cavity volume changes after rapid maxillary expansion in adolescents evaluated with 3-dimensional simulation and modeling programs. *American journal of orthodontics and dentofacial orthopedics*. 2011;140(5):633-640.
53. Haralambidis A, Ari-Demirkaya A, Acar A, Küçükkeleş N, Ateş M, Özkaya S. Morphologic changes of the nasal cavity induced by rapid maxillary expansion: A study on 3-dimensional

- computed tomography models. *American journal of orthodontics and dentofacial orthopedics*. 2009;136(6):815-821.
54. Iwasaki T, Saitoh I, Takemoto Y, et al. Improvement of nasal airway ventilation after rapid maxillary expansion evaluated with computational fluid dynamics. *American journal of orthodontics and dentofacial orthopedics*. 2012;141(3):269-278.
55. Iwasaki T, Saitoh I, Takemoto Y, et al. Tongue posture improvement and pharyngeal airway enlargement as secondary effects of rapid maxillary expansion: a cone-beam computed tomography study. *American journal of orthodontics and dentofacial orthopedics*. 2013;143(2):235-245.
56. Izuka EN, Feres MF, Pignatari SS. Immediate impact of rapid maxillary expansion on upper airway dimensions and on the quality of life of mouth breathers. *Dental press journal of orthodontics*. 2015;20(3):43-49.
57. Motro M, Schauseil M, Ludwig B, et al. Rapid-maxillary-expansion induced rhinological effects: a retrospective multicenter study. *European Archives of Oto-Rhino-Laryngology*. 2016;273(3):679-687.
58. Pangrazio-Kulbersh V, Wine P, Haughey M, Pajtas B, Kaczynski R. Cone beam computed tomography evaluation of changes in the naso-maxillary complex associated with two types of maxillary expanders. *The Angle orthodontist*. 2012;82(3):448-457.
59. Ribeiro ANC, De Paiva JB, Rino-Neto J, Illipronti-Filho E, Trivino T, Fantini SM. Upper airway expansion after rapid maxillary expansion evaluated with cone beam computed tomography. *Angle Orthodontist*. 2012;82(3):458-463.
60. Smith T, Ghoneima A, Stewart K, et al. Three-dimensional computed tomography analysis of airway volume changes after rapid maxillary expansion. *American journal of orthodontics and dentofacial orthopedics*. 2012;141(5):618-626.
61. Zeng J, Gao X. A prospective CBCT study of upper airway changes after rapid maxillary expansion. *International journal of pediatric otorhinolaryngology*. 2013;77(11):1805-1810.
62. Kavand G, Lagravere M, Kula K, Stewart K, Ghoneima A. Retrospective CBCT analysis of airway volume changes after bone-borne vs tooth-borne rapid maxillary expansion. *The Angle orthodontist*. 2019;89(4):566-574.
63. Lotfi V, Ghoneima A, Lagravere M, Kula K, Stewart K. Three-dimensional evaluation of airway volume changes in two expansion activation protocols. *International orthodontics*. 2018;16(1):144-157.
64. Haas AJ. Rapid expansion of the maxillary dental arch and nasal cavity by opening the midpalatal suture. *The Angle orthodontist*. 1961;31:73-90.

65. Badreddine FR, Fujita RR, Alves FE, Cappellette M, Jr. Rapid maxillary expansion in mouth breathers: a short-term skeletal and soft-tissue effect on the nose. *Brazilian journal of otorhinolaryngology*. 2017.
66. Bucci R, D'Anto V, Rongo R, Valletta R, Martina R, Michelotti A. Dental and skeletal effects of palatal expansion techniques: a systematic review of the current evidence from systematic reviews and meta-analyses. *Journal of oral rehabilitation*. 2016;43(7):543-564.
67. Guijarro-Martinez R, Swennen GR. Three-dimensional cone beam computed tomography definition of the anatomical subregions of the upper airway: a validation study. *International journal of oral and maxillofacial surgery*. 2013;42(9):1140-1149.
68. Kabalan O, Gordon J, Heo G, Lagravère MO. Nasal airway changes in bone-borne and tooth-borne rapid maxillary expansion treatments. *International orthodontics / Collège européen d'orthodontie*. 2015;13(1):1-15.
69. Lagravère MO, Heo G, Major PW, Flores-Mir C. Meta-analysis of immediate changes with rapid maxillary expansion treatment. *The Journal of the American Dental Association*. 2006;137(1):44-53.
70. Ramires T, Maia RA, Barone JR. Nasal cavity changes and the respiratory standard after maxillary expansion. *Brazilian journal of otorhinolaryngology*. 2008;74(5):763-769.
71. Lagravere MO, Major PW, Flores-Mir C. Long-term skeletal changes with rapid maxillary expansion: a systematic review. *The Angle orthodontist*. 2005;75(6):1046-1052.
72. Baccetti T, Franchi L, Cameron CG, McNamara JA, Jr. Treatment timing for rapid maxillary expansion. *The Angle orthodontist*. 2001;71(5):343-350.
73. Wertz RA. Changes in nasal airflow incident to rapid maxillary expansion. *The Angle orthodontist*. 1968;38(1):1-11.
74. Buck LM, Dalci O, Darendeliler MA, Papageorgiou SN, Papadopoulou AK. Volumetric upper airway changes after rapid maxillary expansion: a systematic review and meta-analysis. *European journal of orthodontics*. 2017;39(5):463-473.
75. McNamara JA, Jr., Lione R, Franchi L, et al. The role of rapid maxillary expansion in the promotion of oral and general health. *Progress in orthodontics*. 2015;16:33.
76. Crouse U, Laine-Alava MT, Warren DW, Wood CL. A longitudinal study of nasal airway size from age 9 to age 13. *The Angle orthodontist*. 1999;69(5):413-418.
77. Warren DW, Hairfield WM, Dalston ET. Effect of age on nasal cross-sectional area and respiratory mode in children. *Laryngoscope*. 1990;100(1):89-93.

78. Mislik B, Hanggi MP, Signorelli L, Peltomaki TA, Patcas R. Pharyngeal airway dimensions: a cephalometric, growth-study-based analysis of physiological variations in children aged 6-17. *European journal of orthodontics*. 2014;36(3):331-339.
79. Grauer D, Cevidanes LS, Proffit WR. Working with DICOM craniofacial images. *American journal of orthodontics and dentofacial orthopedics*. 2009;136(3):460-470.

Figure legends

Figure 1. Midsagittal MRI image of a normal subject, demonstrating the upper airway regions: (A) nasopharynx - from the skull base to the hard palate; (B) retropalatal region (RP) - from the level of the hard palate to the caudal margin of the soft palate; (C) retroglossal region (RG) - from the caudal margin of the soft palate to the base of the epiglottis; and (D) hypopharynx - from the base of the epiglottis to the larynx.

Figure 2. Flow diagram for the identification and selection of studies.

Figure 3-1. (a) Forest plot for the changes of nasal cavity volume immediately after expansion (T1) and retention (T2-T4), (b) Forest plot for the changes of nasopharynx volume immediately after expansion (T1) and retention (T2). T0 = pre-expansion; T1 = immediately after expansion; T2 = three months after expansion; T3 = six months after expansion; T4 = 12 months after expansion. WMD, weighted mean difference; CI, confidence interval.

Figure 3-2. (a) Forest plot for the changes of velopharynx volume immediately after expansion (T1) and retention (T2), (b) Forest plot for the changes of oropharynx volume immediately after expansion (T1) and retention (T2). T0 = pre-expansion; T1 = immediately after expansion; T2 = three months after expansion; T3 = six months after expansion; T4 = 12 months after expansion. WMD, weighted mean difference; CI, confidence interval.

Table 1a. Study Characteristics-Participants

Study	Country	Study design	Treatment group				Control group	Ethical approval	Eligibility criteria
			Total	Male	Female	Age			
Abdalla et al. ³⁸ (2019)	Denmark/study material from Australia	Retrospective study	26	N/A	N/A	12.3±2.3	26 Pts, 12 boys and 14 girls, mean age: 12.33	YES/but only from DK	Inclusion criteria: 8-15 years old; uni- or bilateral crossbite; tooth-borne Hyrax expander; a minimum increase of 3 mm in the intermolar width during treatment; pretreatment and progress CBCT scans with complete imaging of the cranial base, maxilla, mandible, first four CV and airways; Class I malocclusions . Exclusion criteria: previous orthodontic treatment, or adenotonsillectomy; known syndromic conditions; movement artifacts; swallowing during scan acquisition; treatment plan requiring orthodontic extractions.
Almuzian et al. ³⁹ (2016)	UK	Prospective cohort study	17	8	9	12.6±1.8	NO	YES	Inclusion criteria: caucasian patients, 10-16 years old, normal BMI, constricted maxillary arch with uni- or bilateral posterior crossbite. Exclusion criteria: previous surgery, or orthodontic treatment; craniofacial deformity; major variation in the head and craniocervical orientation (>5 degrees) between T1 and T2

										CBCT scans.
Badreddine et al. ⁴⁰ (2017)	Brazil	Retrospective controlled study	39	23	16	9.7±2.28	16 Pts, mean age: 8.8 years	YES		Exclusion criteria: syndromic patients or patients with craniofacial abnormalities, and patients with dental or periodontal changes.
Ballanti et al. ^{36, 37} (2008, 2010)	Italy	Prospective cohort study	17	7	10	Mean: 11.2; range: 8-14.	NO	YES		Inclusion criteria: constricted maxillary arches, presence of uni- or bilateral posterior crossbite; variable degree of crowding; one or both maxillary canines presenting with palatal displacement as assessed by panoramic radiographs. Exclusion criteria: above 15 years old; CVM stage > 4 (post-pubertal); absence of maxillary first molars; metallic restorations on the maxillary posterior teeth; previous periodontal diseases, or orthodontic treatments; genetic diseases.
Baratieri et al. ⁴¹ (2014)	Brazil	Prospective controlled clinical trial	15	8	7	Mean: 9.6	15 Pts, 10 boys and 5 girls, mean age: 9.4 years	YES		Inclusion criteria: early mixed dentition; Class I or II malocclusions; CVM stage 1, 2 or 3(pre-pubertal); no systemic diseases; healthy dentition.
Cappellette et al. ⁴² (2017)	Brazil	Prospective controlled clinical trial	23	11	12	Mean: 9.6; range: 6.4-14.2.	15 Pts, 9 boys and 6 girls, mean age 10.5 years.	YES		Inclusion criteria: mouth breathing patients; 4-14 years old; clinical diagnosis of maxilla hypoplasia.

Chang et al. ⁴³ (2013)	USA	Prospective cohort study	14	5	9	Mean:12.9, range: 9.7-16	NO	YES	Inclusion criteria: under 16 years old; uni- or bilateral posterior crossbites; scheduled to receive RME as an initial part of their comprehensive orthodontic treatment. Exclusion criteria: craniofacial anomalies; previous orthodontic treatments; systemic diseases.
Chang et al. ⁴¹ (2017)	China	Randomized controlled trial	Group A: 18	7	11	9.8±1.3	NO	YES	Inclusion criteria: 7-13 years old; Upper first molars erupted; Class III, anterior cross bite; ANB < 0°; Wits < -2mm; A-Np < 0mm; Exclusion criteria: systemic diseases, craniofacial syndrome, or naso-pharyngeal diseases; previous orthodontic treatment.
			Group B: 16	6	10	10.3±1.6			
Christie et al. ⁴⁴ (2010)	USA	Prospective cohort study	24	14	10	Mean: 9.9; range: 7.8-12.8.	NO	N/A	Inclusion criteria: children who required RME treatment. The mean skeletal age of the patients was 10.3 years (range, 7.5-13 years) by a hand-wrist radiograph.
El et al. ⁴⁵ (2014)	Turkey	Retrospective controlled study	35	20	15	14.02±1.46	35 Pts, 14.10±1.44 years old	YES	Inclusion criteria: complete records; Hyrax expander as part of the treatment provided. Exclusion criteria: history of craniofacial deformities; extraction treatment plan; pharyngeal pathology and/or nasal obstruction; snoring; obstructive sleep apnea; adenoidectomy and tonsillectomy; any CBCT scans, in which the airways were not clear, not fully contained in

the volume, or contained artifacts.

Caprioglio and Fastuca ^{32, 33, 35} (2014, 2015)	Italy	Prospective cohort study ^{32, 35;} Retrospective study ³³	15 ^{35;} 14 ^{32, 33;}	11	4	7.5 ± 0.3 ^{35;} Mean: 7.1 ^{32, 33}	NO	YES	Inclusion criterial: 6 to 9 years old; CVM stage 1; Class I; unilateral functional posterior crossbite; upper and lower first molars erupted. Exclusion criterial: systemic diseases; previous orthodontic treatment; asymmetries.
Fastuca et al. ³⁴ (2015)	Italy	Prospective cohort study	22	9	13	8.3±0.9	NO	YES	Inclusion criteria: good general health; narrow maxillary arches, presence of uni- or bilateral posterior crossbite; CVM stage 1 or 2, upper and lower first molars fully erupted.
Fastuca et al. ⁴⁶ (2017)	Italy	Retrospective cohort study	44	20	24	Male: 8y 8 m ± 1y 2 m; Females: 8y 2 m ± 1y 4 m	NO	YES	Inclusion criterial: good general health; CVM stage 1 or 2; transverse maxillary deficiency with uni- or bilateral crossbite treated by RME; complete initial and final records including CT scans, photographs, dental casts, and medical history forms. Exclusion criterial: systemic diseases and craniofacial syndromes; severe facial asymmetry; dental anomalies; naso-pharyngeal diseases; history of nasal or tonsil surgery, or orthodontic treatment prior to RME.
Gorgulu et al. ⁴⁷ (2011)	Turkey	Prospective cohort study	15	9	6	13.86±1.4; Range: 12-16.	NO	YES	Inclusion criterial: constricted maxillary arches with or without cross bite and full permanent

Haralambidis et al. ⁴⁸ (2009)	Turkey	Prospective cohort study	24	10	14	Mean: 14.5	NO	YES	<p>Inclusion criterial: 10-17 years old; transverse maxillary deficiency with bilateral posterior crossbite; complete permanent dentition.</p> <p>Exclusion criterial: no systemic disease; no previous orthodontic treatment.</p>
Iwasaki et al. ⁴⁹ (2012)	Japan	Prospective cohort study	23	9	14	Mean: 9.74	NO	YES	<p>Exclusion criterial: patients who had previous orthodontic treatment, craniofacial, or growth abnormalities.</p>
Iwasaki et al. ⁵⁰ (2013)	Japan	Retrospective controlled study	28	13	15	Mean: 9.96	20 Pts, 9.68±1.02 years old	YES	<p>Inclusion criteria: Class II skeletal relationship.</p> <p>Exclusion criterial: previous orthodontic treatment; craniofacial or growth abnormalities; enlarged adenoids or tonsils.</p>
Izuka et al. ⁵¹ (2015)	Brazil	Prospective cohort study	25	11	14	Mean:10.5, range: 7.1-14.3	NO	YES	<p>Children with maxillary atresia and posterior crossbite, as revealed by clinical examination performed by a single experienced orthodontist.</p>
Kavand et al. ⁵⁷ (2019)	USA	Retrospective study	Tooth-borne: 18	8	10	Mean:14.4±1.3	No	YES	<p>Inclusion criteria: 11 to 15 years old.</p> <p>Exclusion criteria: previous orthodontic treatment, or adenoidectomy or tonsillectomy;</p>

dentitions.

Exclusion criterial: patients with any sign of fluid accumulation in the maxillary sinus CBCT image.

			Bone-borne: 18	6	12	Mean: 14.7±1.4			TMD; periodontal diseases; systemic diseases; craniofacial anomalies; active caries.
Li et al. ²² (2015)	China	Prospective cohort study	35	18	17	12.1±1.1	NO	YES	Inclusion criteria: full permanent dentition erupted; narrow maxilla; uni- or bilateral crossbite; patients at a stage prior to the pubertal growth peak ; clear and complete CBCT records. Exclusion criterial: cleft lip and/or palate; facial damage; issues with trauma, adenoids or other factors affecting craniofacial development
Lofti et al. ⁵⁸ (2018)	USA	Retrospective study	Group A: 20 Group B: 20	8 10	12 10	Mean: 12.3 ± 1.9 Mean: 13.8 ± 1.3	NO	YES	Inclusion criteria: bilateral crossbite, complete medical and dental records; 3D CBCT; full anatomy of the airway to the level of fourth CV present in the scans; RME as a part of comprehensive orthodontic treatment.
Luo et al. ²³ (2017)	China	Prospective cohort study	30	8	22	13.13±1.45	NO	N/A	Inclusion criteria: transverse maxillary deficiency with bilateral posterior crossbite; patients at a stage prior to the pubertal growth peak; clear and complete CBCT records. Exclusion criteria: craniofacial trauma tumor, or abnormalities; TMD; cleft lip and/or palate; enlarged adenoids or tonsils, no adenoidectomy or tonsillectomy; history of other orthodontic treatment prior to RME.

Motro et al. ⁵² (2016)	USA/Germany	Retrospective cohort study	31	12	19	Mean: 14.63; range: 11-23.	NO	YES	Inclusion criteria: nasomaxillary constriction and a successful expansion; low-dose CT available at T1 and T2. Exclusion criteria: a need for supplementary surgical weakening; a lack of suitable 3D images; a discontinuous active expansion phase.
Pangrazio-Kulbersh et al. ⁵³ (2012)	USA	Prospective cohort study	Banded: 13 Bonded: 10	7	6	12.6±1.8 13.5±2.1	NO	YES	Inclusion criteria: constricted maxillary arch (with or without crossbite); full permanent dentition.
Ribeiro et al. ⁵⁴ (2012)	Brazil	Retrospective cohort study	15	7	8	Mean: 7.5	NO	YES	Inclusion criteria: transverse maxillary deficiency; unilateral posterior crossbite.
Smith et al. ⁵⁵ (2012)	USA/Egypt	Prospective cohort study	20	8	12	Mean: 12.37.	NO	YES	Inclusion criteria: 8 to 15 years old; bilateral maxillary constriction. Exclusion criteria: previous orthodontic or orthopedic treatment; systemic diseases, craniofacial anomalies, or TMD; tonsillectomy or adenoidectomy; carious, gingival, or periodontal lesions; metallic restorations; RME planned as a part of comprehensive orthodontic treatment.

Zeng et al. ⁵⁶ (2013)	China	Prospective cohort study	16	10	6	12.73±1.7	NO	YES	<p>Inclusion criteria: Constricted maxilla with or without posterior crossbite, upper first premolars and first molars erupted.</p> <p>Exclusion criteria: above 15 years old, severe adenoid or tonsil hypertrophy, severe periodontal disease, other simultaneous orthodontic treatment, history of systemic disease or presence of a craniofacial congenital syndrome</p>
-------------------------------------	-------	--------------------------	----	----	---	-----------	----	-----	--

Pts: patients; **PSG:** Polysomnography; **CV:** cervical vertebral; **CVM:** cervical vertebral maturation; **N/A:** information not available; **TMD:** temporomandibular joint disorders.

Table 1b: Study Characteristics-Intervention

Study	Treatment			Retention	Evaluation time points	The expansion of mid-palatal suture
	Appliance	Active protocol	Duration			
Abdalla et al. ³⁸ (2019)	Tooth-borne Hyrax-type expander	0.25 mm per day	Minimum of 2 weeks	Retention period of 6 months, after which some of the RME patients continued with fixed appliances.	1 st TP: pretreatment 2 nd TP: The end of active treatment	N/A
Almuzian et al. ³⁹ (2016)	A cast-cap appliance with a Hyrax screw	A quarter turn (approximately 0.25 mm), twice/d until OE achieved.	The mean period for the active phase was 14 days with a range of 12 - 21 days.	N/A	1 st TP: pretreatment 2 nd TP: immediate posttreatment	N/A

Badreddine et al. ⁴⁰ (2017)	Hyrax maxillary expander	Six quarter initial activations and two quarter daily activations	Until the superior buccal bone seems compatible with inferior WALA edge.	Appliances kept in place for a period of 3 months, as a retainer	1 st TP: pretreatment 2 nd TP: 3 months after expansion	N/A
Ballanti et al. ^{36,37} (2008, 2010)	Butterfly-shaped expander	A quarter turn (0.25mm), twice/d	14 days	Screw tied off with a ligature wire and the expander kept on teeth as a passive retainer for 6 months.	1 st TP: pretreatment 2 nd TP: immediate posttreatment 3 rd TP: after the 6 months' retention period	Anterior, middle, and posterior suture width after RME
Baratieri et al. ⁴¹ (2014)	Haas expander	At delivery, expander activated by one complete turn (0.8 mm). After initial activation, quarter turn/d in the morning and in the evening.	Until the required expansion was achieved (according to the individual skeletal deficiency). Mean screw activation was 7 mm (5.6 mm - 9 mm).	Screw was stabilized with 0.012-in double thread ligature and kept in place passively for 6 months of retention when the expander was removed.	1 st TP: pretreatment 2 nd TP: one year after expansion	N/A
Cappellette et al. ⁴² (2017)	Hyrax expander	Two daily activations	15-20 days	The appliance was kept in place for about 3 months; removed after bone formation was observed through occlusal radiographs	1 st TP: pretreatment 2 nd TP: 3 months after the first measurement	N/A
Chang et al. ⁴³ (2013)	Hyrax expander	One quarter turn /d	28 consecutive days or until resolution of the posterior crossbite.	Tying off the jackscrew with a ligature wire, placing composite material over it.	1 st TP: pretreatment 2 nd TP: 3-4 months after expansion	N/A

Chang et al. ²¹ (2017)	Group A: Hyrax expander	0.5 mm/d;	2 weeks	N/A	1 st TP: pretreatment 2 nd TP: posttreatment	N/A
	Group B: Hyrax expander	Expansion: 0.5 mm/d, 2 weeks; then constriction: 0.5 mm/d, 2 weeks	10 weeks			
Christie et al. ⁴⁴ (2010)	Bonded Haas-type RPE	Twice/d (0.4mm)	30 days (range, 21-42 days)	N/A	1 st TP: pretreatment 2 nd TP: immediately after expansion	The suture opening for the maxillary first molar, the second premolar, first premolar, and canine
El et al. ⁴⁵ (2014)	Hyrax expander	Twice/d	Until dental Oc	Screws stabilized, and expander left passively in place for 4–6 months.	1 st TP: pretreatment 2 nd TP: posttreatment	N/A
Caprioglio and Fastuca ^{32, 33, 35} (2014, 2015)	Banded Haas-type expander	Twice (0.45mm) at first, then once/d (0.225mm)	Until dental Oc	At the end of active expansion period, screw locked with light-cure flow composite.	1 st TP: pretreatment 2 nd TP: after the removal of the maxillary expander 12 months later	N/A
Fastuca et al. ³⁴ (2015)	Banded Haas-type expander	The expander was initially turned twice (0.45-mm initial transverse activation).	Until dental Oc	Screw locked with a light-cured composite; the expander remained on teeth as passive	1 st TP: pretreatment 2 nd TP: immediately after the removal of the	N/A

		Afterwards, once/d (0.225/d).		retainer for a 12 months period.	maxillary expander, 12 months later	
Fastuca et al. ⁴⁶ (2017)	HX-6 Group (Hyrax expander anchored to permanent teeth): 15 patients; HX-E Group (Modified Hyrax expander anchored to deciduous teeth): 14 patients; HS-E Group (Modified Haas-type expander anchored to deciduous teeth): 15 patients	Initially turned eight times; afterwards three times/d In both groups, HX-E and HS-E, the screw was initially activated twice by the clinician; after that, it was turned once or twice/d	Until the dental Oc	Screw stabilized and expander passively kept in situ. Retention period of at least 7 months.	1 st TP: pretreatment 2 nd TP: after the 6 months' retention period	N/A
Gorgulu et al. ⁴⁷ (2011)	Bonded RME	A quarter turn (0.25mm) twice/d	Until the desired expansion was obtained.	N/A	1 st TP: pretreatment 2 nd TP: 6 months after the end of expansion	N/A
Haralambidis et al. ⁴⁸ (2009)	Bonded Hyrax expander	Twice/d	23.7 days	The screw was secured with a stainless-steel ligature wire, and the RME appliance was left in place for 3 months as a retention appliance.	1 st TP: pretreatment 2 nd TP: at the end of the 3-month retention period.	N/A

Iwasaki et al. ⁴⁹ (2012)	RME (unspecified)	approximately 5mm of maxillary expansion	N/A	N/A	1 st TP: before expansion 2 nd TP: after expansion	N/A
Iwasaki et al. ⁵⁰ (2013)	RME (unspecified)	approximately 5mm of maxillary expansion	N/A	No passive retention appliance was used before full orthodontic treatment	1 st TP: before expansion 2 nd TP: after expansion	N/A
Izuka et al. ⁵¹ (2015)	Modified Biederman	Four activations when appliance installed, then twice/d	Until dental Oc	N/A	1 st TP: pretreatment 2 nd TP: immediate after expansion	N/A
Kavand et al. ⁵⁷ (2019)	Hyrax expander	A quarter turn (0.25mm) twice/d	Until the mesiopalatal cusps of the maxillary first permanent molars were in contact with the buccal cusps of mandibular first permanent molars	N/A	1 st TP: pretreatment 2 nd TP: 3 months after expansion	N/A
Li et al. ²² (2015)	Hyrax expander	A quarter turn (0.25mm) twice/d	16 days	N/A	1 st TP: pretreatment 2 nd TP: 16 days after expansion 3 rd TP: 3 months after expansion	N/A
Lofti et al. ⁵⁸ (2018)	Hyrax expander	Group A: 0.2 mm, four times/d	Until the required amount of expansion was achieved and	Appliance left in situ as a passive retainer for three	1 st TP: pretreatment 2 nd TP: 3 months after	N/A

		Group B: 0.25 mm, twice/d	palatal cusp of maxillary first molar was in contact with buccal cusp of mandibular first molar.	months.	expansion	
Luo et al. ²³ (2017)	Hyrax expander	A quarter turn (0.025mm) twice/ d	14-28 days, until dental Oc	N/A	1 st TP: pretreatment 2 nd TP: posttreatment	N/A
Motro et al. ⁵² (2016)	5 patients were treated with a Hyrax expander; 6 with Hybrid RME; and 20 with acrylic cap RME.	No active protocol given	N/A	N/A	1 st TP: pretreatment 2 nd TP: immediately after expansion	N/A
Pangrazio-Kulbersh et al. ⁵³ (2012)	Hyrax expander	N/A	4-6 weeks, with 6-10 mm of activation	6 months	1 st TP: pretreatment 2 nd TP: immediately after expansion	N/A
Ribeiro et al. ⁵⁴ (2012)	A fixed appliance with occlusal acrylic coating	N/A	N/A	N/A	1 st TP: before treatment 2 nd TP: 4 months after expansion	N/A
Smith et al. ⁵⁵ (2012)	Hyrax expander	2 turns twice/d (0.8mm/d)	Until the palatal cusps of the maxillary first molars contacted the buccal cusps of	N/A	1 st TP: before treatment 2 nd TP: 3 months after treatment	N/A

			the mandibular first molars.			
Zeng et al. ⁵⁶ (2013)	Hyrax expander	2 turns/d	The active expansion period ranged from 2 to 3 weeks according to the expansion amount (2.7–6.3 mm).	Then the screw was locked with the light-cured composite. The retention period lasted 3 months.	1 st TP: pretreatment 2 nd TP: 3 months after expansion	N/A

TP: time point; **RME:** Rapid maxillary expansion; **OE:** over-expansion; **N/A:** not available; **d:** day; **RME:** rapid maxillary expansion; **Oc:** over-correction.

Table 1c: Study Characteristics-Analysis

Study	3D imaging	Scanning setting parameters	Analysis software	Segmentation	Nasal cavity boundary	Airway Analysis	Reference horizontal plane	Measured region	Dentoskeletal expansion outcome
Abdalla et al. ³⁸ (2019)	CBCT (i-CAT; Imaging Sciences International, Hatfield, Pa, USA)	120 Kv, 5mA, FOV: 13cm x16 cm, voxel size: 0.4mm, scan time: 8.9s.	Dolphin (Dolphin Imaging and Management Solutions, Chatsworth, Calif)	Automatic segmentation. Threshold manually adjusted if necessary for each data set.	N/A	Total airway: from Palatal plane to CV4AS – Me plane	FH	Total airway	Maxillary width; Maxillary intermolar width; Mandibular width.
Almuzian et al. ³⁹ (2016)	CBCT (i-CAT; Imaging Sciences International, Hatfield, Pa, USA)	N/A	OnDemand3D (Cybermed, Seoul, Republic of Korea) and ITK-SNAP	Automatic and manual segmentation.	Anteriorly: vertical plane passing through ANS; Posteriorly: PNSV plane; Superiorly: LOrH plane; Inferiorly: Inferior nasal wall	Upper nasopharynx: LOrH plane- horizontal plane passing through PNS; Lower retropalatal space: PNS – Spip (Most inferior-posterior point of soft palate shadow as viewed from the axial section);	FH	Lower nasal cavity; Upper nasopharynx; Retropalatal	N/A
Badreddine et al. ⁴⁰ (2017)	CT (Philips Brilliance CT 64 channel scanner)	FOV:20 cm, voxel size: 0.25 mm	OsiriX MD (Pixmeo, Geneva, Switzerland)	N/A	N/A	N/A	N/A	Nasal cavity width	

Ballanti et al. ^{36, 37} (2008, 2010)	CT (General Electric?)	80 Kv, 100 mA, FOV: 13.7cm, voxel size: 1.25 mm, matrix: 512 x 512, 0.6-mm interval, and 0° gantry angle	Dentascan (Milwaukee, Wis)	N/A	N/A	N/A	N/A	Nasal cavity width
Baratieri et al. ⁴¹ (2014)	CBCT (i-CAT; Imaging Sciences International, Hatfield, Pa, USA)	120 KVp, 5 mA, FOV: 16x22 cm, voxel size: 0.4mm	Dolphin (Dolphin Imaging and Management Solutions, Chatsworth, Calif)	N/A	N/A	N/A	N/A	Nasal cavity area
Cappellette et al. ⁴² (2017)	CT (Philips® Brilliance CT scanner 64 channels)	N/A	Dolphin (Dolphin Imaging and Management Solutions, Chatsworth, Calif)	N/A	N/A	N/A	N/A	Nasal cavity; Oropharyngeal
Chang et al. ⁴³ (2013)	CBCT, Scanora 3D (Soredex, Tuusula, Finland)	125 mSv, FOV: 14.5cm x 13.0cm; voxel size: 0.35 mm; scan time: 20 sec; effective radiation time of 4.5s.	Dolphin (Dolphin Imaging and Management Solutions, Chatsworth, Calif)	Fixed value: 60 units (?), or 50 units (in 2 cases); Segmentation procedure not well specified	N/A	Retropalatal: PNS to soft palatal; Retroglossal: soft palatal – epiglottis	on the midsagittal horizontal line connecting the PNS to Ba	Retropalatal; Retroglossal; Total upper airway

Chang et al. ²¹ (2017)	CBCT (VATECH, Korea)	90 Kv, 7mA, FOV: 20cm x 19 cm, voxel size: 0.4mm, scan time: 15s	Dolphin (Dolphin Imaging and Management Solutions, Chatsworth, Calif)	N/A	Anterior: ANS to the tip of the nasal bone to N; Posterior: S to PNS; Superior: N to S; Inferior: ANS to the PNS.	Nasopharynx: PNS-S to PNS-Odp Oropharynx: PNS-Odp to CV4SP-the base of the epiglottis Hypopharynx: the base of the epiglottis-CV4SP to the inferior border of the symphysis-CV4PI.	N/A	Nasal cavity; Nasopharyngeal; Oropharyngeal; Hypopharyngeal
Christie et al. ⁴⁴ (2010)	CBCT (i-CAT; Imaging Sciences International, Hatfield, Pa, USA)	N/A	Dolphin (Dolphin Imaging and Management Solutions, Chatsworth, Calif)	N/A	N/A	N/A	N/A	Nasal cavity width
El et al. ⁴⁵ (2014)	CBCT (Hitachi Medical Systems America Inc, Twinsburg, Ohio)	120 Kv, 2 mA, FOV: 12-inch (F Mode).	Dolphin (Dolphin Imaging and Management Solutions, Chatsworth, Calif)	N/A	N/A	Nasopharynx: the last slice before the nasal septum fuses with the posterior wall of the pharynx to PP; Oropharynx: PP to CV2AI.	line passing from PP	Posterior airway space(mm); MinAx(mm2), Oropharynx; Nasopharynx

Caprioglio and Fastuca 32, 33, 35 (2014, 2015)	CBCT (i-CAT; Imaging Sciences International, Hatfield, Pa, USA)	120 KV, 3.8 mA, scan time: 30 s	Mimics (Materialise Medical Co, Leuven, Belgium)	The airway region were segmented using a threshold-based procedure manually executed and corrected slice by slice.	Upper airway: between the edges of the nasal bones and ethmoid bone from nares to the PNSV plane;	Middle airway: PNSV to OdP plane; Lower airway: OdP plane to epiglottis. Total airway: Upper airway + Middle airway + Lower airway	FH	Upper airway; Middle airway; Lower airway; Total airway
Fastuca et al. 34 (2015)	CBCT (i-CAT; Imaging Sciences International, Hatfield, Pa, USA)	120 KV, 3.8 mA, scan time: 30 s	Mimics (Materialise Medical Co, Leuven, Belgium)	The airway region were segmented using a threshold-based procedure manually executed and corrected slice by slice.	N/A	Total airway: nares to the base of tongue	N/A	Total airway
Fastuca et al. 46 (2017)	low-dose CT (Philips Medical Systems, Best, The Netherlands) or CBCT (i-CAT; Imaging Sciences International, Hatfield, Pa, USA)	Low-dose CT: 80 Kv, 28 mAs, Pitch 1, CDTIVol 2.5 mgy CBCT: 120 KV, 3.8 mA, scan time: 30 s	Mimics (Materialise Medical Co, Leuven, Belgium)	N/A	N/A	N/A	N/A	Nasal cavity width

Gorgulu et al. ⁴⁷ (2011)	CT (MX 8000 IDT Multislice CT System-V 2.5; Philips Medical Systems, Best, the Netherlands)	120 kV; 200 mAs 16 x 0.75-mm detector collimation (pitch, 0.6); 1-mm slice thickness; 0.5-mm increments; 0.75-second rotation time	Mimics and Simplant Ortho software program (both, Materialise, Leuven, Belgium)	Segmentation was performed by using the software's threshold feature on each slice or on the direct 3D virtual model.	Nasal cavity segments were restricted to the ostium of the paranasal sinuses, the posterior airway, and the nostrils.	N/A	N/A	N/A	Nasal cavity
Haralambidis et al. ⁴⁸ (2009)	CT (Siemens Sensation 40, Siemens Medical Solutions, Germany)	120 KV, 80 mAs, FOV: 12.6 cm, voxel size: 0.3mm matrix: 512 x 512 pixels.	Mimics (Materialise Medical Co, Leuven, Belgium)	Manual segmentation. No detail for threshold.	N/A	N/A	N/A	N/A	Anterior nasal cavity
Iwasaki et al. ⁴⁹ (2012)	CBCT (CB MercuRay, Hitachi Medical, Tokyo, Japan)	Maximum 120Kv, 15 mA, and exposure time of 9.6s.	INTAGE Volume Editor (CYBERNET, Tokyo, Japan)	Manual segmentation. No detail for threshold.	N/A	N/A	N/A	N/A	Nasal cavity width
Iwasaki et al. ⁵⁰ (2013)	CBCT (CB MercuRay; Hitachi Medical, Tokyo, Japan)	Maximum 120 kV, 15 mA, and exposure time of 9.6s.	INTAGE Volume Editor (CYBERNET, Tokyo, Japan)	Manual segmentation. No detail for threshold.	The nasal airway: From the external nares to the choanae, including the paranasal sinuses.	Retropalatal: From PP to soft palatal plane.	PP	Oropharyngeal: From soft palatal to EP plane.	Intraoral airway; Total pharyngeal; Retropalatal; Oropharyngeal
								Intraoral airway: between the tongue and palate was measured as an	

						indication of vertical tongue position.		
Izuka et al. ⁵¹ (2015)	CBCT (Kavo i-Cat)	120 kVp, 8 mA, voxel size: 0.3 mm, scan time: 20s	Dolphin (Dolphin Imaging and Management Solutions, Chatsworth, Calif)	N/A	Nasopharynx and nasal cavities: Upper: the last axial slice before the fusion of the nasal septum with the pharyngeal wall observed at sagittal view; Lower: PP; Posterior: the posterior pharyngeal wall; Anterior: the nasal cavities.	Oropharynx: PNS to the most anterior point of CV2.	PP	Nasopharynx and nasal cavities; Oropharynx
Kavand et al. ⁵⁷ (2019)	CBCT (Imaging Sciences International, Hartfield, PA)	120Kv, 20mA, voxel: 0.3mm, scan time: 8.9s.	Dolphin (Dolphin Imaging and Management Solutions, Chatsworth, Calif)	N/A	Anterior: ANS to the tip of the nasal bone to N; Posterior: S to PNS; Superior: N to S; Inferior: ANS to the	Nasopharynx: PNS-S to PNS-Odp. Oropharynx: PNS-Odp to Odp-CV3AI to CV3AI-Me to Me-PNS	FH	Nasal cavity; Nasopharynx; Oropharynx

PNS.

Li et al. ²² (2015)	CBCT (DCTORO-45, Vatech, Korea)	85Kv, 8mA, voxel size: 0.1-0.3 mm, exposure time of 24 seconds	EzImplant	N/A	N/A	Nasopharynx: the last slice before the nasal septum fuses with the posterior wall of the pharynx to PP Oropharynx: PNS to CV3AI	N/A	Nasopharynx; Oropharynx
Lofti et al. ⁵⁸ (2018)	CBCT (i-CAT; Imaging Sciences International, Hatfield, Pa, USA)	120 kV, 20 mA, FOV: 17 cm x 23 cm, voxel size: 0.3 mm, scan time: 8.9 s.	Dolphin (Dolphin Imaging and Management Solutions, Chatsworth, Calif)	N/A	Anterior: ANS to the tip of the nasal bone to N; Posterior: S to PNS; Superior: N to S; Inferior: ANS to the PNS.	Nasopharynx: PNS-S to PNS-Odp Oropharynx: PNS- Odp to CV4SP-the base of the epiglottis Hypopharynx: the base of the epiglottis- CV4SP to the inferior border of the symphysis-CV4PI.	FH	Nasal cavity; Nasopharynx; Oropharynx; Hypopharynx
Luo et al. ²³ (2017)	CBCT (NEWTOM 3G)	N/A	Dolphin (Dolphin Imaging and Management	N/A	N/A	Nasopharynx: the last slice before the nasal septum fuses with the	FH	Nasopharynx; Oropharynx;

			Solutions, Chatsworth, Calif)			posterior wall of the pharynx to PP;		Hypopharynx
						Oropharynx: PP to CV2AI/FH;		
						Hypopharynx: CV2AI/FH to CV3AI/FH		
Motro et al. ⁵² (2016)	low-dose CT (N/A)	N/A	Mimics (Materialise Medical Co, Leuven, Belgium)	The airways were segmented using a defined density unit (HU) of 1000.	N/A	N/A	N/A	Total airway; Nasopharynx; Oropharynx; Laryngopharynx
Pangrazio- Kulbersh et al. ⁵³ (2012)	CBCT (N/A)	N/A	Dolphin (Dolphin Imaging and Management Solutions, Chatsworth, Calif)	N/A	N/A	PNS to the epiglottis.	N/A	Maxillary sinuses; Posterior Airway
Ribeiro et al. ⁵⁴ (2012)	CBCT (i-CAT; Imaging Sciences International, Hatfield, Pa, USA)	N/A	Dolphin (Dolphin Imaging and Management Solutions, Chatsworth, Calif)	N/A	N/A	Nasopharynx: PNS to VP, horizontal extension point VP and vertical extension point ENP (VA), Ba, PPINf, and PAINf;	PP	Nasopharynx; Oropharynx
						Oropharynx: the upper limit of the epiglottis was		

identified in the coronal plane, cut as this is in its greatest length, and its uppermost portion was landmarked.

Smith et al. 55 (2012)	Spiral CT (Xvision EX; Toshiba Medical Systems, Otawara-Shi, Japan)	120Kv, 20mA, FOV: 25cm, voxel size: 0.4mm, and 2 seconds per section	Dolphin (Dolphin Imaging and Management Solutions, Chatsworth, Calif)	N/A	Anterior: ANS to the tip of the nasal bone to N; Posterior: S to PNS; Superior: N to S; Inferior: ANS to the PNS.	Nasopharynx: PNS-S to PNS-Opd Oropharynx: PNS - Opd to CV4sp-the base of the epiglottis Hypopharynx: the base of the epiglottis-CV4ps to the inferior border of the symphysis-CV4pi.	N/A	Nasal cavity; Nasopharynx; Oropharynx; Hypopharynx
Zeng et al. 56 (2013)	CBCT (DCTPRO-050Z, VATECH Co, Ltd, Korea)	N/A	Ez3D2009 (E-WOO Technology Co, Ltd. Korea)	N/A	NV: Multiply the palatal length (ANS-PNS) by the average area of cross-section 1-3 of the lower portion of the nasal cavity.	Multiply the pharyngeal airway length by the average cross-sectional area.	N/A	Lower nasal cavity; Nasopharynx; Oropharynx

FOV: field of view; **N/A:** not available; **CV:** cervical vertebra; **AS:** anterior-superior; **Me:** menton; **FH:** Frankfort plane; **ANS:** anterior nasal spine; **PNS:** posterior nasal spine; **PNSV plane:** True vertical plane (a reference plane constructed vertical to the floor at any point) passing through PNS; **LORH plane:**

True horizontal plane tangent to lowest point of the left inferior orbital floor; **Ba**: basion; **Odp**: the tip of the odontoid process; **N**: nasion; **S**: Sella; **VP**: vomer posterior; **SP**: superior- posterior; **PI**: posterior-interior; **PP**: palatal plane (through ANS and PNS); **AI**: anterior-interior; **MinAx**: area of the most constricted region at the base of the tongue; **Odp plane**: a plane passing through the middle point of odontoid process of second cervical vertebra and parallel to axial reference plane; **EP plane**: the horizontal line passing through the most superior point of the epiglottis; **PPINF**: located 15 mm posterior to the lower limit of the uvula; **PAINf**: located 15 mm above the lower limit to the uvula;

Table 2a: Risk of bias assessment of the included randomized clinical trial

Study	Adequate sequence generation	Allocation concealment	Blinding	Incomplete outcome data	Selective reporting	Blinding of outcome assessment	Other bias
Chang et al. ²¹ (2017)	Low risk	Low risk	High risk	Low risk	Low risk	Low risk	Moderate risk

Table 2b: Risk of bias assessment of the included non-randomized studies (max score=16 points)

Study	[SD]	[R]	[SS]	[SC]	[C]	[FU]	[OB]	[DO]	[IV]	[A]	[B]	[RE]	[S]	[ST]	[DP]	[Con.]	Total	% score
Abdalla et al. ³⁸ (2019)	0	0	1	1	1	0	1	0	1	1	0	1	1	1	1	1	11	69
Almuzian et al. ³⁹ (2016)	1	0	0	1	0	0	1	0	1	1	0	1	0	1	0	1	8	50
Badreddine et al. ⁴⁰ (2017)	0	0	1	0	1	1	1	0	1	1	0	1	0	1	1	1	10	63
Ballanti et al. ^{36,37} (2008, 2010)	1	0	0	1	0	1	1	0	1	1	0	1	0	1	1	1	10	63
Baratieri et al. ⁴¹ (2014)	1	1	1	0	1	1	1	0	1	1	1	1	0	1	1	0	12	75
Cappellette et al. ⁴² (2017)	1	0	1	1	1	1	1	0	1	1	0	0	0	1	1	0	10	63

Chang et al. ⁴³ (2013)	1	0	0	1	0	0	1	0	1	1	0	1	1	1	1	1	10	63
Christie et al. ⁴⁴ (2010)	1	0	1	0	0	0	1	0	1	1	0	1	0	0	0	0	8	50
El et al. ⁴⁵ (2014)	0	0	1	1	1	0	1	1	0	1	0	1	0	1	1	1	11	69
Caprioglio and Fastuca ^{32, 33, 35} (2014, 2015)	0	0	0	1	0	1	1	1	1	1	0	1	1	1	0	1	10	63
Fastuca et al. ³⁴ (2015)	1	0	1	1	0	1	1	0	1	1	0	1	1	1	0	1	11	69
Fastuca et al. ⁴⁶ (2017)	0	0	1	1	0	0	1	0	1	1	0	1	0	1	1	0	8	50
Gorgulu et al. ⁴⁷ (2011)	1	0	0	0	0	0	1	0	1	1	0	1	1	1	1	1	9	56
Haralambidis et al. ⁴⁸ (2009)	1	0	1	1	0	0	1	0	1	1	0	1	1	0	1	1	10	63
Iwasaki et al. ⁴⁹ (2012)	1	0	1	0	0	0	1	0	0	1	0	1	1	0	1	0	7	44
Iwasaki et al. ⁵⁰ (2013)	0	0	1	1	1	0	1	0	0	1	0	1	1	1	1	0	9	56
Izuka et al. ⁵¹ (2015)	1	0	1	0	0	0	1	0	1	1	0	0	0	0	1	0	7	44
Kavand et al. ⁵⁷ (2019)	0	0	0	1	0	1	1	0	0	1	0	0	0	0	1	1	6	38
Li et al. ²² (2015)	1	0	1	1	0	1	1	0	1	0	0	0	0	1	1	1	9	56
Lofti et al. ⁵⁸ (2018)	0	0	1	0	0	0	1	0	1	1	0	1	0	1	1	0	7	44
Luo et al. ²³ (2017)	1	0	1	1	0	0	1	1	1	0	0	0	0	1	1	1	9	56
Motro et al. ⁵² (2016)	0	0	1	1	0	0	1	0	0	0	0	1	1	1	1	1	8	50
Pangrazio-Kulbersh et al. ⁵³ (2012)	1	1	1	0	0	0	1	0	0	1	0	1	0	0	1	0	7	44
Ribeiro et al. ⁵⁴ (2012)	0	0	0	0	0	0	0	0	0	1	0	0	0	1	1	0	3	19
Smith et al. ⁵⁵ (2012)	0	0	1	1	0	0	1	0	1	1	0	1	0	1	1	0	8	50
Zeng et al. ⁵⁶ (2013)	1	0	0	1	0	0	1	0	1	0	0	1	0	1	1	0	7	44
Total	15	2	16	15	5	7	22	3	17	19	1	18	8	18	19	12	/	/

[SD]: Study design; [R]: Randomization; [SS]: Sample Size; [SC]: Selection criteria; [C]: Control; [FU]: Follow-up; [OB]: Objective; [DO]: Dropouts; [IV]: Intervention; [A]: Analysis; [B]: Blinding; [RE]: Reliability; [S]: Segmentation; [ST]: Statistical; [DP]: Data Presentation; [Con.]: Conclusion

Table 3c: Quality assessment and summary of findings across studies (GRADE)

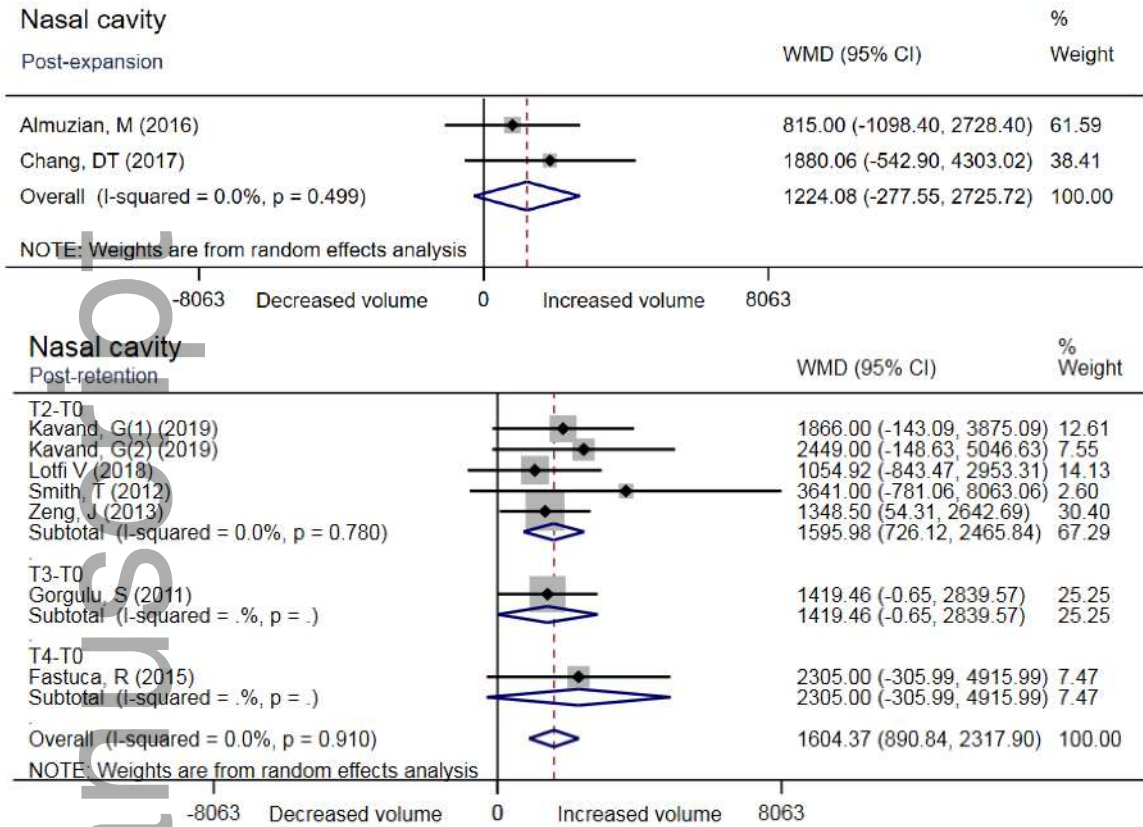
Quality assessment							Summary of findings		
Number of studies	Study design	Risk of bias	Inconsistency	Indirectness	Imprecision	Publication bias (Egger's test)	Number of patients	Difference in means (95% CI)	Quality
Nasal cavity volume changes after expansion									
2	Observational studies	Serious	Not serious (I ² = 0.0%, P = 0.499)	Not serious	Not serious	N/A	35	1224 mm ³ [-278, 2726]	⊕⊕⊕○ Moderate
Nasal cavity volume changes after retention (follow up: range 3 to 12 months)									
6	Observational studies	Serious	Not serious (I ² = 0.0%, P = 0.910)	Not serious	Not serious	Not serious (P = 0.110)	142	1604 mm ³ [-891, 2318]	⊕○○○ Very low
Nasopharynx volume changes after expansion									
5	Observational studies	Not serious	Not serious (I ² = 27.6%, P = 0.238)	Not serious	Not serious	Not serious (P = 0.990)	135	829 mm ³ [441, 1217]	⊕⊕⊕○ Moderate
Nasopharynx volume changes after retention (follow up: 3 months)									
5	Observational studies	Serious	Not serious (I ² = 28.0%, P = 0.224)	Not serious	Not serious	Not serious (P = 0.544)	147	492 mm ³ [70, 913]	⊕⊕⊕○ Moderate
Oropharynx volume changes after expansion									
6	Observational studies	Serious	Serious (I ² = 56.5%, P = 0.042)	Not serious	Not serious	Not serious (P = 0.478)	139	1424 mm ³ [197, 2651]	⊕⊕○○ Low
Oropharynx volume changes after retention (follow up: 3 months)									
7	Observational studies	Serious	Not serious	Not serious	Not serious	Not serious	184	579 mm ³	⊕○○○

studies	(I ² = 36.2%, P = 0.139)	(P = 0.753)	[-301, 1459]	Very low
---------	-------------------------------------	-------------	--------------	----------

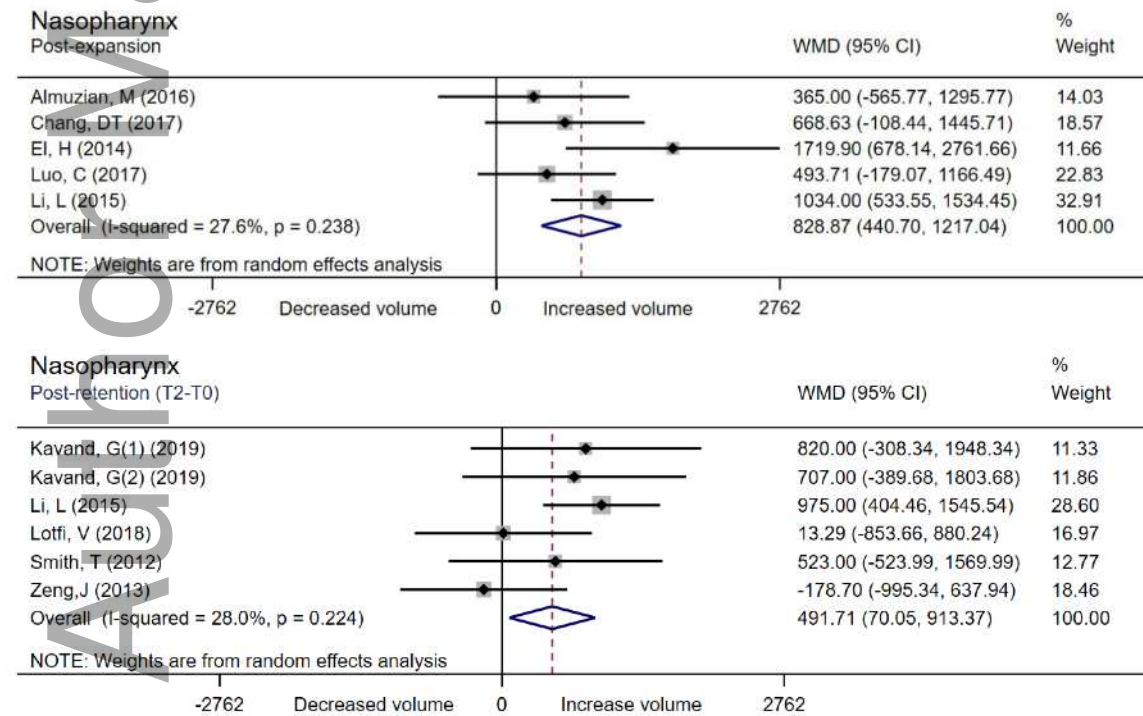
N/A: not available

Author Manuscript





(a)



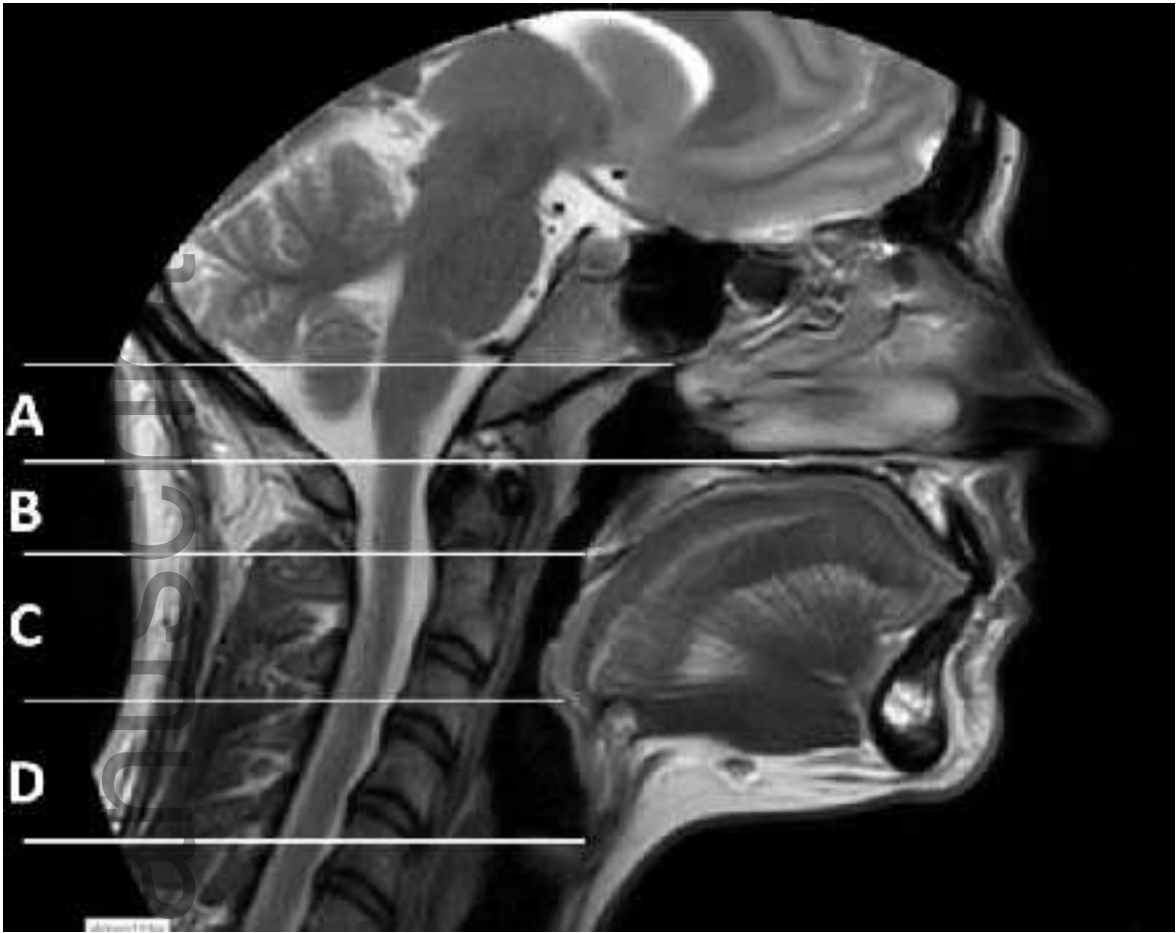
(b)



ocr_12378_f3.1.tif



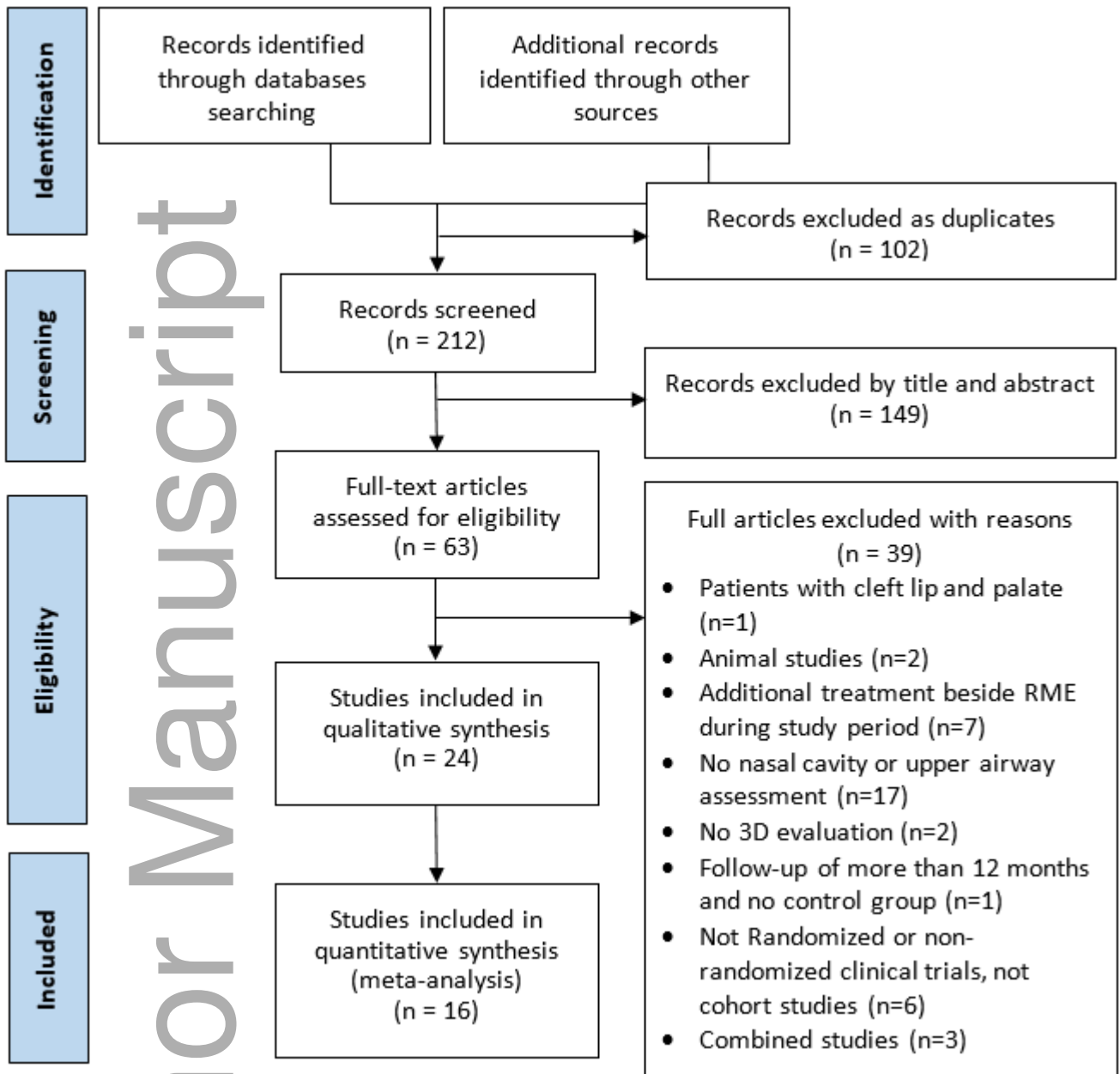
ocr_12378_f3.2.tif



ocr_12378_f1.tif

Author M

Author Manuscript



ocr_12378_f2.tif