



Minerva Access is the Institutional Repository of The University of Melbourne

Author/s:

Lane, J;Price, J;Moore, A;Dandrieux, JRS;Clifford, C;Curran, K;Choy, K;Cannon, C

Title:

Low-grade gastrointestinal lymphoma in dogs: 20 cases (2010 to 2016)

Date:

2018-01-01

Citation:

Lane, J., Price, J., Moore, A., Dandrieux, J. R. S., Clifford, C., Curran, K., Choy, K. & Cannon, C. (2018). Low-grade gastrointestinal lymphoma in dogs: 20 cases (2010 to 2016). *Journal of Small Animal Practice*, 59 (3), pp.147-153. <https://doi.org/10.1111/jsap.12769>.

Persistent Link:

<https://hdl.handle.net/11343/293577>

Lane Jeanne (Orcid ID: 0000-0002-7195-3736)
Dandrieux Julien (Orcid ID: 0000-0001-6308-8749)
Cannon Claire (Orcid ID: 0000-0002-0656-6916)

Low grade gastrointestinal lymphoma in dogs: twenty cases (2010 – 2016)

J. Lane¹, J. Price², A. Moore³, J.R.S. Dandrieux⁴, C. Clifford⁵, K. Curran⁶, K. Choy⁷ and C. Cannon⁸

¹University of Tennessee Veterinary Medical Center, Knoxville, TN 37996, USA

²University of Tennessee Office of Information Technology, Knoxville, TN 37996, USA

³Veterinary Oncology Consultants, Lake Innes, NSW 2446, Australia

⁴University of Melbourne, Werribee, Victoria 3010, Australia

⁵Hope Veterinary Specialists, Malvern, PA 19355, USA

⁶Oregon State University, Corvallis, OR 97331, USA

⁷Seattle Veterinary Specialists, Kirkland, WA 98034, USA

⁸University of Minnesota College of Veterinary Medicine, St. Paul, MN 55108, USA

Corresponding author:

Jeanne Lane

C247 Veterinary Medical Center

This is the author manuscript accepted for publication and has undergone full peer review but has not been through the copyediting, typesetting, pagination and proofreading process, which may lead to differences between this version and the [Version of Record](#). Please cite this article as doi: [10.1111/jsap.12769](https://doi.org/10.1111/jsap.12769)

2407 River Drive

Knoxville, TN 37996

865-974-8387

Email: jeannelanedvm@gmail.com

No conflicts of interest have been declared.

Contributing Institutions:

Records of dogs diagnosed between 2010 and 2016 at The University of Tennessee Veterinary Medical Center, Knoxville, TN, USA; The University of Minnesota College of Veterinary Medicine, St. Paul, MN, USA; Veterinary Oncology Consultants, Lake Innes, Australia; BluePearl Veterinary Partners, New York, NY, USA; Oregon State University, Corvallis, OR, USA; University of Adelaide, Adelaide, Australia; Veterinary Specialty Center of Delaware, New Castle, DE, USA; Coral Springs Animal Hospital, Coral Springs, FL, USA; Seattle Veterinary Specialists, Kirkland, WA, USA; Animal Emergency and Referral Associates, Fairfield, NJ, USA; University of Melbourne, Werribee, Victoria, Australia; Melbourne Veterinary Specialist Centre, Glen Waverly, Victoria, Australia; and Summit Veterinary Referral Center, Tacoma, WA, USA were retrospectively reviewed.

Acknowledgements:

The authors thank Joshua Lachowicz (BluePearl Veterinary Partners, New York, NY, USA), Anne Peaston (University of Adelaide, Adelaide, Australia), Rachael Gaeta (Veterinary Specialty Center of Delaware, New Castle, DE, USA), Amanda Foskett and Christine Manley (The Oncology Service, Leesburg, VA, USA), Francisco Alvarez (Coral Springs Animal Hospital, Coral Springs, FL, USA), Seth Glasser (Animal Emergency and Referral Associates, Fairfield, NJ, USA), Kate Heading (Melbourne Veterinary Specialist Centre, Glen Waverly, Victoria, Australia), Laura Brockley (Victorian Animal Cancer Care, Melbourne, Victoria, Australia), and Sarah Gillings (Summit Veterinary Referral Center, Tacoma, WA, USA) for contributing cases to this study. The authors also thank the Animal Cancer Care and Research Program at the University of Minnesota College of Veterinary Medicine for providing funding for immunohistochemistry.

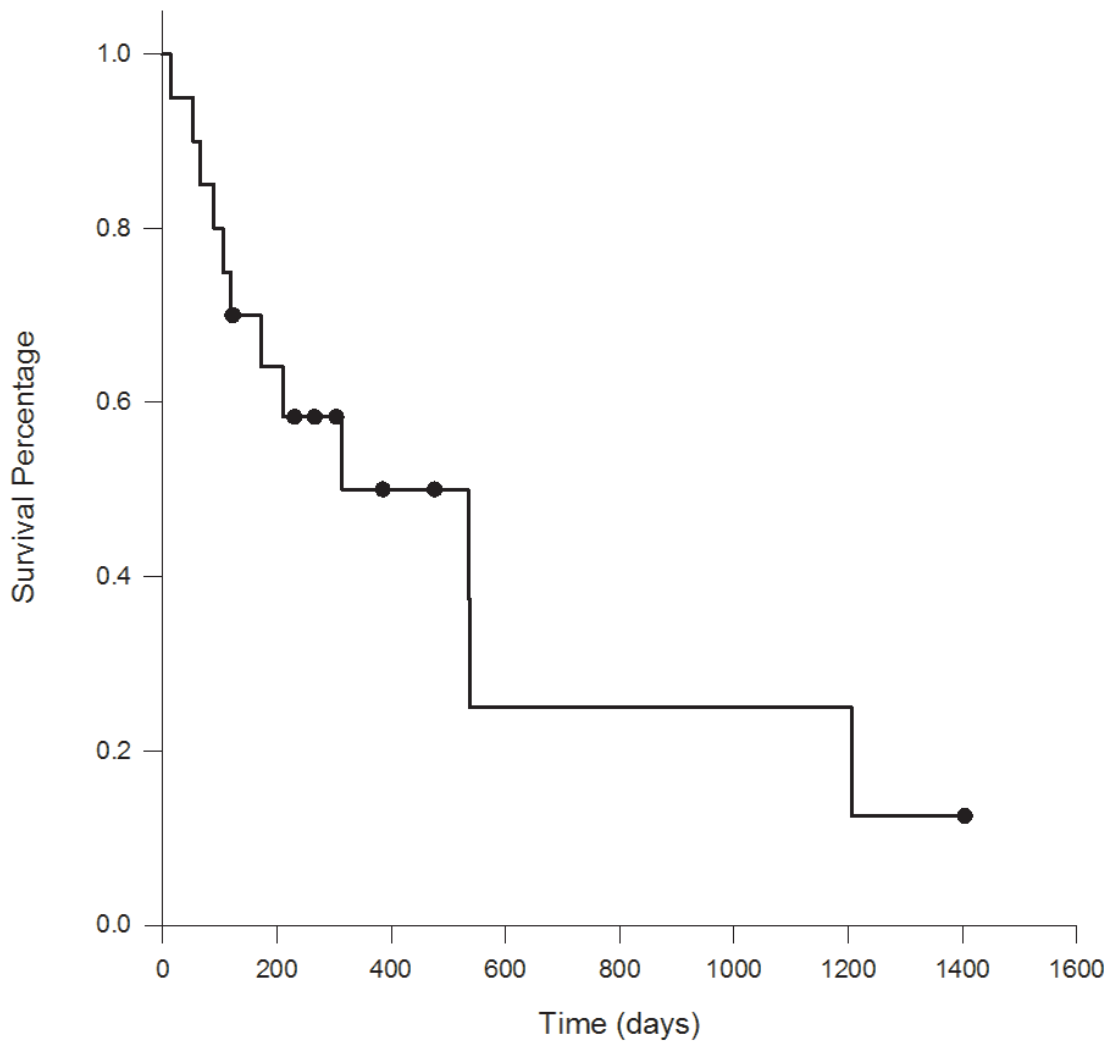


Figure 1.TIF
This article is protected by copyright. All rights reserved.

Structured Summary

OBJECTIVES: To report the clinical presentation, treatment, and prognosis of dogs with low-grade gastrointestinal lymphoma.

METHODS: Cases were solicited from the American College of Veterinary Internal Medicine Oncology Diplomate listserv. Medical records of dogs with low-grade gastrointestinal lymphoma diagnosed via a combination of histology and immunohistochemistry with or without analysis of polymerase chain reaction for antigen receptor rearrangement (PARR) were included. Signalment, clinical signs, diagnostic test results, chemotherapy protocol, response to treatment, date of first progression, rescue therapies, and date and cause of death or last follow-up visit were collected.

RESULTS: Twenty cases were included. Males and small breed dogs were overrepresented. Frequent clinical signs included weight loss, vomiting, and diarrhoea. Most lymphomas were T-cell phenotype (95%), and epitheliotropism was commonly described (60%). Immunohistochemistry, PARR, or both were frequently required for definitive diagnosis. Two dogs had resection of an intestinal mass, and all dogs were treated with chemotherapy; chlorambucil and prednisone were most commonly prescribed. Overall response rate was 70% and median survival time was 424 days (95% CI: 105 – 1206 days).

CLINICAL SIGNIFICANCE: Low-grade gastrointestinal lymphoma appears to be a rare condition in dogs, and treatment with chemotherapy results in a high response rate and favorable survival times. Further study is needed to determine its prevalence in dogs with chronic enteropathies.

Key Words: canine, gastrointestinal, enteropathy, lymphoma, chlorambucil

Introduction

Gastrointestinal lymphoma represents 5-7% of all lymphomas in dogs. Most dogs present with disease confined to the gastrointestinal tract, with a minority displaying multicentric involvement (Couto *et al.* 1989, Rassnick *et al.* 2009). A higher frequency in male dogs was reported in one study (Couto *et al.* 1989), while others have found no sex predilection (Frank *et al.* 2007, Rassnick *et al.* 2009). Breed predispositions have been suggested in shar peis and boxers (Coyle & Steinberg 2004). Among lymphomas of the small intestinal tract, the T-cell phenotype is most common, and epitheliotropism is commonly identified on histopathology (Coyle & Steinberg 2004, Steinberg *et al.* 1995).

In most reported cases, primary gastrointestinal lymphoma in dogs is large cell and high-grade, with small cell, low-grade lymphomas of the canine gastrointestinal tract rarely described (Carrasco *et al.* 2015, Couto *et al.* 1989, Nakashima *et al.* 2015, Ozaki *et al.* 2006). Several studies have evaluated treatment and response in dogs with high-grade gastrointestinal lymphoma. The prognosis with an injectable multi-agent chemotherapy protocol is reported to be poor, with MST ranging from 13 to 77 days (Frank *et al.* 2007, Rassnick *et al.* 2009). In one study, dogs with diarrhoea had a worse prognosis as compared to those without (Rassnick *et al.* 2009). The survival time for dogs with low-grade gastrointestinal lymphoma is reported to be much better than the high-grade form (Nakashima *et al.* 2015), but it is not well-studied.

The primary objective of this study was to describe the clinical presentation and treatment of dogs with histologically-confirmed low-grade gastrointestinal lymphoma. A secondary objective was to identify prognostic factors influencing progression-free survival and overall survival time.

Materials and methods

The American College of Veterinary Internal Medicine Oncology Diplomate listserv was solicited to recruit cases for this retrospective study. Medical records of dogs with a diagnosis of low grade gastrointestinal lymphoma (*via* a combination of histology and immunohistochemistry, polymerase chain reaction for antigen receptor rearrangement (PARR), or both) were included. Records of dogs diagnosed between 2010 and 2016 at *** were retrospectively reviewed.

Information gathered from the medical record included signalment, weight, dates of diagnosis and treatment initiation, presenting clinical signs, duration of clinical signs, previous treatments, concurrent diseases, physical examination findings, laboratory test results (including complete blood count, serum chemistry, urinalysis, folate, cobalamin, trypsin-like immunoreactivity, and pancreatic lipase immunoreactivity levels, and faecal analysis when available), imaging findings (thoracic radiographs and abdominal ultrasound), method of biopsy (endoscopic or full-thickness), sites biopsied, immunohistochemistry and results of PARR testing, location of lymphoma within the gastrointestinal tract, chemotherapy protocol, response to treatment, date of first progression, rescue therapies, and date and cause of death or last follow-up visit. Results of laboratory testing were classified as normal or abnormal by comparing results to the established reference range for that particular facility. Biopsy samples were not re-evaluated.

Response to treatment was reported by the veterinarian and, in most cases, was determined by monitoring of clinical signs. In some cases, follow-up abdominal imaging was also assessed. In cases evaluated by monitoring of clinical signs alone, complete response (CR) was defined as resolution of all clinical signs (*i.e.* vomiting, diarrhoea, weight loss), partial response (PR) was defined as improvement but not resolution of clinical signs for a minimum of 6 weeks, and no response (NR) was defined as no improvement in clinical signs. For patients with an initial response to treatment, progressive disease (PD) was defined as relapse or worsening of clinical signs. Among patients evaluated with recheck

abdominal ultrasound, response (CR, PR, stable disease [SD], and PD) was classified using Veterinary Cooperative Oncology Group criteria (Nguyen *et al.* 2013).

Categorical data are presented as either percentages or ratios. Continuous data are presented as median (range). Progression-free survival (PFS) was defined as the time from initiation of treatment until recurrence or progression of clinical signs consistent with lymphoma. Dogs that had not relapsed during the study period were censored at the last date they were evaluated by the veterinarian. Survival time was defined as the time from the initiation of treatment until natural death or euthanasia. Dogs that were lost to follow-up or still alive at the end of the study period were censored. All deaths were attributed to lymphoma, because necropsy was not performed in any case.

Survival analysis was performed using the Kaplan-Meier product limit method to estimate median PFS and median survival time (MST). Using univariate analysis, potential prognostic factors were analysed to determine their effect on PFS and MST. These included sex, weight, clinical signs (presence of vomiting, diarrhoea, and weight loss), duration of clinical signs, pretreatment with steroids, hypoalbuminaemia, and initial treatment with chlorambucil and a glucocorticoid versus other forms of chemotherapy. The log-rank test was used to compare survival distributions for PFS and MST between factors. Due to the small number of dogs in each group and high number of dogs that were censored, multivariate analysis was not performed. A value of $P < 0.05$ was considered significant. Calculations were performed using standard statistical software (SAS version 9.4 for Windows, Cary, NC).

Results

A total of 20 dogs were included in the study. Table 1 summarises signalment, clinical signs, and pre-treatment diagnostics. There were 13 castrated males (65%) and 7

spayed females (35%). The median age at presentation was 9.5 years (range: 4.2– 15.1 years), and the median weight was 9.9 kg (range: 3.7 – 44 kg). The majority of dogs (19/20; 95%) showed clinical signs at the time of presentation, and the median duration of clinical signs before presentation was 54 days (range: 1 – 420 days) for the 18 dogs in which this information was recorded.

Two dogs (10%) had a history of chronic enteropathy: lymphangiectasia in Case 17 (diagnostic method not recorded) and inflammatory bowel disease in Case 19 (diagnosed as lymphoplasmacytic enteritis *via* endoscopic biopsies). Concurrent diseases were diagnosed in 3 dogs (15%) at the time of diagnosis of low grade gastrointestinal lymphoma and included chronic lymphocytic leukaemia (Case 19), splenic marginal zone lymphoma (Case 4), and a high-grade soft tissue sarcoma (which was treated with surgical excision) (Case 8).

Four dogs (4/20; 20%) had been previously treated with corticosteroids. Case 19 had been on long-term prednisone at 1 mg/kg once daily for previously diagnosed conditions (hypoadrenocorticism and inflammatory bowel disease). The remaining 3 dogs (Cases 1, 2, and 20, respectively), had received a steroid trial (1 mg/kg once daily tapered over 2 weeks, 1 mg/kg once daily for 5 months, and 0.5 mg/kg once daily for 1 month) before diagnosis of low-grade gastrointestinal lymphoma, and clinical signs persisted with no apparent response to corticosteroids in all 3 dogs.

Frequently observed abdominal ultrasound abnormalities included thickening of the *muscularis* layer of the small intestinal wall (6/18; 33.3%), mesenteric lymphadenomegaly (5/18; 27.8%), and a splenic mass or nodule (4/18; 22.2%). Enlarged mesenteric lymph nodes were sampled *via* fine needle aspiration in 2 dogs; cytology was consistent with lymphoid neoplasia in Case 1 and hyperplasia in Case 8.

Histopathological samples were obtained in all dogs either *via* laparotomy (11/20; 55%) or endoscopy (9/20; 45%). In addition to the acquisition of full-thickness gastrointestinal biopsies, additional procedures in dogs undergoing laparotomy included resection and anastomosis of a mass affecting the intestine (2/11; 18.2%) and splenectomy (2/11; 18.2%). Of the dogs that underwent endoscopy, most procedures evaluated the upper gastrointestinal tract only (7/9; 77.8%), while 2 dogs had both upper and lower endoscopy (2/9; 22.2%). No complications associated with laparotomy or endoscopy were reported. Tables 2 and 3 summarise the findings in patients undergoing laparotomy and endoscopy, respectively.

Chemotherapeutic protocols varied between dogs. Most dogs were treated with chlorambucil and a glucocorticoid (15/20; 75%). The median dose of chlorambucil was 5 mg/m² q24-48 hours (range of 1.8 – 8 mg/m² q24-48 hours). Chemotherapeutic protocols and response are summarised in Table 4. Six dogs were re-evaluated via abdominal ultrasound after therapy was initiated. CR with resolution of intestinal thickening and lymphadenomegaly was observed in 2 dogs (Cases 13 and 16). In Case 18, no abnormalities were seen on abdominal ultrasound before or after initiating chemotherapy, but clinical signs in this dog completely resolved. In the 2 dogs (Cases 7 and 8) that had undergone resection and anastomosis of an intestinal mass, both had no abnormalities found on post-operative imaging, including resolution of mesenteric lymphadenomegaly in Case 8. In Case 14, PD was noted 6 weeks after starting lomustine and prednisone therapy. Overall, 5/6 (83.3%) dogs undergoing recheck abdominal ultrasound responded to treatment. Among the 14 dogs for which response was evaluated based on clinical signs alone, complete resolution of clinical signs was noted in 7 dogs (50%) and partial resolution in 2 dogs (14.3%) for an overall response rate of 64.3%. In 5 dogs there was no clinical response to initial therapy. Rescue protocols and response are also summarised in Table 4.

At the end of the study period, 8 dogs were still alive (40%), 12 dogs died or were euthanased with clinical signs attributed to lymphoma (60%), and no dogs were lost to follow-up. Necropsy was not performed in any dog. The median follow-up time was 285 days (range: 122 – 1404 days). The overall MST was 424 days (95% CI: 105 – 1206 days) (Figure 1). The 1-year survival rate was 55%. Dogs achieving CR or PR had a MST of 535 days (95% CI: 172 – 1206 days), while dogs with NR to chemotherapy had a MST of 92 days (95% CI: 14 – 537 days).

On univariate analysis of this small sample population, there was no statistically significant association between any of the evaluated factors (sex, weight, presence of vomiting, diarrhea, or weight loss, duration of clinical signs, pretreatment with steroids, hypoalbuminemia, initial treatment with chlorambucil and a glucocorticoid versus other forms of chemotherapy) and either median PFS or MST.

Discussion

The objective of the current study was to describe the clinical presentation, treatment, and prognosis in dogs with low-grade gastrointestinal lymphoma. This form of gastrointestinal lymphoma occurs over a wide age range (4.2 – 15.1 years), and small dogs (median weight of 9.9kg) appeared over-represented in this study, although the comparator population against which to judge this is not well defined. As has been suggested for high-grade gastrointestinal lymphoma in dogs (Couto *et al.* 1989), male dogs might be predisposed to low-grade gastrointestinal lymphoma, with a male:female ratio in the current study of 1.9:1. The majority of dogs presented with clinical signs of gastrointestinal disease, with weight loss, vomiting, and diarrhea most commonly reported. Results of this study also suggest that low-grade gastrointestinal lymphoma in dogs is typically T-cell in phenotype and often exhibits epitheliotropism.

Unlike high-grade gastrointestinal lymphoma in dogs, which is associated with a short response duration to chemotherapy and survival times of 13 to 77 days (Frank *et al.* 2007, Rassnick *et al.* 2009), most dogs with low-grade gastrointestinal lymphoma appear to have a positive response to chemotherapy (70% overall response rate) with a MST of 535 days in dogs responding to treatment. Overall MST in this study, including dogs that did not respond to their initial treatment protocol, was 424 days.

In this patient population, biopsy samples were obtained *via* laparotomy in 11 dogs and *via* endoscopy in 9 dogs, 7 of which had upper endoscopy alone. Studies in cats with low-grade gastrointestinal lymphoma and in dogs with chronic gastrointestinal signs have demonstrated that full-thickness biopsies might be superior to endoscopically-obtained biopsies to obtain adequate tissue samples to reach a definitive diagnosis (Evans *et al.* 2006, Scott *et al.* 2011). In cats, sampling of the ileum can be critical in some cases to obtain a diagnosis of low-grade gastrointestinal lymphoma (Kleinschmidt *et al.* 2006). Additionally, the importance of ileal sampling has been demonstrated in dogs with chronic small intestinal enteropathies (Procoli *et al.* 2013). In the current study, low-grade gastrointestinal lymphoma was diagnosed in various portions of the gastrointestinal tract ranging from stomach to ileum. In 3 dogs (27.3%) that underwent laparotomy, only samples from the ileum were confirmatory for lymphoma, further suggesting that ileal sampling might also be critical in dogs. Given this finding, it is possible that the diagnosis of low-grade gastrointestinal lymphoma might be overlooked if patients undergo upper endoscopy alone. Ileal sampling may be achieved *via* laparotomy, laparoscopy, or by performing both upper and lower gastrointestinal endoscopy.

While all dogs in the current study were ultimately confirmed to have low-grade gastrointestinal lymphoma, the initial histopathology was not always definitive for lymphoma. In 8 dogs (40%; 6 dogs that underwent surgical biopsies and 2 dogs that underwent endoscopic biopsies), the diagnosis was confirmed on initial evaluation of the

biopsy, while in the remaining 12 dogs (60%; 5 dogs that underwent surgical biopsies and 7 dogs that underwent endoscopic biopsies), histopathology indicated lymphocytic enteritis with possible or suspected lymphoma. In these dogs, the diagnosis of low-grade gastrointestinal lymphoma was established with immunohistochemistry (IHC) and, in 7 of these 12 dogs, the diagnosis was further confirmed with a monoclonal neoplastic cell population identified on PARR analysis. In 2 cases, the pathologist reported that IHC enabled identification of clusters of T-cells present within the mucosa that were not recognised on routine examination. As has been suggested in previous studies of canine gastrointestinal lymphoma (Carrasco *et al.* 2015, Nakashima *et al.* 2015) and in a study of low-grade gastrointestinal lymphoma in cats (Kiupel *et al.* 2011), these findings indicate that IHC, PARR, or both are often necessary to differentiate lymphocytic inflammation from low-grade lymphoma in cases of chronic enteropathy in dogs. Development of standardised histologic criteria and a routine diagnostic algorithm for canine intestinal biopsies is recommended to ensure that a diagnosis of low grade lymphoma is not overlooked.

Interestingly, 3 of the 20 dogs in the current study had a gastrointestinal mass (1 gastric mass, 1 jejunal mass, and 1 mass at the jejunoileal junction). The dog with the gastric mass underwent superficial endoscopic biopsy only, but both the jejunal and jejunoileal masses were histologically confirmed to be a transmural low-grade gastrointestinal lymphoma. In cats with gastrointestinal lymphoma, transmural lymphomas are typically associated with a large-cell, high-grade phenotype (Moore *et al.* 2012). While focal transmural intestinal masses have occasionally been described in cats with low-grade gastrointestinal lymphoma (Lingard *et al.* 2009), our findings may suggest that this is a more common phenomenon in dogs with this disease.

Two dogs in this study had additional lymphoid neoplasms identified at the time of their lymphoma diagnosis; chronic lymphocytic leukaemia (Case 19) and splenic marginal zone lymphoma (Case 4). The documentation of additional low-grade lymphoid

malignancies raises the question of whether these cancers may be related within the patient. In both cases, the low-grade gastrointestinal lymphoma was confirmed to be T-cell on IHC. Flow cytometry in Case 19 confirmed T-cell leukaemia, and therefore it is possible that these circulating lymphocytes represent extension of gastrointestinal lymphoma. In Case 4, however, IHC of the spleen after splenectomy confirmed a B-cell marginal zone lymphoma, and therefore two separate lymphoid malignancies were suspected in this case.

A high number of dogs (50%) in this study were hypoalbuminaemic at presentation. This highlights the importance of considering low-grade gastrointestinal lymphoma as a differential diagnosis in dogs with protein-losing enteropathy (PLE), especially if there is a poor response to standard treatment. In one study, a longer clinical response was observed in dogs with PLE treated with a combination of chlorambucil and prednisolone as compared to dogs treated with azathioprine and prednisolone, and the authors proposed that some of these dogs may have had an underlying low grade lymphoma (Dandrieux *et al.* 2013). Prospective studies are needed to determine the prevalence of low-grade gastrointestinal lymphoma in dogs presenting with PLE.

Additionally, hypocobalaminaemia was documented in 4 of the 10 dogs tested in this current study. As lymphoma in many dogs involved the ileum, decreased absorption of cobalamin and subsequent hypocobalaminaemia might be an important comorbidity. Hypocobalaminaemia is reported to be a negative prognostic factor for survival in dogs with chronic enteropathies (Allenspach *et al.* 2007), and therefore measurement of cobalamin and supplementation if indicated may be an important component of treatment for dogs with low-grade gastrointestinal lymphoma.

There are several limitations to this study based on its multi-institutional retrospective design and small sample size. In the majority of dogs, response to treatment was based on monitoring of clinical signs alone. It is important to note that gastrointestinal side effects from chemotherapy may mimic symptoms of progressive gastrointestinal

lymphoma, and therefore assumptions made regarding response to treatment may have been inaccurate. Additionally, there was considerable variability in treatment protocols and frequency of follow-up. Dosing, schedule, and duration of chemotherapy were not standardised and varied widely amongst dogs. Finally, because 40% of the study population was still alive at last follow-up, there was a high degree of censoring which limits the reliability of statistical analysis and precluded multivariable analysis. Low-grade gastrointestinal lymphoma appears to be a rare cancer in dogs, but it might be under-recognised. A prospective, multi-institutional study evaluating response to standardised protocols would allow further elucidation of the prevalence of this cancer, prognostic factors, and the most effective treatment options.

In conclusion, canine low-grade gastrointestinal lymphoma typically affects small breed, male dogs and is most frequently T-cell in phenotype. Treatment with chemotherapy results in a high response rate and favorable survival times.

References

- Allenspach, K., Wieland, B., Grone, A., *et al.* (2007) Chronic enteropathies in dogs: evaluation of risk factors for negative outcome. *Journal of Veterinary Internal Medicine* 21, 700-708
- Carrasco, V., Rodriguez-Bertos, A., Rodriguez-Franco, F., *et al.* (2015) Distinguishing intestinal lymphoma from inflammatory bowel disease in canine duodenal endoscopic biopsy samples. *Veterinary Pathology* 52, 668-675
- Couto, C. G., Rutgers, H. C., Sherding, R. G., *et al.* (1989) Gastrointestinal lymphoma in 20 dogs. A retrospective study. *Journal of Veterinary Internal Medicine* 3, 73-78
- Coyle, K. A. and Steinberg, H. (2004) Characterization of lymphocytes in canine gastrointestinal lymphoma. *Veterinary Pathology* 41, 141-146

- Dandrieux, J. R. S., Noble, P. J. M., Scase, T. J., *et al.* (2013) Comparison of a chlorambucil-prednisolone combination with an azathioprine-prednisolone combination for treatment of chronic enteropathy with concurrent protein-losing enteropathy in dogs: 27 cases (2007-2010). *Journal of the American Veterinary Medicine Association* 242, 1705-1714
- Evans, S. E., Bonczynski, J. J., Broussard, J. D., *et al.* (2006) Comparison of endoscopic and full-thickness biopsy specimens for diagnosis of inflammatory bowel disease and alimentary tract lymphoma in cats. *Journal of the American Animal Hospital Association* 229, 1447-1450
- Frank, J. D., Reimer, S. B., Kass, P. H., *et al.* (2007) Clinical outcomes of 30 cases (1997-2004) of canine gastrointestinal lymphoma. *Journal of the American Animal Hospital Association* 43, 313-321
- Kiupel, M., Smedley, R. C., Pfent, C., *et al.* (2011) Diagnostic algorithm to differentiate lymphoma from inflammation in feline small intestinal biopsy samples. *Veterinary Pathology* 48, 212-222
- Kleinschmidt, S., Meneses, F., Nolte, I., *et al.* (2006) Retrospective study on the diagnostic value of full-thickness biopsies from the stomach and intestines of dogs with chronic gastrointestinal disease symptoms. *Veterinary Pathology* 43, 1000-1003
- Lingard, E. A., Briscoe, K., Beatty, J. A., *et al.* (2009) Low-grade alimentary lymphoma: clinicopathological findings and response to treatment in 17 cases. *Journal of Feline Medicine and Surgery* 11, 692-700
- Moore, P. F., Rodriguez-Bertos, A., and Kass, P. H. (2012) Feline gastrointestinal lymphoma: mucosal architecture, immunophenotype, and molecular clonality. *Veterinary Pathology* 49, 658-668
- Nakashima, K., Hiyoshi, S., Ohno, K., *et al.* (2015) Prognostic factors in dogs with protein-losing enteropathy. *The Veterinary Journal* 205, 28-32

- Nguyen, S. M., Thamm, D. H., Vail, D. M., *et al.* (2013) Response evaluation criteria for solid tumours in dogs (v1.0): a Veterinary Cooperative Oncology Group (VCOG) consensus document. *Veterinary and Comparative Oncology* 13, 176-183
- Ozaki, K., Yamagami, T., Nomura, K., *et al.* (2006) T-cell lymphoma with eosinophilic infiltration involving the intestinal tract in 11 dogs. *Veterinary Pathology* 43, 339-344
- Procoli, F., Motskula, P. F., Keyte, S. V., *et al.* (2013) Comparison of histopathologic findings in duodenal and ileal endoscopic biopsies in dogs with chronic small intestinal enteropathies. *Journal of Veterinary Internal Medicine* 27, 268-274
- Rassnick, K. M., Moore, A. S., Collister, N. E., *et al.* (2009) Efficacy of combination chemotherapy for treatment of gastrointestinal lymphoma in dogs. *Journal of Veterinary Internal Medicine* 23, 317-322
- Scott, K. D., Zoran, D. L., Mansell, J., *et al.* (2011) Utility of endoscopic biopsies of the duodenum and ileum for the diagnosis of inflammatory bowel disease and small cell lymphoma in cats. *Journal of Veterinary Internal Medicine* 25, 1253-1257
- Steinberg, H., Dubielzig, R. R., Thomson, J., *et al.* (1995) Primary gastrointestinal lymphosarcoma with epitheliotropism in three Shar-Pei and one Boxer dog. *Veterinary Pathology* 32, 423-426

Captions to Figures

Figure 1: Kaplan-Meier analysis of survival time for 20 dogs with low grade gastrointestinal lymphoma. Dogs still alive at the end of the study period were censored. All deaths were attributed to lymphoma, as a necropsy was not performed in any case. The median survival time was 424 days (95% CI: 105 – 1206 days). Solid circles represent censored dogs.