University Library

MINERVA ACCESS

A gateway to Melbourne's research publications

Minerva Access is the Institutional Repository of The University of Melbourne

Author/s:
Fletcher, EL

Title:
Contribution of microglia and monocytes to the development and progression of age related macular degeneration

Date:
2020-03-01

Citation:
Fletcher, E. L. (2020). Contribution of microglia and monocytes to the development and progression of age related macular degeneration. Ophthalmic and Physiological Optics, 40 (2), pp.128-139. https://doi.org/10.1111/opo.12671.

Persistent Link:
https://hdl.handle.net/11343/275365

PROF. ERICA FLETCHER (Orcid ID : 0000-0001-9412-9523)

Author Manuscript

Article type : Invited Review

Title page

Full title: Contribution of microglia and monocytes to the development and progression of age related macular degeneration

Running head: The immune system and AMD

Author's name and institutional affiliation: Erica L Fletcher

Department of Anatomy and Neuroscience, University of Melbourne, Parkville, Victoria, Australia

Corresponding author:
Erica L Fletcher
E-mail: elf@unimelb.edu.au

Keywords: microglia, photoreceptor, retinal degeneration, age related macular degeneration, age

This is the author manuscript accepted for publication and has undergone full peer review but has not been through the copyediting, typesetting, pagination and proofreading process, which may lead to differences between this version and the Version of Record. Please cite this article as doi: 10.1111/OPO.12671

This article is protected by copyright. All rights reserved

Author contribution: The author certifies that they have participated sufficiently in the work to take public responsibility for the content, including participation in the concept, design, analysis and writing or revision of the manuscript.

Abstract

Purpose: Age related macular degeneration (AMD) is the leading cause of irreversible vision loss in industrialised nations. Based on genetics, as well as proteome analysis of drusen, the role the innate immune system in the development and/or progression of the disease is well established. Mononuclear phagocytes, such as microglia and monocytes, play critical roles in innate immunity. Here, the role of retinal microglia in mediating normal retinal function, and how these cells change with age is discussed, so as to understand their role in the development and progression of AMD.

Recent findings: It is now known that microglia dynamically survey the neural environment, responding rapidly to even the most subtle neural injury. The dynamic and phagocytic roles of microglia can change with age contributing to alteration in the response of these cells to damage with age. Accumulation of innate immune cells in the subretinal space is a hallmark feature of the development of AMD, reflecting either an increase in migration of monocytes into the retina, or a failure of immune cell elimination from the retina. Furthermore, changes in phagocytic ability of immune cells could contribute to the accumulation of drusen deposits in the posterior eye.

Summary: An overview of how retinal microglia maintain retinal homeostasis under normal conditions is provided, and then how they contribute to each stage of AMD. In addition, circulating monocytes are altered in those with AMD, contributing to the overall inflammatory state. Understanding the role of cells of the innate immune system in AMD may uncover novel therapeutic targets with which to reduce either the development or progression of disease.

Author Manuscript

1. Introduction

Age related macular degeneration (AMD) is the leading cause of irreversible vision loss in industrialised nations[1]. The early stages of this disease affect approximately one in seven people of European descent over 50 years of age and are characterised by the formation of

This article is protected by copyright. All rights reserved

deposits called drusen, within the posterior eye [2]. Of those with signs of early stage disease, approximately one in seven develop advanced, vision threatening disease. The majority of people with advanced disease develop geographic atrophy - characterised by the loss of retinal pigment epithelial cells (RPE) and photoreceptors. In contrast, approximately 10% of people develop neovascular AMD, characterised by pathological growth of blood vessels at the macula[1, 2]. In view of the long period of time between when drusen are first observed and the development of advanced disease there is significant opportunity to intervene to prevent progression of the disease. Understanding the underlying causes of the development of disease and the mechanisms involved in progression are critical for development of new therapies.

The innate immune system has been implicated in the development of advanced AMD[3, 4]. It is the part of the body's immune system that is non-specific that can respond rapidly to the presence of any antigen. In the retina, innate immune functions are mediated by mononuclear phagocytes, such as microglia, monocytes and macrophages, as well as a range of chemical mediators of immune cell function such as complement, chemokines and cytokines [5]. The importance of innate immunity in the development of AMD is exemplified by the accumulation of complement components within drusen deposits[6, 7] and also the widespread inheritance of mutations in genes affecting the complement system including single nucleotide polymorphisms in Complement Factors H, B and I as well as other components such as C3[4, 8]. More recently, the cellular mediators of the innate immune system, especially mononuclear phagocytes, have been implicated in the development of AMD [9]. Although they play critical roles in maintaining normal retinal function, they can change with age, genetics or disease[9]. It is generally viewed that the accumulation of mononuclear phagocytes within the normally immune privileged subretinal space with age leads to deleterious inflammatory changes in the posterior eye affecting the integrity of RPE and photoreceptors[9]. Understanding how mononuclear phagocytes contribute to the different stages of disease is therefore important for not only understanding disease mechanisms, but also for identifying new therapeutic targets for AMD.

This article provides an overview of the role of two types of mononuclear phagocytes, retinal microglia and peripheral blood monocytes, in the development and progression of AMD.

This article is protected by copyright. All rights reserved

Author Manuscript

First, the focus is on how retinal microglia maintain normal retinal integrity, how they change with age and genetics, and what their potential role is in the development and progression of AMD. Next, a consideration of how peripheral blood monocytes contribute to disease development and progression is made, and finally, it is suggested that activated immune cells can be detected by Optical Coherence Tomography (OCT), highlighting the potential for using OCT to identify immune cell changes in AMD *in vivo*.

Author Manuscript

2. Resident microglia as guardians of the retina

The principal resident immune cells and contributors to innate immunity within the central nervous system are microglia [10]. It is now known that these cells constantly survey the retinal environment and respond rapidly to injury and disease [11]. They remove inactive synapses during development [11] and in the retina are important for mediating maturation of cones [12]. Importantly, deficits in microglial function are thought to be an important factor in the development of early AMD [9]. This review outlines the role of microglia in maintaining normal retinal function and how they may be important in the development of disease.

For most retinal eccentricities, retinal microglia are localised to the two plexiform layers of the retina and extend their ramified processes to contact neural synapses as well as blood vessels (*Figure 1*[13]). This anatomical arrangement of microglia applies to all retinal eccentricities with the exception of the fovea, where there are very few microglia. This "microglial-free zone" corresponds to the centre of the foveal avascular zone[14]. Traditionally, microglia have been viewed as quiescent cells that only respond when the neural environment is compromised[10]. However, dynamic changes in microglia behaviour have been observed in both the retina and brain that suggest that these cells play important roles in maintaining normal retinal function[15-17]. Using *ex vivo* preparations, slow and sustained extension and retraction of retinal microglial processes can be observed[16, 18, 19]. This dynamic behaviour suggests that microglia continuously survey the neural environment, responding to signals released from neurons. Indeed, dynamic behaviour can be attenuated by application of agonists or antagonists to neurotransmitter receptors[20], or the vascular modulator, angiotensin II[19]. More recently, the function of microglia in the inner and outer retina has been probed in more detail using single cell RNAseq demonstrating an unexpected heterogeneity in the two populations [21]. In contrast to microglia of the outer plexiform layer, maintenance of microglia

This article is protected by copyright. All rights reserved

in the inner retina was dependent on IL34. In addition, inner microglia were important for maintaining inner retinal function [21].

An additional but important mediator of neuron-microglial communication is the chemokine, fractalkine (also called cx3cl1)[22]. Fractalkine is expressed by neurons including those of the retina[13, 23] and mediates functional changes in microglia by binding to its receptor, cx3cr1 that is solely expressed by microglia. Our results and that of others demonstrates that fractalkine-cx3cr1 signalling is important for maintaining neural integrity [12, 22, 24]. Notably, when cx3cr1 is genetically ablated in mouse models of neurodegeneration, the extent of neural loss is greater than when cx3cr1 is present[22]. Similarly, when fractalkine-cx3cr1 signalling is absent in the retina, such as in cx3cr1-null mice there is loss of cone photoreceptor integrity during visual maturation[13] and loss of cone mediated function in adult mice[24]. At more advanced ages, loss of rod photoreceptors also occurs in these mice[13, 25]. These results highlight that neuron-microglial communication via fractalkine-cx3cr1 is important for regulating neural integrity, especially photoreceptors in the retina.

In order to understand the effect that microglia have on cone maturation and integrity, structural, function and transcriptomic analysis has been undertaken in cx3cr1null mice from an early age[12]. Our results show that lack of cx3cr1 signalling is associated with a failure of photoreceptor outer segment maturation, followed by cone death[12]. The photoreceptor outer segment is that part of the cell that contains photopigments such as rhodopsin or cone-opsin. Following eye-opening in rodents, the outer-segment increases in length to accommodate the maturing visual system. This aspect of maturation is absent when signalling between neurons and microglia is impaired[13]. In order to understand the mechanism by which microglial-dependent photoreceptor maturation occurs, transcriptome analysis was performed in young cx3cr1null mice. The results indicate that there is reduced expression in genes important for the function of the photoreceptor connecting cilium, an important structure that carries proteins from their site of synthesis in the photoreceptor inner segment to the outer segment [13]. These results suggest that signalling from photoreceptors to microglia is important for mediating the maturation of cones, especially the cone outer segment following eye opening. The nature of the signalling between microglia and neurons, however, remains unknown.

A key result of microglial surveillance of the neural environment is pruning or removal of inactive synapses[26, 27]. Refinement of neural connections via microglial phagocytosis occurs

This article is protected by copyright. All rights reserved

Author Manuscript

in both the retina and other parts of the visual system occurs during maturation is response to neural activity[24, 28, 29]. In particular, synapses that are inactive are phagocytosed by microglia in a process that involves activation of the complement system [29].

Microglia phagocytosis of neuronal synapses may also be important as a response to subtle forms of neural damage. It is well known that microglia migrate to areas of neural damage in order to rapidly remove debris. However, recent studies suggest that microglial phagocytosis of living, but stressed, neurons may also occur[30, 31], in a process that may involve fractalkine-cx3cr1 signalling[30]. This is exemplified in a study of phagocytic behaviour of microglia in the *rd10* mouse model of inherited retinal degeneration[31]. These mice carry a mutation in phosphodiesterase 6 that leads to death of rod photoreceptors that peaks at postnatal day 21. Although microglial phagocytosis was observed in *rd10* retinae, it rarely involved the removal of dead photoreceptors (i.e. TUNEL positive photoreceptors). Rather, dying or stressed photoreceptors were the object of phagocytosis, in a manner mediated by complement component 3 (C3) and its receptor CR3[32]. Moreover, inhibition of microglia phagocytosis was associated with preservation of rod photoreceptors[31].

In summary, over the last 15 years, there has been a dramatic increase in our knowledge of the role of microglia in regulating normal health of the nervous system including the retina. Importantly, microglia are dynamic, constantly surveying the neural environment so as to rapidly respond to even the most subtle of injuries. They are critical for cone maturation and synaptic refinement during development. In this way, microglia play key roles in preserving the normal retina.

[Figure 1 about here]

3. The role of microglia in ageing and disease

Microglia respond to injury, ageing and disease by increasing in number, changing morphology, releasing a range of inflammatory mediators and also by phagocytosing and removing cellular debris that accumulates with disease. With age there is a steady increase in microglia number in both synaptic layers of the retina that is accompanied by a change in morphology involving an increase in soma size and decrease in process length, hallmark signs of microglial activation [33]. Dynamic behaviour of microglia remains intact and

This article is protected by copyright. All rights reserved

Author Manuscript

unaffected by advancing age suggesting that the surveillance function of microglia remains largely intact even at an advanced age[33]. However, the response of microglia to the major cellular damage signal, extracellular ATP, is reduced in aged mouse retinae, and when a focal injury is induced in the retina by a laser, the speed by which microglia respond to that injury is reduced[33]. Gene expression in isolated microglia also shows changes with age, with genes associated with the complement system, including complement component 3 and complement factor B, upregulated in old mice[34]. These are important findings that suggest that microglia are altered with age and show reduced capacity to respond to injury. In age-related diseases, such as AMD, it is possible that these normal ageing changes are further exaggerated leading to potentiation of cellular damage and pathology.

Increase in microglial density and a change in morphology is a well-known event that occurs in response to retinal injury or disease and assessment of microglial number and/or their morphology can be a useful tool for quantifying the subtlest of retinal stresses. For example, application of subthreshold laser injury using a nanosecond laser induces selective loss of an area of RPE that is associated with extension of microglial processes into the injured area within one hour, in the absence of a change in microglial density or inflammation[35]. Similarly, the effect thermal injury on retinal integrity has been quantified by evaluating changes in microglial morphology (e.g. soma size and process length), providing a means for establishing the thermal limits over which an electronic implant can be apply current[36].

A change in microglial density correlates with the extent of injury or pathology in mouse models of retinal disease or in human retinae with retinal degeneration[31]. For example, mouse models of AMD show an accumulation of innate immune cells in the subretinal space [25, 37-40], and immune cells accumulate in and around lesions of AMD including drusen and geographic atrophy [9, 41]. The large influx of immune cells into the retina in response to photoreceptor death in inherited retinal degeneration is associated with changes in inflammation that is thought to exacerbate neural loss. Indeed, blockade of microglial behaviour or inflammation has been reported to reduce photoreceptor loss [42]. Microglial density can also be used to measure more subtle changes in retinal pathology as seen, for example, in the mouse model of oxygen induced retinopathy [43]. Oxygen induced retinopathy is a model of inner retinal angiogenesis that is associated with changes in glia and neurons that varies from central to peripheral retina[43-46]. A change in microglial number can be used to identify those regions of the retina associated with greater levels of neural stress; there is a

This article is protected by copyright. All rights reserved

Author Manuscript

correlation between increasing number of microglia in the retina and changes in outer retinal blood vessels [43].

4. Changes in mononuclear phagocytes in age related macular degeneration

One of the more prominent features that occurs in retinae with age is the accumulation of cells of the innate immune system within the subretinal space[25, 40, 47, 48]. As shown in *Figure 2*, immune cells accumulate around some of the lesions associated with AMD, especially reticular pseudodrusen, and have also been reported in association with atrophic areas in retinae with geographic atrophy and or choroidal neovascularisation [41].

The subretinal space is the region of the posterior eye between the RPE and outer segments of photoreceptors. Under normal circumstances the subretinal space is immune privileged, owing to the expression and release of immunosuppressive factors by the RPE such as TGFβ [49]. With age, or in response to a range of chemotactic factors, cells of the innate immune system accumulate within the subretinal space[40, 47, 48]. Many of these cells express complement components such as C3 or C5, suggesting they contribute to the pro-inflammatory environment of the posterior eye that develops with advancing age[37, 40, 47].

The origin of the cells in the subretinal space remains a source of debate. These cells may reflect migration of monocytes and macrophages from the underlying vasculature into the subretinal space, or alternatively, distal migration of resident immune cells, microglia, from the synaptic layers into the subretinal space. Distinguishing blood monocytes from retinal microglia is challenging because the markers used to identify each cell population can change once cells migrate into the retina. Using single cell RNAseq, Ronin *et al* (2019) recently showed that the immune cells that accumulate within the retina following the onset of retinal degeneration represent microglia, activated microglia, monocytes and monocyte-derived macrophages[50]. These results highlight that migration of immune cells from the peripheral circulation form a critical component of the response to retinal degeneration. Further evidence for a contribution of leucocytes to retinal pathology comes from a transcriptomic study of CD45+ retinal leucocytes at different stages following light induced retinal degeneration. Importantly, there were major shifts in genes associated with leucocyte activation, the complement cascade and chemokine signalling highlighting that migration of leucocytes from the blood into the retina could play a major role in the subsequent retinal

This article is protected by copyright. All rights reserved

Author Manuscript

inflammation that occur[51]. What was not clear in either of these studies was whether there were differences in the origins of the immune populations that accumulate within the subretinal space compared to inner retina[50]. Notably, one study evaluating the expression of Ccr2, a marker of monocytes, showed that following light induced retinal damage there were Ccr2 positive cells as well as microglial cells in the subretinal space[52]. In contrast, O'Koren *et al*[21] showed that retinal microglia populate the subretinal space in the light induced model of retinal degeneration and monocyte migration was restricted to populating the inner retinal layers during retinal degeneration.

The ability for immune cells to accumulate in the subretinal space may depend on the expression of a range of chemotactic factors, such as chemokines that mediate chemotaxis into the subretinal space. Chemokines are small molecules released by cells that induce chemotaxis. A number of chemokines have been investigated for their potential for attracting immune cells to the subretinal space. Chemokine ligand 2 (Ccl2) is important for recruitment of monocytes, memory T cells and dendritic cells to sites of inflammation. It is highly expressed in the retina during disease, especially in immune cells that accumulate within the subretinal space as well as in Müller cells during retinal degeneration [53]. When Ccl2 is genetically deleted in transgenic mouse models with features of AMD (e.g., Cx3cr1/Ccl2 double knockout or ApoEε2/Ccl2 transgenic), the number of immune cells within the subretinal space is significantly reduced, emphasising the importance of this chemokine in migration of immune cells into the subretinal space[38, 52]. However, Ccl2 is unlikely to be the sole mediator of immune cell migration into the subretinal space, because in normal, non-diseased, aged Ccl2null mice, there is significant accumulation of immune cells within the subretinal space. More work is needed to elucidate which chemokines attract immune cells to the subretinal space.

Complement factor H may have a role in regulating the inflammatory environment of the subretinal space. Complement factor H is known to be released by immune cells and normally inhibits complement activation by binding to cell surface glycosaminoglycans. However, recently, an additional role for complement Factor H was identified, whereby it regulates the turnover of immune cells in the subretinal space[54]. Immune cells continuously turnover in the subretinal space. They migrate into the subretinal space and are then eliminated by a process that involves activation of the thrombospondin receptor, CD47.

This article is protected by copyright. All rights reserved

Author Manuscript

However, in the context of retinal inflammation induced by exposure to excessive light, complement Factor H inhibited the elimination of immune cells by binding to CD47 and preventing the normal interaction with thrombospondin[54].

Regardless of the underlying mechanism(s) for their accumulation, the presence of immune cells in the subretinal space has a range of deleterious effects on neighbouring structures, including the RPE and photoreceptors. Mouse models of AMD including Cx3cr1null and ApoEε2 mice show loss of photoreceptors in association with the accumulation of subretinal immune cells, and a reduction in these cells correlates with preservation of photoreceptors[38, 52, 54]. Macrophages release inflammatory mediators, including IL1β, IL6 and CCl_2 all of which influence photoreceptor and RPE integrity[41]. In addition, activated monocytes can downregulate the transcription factor, OTX2 within the RPE, leading to attenuation of a range of functions including retinoid recycling[55].

In summary, it is possible that with advancing age and/or inheritance of genetic risk factors, mononuclear phagocytes accumulate into the subretinal space, where they release a range of inflammatory mediators that influence photoreceptor and RPE integrity.

[Figure 2]

5. Peripheral blood monocytes and age related macular degeneration

Having established that the accumulation of immune cells within the subretinal space is a critical step in the development of early AMD, it is important to consider whether abnormal monocyte function could underpin the inflammatory state that develops with age and during AMD.

In order for leucocytes (including monocytes) to migrate across physiological barriers such as the blood retinal barrier, changes in the expression of adhesion molecules, such as CD11β, is required. Consistent with this, the proportion of monocytes expressing CD11β is increased in subjects with neovascular AMD[56]. CD200 is another surface glycoprotein expressed by many cell types including monocytes that is thought to attenuate inflammation, via activation of its receptor CD200R. Notably, the expression of CD200 on monocytes in those with rapidly

This article is protected by copyright. All rights reserved

Author Manuscript

progressing geographic atrophy was shown to increase in comparison to those with slowly progressing geographic atrophy or healthy age matched controls [57].

In order to understand whether specific leucocyte types are modified during AMD, studies in cell specific populations have been undertaken. Peripheral blood monocytes are traditionally identified by their surface markers, CD14 and CD16: classical monocytes are CD14+ and show low levels of CD16, whereas non-classical monocytes have high surface expression of CD16 and low levels of CD14. Intermediate monocytes show both CD14 and CD16 surface expression. These three classes of monocytes are found in different proportions within peripheral blood, and have different functional responses to stimuli. Classical monocytes are found in the greatest abundance and are potent producers of pro-inflammatory cytokines in response to bacteria, whilst non-classical monocytes are found in the smallest abundance and likely to respond to stimuli related to immunoglobulin. Non-classic monocytes have increased complement gene expression (e.g., C1Q, C2 and C3) as well as genes associated with phagocytosis [58]. Lastly, intermediate monocytes are thought to be associated with antigen presentation. Some studies have suggested that the proportion of the three monocyte classes is unchanged in advanced AMD [59], although an increase in monocytes has been reported during the first month following the onset of neovascular AMD [60]. However, changes gene expression (transcriptome) in monocytes isolated from subjects with neovascular AMD highlight that alterations occur in peripheral blood monocytes during disease. In particular, the proportion of non-classic monocytes that express markers such as CCR2+ is increased in neovascular AMD and there is an increase in expression of a range of inflammatory mediators and scavenger receptors[61, 62]. In addition, the expression level of the chemokine receptors, CCR1+ or CCR3+, is increased in those that fail to respond to anti-VEGF therapy, suggesting that systemic immunological factors may have a role in treatment outcome [63]. Consistent with these findings, cytokine expression and release from peripheral blood monocytes isolated from subjects with various types of AMD has also been demonstrated[64-66].

The mechanisms by which monocyte changes occur during AMD, and importantly whether the changes contribute to disease progression is not known. One factor that may influence the development of systemic inflammation during AMD are microRNAs. MicroRNAs are small non-coding RNAs approximately 20 nucleotides in length that are potent regulators of gene expression. They are highly expressed in the blood (as well as other body fluids). Recently, A

This article is protected by copyright. All rights reserved

Author Manuscript

detailed study of microRNAs isolated from cells of the peripheral blood was correlated with the expression of inflammatory mediators in plasma [66], highlighting that complex genetic regulation of inflammatory pathways within the peripheral blood may occur during AMD.

Overall, these studies suggest that even though AMD is an ocular disease, there are systemic changes in peripheral blood monocytes that may be important contributors to the inflammatory environment implicated in AMD. Importantly, systemic immunological changes have been reported during different stages of AMD and with these changes in mind, migration of monocytes into the subretinal space is likely to lead to an accumulation of aberrant immune cells and potentially contribute to disease progression.

6. The role of scavenger receptors in the development of early AMD

An important function of immune cells (both microglia and monocytes) is the ability to remove or phagocytose cellular waste to reduce disease progression. The formation of drusen deposits within the posterior eye implies that the processes that normally remove waste products may be impaired in those with AMD. The mechanism(s) by which immune cells phagocytose debris involves the binding of scavenger receptors to the surface of dead or dying cells. There are a range of scavenger receptors expressed by mononuclear phagocytes, and abnormalities in some of these scavenger receptors have been implicated in other age-related diseases of the CNS including Alzheimer's disease and Parkinson's disease [67-69]. One receptor that has received some attention for its role in removal of debris is the $P2X_7$ receptor. $P2X_7$ receptors expressed on mononuclear phagocytes including retinal microglia and have been implicated in the development of advanced AMD.

$P2X_7$ is a ligand gated ion channel that performs a dual role depending on the level of extracellular ATP in the environment[70, 71]. In the presence of extracellular ATP, $P2X_7$ receptors open so as to allow the passage of cations into cells, leading to a change in membrane potential. Such as scenario is common in many neural subtypes within the retina[72-74], as well as other cell types in the enteric and central nervous system[75, 76]. In contrast, in the absence of ATP, the extracellular part of the $P2X_7$ receptor can bind to the surface of dead and dying cells to mediate phagocytosis[77-79].

Based on mutagenesis experiments there are two regions of the extracellular domain that have been identified that interact with the phosphatidylserine moieties found on cellular

This article is protected by copyright. All rights reserved

Author Manuscript

debris to mediate phagocytosis[78]. Moreover, an analysis of single nucleotide polymorphisms (SNPs) of the $P2X_7$ receptor[80], suggest that not only are some of these SNPs associated with increased risk of disease, but also associated with variation in phagocytosis. Notably, inheritance of one SNP in $P2X_7$ in combination with P2X4 has been shown to increase risk of advanced AMD by four fold[81]. The combination of inheritance of these two SNPs is found in only a small percentage of people – 0.57% in the health population and 2.28% in the population with advanced AMD. However, of greater significance was the observation that the combination of these two SNPs reduced phagocytosis *in vitro*, and *in vivo*[81]. Further evidence for a potential role of $P2X_7$ in the development of early AMD comes from an evaluation of the ocular pathology in $P2X_7$-null mice[37]. Ageing $P2X_7$ null mice show an increase in Bruch's membrane thickness compared to age matched control mice, as well as a gradual reduction in monocyte phagocytosis with age[37]. In addition, aged $P2X_7$ null mice develop other signs of early AMD including an accumulation of innate immune cells within the subretinal space that are immunoreactive for component components C3 and C5, as well as changes in the RPE such as an increase in lipofuscin. Overall, these findings are important as they implicate poor phagocytic ability in monocytes with the development of signs of AMD. More work is needed now to identify pharmacological agents that might alter phagocytosis as a potential way for reducing retinal pathology.

7. Is it possible to visualise mononuclear phagocytes in the retina using OCT?

Having ascribed an important role for immune cells in the development and/or progression of AMD, it would be useful if *in vivo* imaging with Optical Coherence tomography (OCT) was capable of detecting changes in these cells in the posterior eye. With the advent of high resolution OCT it is now possible to image the human retina with resolution that has similarities to what is observed histologically. Moreover, a range of discrete hyperreflective lesions have been documented at various stage of AMD. Hyperreflective foci are visible on OCT imaging in those with AMD, and are considered a sign of advancing disease [82, 83]. They are discrete hyperreflective spots located above large drusen and have generally been viewed as being associated with the proximal migration of RPE cells. However, as shown in *Figure 3*, a collection of activated immune cells can also be associated with a hyperreflective lesion with OCT imaging. *Figure 3* shows a region of retina that has been treated with a pulsed laser and imaged with OCT as well as histology. There are a collection of immune cells at the outer limiting membrane in the region corresponding to the lasered lesion. In particular small

This article is protected by copyright. All rights reserved

Author Manuscript

hyperreflective spots are visible in the corresponding OCT (indicated by the white arrowhead in *Figure 3B*) and at higher magnification in *Figure 3C*. The green Iba1 immunolabelled immune cells in *Figure 3D* are located in the same region at the hyperreflective spots in *Figures 3B* and *3C*, suggesting that accumulation of microglia and recruited monocytes in the retina in response to injury can be visualised with the OCT. Hyperreflective spots may also reflect migration of pigmented cells migrating into the retina. Whilst imaging of immune cells may be possible with an OCT, it will be necessary to develop tools that allow one to distinguish immune cells from pigment cells.

Imaging of immune cells with *in vivo* imaging modalities is also now possible in rodent models of disease[84]. For example, accumulation of microglia within the retina and changes in morphology of microglia during disease is now possible in rodents using adaptive optics

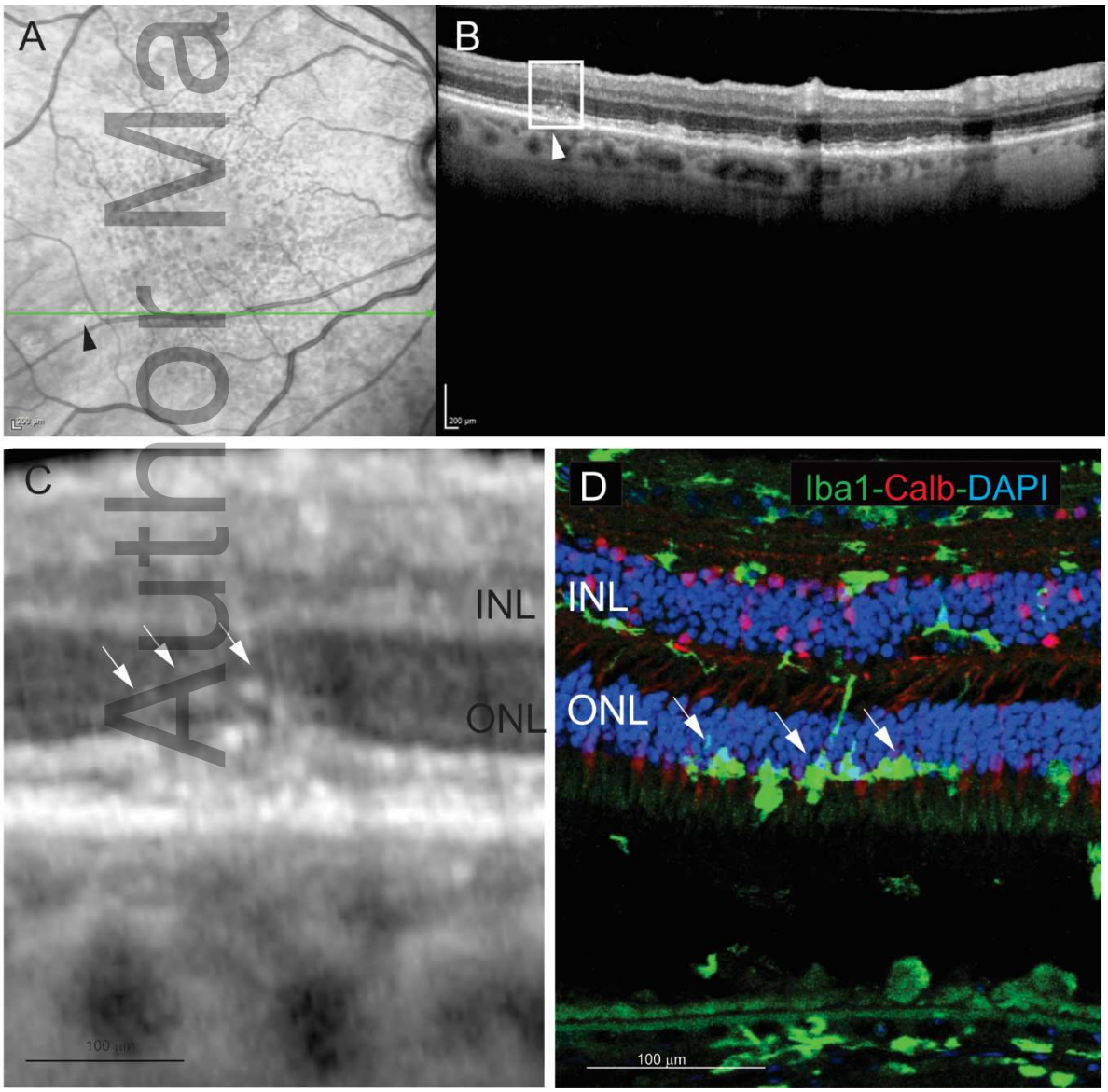

Author Manuscript

scanning laser ophthalmoloscopy[84]. With these new tools, it will be possible to gain greater insights into the changes in immune cells that occur during disease.

8. Conclusion

In conclusion, a range of cellular changes occur during different stages of AMD that can be influenced by the function of cells of the innate immune system. Importantly, with age, immune cells increase in number, respond differently to neural damage and release inflammatory mediators that can, in turn, influence photoreceptor and RPE function. Immune cells accumulate within the normally immune privileged subretinal space, in response to changes in chemokines. These cells release inflammatory mediators such as IL6, IL1β and Ccl2 to influence photoreceptor and RPE function. In addition, the ability of immune cells to remove debris (via phagocytosis) may be important for the development of AMD. Indeed, inheritance of loss of function $P2X_7$ and $P2X_4$ single nucleotide polymorphisms are associated with increased risk of advanced AMD, as well as the development of early signs in a mouse model with features of AMD. Overall, understanding how immune cells contribute to the various forms of AMD may offer new therapeutic targets that could reduce the development or progression of disease.

Acknowledgements

I have been fortunate to have worked over many years with a number of highly skilled and hardworking research associates and research higher degree. The research described here could not have been possible without the dedication of Dr Andrew Jobling, Dr Joanna Phipps, Dr Kirstan Vessey and Dr Una Greferath who led the laboratory work described here. I have also enjoyed a longstanding collaboration with clinician-scientist Prof Robyn Guymer. For the purposes of this article, I would like to thank Dr Una Greferath for assistance with preparing the figures.

Funding sources: National Health and Medical Research Council of Australia, Macular Disease Foundation of Australia.

This article is protected by copyright. All rights reserved

Author Manuscript

Disclosures: The author reports no conflicts of interest and has no proprietary interest in any of the materials mentioned in this article.

Author Manuscript

References

1. Lim LS, Mitchell P, Seddon JM, Holz FG & Wong TY. Age-related macular degeneration. *Lancet* 2012;379:1728-1738.
2. Mitchell P, Liew G, Gopinath B & Wong TY. Age-related macular degeneration. *Lancet* 2018;392:1147-1159.
3. Hageman GS, Luthert PJ, Victor Chong NH, Johnson LV, Anderson DH & Mullins RF. An integrated hypothesis that considers drusen as biomarkers of immune-mediated processes at the RPE-Bruch's membrane interface in aging and age-related macular degeneration. *Prog Retin Eye Res* 2001;20:705-732.
4. Toomey CB, Kelly U, Saban DR & Bowes Rickman C. Regulation of age-related macular degeneration-like pathology by complement factor H. *Proc Natl Acad Sci USA*. 2015;112:E3040-E3049.
5. Copland DA, Theodoropoulou S, Liu J & Dick AD. A Perspective of AMD Through the Eyes of Immunology. *Invest Ophthalmol Vis Sci* 2018;59:AMD83-AMD92.
6. Mullins RF, Russell SR, Anderson DH & Hageman GS. Drusen associated with aging and age-related macular degeneration contain proteins common to extracellular deposits associated with atherosclerosis, elastosis, amyloidosis, and dense deposit disease. *FASEB J*. 2000;14:835-846.
7. Crabb JW, Miyagi M & Gu X, *et al*. Drusen proteome analysis: an approach to the etiology of age-related macular degeneration. *Proc Natl Acad Sci USA*. 2002;99:14682-14687.
8. Edwards AO, Ritter R, 3rd, Abel KJ, Manning A, Panhuysen C & Farrer LA. Complement factor H polymorphism and age-related macular degeneration. *Science* 2005;308:421-424.
9. Guillonneau X, Eandi CM, Paques M, Sahel JA, Sapieha P & Sennlaub F. On phagocytes and macular degeneration. *Prog Retin Eye Res* 2017;61:98-128.
10. Hanisch UK & Kettenmann H. Microglia: active sensor and versatile effector cells in the normal and pathologic brain. *Nat Neurosci* 2007;10:1387-1394.

This article is protected by copyright. All rights reserved

11. Stevens B & Schafer DP. Roles of microglia in nervous system development, plasticity, and disease. *Dev Neurobiol* 2018;78:559-560.
12. Jobling AI, Mills SA & Phipps JA, *et al*. Miocroglial involvement in the neurovascular unit and alterations during early diabetic retinopathy. *Invest Ophthalmol Vis Sci* 2018;59:5379 (ARVO Abstracts).
13. Jobling AI, Waugh M & Vessey KA, *et al*. The role of the microglial Cx3cr1 pathway in the postnatal maturation of retinal photoreceptors. *J Neurosci* 2018;38:4708-4723.
14. Singaravelu J, Zhao L, Fariss RN, Nork TM & Wong WT. Microglia in the primate macula: specializations in microglial distribution and morphology with retinal position and with aging. *Brain Struct Funct* 2017;222:2759-2771.
15. Davalos D, Grutzendler J & Yang G, *et al*. ATP mediates rapid microglial response to local brain injury in vivo. *Nat Neurosci* 2005;8:752-758.
16. Lee JE, Liang KJ, Fariss RN & Wong WT. Ex vivo dynamic imaging of retinal microglia using time-lapse confocal microscopy. *Invest Ophthalmol Vis Sci* 2008;49:4169-4176.
17. Nimmerjahn A, Kirchhoff F & Helmchen F. Resting microglial cells are highly dynamic surveillants of brain parenchyma in vivo. *Science* 2005;308:1314-1318.
18. Liang KJ, Lee JE & Wang YD, *et al*. Regulation of dynamic behavior of retinal microglia by CX3CR1 signaling. *Invest Ophthalmol Vis Sci* 2009;50:4444-4451.
19. Phipps JA, Vessey KA & Brandli A, *et al*. The role of angiotensin II/AT1 receptor signaling in regulating retinal microglial activation. *Invest Ophthalmol Vis Sci* 2018;59:487-498.
20. Fontainhas AM, Wang M & Liang KJ, *et al*. Microglial morphology and dynamic behavior is regulated by ionotropic glutamatergic and GABAergic neurotransmission. *PLoS One* 2011;6:e15973.
21. O'Koren EG, Yu C & Klingeborn M, *et al*. Microglial function is distinct in different anatomical locations during retinal homeostasis and degeneration. *Immunity* 2019;50:723-737 e7.
22. Cardona AE, Pioro EP & Sasse ME, *et al*. Control of microglial neurotoxicity by the fractalkine receptor. *Nat Neurosci* 2006;9:917-924.
23. Harrison JK, Jiang Y & Chen S, *et al*. Role for neuronally derived fractalkine in mediating interactions between neurons and CX3CR1-expressing microglia. *Proc Natl Acad Sci USA* 1998;95:10896-10901.
24. Wang X, Zhao L & Zhang J, *et al*. Requirement for microglia for the maintenance of synaptic function and integrity in the mature retina. *J Neurosci* 2016;36:2827-2842.

This article is protected by copyright. All rights reserved

Author Manuscript

25. Combadiere C, Feumi C & Raoul W, *et al*. CX3CR1-dependent subretinal microglia cell accumulation is associated with cardinal features of age-related macular degeneration. *J Clin Invest* 2007;117:2920-2928.
26. Schafer DP, Lehrman EK & Kautzman AG, *et al*. Microglia sculpt postnatal neural circuits in an activity and complement-dependent manner. *Neuron* 2012;74:691-705.
27. Tremblay ME, Stevens B, Sierra A, Wake H, Bessis A & Nimmerjahn A. The role of microglia in the healthy brain. *J Neurosci* 2011;31:16064-16069.
28. Lehrman EK, Wilton DK & Litvina EY, *et al*. CD47 protects synapses from excess microglia-mediated pruning during development. *Neuron* 2018;100:120-134 e6.
29. Stevens B, Allen NJ & Vazquez LE, *et al*. The classical complement cascade mediates CNS synapse elimination. *Cell* 2007;131:1164-1178.
30. Zabel MK, Zhao L & Zhang Y, *et al*. Microglial phagocytosis and activation underlying photoreceptor degeneration is regulated by CX3CL1-CX3CR1 signaling in a mouse model of retinitis pigmentosa. *Glia* 2016;64:1479-14791.
31. Zhao L, Zabel MK & Wang X, *et al*. Microglial phagocytosis of living photoreceptors contributes to inherited retinal degeneration. *EMBO Mol Med* 2015;7: 1179-1197.
32. Silverman SM, Ma W, Wang X, Zhao L & Wong WT. C3- and CR3-dependent microglial clearance protects photoreceptors in retinitis pigmentosa. *J Exp Med* 2019;216:1925-1943.
33. Damani MR, Zhao L, Fontainhas AM, Amaral J, Fariss RN & Wong WT. Age-related alterations in the dynamic behavior of microglia. *Aging Cell* 2011;10:263-276.
34. Ma W, Cojocaru R & Gotoh N, *et al*. Gene expression changes in aging retinal microglia: relationship to microglial support functions and regulation of activation. *Neurobiol Aging* 2013;34:2310-2321.
35. Jobling AI, Guymer RH & Vessey KA, *et al*. Nanosecond laser therapy reverses pathologic and molecular changes in age-related macular degeneration without retinal damage. *FASEB J* 2015;29:696-710.
36. Opie NL, Greferath U & Vessey KA, *et al*. Retinal prosthesis safety: alterations in microglia morphology due to thermal damage and retinal implant contact. *Invest Ophthalmol Vis Sci* 2012;53:7802-7812.
37. Vessey KA, Gu BJ & Jobling AI, *et al*. Loss of function of P2X7 receptor scavenger activity in aging mice: a novel model for investigating the early pathogenesis of age-related macular degeneration. *Am J Pathol* 2017;187:1670-1685.

This article is protected by copyright. All rights reserved

Author Manuscript

38. Levy O, Calippe B & Lavalette S, *et al*. Apolipoprotein E promotes subretinal mononuclear phagocyte survival and chronic inflammation in age-related macular degeneration. *EMBO Mol Med* 2015;7:211-226.
39. Levy O, Lavalette S & Hu SJ, *et al*. APOE isoforms control pathogenic subretinal inflammation in age-related macular degeneration. *J Neurosci* 2015;35:13568-13576.
40. Vessey KA, Greferath U & Jobling AI, *et al*. Ccl2/Cx3cr1 knockout mice have inner retinal dysfunction but are not an accelerated model of AMD. *Invest Ophthalmol Vis Sci* 2012;53:7833-7846.
41. Eandi CM, Charles Messance H & Augustin S, *et al*. Subretinal mononuclear phagocytes induce cone segment loss via IL-1beta. *Elife*. 2016;5.
42. Yang LP, Li Y, Zhu XA & Tso MO. Minocycline delayed photoreceptor death in rds mice through iNOS-dependent mechanism. *Mol Vis* 2007;13:1073-1082.
43. Vessey KA, Wilkinson-Berka JL & Fletcher EL. Characterization of retinal function and glial cell response in a mouse model of oxygen-induced retinopathy. *J Comp Neurol* 2011;519:506-527.
44. Downie LE, Hatzopoulos KM & Pianta MJ, *et al*. Angiotensin type-1 receptor inhibition is neuroprotective to amacrine cells in a rat model of retinopathy of prematurity. *J Comp Neurol* 2010;518:41-63.
45. Downie LE, Pianta MJ, Vingrys AJ, Wilkinson-Berka JL & Fletcher EL. Neuronal and glial cell changes are determined by retinal vascularization in retinopathy of prematurity. *J Comp Neurol* 2007;504:404-417.
46. Downie LE, Pianta MJ, Vingrys AJ, Wilkinson-Berka JL & Fletcher EL. AT1 receptor inhibition prevents astrocyte degeneration and restores vascular growth in oxygen-induced retinopathy. *Glia* 2008;56:1076-1090.
47. Vessey KA, Waugh M & Jobling AI, *et al*. Assessment of retinal function and morphology in aging Ccl2 knockout mice. *Invest Ophthalmol Vis Sci* 2015;56:1238-1252.
48. Chinnery HR, McLenachan S & Humphries T, *et al*. Accumulation of murine subretinal macrophages: effects of age, pigmentation and CX3CR1. *Neurobiol Aging* 2012;33:1769-1776.
49. Stein-Streilein J. Mechanisms of immune privilege in the posterior eye. *Int Rev Immunol* 2013;32:42-56.

Author Manuscript

This article is protected by copyright. All rights reserved

50. Ronning KE, Karlen SJ, Miller EB & Burns ME. Molecular profiling of resident and infiltrating mononuclear phagocytes during rapid adult retinal degeneration using single-cell RNA sequencing. *Sci Rep* 2019;9:4858.
51. Natoli R, Mason E & Jiao H, *et al*. Dynamic interplay of innate and adaptive immunity during sterile retinal inflammation: insights from the transcriptome. *Front Immunol* 2018;9:1666.
52. Sennlaub F, Auvynet C & Calippe B, *et al*. CCR2(+) monocytes infiltrate atrophic lesions in age-related macular disease and mediate photoreceptor degeneration in experimental subretinal inflammation in Cx3cr1 deficient mice. *EMBO Mol Med* 2013;5:1775-1793.
53. Rutar M, Natoli R & Provis JM. Small interfering RNA-mediated suppression of Ccl2 in Muller cells attenuates microglial recruitment and photoreceptor death following retinal degeneration. *J Neuroinflammation* 2012;9:221.
54. Calippe B, Augustin S & Beguier F, *et al*. Complement factor H inhibits CD47-mediated resolution of inflammation. *Immunity* 2017;46:261-272.
55. Mathis T, Housset M & Eandi C, *et al*. Activated monocytes resist elimination by retinal pigment epithelium and downregulate their OTX2 expression via TNF-alpha. *Aging Cell* 2017;16:173-182.
56. Singh A, Falk MK, Hviid TV & Sorensen TL. Increased expression of CD200 on circulating CD11b+ monocytes in patients with neovascular age-related macular degeneration. *Ophthalmology* 2013;120:1029-1037.
57. Krogh Nielsen M, Subhi Y & Molbech CR, *et al*. Patients with a fast progression profile in geographic atrophy have increased CD200 expression on circulating monocytes. *Clin Exp Ophthalmol* 2019;47:69-78.
58. Wong KL, Tai JJ & Wong WC, *et al*. Gene expression profiling reveals the defining features of the classical, intermediate, and nonclassical human monocyte subsets. *Blood* 2011;118:e16-31.
59. Subhi Y, Krogh Nielsen M, Molbech CR & Sorensen TL. Altered proportion of CCR2(+) and CX3CR1(+) circulating monocytes in neovascular age-related macular degeneration and polypoidal choroidal vasculopathy. *Clin Exp Ophthalmol* 2018;46:661-669.
60. Subhi Y & Lykke Sørensen T. New neovascular age-related macular degeneration is associated with systemic leucocyte activity. *Acta Ophthalmol* 2017;95:472-480.

This article is protected by copyright. All rights reserved

Author Manuscript

61. Grunin M, Hagbi-Levi S, Rinsky B, Smith Y & Chowers I. Transcriptome analysis on monocytes from patients with neovascular age-related macular degeneration. *Sci Rep* 2016;6:29046.
62. Subhi Y, Nielsen MK & Molbech CR, *et al*. The transcriptome of peripheral blood mononuclear cells in patients with clinical subtypes of late age-related macular degeneration. *Immun Ageing* 2019;16:20.
63. Bjerregaard T, Krogh Nielsen M, Molbech CR, Subhi Y & Sorensen TL. Treatment failure in neovascular age-related macular degeneration is associated with a complex chemokine receptor profile. *BMJ Open Ophthalmol* 2019;4:e000307.
64. Lechner J, Chen M & Hogg RE, *et al*. Peripheral blood mononuclear cells from neovascular age-related macular degeneration patients produce higher levels of chemokines CCL2 (MCP-1) and CXCL8 (IL-8). *J Neuroinflammation* 2017;14:42.
65. Chen M, Lechner J & Zhao J, *et al*. STAT3 activation in circulating monocytes contributes to neovascular age-related macular degeneration. *Curr Mol Med* 2016;16:412-423.
66. Litwinska Z, Sobus A & Luczkowska K, *et al*. The interplay between systemic inflammatory factors and microRNAs in age related macular degeneration. *Front Aging Neurosci* 2019;11:286.
67. Gu BJ, Huang X & Ou A, *et al*. Innate phagocytosis by peripheral blood monocytes is altered in Alzheimer's disease. *Acta Neuropathol* 2016;132:377-389.
68. Fiala M, Lin J & Ringman J, *et al*. Ineffective phagocytosis of amyloid-beta by macrophages of Alzheimer's disease patients. *J Alzheimers Dis* 2005;7:221-232; discussion 55-62.
69. Tremblay ME, Cookson MR & Civiero L. Glial phagocytic clearance in Parkinson's disease. *Mol Neurodegener* 2019;14:16.
70. Ho T, Aplin FP & Jobling AI, *et al*. Localization and possible function of P2X receptors in normal and diseased retinae. *J Ocul Pharmacol Ther* 2016;32:509-517.
71. Fletcher EL, Wang AY & Jobling AI, *et al*. Targeting P2X7 receptors as a means for treating retinal disease. *Drug Discov Today* 2019;24:1598-605.
72. Puthussery T & Fletcher EL. Synaptic localization of P2X7 receptors in the rat retina. *J Comp Neurol* 2004;472:13-23.
73. Puthussery T, Yee P, Vingrys AJ & Fletcher EL. Evidence for the involvement of purinergic P2X receptors in outer retinal processing. *Eur J Neurosci* 2006;24:7-19.

This article is protected by copyright. All rights reserved

Author Manuscript

74. Vessey KA, Jobling AI, Greferath U & Fletcher EL. The role of the P2X7 receptor in the retina: cell signalling and dysfunction. *Adv Exp Med Biol* 2012;723:813-819.
75. Gulbransen BD, Bashashati M & Hirota SA, *et al*. Activation of neuronal P2X7 receptor-pannexin-1 mediates death of enteric neurons during colitis. *Nat Med* 2012;18:600-604.
76. Kaczmarek-Hajek K, Zhang J & Kopp R, *et al*. Re-evaluation of neuronal P2X7 expression using novel mouse models and a P2X7-specific nanobody. *Elife* 2018;7.
77. Gu BJ, Saunders BM, Jursik C & Wiley JS. The P2X7-nonmuscle myosin membrane complex regulates phagocytosis of non-opsonized particles and bacteria by a pathway attenuated by extracellular ATP. *Blood* 2010;115:1621-1631.
78. Gu BJ, Saunders BM, Petrou S & Wiley JS. P2X(7) is a scavenger receptor for apoptotic cells in the absence of its ligand, extracellular ATP. *J Immunol* 2011;187:2365-2375.
79. Wiley JS & Gu BJ. A new role for the P2X7 receptor: a scavenger receptor for bacteria and apoptotic cells in the absence of serum and extracellular ATP. *Purinergic Signal* 2012;8:579-586.
80. Wiley JS, Sluyter R, Gu BJ, Stokes L & Fuller SJ. The human P2X7 receptor and its role in innate immunity. *Tissue Antigens* 2011;78:321-332.
81. Gu BJ, Baird PN & Vessey KA, *et al*. A rare functional haplotype of the P2RX4 and P2RX7 genes leads to loss of innate phagocytosis and confers increased risk of age-related macular degeneration. *FASEB J* 2013;27:1479-1487.
82. Nassisi M, Fan W & Shi Y, *et al*. Quantity of intraretinal hyperreflective foci in patients with intermediate age-related macular degeneration correlates with 1-year progression. *Invest Ophthalmol Vis Sci* 2018;59:3431-3439.
83. Christenbury JG, Folgar FA & O'Connell RV, *et al*. Progression of intermediate age-related macular degeneration with proliferation and inner retinal migration of hyperreflective foci. *Ophthalmology* 2013;120:1038-1045.
84. Miller EB, Zhang P, Ching K, Pugh EN, Jr. & Burns ME. In vivo imaging reveals transient microglia recruitment and functional recovery of photoreceptor signaling after injury. *Proc Natl Acad Sci USA* 2019;116:16603-16612.

Author Manuscript

Erica Fletcher

Erica Fletcher is a Professor of the Department of Anatomy and Neuroscience at The University of Melbourne, Victoria, Australia. She completed her undergraduate optometry

This article is protected by copyright. All rights reserved

training, a MSc in corneal diseases and PhD in retinal cell biology at The University of Melbourne. This was followed by postdoctoral training in Germany at the Max-Planck Institute for Brain Research with Prof Dr Heinz Wassle funded by an NH&MRC CJ Martin Award. Prof Fletcher has been a tenured academic at The University of Melbourne since 2000.

A central focus of Prof Fletcher's work has been the translation of her work to address clinically significant questions and to aid in the development of better treatments for retinal disease. In particular, Prof Fletcher's work has uncovered new mechanisms of age related macular degeneration using novel animal models of disease. Prof Fletcher has received considerable research funding primarily from the NH&MRC and also a number of international funding agencies (e.g., Health Research Council, New Zealand, American Health Assistance Foundation). She has published widely in a range of high impact journals, whilst maintaining a teaching load and mentoring of research personnel. In addition, Prof Fletcher serves on a number of editorial boards, provides leadership within optometry by serving on boards of management. In recognition of her excellence in vision research, Prof Fletcher was awarded the 2019 H Barry Collin Research Medal, the 2016 Glen Fry Award and the 2006 Irvin M and Beatrice Borish Award from the American Academy of Optometry. She is also the 2020 recipient of the Nina Kondelos prize from the Australian Neuroscience Society, an award that recognizes outstanding female neuroscientists.

Author Manuscript

Figure legends

Figure 1. Retinal microglia in the human retina. (A). A vertical section of the human retina at the fovea (fv) immunolabelled for the microglial label, ionized calcium-binding adapter molecule 1 (Iba1; green). Microglia are located in the outer and inner plexiform layers across most eccentricities with the exception of the fovea. At the fovea there is a paucity of microglia in both plexiform layers. (B) Vertical section through a human retina labelled for Iba1, the neuronal marker, calbindin (Calb), and cone marker, peanut agglutinin (PNA). An Iba-1 labelled microglia is shown in contact with both a blood vessel (bv) and photoreceptor synapse (C) Vertical section through the human nerve fibre layer. A microglia is shown in contact with both a blood vessel (bv) and bipolar cell synapse that had been immunolabelled for the vesicular glutamate transporter 1 (vGlut; red). Abbreviations: OPL -outer plexiform layer; IPL-inner plexiform layer; ONL – outer nuclear layer; vitro-vitronectin.

This article is protected by copyright. All rights reserved

Figure 2. Immune cells and deposits in a human retina with early stage AMD. (A) Flatmount of the RPE showing vitronectin labelled reticular pseudodrusen deposits and adherent Iba1 labelled immune cells. Immune cells were associated with some deposits**.** (B) high magnification of a reticular pseudodrusen deposit with associated Iba-1 immunolabelled immune cells. (C) Vertical section of the human retina labelled for microglia (Iba-1; green) and vitronectin (red). A small vitronectin labelled drusen is present. There are few if any immune cells associated with the drusen. Abbreviations: RPE – retinal pigment epithelium; ONL – outer nuclear layer; INL-inner nuclear layer; OLM-outer limiting membrane; vitro-vitronectin; Phall – phalloidin an F-actin label that indicates the cell membrane of RPE cells.

Figure 3. Correlation of an Optical Coherence Tomography with human retinal section labelled for the immune cell marker IBA-1. (A) Red free fundus image of a human retina showing the location of a nanosecond lasered region (arrow). (B) corresponding OCT with the lasered lesion induced by the arrow. (C) high magnification of the OCT image through the lasered lesion. A series of hyperreflective dots can be seen at the level of the outer limiting membrane (arrows). (D) Corresponding histological section at the same laser lesioned area. Hypereflective spots are evident in both OCT images that correspond to the presence of Iba-1 immunolabelled immune cells (white arrows). Abbreviations: INL – inner nuclear layer; ONL-outer nuclear layer.

Author Manuscript

This article is protected by copyright. All rights reserved

Author Manuscript

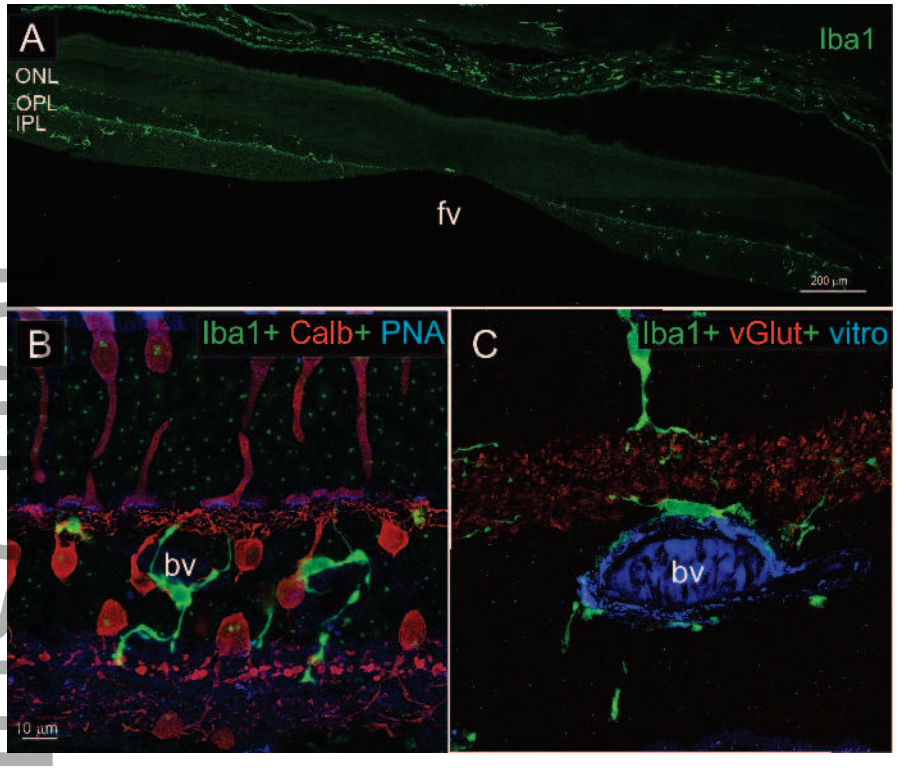

opo_12671_f1.tif

This article is protected by copyright. All rights reserved

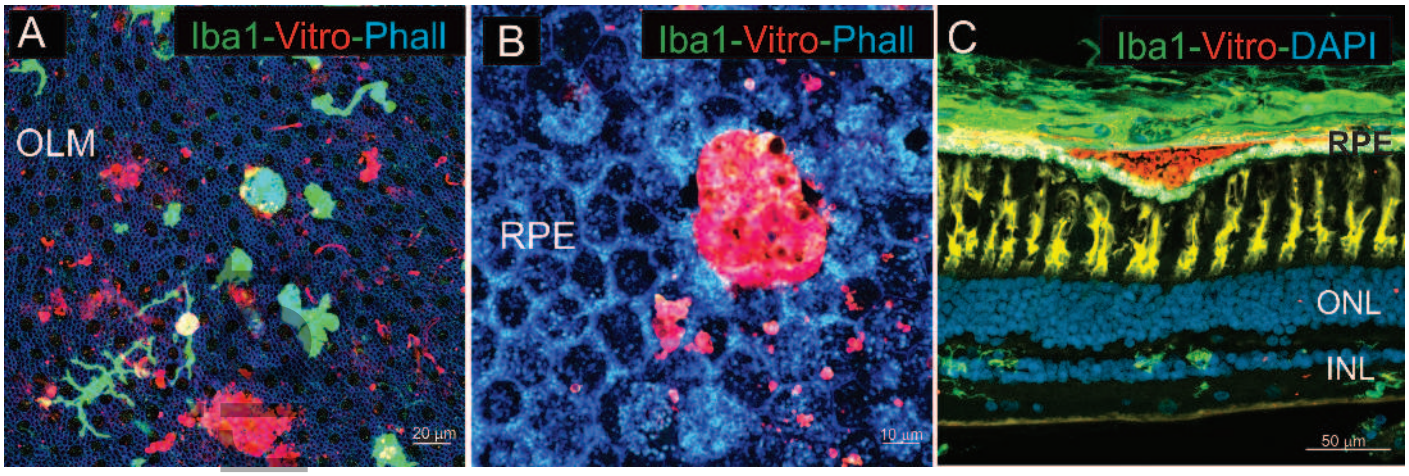

opo_12671_f2.tif

Author Manuscript

This article is protected by copyright. All rights reserved

Author Manuscript

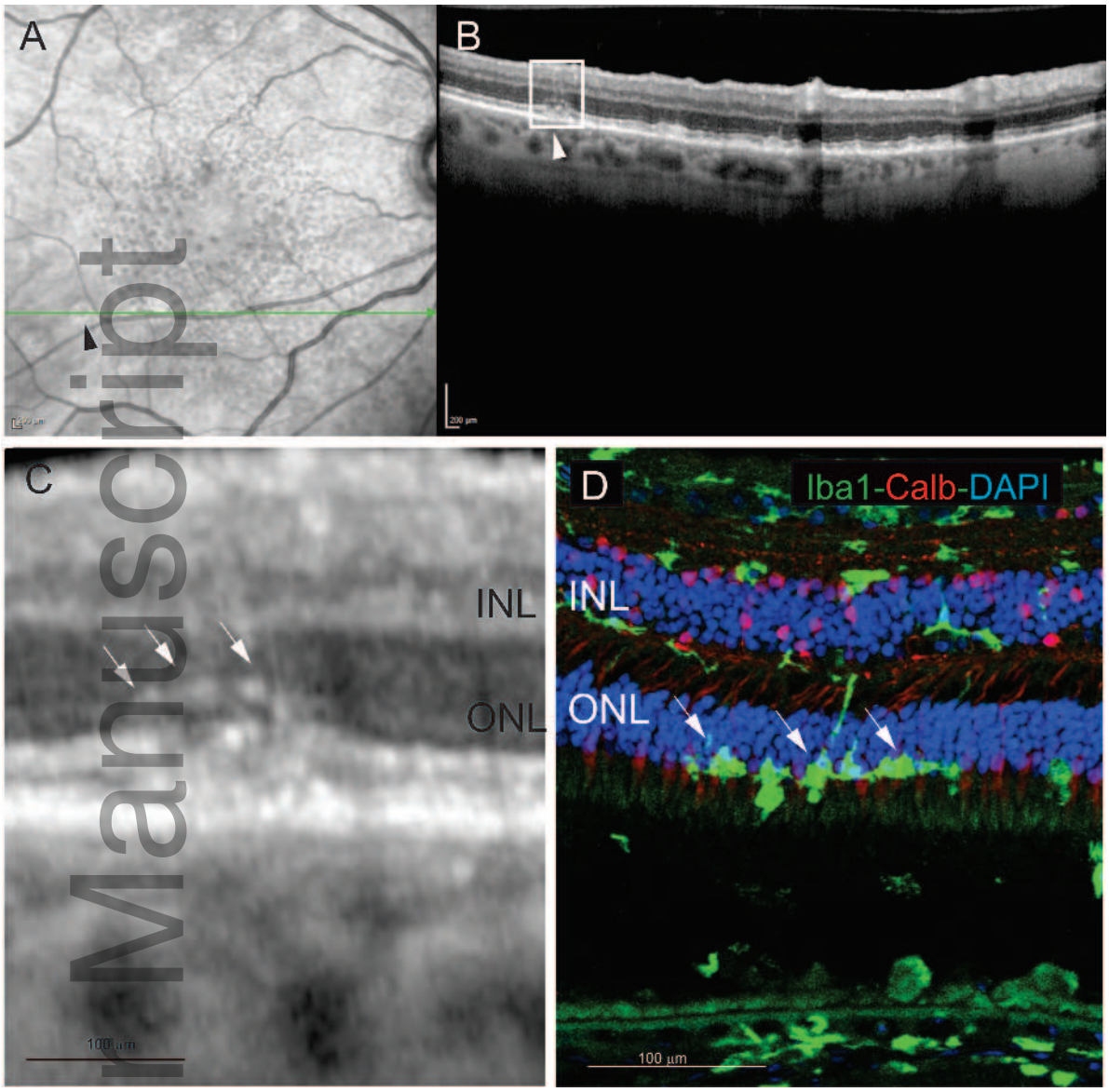

opo_12671_f3.tif

This article is protected by copyright. All rights reserved