



Minerva Access is the Institutional Repository of The University of Melbourne

Author/s:

Jayakar, P;Gotman, J;Harvey, AS;Palmini, A;Tassi, L;Schomer, D;Dubeau, F;Bartolomei, F;Yu, A;Kršek, P;Velis, D;Kahane, P

Title:

Diagnostic utility of invasive EEG for epilepsy surgery: Indications, modalities, and techniques

Date:

2016-11-01

Citation:

Jayakar, P., Gotman, J., Harvey, A. S., Palmini, A., Tassi, L., Schomer, D., Dubeau, F., Bartolomei, F., Yu, A., Kršek, P., Velis, D. & Kahane, P. (2016). Diagnostic utility of invasive EEG for epilepsy surgery: Indications, modalities, and techniques. *Epilepsia*, 57 (11), pp.1735-1747. <https://doi.org/10.1111/epi.13515>.

Persistent Link:

<https://hdl.handle.net/11343/291779>

Accepted Date : 02-Aug-2016

Article type : Special Report

**Diagnostic Utility of Invasive EEG for Epilepsy Surgery:
Indications, modalities and techniques**

¹Prasanna Jayakar, ²Jean Gotman, ³A. Simon Harvey, ⁴André Palmi, ⁵Laura Tassi, ⁶Donald Schomer, ⁷Francois Dubeau, ⁸Fabrice Bartolomei, ⁹Alice Yu, ¹⁰Pavel Kršek, ¹¹Demetrios Velis, ¹²Philippe Kahane

Recommendations on behalf of the Neurophysiology Task Force, Commission on Diagnostic Methods, International League Against Epilepsy

Address correspondence to:

Prasanna Jayakar MD., PhD
Chair, Brain Institute
Nicklaus Children's Hospital
3100 SW 62nd Avenue
Miami, FL 33156
Tel: 001 305 663 8590
Email : prasanna.jayakar@mch.com

1. Brain Institute, Nicklaus Children's Hospital, Miami, USA. prasanna.jayakar@mch.com
2. Montreal Neurological Hospital and Institute, McGill University, Montréal, Canada.
<jean.gotman@mcgill.ca>
3. The Royal Children's Hospital, University of Melbourne, Melbourne, Australia.
<simon@harvey.md>

This is the author manuscript accepted for publication and has undergone full peer review but has not been through the copyediting, typesetting, pagination and proofreading process, which may lead to differences between this version and the [Version of Record](#). Please cite this article as [doi: 10.1111/epi.13515](https://doi.org/10.1111/epi.13515)

This article is protected by copyright. All rights reserved

4. Services of Neurology and Neurosurgery, Hospital São Lucas, Porto Alegre, Brazil.
<apalmini@uol.com.br>
5. Claudio Munari Epilepsy Surgery center, Niguarda Hospital, Milan, Italy. Laura.Tassi@OspedaleNiguarda.it
6. Harvard University, Boston, USA. (dschomer@caregroup.harvard.edu)
7. Montreal Neurological Hospital and Institute, McGill University, Montréal, Canada.
<francois.dubeau@muhc.mcgill.ca>
8. Service de Neurophysiologie Clinique, Assistance Publique des Hôpitaux de Marseille, Marseille, France. (fabrice.bartolomei@univ-amu.fr)
9. Neurology Department, Taipei Veterans General Hospital and National Yang Ming University, Taipei, Taiwan. alicehyyu@gmail.com
10. Department of Pediatric Neurology, Charles University, Motol University Hospital, Prague, Czech Republic. <pavel.krsek@post.cz>
11. Epilepsy Surgery Program, Free University Medical Center (VUmc), Amsterdam, The Netherlands. <d.velis@vumc.nl>
12. Grenoble-Alpes Hospital and University, GIN INSERM U1216, Grenoble, France.
<philippe.kahane@ujf-grenoble.fr>

Running title: Recommendations for use of Invasive EEG

Key words: Epilepsy surgery, Intracranial EEG, Indications, Utility

Key words for use by abstracting services: Epilepsy surgery, Intracranial EEG, Indications, Utility

Number of text pages: 19

Number of words (summary): 200

Number of words (main text); 5997

Number of tables: 4

Number of figures: 1 in color.

Summary

Many patients with medically refractory epilepsy now undergo successful surgery based on non-invasive diagnostic information, but intracranial EEG (IEEG) continues to be used as increasingly complex cases are considered surgical candidates. The indications for IEEG and the modalities employed vary across epilepsy surgical centers; each modality has its advantages and limitations. IEEG can be performed in the same intraoperative setting, ie. intra-operative electrocorticography, or through an independent implantation procedure with chronic extra-operative recordings; the latter are not only resource intensive but also carry risk. A lack of understanding of IEEG limitations predisposes to data misinterpretation that can lead to either denying surgery when indicated or worse yet, incorrect resection with adverse outcomes. Given the lack of class 1 or 2 evidence on IEEG, a consensus-based expert recommendation on the diagnostic utility of IEEG is presented, with emphasis on the application of various modalities in specific substrates or locations, taking into account their relative efficacy, safety, ease, and incremental cost-benefit. These recommendations aim to curtail outlying indications that risk the over or underutilization of IEEG, while retaining substantial flexibility in keeping with most standard practices at epilepsy centers and addressing some of the needs of resource poor regions around the world.

Introduction

Epilepsy surgery is now widely used for the management of both adult and pediatric patients with medically refractory focal epilepsy. Resection strategies can often be defined through non-invasive diagnostic techniques but a subgroup of patients may require additional information that can only be obtained from intracranial EEG (IEEG) studies. Although the progress in non-invasive diagnostic techniques has reduced the need for IEEG in some settings, this trend is partially offset by the wider etiological spectrum and complexity of cases being considered for surgery, the establishment of many more epilepsy centers willing to carry out IEEG, and the increasing confidence in the safety of IEEG.

Recommendations published through the joint efforts of the ILAE Diagnostic Methods Commission and the Pediatric Epilepsy Surgery Task Force¹ helped to standardize the overall

evaluation process and guide utilization in specific substrates commonly encountered in children. Even so, epilepsy centers' experiences and biases continue, especially related to IEEG usage. While some centers are comfortable performing surgical resections based entirely on non-invasive data, especially in the presence of an MRI lesion, others regularly pursue intra-operative electrocorticography (ECoG) or extra-operative IEEG assessments to tailor resections. Extra-operative IEEG is not only resource intensive but carries risk of adverse effects.^{2,3,4} Furthermore, some centers rely on a single IEEG modality almost exclusively whereas others adapt the modality they believe is best suited clinically for each case. Thus, there is a need to further define the continuing role of IEEG and standardize its usage.

These recommendations address the indications for IEEG, with emphases on the various modalities and techniques of IEEG recording. The general IEEG indications are outlined first and then further specified in the context of the strengths, limitations, and risks of each modality. Recognizing that a unified IEEG strategy that is acceptable to all epilepsy centers is unachievable, the recommendations are devised to minimize over- and underutilization especially that which could jeopardize patient care. The intent is not to enforce changes in current practices at established epilepsy centers, but rather present options that are believed to be reasonable in light of available data and experience, thus retaining substantial flexibility in each center's ability to design its IEEG protocols.

Methodology

A panel formed from the ILAE Neurophysiology Task Force of the Diagnostic Methods Commission reviewed literature on the utility of IEEG in presurgical evaluation using the American Academy of Neurology guidelines.⁵ This review revealed that there is no class 1 or 2 evidence that support IEEG application in specific clinico-pathological settings. Data interpretation was confounded by several factors: (i) most studies combine adult and pediatric age groups and include patients with heterogeneous pathophysiological substrates; (ii) IEEG sensitivity and specificity is difficult to assess without the availability of a "gold standard" to define the epileptogenic zone, the closest approximation being the outcome after resection; (iii) access to and usage of IEEG vary considerably across centers; and (iv) comparison of studies is difficult as there is usually a bias with the specific IEEG modality at any given center.

Given the lack of class 1 and class 2 evidence, a consensus opinion of a broad based global panel of experts was deemed appropriate. Special consideration was given to the known strengths and limitations, risks, and incremental costs versus perceived effectiveness of each modality. The panel assumed that each epilepsy center has a multidisciplinary team with appropriate standard of proficiency and the minimal diagnostic capabilities required.¹ The panel recognized that resource limited regions of the world face unique challenges, with limited access to costly extra-operative IEEG technologies or expertise.

Background considerations

The primary goal of IEEG is to “complement” the non-invasive evaluation in guiding surgical resections by providing more precise information on the localization of the presumed epileptogenic zone (EZ) and its relationship to eloquent cortex (EC) via electrical stimulation mapping (ESM). The term EZ refers to the minimum cortical area(s) that have to be removed (disconnected) to render the patient seizure-free. The surgical planning at any center generally occurs within a multidisciplinary case conference setting and is guided by an analysis of all pertinent data which includes the general medical and social history and seizure semiology. Detailed analyses of the scalp EEG interictal and ictal patterns, neuropsychological evaluation and high-resolution MRI with epilepsy protocols are considered mandatory¹; ancillary tests including PET, ictal SPECT, magnetic resonance spectroscopy, fMRI, and electrical or magnetic source imaging may be optionally employed. This analysis leads to the generation of a reasonable hypothesis (or hypotheses) concerning the underlying etiology, the site(s) of seizure onset, the possible region that needs to be resected or disconnected i.e., the presumed EZ, and its relationship to EC. The resources and expertise for non-invasive tests evaluation at each center influence the team’s level of confidence in this hypothesis and the need for additional information through IEEG. Center biases can exist in the weight assigned to the information from various non-invasive tests and thus contribute heavily to the decision as to whether or not to proceed with IEEG recordings¹, and if so, the regions over one or both hemispheres that need to be sampled. Additional ancillary tests may be performed to help minimize the extent of coverage required.

All IEEG electrodes share some common recording features based on physical principles. Being very close to or within the neuronal electrical source, the spatial resolution is very high and the information is precise. However, in keeping with solid angle theory⁶, only a small portion of brain tissue can be sampled by each electrode estimated to be a sphere of about 5mm radius beyond its boundaries⁷⁻⁸, therefore making IEEG recording 'blind' if the electrodes are placed in insufficient numbers, or even a short distance away from the focus. This fact underscores the need of having a clear hypothesis of the presumed EZ based on all non-invasive data as erroneous implantation may lead to either withholding resection altogether or resection of inappropriate regions. Furthermore, some epileptic generators may behave as closed fields and require sampling with depth electrodes. The aim, in general, is to place enough electrodes to allow the best possible delineation of cortical areas involved in seizure onset, early propagation and also allow for an understanding of functional networks involved in further spread. Additional coverage is required to perform ESM as needed.

The challenges to IEEG are further compounded by the fact that the interpretation of IEEG findings is subjective and often empirical, and that inter-observer agreement is poor.⁹ Thus, how these interpretations are used to define a proposed surgical resection can also be, to some extent, subjective. The different aspects of interpreting IEEG data will be addressed in detail in a separate ILAE report but are summarized below. Interictal epileptiform discharges (IEDs) and background abnormalities recorded on intra-operative ECoG may be used to tailor some resections.¹⁰⁻¹⁵ ECoG may reveal continuous epileptiform discharges (CEDs), a finding increasingly being considered as a reliable marker of the EZ.¹⁶⁻²⁰ Capture of the ictal onset zone is cited as the primary added-value by proponents of extra-operative IEEG modalities, although the specific IEEG patterns and the timeframe that characterizes the ictal onset zone remain to some extent subjective.⁹ There are several specific IEEG patterns, such as high frequency oscillations²¹⁻²² and analyses of epileptic discharges within the conceptual construct of an epileptogenic network²³⁻²⁴ that are gaining increased attention but currently have insufficient data or experience to be addressed in these recommendations.

The end point of an IEEG exploration may be: (1) a decision to proceed with resection of the entire EZ. In this context, it is important to be mindful of the ambiguities of IEEG interpretation discussed above and exercise caution in extending the resection to EC, (2) a limited resection or ablation of the EZ in order to preserve EC and minimize post-operative deficits, (3) withhold resection altogether if there is no clear focus identified or the risk of deficit is deemed too high. The proportion of implanted patients that do not undergo resection can reach as much as 35-40%.²⁵⁻²⁶ A well defined hypotheses prior to the IEEG study helps minimize this undesirable and costly end point, or, (4) undergo re-implantation using the same or different IEEG modality^{25, 27} or following corpus callosotomy,²⁸ to further clarify ambiguities from the initial implantation. Resections following such multi-staged implantations may result in seizure freedom, but their cost-benefit becomes incrementally difficult to justify and are strongly discouraged as a general strategy.

General Indications

The case conference serves as the main forum where due considerations are given to pragmatic issues that guide IEEG usage (Table 1). Usage of IEEG purely as an exploratory procedure without a hypothesis, i.e. “a fishing expedition with extensive bilateral implantations”, or where the goals are palliative, is strongly discouraged. IEEG is unwarranted when it is not expected to change the surgical plan such as in typical cases of hypothalamic hamartoma or hemispheric syndromes with no hemispheric functions. Cognitive/behavioural disturbances or a medical comorbidity may also represent contra-indications for extraoperative IEEG modalities in some patients. The need to obtain the added information must be weighed against the limitations, risks and costs associated with IEEG studies. Lastly, following a full understanding of the risks and benefits of resecting the presumed EZ, the patient (or the family) is empowered to participate in the team’s decision of whether or not to proceed with IEEG study.

The decision in any clinical case is strongly influenced by the underlying pathological substrate. A graded scale of IEEG usage ranging from “highly recommended/mandatory”, to “optional”, to “little use/unwarranted” was recommended by the ILAE Diagnostic Methods Commission and the Pediatric Epilepsy Surgery Task Force.¹ The MRI negative cohort that may have very restricted or extensive neocortical involvement presents one of the strongest justifications for

IIEG.²⁹ In general, IIEG is more often utilized in MRI-negative extratemporal than temporal lobe foci. The temporal lobe cases are usually related to differentiating mesial from neocortical involvement, or the extent beyond the temporal lobe³⁰, or the side of seizure onset in patients with bilateral temporal epilepsy. Evaluation of mesial temporal structures with or without hippocampal sclerosis is a particularly common indication in adults, where bilateral IIEG recordings are used to confirm or refute lateralized onset hypotheses.³¹

IIEG studies are also useful in some patients with focal cortical dysplasia where the MRI visible structural abnormality often reflects only a part of the EZ³², a scenario more often encountered in type I dysplasia. IIEG is also valuable in patients with MRI features suggestive of “dual” pathology where the primary lesion is associated with dysplasia, or reveals multiple lesions such as tuberous sclerosis and nodular heterotopias or in hemispheric syndromes such as polymicrogyria³³ with preserved function. The role of IIEG in other specific lesional substrates such as discrete developmental tumors, acquired/low-flow vascular lesions, or Sturge-Weber syndrome is considered optional especially in the absence of MRI evidence of “dual” pathology. Some centers advocate primarily a lesionectomy whereas others opt for using IIEG to extend the resection beyond the anatomic lesion with hopes of achieving higher rates of seizure freedom.¹⁰⁻

15

Table 2 summarizes the general indications and scenarios that prompt IIEG usage. Inconclusive non-invasive data, where there is ambiguity in the consistent lateralization or precise location and extent of the EZ, is one of the commonest indications. Resolving divergent data occurs when non-invasive evaluation reveals discrepancies between clinical, anatomical (if any), neurophysiological, neuropsychological and functional imaging data. Adequate sampling of all possible sources is particularly crucial in the context of divergent non-invasive data that is often related to complex patterns of seizure propagation with interaction between multiple regions. It is worth emphasizing that divergence may at times be explained by known limitations of the scalp EEG, neuropsychological evaluations, and functional imaging tests that predispose to false lateralizing or localizing information thereby prompting unnecessary IIEG recording. These limitations are covered in depth by the ILAE diagnostics test utility recommendations.¹ Lastly, defining the cortex subserving eloquent functions via ESM may be required since noninvasive

tests such as fMRI, magnetoencephalography, transcranial magnetic stimulation, or Wada test are unable to always lateralize and localize function unambiguously; a limitation particularly encountered when delineating the extent of language cortex. Some lesions such as FCD type IIb and developmental tumors are generally non-functional, whereas other lesions such as polymicrogyria and Type 1 FCD may retain eloquent function³⁴⁻³⁶; atypical representation may occur in malformative substrates even when MRI is negative.³⁷ Like the recording of IIEEG, ESM can be performed either in the intra-operative or extra-operative setting. In one study³⁸, extra-operative IIEEG was found to have greatest utility for resolving discordant data and inconclusive extra-temporal and multi-lobar EZ.

As a supplement to the primary indications discussed above, electrical stimulation of the suspected cortex may be used to provoke manifestations mimicking spontaneous seizures or to provoke afterdischarges at low-thresholds to further corroborate the EZ although the variability of response precludes wide acceptance of this technique.³⁹ IIEEG may also provide information of prognostic value by accurately defining the nature of abnormalities beyond the resection. In specific circumstances, the IIEEG recording electrodes can also be used for radio-frequency thermocoagulation to selectively ablate defined targets and serve a therapeutic role. The scenarios in which this approach is efficacious are still being evaluated.⁴⁰⁻⁴² Finally, given the privileged access provided to human brain structures, IIEEG may be used under approved research protocols to study the mechanisms underlying normal or abnormal functions.

Modalities for IIEEG studies

There are several modalities available to perform IIEEG based on type of electrodes used and the specific technique employed. Table 3 summarizes the salient features of the types of electrodes used to perform IIEEG recordings. The electrodes may be made of different metals including stainless steel, gold-chromium alloy, nickel-chromium composite or platinum-iridium composite. Electrodes made of nickel-chromium or platinum-iridium composite are favored because they are nonmagnetic and compatible with MRI provided adequate safety testing has been performed and local protocols for safe MR scanning with the IIEEG electrodes are in place. Silver and copper electrodes are not used because of their toxic effects. The configurations, sizes, and

number of contacts vary with each type of electrode and can be further tailored to suit the clinical needs of individual cases. Special designs such as micro-contacts available for research purposes are not addressed in these recommendations.

One of the main factors differentiating various IEEG modalities is whether the study is done just prior to the resection but in the same intra-operative setting, ie, intra-operative ECoG, or done through an independent implantation procedure with chronic extra-operative monitoring; the main indications for the latter are the need for ictal capture or where intra-operative ESM is not feasible. Scenarios requiring ictal capture include patients with divergent non-invasive data, or with inconclusive non-invasive data in the context of “dual” pathology or multiple lesions such as tuberous sclerosis and nodular heterotopias. In hemispheric syndromes such as polymicrogyria with preserved function, ictal capture through extra-operative IEEG may be the only means to allow focal/lobar resections instead of a more extensive surgery such as hemispherectomy that may lead to functional deficits.³³ For chronic extra-operative monitoring, the following modalities can be distinguished: (1) Subdural grids, strips or a combination of subdural grids/strips and depth electrodes can be implanted through an open craniotomy (CEEG), (2) intra-cerebral depth electrodes can be implanted stereotactically (SEEG) through burr holes, (3) a combination of subdural strips and depth electrodes can be implanted through burr holes employing a hybrid (HEEG) of fluoroscopy and stereotaxy, (4) linear strands of electrodes can be placed through the foramen ovale, or (5) peg electrodes are placed epidurally through twist drill holes or burr holes. There is no single “best” IEEG modality. Each has unique resource needs, advantages, limitations, and risks that make it more or less suitable in specific clinical scenarios (Table 4).

Intraoperative ECoG

Technique.

The IIEG recording and ESM are done intra-operatively through the craniotomy, prior to, during and often following resection. A combination of subdural strip/grid and depth electrodes can be used. The subdural electrodes can be slipped under the dura beyond the craniotomy to cover basal or interhemispheric regions. Depth electrodes can be inserted manually between the subdural electrodes to sample deep structures either under direct visual or neuro-navigational system guidance. Alternatively, individual wire tipped “wick” electrode held in place over exposed cortical surface and secured in a frame can be used to record over the exposed hemispheric convexity. The spacing between the wick electrodes can be adjusted thus allowing greater flexibility in sampling uneven regions of the convexity cortex. However, wick electrodes cannot be used for interhemispheric or basal foci.

Strengths and limitations

A major advantage of ECoG is that it avoids the discomfort, risks and costs of staged implantation and extra-operative IIEG monitoring and the need for a second surgical procedure. Added advantage is that recording and ESM mapping can be conducted prior to, periodically during, and at the end of resection to maximize removal of all regions revealing significant abnormality while preserving function.

The main limitation of ECoG is the time constraint of the recording that generally lasts 20-60 minutes. It thus records mainly IEDs or CEDs and is unsuitable when ictal data or advanced analyses such as high frequency oscillations are considered essential for ensuring surgical success. Placement of electrode within specific deep targets is less accurate without stereotactic guidance. Furthermore, for practical reasons ECoG generally uses fewer electrodes compared to CEEG, SEEG or HEEG and while large areas may be sampled, these are generally recorded sequentially rather than simultaneously, such that interpretation of propagated IEDs and ictal rhythms is limited. Lastly, although the effects of anesthesia generally do not impede recording of abnormalities or ESM⁴³⁻⁴⁴, the effects are unpredictable and may occasionally render the study unhelpful. Recordings performed with the patient awake maximize the yield but are not feasible in young or uncooperative patients.

Risk/morbidity

Since ECoG is performed during surgery it carries virtually no risk/morbidity other than the small incremental risk related to prolongation of anesthesia. In that sense it may be regarded as the only “non-invasive” IEEG modality available.

Specific Indications

A growing number of centers consider focal CEDs to be reliable markers for the EZ and use ECoG to tailor resections guided by periodic recording until the CEDs are abolished^{16,17,20}, thus alleviating the need for ictal capture through extra-operative IEEG. Although typically associated with dysplastic substrate (especially type II focal cortical dysplasia), CEDs may also be evident in patients with tuberous sclerosis, encephaloclastic lesions and ulegyria.^{18-19,45} In some patients, CEDs may be evident on the scalp EEG and help in planning the surgical strategy. Similar considerations apply for patients with specific types of CEDs such as focal continuous spike wave during sleep, or those associated with epilepsy partialis continua.

The utility of traditional IEDs and background abnormalities to tailor resection beyond the boundaries of an anatomic lesion is equivocal.¹ ECoG proponents have claimed improved outcomes after its usage compared to lesionectomy alone in a variety of substrates.¹³⁻¹⁴ ECoG is considered useful to tailor resection in patients with dual-pathology, e.g., MRI-proven mesial temporal sclerosis associated with cortical dysplasia. By contrast, in patients with mesial temporal sclerosis alone, several studies failed to document correlation of ECoG findings with surgical outcome arguing against its usage for tailoring mesial resections.⁴⁶⁻⁴⁷ Lastly, ECoG may be the only option available in cases where medical contraindications or resource limitations preclude the use of extra-operative IEEG.

Extraoperative IEEG through open craniotomy [CEEG]

Technique.

As with ECoG, CEEG uses subdural grids/strips or a combination of subdural electrodes and depth electrodes that are placed under direct observation following an open craniotomy. While the location and size of the craniotomy are important for achieving the desired electrode coverage, it

should also take the anticipated resection into consideration. Special configuration such as “hockey stick” aid placement along interhemispheric regions and may be designed to record simultaneously from both hemispheres.⁴⁸ MRI-generated gyral maps revealing venous/sulcal landmarks and intra-operative neuro-navigation facilitate the implantation.

When using combined subdural and depth electrodes, the latter can be placed between or through grids and strips and fixed to the silicone. A splitting or perforation of the grids is frequently required to insert the depth electrode. A brief ECoG recording may be acquired at the end of the implantation to check whether the electrodes work or the abnormalities extend beyond the coverage, so that the electrode positioning can be adjusted. Photographs of the cortex and electrodes taken intra-operatively help define electrode placement but the exact location can be determined extra-operatively on MRI or high-resolution CT scan co-registered to the MR.⁴⁹

Strengths and limitations

The main strength of the CEEG modality is that it allows coverage afforded by both subdural grids/strips and select depth electrodes. Subdural electrodes provide excellent coverage of large areas of the hemispheric surface, coverage over the convexity is generally easier than interhemispheric or basal cortex. The fixed setting within the silastic sheet allows accurate depiction of the surface distribution of the EZ and its relationship to EC especially the motor and language cortex on the convexity. Both the subdural and depth electrodes can be used as strategic guides during resection. CEEG can be used safely in young children and is generally well tolerated even in infancy.⁵⁰⁻⁵¹

It must be remembered, however, that subdural electrodes may miss activity from deep epileptogenic sources or closed fields, a limitation overcome by concomitant usage of intra-cerebral depth electrodes placed in select deep targets. The number of depth electrodes implanted during CEEG is in general limited compared to SEEG/HEEG studies and the electrodes are shorter but the open access enables greater sampling of lesion or cortex compared to white matter. The information from subdural and depth electrodes is generally complementary depending upon the location and extent of the EZ⁵²⁻⁵³; in some patients, epileptic discharges may be evident only on the subdural contacts⁵⁴⁻⁵⁵, in others they may be seen only in the intracerebral depth contacts.²⁰

The subdural grid may pose problems in allowing optimal contact over uneven cortical surfaces or avoiding vascular structures. Bilateral grid placements are cumbersome and usually not done because of the large craniotomy required and significant risks of complications.⁵⁶ Wrapping all three surfaces of one hemisphere (dorsolateral, basal and mesial) with grids also increases the risk of venous occlusion and brain swelling. The trajectory of basal or interhemispheric electrodes is difficult to control since irregularities of the adjacent bone or dural adhesions tend to deflect the electrodes from their intended targets. Interhemispheric coverage may be particularly challenging due to bridging veins at the midline but is generally still feasible and safe.⁴⁸ Furthermore, subdural electrode placement is usually challenging in patients who have undergone prior surgery since the dura is often adherent and difficult to peel. Extra-dural placement may be an option in such cases although it precludes performing ESM. Alternatively, depth electrodes may be used alone. Lastly, CEEG requires a generous craniotomy at the time of implantation and may occasionally have to be extended at time of resection when all data is analysed.

Risks/morbidity

CEEG is generally less well tolerated compared to SEEG/HEEG. Complications including wound infection, CSF leak, intracranial bleeding, raised intracranial pressure, or symptomatic pneumocephalus have all been reported but are rare.⁵⁷⁻⁵⁸ Depth placements may lead to intracerebral micro-hemorrhage, subdural electrodes may cause local inflammatory reactions. Prophylactic steroids help minimize the risk of reaction to the implant, but might theoretically reduce seizures and IEDs in some patients. Permanent neurological deficit or death associated with implantation is rare. In one series of 198 monitoring sessions on 187 patients, 1 death and 3 cases of permanent neurological deficits occurred⁵⁶, 2 deaths were reported in another series of 71 implanted patients⁵⁹; in the latter study, complication rates correlated with maximal size of grid used, greater number of electrodes, and electrode density per cortical surface implanted.

In a recent review and meta-analysis of 21 studies with a total of 2,542 patients, the reported mean number of electrodes per patient and duration of monitoring varied from 52 to 95, and 5 to 17 days, respectively.⁴ Neurologic infections (pooled prevalence 2.3%, 95% confidence interval 1.5-3.1), superficial infections (3.0%, 1.9-4.1), intracranial hemorrhage (4.0%, 3.2-4.8), and elevated intracranial pressure (ICP) (2.4%, 1.5-3.3) were found to be the most common adverse

events. Up to 3.5% of patients required additional surgical procedure(s) for management of these adverse events. Increased number of electrodes (≥ 67) was found to be independently associated with increased incidence of adverse events (fairly specific to raised ICP).

Specific risks may arise from region related coverage, e.g., placements over the interhemispheric regions may be associated with leg weakness. In a subgroup of patients, the complications may be severe enough to warrant early surgical interventions. Risks are expectedly higher in patients who are re-operated but do not appear to be a significant concern.⁶⁰ Bilateral implantations have been associated with an increased risk for the occurrence of complications. In one series two of the three patients having permanent neurological deficit after subdural grid implantation had undergone bilateral placement of grid electrodes.⁵⁶

Specific Indications

CEEG is suited for most general indications for IEEG monitoring² including infants and young children.⁵¹ CEEG is specifically indicated when needing evaluation of large areas of the hemispheric surface for accurate topographical mapping of EC along with select deep targets/lesions.^{50,61-62} It is particularly well suited for patients with hemispheric polymicrogyria with preserved function or other large ill-defined dysplastic lesions or tubers adjacent to EC, which may have atypical representation and need detailed cortical mapping. Likewise, patients with hippocampal sclerosis and FCD (dual pathology) often benefit from combined electrode usage as do those presenting with divergent data in the context of large or deep-seated lesions.

Stereotactic intra-cerebral EEG (SEEG)

Technique.

The SEEG method uses only intra-cerebral depth electrodes, but the number of depth electrodes used is much larger compared to CEEG, where use of the depth electrodes is restricted to only a few specific deep targets. The trajectories of the depth electrodes must be planned thoroughly in a 3D-Gadolinium enhanced-MRI data set to avoid crossing blood vessels; in some centers, however, angiography is still acquired and co-registered with the 3D MRI. Generally 5 to 18

multi-contact electrodes are implanted under general anaesthesia. They are inserted stereotactically through a twist drill hole or burr hole and placed either with a frame or under neuro-navigational guidance, and sometimes, robotic assistance. The position of the electrodes is reconstructed using CT superimposed on MRI, or directly visualized on MRI if the electrodes are MRI compatible.

Strengths and limitations

The main advantage of SEEG is that it can provide an accurate sampling of all cortical areas not only at the lateral and mesial aspect of the cerebral hemispheres, but also the bottom of the sulci or deep-seated structures or lesions.⁶³⁻⁶⁵ When electrodes are densely implanted in a particular region, it may be possible to provide a 3-D assessment of the epileptogenic network by interpolation, a philosophical objective that is purportedly different from CEEG studies where only a few depth electrodes are used. In the scenarios requiring bilateral implantation, SEEG allows extensive coverage of both hemispheres without performing large craniotomies. A technical advantage compared to CEEG is the capability to remove the electrodes after completion of the SEEG study without a second operative procedure and the ability to plan the craniotomy for resection after all data is analyzed.

SEEG electrodes sample the gyral crowns, but do not provide as extensive a coverage of gyral surfaces as subdural grids and strips. Thus, although ESM is feasible with SEEG, its accuracy is generally more restricted than CEEG especially for mapping atypical representations of EC. SEEG also allows ESM of white matter tracts that may be of added value in defining motor pathways and planning resection but precise anatomic coregistration is required to differentiate effects of grey matter stimulation. SEEG recordings can be more difficult to perform in very young children below age 2-3 years because of technical reasons (i.e. thickness of the skull).

Risks/morbidity

The morbidity reported using SEEG may vary from 0 to 7.5%, and is predominantly related to hemorrhagic or infectious complications.⁶⁶ In this meta analysis, the pooled prevalence of complications was low (1.3%) with permanent neurological deficits being 0.6%; a rate similar to that reported following CEEG. Mortality related directly to the procedure is very rare but can occur.⁶⁷ A few studies reported specifically the risks of SEEG in children; the procedure also

appears to be safe in this age group.^{26, 68}

In one series of 215 SEEG implantations in 211 patients, morbidity related to electrode implantation occurred in 12 procedures (5.6%), with severe permanent deficits from intracerebral hemorrhage in 2 (1%) patients.⁶⁸ Indeed, intracerebral hematomas are the main complications reported, occurring either during or shortly after insertion or immediately after withdrawal of the SEEG electrodes upon completion of invasive monitoring. Recent advances in implantation techniques including acquisition of brain 3-dimensional angiography and magnetic resonance imaging in frameless and markerless conditions, advanced multimodal planning, and robot-assisted implantation may help in further reducing morbidity.⁶⁹

Specific Indications

As with CEEG usage, SEEG can be applied to most general indications for IEEG. SEEG is best suited to record all deep structures particularly the amygdala-hippocampal complex, the insula, and subcortical targets such as heterotopic grey matter. When exploration of both hemispheres is indicated, SEEG (or HEEG) is safer than CEEG and becomes the preferred modality.

Hybrid extraoperative EEG (HEEG)

Technique

As a hybrid between CEEG and SEEG, HEEG allows implantations of subdural strips and depth electrodes and extensive coverage either unilaterally or bilaterally. Subdural strips are implanted through fronto-central trephine holes under fluoroscopy to cover the cerebral convexity. Using the same trephine holes, an additional number of depth electrodes may be implanted to sample deep targets using a stereotactic head frame. The technique has undergone several modifications in the course of time and it remains the preferred approach of IEEG monitoring in several epilepsy centers.^{25,52, 70-72}

Strengths and limitations

HEEG allows extensive sampling from the cortical convexity and deep regions, and the removal of the electrodes without a second operative procedure. The limitations are primarily undersampling of the posterior temporobasal and the interhemispheric cortical surfaces, which

may not be reached by the subdural strip electrodes. The coverage of the cortical surface on the hemispheric convexity is limited compared to CEEG.

Risks/morbidity

In one series of 70 bilaterally and symmetrically implanted cases, transient complications occurred in 4.2%, while in 1.4% there was possibly permanent slight neurological deficit due to intracerebral haemorrhage after implantation of an intracerebral electrode.⁷³ More recently a study of 163 adults reported overall complications in 8 (4.9%), of whom 5 required treatment or led to neurological impairment though no permanent morbidity or mortality was recorded. Infection occurred in 1.2% and hemorrhage in 3.7% of patients.⁷²

Specific indications

The primary indication for HEEG is extensive exploration of the convexity neocortex and deeper regions including cases where bilateral implantations are required in patients with non-lateralizing and/or divergent non-invasive data but in whom there is clinical suspicion of a resectable lateralized focus.^{25,53}

Foramen Ovale IEEG

Technique

This electrode is a multi-contact electrode placed under local or mild general anesthesia inferior to the zygoma and medial to the anterior ramus of the mandible in an approach similar to the surgical approach taken to coagulate the Gasserian ganglion for tic douloureux.⁷⁴ A hollow bore needle is placed through the foramen ovale, through which the electrode is threaded so that it comes to lie along the long axis of the hippocampus. These electrodes are usually placed bilaterally.

Strengths and limitations

The main advantage is that it employs a natural skull opening and thus considered “semi-invasive”. Foramen Ovale recordings are generally technically satisfactory but the sampling is mainly from the middle and posterior hippocampus. A large proportion of discharges seen at the most distal foramen ovale contacts, possibly representing sources in the posterior

parahippocampal gyrus, are not seen at the more anterior contacts.⁷⁵ As such, they are less accurate in detecting sources in the very anterior portions of the hippocampi or in the amygdalae as compared to the SEEG/HEEG.

Risks/morbidity

The complication rate for this modality is significantly less than for other extra-operative IEEG modalities. Still, occasional subarachnoid hemorrhages, infection and occasional post removal tic-like pain syndrome have been reported.⁷⁶⁻⁷⁷

Specific indications

The main clinical indication is unclear laterality of a likely mesial temporal seizure focus.⁷⁶⁻⁷⁷

The approach appears to be gaining converts to its use and in a recent publication has shown its continued utility in differentiating side of onset of mesial or inferior temporal seizures.

Epidural IEEG

Technique

Epidural peg electrodes are placed through a tight fitting twist drill hole; the base of the electrode sits on top of the exposed skull whereas the stem penetrates the skull.⁷⁸⁻⁷⁹ The length of the stem can be varied and made to match the thickness of the skull where it is being inserted. The tip of the electrode resides in the epidural space overlying the cortex of interest. Since the electrode is limited in the field of recording, multiple electrodes are usually used.

Strengths and limitations

The Epidural peg modality is less invasive than CEEG and SEEG/HEEG, but limited to sampling the convexity. Furthermore, epidural placement precludes ESM.

Risks/morbidity

While technically it is a fairly easy to insert, there is a significant risk of infection.⁸⁰

Specific indications

The modality has no use by itself but occasionally may be employed in conjunction with other invasive approaches to monitor large areas of contralateral brain or more remote sites from the site where more invasive electrodes have been used.

"Flow Chart" Protocol

In an attempt to reconcile various practices and make general recommendations to guide strategy, the recommendations for various modalities are schematically summarized within the framework of a flow chart protocol (Figure 1) based on their known strengths, limitations, risks and costs discussed above. The decisions generally occur within the context of a multidisciplinary case conference reviewing all non-invasive data. Once the scenarios where IEEG is unwarranted or contraindicated are excluded, the next key step is deciding the region(s) to be sampled and choosing the modality that is best suited within the constraints of each center's resources and experience.

Intra-operative ECoG is gaining increasing popularity at many centers worldwide and is not just relegated to resource poor regions. In those patients where the ECoG turns out to be uninformative, the electrodes may be implanted for extra-operative IEEG studies - a flexible cost-effective strategy often well accepted by patients/families. In general the main choice for extraoperative IEEG is between the CEEG, SEEG, and HEEG modalities; Foramen Ovale and epidural peg play very specific and restricted roles. Whereas CEEG is better suited for unilateral widespread cortical EZs that require detailed ESM, SEEG or HEEG are better suited for exploration of deep or bilateral regions. The latter two are much better tolerated than CEEG, a factor driving their increasing popularity. Furthermore, an added advantage is that the craniotomy for resection is designed after the surgical plan is finalized whereas CEEG requires a more generous craniotomy at the time of implantation that may occasionally have to be extended at time of resection when all data is analyzed.

Lastly, IEEG may fail to provide the necessary information and lead to explantation without resection. A continued refinement of surgical candidacy and selection of modality will help minimize this unfortunate and disheartening scenario. Note that the flow chart refrains from depicting the loop representing multi-staged implantation IEEG, a strategy discouraged for general application as it diminishes the need for a clear hypothesis prior to the initial implantation and promotes an “exploratory” usage of the procedure.

Conclusions

The consensus based recommendations presented herein strive to achieve an optimal balance between perceived efficacy, safety and incremental cost-benefit. Neither the position of insisting on one particular IEEG modality in all cases or rejecting its added value altogether in any scenario lend themselves to scientific scrutiny or meet the complex needs of various clinical cohorts. Asking the seminal question of when and how the added information from a particular IEEG modality altered the resection from a surgical plan based on non-invasive data alone and how this improved outcome in specific clinical scenarios will be an essential step towards minimizing cultural biases across centers and an important step towards standardization.

Key points:

- A consensus-based expert recommendation on the diagnostic utility of IEEG is presented,
- It provides an overview of various IEEG modalities emphasizing their strengths, limitations, and risks.
- The general indications for IEEG usage are proposed followed by specific scenarios where each IEEG modality is believed to be best suited.

We confirm that we have read the Journal's position on issues involved in ethical publication and affirm that this report is consistent with those guidelines

Acknowledgements : We wish to thank the International League Against Epilepsy (ILAE) and its Diagnostic Commission for support for the Neurophysiology Task Force of meetings

Disclosure of Conflict of Interest: This report was written by experts selected by the International League Against Epilepsy (ILAE) and was approved for publication by the ILAE. Opinions expressed by the authors, however, do not necessarily represent official policy or position of the ILAE.

None of the authors has any conflict of interest to disclose.

References

1. Jayakar P, Gaillard WD, Tripathi M, et al. Diagnostic Test Utilization in Evaluation for Resective Epilepsy Surgery in Children. Recommendations on behalf of the Task Force for Paediatric Epilepsy Surgery and the Diagnostic Commission of the ILAE. *Epilepsia* 2014;55:507-18.
2. Bulacio JC, Jehi L, Wong C, et al. Long-term seizure outcome after resective surgery in patients evaluated with intracranial electrodes. *Epilepsia* 2012;53:1722-30.
3. Wellmer J, von der Groeben F, Klarman U, et al. Risks and benefits of invasive epilepsy surgery workup with implanted subdural and depth electrodes. *Epilepsia* 2012;53:1322-32.
4. Arya R, Mangano FT, Horn PS, et al. Adverse events related to extraoperative invasive EEG monitoring with subdural grid electrodes: a systematic review and meta-analysis. *Epilepsia* 2013 May; 54:828-39.
5. American Academy of Neurology. Clinical Practice Guideline Process Manual, 2011 ed. St. Paul, MN: <http://tools.aan.com/globals/axon/assets/9023.pdf>.

6. Gloor P. Contributions of electroencephalography and electrocorticography to the neurosurgical treatment of the epilepsies. *Adv Neurol* 1975;8:59-105.
7. Lachaux, J.P., Rudrauf, D., Kahane, P. Intracranial EEG and human brain mapping. *Journal of Physiology* 2003;97:613–28.
8. von Ellenrieder N, Beltrachini L, Muravchik CH. Electrode and brain modeling in stereo-EEG. *Clin Neurophysiol* 2012; 123:1745-54.
9. Singh S, Sandy S, Wiebe S. Ictal onset on intracranial EEG: Do we know it when we see it? State of the evidence. *Epilepsia* 2015; 56:1629-38.
10. Giulioni M, Rubboli G, Marucci G, et al. Seizure outcome of epilepsy surgery in focal epilepsies associated with temporomesial glioneuronal tumors: lesionectomy compared with tailored resection. *J Neurosurg* 2009; 111:1275-82.
11. Chang EF, Christie C, Sullivan JE, et al. Seizure control outcomes after resection of dysembryoplastic neuroepithelial tumor in 50 patients. *J Neurosurg Pediatr* 2010; 5:123-30.
12. Ogiwara H, Nordli DR, DiPatri AJ, et al. Pediatric epileptogenic gangliogliomas: seizure outcome and surgical results. *J Neurosurg Pediatr* 2010;5:271-6.
13. Tripathi M, Garg A, Gaikwad S, et al. Intra-operative electrocorticography in lesional epilepsy. *Epilepsy Res* 2010; 89:133-41.
14. Gelinas JN, Battison AW, Smith S, et al. Electrocorticography and seizure outcomes in children with lesional epilepsy. *Childs Nerv Syst* 2011; 27:381-90.
15. Englot DJ, Berger MS, Barbaro NM, et al. Factors associated with seizure freedom in the surgical resection of glioneuronal tumors. *Epilepsia* 2012; 53:51-7.
16. Palmieri A, Gambardella A, Andermann F, et al. Intrinsic epileptogenicity of human dysplastic cortex as suggested by corticography and surgical results. *Ann Neurol* 1995; 37:476-87.
17. Mohamed AR, Bailey CA, Freeman JL, et al. Intrinsic epileptogenicity of cortical tubers revealed by intracranial EEG monitoring. *Neurology* 2012; 79:2249-57.
18. Pascoal T, Paglioli E, Palmieri A, et al. Immediate improvement of motor function after epilepsy surgery in congenital hemiparesis. *Epilepsia* 2013; 54:1360-7.

19. Schilling LP, Kieling RR, Pascoal TA, et al. Bilateral perisylvian ulegyria: an under-recognized, surgically remediable epileptic syndrome. *Epilepsia* 2013; 54:1360-7.
20. Harvey AS, Mandelstam SA, Maixner WJ, et al. The surgically remediable syndrome of epilepsy associated with bottom-of-sulcus dysplasia. *Neurology* 2015; 84:2021-8.
21. Höller Y, Kutil R, Klaffenböck L, et al. High frequency oscillations in epilepsy and surgical outcome. A meta-analysis. *Front Hum Neurosci* 2015; 9:574.
22. van 't Klooster MA, Leijten FS, Huiskamp G, et al. HFO study group. High frequency oscillations in the intra-operative ECoG to guide epilepsy surgery ("The HFO Trial"): study protocol for a randomized controlled trial. *Trials* 2015;16:422.
23. Kahane P, Landré E, Minotti L, et al. The Bancaud and Talairach view on the epileptogenic zone: a working hypothesis. *Epileptic Disord* 2006; 8:S16-26.
24. Bartolomei F, Bettus G, Stam CJ, et al. Interictal network properties in mesial temporal lobe epilepsy: a graph theoretical study from intracerebral recordings. *Clin Neurophysiol* 2013;124:2345-53.
25. Placantonakis DG, Shariff S, Lafaille F, et al. Bilateral intracranial electrodes for lateralizing intractable epilepsy: efficacy, risk, and outcome. *Neurosurgery* 2010; 66:274-83.
26. Gonzalez-Martinez J, Mullin J, Bulacio J, et al. Stereoelectroencephalography in children and adolescents with difficult-to-localize refractory focal epilepsy. *Neurosurgery* 2014; 75:258-68.

27. Weiner HL, Ferraris N, LaJoie J, et al. Epilepsy surgery for children with tuberous sclerosis complex. *J Child Neurol* 2004;19:687-9.
28. Chen PC, Baumgartner J, Seo JH, et al. Bilateral intracranial EEG with corpus callosotomy may uncover seizure focus in nonlocalizing focal epilepsy. *Seizure* 2015; 24:63-9.
29. Jayakar P, Dunoyer C, Dean P, et al. Epilepsy Surgery in Patients with Normal or Non-focal MRI Scans: Integrative Strategies Offer Long-term Seizure Relief. *Epilepsia* 2008; 49:758-64.
30. Kahane P, Barba C, Rheims S, et al. The concept of temporal 'plus' epilepsy. *Rev Neurol* 2015; 171: 267-72.
31. So N, Olivier A, Andermann F, et al. Results of surgical treatment in patients with bitemporal epileptiform abnormalities. *Ann Neurol* 1989; 25:432-9.
32. Aubert S, Wendling F, Regis J, et al. Local and remote epileptogenicity in focal cortical dysplasias and neurodevelopmental tumours. *Brain* 2009;132:3072-86.
33. Wang DD, Knox R, Rolston JD, et al. Surgical management of medically refractory epilepsy in patients with polymicrogyria. *Epilepsia* 2015 Dec 9. doi: 10.1111/epi.13264. [Epub ahead of print].
34. Marusic P, Najm IM, Ying Z, et al. Focal cortical dysplasias in eloquent cortex: functional characteristics and correlation with MRI and histopathologic changes. *Epilepsia* 2002; 43: 27-32.
35. Janszky J, Ebner A, Kruse B, et al. Functional organization of the brain with malformations of cortical development. *Ann Neurol* 2003; 53:759-67.
36. Burneo JG, Kuzniecky RI, Bebin M, et al. Cortical reorganization in malformations of cortical development: a magnetoencephalographic study. *Neurology* 2004; 63:1818-24.
37. Gaillard WD, Berl MM, Moore EN, et al. Atypical language in lesional and nonlesional complex partial epilepsy. *Neurology* 2007; 69:1761-71.
38. Brna P, Duchowny M, Jayakar P, et al. The diagnostic utility of intracranial EEG monitoring for epilepsy surgery in children. *Epilepsia* 2015; 56:1065-70.

39. Kovac S, Kahane P, Diehl B. Seizures induced by direct electrical cortical stimulation - Mechanisms and clinical considerations. *Clin Neurophysiol* 2014; S1:388-2457.
40. Guénot M, Isnard J, Catenoux H, et al. SEEG-guided RF-thermocoagulation of epileptic foci: A therapeutic alternative for drug-resistant non-operable partial epilepsies. *Adv Tech Stand Neurosurg* 2011; 36:61-78.
41. Cossu M, Fuschillo D, Cardinale F, et al. Stereo-EEG-guided radio-frequency thermocoagulations of epileptogenic grey-matter nodular heterotopy. *J Neurol Neurosurg Psychiatry* 2014;85:611-17.
42. Catenoux H, Mauguière F, Montavont A, et al. Seizures Outcome After Stereoelectroencephalography-Guided Thermocoagulations in Malformations of Cortical Development Poorly Accessible to Surgical Resection. *Neurosurgery* 2015;77:9-14.
43. Breshears JD, Roland JL, Sharma M, et al. Stable and dynamic cortical electrophysiology of induction and emergence with propofol anesthesia. *Proc Natl Acad Sci* 2010; 107:21170-5.
44. Fukui K, Morioka T, Hashiguchi K, et al. Relationship between regional cerebral blood flow and electrocorticographic activities under sevoflurane and isoflurane anesthesia. *J Clin Neurophysiol* 2010; 27:110-5.
45. Turkdogan D, Jayakar P, Duchowny M, et al. Subdural EEG Patterns in Children with Taylor-type Cortical Dysplasia: Comparison with Nondysplastic Lesions. *J Clin Neurophys* 2005; 22:37-42.
46. Tran TA, Spencer SS, Marks D, et al. Significance of spikes recorded on electrocorticography in nonlesional medial temporal lobe epilepsy. *Ann Neurol* 1995; 38:763-70.
47. Kanazawa O, Blume WT, Girvin JP. Significance of spikes at temporal lobe electrocorticography. *Epilepsia* 1996; 37: 50-5.
48. Bekelis K, Radwan TA, Desai A, et al. Subdural interhemispheric grid electrodes for intracranial epilepsy monitoring: feasibility, safety, and utility: clinical article. *J Neurosurg* 2012;117:1182-8.

49. Serra C, Huppertz HJ, Kockro RA, et al. Rapid and accurate anatomical localization of implanted subdural electrodes in a virtual reality environment. *Cent Eur Neurosurg* 2013;74:175-82.
50. Wyllie E, Luders H, Morris HH, et al. Subdural electrodes in the evaluation for epilepsy surgery in children and adults. *Neuroped* 1988; 19:80-6.
51. Taussig D, Dorfmueller G, Fohlen M, et al. Invasive explorations in children younger than 3 years. *Seizure* 2012; 21:631-8.
52. Spencer SS, Spencer DD, Williamson PD, et al. Combined depth and subdural electrode investigation in uncontrolled epilepsy. *Neurology* 1990; 40:74-9.
53. Brekelmans GJ, van Emde Boas W, Velis DN, et al. Comparison of combined versus subdural or intracerebral electrodes alone in presurgical focus localization. *Epilepsia* 1998; 39:1290-301.
54. Madhavan D, Weiner HL, Carlson C, et al. Local epileptogenic networks in tuberous sclerosis complex: a case review. *Epilepsy Behav* 2007; 11:140-6.
55. Major P, Rakowski S, Simon MV, et al. Are cortical tubers epileptogenic? Evidence from electrocorticography. *Epilepsia* 2009; 50:147-54.
56. Hamer HM, Morris HH, Mascha EJ, et al. Complications of invasive video-EEG monitoring with subdural grid electrodes. *Neurology* 2002; 58:97-103.
57. Burneo JG, Steven DA, McLachlan RS, et al. Morbidity associated with the use of intracranial electrodes for epilepsy surgery. *Can J Neurol Sci* 2006; 33:223-7.
58. Vale FL, Pollock G, Dionisio J, et al. Outcome and complications of chronically implanted subdural electrodes for the treatment of medically resistant epilepsy. *Clin Neurol Neurosurg* 2013; 115:985-90.
59. Wong CH, Birkett J, Byth K, et al. Risk factors for complications during intracranial electrode recording in presurgical evaluation of drug resistant partial epilepsy. *Acta Neurochir (Wien)* 2009;151:37-50.
60. Vadera S, Jehi L, Gonzalez-Martinez J, et al. Safety and Long Term Seizure Free Outcomes of Subdural Grid Placement in Patients with a History of Prior Craniotomy. *Neurosurgery* 2013; 73:395-400.

61. Nespeca M, Wyllie E, Luders H, et al. EEG Recording and functional localization studies with subdural electrodes in infants and young children. *J Epilepsy* 1990; 3:107-24.
62. Pieper T, Kudernatsch M, Kessler S, et al. Invasive pre-surgical epilepsy diagnostics in children: The advantage of depth electrodes combined with subdural grids in the evaluation of focal cortical dysplastic lesions. *Neuropediatrics* 2011;42:S10
63. Munari C, Bancaud J. The role of stereo-electro-encephalography (SEEG) in the evaluation of partial epileptic patients. In: Porter RJ, Morselli PL (Eds.), *The epilepsies*. Butterworths, London, 1987; 267-306.
64. Kahane P, Minotti L, Hoffmann D, et al. Invasive EEG in the definition of the seizure onset zone: depth electrodes. In: Rosenow F, Lüders HO, eds. *Handbook of Clinical Neurophysiology, Vol.3. Presurgical assessment of the epilepsies with clinical neurophysiology and functional imaging*. Amsterdam: Elsevier BV, 2004;109-133.
65. Kahane P, Dubeau F. Intracerebral depth electrodes electroencephalography (stereoelectroencephalography). In : Ebersole JS, Husain AM, Nordli DR, eds. *Current practice of clinical electroencephalography, 4th edition*. Philadelphia: Wolters Kluwer Health, 2014: 393-441.
66. Mullin JP, Shriver M, Alomar S, Najm I, Bulacio J, Chauvel P, Gonzalez-Martinez J. Is SEEG safe? A systematic review and meta-analysis of stereo-electroencephalography-related complications. *Epilepsia*. 2016 Mar;57(3):386-401.
67. Serletis D, Bulacio J, Bingaman W, et al. The stereotactic approach for mapping epileptic networks: a prospective study of 200 patients. *J Neurosurg* 2014; 121:1239-46.
68. Cossu M, Cardinale F, Colombo N, et al. Stereoelectroencephalography in the presurgical evaluation of children with drug-resistant focal epilepsy. *J Neurosurg* 2005; 103:Supp 4:333-43.
69. Cardinale F, Cossu M, Castana L, et al. Stereoelectroencephalography: surgical methodology, safety, and stereotactic application accuracy in 500 procedures. *Neurosurgery* 2013; 72:353-66.

70. van Veelen CW, Debets RM, van Huffelen AC, et al. Combined use of subdural and intracerebral electrodes in preoperative evaluation of epilepsy. *Neurosurgery* 1990; 26:93-101.
71. Guerrini R, Scerrati M, Rubboli G, et al. Commission for Epilepsy Surgery of the Italian League Against Epilepsy. Overview of presurgical assessment and surgical treatment of epilepsy from the Italian League Against Epilepsy. *Epilepsia* 2013; 54 Suppl 7:35-48.
72. Mathon B, Clemenceau S, Hasboun D, et al. Safety profile of intracranial electrode implantation for video-EEG recordings in drug-resistant focal epilepsy. *J Neurol* 2015 Sep 26. [Epub ahead of print].
73. van Veelen CW, Debets RM. Functional neurosurgery in the treatment of epilepsy in The Netherlands. Aspects of presurgical evaluation and the contribution of subdural and stereotactically implanted depth electrodes in the Dutch Workgroup for Functional Surgery. *Acta Neurochir (Wien)* 1993; 124:7-10.
74. Wieser, HG, Elger, CE, Stodieck, SRG. The foramen ovale electrode: A new recording method for the preoperative evaluation of patients suffering from mesio-basal temporal lobe epilepsy. *Electroencephalogr Clin Neurophysiol* 1985; 61:314-22.
75. Fernández Torre JL, Alarcón G, Binnie CD, et al. Comparison of sphenoidal, foramen ovale and anterior temporal placements for detecting interictal epileptiform discharges in presurgical assessment for temporal lobe epilepsy. *Clin Neurophysiol* 1999;110:895-904.
76. Wieser HG and Schindler K, Foramen ovale and epidural electrodes in the definition of the epileptogenic zone. In: Lüders HO *Textbook of Epilepsy Surgery*, 2008, Chapter 71, pp 629-640
77. Sheth, SA, Aronson, JP, Shafi, MM, et.al. Utility of foramen ovale electrode in mesial temporal lobe epilepsy. *Epilepsia* 2014; 55:713-24.
78. Barnett, GH, Burgess, RC, Awad, IA, et.al. Epidural pegs electrodes for the presurgical evaluation of intractable epilepsy. *Neurosurgery* 1990; 27:113-5.

79. Awad, IA, Assirati, JA Jr., Burgess, R, et.al. A new class of electrodes of “intermediate invasiveness”: Preliminary experience with epidural pegs and foramen ovale electrodes in the mapping of seizure foci. *Neurol Res* 1991; 13:117-83.
80. Schüler, P , Stefan, H, Neubauer, U, et.al. Foramen-Ovale und subduralen Streifenektroden zur präoperativen Epilepsiediagnostik. . 36th Annual Meeting German EEG Society. Celle 152, 1991.

Figure legends

Figure 1. Protocol guiding IIEG strategies.

Table1. Pragmatic considerations leading to a decision to use IIEG

<ol style="list-style-type: none"> 1. Is there a reasonable hypothesis (or hypotheses) concerning the underlying etiology, the EZ and its relationship to EC that can lead to resective surgery? 2. Can the “inconclusive” or apparent “divergent” non-invasive information be explained by known limitations of the scalp EEG and functional imaging data? 3. Are there any other non-invasive techniques that would potentially eliminate the need for IIEG? 4. Will the added information obtained through IIEG be likely to change the end point, i.e., the resection plan? 5. Is this added information achievable with intra-operative ECoG? 6. Are there medical co-morbidities that contraindicate extra-operative IIEG studies? 7. Which of the extra-operative IIEG modalities is best suited? 8. Is the patient/family fully empowered to participate in the team’s decision? 	<p>dly hose seen in regional versus (e.g. temporal rmining the hesial vs. nt, “dual” ng deep seated rces especially not evident on</p>
--	--

<p>2. To resolve divergence of non-invasive data pointing to two or more regions.</p>	<p>Divergence is not uncommon; scenarios particularly prone include bilateral mesial temporal foci, large lesions such as encephalomalacia, multiple lesions such as those in tuberous sclerosis or nodular heterotopia.</p>
<p>3. To map eloquent cortical function precisely.</p>	<p>EZ encroaching or involving EC. Unlike acquired tumors or early acquired atrophic/gliotic lesions that tend to displace function, developmental substrates often retain eloquent function and may manifest atypical representations.</p>
<p>4. Secondary indications.</p>	<p>To further corroborate the EZ or provide information of prognostic value, to selectively ablate active regions using thermo-coagulation.</p>

Table 3. Types of electrodes for IEEG studies

<u>Type</u>	<u>Characteristics</u>
Subdural electrodes.	Configured as discs 4-5 mm in diameter and spaced 5 to 10 mm apart center-to-center. They are embedded in silastic strips (4 to 8 contacts) or rectangular grids (20 to 128 contacts). Special shapes for interhemispheric placement.
Intra-cerebral (depth) electrodes.	Configured as strands of serial cylindrical contacts [ranging from 4-18], spaced 2-10 mm apart, diameter of 1 mm or less, recording areas of 3-5 mm ² . The electrodes are either flexible with a retractable rigid stylet used for insertion, or semi-rigid.
Epidural peg electrodes	Mushroom shaped single contacts.

Wick electrodes	Multiple flexible strands with single recording contact at the tip.
Foramen ovale electrodes	Linear strands with 4-6 contacts.

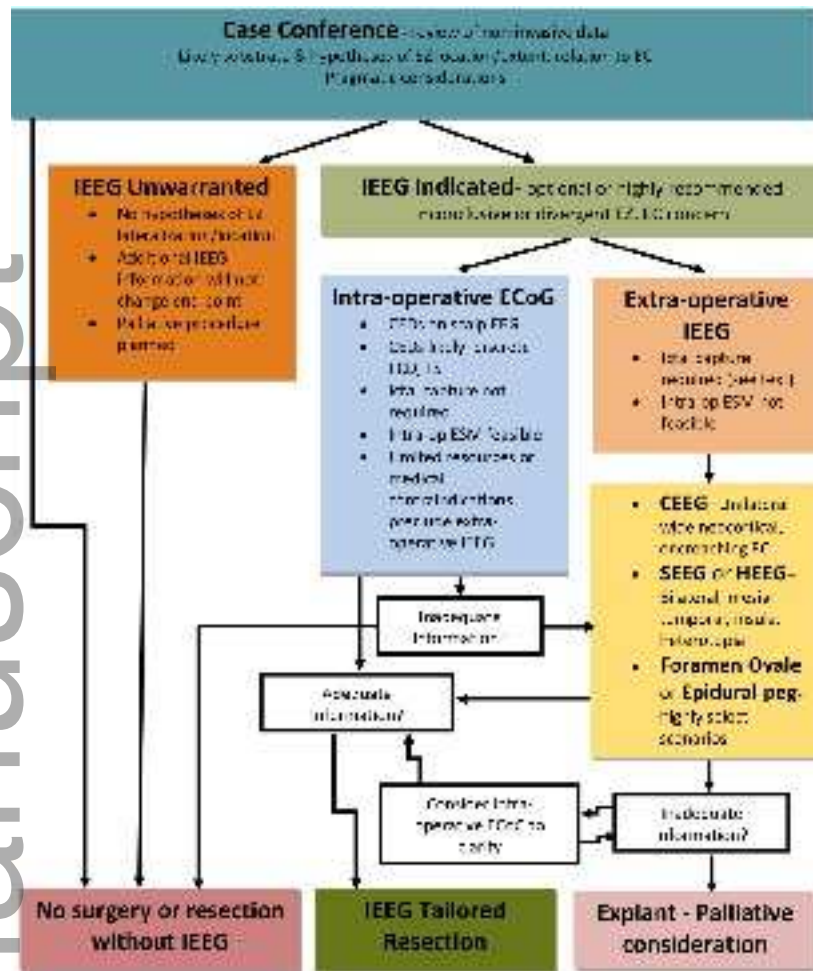
Table 4. Modalities for IEEG studies

<u>Modality</u>	<u>Strengths</u>	<u>Limitations</u>	<u>Risk/ Morbidity</u>	<u>Specific Indications</u>
ECoG Intraoperative IEEG using subdural, depth, or wick electrodes placed under direct visualization or guided by neuro- navigational systems.	No additional invasive procedure, allows maneuvering of placement and periodic recording and ESM during the resection, low resource requirement.	Limited temporal sampling and absence of ictal capture, language mapping only if patient is awake, prolonged operative times, effect of anesthesia on EEG and motor mapping thresholds. Wick electrodes cannot sample interhemispheric or basal regions. Limited time for decision making.	Minimal risk of bleeding related to electrode insertion. Small incremental risk related to length of anesthesia.	Cortical dysplasia, tuberous sclerosis, scalp EEG consistent with CEDs, extra- operative IEEG not feasible.

<p>CEEG Extraoperative IEEG using subdural, depth electrodes or their combination implanted through an open craniotomy, often guided by neuro-navigational systems.</p>	<p>Wide coverage of neocortical gyral surface along with select coverage of deep targets, allows maneuvering of placement during implantation, allows precise ESM of the cortical surface, can be used in infancy.</p>	<p>Large craniotomy [especially for grids], limited precision for deep targets, higher morbidity, difficulty for bilateral exploration or in cases being re-operated.</p>	<p>Low risk of infection, bleeding, CSF leak, raised ICP, significant discomfort,</p>	<p>Extensive unilateral neocortical EZ requiring surface as well as select deep sampling and accurate assessment of EC that may be atypical.</p>
<p>SEEG extraoperative IEEG using intra-cerebral depth electrodes placed stereotactically through burr holes.</p>	<p>Accurate sampling of all deep targets with some coverage of gyral surface, extensive uni- or bilateral implantation, findings can be standardized in a common stereotactic space allowing intersubject</p>	<p>Limited coverage of gyral surface, less well suited for exhaustive ESM of the cortical surface (especially mapping atypical representations), only a subset of electrode contacts sample grey matter, cannot be used below age 2-3 yrs.</p>	<p>Little or no discomfort, low infection, bleeding risk.</p>	<p>Exploration of all deep targets including mesial temporal, insula, heterotopic nodules, bilateral exploration when indicated.</p>

	comparisons, allows ESM of white matter tracts.			
HEEG Combinations of subdural strips and intra-cerebral depth electrodes placed through burr holes using fluoroscopy and stereotaxy.	Accurate sampling of deep targets and selective neocortical convexity, extensive coverage without craniotomies.	Limited coverage of neocortical areas further away from site of burr holes; may require additional craniotomies; less suitable for detailed ESM of gyral surface.	Little or no discomfort, low infection, bleeding.	Distinguishing gyral surface from deep EZ, extensive bilateral exploration when indicated.
Epidural Peg Extra-operative IEEG using epidural peg electrodes placed through burr holes.	Easy to install through twist drill or burr holes bilaterally, satisfactory coverage of neocortical convexity.	No sampling of basal or deep structures; no direct recording of the brain; sensitivity of the dura precludes ESM.	Low morbidity.	Used in conjunction with other modalities to sample contralateral or remote sites.
Foramen ovale extraoperative IEEG using strand electrodes placed through the foramen ovale.	Easy to install without skull opening, considered as "semi-invasive".	Limited sampling with poor coverage over anterior hippocampus/amygdale.	Low morbidity.	Bilateral mid-posterior mesial temporal coverage.

Author Manuscript



epi_13515_f1.tiff