University Library

MINERVA ACCESS

A gateway to Melbourne's research publications

Minerva Access is the Institutional Repository of The University of Melbourne

Author/s:
Vlaskamp, DRM;Shaw, BJ;Burgess, R;Mei, D;Montomoli, M;Xie, H;Myers, CT;Bennett, MF;Xiangwei, W;Williams, D;Maas, SM;Brooks, AS;Mancini, GMS;Van De Laar, IMBH;Van Hagen, JM;Ware, TL;Webster, RI;Malone, S;Berkovic, SF;Kalnins, RM;Sicca, F;Korenke, GC;Van Ravenswaaij-Arts, CMA;Hildebrand, MS;Mefford, HC;Jiang, Y;Guerrini, R;Scheffer, IE

Title:
SYNGAP1 encephalopathy: A distinctive generalized developmental and epileptic encephalopathy

Date:
2019-01-08

Citation:
Vlaskamp, D. R. M., Shaw, B. J., Burgess, R., Mei, D., Montomoli, M., Xie, H., Myers, C. T., Bennett, M. F., Xiangwei, W., Williams, D., Maas, S. M., Brooks, A. S., Mancini, G. M. S., Van De Laar, I. M. B. H., Van Hagen, J. M., Ware, T. L., Webster, R. I., Malone, S., Berkovic, S. F. ,... Scheffer, I. E. (2019). SYNGAP1 encephalopathy: A distinctive generalized developmental and epileptic encephalopathy. Neurology, 92 (2), pp.E96-E107. https://doi.org/10.1212/WNL.0000000000006729.

Persistent Link:
https://hdl.handle.net/11343/250347

License:
CC BY-NC-ND

ARTICLE OPEN ACCESS

SYNGAP1 encephalopathy

A distinctive generalized developmental and epileptic encephalopathy

Danique R.M. Vlaskamp, MD, Benjamin J. Shaw, MD, Rosemary Burgess, PhD, Davide Mei, MSc, Martino Montomoli, MD, Han Xie, PhD, Candace T. Myers, PhD, Mark F. Bennett, PhD, Wenshu XiangWei, BSc, Danielle Williams, BappSc, Saskia M. Maas, MD, Alice S. Brooks, MD, Grazia M.S. Mancini, MD, PhD, Ingrid M.B.H. van de Laar, MD, Johanna M. van Hagen, MD, PhD, Tyson L. Ware, FRACP, Richard I. Webster, MBBS, MSc, FRACP, Stephen Malone, FRACP, Samuel F. Berkovic, MD, FRS, Renate M. Kalnins, MBBS, Federico Sicca, MD, G. Christoph Korenke, MD, PhD, Conny M.A. van Ravenswaaij-Arts, MD, PhD, Michael S. Hildebrand, PhD, Heather C. Mefford, MD, PhD, Yuwu Jiang, MD, PhD, Renzo Guerrini, MD, FRCP, and Ingrid E. Scheffer, MBBS, PhD, FRACP

Correspondence
Dr. Scheffer
scheffer@unimelb.edu.au

Neurology® 2019;92:e96-e107. doi:10.1212/WNL.0000000000006729

Abstract

Objective

To delineate the epileptology, a key part of the *SYNGAP1* phenotypic spectrum, in a large patient cohort.

Methods

Patients were recruited via investigators' practices or social media. We included patients with (likely) pathogenic *SYNGAP1* variants or chromosome 6p21.32 microdeletions incorporating *SYNGAP1*. We analyzed patients' phenotypes using a standardized epilepsy questionnaire, medical records, EEG, MRI, and seizure videos.

Results

We included 57 patients (53% male, median age 8 years) with *SYNGAP1* mutations (n = 53) or microdeletions (n = 4). Of the 57 patients, 56 had epilepsy: generalized in 55, with focal seizures in 7 and infantile spasms in 1. Median seizure onset age was 2 years. A novel type of drop attack was identified comprising eyelid myoclonia evolving to a myoclonic-atonic (n = 5) or atonic (n = 8) seizure. Seizure types included eyelid myoclonia with absences (65%), myoclonic seizures (34%), atypical (20%) and typical (18%) absences, and atonic seizures (14%), triggered by eating in 25%. Developmental delay preceded seizure onset in 54 of 56 (96%) patients for whom early developmental history was available. Developmental plateauing or regression occurred with seizures in 56 in the context of a developmental and epileptic encephalopathy (DEE). Fifty-five of 57 patients had intellectual disability, which was moderate to severe in 50. Other common features included behavioral problems (73%); high pain threshold (72%); eating problems, including oral aversion (68%); hypotonia (67%); sleeping problems (62%); autism spectrum disorder (54%); and ataxia or gait abnormalities (51%).

Conclusions

SYNGAP1 mutations cause a generalized DEE with a distinctive syndrome combining epilepsy with eyelid myoclonia with absences and myoclonic-atonic seizures, as well as a predilection to seizures triggered by eating.

RELATED ARTICLE

Editorial
A synaptic protein defect associated with reflex seizure disorder
Page 63

MORE ONLINE

Videos

From the Epilepsy Research Centre (D.R.M.V., B.J.S., R.B., M.F.B., S.F.B., M.S.H., I.E.S.), Department of Medicine, University of Melbourne, Austin Health, Australia; Departments of Genetics (D.R.M.V., C.M.A.v.R.-A.) and Neurology (D.R.M.V.), University Medical Center Groningen, University of Groningen, the Netherlands; Pediatric Neurology Unit and Laboratories (D.M., M.M.) and Pediatric Neurology (R.G.), Neurogenetics and Neurobiology Unit and Laboratories, A. Meyer Children's Hospital, University of Florence, Italy; Department of Pediatrics and Pediatric Epilepsy Centre (H.X., W.X.W., Y.J.), Peking University First Hospital, Beijing, China; Department of Pediatrics (C.T.M., H.C.M.), Division of Genetic Medicine, University of Washington, Seattle; Population Health and Immunity Division (M.F.B.), Walter and Eliza Hall Institute of Medical Research, Melbourne, Australia; Department of Medical Biology (M.F.B.), University of Melbourne, Australia; Caulfield (D.W.), Melbourne, Australia; Department of Clinical Genetics (S.M.M.), Academic Medical Centre, Amsterdam, the Netherlands; Department of Clinical Genetics (A.S.B., G.M.S.M., I.M.B.H.v.d.L.), Erasmus University Medical Centre, Rotterdam, the Netherlands; Department of Clinical Genetics (J.M.v.H.), VU University Medical Center, Amsterdam, the Netherlands; Tasmanian Health Service (T.L.W.), Women's and Children's Services, Launceston General Hospital, Tasmania, Australia; TY Nelson Department of Neurology and Neurosurgery (R.I.W.) and Institute of Neuroscience and Muscle Research (R.I.W.), Children's Hospital at Westmead, Sydney, Australia; Department of Neurosciences (S.M.), Lady Cilento Children's Hospital, Brisbane, Australia; Department of Anatomical Pathology (R.M.K.), Austin Hospital, Melbourne, Australia; IRCCS Stella Maris Foundation (F.S., R.G.), Pisa, Italy; Klinikum Oldenburg (G.C.K.), Zentrum für Kinder-und Jugendmedizin, Klinik für Neuropädiatrie u. angeborene Stoffwechselerkrankungen, Oldenburg, Germany; Centre of Epilepsy (Y.J.), Beijing Institute for Brain Disorders, China; Department of Paediatrics (I.E.S.), University of Melbourne, Royal Children's Hospital, Australia; and Florey Institute of Neurosciences and Mental Health (I.E.S.), Parkville, Australia.

Go to Neurology.org/N for full disclosures. Funding information and disclosures deemed relevant by the authors, if any, are provided at the end of the article.

The Article Processing Charge was funded by the authors.

This is an open access article distributed under the terms of the Creative Commons Attribution-NonCommercial-NoDerivatives License 4.0 (CC BY-NC-ND), which permits downloading and sharing the work provided it is properly cited. The work cannot be changed in any way or used commercially without permission from the journal.

 Copyright © 2018 The Author(s). Published by Wolters Kluwer Health, Inc. on behalf of the American Academy of Neurology.

Glossary

AED = antiepileptic drug; **ASD** = autism spectrum disorder; **DEE** = developmental and epileptic encephalopathy; **DSM-V** = *Diagnostic and Statistical Manual of Mental Disorders, 5th edition*; **EM** = eyelid myoclonia; **EMA** = epilepsy with eyelid myoclonia with absences; **GSW** = generalized spike wave; **ID** = intellectual disability; **MAE** = epilepsy with myoclonic-atonic seizures; **TCS** = tonic-clonic seizures.

Mutations of the *SYNGAP1* gene were first identified in 2009 in patients with nonsyndromic intellectual disability (ID) and autism spectrum disorder (ASD), followed in 2013 by recognition of their important role in the developmental and epileptic encephalopathies (DEEs).[1–3] Most affected individuals have de novo mutations, with truncating mutations predominating, although missense mutations, chromosomal translocations, or microdeletions disrupting *SYNGAP1* are also described.[4–8]

SYNGAP1 (MIM *603384) on chromosome 6p21.32 encodes a synaptic Ras-GTPase-activating protein, expressed mainly in the synapses of excitatory neurons.[9,10] SYNGAP1 is a key mediator in the NMDA receptor activated RAS-signaling cascade regulating the postsynaptic density and the formation, development, and maturation of dendritic spines.[11,12] Loss of function of SYNGAP1 has major consequences for neuronal homeostasis and development, which are crucial for learning and memory.[11] *Syngap1*-null mice die within a week, and *Syngap1*-heterozygous mutant mice have a lower seizure threshold, learning and memory deficits, and behavioral problems.[13–16]

Since our original description of 5 patients with an *SYNGAP1*-DEE,[3] 2 additional studies have described the epilepsy in 24 of 27 patients with *SYNGAP1* encephalopathy; the specific epilepsy syndrome was described in only 4 of these cases.[8,17] *SYNGAP1* was originally identified in 38 patients with ID or ASD, of whom 15 had seizures and only 1 had an epilepsy syndrome diagnosis.[1,2,4–7,18–28] We aimed to delineate the epilepsy syndromes within the *SYNGAP1* phenotypic spectrum in a large international cohort of patients with *SYNGAP1* mutations and microdeletions.

Methods

Study cohort

We recruited 66 patients with *SYNGAP1* variants via investigators' practices in Australia, Italy, the Netherlands, and China (n = 39) and via the *SYNGAP1* Facebook group on which parents posted our invitation to participate (n = 27). The pathogenicity of all *SYNGAP1* variants was evaluated with the use of standard American College of Medical Genetics and Genomics guidelines (table e-1, available from Dryad, doi.org/10.5061/dryad.ck70sj0).[29] We included 57 (86%) patients with (likely) pathogenic *SYNGAP1* variants (n = 53) or chromosome 6p21.32 microdeletions including *SYNGAP1* and other genes (n = 4). Five (8%) patients with a *SYNGAP1* variant of unknown significance were studied separately. Four (6%) patients with likely benign *SYNGAP1* variants were excluded.

Phenotyping

Parents or caregivers of all patients were interviewed with a standardized epilepsy questionnaire.[30] We analyzed medical records, EEGs, neuroimaging, including MRI results, and, when available, seizure videos and video-EEG data. Seizure types and syndromes were classified with the 2017 International League Against Epilepsy classification.[31,32] The severity of ID was established with IQ scores (when available) or information on the level of functioning in accordance with the DSM-V.[33]

Genotyping

SYNGAP1 mutations were described on the basis of the longest isoform 1 of *SYNGAP1 (NM_0067772.2)*[34] and chromosomal microdeletions on the basis of the Genome Reference Consortium Human Reference sequence version 37 (GRCh37/hg19).

Genotype-phenotype correlation

We examined genotype-phenotype correlations in 4 patient groups: (1) truncating mutations, which included nonsense and frameshift mutations; (2) splice-site mutations; (3) missense and in-frame insertion/deletion mutations; and (4) chromosome 6p21.32 microdeletions including *SYNGAP1* and other genes. Splice-site mutations were considered separately because their effects on the protein are variable.[35]

Standard protocol approvals, registrations, and patient consents

All parents or legal representatives of the patients gave written informed consent for inclusion and use of photos and videos. This study was approved by the local institutional Ethics Committee (Austin Health reference No. H2007/02961).

Data availability

Anonymized data will be shared by request from any qualified investigator.

Results

Cohort

Fifty-seven patients (53% male, median age at study 8 years) with (likely) pathogenic *SYNGAP1* variants were included: 34 truncating, 8 splice-site, and 11 missense/in-frame mutations and 4 microdeletions. Forty-six (81%) patients have not been previously reported. Thirty-nine of these patients had novel

Figure 1 Schematic presentation of *SYNGAP1* mutations and microdeletions (A) in patients of our cohort or (B) previously published in the literature

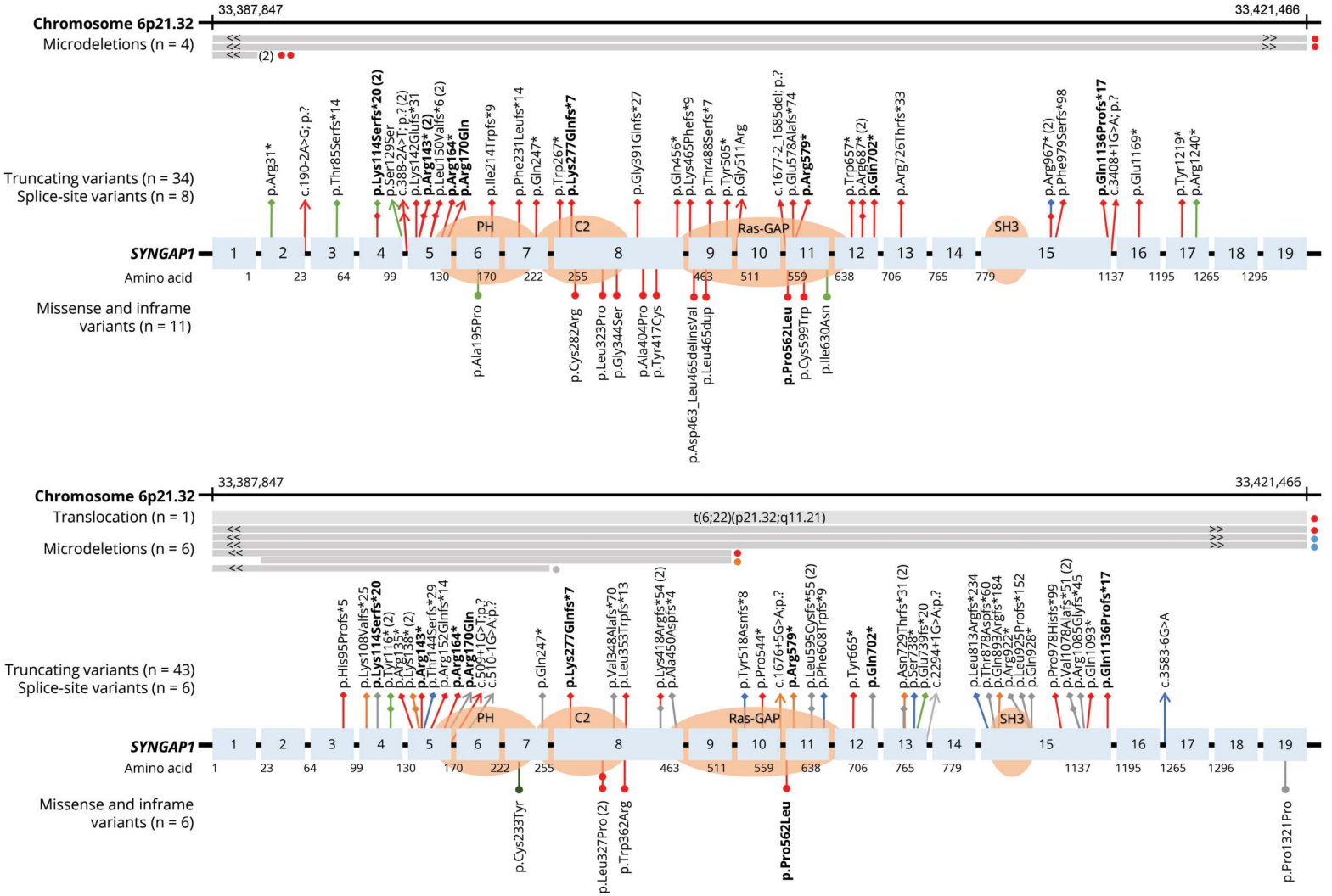

Chromosome 6p21.32 microdeletions including *SYNGAP1*, are presented as gray bars with << and >> indicating that their breakpoints were outside the region presented here. Truncating (♦) and splice-site (→) mutations are presented above the gene, and missense and in-frame (•) mutations are shown underneath the gene. Bold variants concern recurrent variants that were identified in our cohort but also previously published in the literature. Colors of the lines represent the epilepsy syndrome phenotype: moderate to severe developmental and epileptic encephalopathy (red), moderate to severe developmental encephalopathy with epilepsy (orange), moderate to severe developmental encephalopathy with no epilepsy (blue), mild developmental and epileptic encephalopathy (light green), mild developmental encephalopathy with no epilepsy (dark green), and unknown/unclassified epilepsy (gray). Chromosomal coordinates were based on National Center for Biotechnology Information Build 37 [hg19] and *SYNGAP1* mutations, protein domains, and exons on the longest isoform 1 (NM_006772.2).

Table 1 Phenotypes in patients with *SYNGAP1* mutations and microdeletions

	Truncating mutations	Splice-site variants	Missense/ in-frame mutations	Microdeletions including *SYNGAP1*	Total cohort
	(n = 34)	(n = 8)	(n = 11)	(n = 4)	(n = 57)
Male, %	18 (52.9)	3 (37.5)	6 (54.5)	3 (75.0)	30 (52.6)
Median age at study (range)	9.5 y (18 mo–33 y)	9.5 y (4 y 9 mo–16 y 9 mo)	8 y 3 mo (3 y 2 mo–18 y 10 mo)	3 y 8 mo (2 y 4 mo–7 y 11 mo)	8 y 3 mo (18 mo–33 y)
Seizures, n (%)	33 (97.1)	8 (100)	11 (100)	4 (100)	56 (98.2)
Median age at seizure onset (range, known in n)	2 y (6 mo–7 y 3 mo, 32)	2 y (6 mo–6 y 2 mo, 8)	2.5 y (4 mo–4 y, 11)	20 mo (12 mo–2.5 y, 4)	2 y (4 mo–7 y 3 mo, 55)
Multiple seizure types, n (%)	25 (73.5)	3 (37.5)	5 (45.5)	2 (50.0)	35 (61.4)
Generalized seizures, n (%)	33 (97.1)	8 (100)	10 (90.9)	4 (100)	55 (96.5)
Any absences, n (%)	33 (97.1)	8 (100)	8 (72.7)	4 (100)	53 (93.0)
EM	26 (76.5)	4 (50.0)	6 (54.5)	1 (25.0)	37 (64.9)
EM-myoclonic-atonic	4 (11.8)	1 (12.5)	—	—	5 (8.8)
EM-atonic	3 (8.8)	—	5 (45.5)	—	8 (14.0)
Atypical absences	5 (14.7)	4 (50.0)	—	2 (50.0)	11 (19.3)
Typical absences	3 (8.8)	2 (25.0)	3 (27.3)	2 (50.0)	10 (17.5)
Myoclonic absences	2 (5.9)	—	—	—	2 (3.5)
Myoclonic	15 (44.1)	1 (12.5)	3 (27.3)	—	19 (33.3)
Atonic	5 (14.7)	—	2 (18.2)	1 (25.0)	8 (14.0)
Myoclonic-atonic	2 (5.9)	—	1 (9.1)	—	3 (5.3)
Unclassified drop attacks	2 (5.9)	—	—	—	2 (3.5)
Tonic-clonic seizures, n (%)	11 (32.4)	1 (12.5)	2 (18.2)	—	14 (24.6)
Focal seizures, n (%)	6 (17.6)	—	1 (9.1)	—	7 (12.3)
Other seizure types: spasms, tonic, n (%)	—, 1 (2.9)	—	1 (9.1), —	—	1 (1.8), 1 (1.8)
Photosensitivity (clinical), n (%)	7 (20.5)	3 (37.5)	2 (18.2)	1 (25.0)	13 (22.8)
Photosensitivity (electric), n (%)	9/19 (47.4)	4 (50.0)	3/6 (50.0)	1/2 (50.0)	17/31 (54.8)
Reflex seizures, n (%)[a]	13 (38.2)	1 (12.5)	5 (45.5)	—	19 (33.3)
EEG: slow background, n (%)	15/31 (48.4)	4 (50.0)	4/9 (44.4)	3 (75.0)	26/52 (50.0)
EEG: generalized discharges, n (%)	25/31 (80.6)	6 (75.0)	5/9 (55.6)	3 (75.0)	39/52 (75.0)
EEG: (multi)focal discharges, n (%)	17/31 (54.8)	4 (50.0)	6/9 (66.7)	1 (25.0)	28/52 (53.8)
Seizure- free, n (%, median age, range, known in n)	4 (11.8, 8 y 4 mo, 3–13 y, 4)	1 (12.5, —)	6 (54.5, 7 y, 5 y–7 y 9 mo, 3)	—	10 (17.8, 7.5 y, 3–13 y, 7)
Developmental delay, n (%)	31/33 (93.9)	8 (100)	11 (100)	4 (100)	54/56 (96.4)
Sitting (range, age known in n, possible in n)	9 mo (4 mo–2.5 y, 32, 33)	10 mo (5 mo–2 y 1 mo, 8, 8)	12 mo (6–20 mo, 11, 11)	19 mo (9 mo–2 y 1 mo, 4, 4)	9 mo (4 mo–2.5 y, 55, 56)
Walking (range, age known in n, possible in n)	2 y (12 mo–6 y, 32, 33)	21 mo (12 mo–4 y 4 mo, 8, 8)	19 mo (12 mo–2.5 y, 10, 10)	2 y 9 mo (—, 1, 1)	2 y (12 mo–6 y, 51, 52)
First word (range, age known in n, possible in n)	2 y 3 mo (8 mo–11 y, 24, 27)	21 mo (12 mo–6 y, 6, 7)	2 y (18 mo–11 y, 9, 9)	2 y 5 mo (20 mo–3 y 1 mo, 2, 2)	2 y (8 mo–9 y, 41, 45)
Two words together (range, age known in n, possible in n)	4 y (16 mo–13 y, 14, 14)	4 y (23 mo–4.5 y, 3, 4)	4 y (2–5 y, 5, 4)	4 y (—, 1, 1)	4 y (16 mo–13 y, 23, 23)

Continued

Table 1 Phenotypes in patients with *SYNGAP1* mutations and microdeletions *(continued)*

	Truncating mutations	Splice-site variants	Missense/ in-frame mutations	Microdeletions including *SYNGAP1*	Total cohort
	(n = 34)	(n = 8)	(n = 11)	(n = 4)	(n = 57)
Intellectual disability (ID, %): moderate-severe ID (%)	32 (94.1): 30 (88.2)	8 (100): 7 (87.5)	11 (100): 9 (81.8)	4 (100): 4 (100)	55 (96.5): 50 (87.7)
Regression (%, median age, range, known in n)	15/33 (45.5, 2 y, 6 mo–18 y, 11)	6 (75.0, 5 y 4 mo, 4 y 9 mo–6 y, 2)	7 (63.6, 13 mo, 9 mo–18 mo, 9)	4 (100, 18 mo, 12 mo–7 y, 4)	32/56 (57.1, 2 y, 6 mo–18 y, 19)
Autism spectrum disorder, n (%)	20 (58.8)	5 (62.5)	5 (45.5)	—	30 (52.6)
Severe behavioral problems, n (%)	28/33 (84.8)	5 (62.5)	6 (54.5)	4 (100)	41/56 (73.2)
High pain thresholds, n (%)	27/33 (81.8)	5/7 (71.4)	4/10 (40.0)	2/3 (66.7)	39/54 (72.2)
Eating problems, n (%)[b]	23 (67.6)	6 (62.5)	7 (63.6)	4 (100)	39 (68.4)
Hypotonia, n (%)	22 (64.7)	4 (50.0)	8 (72.7)	4 (100)	38 (66.7)
Sleep problems, n (%)	20/33 (60.6)	5/7 (71.4)	6 (54.5)	3 (75.0)	34/55 (61.8)
Ataxia and/or gait abnormalities, n (%)	20/34 (58.8)	5 (62.5)	4 (36.4)	—	29 (50.9)
Orthopedic issues, n (%)	10 (29.4)	3 (37.5)	3 (27.3)	—	16 (28.1)
Other features: tremor, microcephaly, n/N (%)	3 (8.8), 0/32 (–)	1 (12.5), 1/7 (14.3)	—	1 (25.0), —	5 (8.8), 1/54 (1.9)

Abbreviations: EM = eyelid myoclonia with or without absences; ID = intellectual disability.
If patients had missing information, a denominator is given that represents the number of patients with known information on this variable. If no denominator is given, there was information on all patients.
[a] Reflex seizures include seizures triggered by eating, sound, or touch.
[b] Eating problems included a poor intake, uncontrolled eating with gorging, eating inedible objects, difficulties with transition from fluids to solid food in early childhood, and difficulties with chewing and swallowing.

mutations, which included a total of 35 unique mutations because 4 were recurrent. The remaining 7 individuals had previously reported mutations. Figure 1A depicts the 57 *SYNGAP1* mutations and microdeletions found in our patient cohort, and figure 1B shows the 62 *SYNGAP1* variants of all previously reported patients who were not included in our cohort.[1,2,4–8,17–28] Inheritance was tested in 53 of 57 patients, and the mutation had arisen de novo in all. Table 1 describes the clinical features for our cohort according to the 4 genotypic groups. More detailed individual genetic and phenotypic are summarized in tables e-1 and e-2 (available from Dryad, doi.org/10.5061/dryad.ck70sj0).

Seizure types

Fifty-six of 57 patients had epilepsy with a median age at seizure onset of 2 years (range 4 months–7 years, known in 55). At onset, 50 patients had generalized seizures, 1 had infantile spasms in the context of West syndrome, 3 had possible focal seizures, and 2 had unknown seizure types.

Absence seizures occurred in 53 of 57 (93%) patients: eyelid myoclonia (EM) with absences in 37, atypical absences in 11, typical absences in 10, and myoclonic absences in 2. Other seizure types included myoclonic (19 of 57, 33%), atonic (8 of 57, 12%), myoclonic-atonic (3 of 57, 5%), and unclassified drop attacks (2 of 57, 4%). Fourteen (25%) patients had tonic-clonic seizures (TCS), of whom 2 also had focal seizures. Five patients had focal seizures without TCS. Four of 57 (7%) patients had febrile seizures before epilepsy onset.

Reflex seizures were seen, often occurring in clusters, and triggered by eating (25%), sound (7%), or touch (4%). Hunger was also associated with seizures in 7%. Clinical photosensitivity occurred in 13 (23%) patients and EEG photosensitivity in 17 of 31 (55%) tested. Three (5%) patients had self-induced seizures with hyperventilation.

Novel seizure type: EM-myoclonic-atonic seizures

Of the 36 patients with EM, we observed a novel seizure type in 13 of 36 (36%) in whom the EM evolved to a drop attack. The nature of the drop attack was an EM-myoclonic-atonic seizure in 5 and an EM-atonic seizure in 8 patients (video 1). Ictal EEG showed generalized spike wave (GSW) discharges coinciding with the EM, followed by a spike-wave complex correlating with the myoclonic (spike) and atonic (slow wave) component (figure 2). We also observed that EM seizures were accompanied by myoclonic jerks of the limbs in 4 of 36 (11%) patients. These novel seizure types, EM-myoclonic-atonic and EM-atonic, occurred mainly when EM clustered and at times of poor seizure control.

Figure 2 Ictal EEG registration during eyelid myoclonia–myoclonic–atonic seizure

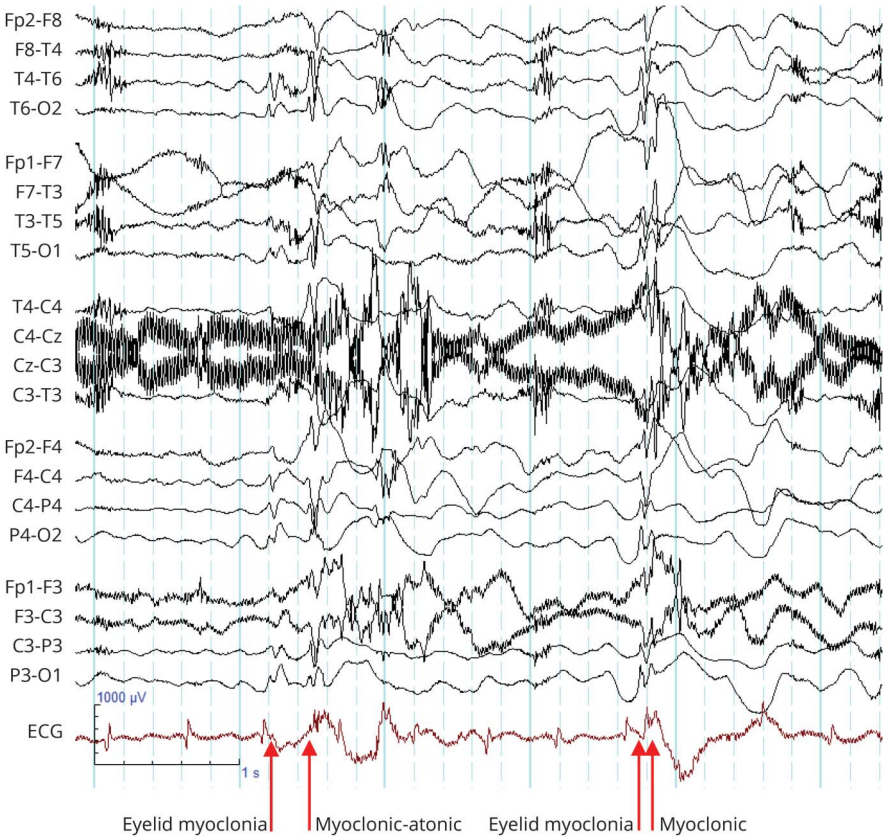

Red arrows indicate the different phases of the seizure associated with a generalized spike wave (eyelid myoclonia) and a further spike wave correlating with the myoclonic (spike) and atonic (wave) components.

Neurodevelopment and behavioral issues

Developmental delay was identified soon after birth in 55 of 56 (96%) patients and preceded seizure onset in all. Development regressed or plateaued with seizure onset in 56 patients. Language was severely impaired, with 12 patients being nonverbal, at age 2 to 33 years. ID was present in 55 of 57 patients, being moderate to severe in 50 and mild in 5.

Behavioral problems were seen in 41 of 56 (73%) patients and were often severe with oppositional and defiant behavior with aggression, self-injury, and tantrums. ASD was diagnosed in 30 (53%) patients.

Other features

An interesting observation was that the families of 39 of 54 (72%) patients noted that they had a high pain threshold. Patients did not respond to painful events such as a fractured bone, surgical incision of a lesion, or a foreign object lodged in their foot.

Difficulties with eating were a major problem in 39 (68%) patients. Twenty-three patients had a poor intake because they were fussy about food type, color, texture, and temperature (16) or had oral aversion (5), oral hypersensitivity (3), and poor appetite (3). Four patients needed a nasogastric tube because of the severity of their eating problems. In contrast, 7 patients had uncontrolled eating with gorging, and 3 would eat inedible objects. Eleven of 55 patients had difficulties with transition from fluids to solid food in early childhood. Seventeen of 56 patients had chewing and swallowing difficulties.

Sleep was disturbed in 34 of 55 (62%) patients with difficulties initiating (n = 19) and maintaining (n = 29) sleep. Improved seizure control led to better sleep in 12 patients. There was no clear correlation with EEG features; there was an increase in epileptiform activity in sleep in 9 of 23 (39%) patients with sleep difficulties, which was also observed in 6 of 12 (50%) without sleep difficulties. Sleep also improved with melatonin (n = 10), clonidine (n = 5), and trazodone (n = 1).

Examination findings

Photographs of 31 of 57 patients were available (figure 3) and revealed subtle dysmorphic features, not present in all patients. These included full, slightly prominent eyebrows with medial flaring in some; hypertelorism; full nasal tip, slightly upturned nasal tip in younger children; short philtrum; cupid bow upper lip; broad mouth with diastemata of the upper teeth; and small pointed chin.

Figure 3 *SYNGAP1* dysmorphology



Portrait photographs from 31 of 56 patients with *SYNGAP1* mutations or microdeletions including *SYNGAP1*. (A) Patient 4, (B) patient 6, (C) patient 7, (D), patient 8 (sibling of patient 9), (E) patient 9 (sibling of patient 8), (F) patient 12, (G) patient 13, (H) patient 14, (I) patient 16, (J) patient 18, (K) patient 19, (L) patient 20, (M) patient 21, (N) patient 23, (O) patient 25, (P) patient 27, (Q) patient 28, (R) patient 29, (S) patient 31, (T) patient 32, (U) patient 33, (V) patient 34, (W) patient 35, (X) patient 37, (Y) patient 45, (Z) patient 47, (AA) patient 50, (AB) patient 51, (AC) patient 52, (AD) patient 54 (monozygotic twin with patient 55), and (AE) patient 55 (monozygotic twin with patient 54).

Neurologic examination showed hypotonia in 38 (67%), ataxia or an unsteady gait in 29 (51%), tremor in 5 (9%), and microcephaly in 1 (2%) of 54. Orthopedic abnormalities included foot or spine deformities in 16 (28%), including pes planus (7), pronated feet (4), scoliosis (3), pes cavus (1), congenital hip dislocation (1), or congenital hip dysplasia (1).

EEG findings

EEG results were available for 52 of 57 patients from when their epilepsy was active. Many children did not have further EEGs because of severe behavioral problems. GSW and generalized poly-spike wave were reported in 39 of 52 (75%) patients. Focal or multifocal epileptiform discharges were seen in 28 of 52 (54%), often in addition to GSW or generalized poly-spike wave (21 of 39, 54%). Slow background activity was seen in 26 of 52 (50%) patients.

Neuroimaging

MRI was reported as normal in 37 of 53 (70%) patients. One patient had a left frontal subcortical nodular heterotopia. The 15 remaining patients had nonspecific findings: thin corpus callosum (3; 2 of 3 also had a thin chiasma opticum), enlarged ventricles or subarachnoid spaces (3), hyperintense T2 signals in the white matter (3), posterior centrum semiovale (2) or fasciculus longitudinalis medialis (1), patent cavum vergae (1), atypical white matter abnormalities (1), mega cisterna magna fossa posterior (1), discrete hippocampal tissue loss (1), or a pineal cyst (1).

Brain pathology

Brain pathology was available from patient 14, a 33-year-old nonverbal woman with a de novo *SYNGAP1* nonsense mutation (video 2), who died of aspiration pneumonia. The pathology showed cerebellar Purkinje cell loss with associated astrocytosis (figure 4A). Astrocytosis was found predominantly in the superficial cortical layer but also in the hippocampi and deep gray nuclei (figure 4B). Macroscopic evaluation showed a low brain weight (1,194 g, −3.2 SD) with widely but moderately distributed leptomeningeal fibrosis, most evident over the frontal lobes (figure 4C). Cortical neurons did not show evidence of anoxic ischemic injury (data not shown).

Figure 4 Brain pathology in a patient with an *SYNGAP1* mutation

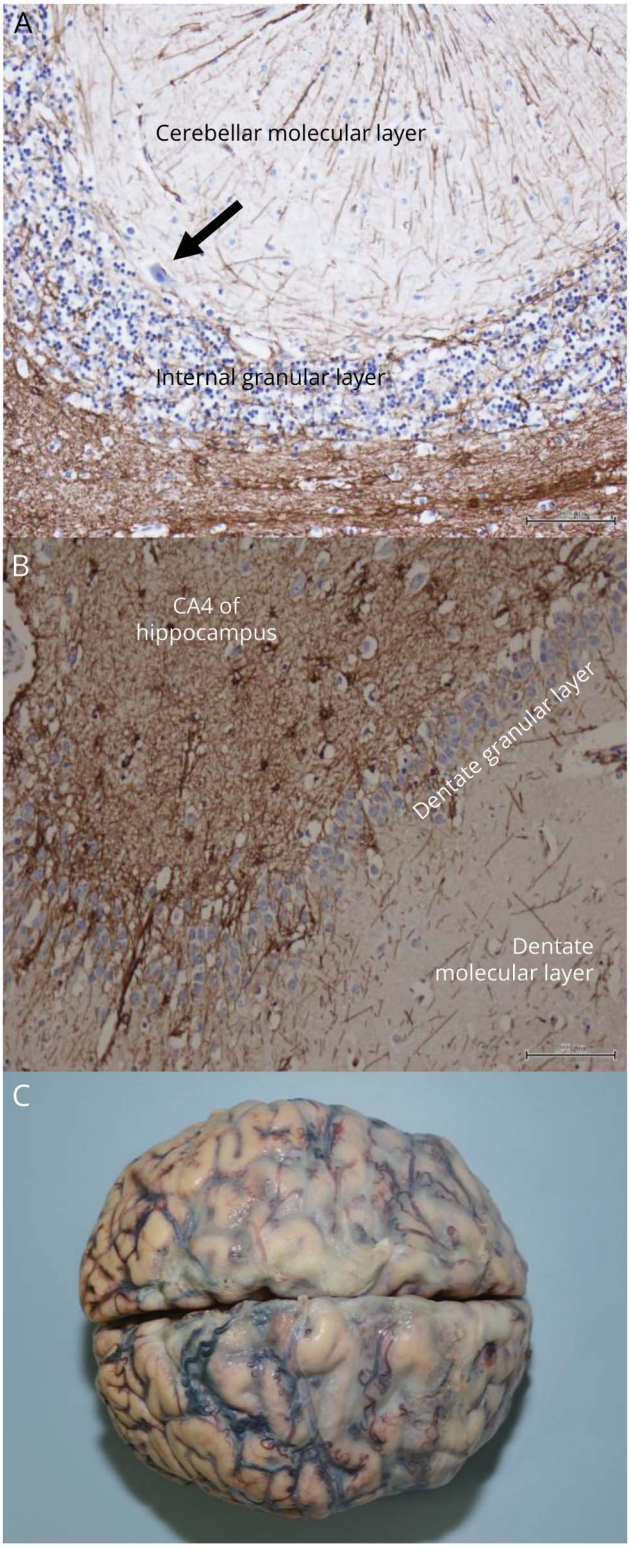

(A) Glial fibrillary acidic protein (GFAP)–stained section of the cerebellar cortex showing a single surviving Purkinje cell (arrow points toward this cell) in a field of Purkinje cell loss and mild internal granular layer and cerebellar molecular layer astrocytosis. (B) GFAP staining of dentate gyrus showing no neuronal loss but mild reactive astrocytosis in the dentate granular layer and the dentate molecular layer of the hippocampus. (C) Vertex view of the cerebral hemispheres showing leptomeningeal fibrosis.

Epilepsy syndrome

A distinctive generalized epilepsy phenotype emerged combining features of 2 well-described syndromes, epilepsy with eyelid myoclonia with absences, reported by Jeavons,[36] and epilepsy with myoclonic-atonic seizures, described by Doose et al.[37] The overall gestalt in 56 of 57 patients was a spectrum of severity of generalized DEE with multiple seizure types, including EM, myoclonic, and atonic (and combinations of all 3). TCS were fairly frequent, whereas focal seizures occurred in a minority. The majority of patients had a severe outcome with moderate to severe ID (49 of 56, 88%), while 7 of 56 (12%) had a milder outcome with normal intellect or mild ID. One child with a mild outcome had West syndrome. The remaining patient with no seizures but epileptiform abnormalities on EEG had a (static) developmental encephalopathy with a severe outcome. Another distinctive feature of *SYNGAP1*, seen in a quarter of cases, was the presence of reflex seizures triggered by eating.

Epilepsy treatment and outcome

Overall, 20 different antiepileptic drugs (AEDs) were started (table e-3, available from Dryad, doi.org/10.5061/dryad.ck70sj0). Valproate and lamotrigine were most commonly prescribed (n = 45 and n = 22), with ongoing prescription of lamotrigine for 77% of patients and valproate for 64% patients. Of the 6 patients who had received cannabidiol, 5 of 6 (83.3%) remained on it.

Thirty-five of 56 (63%) patients had refractory epilepsy with ongoing seizures after 2 AEDs. Six became seizure-free on the third to sixth AED. In total, 10 of 56 (18%) patients became seizure-free at 7 years of age (median, range 3–13 years). Of these, seizures were controlled on monotherapy with valproate (3), levetiracetam (1), or steroids (1, for infantile spasms). Polytherapy combinations resulting in seizure freedom included levetiracetam and topiramate (1), valproate and lamotrigine (1), and cannabidiol, valproate, and lamotrigine (1). Two were seizure-free on no treatment. Four patients had no seizures for a period of 6 months to 7 years while treated with carbamazepine (1), lamotrigine (1), valproate (1), or valproate, lamotrigine, and clobazam, but seizures recurred.

Genotype-phenotype correlation

The phenotypes of patients with truncating, splice-site, or missense/in-frame mutations and microdeletions were similar overall, except that 4 patients with microdeletions all had an earlier seizure onset (20 months compared with 2 years in the remaining cohort, table 1). All 4 patients had microdeletions that included additional genes (4–13 genes). In terms of the outcome, all 4 cases had severe ID, consistent with the rest of the cohort. Given their similar epileptology and other features (high pain threshold in 2, poor oral intake in 2, seizures triggered by hunger and photosensitivity in 1, and dysmorphic features in 2), we included them in the total cohort.

For evaluating genotype-phenotype correlations, we separated *SYNGAP1* encephalopathies into 2 groups based on severity determined by their intellect. Milder phenotypes included

Figure 5 *SYNGAP1* encephalopathy

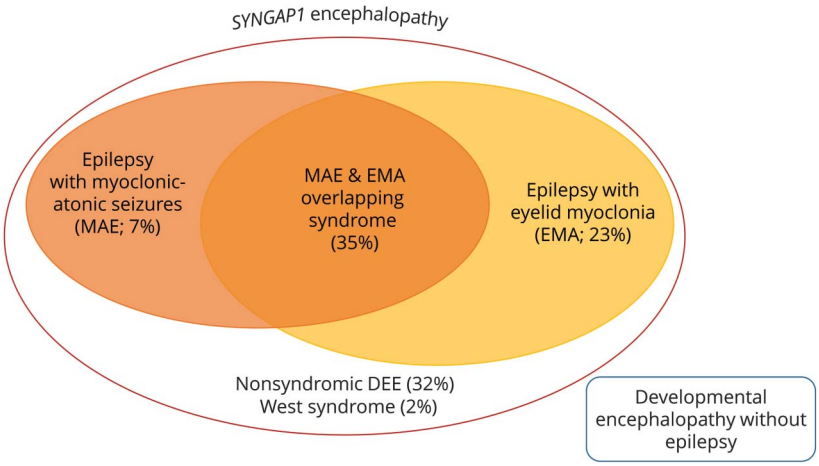

This conceptual diagram highlights that the most common epilepsy phenotype in our cohort was an overlapping syndrome combining the features of 2 well-recognized epilepsy syndromes: epilepsy with eyelid myoclonia with absences (EMA) and epilepsy with myoclonic-atonic seizures (MAE). About one-third of the cohort did not fit into either of these syndromes and had nonsyndromic developmental and epileptic encephalopathy (DEE). One case had West syndrome. Other individuals with *SYNGAP1* encephalopathy may have developmental encephalopathy (intellectual disability) without epilepsy.

normal intellect or mild ID; severe phenotypes referred to moderate to severe ID. Of the 7 patients with a milder phenotype (green mutations, figure 1A), 5 had a truncating or splice-site mutation, of which 4 were located in exons 1 to 4. Two other patients had a missense variant in exons 6 and 11. Five previously reported patients also had a milder phenotype (green and dark green mutations, figure 1B), with 3 of 5 having mutations in exons 1 to 4. In the combined cohort of our and previously reported patients, milder phenotypes were significantly more often observed in patients with mutation or deletions in exons 1 to 4 (50%, n = 6 of 12) compared to exons 5 to 19 (7%, 6 of 85, $p = 0.001$, Fisher exact test). No significant differences were observed in outcome between patients with different mutation types (data not shown).

Patients with *SYNGAP1* variants of unknown significance (n = 5)

Not included in our cohort of 56 patients were 5 individuals with an *SYNGAP1* variant of unknown significance. Tables e-1 and e-2 (available from Dryad, doi.org/10.5061/dryad.ck70sj0) show details of their pathogenicity predictions and associated phenotypes. Three patients who had variants reported in gnomAD or ExAC and for whom inheritance of their *SYNGAP1* variant was unavailable had phenotypes that were consistent with our large cohort.[38] Two had generalized DEE and 1 had mild ID with EM. Their presence in population databases is difficult to explain, although EM can be subtle and easily missed. It remains to be determined whether their *SYNGAP1* variant has a role in their presentation. The

Figure 6 Comorbidities of *SYNGAP1* encephalopathy

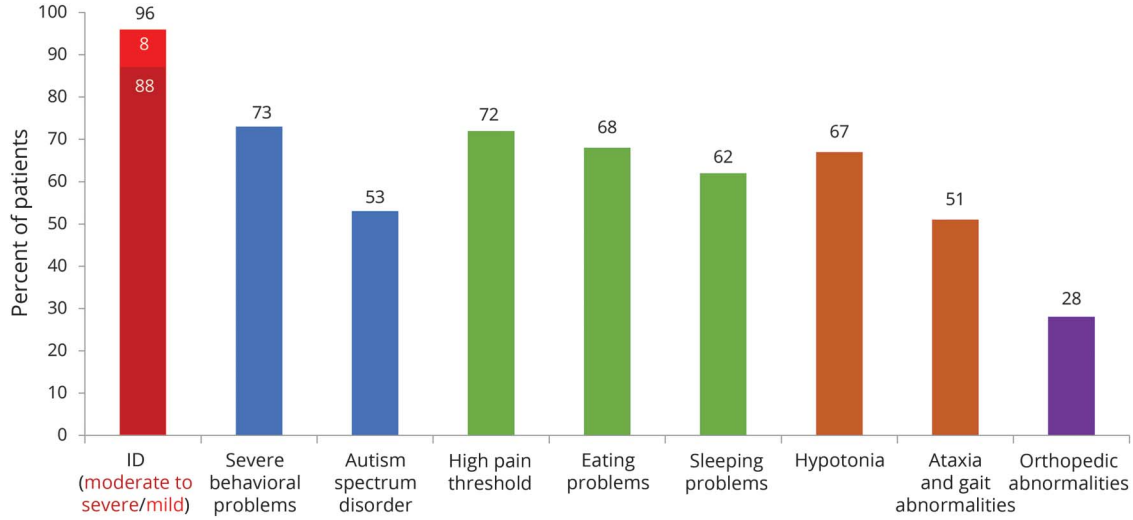

The figure shows the percentage of each comorbidity associated with *SYNGAP1* encephalopathy in our cohort. Dark red denotes moderate to severe intellectual disability; light red denotes mild intellectual disability.

remaining 2 had variants with lower conservation and pathogenicity prediction scores and had focal epilepsy with or without ID, so their phenotype was quite different.

Discussion

SYNGAP1 is an important gene for the DEEs, present in 1% of our original cohort of patients with unsolved DEEs,[3,8,17] having been first identified as a gene for ID.[1] Here, we describe a distinctive generalized DEE phenotype for *SYNGAP1* combining syndromic features of epilepsy with eyelid myoclonia with absences (EMA) and epilepsy with myoclonic-atonic seizures (MAE) (figure 5). *SYNGAP1* encephalopathy was associated with a spectrum of mild (8%) to severe (88%) ID and a range of other comorbid conditions (figure 6). Seizures were often triggered by eating. The 1 patient without a DEE had a static developmental encephalopathy without seizures but had epileptiform abnormalities on EEG.

SYNGAP1-DEE shares many of the striking features of the syndrome of EMA.[39] The key seizure type, absences with EM, together with photosensitivity, was found in the majority (64% and 55%, respectively) of our cohort. The onset of EM was earlier for *SYNGAP1*-DEE (<3 years) compared with the classic syndrome of EMA (peak onset 6–8 years).[39] In addition, EMA is often associated with better cognitive outcome, with individuals being of normal intellect or having mild ID. An earlier age at onset (<3 years) of EM is associated with poorer intellectual outcome, and perhaps some of these individuals have *SYNGAP1* mutations.[40–43] However, there is debate as to whether the diagnosis of EMA allows for the presence of additional seizures types.[40] Our *SYNGAP1*-DEE cohort with EM also had myoclonic (33%) and atonic (8%) seizures. We speculate that the more severe cases of EMA may be explained by *SYNGAP1* mutations, especially those individuals with earlier onset of EM or myoclonic or atonic seizures.

SYNGAP1-DEE also resembles the syndrome of MAE (formerly called myoclonic-astatic epilepsy), as reported in 3 of 11 patients in a previous series.[8] Drop attacks are the hallmark of MAE, due to atonic seizures, myoclonic seizures, and MAE. Eleven of 57 patients had features consistent with myoclonic-atonic seizures but with a more severe overall outcome compared with the variable outcome described in MAE.[37,44,45] Furthermore, severe developmental delay before the onset of seizures in all but 2 patients, together with focal and multifocal epileptiform activity in 57% of cases, mitigates against the classic features of MAE.[37,44,45]

SYNGAP1 encephalopathy often combines the features of these 2 epilepsy syndromes, EMA and MAE. An overlapping diagnosis of MAE and EMA was present in 35% of our cohort (figure 5). Bringing the 2 syndromic concepts together, we also identified a novel, distinctive seizure type, a drop attack beginning with EM followed by a myoclonic-atonic component (EM-myoclonic-atonic) or simply an atonic component (EM-atonic). We considered EM-myoclonic-atonic and EM-atonic as overlapping seizure types because the myoclonic component could be easily missed (video 1). We distinguished EM-(myoclonic)-atonic seizures from atypical absences, which may also include myoclonic and atonic components. First, the myoclonic jerks and atonic seizures were more abrupt and pronounced than in atypical absence seizures, in which subtle jerks and loss of tone can occur. Second, the frequency of GSW was faster (>3 Hz) compared with atypical absences (<2.5 Hz). One reported patient had seizures with blinking followed by a head drop and fall with irregular GSW,[27] suggestive of our *SYNGAP1* seizure type.

One patient in our cohort had West syndrome, which has not been associated with *SYNGAP1* before (figure 5). Although atypical absences, present in 20% of our cohort, may suggest a diagnosis of Lennox-Gastaut syndrome, other diagnostic criteria such as tonic seizures and generalized paroxysmal fast activity on EEG were absent. Only 1 patient had nocturnal tonic seizures (patient 19).[46]

We observed a DEE in all but 1 of our 57 patients, while only 55% of the previously published patients had a DEE (figures 1–5).[6,17,22] The remaining patients in the literature had a mild to severe developmental encephalopathy with (20%) or without (25%) seizures; it was not possible to determine whether some of these patients may have had a DEE. Our findings that such a high proportion of patients with *SYNGAP1* encephalopathy had a DEE may be due to ascertainment bias because perhaps parents from the *SYNGAP1* Facebook group participated in the study only if they were concerned that their child had seizures. Equally, EM seizures can be very subtle and misinterpreted as a behavioral mannerism. For example, patient 24 was a 9-year-old boy in whom the parents recognized that his eyelid fluttering was seizure activity only after an *SYNGAP1* mutation was identified. Patient 16 had frequent eyelid fluttering from the age of 1 year, but her first EEG was not performed until the age of 10 years and showed frequent epileptiform abnormalities. Her seizures and behavioral and sleep problems all improved after she started AEDs. In 8 patients, developmental regression occurred 2 months to >3 years before the recognition of seizures. Diagnosis of seizures in *SYNGAP1* encephalopathy is thus crucial because appropriate management may potentially improve outcome.

We found that a quarter of patients in our cohort had the distinctive feature that their reflex seizures were triggered by eating, observed previously in a single patient with seizures triggered by chewing.[8] The underlying pathophysiologic mechanism for this is unknown. Eating problems, with poor intake or gorging, were also found in more than half of our cohort.

From our historical data, we could not reliably evaluate the efficacy of the prescribed AEDs. Further studies are warranted to explore the efficacy of the drugs, particularly those that appear of benefit such as lamotrigine, valproate, and cannabidiol for *SYNGAP1*-DEE.

SYNGAP1-DEE is associated with 4 main comorbid conditions: ID, behavioral problems, a high pain threshold, and ataxia (figure 6). ID was moderate to severe in 88% of patients, with only 2 exhibiting borderline intellect. We might have underestimated the prevalence of milder phenotypes due to ascertainment bias, given our recruitment via Facebook. Severe behavioral problems with oppositional behavior, tantrums, aggression, and self-injury were present in almost three-quarters of patients, as previously observed. One of our most fascinating findings was that three-quarters of the families reported a high pain threshold in their child, often leading to a delay in diagnosis of injuries and inflammation. Parker et al.[17] also reported a high pain threshold as an anecdotal observation by some families. This finding of a high pain threshold may suggest a role for *SYNGAP1* in sensory processing.

The neuropathologic study of the brain of a woman with a truncating *SYNGAP1* mutation identified a clear loss of cerebellar Purkinje cells and associated astrocytosis (figure 4A). An unsteady or ataxic gait was identified in 51% of our patients, including this patient. Ataxia or gait abnormalities were also observed in 7 of 10 and 10 of 17 patients reported by Parker et al.[17] and Mignot et al.,[8] respectively, highlighting that cerebellar features are a key part of the *SYNGAP1*-DEE phenotype.[8,17]

Truncating and splice-site mutations occur throughout *SYNGAP1*, while missense mutations mainly cluster in the protein domains.[8] A milder outcome of *SYNGAP1*-DEE was observed significantly more frequently in patients with mutations in exons 1 to 4 compared with those with mutations in exons 5 to 19.[8] In line with this, Mignot et al.[8] also showed that patients with mutations in exons 4 and 5 were more pharmacosensitive compared to those with mutations in exons 6 to 19.[8] SYNGAP1 has several isoforms in humans with different promoter sites and alternative splicing; these may explain the variation in phenotypic severity because variants early within the gene transcript often lead to complete loss of the gene product due to nonsense-mediated decay. Further studies on the presence and function of different human isoforms of *SYNGAP1* are warranted to explain the correlation between mutation location and phenotype. Other environmental and genetic factors may also contribute to phenotypic variability. We identified concordant phenotypes in monozygotic twins (patients 53 and 54), similar phenotypes in 2 siblings (patients 8 and 9), yet variable phenotypes in individuals sharing the same mutation (patients 3 and 4, 6 and 7, 24 and 25, 28 and 29, 37 and 38).

We describe *SYNGAP1*-DEE as a predominantly generalized DEE with ID, behavioral problems, a high pain threshold, and ataxia. *SYNGAP1*-DEE combines features of both EMA and MAE. In *SYNGAP1*-DEE, we observed a novel type of drop attack with EM evolving into a myoclonic-atonic or an atonic seizure. Furthermore, a quarter of patients had seizures triggered by eating. Recognition of seizures in the context of *SYNGAP1*-DEE can be challenging but is crucial to optimizing antiepileptic therapy and improving long-term outcome.

Author contributions

D.R.M. Vlaskamp: drafting and revising manuscript, data analysis, acquisition of data. B.J. Shaw: acquisition of data. R. Burgess: data analysis. D. Mei, M. Montomoli, H. Xie, and W. XiangWei: acquisition of data and data analysis. C.T. Meyers and M.F. Bennett: analysis of *SYNGAP1* variants. D. Williams: initiative of study, study design. S.M. Maas, A.S. Brooks, G.M.S. Mancini, I.M.B.H. van de Laar, J.M. van Hagen, T. Ware, R. Webster, S. Malone, S.F. Berkovic: acquisition of data. R.M. Kalnins: analysis of brain pathology. F. Sicca: acquisition of data. G.C. Korenke: data analysis. C.M.A. van Ravenswaaij-Arts: analysis of dysmorphology, acquisition of data. M.S. Hildebrand, H.C. Mefford: supervision of analysis of *SYNGAP1* variants. Y Jiang: study supervision, revise manuscript, data acquisition. R. Guerrini: study supervision, revise manuscript, acquisition of data. I.E. Scheffer: co-writing manuscript, data analysis, study design.

Acknowledgment

The authors thank all patients and their families for their participation. They are grateful for the support of the *SYNGAP1* parent support group. They thank the Victorian Institute of Forensic Medicine, Dr. Angelika Riess, Dr. Marjolaine Willems, Dr. Einar Bryne, and Dr. Ferdinant Kok for providing clinical information and Dr. Zhixian Yang and Dr. Xiaoyan Liu for EEG review.

Study funding

Danique R.M. Vlaskamp has received an unrestricted travel grant from the Dutch Society of Child Neurology, Jo Kolk Foundation, and the Research School of Behavioural and Cognitive Neurosciences. Han Xie is supported by the National Natural Science Foundation of China (Youth Foundation) (grant 81501123). Mark F. Bennett is supported by the Victorian State Government Operational Infrastructure Support and Australian Government National Health and Medical Research Council Independent Research Institute Infrastructure Support Scheme. Yuwu Jiang is supported by the Chinese National Key Research Project (2016YFC1306200, 2016–2020). This work was supported in part by a grant from the EU Seventh Framework Programme FP7 under the project DESIRE (grant agreement 602531) to Renzo Guerrini. Ingrid E. Scheffer is supported by a National Health and Medical Research Council Program Grant (1091593, 2016–2020) and Senior Practitioner Fellowship (1104831, 2016–2020).

Disclosure

D. Vlaskamp, B. Shaw, and R. Burgess report no disclosures relevant to the manuscript. D. Mei has received scientific advisory board honoraria from BioMarin Pharmaceutical. M. Montomoli, H. Xie, C. Myers, M. Bennett, W. XiangWei, D. Williams, S. Maas, A. Brooks, G. Mancini, I. van de Laar, J. van Hagen, T. Ware, and R. Webster report no disclosures relevant to the manuscript. S. Malone has received scientific advisory board honoraria from UCB and BioMarin. S. Berkovic, R. Kalnins, F. Sicca, G. Korenke, C. van Ravenswaaij-Arts, and M. Hildebrand report no disclosures relevant to the manuscript. H.

Mefford is funded by NIH grant National Institute of Neurological Disorders and Stroke 1R01NS069605. Y. Jiang reports no disclosures relevant to the manuscript. R. Guerrini serves on the editorial boards of *Neurology®* and *Seizure;* has received speaker and consultancy fees from Eisai Inc, Novartis, Zogenix, BioMarin, UCB Pharma, and GW Pharma; receives/has received research support from the European Community, the Italian Ministry of Health, the Mariani Foundation, the Italian Epilepsy Federation, Telethon, the Tuscany Region, the Pisa Foundation, and the Italian Ministry of University and Research. I. Scheffer serves on the editorial boards of *Neurology®*eand *Epileptic Disorders*; may accrue future revenue on a pending patent regarding a therapeutic compound; has received speaker honoraria from Athena Diagnostics, UCB, GSK, Eisai, and Transgenomics; has received scientific advisory board honoraria from Nutricia, UCB and GSK; has received funding for travel from Athena Diagnostics, UCB, and GSK; and receives/has received research support from the National Health and Medical Research Council, Australian Research Council, NIH, Health Research Council of New Zealand, March of Dimes, the Weizmann Institute, Citizens United for Research in Epilepsy, US Department of Defense, and the Perpetual Charitable Trustees. Go to Neurology.org/N for full disclosures.

Publication history

Received by *Neurology* March 5, 2018. Accepted in final form August 27, 2018.

References

1. Hamdan FF, Gauthier J, Spiegelman D, et al. Mutations in SYNGAP1 in autosomal nonsyndromic mental retardation. N Engl J Med 2009;360:599–605.
2. Pinto D, Pagnamenta AT, Klei L, et al. Functional impact of global rare copy number variation in autism spectrum disorder. Nature 2010;466:368–372.
3. Carvill GL, Heavin SB, Yendle SC, et al.. Targeted resequencing in epileptic encephalopathies identifies de novo mutations in CHD2 and SYNGAP1. Nat Genet 2013; 45:1–16.
4. Klitten LL, Møller RS, Nikanorova M, Silahtaroglu A, Hjalgrim H, Tommerup N. A balanced translocation disrupts SYNGAP1 in a patient with intellectual disability, speech impairment, and epilepsy with myoclonic absences (EMA). Epilepsia 2011;52:190–193.
5. Krepischi ACV, Rosenberg C, Costa SS, Crolla JA, Huang S, Vianna-Morgante AM. A novel de novo microdeletion spanning the SYNGAP1 gene on the short arm of chromosome 6 associated with mental retardation. Am J Med Genet A 2010;152A:2365–2378.
6. Zollino M, Gurrieri F, Orteschi D, Marangi G, Leuzzi V, Neri G. Integrated analysis of clinical signs and literature data for the diagnosis and therapy of a previously undescribed 6p21.3 deletion syndrome. Eur J Hum Genet 2011;19:239–242.
7. Writzl K, Knegt AC. 6p21.3 Microdeletion involving the SYNGAP1 gene in a patient with intellectual disability, seizures, and severe speech impairment. Am J Med Genet A 2013;161A:1682–1685.
8. Mignot C, Stülpnagel CV, Nava C, et al. Genetic and neurodevelopmental spectrum of SYNGAP1-associated intellectual disability and epilepsy. J Med Genet 2016;53: 511–522.
9. Chen HJ, Rojas-Soto M, Oguni A, Kennedy MB. A synaptic Ras-GTPase activating protein (p135 SynGAP) inhibited by CaM kinase II. Neuron 1998;20:895–904.
10. Kim JH, Liao D, Lau LF, Huganir RL. SynGAP: a synaptic RasGAP that associates with the PSD-95/SAP90 protein family. Neuron 1998;20:683–691.
11. Jeyabalan N, Clement JP. SYNGAP1: mind the gap [online serial]. Front Cell Neurosci 2016;10:1–16.
12. Tidyman WE, Rauen KA. Expansion of the RASopathies. Curr Genet Med Rep 2016; 4:57–64.
13. Kim JH, Lee HK, Takamiya K, Huganir RL. The role of synaptic GTPase-activating protein in neuronal development and synaptic plasticity. J Neurosci 2003;23:1119–1124.
14. Komiyama NH, Watabe AM, Carlisle HJ, et al. SynGAP regulates ERK/MAPK signaling, synaptic plasticity, and learning in the complex with postsynaptic density 95 and NMDA receptor. J Neurosci 2002;22:9721–9732.
15. Guo X, Hamilton PJ, Reish NJ, Sweatt JD, Miller CA, Rumbaugh G. Reduced expression of the NMDA receptor-interacting protein SynGAP causes behavioral abnormalities that model symptoms of schizophrenia. Neuropsychopharmacology 2009;34:1659–1672.
16. Clement JP, Aceti M, Creson TK, et al. Pathogenic SYNGAP1 mutations impair cognitive development by disrupting the maturation of dendritic spine synapses. Cell 2013;151:709–723.
17. Parker MJ, Fryer AE, Shears DJ, et al. De novo, heterozygous, loss-of-function mutations in SYNGAP1 cause a syndromic form of intellectual disability. Am J Med Genet A 2015;167A:2231–2237.
18. Vissers LE, de Ligt J, Gilissen C, et al. A de novo paradigm for mental retardation. Nat Genet 2010;42:1109–1112.
19. Hamdan FF, Gauthier J, Araki Y, et al. Excess of de novo deleterious mutations in genes associated with glutamatergic systems in nonsyndromic intellectual disability. Am J Hum Genet 2011;88:306–316.
20. de Ligt J, Willemsen MH, van Bon BWM, et al. Diagnostic exome sequencing in persons with severe intellectual disability. N Engl J Med 2012;367:1921–1929.
21. Rauch A, Wieczorek D, Graf E, et al. Range of genetic mutations associated with severe non-syndromic sporadic intellectual disability: an exome sequencing study. Lancet 2012;380:1674–1682.
22. Berryer MH, Hamdan FF, Klitten LL, et al. Mutations in SYNGAP1 cause intellectual disability, autism, and a specific form of epilepsy by inducing haploinsufficiency. Human Mutat 2013;34:385–394.
23. von Stülpnagel C, Funke C, Haberl C, et al. SYNGAP1 mutation in focal and generalized epilepsy: a literature overview and a case report with special aspects of the EEG. Neuropediatrics 2015;46:287–291.
24. Redin C, Gérard B, Lauer J, et al. Efficient strategy for the molecular diagnosis of intellectual disability using targeted high-throughput sequencing. J Med Genet 2014; 51:724–736.
25. Dyment DA, Tétreault M, Beaulieu CL, et al. Whole-exome sequencing broadens the phenotypic spectrum of rare pediatric epilepsy: a retrospective study. Clin Genet 2015;88:34–40.
26. O'Roak BJ, Stessman HA, Boyle EA, et al. Recurrent de novo mutations implicate novel genes underlying simplex autism risk. Nat Commun 2014;5:5595.
27. Prchalova D, Havlovicova M, Sterbova K, Stranecky V, Hancarova M, Sedlacek Z. Analysis of 31-year-old patient with SYNGAP1 gene defect points to importance of variants in broader splice regions and reveals developmental trajectory of SYNGAP1-associated phenotype: case report. BMC Med Genet 2017;18:62.
28. McRae JF, Clayton S, Fitzgerald TW, et al. Prevalence and architecture of de novo mutations in developmental disorders. Nature 2017;542:433–438.
29. Richards S, Aziz N, Bale S, et al. Standards and guidelines for the interpretation of sequence variants: a joint consensus recommendation of the American college of medical genetics and genomics and the association for molecular pathology. Genet Med 2015;17:405–424.
30. Reutens TC, Howell RA, Gebert KE, Berkovic SF. Validation of a questionnaire for clinical seizure diagnosis. Epilepsia 1992;33:1065–1071.
31. Fisher RS, Cross JH, French JA, et al. Operational classification of seizure types by the International League Against Epilepsy [online serial]. Epilepsia 2017:1–9. Available at: ilae.org. Accessed January 17, 2018.
32. Scheffer IE, Berkovic S, Capovilla G, et al. ILAE classification of the epilepsies: position paper of the ILAE Commission for Classification and Terminology [online serial]. Epilepsia 2017:1–10. Available at: ilae.org. Accessed January 17, 2018.
33. American Psychiatric Association. Diagnostic and Statistical Manual of Mental Disorders: DSM-V, Washington, DC: American Psychiatric Association; 2013.
34. Bateman A, Martin MJ, O'Donovan C, et al. UniProt: a hub for protein information. Nucleic Acids Res 2015;43:D204–D212.
35. Krawczak M, Riess J, Cooper DN. The mutational spectrum of single base-pair substitutions in mRNA splice junctions of human genes: causes and consequences. Hum Genet 1992;90:41–54.
36. Jeavons PM. Nosological problems of myoclonic epilepsies in childhood and adolescence. Dev Med Child Neurol 1977;19:3–8.
37. Doose H, Gerken H, Leonhardt R, Völzke E, Völz C. Centrencephalic myoclonic-astatic petit mal: clinical and genetic investigation. Neuropadiatrie 1970;2:59–78.
38. Lek M, Karczewski KJ, Minikel EV, et al. Analysis of protein-coding genetic variation in 60,706 humans. Nature 2016;536:285–291.
39. Striano S, Capovilla G, Sofia V, et al. Eyelid myoclonia with absences (Jeavons syndrome): a well-defined idiopathic generalized epilepsy syndrome or a spectrum of photosensitive conditions? Epilepsia 2009;50:15–19.
40. Striano S. Eyelid myoclonia with absences: an overlooked epileptic syndrome? Neurophysiol Clin 2002;32:287–296.
41. Caraballo RH, Fontana E, Darra F, et al. A study of 63 cases with eyelid myoclonia with or without absences: type of seizure or an epileptic syndrome? Seizure 2009;18: 440–445.
42. Sadleir LG, Vears D, Regan B, Redshaw N, Bleasel A, Scheffer IE. Family studies of individuals with eyelid myoclonia with absences. Epilepsia 2012;53:2141–2148.
43. Fournier-Goodnight AS, Gabriel M, Perry MS. Preliminary neurocognitive outcomes in Jeavons syndrome. Epilepsy Behav 2015;52:260–263.
44. Stephani U. The natural history of myoclonic astatic epilepsy (Doose syndrome) and Lennox-Gastaut syndrome. Epilepsia 2006;47(suppl 2):53–55.
45. Oguni H, Hayashi K, Awaya Y, Fukuyama Y, Osawa M. Severe myoclonic epilepsy in infants: a review based on the Tokyo Women's Medical University series of 84 cases. Brain Dev 2001;23:736–748.
46. Arzimanoglou A, French J, Blume WT, et al. Lennox-Gastaut syndrome: a consensus approach on diagnosis, assessment, management, and trial methodology. Lancet Neurol 2009;8:82–93.