

**A rare manifestation of Neurofibromatosis type 1: A plexiform neurofibroma involving the mediastinum and lungs with endobronchial neurofibromata.**

**Running title:** Plexiform neurofibroma involving the mediastinum.

**Authors:**

Dr Heather M. Pascoe<sup>1</sup>

Mr Phillip Antippa<sup>2</sup>

Associate Professor Louis Irving<sup>3</sup>

Dr Michael Christie<sup>4</sup>

Dr Mark W. McCusker<sup>1</sup>

<sup>1</sup>Department of Radiology, Royal Melbourne Hospital, University of Melbourne, Parkville, Victoria, Australia.

<sup>2</sup>Department of Cardiothoracic Surgery, Royal Melbourne Hospital, University of Melbourne, Parkville, Victoria, Australia.

<sup>3</sup>Department of Respiratory Medicine, Royal Melbourne Hospital, University of Melbourne, Parkville, Victoria, Australia.

<sup>4</sup>Department of Pathology, The Royal Melbourne Hospital, University of Melbourne, Parkville, Victoria, Australia.

**Corresponding Author:**

Dr Heather Michelle Pascoe

Level 1 Radiology Department, Royal Melbourne Hospital, Grattan St, Parkville, Victoria, Australia, 3050

Email: [pasceh@gmail.com](mailto:pasceh@gmail.com)

Phone: 0438674141

Fax: 61 3 9342 8369

**This is the author manuscript accepted for publication and has undergone full peer review but has not been through the copyediting, typesetting, pagination and proofreading process, which may lead to differences between this version and the [Version of Record](#). Please cite this article as [doi: 10.1111/1754-9485.12802](https://doi.org/10.1111/1754-9485.12802)**

This article is protected by copyright. All rights reserved

1

2 DR. HEATHER MICHELLE PASCOE (Orcid ID : 0000-0002-9500-2978)

3

4

5 Article type : Radiology Case Report

6

7

8 **A rare manifestation of Neurofibromatosis type 1: A plexiform**  
9 **neurofibroma involving the mediastinum and lungs with endobronchial**  
10 **neurofibromata.**

11 Pascoe HM<sup>1</sup>, Antippa P<sup>2</sup>, Irving L<sup>3</sup>, Christie M<sup>4</sup>, McCusker MW<sup>1</sup>.12 <sup>1.</sup> Department of Radiology, The Royal Melbourne Hospital, University of Melbourne,  
13 Parkville, Victoria, Australia.14 <sup>2.</sup> Department of Cardiothoracic Surgery, The Royal Melbourne Hospital, University of  
15 Melbourne, Parkville, Victoria, Australia.16 <sup>3.</sup> Department of Respiratory Medicine, The Royal Melbourne Hospital, University of  
17 Melbourne, Parkville, Victoria, Australia.18 <sup>4.</sup> Department of Pathology, The Royal Melbourne Hospital, University of Melbourne,  
19 Parkville, Victoria, Australia.

20

21 HM Pascoe: MBBS (Hons), BMedSci, MMed

22 P Antippa: MBBS, FRACS

23 L Irving: MBBS, FRACP

24 M Christie: MBBS, FRCPA, PhD

25 MW McCusker: MB BCh, MRCPI, FFR(RCSI), FRANZCR

26

27 **Key words:**

28 Computed tomography, Endobronchial nodules, Lung, Mediastinal neurofibroma,  
29 Neurofibromatosis type 1, Plexiform neurofibroma

30 **Summary:**

31 Neurofibromatosis type 1 (NF1) is a multisystem phakomatosis. The intrathoracic  
32 manifestations of NF1 are protean. We describe a rare case of a plexiform  
33 neurofibroma infiltrating the mediastinum and lungs with multiple endobronchial  
34 neurofibromata. To our knowledge, a mediastinal plexiform neurofibroma extending  
35 into the lungs on CT has not been reported.

36 **Case Presentation:**

37 A 24-year-old male patient with known NF1, under surveillance for an optic nerve  
38 glioma, presented with right chest wall radicular pain. CT of the thorax demonstrated a  
39 right posterior mediastinal mass, likely the cause of his symptoms. In addition, CT  
40 identified a soft tissue mass in the mediastinum encasing the carina and left main  
41 bronchus (Figure 1a and 1b) and infiltrating into the lung parenchyma along the left  
42 upper and lower lobe bronchi (Figure 1c and 1d). There were also multiple nodules  
43 present within the trachea and bronchi on both sides (Figure 2).

44 Bronchoscopy confirmed multiple nodules within the trachea and both main bronchi  
45 (Figure 3) of which biopsies were taken. Histopathology demonstrated myxoid stroma  
46 and bland spindle cells which were S100 positive with scattered nerve fibres on  
47 neurofilament protein (NFP) staining, consistent with neurofibromata (Figure 4). There  
48 was no evidence of malignancy.

49 Fine needle aspirate of the mediastinal component yielded blood-stained fluid and  
50 mixed inflammatory cells only. No malignant cells were identified. However, given the  
51 infiltrative growth pattern and biopsy proven neurofibromata within the adjacent  
52 bronchi, this was favoured to represent a plexiform neurofibroma.

53 Surveillance imaging has been organised to monitor for growth of the endobronchial  
54 nodules and plexiform neurofibroma, as well as to monitor for potential malignant  
55 degeneration.

**56 Discussion:**

57 Neurofibromatosis type 1 (NF1) is the most common phakomatosis occurring in  
58 approximately one in every 2000 births (1). It can be inherited in an autosomal  
59 dominant manner, however approximately 50% of cases occur sporadically due to a  
60 spontaneous mutation (1). NF1 involves multiple body systems with manifestations  
61 occurring in the thorax, abdomen, central nervous system, musculoskeletal system,  
62 and skin.

63 Many intrathoracic manifestations of NF1 are recognised, including spinal and rib  
64 abnormalities, posterior mediastinal neurofibromata, cystic lung disease, pulmonary  
65 fibrosis, and intrapulmonary neurofibromata (1). Plexiform neurofibromata are  
66 pathognomic of NF1 and in the thorax, most commonly occur adjacent to ribs and in  
67 the paravertebral region (1,2). Mediastinal plexiform neurofibromas are well described  
68 and occur in the distribution of the mediastinal nerves (2,3). Bourgooin et al.(3)  
69 described four cases of mediastinal plexiform neurofibromata which involved the  
70 entire mediastinum in three patients and the middle and posterior mediastinum in  
71 one. A mediastinal plexiform neurofibroma infiltrating along the bronchi into the lungs  
72 however has not been previously described.

73 Endobronchial neurofibromata in NF1 are rare (4,5). In a case report by Gillissen et al.  
74 (4), infiltration of the bronchial tree with neurofibromata was demonstrated on  
75 bronchoscopy and biopsy, however CT and MRI of the thorax were normal. In a case  
76 reported by Venugopal et al. (5), multiple nodular swellings within both main bronchi  
77 were neurofibromata on histology; additional intrapulmonary nodules were thought to  
78 represent intrapulmonary neurofibromata.

79 In this case, it is hypothesized that the soft tissue mass in the mediastinum and lungs is  
80 a plexiform neurofibroma given the infiltrating pattern and the presence of biopsy  
81 proven neurofibromata in the adjacent the airways. This is the first description of such  
82 an entity.

**83 References:**

- 84 (1) Rossi SE, Erasmus JJ, McAdams HP, Donnelly LF. Thoracic manifestations of  
85 neurofibromatosis-1. AJR 1999 Dec;173(6):1631-1638.
- 86 (2) Tongsgard JH, Kwak SM, Short MP, Dachman AH. CT imaging in adults with  
87 neurofibromatosis-1: frequent asymptomatic plexiform lesions. Neurology 1998  
88 Jun;50(6):1755-1760.
- 89 (3) Bourgouin PM, Shepard JO, Moore EH, McCloud TC. Plexiform neurofibromatosis of  
90 the mediastinum: CT appearance. AJR 1988 Sep;151(3):461-463.
- 91 (4) Gillissen A, Kotterba S, Rasche K, Müller K, Schultze-Werninghaus G. A rare  
92 manifestation of von Recklinghausen neurofibromatosis: advanced neurofibromatous  
93 infiltration in lung of a HIV-positive patient. Respiration 1994;61(5):292-294.
- 94 (5) Venugopal P, Karunakaran R, Bindu CG, Elizabeth. Intrabronchial  
95 neurofibromatosis. J Assoc Physicians India 2013 Sep;61(9):669-671.

96

97

**98 Figure Legends:**

99

100 Figure 1: Coronal (A) and axial (B-D) CT thorax demonstrating a soft tissue mass in the  
101 mediastinum encasing the carina and left main bronchus (arrows in A and B) and  
102 infiltrating into the lung parenchyma along the left upper and lower lobe bronchi  
103 (arrows in C and D).

104

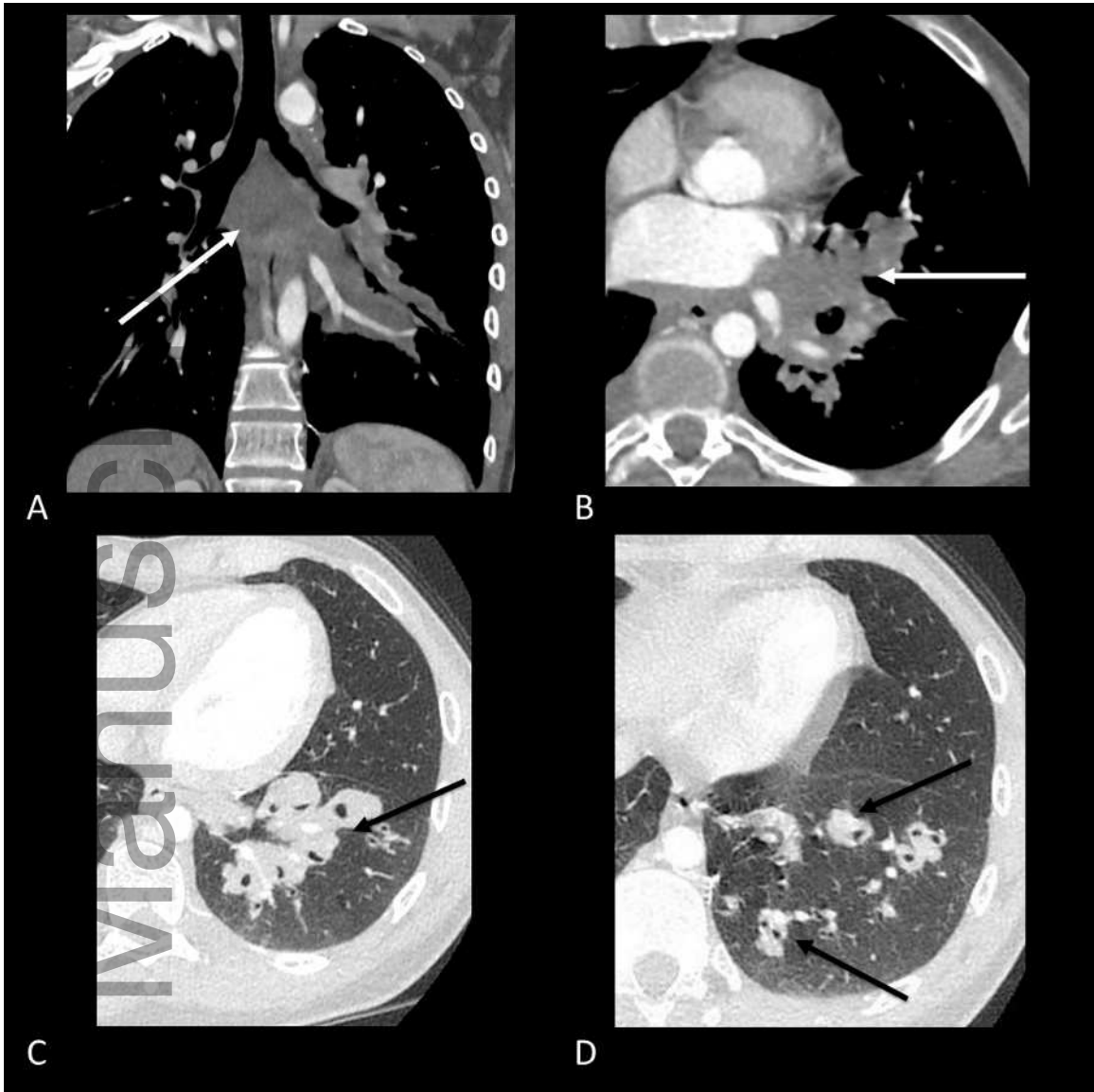
105 Figure 2: Coronal (A) and sagittal (B) CT thorax demonstrates multiple nodules within  
106 the trachea (open arrow in A) and left sided bronchi (black arrows in A and B).

107

108 Figure 3: Bronchoscopy images demonstrating multiple nodules within the left main  
109 bronchus.

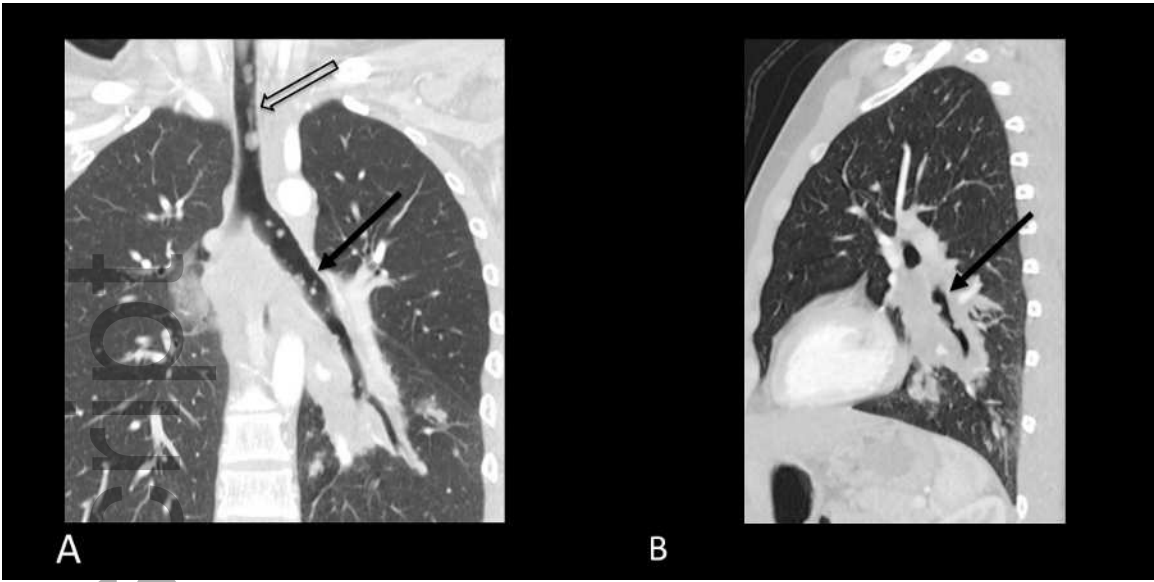
110

111 Figure 4: Histopathology pictures of the bronchoscopy specimens (x200 magnification)  
112 showed bland spindle cells with myxoid stroma (A). On immunohistochemistry, the  
113 cells were positive for S100 (B). Appearances are consistent with neurofibromata.



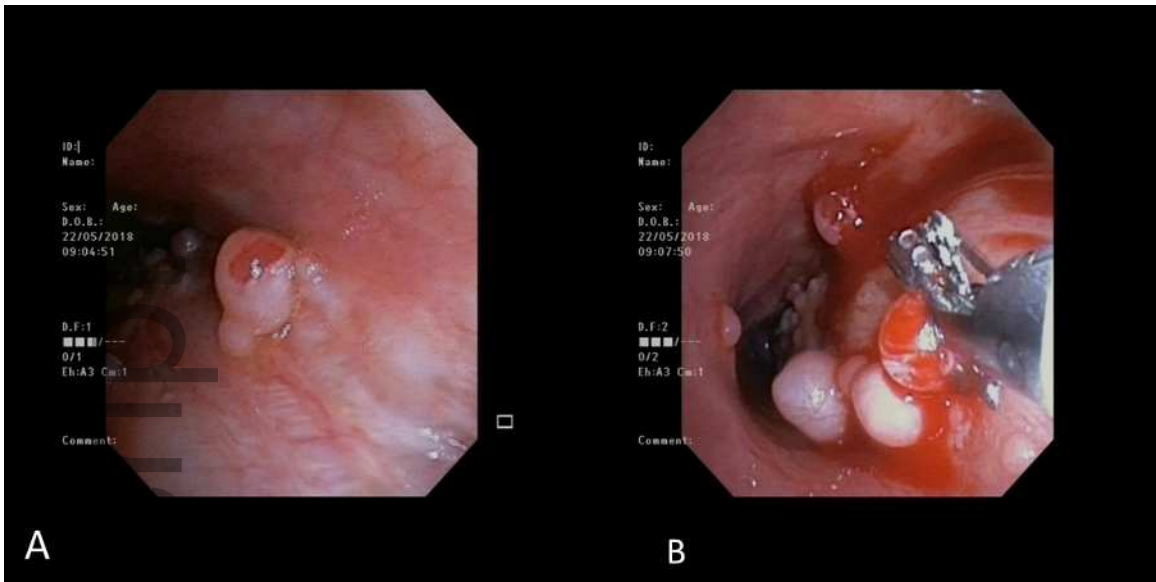
ara\_12802\_f1.tif

Autho



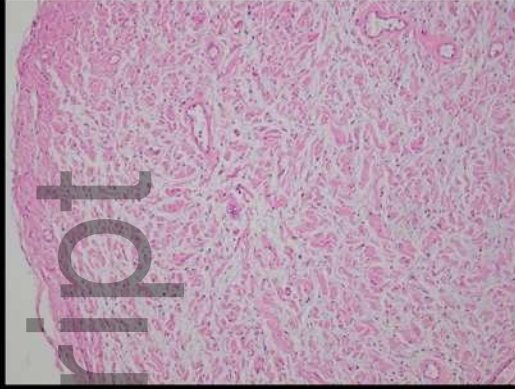
ara\_12802\_f2.tif

Author Manuscript

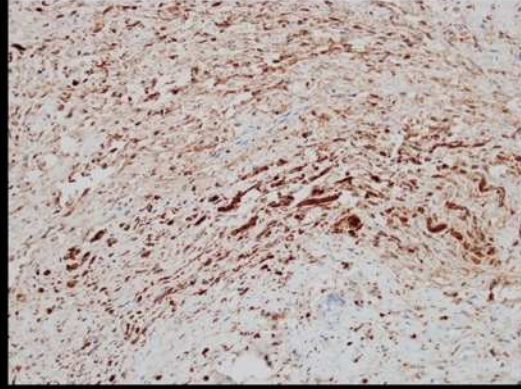


ara\_12802\_f3.tif

Author Manuscript



A



B

ara\_12802\_f4.tif

Author Manuscript