



Minerva Access is the Institutional Repository of The University of Melbourne

Author/s:

McCamley, C;Bozin, M;Tasevski, R;Mann, B

Title:

Post-partum necrotizing fasciitis of the breast: a case study

Date:

2021-10-01

Citation:

McCamley, C., Bozin, M., Tasevski, R. & Mann, B. (2021). Post-partum necrotizing fasciitis of the breast: a case study. ANZ Journal of Surgery, 91 (10), pp.2214-2215. <https://doi.org/10.1111/ans.16678>.

Persistent Link:

<https://hdl.handle.net/11343/298378>

McCamley Chere (Orcid ID: 0000-0003-2440-1821)

Title:

Post-partum necrotising fasciitis of the breast: a case study

Authors:

Corresponding author: Dr Chere McCamley (FRACS), General Surgery, West Gippsland Healthcare Group, Warragul, Victoria, Australia, 3820

Postal: PO Box 297, Warragul, VIC 3820.

Email: chere.mccamley@gmail.com

Phone: 0418467795

Dr Michael Bozin (BMBS) General Surgery, Royal Melbourne Hospital, Melbourne, Victoria Australia

Mr Robert Tasevski (FRACS), The Breast Service, The Royal Melbourne and The Royal Women's Hospital, Melbourne, Victoria, Australia

Professor Bruce Mann (FRACS) The Breast Service, The Royal Melbourne and The Royal Women's Hospital, Melbourne, Victoria, Australia

Acknowledgements: N/A

This is the author manuscript accepted for publication and has undergone full peer review but has not been through the copyediting, typesetting, pagination and proofreading process, which may lead to differences between this version and the [Version of Record](#). Please cite this article as doi: [10.1111/ans.16678](https://doi.org/10.1111/ans.16678)

This article is protected by copyright. All rights reserved.

This case describes a 37-year-old female with a complex history of post-partum lactational breast abscess who developed necrotising fasciitis (NF) of the breast. The patient had no background medical issues, had a healthy BMI, was a non-smoker, and was not on any regular medication. When she was 2 months post-partum she had been successfully treated for a left breast abscess due to staphylococcus aureus.

At 7 months post-partum, the patient represented with a 2 week history of right breast pain and swelling, consistent with a lactational abscess. Ultrasound examination revealed a large complex collection of the lateral breast extending to the axilla. Radiological drainage was unsuccessful. She proceeded to the operating theatre and 100ml of purulent fluid was evacuated and the wound was packed. Staphylococcus aureus sensitive to flucloxacillin was cultured and antibiotics were administered intravenously (1 gram q6h). The patient required two further surgical debridement/washout in theatre. Repeat microbiology showed staphylococcus epidermidis. The patient made a good clinical recovery with daily dressings. The cellulitis resolved and inflammatory markers normalised. The patient was seen by the lactation consultant and ceased breastfeeding during admission. She was discharged home with Hospital in the Home and daily wound care. She was seen weekly by the Breast Surgery team in outpatients and was progressing well.

Two weeks following discharge from hospital, the patient represented to the Emergency Department with new right breast cellulitis, severe breast pain and feeling unwell. She was afebrile, heart rate 62 bpm, blood pressure 94/62. Her right breast was cellulitic and discharging purulent fluid from a medial breast wound. She was taken to theatre and intra-operatively, extensive necrosis of the inferior breast and signs of necrotising fasciitis was found involving the fascia of pectoralis major and rectus abdominus (photo 1). The wound was extensively debrided and gram stains performed. A negative pressure dressing was applied. The patient was treated with empirical vancomycin, meropenem and clindamycin.

The Infectious Diseases team continued the empirical antibiotic treatment for 7 days. Final microbiology found Escherichia coli sensitive to Augmentin and her antimicrobial treatment changed to oral Augmentin for 10 days.

The patient required four further debridements in theatre and negative pressure dressings (photos 2 & 3). Following good clinical and biochemical progress, her wound was primarily closed with interrupted nylon sutures with a temporary drain for 3 days. She was discharged to hospital in the home and outpatients follow-up. The patient has remained well since discharge.

Lactational mastitis (LM) is a common condition that affects post-partum women, however the true incidence is unknown (1) and a standardised definition of LM is lacking (2). In an Australian study, of the LM cases that required antibiotics (n=206), only 5 cases required ultrasound-guided aspiration or incision and drainage in theatre. Progression of LM to necrotising fasciitis (NF) of the breast is a rare entity (3,4). A literature review described two prior cases of breast NF in the post-partum lactating breast (5).

Necrotising fasciitis is time critical surgical condition that has a high mortality rate often despite aggressive therapy (3,4,6). As NF pathogens spread along fascial planes, tissue necrosis, cytotoxin release and rapid deterioration results (3,6). Clinical signs include rapid progression of painful skin erythema and necrosis, haemorrhagic bullae and haemodynamic instability (5). It been suggested that skin changes in breast NF is delayed due to preferential infection of Coopers suspensory ligaments (5).

In our case, pre-operative imaging was not performed due to the clinical findings of discharging pus. A case report of ultrasound diagnosed breast NF described deep fluid collection within the breast with bright echoes representing gas (7). Computerised tomography (CT) of NF may show interstitial free gas and fat stranding (5). MRI is reported as a highly sensitive, low specificity, however timeliness and haemodynamic parameters often preclude its use in suspected cases of NF (6).

Principles of treatment involve urgent and aggressive surgical debridement, antimicrobial therapy and intensive care support. Hyperbaric therapy is utilised in some settings (3). Treatment of breast NF often involves radical mastectomy (3), however early identification may allow breast conservation (3).

Our case describes a case of breast NF in a young, otherwise healthy female with a recent history of lactational abscess. Our case demonstrates that pain out of proportion to clinical findings may be a clue to NF rather than a simple lactational breast abscess. This case highlights the need for NF of the breast to be a diagnostic consideration and shows that aggressive early debridement can lead to a good clinical outcome.

Authors contribution:

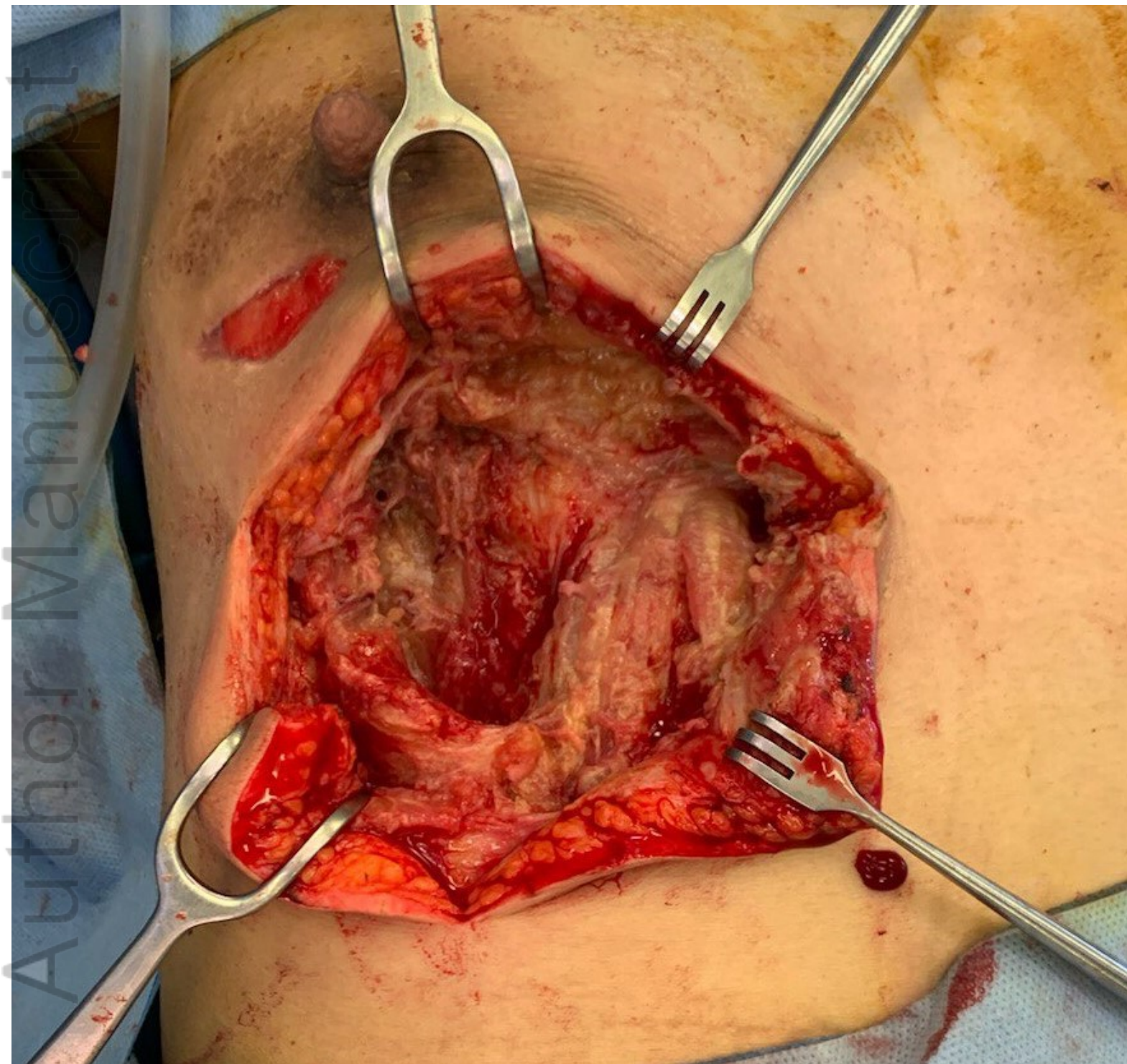
Chere McCamley; investigation, writing original draft, writing review and editing, **Michael Bozin**; Writing review and editing, **Robert Tasevski**; supervision, writing review and editing, **Bruce Mann**; supervision, writing review and editing.

References

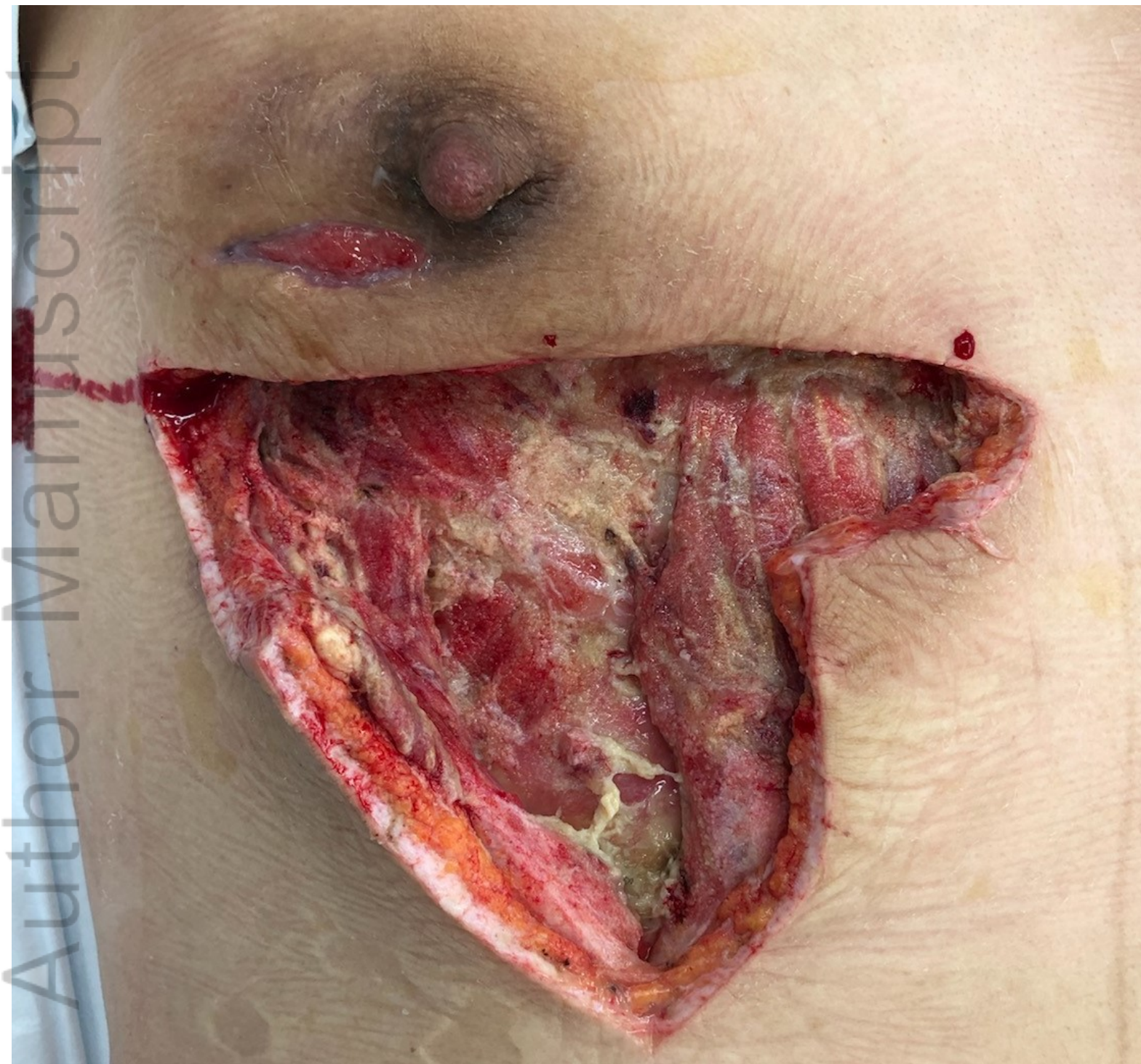1. Wilson E, Woodd SL, Benova L. Incidence of and Risk Factors for Lactational Mastitis: A Systematic Review. *J Hum Lact.* 2020 Apr 14;890334420907898.
2. Amir LH, Forster DA, Lumley J, McLachlan H. A descriptive study of mastitis in Australian breastfeeding women: incidence and determinants. *BMC Public Health.* 2007 Apr 25;7:62.
3. Dodaro CA, Zaffiro A, Iannicelli AM, Giordano L, Sorbino L, Mangiapia F, et al. Combined Timed Surgery and Conservative Management of Primary Necrotizing Fasciitis of the Breast: A Case Report. *Am J Case Rep.* 2020 Jun 3;21:e922688.
4. Chen R, Gillespie C, Jassal K, Lee J, Read M. Delayed presentation of breast necrotising fasciitis due to COVID-19 anxiety. *ANZJS.* 2020;(June):1485–7.
5. Marks B, Fasih T, Amonkar S, Pervaz M. Necrotising fasciitis of the breast: A rare but deadly disease. *Int J Surg Case Rep.* 2019;65:10–4.
6. Lee J, Lee KJ, Sun WY. Necrotizing fasciitis of the breast in a pregnant woman successfully treated using negative-pressure wound therapy. *Ann Surg Treat Res.* 2015 Aug;89(2):102–6.
7. Hanif MA, Bradley MJ. Sonographic findings of necrotizing fasciitis in the breast. *J Clin Ultrasound.* 2008 Oct;36(8):517–9.

Case Study Figures:

- 1) Photo 1: Intra-operative image: debridement of necrotising fasciitis
- 2) Photo 2: Intra-operative image: subsequent debridement
- 3) Photo 3: Intra-operative image: negative pressure dressing

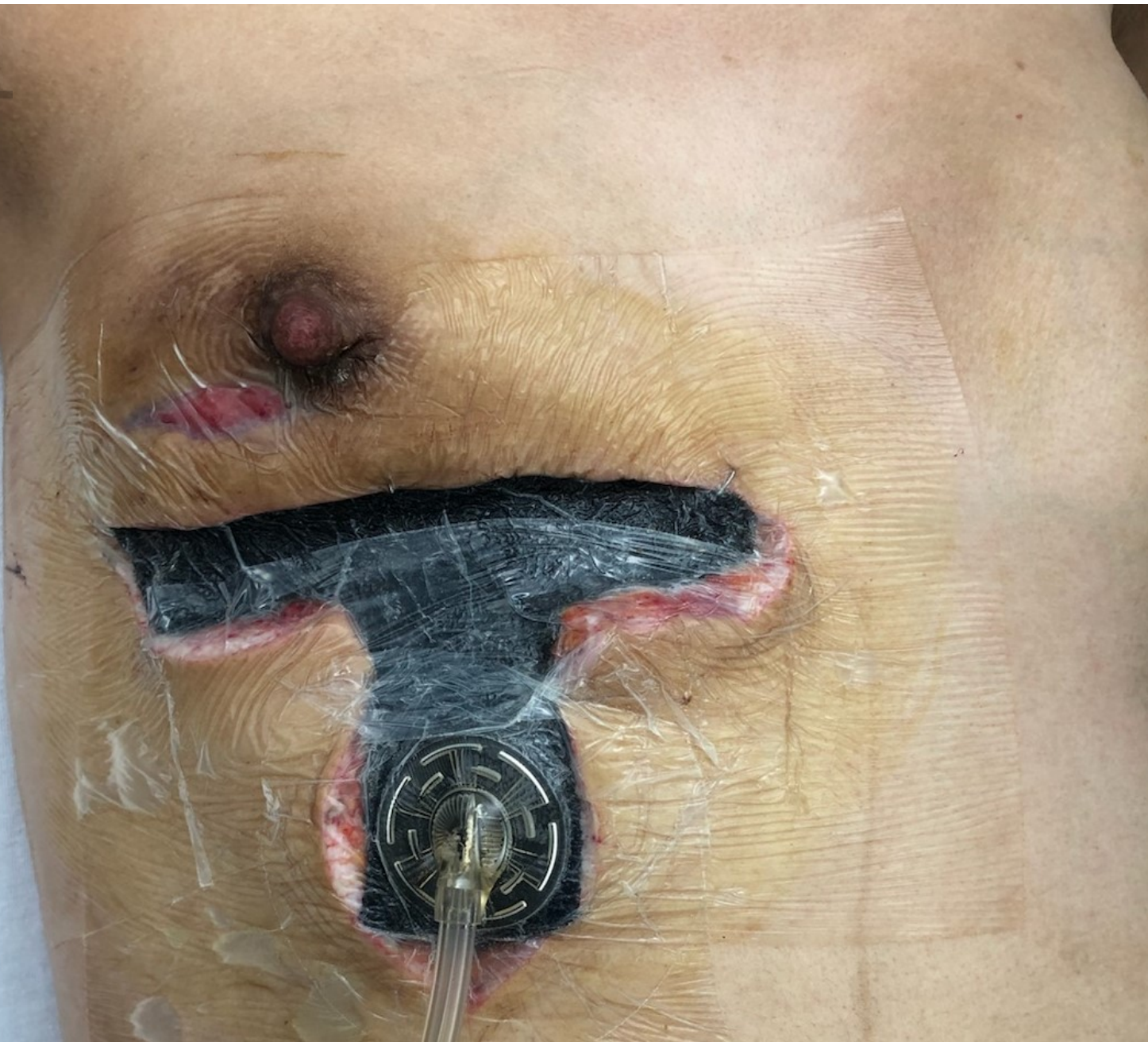

ANS_16678_Case study photo1.jpg



ANS_16678_Case study photo2.jpg

Author Manuscript



ANS_16678_Case study photo3.jpg