



Minerva Access is the Institutional Repository of The University of Melbourne

Author/s:

Lee, MH;Moxey, JE;McLachlan, SA;Macisaac, RJ;Sachithanandan, N

Title:

Dilemmas in metastatic differentiated thyroid cancer: To irradiate, medicate, or palliate?

Date:

2016-05-01

Citation:

Lee, M. H., Moxey, J. E., McLachlan, S. A., Macisaac, R. J. & Sachithanandan, N. (2016). Dilemmas in metastatic differentiated thyroid cancer: To irradiate, medicate, or palliate?. World Journal of Endocrine Surgery, 8 (2), pp.168-171. <https://doi.org/10.5005/jp-journals-10002-1184>.

Persistent Link:

<https://hdl.handle.net/11343/345599>

Terms and Conditions:

CC BY-NC

License:

<https://creativecommons.org/licenses/by-nc/4.0/>

CASE REPORT

Dilemmas in Metastatic Differentiated Thyroid Cancer: To irradiate, medicate, or palliate?

¹Melissa H Lee, ²Jayne E Moxey, ³Sue-Anne McLachlan, ⁴Richard J MacIsaac, ⁵Nirupa Sachithanandan

ABSTRACT

Aims: To explore the challenges in the management of metastatic differentiated thyroid cancer.

Introduction: Differentiated thyroid cancer (DTC) is the most common form of thyroid cancer. The initial diagnosis of thyroid carcinoma and the distinction between benign and neoplastic disease can be challenging. Radioiodine-refractory metastatic DTC also presents a therapeutic dilemma. Novel targeted agents for advanced radioiodine-refractory metastatic thyroid cancer, such as tyrosine kinase inhibitors (TKIs), are being increasingly used with clinical success, broadening current available therapeutic options.

Case report: We present the case of a 61-year-old woman with radioiodine-refractory metastatic follicular thyroid carcinoma, which was initially misdiagnosed as benign Hurthle cell adenoma. We focus on the challenges in both the initial diagnosis and the subsequent management of her advanced disease with skeletal dominant metastases.

Conclusion: The advent of targeted systemic therapies as emerging frontline and salvage therapy is a novel addition to the management of radioiodine-refractory advanced DTC. Further studies to expand the role of sequential and redifferentiation therapy for advanced disease and strategies to reduce skeletal-related events are still required.

Keywords: Metastatic disease, Radioiodine-refractory, Thyroid cancer, Tyrosine kinase inhibitors.

How to cite this article: Lee MH, Moxey JE, McLachlan S-A, MacIsaac RJ, Sachithanandan N. Dilemmas in Metastatic Differentiated Thyroid Cancer: To irradiate, medicate, or palliate? *World J Endoc Surg* 2016;8(2):168-171.

Source of support: Nil

Conflict of interest: None

¹Trainee, ²Resident, ³⁻⁵Consultant Oncologist,

^{1,2}Department of Endocrinology and Diabetes, St. Vincent's Hospital Melbourne, Victoria, Australia

³Department of Oncology, St. Vincent's Hospital; Department of Medicine, The University of Melbourne, Melbourne, Victoria Australia

^{4,5}Department of Endocrinology and Diabetes, St. Vincent's Hospital; Department of Medicine, The University of Melbourne, Melbourne, Victoria, Australia

Corresponding Author: Melissa H Lee, Trainee, Department of Endocrinology and Diabetes, St. Vincent's Hospital, Melbourne Victoria, Australia, Phone: +392312211, e-mail: mellee005@gmail.com

INTRODUCTION

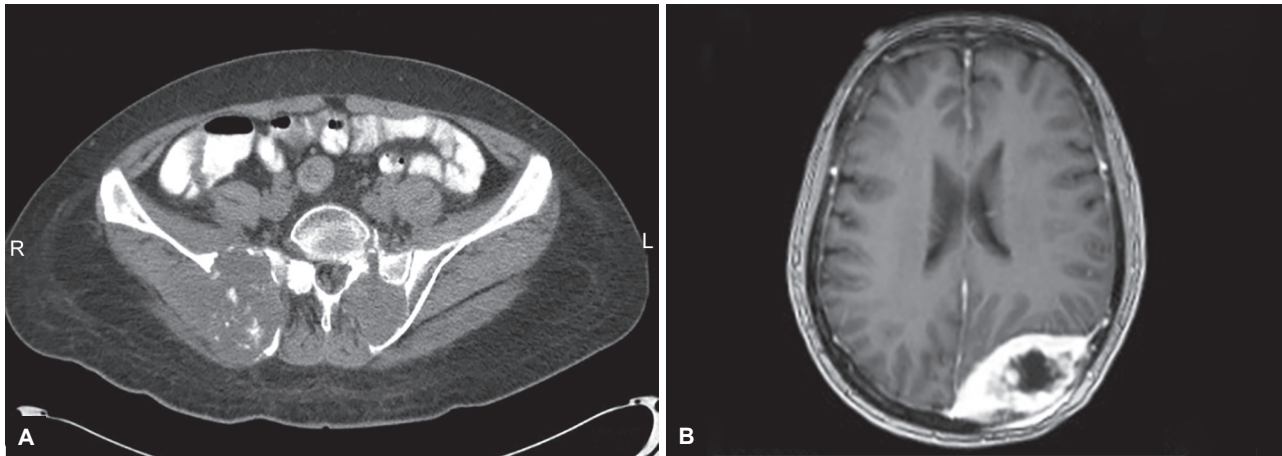
Differentiated thyroid cancer (DTC) make up the vast majority of thyroid cancers. The initial diagnosis of thyroid carcinoma and the distinction between benign and neoplastic disease can be challenging. Radioiodine-refractory metastatic DTC also presents a therapeutic dilemma. Novel targeted agents for advanced radioiodine-refractory metastatic thyroid cancer, such as tyrosine kinase inhibitors (TKIs), are being increasingly used with clinical success, broadening current available therapeutic options.

CASE REPORT

A 61-year-old Cambodian woman presented in 2008 to our institution with pelvic pain secondary to metastatic follicular thyroid carcinoma. She had undergone a left hemithyroidectomy 20 years prior for a benign nodule and subsequently developed a right-sided nodule 11 years later measuring 3.5×3.5×2.5 cm. A fine needle aspirate (FNA) was suggestive of papillary carcinoma and she underwent completion thyroidectomy. However, post-operative histology revealed Hurthle cell adenoma and thus, she received no adjuvant therapy.

Subsequent computed tomography (CT) scan showed pelvic and skull metastases (Figs 1A and B). Sacroiliac biopsy confirmed metastatic follicular thyroid carcinoma (positive immune staining for thyroglobulin, cytokeratin-7, and thyroid transcription factor-1). Initial management included therapeutic radioactive iodine (RAI, 198 mCi I-131), external beam radiotherapy (EBRT) to pelvis and skull, and eight cycles of doxorubicin with symptomatic improvement.

Three years later, she developed further skull and skeletal metastases in her ribs, T4, and L1 vertebral bodies. She underwent excision of the skull lesion and received two further doses of RAI (cumulative dose 578 mCi I-131). Post-RAI, whole-body scan (WBS) revealed disease progression consistent with RAI-refractory disease, including new uptake in multiple thoracolumbar vertebral bodies, pelvis, and bilateral femur (Fig. 2). Her disease was Fluorodeoxyglucose (FDG-avid). In the setting of progressive, RAI-refractory disease and good performance status, pazopanib was commenced. She achieved initial biochemical response with declining



Figs 1A and B: (A) Computed tomography pelvis showing pelvic metastases; and (B) magnetic resonance imaging brain showing skull metastases

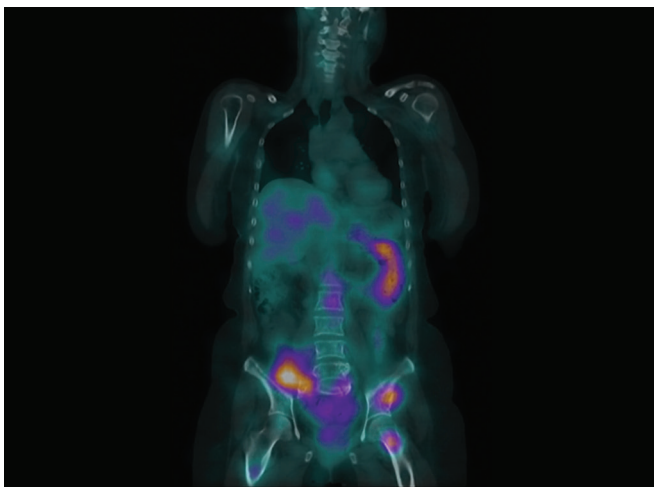


Fig. 2: Post-therapeutic I-131 WBS demonstrating progressive disease

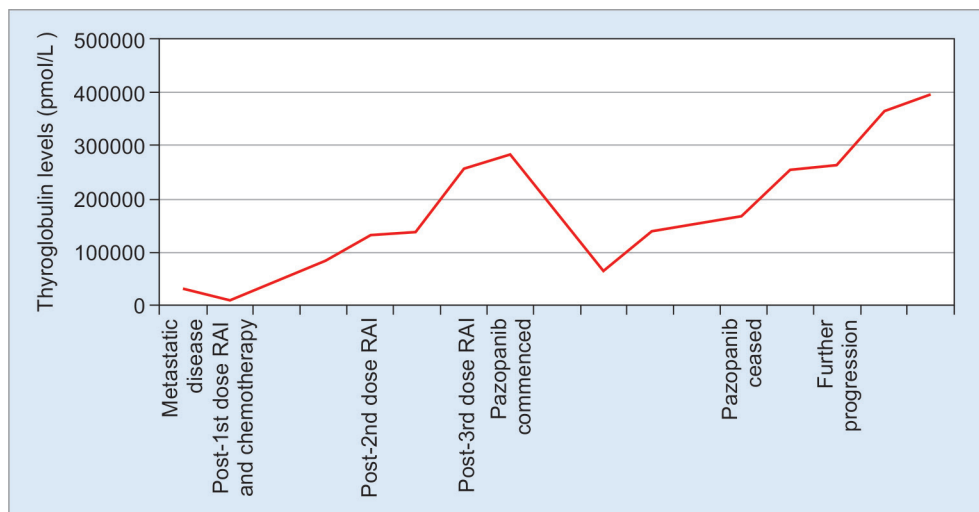
She has since experienced rapid progression with innumerable skeletal metastases within the manubrium and sternum; pathological fractures of the sternum, bilateral humeri, and pubic rami; and cranial nerve impingement secondary to a skull base lesion. She has now received further EBRT as well as orthopedic fixation to the humeri. She subsequently also developed T10 spinal cord compression that was managed with high dose of dexamethasone.

Gene mutation analysis of tumor tissue showed wild-type NRAS and BRAF. Further, 2nd line systemic therapy was considered given failure of 1st line TKI therapy; however, it was felt to be inappropriate due to her rapidly declining functional status. Her thyroglobulin levels continue to rise (Graph 1). Currently, she is maintained on suppressive thyroxine, alendronate, calcium, vitamin D, and opiate analgesia.

thyroglobulin levels; however, treatment was complicated by myelosuppression and hypertension necessitating dose reduction. Pazopanib was ceased 17 months later due to progressive disease.

DISCUSSION

Hurthle cell neoplasms are considered a variant of thyroid follicular cell carcinoma and are predominantly comprised



Graph 1: Thyroglobulin levels throughout the disease course

of cells displaying oncocytic features, also called Hurthle cells.¹ The distinction between Hurthle cell hyperplasia and neoplasia can be challenging. Histologically, Hurthle cell adenomas have no evidence of capsular or vascular invasion and no nuclear features of papillary carcinoma.² However, as demonstrated in this case, benign Hurthle cell lesions can subsequently develop malignant behavior with metastatic disease. Limitations in evaluation of frozen sections, such as sampling error, variable thickness, and freezing artifacts of irregularity of the capsule, could lead to the misdiagnosis of Hurthle cell carcinoma as benign disease.³ The disparate findings between the initial FNA and postoperative histology in this case were unusual; however, retrospective analysis of both samples has confirmed the original cytological and subsequent histological diagnoses. Given the incongruence, measurement of a serum thyroglobulin level and long-term surveillance may have been useful retrospectively given the suggestion of carcinoma on initial cytology.

Radioactive iodine-refractory (RAI) metastatic DTC presents a significant therapeutic challenge. While most patients with DTC have an excellent prognosis, 10 to 15% of patients will either present with or develop metastatic disease⁴ and two-thirds will progress to RAI-refractory disease.⁵ Historically, 10-year median survival rate is only 10% for RAI-refractory metastatic DTC due to poor response to cytotoxic chemotherapy, such as doxorubicin.⁴ However, improved understanding of the molecular pathways promoting growth and tumorigenesis in metastatic DTC has led to the development of multi-targeted TKIs, which offer a novel treatment option for patients with metastatic, rapidly progressive and/or symptomatic disease not amenable to local control.

In this case, pazopanib was the chosen TKI following results of a phase II trial published that year.⁶ Bible et al⁶ demonstrated that pazopanib was clinically efficacious in patients with RAI-refractory metastatic DTC, with partial response rates of 49 and a 66% likelihood of having responses lasting longer than 1 year. Since then, two TKIs have undergone phase III trials for RAI-refractory metastatic DTC and have US Food and Drug Administration (FDA) approval for this patient group. Sorafenib and lenvatinib were compared to placebo in the DECISION and SELECT trials respectively.^{7,8} Both the trials revealed promising results, with improved disease response rate and median progression-free survival (PFS) compared to placebo (sorafenib PFS 10.8 vs 5.8 months for placebo; lenvatinib PFS 18.3 vs 3.6 months for placebo).^{7,8} Importantly, the SELECT trial for lenvatinib included patients treated with one prior TKI and demonstrated a benefit in PFS survival in this subgroup.⁸ Median overall survival was not reached at the time of data cutoff for each agent and any difference compared to placebo may be affected by significant crossover. However, the potential adverse

effects of TKIs are substantial, including myelosuppression, severe cutaneous complications including hand-foot syndrome, hypertension, and secondary malignancies including squamous cell carcinoma. Adverse effects may necessitate dose reduction or treatment cessation. Accordingly, their use should be limited to patients with good performance status and those at significant risk of morbidity or mortality due to progressive disease.

To date, there is little evidence and no prospective studies investigating the efficacy of salvage therapy following 1st line TKI failure. Given the similarity of drug targets, cross-resistance and reduction or loss of efficacy may occur with sequential TKI therapy. However, retrospective studies have suggested that other TKIs are effective salvage therapies after 1st line TKI failure.⁹ Partial response occurred in 41% and stable disease in 59% of patients receiving salvage therapy with another TKI after sorafenib failure.⁹ The median overall survival and PFS were also significantly longer.⁹

Recent clinical trials have also assessed a novel application for TKIs in restoring radioiodine uptake and responsiveness in RAI-refractory metastatic DTC.⁵ The refractory disease is thought to occur through loss of sodium-iodide symporter expression due to aberrant activation of the mitogen-activated protein kinase (MAPK) pathway and/or Phosphatidylinositol-4,5-bisphosphate 3-kinase (PI3K)-protein kinase B (AKT)-mammalian target of rapamycin (mTOR) pathway.⁵ Selumetinib is a TKI that inhibits MEK1/2, a component of the MAPK pathway. A phase II trial demonstrated the ability of selumetinib to resensitize patients with RAI-refractory metastatic DTC to radioiodine therapy.¹⁰ Increased iodine uptake was observed in 60% of patients, with a subsequent 40% displaying sufficient uptake to receive a further dose of therapeutic RAI. During follow-up, there were partial responses in five patients and stable disease in three. Tumor genotype affected response, with the greatest efficacy in patients with NRAS-mutant tumors and least efficacy in those with BRAF-positive tumors. It was well tolerated and may have a favorable cost-benefit analysis as therapy is needed only for 4 weeks per cycle.

Our patient experienced significant morbidity due to a high burden of skeletal metastatic disease, notoriously resistant to treatment.¹¹ While bone metastases are frequently refractory to TKIs, lenvatinib achieved a reduction in the rate of progression of existing bone metastases⁸ and may represent a viable treatment option for extensive bone involvement. Although, there is a paucity of clinical trials exploring the efficacy of antiresorptive therapies in managing bone metastases from metastatic DTC, data from other solid tumors show that they delay time to 1st skeletal-related event [(SRE) which includes spinal cord compression, pathological fracture, need for

EBRT or surgery, and hypercalcemia of malignancy] and decreases the incidence of SREs.¹² Pamidronate and zoledronic acid are the most studied bisphosphonates for bone metastases in DTC; with monthly treatment shown to reduce SREs, delay the onset of 1st SRE, and improve bone pain and quality of life.^{13,14} Consideration needs to be made of the risks associated with long-term use of potent antiresorptives, such as osteonecrosis of the jaw and atypical subtrochanteric fractures, as patients with metastatic DTC usually have a longer disease course than those with other solid tumors. Recently, denosumab has been shown to reduce SREs compared to bisphosphonates in those with bone metastases from other solid tumors.¹⁵ However, there have been no studies addressing its use in metastatic thyroid cancer.

CONCLUSION

In summary, this complex case illustrates the challenges in managing radioiodine-refractory metastatic DTC with skeletal dominant metastases. The advent of TKIs as emerging frontline and salvage therapy is a novel addition to the future of thyroid cancer. Future studies expanding the role of sequential and redifferentiation therapy for advanced disease and strategies to reduce SREs are needed.

CLINICAL SIGNIFICANCE

This case highlights the challenges in the diagnosis of thyroid cancer, in particular the importance of accurate histological diagnosis and long-term clinical surveillance of apparently benign thyroid oncocytic tumors in those at high risk. We also review the management of radioiodine-refractory metastatic DTC focusing on the role of the novel TKIs.

REFERENCES

- Barnabei A, Ferretti E, Baldelli R, Procaccini A, Spriano G, Appetecchia M. Hurthle cell tumors of the thyroid. Personal experience and review of the literature. *Acta Otorhinolaryngol Ital* 2009 Dec;29(6):305-311.
- Asa SL. My approach to oncocytic tumors of the thyroid. *J Clin Pathol* 2004 Mar;57(3):225-232.
- Cannon J. The significance of Hurthle cells in thyroid disease. *Oncologist* 2011;16(10):1380-1387.
- O'Neill CJ, Oucharek J, Learoyd D, Sidhu SB. Standard and emerging therapies for metastatic differentiated thyroid cancer. *Oncologist* 2010;15(2):146-156.
- Spitzweg C, Bible KC, Hofbauer LC, Morris JC. Advanced radioiodine-refractory differentiated thyroid cancer: the sodium iodide symporter and other emerging therapeutic targets. *Lancet Diabetes Endocrinol* 2014 Oct;2(10):830-842.
- Bible KC, Suman VJ, Molina JR, Smallridge RC, Maples WJ, Menefee ME, Rubin J, Sideras K, Morris JC 3rd, McIver B, et al. Efficacy of pazopanib in progressive, radioiodine-refractory, metastatic differentiated thyroid cancers: results of a phase 2 consortium study. *Lancet Oncol* 2010 Oct;11(10):962-972.
- Brose MS, Nutting CM, Jarzab B, Elisei R, Siena S, Bastholt L, de la Fouchardiere C, Pacini F, Paschke R, Shong YK, et al. Sorafenib in radioactive iodine-refractory, locally advanced or metastatic differentiated thyroid cancer: a randomised, double-blind, phase 3 trial. *Lancet* 2014 Jul 26;384(9940):319-328.
- Schlumberger M, Tahara M, Wirth LJ, Robinson B, Brose MS, Elisei R, Habra MA, Newbold K, Shah MH, Hoff AO, et al. Lenvatinib versus placebo in radioiodine-refractory thyroid cancer. *N Engl J Med* 2015 Feb 12;372(7):621-630.
- Dadu R, Devine C, Hernandez M, Waguespack SG, Busaidy NL, Hu MI, Jimenez C, Habra MA, Sellin RV, Ying AK, et al. Role of salvage targeted therapy in differentiated thyroid cancer patients who failed first-line sorafenib. *J Clin Endocrinol Metab* 2014 Jun;99(6):2086-2094.
- Ho AL, Grewal RK, Leboeuf R, Sherman EJ, Pfister DG, Deandreis D, Pentlow KS, Zanzonico PB, Haque S, Gavane S, et al. Selumetinib-enhanced radioiodine uptake in advanced thyroid cancer. *N Engl J Med* 2013 Feb;368(7):623-632.
- Wexler JA. Approach to the thyroid cancer patient with bone metastases. *J Clin Endocrinol Metab* 2011 Aug;96(8):2296-2307.
- Farooki A, Leung V, Tala H, Tuttle RM. Skeletal-related events due to bone metastases from differentiated thyroid cancer. *J Clin Endocrinol Metab* 2012 Jul;97(7):2433-2439.
- Vitale G, Fonderico F, Martignetti A, Caraglia M, Ciccarella A, Nuzzo V, Abbruzzese A, Lupoli G. Pamidronate improves the quality of life and induces clinical remission of bone metastases in patients with thyroid cancer. *Br J Cancer* 2001 Jun;84(12):1586-1590.
- Orita Y, Sugitani I, Toda K, Manabe J, Fujimoto Y. Zoledronic acid in the treatment of bone metastases from differentiated thyroid carcinoma. *Thyroid* 2011 Jan;21(1):31-35.
- Fizazi K, Lipton A, Mariette X, Body JJ, Rahim Y, Gralow JR, Gao G, Wu L, Sohn W, Jun S. Randomized phase II trial of denosumab in patients with bone metastases from prostate cancer, breast cancer, or other neoplasms after intravenous bisphosphonates. *J Clin Oncol* 2009 Apr 1;27(10):1564-1571.