



Minerva Access is the Institutional Repository of The University of Melbourne

**Author/s:**

Rouse, M;Choi, J;Bakhit, J;Soh, B;Chan, S

**Title:**

Laparoscopic EndoClose fixation of a peritoneal catheter reduces migration

**Date:**

2020-01-01

**Citation:**

Rouse, M., Choi, J., Bakhit, J., Soh, B. & Chan, S. (2020). Laparoscopic EndoClose fixation of a peritoneal catheter reduces migration. ANZ Journal of Surgery, 90 (1-2), pp.72-75.  
<https://doi.org/10.1111/ans.15506>.

**Persistent Link:**

<https://hdl.handle.net/11343/286678>

Rouse Michael (Orcid ID: 0000-0001-6741-7562)  
BAKHIT JACQUELINE (Orcid ID: 0000-0002-5945-6745)

2

## Laparoscopic EndoClose Fixation of Peritoneal Catheter Reduces Migration

### Short Title: Reduced Peritoneal Catheter Migration

Michael Rouse MD<sup>1</sup>, Julian Choi MD<sup>1</sup>, Jacqueline Bakhit MBBS<sup>1</sup>, Brian Soh MBBS<sup>1</sup>, Steven Chan PhD, FRACS<sup>1,3</sup>

<sup>1</sup> Department of General Surgery, Western Health, Victoria, Melbourne. <sup>2</sup> Department of Nephrology, Western Health, Victoria, Melbourne. <sup>3</sup> Department of Surgery, University of Melbourne.

### Corresponding Author

Michael Rouse, [michaelmrouse@gmail.com](mailto:michaelmrouse@gmail.com), Department of Surgery, Western Health, 160 Gordon St, Footscray, Victoria 3011. Ph: +61413074908 Fax: +613 83456885

Two tables and two figures included

Abstract word count: 246

Text word count: 1496

This is the author manuscript accepted for publication and has undergone full peer review but has not been through the copyediting, typesetting, pagination and proofreading process, which may lead to differences between this version and the [Version of Record](#). Please cite this article as doi: [10.1111/ans.15506](https://doi.org/10.1111/ans.15506)

**ABSTRACT**

## Background:

With the introduction of laparoscopic Tenckhoff catheter insertion in the early 1990s, catheter malposition resulting in malfunction remains a frequent complication, often requiring surgical or radiological intervention. In this pioneer study, we describe the technique of suturing the Tenckhoff catheter using an EndoClose™ device to the anterior abdominal wall during laparoscopic insertion and compare its outcomes with those not sutured.

## Methods:

This is a retrospective study of all patients who underwent laparoscopic Tenckhoff catheter insertion at Western Health from January 2013 to June 2018. All procedures were undertaken or supervised by one surgeon. The primary outcome was catheter malposition requiring surgical revision. Secondary outcomes were time to malposition and complications. Peri and post-operative factors were analysed to adjust for confounders using the Cochran-Mantel-Haenszel (CMH) test.

## Results:

There were 82 patients in the sutured group and 63 patients in the non-sutured group. Catheter malposition occurred in 7.32% in the sutured group and 19.05% in the non-sutured group ( $p = 0.034$ ; 95% confidence interval for the difference was 0.007 to 0.237). There was an overall reduction in the odds of catheter malposition of 63% in favour of the sutured group. The median time-to-malposition was 128 and 182 days for the non-sutured and sutured group respectively but not statistically different. No differences were found for the number of post-operative complications.

## Conclusion:

Suturing of Tenckhoff catheter with an EndoClose device to the anterior abdominal wall during laparoscopic insertion is a simple, safe and useful method of reducing catheter malposition.

Word Count: 246

## **Introduction**

Peritoneal Dialysis (PD) is a method of renal replacement utilised in patients with chronic kidney disease. For patients, PD offers greater independence, technically easier and lower cost (<sup>1</sup>). Both open and laparoscopic have been utilised to insert the Tenckhoff catheter to use for PD(<sup>2</sup>). Since the commencement of laparoscopic insertion, conflicting literature exists as to the safest procedure that minimises risks of catheter malfunction (obstruction/migration), peritonitis, bleeding, pain and improving recovery time(<sup>1, 3-5</sup>). Qiao et al (<sup>4</sup>) performed a systematic review in 2016 when comparing open technique versus laparoscopic technique. This found the laparoscopic technique to be superior in reducing catheter migration and prolonging catheter survival. Similarly, Hagen et al (<sup>5</sup>) in 2013 performed a systematic review which found that laparoscopic approach when compared with the open approach can reduce catheter migration and 1 year survival. However, these systematic reviews do not compare laparoscopic techniques that may or may not include abdominal wall fixation. Shen et al (<sup>6</sup>) in 2017 performed an analysis on 39 consecutive patients using abdominal wall fixation with a suture passer hernia forceps which found 100% catheter survival at 6 months with no exit site infections, post-operative bleeding or abdominal wall hernias. Other studies also utilise techniques that involve rectus sheath tunnelling or omentopexy (<sup>1, 7, 8</sup>) which reveal improved catheter survival in comparison to open technique. In this study, we sought to assess our laparoscopic technique outcomes in patients with abdominal wall fixation, compared to those without abdominal wall fixation.

## **Methods**

All consecutive peritoneal dialysis catheter insertions at Western Health between January 2013 to June 2018 were included in this study. From June 2015 to June 2018, prospective data were collected on consecutive patients with EndoClose sutured (S) Tenckhoff catheter placement. The data were compared with those from a retrospective review of catheter placement without suture (NS) done in January 2013 to May 2015. Patients were placed into sutured (S) and non-sutured (NS) groups. The primary outcome was catheter malposition requiring surgical revision. Secondary outcomes included the time to malposition and complications. Peri-operative factors (gender, age, body mass index (BMI), previous abdominal surgery and operative duration) and post-operative factors (bleeding, exit-site infection and peritoneal dialysis related peritonitis) were analysed. Ethical approval was obtained at Western health QA2017.02.

### Surgical Technique

The patient is placed in a supine, prepped and draped in a routine fashion using an alcoholic preparation and loban. A dose of prophylactic antibiotic and deep vein thrombosis prophylaxis are given at induction. An infra-umbilical Hasson port is inserted through an open technique. Pneumo-peritoneum is achieved using CO<sub>2</sub> with 12mmHg pressure. A 5mm port is inserted into the right iliac fossa, 13cm from the pubic symphysis. A second 5mm port is positioned in the left iliac fossa. The pigtail, 15cm peritoneal dialysis catheter is introduced through the Hasson port and positioned well into the pelvis. The tubing of the PD catheter is facing the left side of the pelvis to ensure the rest of the tubing is in its natural curved lie. The PD catheter is then pulled through the right iliac fossa port and its first cuff is positioned just superficial to the peritoneal surface. The catheter is then tunnelled inferolaterally to bury the second cuff. The PD catheter is fixed to the anterior abdominal wall in the midline, one third from the pubic symphysis to umbilicus using 2/0 Prolene suture with an EndoClose™ device. This ensures fixation of the PD catheter and easy removal of the catheter without need for further laparoscopy. The catheter is then flushed with normal saline to confirm free flow of fluid in and out of the PD catheter.

## Statistical analysis

A minimum sample size of 125 patients was calculated to achieve a power of 80% (2-sided alpha of 0.05) in a test of superiority between two binomial proportions. For univariate analysis, difference in binomial proportions between NS and S groups were performed using exact test. Continuous data were analysed using the Mann-Whitney-U statistics. To produce a combined odds ratio to adjust for pre/peri-operative and post-operative factors, the Cochran-Mantel-Haenszel (CMH) test was used and graphically presented as a Forest plot. All analyses were undertaken with StatsDirect™ (UK).

## Results

A total of 145 patients (54 females and 91 males) were included in this study. The median follow-up period was 15.5 months (inter-quartile range (IQR) 8.7 to 25.6). Sixty-three patients were included in the non-sutured group and 82 were included into the EndoClose™ sutured group. The median age was 61 years (IQR 48.75 to 71.25). Patient demographics are shown in Table 1. There was a shorter operative time favouring the non-sutured group.

Tenckhoff catheter malposition was identified in 12/63 (19.05%) of patients in the NS group versus 6/82 (7.32%) in the S group (95% confidence interval (CI) for the difference 0.007 to 0.237,  $P = 0.034$ ) (Table 2).

Figure 1: A Forest plot illustrates the odds ratio adjusted for peri- and post-operative factors and their effects on catheter malposition. A combined odds ratio of 0.37 was found in favour of the sutured group with an overall reduction in the odds of catheter malposition of 63%.

Figure 2 shows a Kaplan-Meier plot for comparing the median time-to-malposition of the sutured and non-sutured groups. There was a 54 days' difference in favour of the sutured group but not statistically different (logrank test  $P = 0.86$ ).

## Discussion

Analysis revealed a statistically significant difference in malposition between the non-sutured and sutured groups for our laparoscopic technique. After adjusting for peri-and post-operative factors, a combined odds ratio of 0.37 implies an overall reduction in the odds of catheter malposition of 63% in favour of the sutured group (Figure 1). The difference in migration is thought to be due to significantly lower likelihood of catheter movement within the pelvis. The technique that has been described above utilises the attributes of the pigtail peritoneal dialysis catheter to its maximal potential. Specifically positioning the right iliac fossa port 13cm from the pubic symphysis allows for optimal positioning within the pelvis, combined with positioning the tail of the catheter pointing to the left pelvis. Shen et al <sup>(6)</sup> also evaluated their experience in 39 patients undergoing PD insertion using a similar technique which demonstrated 100% catheter-related complication-free survival. However, the sample size of their study limits definite conclusions. Other techniques have been utilised in laparoscopic surgery to secure the Tenckhoff catheter, such as rectus sheath tunnelling and selective omentopexy<sup>(7)</sup>. However, these techniques have never been compared to evaluate the more superior technique.

To our knowledge this is the first study detailing the use of the EndoClose device in fixation of the PD catheter that reveals a reduction in migration. With this technique, removal of PD catheters requires local anaesthetic +/- sedation, which reduces the risk of risks associated with general anaesthetic.

Analysis of the median-time-to malposition showed a 54 days' difference (Figure 2) in favour of the sutured group; statistical significance was not achieved as sample size calculations were not powered sufficiently for this secondary outcome measure.

It could be argued that a limitation of this study is the comparative analysis of a prospectively collected data with a retrospective review data. However Table 1 showed stability of outcome over the two study epochs. Furthermore, all peri- and operative managements were under the control of one surgeon.

### **Conclusion**

Suturing of the Tenckhoff catheter to the anterior abdominal wall during laparoscopic insertion has been shown to be a simple, safe and useful method of reducing catheter malposition. This technique is now routinely used in our institution.

### **Disclosure**

The authors have no disclosures, financial or support from any company.

### **References**

1. Bae IE, Chung WK, Choi ST, Kang J. Laparoscopic internal fixation is a viable alternative option for continuous ambulatory peritoneal dialysis catheter insertion. *Journal of the Korean Surgical Society*. 2012; **83**: 381-7.
2. Soontrapornchai P, Simapatanapong T. Comparison of open and laparoscopic secure placement of peritoneal dialysis catheters. *Surgical Endoscopy And Other Interventional Techniques*. 2005; **19**:137-9.
3. Cox TB, LJ Huntington CR, Prasad T. Laparoscopic versus open peritoneal dialysis catheter placement. *Surgical Endoscopy*. 2016; **30**: 899-905.

4. Qiao Q, Zhou L, Hu K, Xu D, Li L, Lu G. Laparoscopic versus traditional peritoneal dialysis catheter insertion: a meta analysis. *Renal Failure*. 2016; **38**: 838-48.
5. Hagen SML, Steyerberg JA, Ijzermans EW, Dor JM. Laparoscopic versus Open Peritoneal Dialysis Catheter Insertion: A Meta-analysis. *PLoS One*. 2013; **8**: e56531.
6. Shen Q, Jiang X, Shen X, Yu F, Tu Q, Chen W, Ye Q, Behera TR, He Q.. Modified laparoscopic placement of peritoneal dialysis catheter with intra-abdominal fixation. *Int Urol Nephrol*. 2017; **49**: 1481-8.
7. Krezalek MA, Bonamici N, Lapin B, Carbray J, Velasco J, Denham W, Linn J, Ujiki M, Haggerty SP. Laparoscopic peritoneal dialysis catheter insertion using rectus sheath tunnel and selective omentopexy significantly reduces catheter dysfunction and increases peritoneal dialysis longevity. *Surgery*. 2016; **140**: 924-35.
8. Ko J, Ra W, Bae T, Lee T, Kim HH, Han HS. Two-port laparoscopic placement of a peritoneal dialysis catheter with abdominal wall fixation. *Surgery Today*. 2009; **39**:356-8.

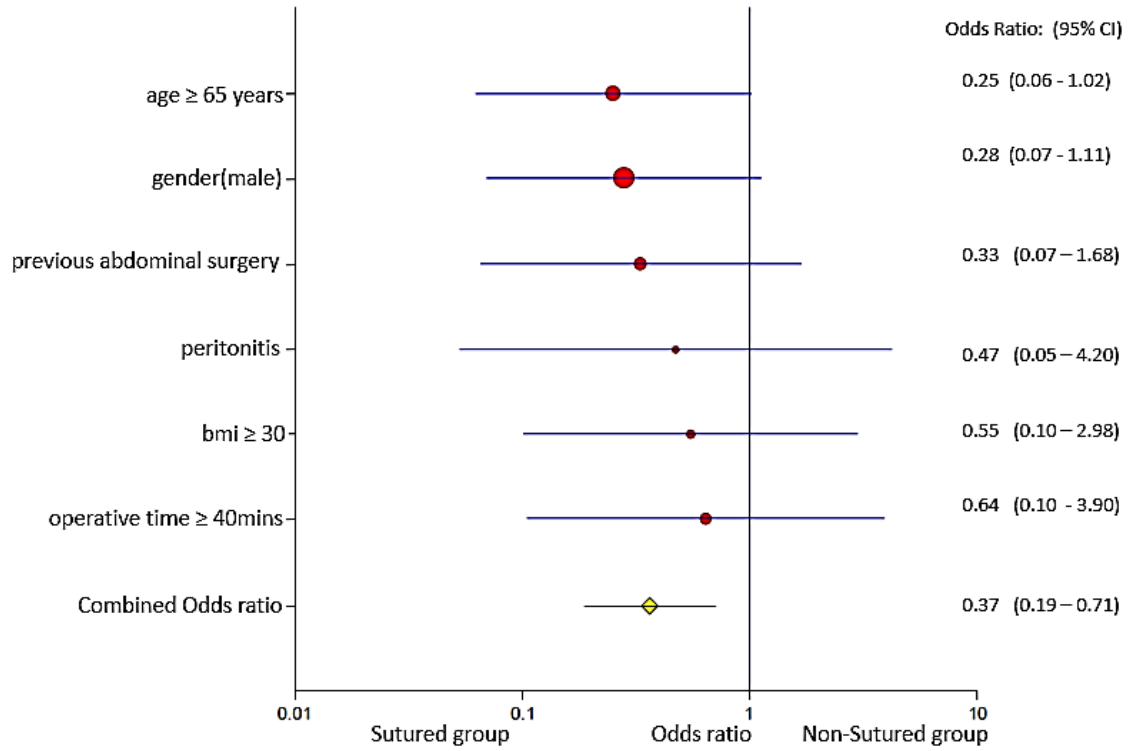
**Figure 1**

Forest plot outlining Odds Ratio of Sutured group vs Non-Sutured group with respect to catheter malposition

**Figure 2**

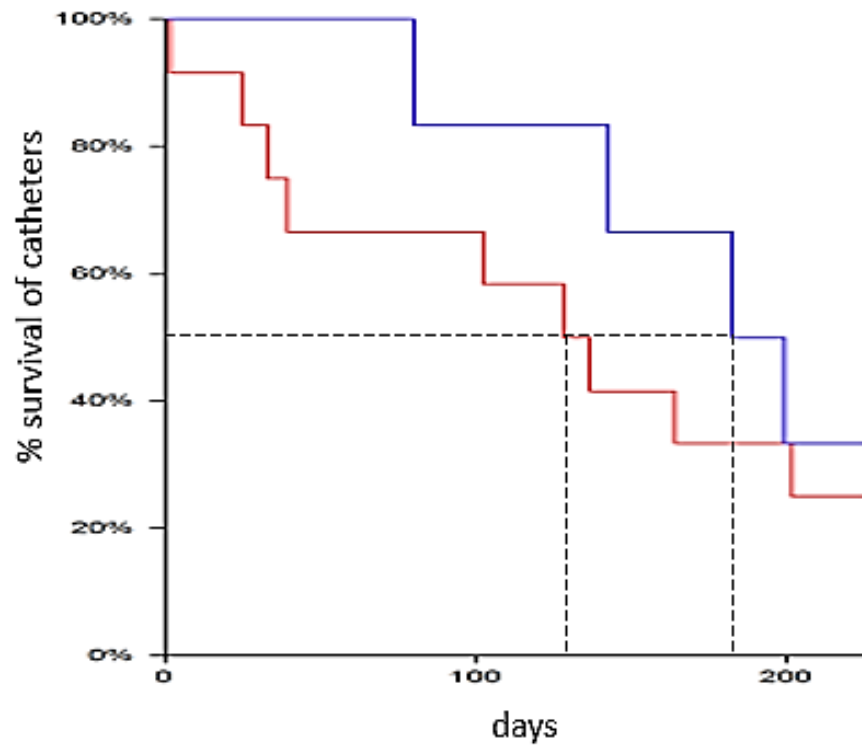
Kaplan-Meier plot for time to catheter malposition between Sutured and Non-Sutured groups.  $p = 0.86$

**Figure 1** Forest plot of Sutured group vs Non-Sutured group: effect on catheter malposition



BMI: body mass index; 95% CI: 95% Confidence Interval

Figure 2 Kaplan-Meier plot of median time-to-malposition



Number at risk

NS	12	8	4
S	6	5	2

Logrank test:  $\chi^2$  0.03 df=1 P = 0.86

Median time-to-malposition: — 128 days; — 182 days

----- median time-to-malposition

**Table 1:** Characteristics of Non-sutured (NS) and sutured (S) groups (N = 145)

Characteristic	NS: n=63	S: n=82	p value
gender (F:M) <sup>¥</sup>	25:38	29:53	0.61
age (years) <sup>†</sup>	62 (IQR 50.25-72.75)	61 (IQR 45-70)	0.37
body mass index <sup>†</sup>	27 (IQR 23.45-29.45)	27.6 (IQR-23.80-30.10)	0.38
past abdominal surgery <sup>¥</sup>	29% (18/63)	33% (27/82)	0.59
operative time (min) <sup>†</sup>	34 (IQR 30.00-38.75)	36 (IQR 32.00-41.00)	0.03*
exit-site infection <sup>¥</sup>	3.17% (2 cases)	0%	0.11
bleeding <sup>¥</sup>	3.17% (2/63)	1.22% (1/82)	0.56
peritonitis <sup>¥</sup>	28.57% (18/63)	18.29 (15/82)	0.16

¥ differences in binomial proportions; † Mann-Whitney-U statistics; IQR inter-quartile range;

\* significant difference

**Table 2:** Tenckhoff catheter malposition: Sutured (S) versus Non-Sutured (NS)<sup>†</sup>

Malposition	Yes	No	Total
S	6	76	82
NS	12	51	63
Total	18	127	145

<sup>†</sup> absolute numbers

Difference 11.7%; 95% CI for the difference: 0.007 - 0.237; P = 0.034