

Manor Emily (Orcid ID: 0000-0002-5233-0007)

Title:

Prior joint disease is associated with increased risk of periarticular histiocytic sarcoma in dogs

Running Title:

Joint disease and canine histiocytic sarcoma

Authors:

E.K. Manor¹ L.E. Craig² X. Sun³ C. Cannon⁴

1. Department of Small Animal Clinical Sciences, University of Tennessee, Knoxville, TN
2. Department of Biomedical and Diagnostic Sciences, University of Tennessee, Knoxville, TN
3. Office of Information Technology, University of Tennessee, Knoxville, TN
4. Department of Veterinary Clinical Sciences, University of Minnesota, St. Paul, MN

Correspondence Address:

Emily Manor

University of Tennessee College of Veterinary Medicine

Department of Small Animal Clinical Sciences

2407 River Drive

Knoxville, TN 37996 USA

Email: ebeiting@utk.edu

This is the author manuscript accepted for publication and has undergone full peer review but has not been through the copyediting, typesetting, pagination and proofreading process, which may lead to differences between this version and the [Version of Record](#). Please cite this article as doi: [10.1111/vco.12338](https://doi.org/10.1111/vco.12338)

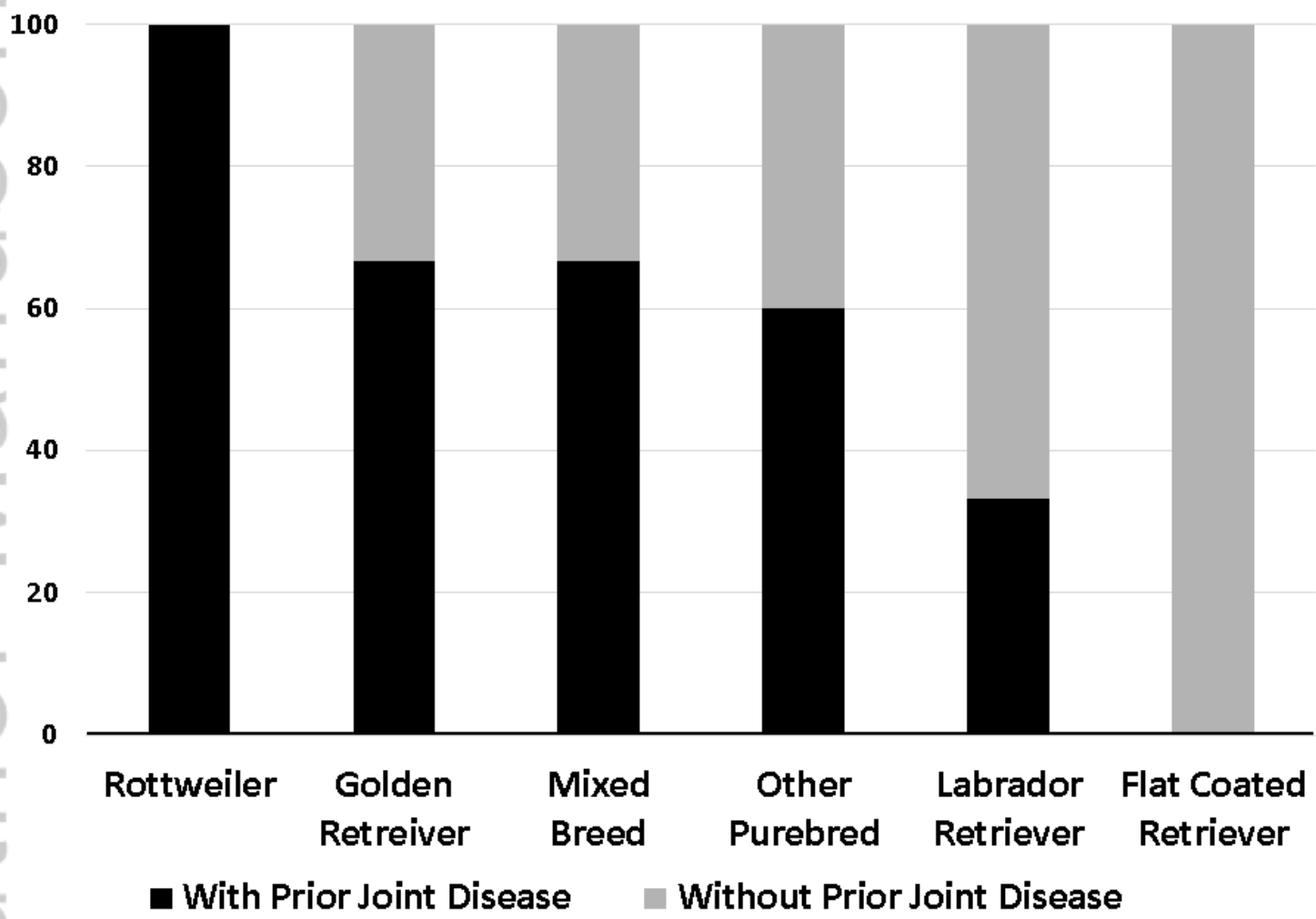


Figure 1 (1).tif

Title:

Prior joint disease is associated with increased risk of periarticular histiocytic sarcoma in dogs

Running Title:

Joint disease and canine histiocytic sarcoma

Authors:

E.K. Manor¹ L.E. Craig² X. Sun³ C. Cannon⁴

1. Department of Small Animal Clinical Sciences, University of Tennessee, Knoxville, TN
2. Department of Biomedical and Diagnostic Sciences, University of Tennessee, Knoxville, TN
3. Office of Information Technology, University of Tennessee, Knoxville, TN
4. Department of Veterinary Clinical Sciences, University of Minnesota, St. Paul, MN

Correspondence Address:

Emily Manor

University of Tennessee College of Veterinary Medicine

Department of Small Animal Clinical Sciences

2407 River Drive

Knoxville, TN 37996 USA

Email: ebeiting@utk.edu

Abstract:

Periarticular histiocytic sarcoma (PAHS) is the most common synovial tumor in dogs and is characterized by aggressive local disease with a high rate of distant metastasis. Previously, an association between PAHS and prior joint disease has been demonstrated in the Bernese Mountain Dog breed and suggested in the Rottweiler. We hypothesized that this association would be present in other breeds and investigated this via a retrospective, case-controlled analysis. Cases were dogs diagnosed with PAHS of the stifle or elbow. Controls were age, breed and sex-matched dogs without a diagnosis of histiocytic sarcoma. Diagnosis of prior joint disease was determined based on review of medical records and direct veterinarian and owner communications. Data were evaluated using logistic regression, two-sampled t-tests, and chi-squared analysis. Our study population consisted of 28 cases and 46 controls, including Flat-Coated, Golden and Labrador Retrievers, Rottweilers, English Bulldogs, Shih Tzus, Australian Shepherds, Staffordshire Terriers, and mixed breed dogs. Dogs with PAHS were more likely to have prior joint disease in the tumor-affected joint compared to the control population (OR = 13.42, $p < 0.0001$, 95% CI = 4.33-48.63). 88.2% of dogs with stifle PAHS had prior joint disease in their tumor-affected joint, most commonly cranial cruciate ligament rupture. This study confirms that the previously noted association between prior joint disease and PAHS in Bernese Mountain Dogs also applies to other breeds. Additional studies are needed to further investigate for a causal relationship.

Introduction:

Canine histiocytic sarcoma (HS) is a malignant neoplasm of dendritic cell or macrophage origin¹⁻³ and can be divided into localized, disseminated, and hemophagocytic variants based on biological behavior. Localized HS has been reported to occur in a variety of tissues including liver, spleen, lungs, eyes, CNS, and skin.^{4,5} Periarticular tissues are a frequent location for development of HS⁶ and it has been suggested that this form of the disease may follow a more indolent course than other types of HS.⁷ Periarticular histiocytic sarcoma (PAHS) was determined to be the most common canine joint tumor by Craig et al, and can be difficult to differentiate from other joint tumors using cytology or histopathology alone.⁸

Breed predispositions to HS have been reported in the Bernese Mountain Dog, Flat Coated Retriever and Rottweiler⁹⁻¹³ and there is an inherited risk in Bernese Mountain Dogs, suggesting the possibility of genetic risk factors. Other investigated potential risk factors for HS in dogs include environmental exposures, previous medical history, and prior orthopedic disease.^{14,15} In a retrospective study of Bernese Mountain Dogs, orthopedic disease was determined to be a predisposing factor associated with the development of HS. Dogs with prior orthopedic disease were 2.5 times more likely to develop HS than those without. Interestingly, dogs in the same study treated with prescription anti-inflammatory medications were at a lower risk for development of HS.¹⁴ In another study, Bernese Mountain Dogs were found to be 5.4 times more likely to develop PAHS in a previously diseased joint compared to a healthy joint.¹⁵ An association in Rottweilers between prior joint disease and PAHS was suggested by Craig et al; 62% of Rottweilers with PAHS of the stifle were found to have previous cranial cruciate ligament rupture in the tumor-affected joint.⁸ There are also individual reports in dogs of other breeds (Flat Coated Retriever, Golden Retriever) developing PAHS in a previously diseased joint.^{16,17}

The purpose of this study was to determine if the association between joint disease and PAHS identified in the Bernese Mountain Dog is also present in dogs of other breeds, which may or may not be otherwise predisposed to HS. We hypothesized that dogs with PAHS would be more likely to have had prior joint disease compared to a control population. Secondary objectives were to describe the types of joint disease associated with development of HS and characterize the time between diagnosis of joint disease and PAHS.

Materials and Methods:

Medical records of patients presenting to the University of Tennessee (UT) and the University of Minnesota (UMN) Veterinary Medical Centers and histopathology submissions to the UT Anatomic Pathology Diagnostic Laboratory between January 2001 and July 2014 were evaluated for a diagnosis of HS affecting the stifle or elbow. Patients with a definitive or probable diagnosis of HS, based on cytology or histopathology (+/- CD18 immunohistochemistry), were initially included. For patients with a 'probable' diagnosis, tissue was reviewed by a single board certified veterinary pathologist (LC) and CD18 immunohistochemistry was performed. Cases that were considered "probable" and did not have tissue available for review and cases with only a cytologic diagnosis available were excluded. All included cases ultimately had a definitive diagnosis of PAHS based on histopathology +/- CD18. We included dogs with PAHS affecting the elbow or stifle only, since these are the most common locations of PAHS⁵ and are also common locations of specific orthopedic diseases in dogs, including cruciate disease and elbow dysplasia. "Osteoarthritis" and "degenerative joint disease" were excluded as prior diagnoses since these are prevalent in the adult and elderly canine population,¹⁸ are frequently underdiagnosed,¹⁹ and because diagnosis can be difficult.^{20, 21} Given that there are recognized differences in underlying etiology between common orthopedic diseases affecting the stifle and elbow, (i.e. degenerative and

inflammatory changes leading to cruciate disease and joint incongruity leading to elbow dysplasia and secondary inflammation),^{22, 23} we were also interested to see if there was a difference in joint disease-PAHS association between these different sites.

Control patients were identified, with the aim of finding two controls for each case to maximize statistical power. Records of patients who presented to UMN or UT between January 2001 and July 2014 with presenting complaints other than HS were evaluated to find age, breed, and sex matched controls. The population of dogs presenting through the community practice service for vaccines or wellness exams was initially searched for controls. If appropriately matched controls were not identified in this population, the search was expanded to dogs presenting for other reasons including dermatologic disease, ocular abnormalities, or lymphoma. PAHS cases presenting to UMN were matched to controls presenting through UMN and PAHS cases presenting to UT or with pathology submissions through UT were matched to controls from UT. When more than two perfectly matched controls were identified, the patients presenting in the same year as the case and with the lowest medical record numbers were used as the controls. When an exact age-matched control could not be identified, the control patient closest in age to the case (starting with 1 year older) was selected. In the rare instance an intact male or female dog of the same age and breed as the case could not be identified, a spayed or neutered dog of the same sex, breed, and age (+/- one year) was used as the control.

Additional information was obtained for both cases and controls via review of medical records sent from referring veterinarians and phone/email communications with owners. Data collected included signalment, weight at time of diagnosis, presence and type of previous joint disease (including method of diagnosis and surgical treatment, when applicable), and date of PAHS and joint disease diagnoses. Patients were considered to have prior joint disease if they had a specific diagnosis of prior joint surgery, joint injury (including fracture, ligament rupture, and

trauma with joint swelling), joint incongruity or dysplastic change diagnosed on imaging or necropsy, or joint inflammation (including immune mediated polyarthritis and septic arthritis). For cases with both joint disease and PAHS, time interval between the two diagnoses was calculated. Patients with an unknown exact date of joint disease onset were excluded from this calculation. Dogs were excluded from both case and control groups when their complete medical records were unavailable, when contact with the owner was not possible, or when owners had incomplete recollection of medical history.

Univariable logistic regression models were constructed to examine the relationship between prior joint disease and PAHS within the entire population as well as the stifle and elbow groups separately. The associations between patient demographics and tumor status were evaluated using Fisher's exact tests (for categorical variables breed and sex) or two-sample t tests (for numeric variables age and weight) to ensure there were not significant differences between the PAHS and control groups. Significance was identified at $p < 0.05$. Data analysis was conducted in JMP Pro 12/01 for Windows from SAS Institute Inc. (Cary, NC).

Results:

After exclusion of patients with incomplete medical records (13), 34 dogs with PAHS remained. Three cases with only a cytologic diagnosis were excluded, and three additional cases with a "probable" diagnosis of PAHS were excluded because they did not have tissue available for pathology review, leaving 28 cases. Breeds included were Golden Retriever (6), Rottweiler (6), Labrador Retriever (6), Flat Coat Retriever (2), Mixed Breed Dog (3), English Bulldog (2), and one each of Australian Shepherd, Shih Tzu, and Staffordshire Terrier. Median age at the time of PAHS diagnosis was eight years (range 4-16 years) and the median weight was 34.5 kilograms. There were 14 males (2 intact, 12 neutered) and 14 females (1 intact, 13 spayed).

46 age, breed, and sex matched controls were identified. The majority of control patients presented for annual wellness exams or vaccines. Other reasons for presentation included lymphoma, dermatologic conditions, or ocular abnormalities. Median age in the control group was eight years (range 4-17 years) and the median weight was 29.8 kilograms. There were 23 males (4 intact, 19 neutered) and 23 females (all spayed). Patient demographics (sex and breed distribution, age, and weight) were compared between the PAHS and control groups. There were no statistically significant differences (Table 1).

All cases were diagnosed by histopathology and CD18 was used to confirm the diagnosis in all but two of the cases. 17/28 (60.1%) cases were confirmed to have previous joint disease in the tumor-affected joint. In comparison, 5/46 (10.9%) of the control patients had previously diagnosed joint disease. The odds of having prior joint disease in the tumor-affected joint were 13.42 times greater in cases than in controls (95% CI= 4.33-48.63, $p < 0.0001$). The most common type of previous joint disease was cranial cruciate ligament rupture, followed by various forms of elbow dysplasia and patellar luxation. Other diagnoses included immune mediated polyarthritis, trauma/fracture, and septic arthritis (Table 2). The median interval between joint disease diagnosis and PAHS diagnosis was 2.1 years (range two months-four years). When breeds were evaluated separately, incidence of prior joint disease varied, but was especially common in the Rottweiler breed: 6/6 (100%) Rottweilers were confirmed to have previous disease in their tumor-affected joint (Figure 1).

2/11 (18.2%) dogs with elbow PAHS and 15/17 (88.2%) dogs with stifle PAHS were diagnosed with previous joint disease in the tumor-affected joint. The association between PAHS and prior joint disease was significant for the stifle (OR = 64.00, 95% CI: 11.72-578.32, $p < 0.0001$) but not for the elbow (OR = 1.89, 95% CI: 0.20-18.01, $p = 0.27$) (Table 2).

Discussion:

Dogs in this study with PAHS were more likely to have had prior joint disease in their tumor-affected joint when compared to the control population. The odds ratio of 13.42 (95% CI= 4.33-48.63, $p < 0.0001$) suggests there is a strong relationship between joint disease and development of PAHS; the existence of this association has been demonstrated previously in Bernese Mountain Dogs^{14, 15} and this study confirms the relationship exists in dogs of other breeds as well. Not all of the breeds reported in the current study have been previously suggested to be predisposed to HS. Bernese Mountain Dogs were not specifically excluded from this study, and it is interesting that none met the inclusion criteria during the study timeframe. Between the two sites, there were 19 Bernese Mountain Dogs diagnosed with suspected or confirmed histiocytic sarcoma, but none with confirmed PAHS affecting the stifle or elbow. In most of these cases, the disease was visceral and/or disseminated, with localized HS affecting the subcutis or lung in 6 cases. Localized histiocytic sarcoma, including PAHS, may be less common than disseminated disease in the Bernese Mountain Dog;²⁴ the fact that no PAHS cases were confirmed in this breed in our study may reflect this. In another study comparing dogs with PAHS versus other locations of HS, 1/19 dogs with PAHS (5%) were Bernese Mountain Dogs, compared with 4/31 with non-PAHS (13%),⁷ and with greater numbers over a longer study period, it is likely we would have identified Bernese Mountain Dogs with PAHS.

Though a causal relationship between prior joint disease and the development of HS cannot be concluded from findings of this study alone, we suggest that inflammation associated with joint disease may contribute to PAHS development. It is now well-established that inflammation is a risk factor for cancer in humans.²⁵ Dogs with previous cruciate disease, degenerative joint

disease, and rheumatoid arthritis have been shown to have an increased number of antigen presenting cells in their synovial membranes^{26, 27} and it has been demonstrated that dogs with cruciate rupture have ongoing synovitis and osteoarthritis, even after surgical repair.²⁸⁻³⁰ While the etiology of cruciate disease is likely multifactorial and is poorly understood, inflammation has been suggested as a predisposing factor³¹ and synovitis has been recognized early in the course of cruciate rupture, prior to clinically detectable joint instability.³² It is possible that synovitis, causing release of inflammatory mediators, leads to degradation of the cruciate ligament and predisposes patients to pathologic rupture. Inflammation could therefore predispose to both cruciate rupture and PAHS. A recent report by Ruple et al demonstrated Bernese Mountain Dogs receiving prescription anti-inflammatory medications had a lower risk of HS development, suggesting that inflammation may play a role in HS development in this breed.¹⁴ How the known genetic risk for HS in the Bernese Mountain Dog impacts the effect of inflammation in promoting HS development is not yet known. Further prospective study of the effect of inflammation on HS development in dogs without a genetic predisposition may help to elucidate the roles of genetics versus inflammation and studies of chemoprevention in dogs at risk for HS may help to determine whether inflammation represents a modifiable risk factor.

When separated by joint, the odds of having had prior joint disease were 64 times greater for dogs with PAHS of the stifle compared to controls, but the association was not significant in the elbow group. It is possible that the different etiologies underlying stifle disease and elbow disease contributed to this finding. Most of the dogs in this study with stifle disease had cruciate ligament rupture, while the most common elbow disease diagnosis was some form of elbow dysplasia. Elbow dysplasia is related to joint incongruity and is generally regarded as genetic or developmental in etiology.²³ Inflammation as a driving factor for joint disease may be more prevalent in dogs with stifle disease compared to elbow disease, leading to the stronger association with PAHS observed in the stifle group. The relatively small number of dogs with

prior diagnoses other than cruciate disease prevented accurate evaluation of the association between PAHS and specific types of prior joint disease. However, the difference when entire elbow and stifle groups were compared, and the known differences in etiologies of common joint diseases between these two locations, suggests that the underlying etiology of the joint disease may affect PAHS risk.

In our study, we did not find a significant association between prior joint disease and PAHS affecting the elbow, in contrast to previous studies in Bernese Mountain Dogs.¹⁵ It is possible that the lack of significant association in the elbow group was exaggerated by difficulty in diagnosing elbow disease. Four dogs in this study were diagnosed with cruciate rupture based on physical exam alone. Since specific diagnosis of elbow disease tends to require imaging, often advanced imaging or arthroscopy,³³⁻³⁵ it is likely there were additional dogs with elbow disease that were undiagnosed. Three dogs in the elbow group had limping in their tumor-affected limb, noted in the medical record or described by the owner, starting at least one year prior to PAHS diagnosis. These dogs were presumed to have OA and additional diagnostics were not performed. Since these patients did not have a specific joint disease diagnosis, they were not considered to have prior joint disease. If there is a true association between PAHS and prior elbow disease that is not as strong as that in the stifle joint, we may not have been able to detect it in our study (type II error), and evaluating larger numbers of dogs may find an association. Alternatively, it may be that the known genetic predisposition in Bernese Mountain Dogs influenced the association between joint disease in general and PAHS in that breed.¹⁵

When breeds were evaluated separately, there were subjective differences between the incidences of prior joint disease. Rottweilers were especially likely to have prior joint disease (100%). It is possible the etiology of PAHS may vary between breeds of dogs. For example, some breeds, including the Rottweiler, may be predisposed to PAHS because they are

predisposed to underlying joint disease.³⁶ In other breeds, including the Flat Coat Retriever and Bernese Mountain Dog, with known genetic predispositions to HS,¹³ the etiology of PAHS may be more hereditary in nature. The population in this study was too small to accurately investigate differences in etiology of PAHS between breeds.

This study has several limitations. Its retrospective nature precluded standardized methods of diagnosis and follow up for most patients, and results are limited by a small study population, especially in the elbow PAHS group. Four PAHS patients were diagnosed with joint disease at the time of tumor diagnosis or at the time of necropsy. These include two dogs diagnosed with joint disease (one patient with elbow dysplasia, and one patient with both patellar luxation and cruciate rupture) on radiographs at the time of presentation for PAHS, one patient with a cruciate rupture diagnosed on physical exam at the time of tumor diagnosis, and one patient found to have a chronic cruciate rupture on necropsy following PAHS diagnosis. Elbow dysplasia and patellar luxation are believed to be largely congenital or developmental in nature^{23, 37} and were therefore assumed to be true prior joint disease, occurring before development of PAHS in these two patients. For the dogs diagnosed with PAHS and cruciate rupture concurrently, it is more difficult to prove their cruciate rupture occurred first. The patient diagnosed on necropsy was described to have osteophytes and eburnation of the femoral condyles, suggesting chronicity of joint instability. The patient diagnosed with cruciate rupture on physical exam had been limping in the tumor-affected leg for two years prior to PAHS diagnosis, also suggesting chronic joint disease. While unlikely to significantly alter findings, it is also possible that diagnosis of prior joint disease was missed in a small number of control patients if their potential joint disease never became significant enough to warrant specific diagnostics or necropsies were not performed. The selection of the control group from patients presenting for wellness exams, dermatologic or ophthalmologic disease, or lymphoma was done in an attempt not to bias towards dogs with a history of prior joint disease. However, this may

have resulted in a bias *against* dogs with a history of prior joint disease, since we did not include dogs referred to the surgery services for orthopedic disease specifically. The magnitude of this potential overestimation is unknown, but results should be interpreted with this in mind.

In a previous study by Klahn et al, PAHS was described to have a prolonged duration of clinical signs compared to other forms of HS; a mean time to diagnosis from onset of clinical signs was 126 days for dogs with PAHS compared to 30 days for dogs with other forms of HS.⁷ It is likely that many dogs with PAHS are initially misdiagnosed or presumed to have osteoarthritis or degenerative joint changes, given the comparatively slow progression of signs associated with PAHS. The patients in the present study were only considered to have prior joint disease when imaging or findings at physical exam or surgery confirmed a specific diagnosis. “Osteoarthritis” and “degenerative joint disease” were excluded as prior joint disease diagnoses in hopes of eliminating patients who truly had undiagnosed PAHS as a cause of their lameness. The median time from joint disease diagnosis to PAHS diagnosis was 2.1 years, but two patients were diagnosed with their joint disease within 6 months of PAHS diagnosis. Both were dogs diagnosed with cruciate ruptures based only on cranial drawer found on physical exam. While it would be unlikely to significantly affect the results, it is possible these patients were misdiagnosed with cruciate ruptures and their lameness was, in fact, related to PAHS instead. It is also possible that PAHS could lead to inflammation within the joint, actually causing cruciate rupture secondary to the tumor.

Obesity is a known predisposing factor for joint disease including cruciate rupture¹⁹ and has been reported as a risk factor for canine transitional cell carcinoma,³⁸ canine mammary cancer,^{38, 39} and a variety of human neoplasias.⁴⁰ Case and control populations were compared in terms of weight distribution and no significant difference was found. It would have been more informative to compare body condition score between the two groups to ensure obesity was not

contributing to development of PAHS, however this was not consistently available in medical records.

In conclusion, this study confirms there is a relationship between prior joint disease and PAHS, particularly in dogs with cranial cruciate ligament rupture. Further study is needed to evaluate the potential causal role of inflammation in the development of PAHS.

Acknowledgments:

We would sincerely like to thank the many referring veterinarians and owners of patients in this study who kindly provided records and details regarding patient history.

Funding:

Funding was provided by the University of Minnesota Animal Cancer Care and Research Program and University of Tennessee Small Animal Clinical Sciences Oncology Fund.

Conflicts of Interest:

The authors declare no potential conflicts of interest.

References:

1. Affolter VK and Moore PF. Localized and disseminated histiocytic sarcoma of dendritic cell origin in dogs. *Vet Pathol.* 2002; **39**(1): 74-83.
2. Moore PF, Affolter VK and Vernau W. Canine hemophagocytic histiocytic sarcoma: a proliferative disorder of CD11d+ macrophages. *Vet Pathol.* 2006; **43**(5): 632-45.

3. Fulmer AK and Mauldin GE. Canine histiocytic neoplasia: an overview. *Can Vet J.* 2007; **48**(10): 1041-3, 6-50.
4. Fidel J, Schiller I, Hauser B, *et al.* Histiocytic sarcomas in flat-coated retrievers: a summary of 37 cases (November 1998-March 2005). *Vet Comp Oncol.* 2006; **4**(2): 63-74.
5. Moore PF. A review of histiocytic diseases of dogs and cats. *Vet Pathol.* 2014; **51**(1): 167-84.
6. Dervisis NG, Kiupel M, Qin Q and Cesario L. Clinical prognostic factors in canine histiocytic sarcoma [published online ahead of print June 23, 2016]. *Vet Comp Oncol.* doi: 10.1111/vco.12252.
7. Klahn SL, Kitchell BE and Dervisis NG. Evaluation and comparison of outcomes in dogs with periarticular and nonperiarticular histiocytic sarcoma. *J Am Vet Med Assoc.* 2011; **239**(1): 90-6.
8. Craig LE, Julian ME and Ferracone JD. The diagnosis and prognosis of synovial tumors in dogs: 35 cases. *Vet Pathol.* 2002; **39**(1): 66-73.
9. Padgett GA, Madewell BR, Keller ET, Jodar L and Packard M. Inheritance of histiocytosis in Bernese mountain dogs. *J Small Anim Pract.* 1995; **36**(3): 93-8.
10. Skorupski KA, Clifford CA, Paoloni MC, *et al.* CCNU for the treatment of dogs with histiocytic sarcoma. *J Vet Intern Med.* 2007; **21**(1): 121-6.
11. Skorupski KA, Rodriguez CO, Krick EL, Clifford CA, Ward R and Kent MS. Long-term survival in dogs with localized histiocytic sarcoma treated with CCNU as an adjuvant to local therapy. *Vet Comp Oncol.* 2009; **7**(2): 139-44.

12. Dobson J, Hoather T, McKinley TJ and Wood JL. Mortality in a cohort of flat-coated retrievers in the UK. *Vet Comp Oncol.* 2009; **7**(2): 115-21.
13. Dobson JM. Breed-predispositions to cancer in pedigree dogs. *ISRN Vet Sci.* 2013; **2013**: 941275. doi: 10.1155/2013/94275.
14. Ruple A and Morley PS. Risk Factors Associated with Development of Histiocytic Sarcoma in Bernese Mountain Dogs. *J Vet Intern Med.* 2016; **30**(4): 1197-203.
15. van Kuijk L, van Ginkel K, de Vos JP, *et al.* Peri-articular histiocytic sarcoma and previous joint disease in Bernese Mountain Dogs. *J Vet Intern Med.* 2013; **27**(2): 293-9.
16. Cannon C, Borgatti A, Henson M and Husbands B. Evaluation of a combination chemotherapy protocol including lomustine and doxorubicin in canine histiocytic sarcoma. *J Small Anim Pract.* 2015; **56**(7): 425-9.
17. Harasen GL and Simko E. Histiocytic sarcoma of the stifle in a dog with cranial cruciate ligament failure and TPLO treatment. *Vet Comp Orthop Traumatol.* 2008; **21**(4): 375-7.
18. Johnston SA. Osteoarthritis. Joint anatomy, physiology, and pathobiology. *Vet Clin North Am Small Anim Pract.* 1997; **27**(4): 699-723.
19. Rychel JK. Diagnosis and treatment of osteoarthritis. *Top Companion Anim Med.* 2010; **25**(1): 20-5.
20. Matyas JR, Atley L, Ionescu M, Eyre DR and Poole AR. Analysis of cartilage biomarkers in the early phases of canine experimental osteoarthritis. *Arthritis Rheum.* 2004; **50**(2): 543-52.
21. Garvican ER, Vaughan-Thomas A, Innes JF and Clegg PD. Biomarkers of cartilage turnover. Part 1: Markers of collagen degradation and synthesis. *Vet J.* 2010; **185**(1): 36-42.

22. Hayashi K, Manley PA and Muir P. Cranial cruciate ligament pathophysiology in dogs with cruciate disease: a review. *J Am Anim Hosp Assoc.* 2004; **40**(5): 385-90.
23. Michelsen J. Canine elbow dysplasia: aetiopathogenesis and current treatment recommendations. *Vet J.* 2013; **196**(1): 12-9.
24. Abadie J, Hedan B, Cadieu E, *et al.* Epidemiology, pathology, and genetics of histiocytic sarcoma in the Bernese mountain dog breed. *J Hered.* 2009; **100 Suppl 1**: S19-27.
25. Coussens LM and Werb Z. Inflammation and cancer. *Nature.* 2002; **420**(6917): 860-7.
26. Hewicker-Trautwein M, Carter SD, Bennett D and Kelly DF. Immunocytochemical demonstration of lymphocyte subsets and MHC class II antigen expression in synovial membranes from dogs with rheumatoid arthritis and degenerative joint disease. *Vet Immunol Immunopathol.* 1999; **67**(4): 341-57.
27. Lemburg AK, Meyer-Lindenberg A and Hewicker-Trautwein M. Immunohistochemical characterization of inflammatory cell populations and adhesion molecule expression in synovial membranes from dogs with spontaneous cranial cruciate ligament rupture. *Vet Immunol Immunopathol.* 2004; **97**(3-4): 231-40.
28. Galloway RH and Lester SJ. Histopathological evaluation of canine stifle joint synovial membrane collected at the time of repair of cranial cruciate ligament rupture. *J Am Anim Hosp Assoc.* 1995; **31**(4): 289-94.
29. Doom M, de Bruin T, de Rooster H, van Bree H and Cox E. Immunopathological mechanisms in dogs with rupture of the cranial cruciate ligament. *Vet Immunol Immunopathol.* 2008; **125**(1-2): 143-61.

30. Lipowitz AJ, Wong PL and Stevens JB. Synovial membrane changes after experimental transection of the cranial cruciate ligament in dogs. *Am J Vet Res.* 1985; **46**(5): 1166-70.
31. Comerford EJ, Smith K and Hayashi K. Update on the aetiopathogenesis of canine cranial cruciate ligament disease. *Vet Comp Orthop Traumatol.* 2011; **24**(2): 91-8.
32. Bleedorn JA, Greuel EN, Manley PA, *et al.* Synovitis in dogs with stable stifle joints and incipient cranial cruciate ligament rupture: a cross-sectional study. *Vet Surg.* 2011; **40**(5): 531-43.
33. Cook CR and Cook JL. Diagnostic imaging of canine elbow dysplasia: a review. *Vet Surg.* 2009; **38**(2): 144-53.
34. Mason DR, Schulz KS, Samii VF, *et al.* Sensitivity of radiographic evaluation of radio-ulnar incongruence in the dog in vitro. *Vet Surg.* 2002; **31**(2): 125-32.
35. Wagner K, Griffon DJ, Thomas MW, *et al.* Radiographic, computed tomographic, and arthroscopic evaluation of experimental radio-ulnar incongruence in the dog. *Vet Surg.* 2007; **36**(7): 691-8.
36. Adams P, Bolus R, Middleton S, Moores AP and Grierson J. Influence of signalment on developing cranial cruciate rupture in dogs in the UK. *J Small Anim Pract.* 2011; **52**(7): 347-52.
37. Harasen G. Patellar luxation: pathogenesis and surgical correction. *Can Vet J.* 2006; **47**(10): 1037-9.
38. Glickman LT, Schofer FS, McKee LJ, Reif JS and Goldschmidt MH. Epidemiologic study of insecticide exposures, obesity, and risk of bladder cancer in household dogs. *J Toxicol Environ Health.* 1989; **28**(4): 407-14.

39. Sonnenschein EG, Glickman LT, Goldschmidt MH and McKee LJ. Body conformation, diet, and risk of breast cancer in pet dogs: a case-control study. *Am J Epidemiol.* 1991; **133**(7): 694-703.
40. Tahergorabi Z, Khazaei M, Moodi M and Chamani E. From obesity to cancer: a review on proposed mechanisms. *Cell Biochem Funct.* 2016; **34**(8): 533-45.

Table 1: Comparison of patient demographics and prior joint disease between case and control populations. Fisher's exact tests were used to compare categorical data and two sample t tests were used to compare continuous data. Using univariate analysis, the only significant difference between PAHS and control populations was in incidence of prior joint disease. PAHS cases were 13.42 times as likely as the control population to have previous joint disease, in the tumor-affected joint.

	PAHS Patients	Control Patients
Number	28	46
Sex		Fisher's exact test p= 0.72
Male Intact	2 (7.1%)	4 (8.7%)
Male Castrated	12 (42.9%)	19 (41.3%)
Female Intact	1 (3.6%)	0 (0.0%)
Female Spayed	13 (46.4%)	23 (50.0%)
Age		Two sample t test p= 0.56
Median	8 years	8 years
Range	4-16 years	4-17 years
Mean	8.75 years	8.33 years
Breed		Fisher's exact test p= 0.67
Rottweiler	6 (21.4%)	8 (17.4%)
Golden Retriever	6 (21.4%)	9 (19.6%)
Labrador Retriever	6 (21.4%)	12 (26.1%)
Mixed Breed Dog	3 (10.7%)	6 (13.0%)
Flat Coated Retriever	2 (7.1%)	4 (8.7%)
English Bulldog	2 (7.1%)	2 (4.3%)
Australian Shepherd	1 (3.6%)	2 (4.3%)
Shih Tzu	1 (3.6%)	2 (4.3%)
Staffordshire Terrier	1 (3.6%)	1 (2.2%)
Weight		Two sample t test p= 0.20
Median	34.5 kg	29.8 kg
Mean	34.2 kg	30.5 kg

Table 2: Joint disease diagnoses in PAHS and control groups. Note that one patient in the stifle PAHS group and two in the stifle control group had two separate joint disease diagnoses. Odds ratios were calculated using univariate analysis with prior joint disease as the dependent variable.

	PAHS (n=28)	Controls (n=46)
Patients with prior stifle disease	15/17 (88.2%)	3/27 (11.1%)
	OR = 64.0 (95% CI: 11.7-578.3), p<0.0001	
Cranial Cruciate Ligament Rupture	12	3
TPLO Repair	4	0
FLO Repair	1	0
Not Repaired	6	2
Unknown Repair Method	1	1
Medial Patellar Luxation	2	0
Other*	2	2
Patients with prior elbow disease	2/11 (18.2%)	2/19 (10.5%)
	OR = 1.9 (95% CI: 0.2-18.0), p=0.56	
Fragmented Medial Coronoid Process	0	1
Elbow Dysplasia	1	0
Other*	1	1
Total patients with prior joint disease	17/28 (60.7%)	5/46 (10.9%)
	OR = 13.42 (95% CI: 4.33-48.63), p<0.0001	
*Immune mediated polyarthritis (2), septic arthritis with arthrocentesis, joint swelling, trauma with elbow joint swelling and arthrocentesis, OCD lesion with arthroscopy		

Figure 1: PAHS cases with and without a prior joint disease diagnosis, arranged by breed

Author Manuscript