



Minerva Access is the Institutional Repository of The University of Melbourne

Author/s:

Oates, R; Jones, D; Foroudi, F; Gill, S; Ramachandran, P; Schneider, M; Lim Joon, M; Kron, T

Title:

Geographical miss of the prostate during image-guided radiotherapy with a 6-mm posterior expansion margin

Date:

2017-06-01

Citation:

Oates, R., Jones, D., Foroudi, F., Gill, S., Ramachandran, P., Schneider, M., Lim Joon, M. & Kron, T. (2017). Geographical miss of the prostate during image-guided radiotherapy with a 6-mm posterior expansion margin. *Journal of Medical Radiation Sciences*, 64 (2), pp.97-105. <https://doi.org/10.1002/jmrs.186>.

Persistent Link:

<https://hdl.handle.net/11343/260698>

License:

[CC BY-NC](#)

ORIGINAL ARTICLE

Geographical miss of the prostate during image-guided radiotherapy with a 6-mm posterior expansion margin

Richard Oates, MRadTher, BSc, SpecCertCR(Onc),^{1,2} Daryl Jones, BAppSc (MedRad),¹ Farshad Foroudi, MBBS, MPA, DMedSc, FRANZCR,^{3,4} Suki Gill, MBBS, MRCP, FRCR, FRANZCR,³ Prabhakar Ramachandran, PhD, MSc, MCA, DABR, MACPSEM, MARPS, MInstP,⁵ Michal Schneider, PhD, MRepSc, BSc, DipEd, GCertHealthProfEdu,² Michael Lim Joon, MBBS, FRANZCR,³ & Tomas Kron, PhD, FCCPM^{5,4}

¹Radiation Therapy Services, Peter MacCallum Cancer Centre, Bendigo, Australia

²Medical Imaging & Radiation Sciences, Monash University, Melbourne, Australia

³Radiation Oncology, Peter MacCallum Cancer Centre, Melbourne, Australia

⁴Sir Peter MacCallum Department of Oncology, The University of Melbourne, Parkville, Australia

⁵Physical Sciences, Peter MacCallum Cancer Centre, Melbourne, Australia

Keywords

Cone-beam CT, margins, motion, prostate cancer, radiotherapy

Correspondence

Richard Oates, Bendigo Radiotherapy Centre, PO Box 126, Bendigo, Victoria 3552, Australia. Tel: +61 3 5454 9234; Fax: +61 3 5454 9289; E-mail: richard.oates@petermac.org

Funding Information

No funding information is provided.

Received: 2 March 2016; Revised: 9 May 2016; Accepted: 13 June 2016

J Med Radiat Sci **64** (2017) 97–105

doi: 10.1002/jmrs.186

Abstract

Introduction: Our department commonly uses a planning target volume (PTV) expansion of 6 mm posterior and 1 cm in all other directions when treating prostate cancer patients with image-guided radiotherapy (IGRT). This study aimed to test the adequacy of this PTV expansion by assessing geographical miss of the prostate on post-treatment cone-beam CT (CBCT) and identify those at risk of geographical miss. **Methods:** Twenty-two prostate cancer patients receiving IGRT with implanted fiducial markers underwent daily pre-treatment orthogonal kV imaging followed by a post-treatment CBCT for a total of 432 fractions. The prostate was outlined on all CBCTs. For each imaging set, the volume of geographic miss was measured by subtracting the PTV from the planning CT and prostate volume on the post-treatment CBCT. **Results:** The prostate volume moved outside the PTV by >0.01 cc in 9% of fractions (39/432). This occurred in 13 (59%) of 22 patients. Large prostates >40 cc and >50 cc had significantly more geographical miss events (both $P < 0.001$). Changes in rectal filling appear to be responsible for prostate motion/deformation in 82% (32/39) of fractions. **Conclusions:** Our analysis suggests that, despite IGRT, prostate PTV margins are not adequate in some patients, particularly those with large prostates. PTV margins may be reduced in some other patients. Prostate rotation and deformation play an important role in setting margins and may not always be represented accurately by fiducial marker displacements. Individualised and adaptive margins for prostate cancer patients should be a priority for future research.

Introduction

One challenging technical aspect of prostate cancer radiotherapy is prostate motion. Interfraction motion that occurs between fractions is responsible for the greatest amount of error in prostate treatments due to systematic errors and anatomical variations.¹ Meanwhile, intrafraction motion, motion which occurs during the treatment fraction, is responsible for short-duration, small, but significant deviations in prostate position.^{2,3} The greatest cause of

intrafraction prostate motion during external beam radiotherapy is changes in the rectal volume.^{2,4,5}

The introduction of image-guided radiotherapy (IGRT) has reduced the impact of interfraction prostate motion, while improving treatment accuracy and reducing treatment side effects.⁶ However, in many centres the margins used during IGRT are still largely based on historic practice from pre-IGRT era. Our departmental clinical protocols currently recommend a clinical target volume (CTV) to planning target volume (PTV)

expansion of 0.5–0.7 cm posterior and 1 cm in all other directions. The posterior expansion has traditionally been reduced as a compromise between covering prostate motion and limiting treatment toxicity.⁷ These PTV expansions have been used in large clinical studies,^{8–10} but need reviewing in the IGRT setting.

With the move to treatment alignment using electromagnetic transponders, further reduction in PTV expansions have been proposed.^{3,11,12} However, the use of electromagnetic transponders without imaging information and correcting the treatment alignment using only translational information may not account for the effect of prostate rotation and deformation.^{13,14}

This study had multiple aims. First, to use post-treatment cone-beam CTs (CBCT) to test the adequacy of our most commonly used CTV to PTV expansion of 0.6 cm posterior and 1 cm in all directions for prostate cancer patients. Second, to investigate the relationship between fiducial marker motion and the rotation/deformation of prostate contoured on CBCT. Third, to determine the cause of prostate displacements, rotations and deformation, and to determine which sub-group of patients were at risk of geographical miss.

Method

Treatment protocol

This prospective study was approved by the Peter MacCallum Cancer Centre Human Research Ethics Committee. Twenty-two prostate cancer patients were treated between February 2010 and July 2011. Some participants followed an anti-flatulent diet intervention with psyllium as a bulk-forming laxative, a full description of the diet intervention has been reported previously.¹⁵ Eligible participants were ≥ 50 years of age, ECOG performance status of 0–2 and had biopsy proven prostate adenocarcinoma, stage T1–T3b. All participants had three gold seed fiducials implanted for IGRT.

All participants were prescribed radiotherapy of 74–78 Gy in 2 Gy fractions. Planning and treatment were in the supine position with a Combifix (CIVCO Medical Solutions, Kalona, IA) for pelvis immobilisation. Kilovoltage (kV) orthogonal images were acquired at the beginning of each fraction and an online correction protocol was applied matching to the gold seed fiducial markers with a 0-mm tolerance.¹⁶ CBCT images were acquired at the end of treatment for fractions 1–5 and then every second fraction.

Contouring

De-identified data sets were contoured by one investigator (D. Jones). All contouring was performed

using FOCAL v4.62 (Elekta, Stockholm, Sweden). The external surface of the rectum was contoured from 9 mm inferior to the superior border of the treatment field to 9 mm superior to the inferior border of the treatment field. The prostate (i.e. CTV) was contoured on the planning CT and CBCTs as the external surface of the prostate from the base to the apex. The seminal vesicles were not contoured for this study. Prostate rotation was measured using the contours as outlined in Owen *et al.*¹⁷

Adequacy of PTV margin

A priori, we considered a margin to be adequate if the PTV expansion covered all CBCT prostate displacements for 90% of patients, which follows a simple interpretation of van Herk's recommendation that 'for 90% of the patient population, the minimum dose to the CTV must be 95% of the nominal dose (i.e. the dose at the specification point) or higher'.¹⁸ We assessed the number of times where the prostate (CBCT-CTV) displaced beyond the PTV as seen on post-treatment CBCT and defined this as a geographical miss. Where the standard margin was inadequate, we created a new CTV to PTV expansion, increasing the margins in 1 mm steps in the required direction (posterior or all other directions) until the PTV covered the CTV for all CBCTs.

Volume of prostate geographical miss

The volume of the prostate outside the PTV at the end of each treatment fraction was measured by creating a structure subtracting the CBCT-CTV from the PTV using FOCAL. Only volumes of 0.01 cc or greater were measurable with FOCAL.

Direction of excursion

The direction of the CBCT-CTV outside of the PTV was recorded by identifying the location of the geographical miss. For each fraction, this was compared to the greatest direction of intrafraction prostate motion, recorded as the displacement of the fiducial markers on post-treatment CBCT imaging from online correction at the start of the treatment fraction by one investigator (R. Oates).

Cause of excursion

One investigator (R. Oates) assessed the cause of prostate displacement. The CBCT rectum contour was compared to the planning rectum contour to determine if rectal distortion (i.e. changes in rectal volume or shape from the planning rectum) may account for prostate motion. The volume and location of the bladder were also visually

compared to the planning volume to determine if prostate displacement was impacted by bladder filling.

Predictors of patients 'at risk' of geographical miss

To identify potential predictors of patients at risk of geographical miss we followed the suggestions by Hatton *et al.*¹⁴ We aimed to identify a large prostate volume and large rectal cross-sectional area (CSA) at planning which may put patients in an 'at risk' sub-group.

Statistical methods

Descriptive statistics were used for all data assessed. To test for 'at risk' sub-groups a chi-square test of independence was used to compare the proportion of prostates above or below the large prostate threshold, grouped with a geographical miss or no miss. The other sub-group compared the proportion of those above or below the large CSA threshold, and grouped with a geographical miss or no miss. This assumes each fraction and prostate size is independent of all others and there is no patient effect. All tests were performed at $\alpha = 0.05$, using R software v2.15.1 (www.r-project.org/).

Results

CBCT data sets were available for 432 fractions from 22 patients with a median (range) of 20 (16–22) CBCT per patient. Fifty (10%) of the 482 planned CBCT scans were unusable due to image quality or data capture failure (e.g. pre-treatment alignment offsets), or were missed due to equipment failures (primarily a CBCT reconstructor failure). Eleven patients received 3D conformal radiotherapy (3DCRT), the remaining 11 received intensity modulated radiotherapy (IMRT). The mean (\pm standard deviation) treatment time from kV imaging to CBCT capture was 7 min (± 2 min).

Adequacy of PTV margin

The prostate displaced outside the PTV by >0.01 cc in 39/432 (9%) of fractions (Table 1). This occurred in 13 (59%) of 22 patients. Only five geographical miss fractions were longer than 9 min (mean plus standard deviation fraction duration) and all were less than 12 min, indicating a small impact of fraction duration. When the posterior margin was expanded to 7 mm, 15 (68%) of 22 patients received adequate coverage. Expanding the posterior margin to 8 mm covered the remaining posterior prostate displacements in all patients. Three patients required expansions in other

directions to cover anterior and superior excursions, with two patients requiring 12 mm expansions to cover the prostate displacement (Table 2). Overall, for the PTV to cover displacements, rotations and deformations for 90% of patients, an expansion of 11 mm in all directions except 8 mm posterior would be required.

Volume of prostate geographical miss

The median (range) of prostate volume displaced beyond the PTV was 0.06 cc (0.01–0.79). The median (range) prostate volume in our patient cohort was 30.85 cc (11.8–54.3), indicating the proportion of prostate geographical miss was relatively small. In 90% (35/39) of cases the geographical miss volume was less than 1%. Only one fraction saw the volume of geographical miss greater than 2%. Table 3 indicates that within patients there may be a trend for prostate intrafraction displacement and, therefore, a variation in the margin required to cover this motion. However, the incidence of geographical miss varied during the course of treatment in each patient. Using early fractions to predict displacement later in treatment would be ineffective for most patients. This indicates that daily margin assessment is required and a daily adaptive treatment approach would be best suited to modifying margins according to individual patient needs.

Direction of excursion

The direction of prostate geographical miss agreed with the fiducial marker shift in 85% (33/39) of fractions. The direction of fiducial marker displacement contradicted the prostate geographical miss direction four times in one patient. This was due to the posterior prostate apex moving beyond the PTV while the superior aspect of the prostate had rotated forwards. In another case, prostate rotation was also responsible for geographical miss where the prostate base rotated posteriorly while the apex was displaced anterior. The last case appeared to be due to prostate deformation where the posterior edge of the prostate displaced outside the PTV, while there was a 1-mm anterior displacement of the seeds. In this case, the rectal contents had 'flattened' the prostate.

Cause of excursion

Rectal changes appeared to be responsible for geographical misses in 82% (32/39) of fractions, with the remaining potentially impacted by the bladder. The changes in the rectum appeared to rotate and/or deform

Table 1. Details of prostate geographical miss for 432 fractions in 22 patients receiving radical prostate radiotherapy.

Patient	CBCT #	Volume outside PTV (cc)	Direction	Intrafraction displacement			Rotation (°)	Agree with fiducial displacement?
				L-R	S-I	A-P		
1	CBCT18	0.04	Post	0	0	0	-22	Yes
2	CBCT17	0.03	Post-Inf	0.1	-0.3	-0.1	-3	Yes
2	CBCT18	0.11	Post-Inf	0	-0.2	-0.4	9	Yes
2	CBCT19	0.09	Post	0.1	-0.4	-0.6	4	Yes
3	CBCT09	0.02	Post-Sup-Lat	-0.3	0	0.2	30	Yes
3	CBCT10	0.02	Post	0.1	0	-0.2	20	Yes
7	CBCT07	0.06	Ant	0.2	0	0.1	12	Yes
7	CBCT08	0.18	Ant	0.1	0	0	1	Yes
9	CBCT22	0.15	Post	0	-0.2	-0.3	9	Yes
11	CBCT03	0.02	Post	-0.1	0.1	-0.1	7	Yes
11	CBCT05	0.03	Post	0	0	0	-6	Yes
11	CBCT06	0.07	Post	-0.2	-0.1	0	-10	Yes
11	CBCT09	0.04	Post	0.1	0	0.1	3	No
11	CBCT17	0.01	Post	0.1	0	0	7	Yes
12	CBCT15	0.02	Post	0.1	0.1	-0.1	0	Yes
12	CBCT19	0.08	Post	-0.1	0	-0.3	-5	Yes
15	CBCT18	0.61	Ant-Sup	-0.1	0.6	0.5	-10	Yes
15	CBCT19	0.06	Post-Sup-Lat	-0.1	0.3	0.2	-16	No
17	CBCT02	0.07	Post	-0.2	-0.4	-0.5	1	Yes
17	CBCT03	0.10	Post-Inf	-0.2	-0.3	-0.2	12	Yes
17	CBCT07	0.02	Post-Inf	-0.3	-0.3	-0.4	3	Yes
18	CBCT02	0.08	Post	-0.1	-0.2	-0.3	3	Yes
18	CBCT04	0.03	Post	0.1	-0.1	-0.3	3	Yes
19	CBCT03	0.17	Post-Sup	0	0	-0.2	-1	Yes
19	CBCT10	0.05	Post-Sup	-0.1	0.5	0.3	30	Yes
19	CBCT14	0.03	Post	-0.2	0	-0.2	13	Yes
19	CBCT15	0.06	Post	-0.1	0	-0.2	31	Yes
19	CBCT17	0.02	Post-Sup-Lat	-0.2	-0.1	-0.4	9	Yes
19	CBCT19	0.79	Post	0	0	-0.3	18	Yes
21	CBCT02	0.63	Post-Inf	0	-0.2	0.1	7	Yes
21	CBCT03	0.63	Post-Inf	0	0.1	0.3	14	No
21	CBCT05	0.47	Post-Inf	0	0.1	0.3	26	No
21	CBCT07	0.05	Post-Inf	0	0	-0.2	9	Yes
21	CBCT08	0.09	Post-Inf	0.2	0	0.2	10	No
21	CBCT10	0.04	Post	0.1	0	0.1	18	No
21	CBCT16	0.20	Post	0.1	0	0	8	Yes
22	CBCT09	0.02	Post	-0.1	-0.3	-0.4	-3	Yes
22	CBCT14	0.04	Ant-Sup	0.2	0.5	0.6	8	Yes
22	CBCT16	0.25	Ant-Sup	0.2	0.9	0.9	7	Yes

Displacements: L = +ve, S = +ve, A = +ve. Rotations: +ve represents the base of the prostate rotating anteriorly from the planned angle. CBCT, cone-beam CT; PTV, planning target volume; cc, cubic centimetres; Ant, anterior; Post, posterior; Sup, superior; Inf, inferior; Lat, lateral.

the prostate volume in most cases, with prostate rotations of ≥ 10 degrees evident in 41% (16/39) of geographical misses. All geographical misses due to bladder impacts were apparent in patient 21 (Table 1). His very large bladder at treatment compared to a small bladder at planning CT appeared to displace the prostate inferiorly in conjunction with a large expansion of the superior rectum (Fig. 1). His seed placement was also not ideal with the seeds clustered at the prostate base, poorly representing the apex.

Predictors of patients 'at risk' of geographical miss

Hatton *et al.*¹⁴ suggested that patients with a prostate of >50 cc were more likely to see the prostate dose compromised. Three patients in our study were above this large prostate threshold and these three patients comprised 36% (14/39) of all geographical miss events. The proportion of geographic miss in patients with >50 cc prostate volumes (14 out of 59) was significantly

Table 2. PTV expansion required to cover all prostate displacements on post-treatment CBCT for 22 patients.

Patient	Diet intervention	Prostate volume (cc)	Planning rectum CSA (cm ²)	Margin required for 95% TD	
				All directions (except posterior) (mm)	Posterior (mm)
1	No	14.8	5.5	10	7
2	Yes	27	9.5	10	8
3	Yes	20.7	6.8	10	7
4	No	25.5	6.3	10	6
5	No	32	7.4	10	6
6	Yes	11.8	6.3	10	6
7	Yes	36.8	5.6	11	6
8	No	31.1	9.6	10	6
9	No	22	6.8	10	8
10	Yes	26.3	3.5	10	6
11	Yes	51.2	7.5	10	8
12	No	39.1	8.9	10	8
13	Yes	22	6.2	10	6
14	Yes	26.8	4.3	10	6
15	No	40.2	6.1	12	8
16	Yes	27.5	6.7	10	6
17	No	32.9	6	10	8
18	No	54.3	3.9	10	8
19	No	41.1	6.1	10	8
20	No	33.3	6.3	10	6
21	No	50.1	4.1	10	8
22	Yes	30.6	6.5	12	7

Bold indicate cases where the margin was changed from standard due to geographic miss on CBCT. CSA, cross-sectional area; TD, target dose; cc, cubic centimetres; CBCT, cone-beam CT; PTV, planning target volume.

Table 3. Patients with the same prostate geographic miss location in multiple fractions, leading to a risk of inadequate treatment dose.

Patient	Prostate location	Number of fractions
2	Posterior apex	3
11	Posterior base	5
17	Posterior apex	3
19	Posterior apex	3
19	Posterior base	4
21	Posterior apex	7

different to those with small prostate volumes (25 out of 373) ($P < 0.001$). If a threshold of >40 cc was used to define a large prostate, five patients were above the threshold. In this case, the proportion of geographic miss in patients with large (>40 cc) prostate volumes (22 out of 59) was significantly different to those with small prostate volumes (17 out of 373) ($P < 0.001$). These five

patients represented 56% (22/39) of all geographical miss events.

No 'at risk' relationship was found with planning rectal CSA. All patients had a rectal CSA below 10 cm² at planning due to our simulation protocol.¹⁹

Discussion

This study uses anatomical data from CBCT to suggest that a PTV expansion margin of 0.6 cm posterior and 1 cm in all other directions from the prostate may not be adequate for all patients in the current IGRT application. Our data suggest that there is variation in prostate motion in a typical population and that individualised margins with an adaptive treatment approach may be beneficial. Our data also suggest that prostate deformation and rotation play a role in at least 41% of geographical miss events. Patients with a large prostate may be 'at risk' of geographical miss and may require a larger PTV margin. Prostate rotation and deformation may not be accurately represented by fiducial marker translations, particularly if the markers are not optimally placed.

Our findings are supported by an investigation using a series of three cine MRI scans on six patients.⁵ The authors found that prostate motion was well characterised by rotation and deformation, with the prostate apex more likely to be stable and rotation of the prostate base common. This indicates the importance of accurate fiducial marker placement, with a marker close to each of the prostate base and apex to demonstrate rotation.

A study of repeated MRI scans in 25 patients assessed prostate deformation and rotation relative to fiducial markers, suggesting that these events were not insignificant, with the difference in prostate surface and fiducial marker location showing a standard deviation of 1.5 mm.¹³ That study demonstrated deformations of the prostate surface of up to 13 mm from the planned prostate surface when only translational alignment of the fiducial markers were used.¹³ MRI offers improved prostate delineation and demonstrated substantial prostate deformation, particularly in patients who had undergone a trans-urethral resection of the prostate and in the event of uncharacteristic rectal and/or bladder filling. Our data, with a greater number of fractions, suggests there is substantial prostate deformation/rotation which appears to be dependent on bladder and rectal filling. However, due to lower image quality, our prostate delineation is less accurate than those obtained on MRI.

Similar to our study, Hatton et al.¹⁴ used a series of repeat post-treatment CBCTs on 12 patients to assess prostate displacement during a treatment fraction and the impact on target coverage with a 7-mm uniform margin.

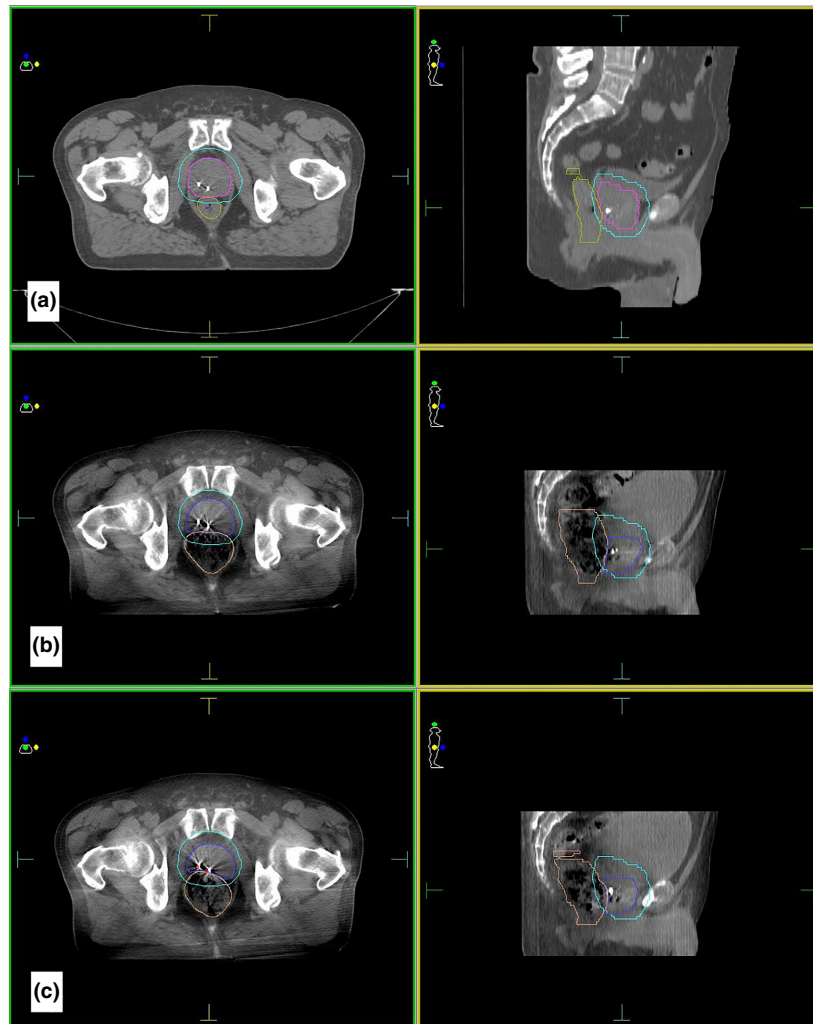


Figure 1. Pelvic anatomy for patient 21. (A) At planning with the clinical target volume (including seminal vesicles) outlined in magenta, the planning target volume in cyan and the rectum in gold. (B) Fraction 5 showing the change to the prostate location in indigo and the rectal volume in pale brown. (C) Fraction 8 showing the change to the prostate location in blue and the rectal volume in brown with the anterior displacement of the gold seeds demonstrated relative to the planned location in red.

They found 4 (33%) of 12 patients had compromised target dose coverage, partly due to intrafraction prostate displacement and mostly due to deformation. Similar to our findings, they found that patients with larger prostates are more likely to have compromised prostate dose.

While Hatton *et al.*¹⁴ and our study suggested changes in the prostate location on post-treatment CBCT were due to intrafraction motion, neither study assessed the impact of prostate rotation/deformation on PTV coverage with pre-treatment kV fiducial alignment. Nichol *et al.*¹³ suggest that some fractions may have a prostate geographical miss at treatment commencement. Our study highlighted the importance of bladder filling at planning being representative of bladder filling during

treatment. Our simulation protocol requires a rectum diameter of approximately 4 cm or less, and the absence of excessive gas or faeces at planning CT.¹⁹ We use the same rectal filling assessment on treatment and will ask patients to empty their bowels if a large amount of gas or faeces is evident on pre-treatment kV imaging. We do not have a policy for prostate rotation, which is often evident on lateral pre-treatment images.

Methods should be developed to determine the impact of prostate rotation on PTV coverage and to define individualised thresholds of rotation before intervention. Planning software image fusion functions could be utilised to determine how much rotation of the fiducial centre of mass around the right–left direction could occur before the patient's CTV breaches the PTV contour

(assuming the prostate rotates as a solid structure). Pre-treatment lateral imaging could use seed segmentation to estimate prostate rotation around the right–left direction. Alternatively, rotation could be more accurately estimated using pre-treatment CBCT imaging with fiducial tracking,²⁰ radiofrequency transponder fiducials or by kilovoltage monitoring during treatment.²¹ If prostate rotation was larger than the patient determined threshold, then the patient could be asked to empty their rectum, or repositioned on a 6-df couch. If a trend of prostate rotation was identified, a repeat planning CT could check for seed migration and/or for replanning if the prostate is consistently rotated relative to the original plan.

Our most commonly used CTV to PTV expansion is 0.6 cm posterior and 1 cm in all other directions. This study suggests that larger margins may be more appropriate in some patients, that is patients with large prostates, and that an individualised approach to setting margins may be beneficial. While the volume of prostate geographical miss is small, the location of geographical miss was consistent in some patients. This could lead to under-dosing part of the prostate. Historically, with 3DCRT, posterior geographical miss would result in a relatively small reduction in the dose received. However, with current rectal-sparing IMRT and VMAT techniques, the impact on prostate dose may be greater and could be of great concern for stereotactic ablative radiotherapy techniques with small margins and high conformity index.

Several papers have proposed small treatment margins with online correction protocols based on translations of electromagnetic transponder fiducials. Liztenberg *et al.*³ suggested margins of 1.4, 2.3 and 1.8 mm using inter-beam adjustment with a zero threshold and 1.3, 1.5 and 1.5 mm using intra-beam adjustment with a 3-mm threshold, in the L–R, A–P and S–I planes respectively. Su *et al.*¹¹ suggested 1.1, 2.3 and 1.8 mm margins with a 3-mm threshold correction and 0.5, 1.5 and 1.0 mm margins with a 2-min correction, in the L–R, A–P and S–I planes respectively. Sandler *et al.*¹² implemented PTV margins of 3–5 mm in 64 patients in their study. The margins suggested in these papers may not be adequate to account for prostate rotations and deformations, as recognised by some authors.²² One paper which accounts for rotations and translations proposed a uniform margin of 5 mm when used with a 3-mm online correction protocol and <10 degree rotation allowance.²³ This is in agreement with our findings that prostate geographical miss may not be represented by all fiducial translations (Table 1).

When IGRT to implanted fiducial markers is used, tight margins of 3 mm, 5 mm and 4 mm (L–R, A–P and S–I planes respectively) and a distended rectum at

planning have a significant negative impact on biochemical control of prostate cancer.²⁴ Clinical data indicated that a uniform 6-mm margin offers superior biochemical control to the previously used tight margins (25 patients in each group).²⁴ Our study did not investigate the possibility of margin reduction, which for many patients may be suitable in the L–R, S–I and anterior expansions.

Our study has several limitations. We considered the prostate only and did not include seminal vesicles which are more prone to movement.²⁵ We only captured the prostate location at the end of treatment, not the full intrafraction excursion of the prostate. As noted by Hatton *et al.*,¹⁴ the impact on dose delivered to the prostate could be considered ‘worst case’ as all motions of the prostate were not considered. It is likely that the location of post-treatment prostate geographical miss will have dwelled in a high-dose region before moving to a low-dose region, except where the prostate is grossly rotated from the start of the treatment fraction or where intrafraction motion was a large, long-lasting prostate displacement early in the fraction. These considerations are supported by Engels *et al.*,²⁴ whose clinical data suggest a 6-mm uniform margin would be suitable and by Li *et al.*,²⁶ who have demonstrated a small impact of intrafraction displacement on dose delivered to the prostate.

There may be some contouring error due CBCT image quality, particularly with contouring the prostate base and apex, which can be difficult to identify.²⁷ Due to this difficulty and reliance on surrounding anatomy, some contours may over-estimate the prostate boundaries, which again indicates worst case scenario. We minimised contouring uncertainty by having one contouring investigator and all CBCT-CTVs were similar to the planned volume. This study relates intrafraction displacements between kV/kV imaging and CBCT imaging, where CBCT ‘best fit’ matching offers greater error as not all fiducials can be visualised simultaneously. This study did not consider all treatment geographical miss events from all treatment fractions, which may overestimate/underestimate the impact on margins for some patients. Finally, some patients in this study underwent a diet intervention,¹⁵ although the data suggest any impact will be small (see Table 2).

From this study, we recommend a larger study to clearly identify if a large prostate is an ‘at-risk’ sub-group, or if the geographical miss events we observed for large prostate patients were simply due to patient effects. We recommend further investigation using cine MRI to confirm our results. If confirmed, hormone therapy could reduce the prostate volume for patients with large prostates. Alternatively, individualised margins and

thresholds for prostate rotations could be determined at planning, with larger margins potentially required for larger prostates. For future studies, pre-treatment CBCT imaging would allow soft tissue assessment of rotation and deformation of the prostate, bladder and rectum. An adaptive approach could select appropriate fractions needing not only larger PTV margins but also a smaller margin when the pre-treatment CBCTs indicate small prostates, stable bladders and rectums. Finally, while VMAT may reduce the fraction duration and risk of intrafraction motion, it will not preclude the risk of geographical miss from the start of the treatment fraction due to rotations/deformations.

Conclusion

Our study suggests that prostate CTV to PTV margins of 0.6 cm posterior and 1 cm in all other directions may not be adequate for all patients. Individualised margins would benefit some patients, with a larger margin potentially being more suitable for patients with a large prostate. The posterior margin was breached most frequently, therefore there is potential to reduce other margins. Prostate rotation and deformation play an important role in setting margins, and further investigation using cine MRI should quantify the impact. To assess prostate rotation, seed placement is critical to represent the prostate base and apex, and soft tissue assessment may play a role. Adaptive margins could potentially be implemented to account for fractions where the prostate is likely to have smaller or larger motions and/or large rotations.

Acknowledgements

The authors acknowledge the support of the Department of Radiation Oncology and Cancer Imaging at the Peter MacCallum Cancer Centre. Special thanks to the staff at the Bendigo Radiotherapy Centre for their assistance with the project.

Conflict of Interest

The authors declare no conflict of interest.

References

- Langen KM, Jones DTL. Organ motion and its management. *Int J Radiat Oncol Biol Phys* 2001; **50**: 265–78.
- Mah D, Freedman G, Milestone B, et al. Measurement of intrafractional prostate motion using magnetic resonance imaging. *Int J Radiat Oncol Biol Phys* 2002; **54**: 568–75.
- Litzenberg DW, Balter JM, Hadley SW, et al. Influence of intrafraction motion on margins for prostate radiotherapy. *Int J Radiat Oncol Biol Phys* 2006; **65**: 548–53.
- Padhani AR, Khoo VS, Suckling J, et al. Evaluating the effect of rectal distension and rectal movement on prostate gland position using cine MRI. *Int J Radiat Oncol Biol Phys* 1999; **44**: 525–33.
- Ghilezan MJ, Jaffray DA, Siewerdsen JH, et al. Prostate gland motion assessed with cine-magnetic resonance imaging (cine-MRI). *Int J Radiat Oncol Biol Phys* 2005; **62**: 406–17.
- Alexander EJ, Harris VA, Sohaib A, et al. Reducing the side effects of external beam radiotherapy in prostate cancer: Role of imaging techniques. *Imaging Med* 2012; **4**: 107–28.
- Prescribing, recording, and reporting photon-beam intensity-modulated radiation therapy (IMRT): Contents. *J ICRU* 2010; **10**: NP.
- Zelevsky MJ, Kollmeier M, Cox B, et al. Improved clinical outcomes with high-dose image guided radiotherapy compared with non-IGRT for the treatment of clinically localized prostate cancer. *Int J Radiat Oncol Biol Phys* 2012; **84**: 125–9.
- Jereczek-Fossa BA, Zerini D, Fodor C, et al. Acute toxicity of image-guided hypofractionated radiotherapy for prostate cancer: Nonrandomized comparison with conventional fractionation. *Urol Oncol* 2011; **29**: 523–32.
- Martin JM, Rosewall T, Bayley A, et al. Phase II trial of hypofractionated image-guided intensity-modulated radiotherapy for localized prostate adenocarcinoma. *Int J Radiat Oncol Biol Phys* 2007; **69**: 1084–9.
- Su Z, Zhang L, Murphy M, et al. Analysis of prostate patient setup and tracking data: Potential intervention strategies. *Int J Radiat Oncol Biol Phys* 2011; **81**: 880–7.
- Sandler HM, Liu P-Y, Dunn RL, et al. Reduction in patient-reported acute morbidity in prostate cancer patients treated with 81-Gy intensity-modulated radiotherapy using reduced planning target volume margins and electromagnetic tracking: Assessing the impact of margin reduction study. *Urology* 2010; **75**: 1004–8.
- Nichol AM, Brock KK, Lockwood GA, et al. A magnetic resonance imaging study of prostate deformation relative to implanted gold fiducial markers. *Int J Radiat Oncol Biol Phys* 2007; **67**: 48–56.
- Hatton JA, Greer PB, Tang C, et al. Does the planning dose–volume histogram represent treatment doses in image-guided prostate radiation therapy? Assessment with cone-beam computerised tomography scans. *Radiother Oncol* 2011; **98**: 162–8.
- Oates RW, Schneider ME, Lim Joon M, et al. A randomised study of a diet intervention to maintain consistent rectal volume for patients receiving radical radiotherapy to the prostate. *Acta Oncol* 2013; **53**: 569–71.

16. Thompson A, Fox C, Foroudi F, et al. Planning and implementing an implanted fiducial programme for prostate cancer radiation therapy. *J Med Imaging Radiat Oncol* 2008; **52**: 419–24.
17. Owen R, Kron T, Foroudi F, et al. Interfraction prostate rotation determined from in-room computerized tomography images. *Med Dosim* 2011; **36**: 188–94.
18. van Herk M, Remeijer P, Rasch C, et al. The probability of correct target dosage: Dose-population histograms for deriving treatment margins in radiotherapy. *Int J Radiat Oncol Biol Phys* 2000; **47**: 1121–35.
19. Stillie AL, Kron T, Fox C, et al. Rectal filling at planning does not predict stability of the prostate gland during a course of radical radiotherapy if patients with large rectal filling are re-imaged. *Clin Oncol* 2009; **21**: 760–7.
20. Gehrke C, Oates R, Ramachandran P, et al. Automatic tracking of gold seed markers from CBCT image projections in lung and prostate radiotherapy. *Phys Med* 2015; **31**: 185–91.
21. Tehrani JN, O'Brien RT, Poulsen PR, et al. Real-time estimation of prostate tumor rotation and translation with a kV imaging system based on an iterative closest point algorithm. *Phys Med Biol* 2013; **58**: 8517.
22. Litzenberg DW, Balter JM, Hadley SW, et al. Prostate intrafraction translation margins for real-time monitoring and correction strategies. *Prostate Cancer* 2012; **2012**: 1–6.
23. Olsen JR, Noel CE, Baker K, et al. Practical method of adaptive radiotherapy for prostate cancer using real-time electromagnetic tracking. *Int J Radiat Oncol Biol Phys* 2012; **82**: 1903–11.
24. Engels B, Soete G, Gevaert T, et al. Impact of planning target volume margins and rectal distention on biochemical failure in image-guided radiotherapy of prostate cancer. *Radiother Oncol* 2014; **111**: 106–9.
25. Mak D, Gill S, Paul R, et al. Seminal vesicle interfraction displacement and margins in image guided radiotherapy for prostate cancer. *Radiat Oncol* 2012; **7**: 139.
26. Li HS, Chetty IJ, Enke CA, et al. Dosimetric consequences of intrafraction prostate motion. *Int J Radiat Oncol Biol Phys* 2008; **71**: 801–12.
27. White EA, Brock KK, Jaffray DA, et al. Inter-observer variability of prostate delineation on cone beam computerised tomography images. *Clin Oncol* 2009; **21**: 32–8.