



Minerva Access is the Institutional Repository of The University of Melbourne

Author/s:

Pedersen, M;Makdissi, M;Parker, DM;Barbour, T;Abbott, DF;McCrory, P;Jackson, GD

Title:

Quantitative MRI as an imaging marker of concussion: evidence from studying repeated events

Date:

2020-10-01

Citation:

Pedersen, M., Makdissi, M., Parker, D. M., Barbour, T., Abbott, D. F., McCrory, P. & Jackson, G. D. (2020). Quantitative MRI as an imaging marker of concussion: evidence from studying repeated events. *European Journal of Neurology*, 27 (10), pp.e53-e54. <https://doi.org/10.1111/ene.14377>.

Persistent Link:

<https://hdl.handle.net/11343/275958>

DR. MANGOR PEDERSEN (Orcid ID : 0000-0002-9199-1916)

DR. DAVID F ABBOTT (Orcid ID : 0000-0002-7259-8238)

Article type : Letters to the Editor

### Title

Quantitative MRI as an imaging marker of concussion: evidence from studying repeated events.

### Running title

T2 relaxometry in concussion

### Authors

Mangor Pedersen<sup>1\*</sup>, Michael Makdissi<sup>1,2</sup>, Donna M. Parker<sup>1</sup>, Tim Barbour<sup>2</sup>, David F. Abbott<sup>1</sup>, Paul McCrory<sup>1</sup> & Graeme D. Jackson<sup>1,3</sup>.

1. The Florey Institute of Neuroscience and Mental Health, Melbourne, The University of Melbourne, Melbourne, VIC, Australia.
2. Olympic Park Sports Medicine Centre, Melbourne, VIC, Australia.
3. Department of Neurology, Austin Health, Melbourne, Australia.

\*Corresponding author: Mangor Pedersen, 245 Burgundy St., Heidelberg, VIC 3084, Australia.

Ph+61390357381; [mangor.pedersen@florey.edu.au](mailto:mangor.pedersen@florey.edu.au)

Title characters: 92

This is the author manuscript accepted for publication and has undergone full peer review but has not been through the copyediting, typesetting, pagination and proofreading process, which may lead to differences between this version and the [Version of Record](#). Please cite this article as [doi: 10.1111/ENE.14377](https://doi.org/10.1111/ENE.14377)

This article is protected by copyright. All rights reserved

Word count (incl. title page, body text, reference list and figure legend): 748/750

Figures: 1

**Keywords:** Concussion, MRI, T2-relaxometry, Football

**Background:**

We present a 23-year-old male professional Australian Football player who experienced a total of seven sports-related concussions between May-2015-March-2019, not associated with loss of consciousness (see supplementary materials for clinical details). Advanced brain imaging was performed after the latter four of these, revealing that his brain underwent a pattern of focal, but transient, increases in T2 relaxometry following concussive events.

**Methods:**

As T2 relaxometry[1] is sensitive to a range of relevant brain pathologies[2], we collected T2 relaxometry within 15 days of each event, and later recovery follow-up (seven datasets in total). The subject consented to participate in this study, which was approved by University of Melbourne ethics committee[3]. Routine T1- and T2-weighted imaging did not show any structural brain abnormalities, apart from a small incidental left thalamic punctuate lesion. T1 hippocampal volume was normal (see supplementary materials). For each MRI scan, we calculated voxel-based T2 relaxometry  $z$ -scores between the individual football player and 19 neurologically normal male controls (Adjusted T2). Multiple comparison correction was performed using the False Discovery Rate ( $q < 0.05$ )[4] (supplementary materials).

**Results:**

Adjusted T2 was significantly increased in left frontal cortices in all three definite concussions and the left inferior frontal cortex and putamen in two of these (Figure 1A). The probable concussion did not show these changes (Figure 1A–scan #6). The three follow-up scans did not show significant changes of this sort (Figure 1A–green).

---Figure 1---

**Discussion:**

We report a professional AFL footballer studied after multiple concussive events. Quantitative MRI T2 relaxometry showed a focal pattern including left frontal lobe brain regions affected in the first and subsequent concussions (Figure 1A–red). Increased T2-relaxometry is a marker of increased

water content in brain regions showing higher signal[5] related to pathologies such as gliosis, increased extracellular or intracellular edema or inflammation[2]. In this subject, areas with high T2 relaxometry may reflect transient post-concussive neuroinflammation or edema[6]. This abnormality persisted during symptomatic MRI scans and recovered towards the baseline between concussions (Figure 1C-green). At the time of his last scan, the ‘recovery’ T2 time was higher than the original baseline and some symptoms persisted. The similar distribution of the recurrent transient T2 increases may be because of an earlier injury that makes these brain regions vulnerable (i.e. a ‘second hit’ process). In all three definite concussions, T2 relaxometry showed brain abnormality (Figure 1A-first, second and fourth event). In the ‘potential’ case, no changes were found (Figure 1A-third event). T2 relaxometry may be a sensitive imaging marker of concussion, aiding clinical interpretation and diagnosis.

**Data Availability Statement:**

The data are not publicly available due to privacy and ethical restrictions.

**References:**

1. Pell GS, Briellmann RS, Waites AB, Abbott DF, Jackson GD. Voxel-based relaxometry: a new approach for analysis of T2 relaxometry changes in epilepsy. *NeuroImage*. 2004;21(2):707–13.

2. Larsson HB, Frederiksen J, Petersen J, Nordenbo A, Zeeberg I, Henriksen O, et al. Assessment of demyelination, edema, and gliosis by in vivo determination of T1 and T2 in the brain of patients with acute attack of multiple sclerosis. *Magn Reson Med.* 1989;11(3):337–48.
3. Jackson GD, Makdissi M, Pedersen M, Parker DM, Curwood EK, Farquharson S, et al. Functional brain effects of acute concussion in Australian rules football players. *J Concussion.* 2019;3:2059700219861200.
4. Benjamini Y, Hochberg Y. Controlling the False Discovery Rate: A Practical and Powerful Approach to Multiple Testing. *J R Stat Soc Ser B Methodol.* 1995;57(1):289–300.
5. Mamere AE, Saraiva L a. L, Matos ALM, Carneiro A. O, Santos AC. Evaluation of Delayed Neuronal and Axonal Damage Secondary to Moderate and Severe Traumatic Brain Injury Using Quantitative MR Imaging Techniques. *Am J Neuroradiol.* 2009;30(5):947–52.
6. Albrecht DS, Granziera C, Hooker JM, Loggia ML. In Vivo Imaging of Human Neuroinflammation. *ACS Chem Neurosci.* 2016;7(4):470–83.

**Figure legend:**

A) Red–Adjusted T2 <15 days after events; Green–Adjusted T2 >15 days after events. B) Average number of statistically significant Adjusted T2 voxels across MRI scans. C) Timeline of concussive events, and peak raw T2-relaxometry in the left frontal lobe.

**Acknowledgement:**

The authors wish to thank the AFL Doctors Association, AFL Players Association, Dr Patrick Clifton (AFL Operations and Innovations Manager) and Dr Peter Harcourt (AFL Medical Director) for their support of the project. We also thank all the recruited subjects who gave their valuable time to participate in this study. The Florey Institute of Neuroscience and Mental Health acknowledges the strong support from the Victorian Government and in particular the funding from the Operational

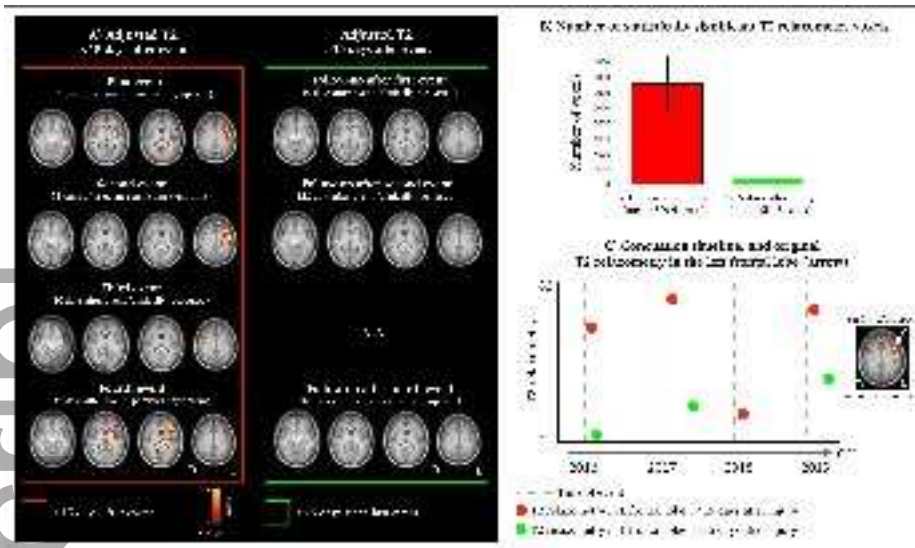
Infrastructure Support Grant. We also acknowledge the facilities, and the scientific and technical assistance of the National Imaging Facility (NIF), an Australian Government National Collaborative Research Infrastructure Strategy (NCRIS) capability, at the Florey node, and The Victorian Biomedical Imaging Capability (VBIC).

**Study Funding:**

This study was supported in part by the National Health and Medical Research Council (NHMRC) of Australia, grant number #1060312 (GJ Practitioner Fellowship) and #1026383 (PM Practitioner Fellowship). DA is supported by fellowship funding from the National Imaging Facility (NIF). Funding for the MRI scans was provided by the Australian Football League (AFL).

**Disclosure of conflict of interest:**

Dr Paul McCrory is a co-investigator, collaborator, or consultant on grants relating to mild TBI funded by several governmental organizations. He is co-chair of the International Concussion in Sport Group. He has been reimbursed by the government, professional scientific bodies, and sporting bodies for travel costs related to presenting research on mild TBI and sport-related concussion at meetings, scientific conferences, and symposiums. He received consultancy fees in 2010 from Axon Sports (US) for the development of educational material (which was not renewed) and has received research funding since 2001 from CogState Inc. He does not hold any individual shares in any company related to concussion or brain injury assessment or technology. He did not receive any form of financial support directly related to this manuscript. Dr. Michael Makdissi is a consultant Sport and Exercise Medicine physician at Olympic Park Sports Medicine Centre and team physician for the Hawthorn football club (AFL). He is a member of the International Concussion in Sport Group. He receives research funding from the AFL and non-financial research support from CogState Pty Ltd. He has attended meetings organised by the International Olympic Committee (IOC), National Football League (USA), National Rugby League (Australia) and FIFA (Switzerland); however, has not received any payment, research funding, or other monies from these groups other than for travel costs. He is an honorary member of concussion working/advisory groups for AFL, Australian Rugby Union, and World Rugby. Dr Pedersen reports no disclosures. Ms Parker reports no disclosures. Dr Barbour reports no disclosures. A/Prof Abbott reports no disclosures. Prof Jackson reports no disclosures.



ene\_14377\_f1.tiff